

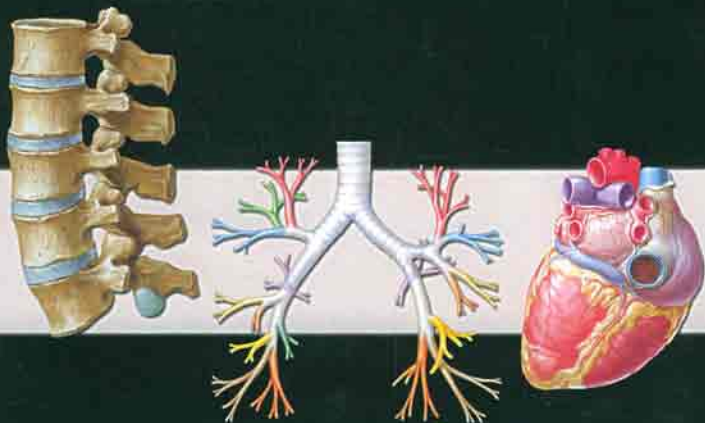
第3版

奈特

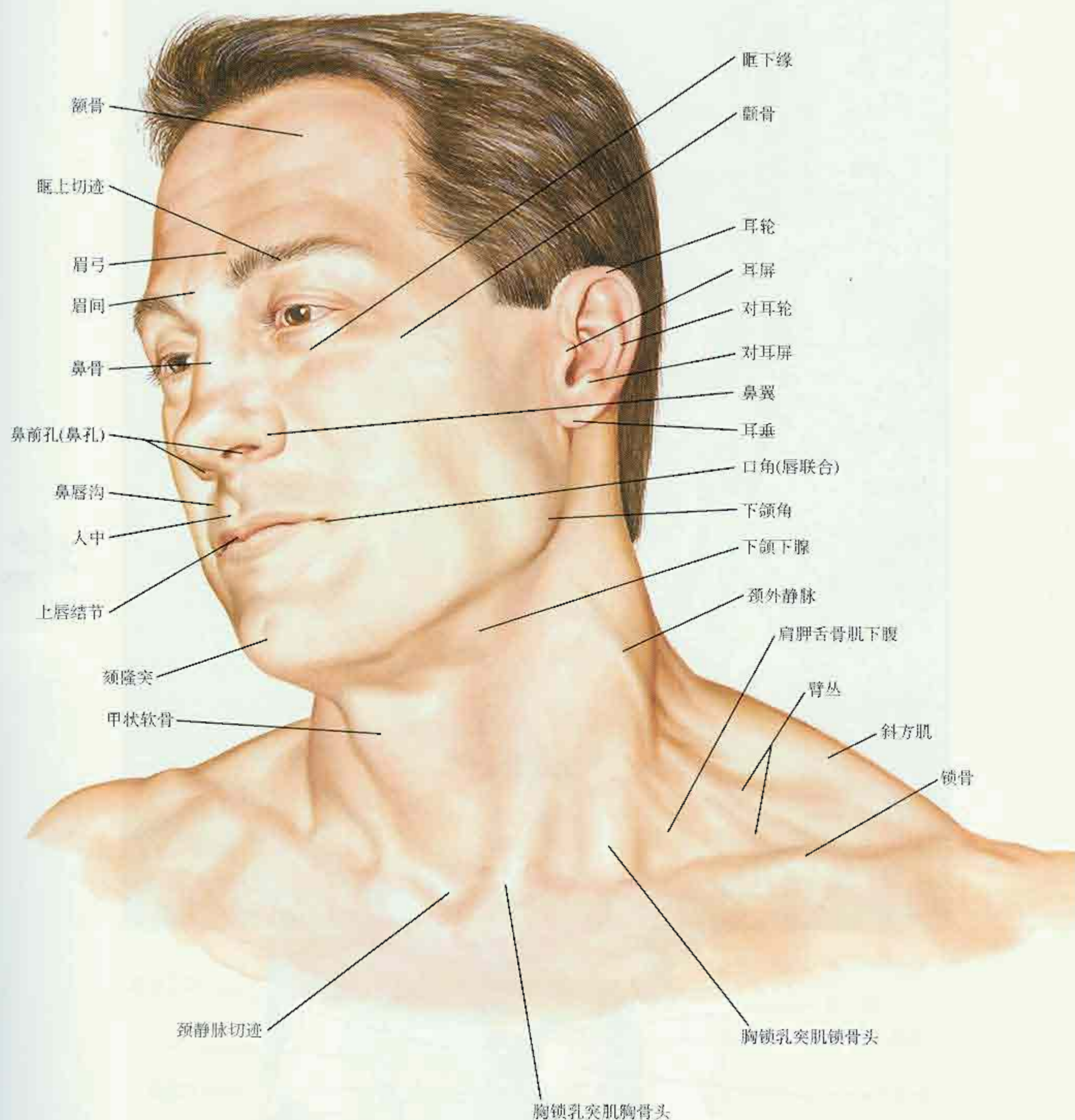
人体解剖彩色图谱

Atlas of Human Anatomy

原著 Frank H. Netter
主译 王怀经

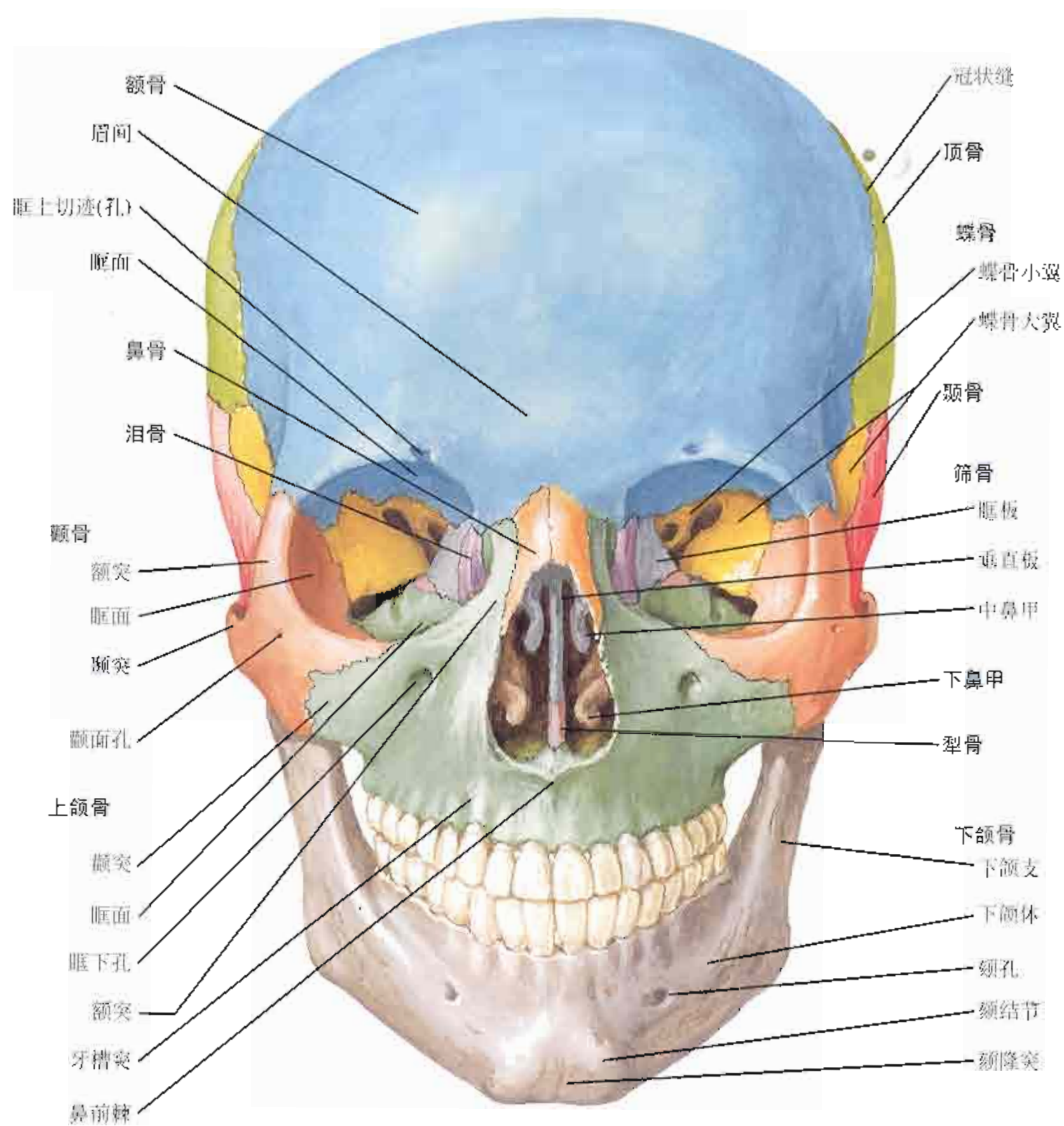


人民卫生出版社

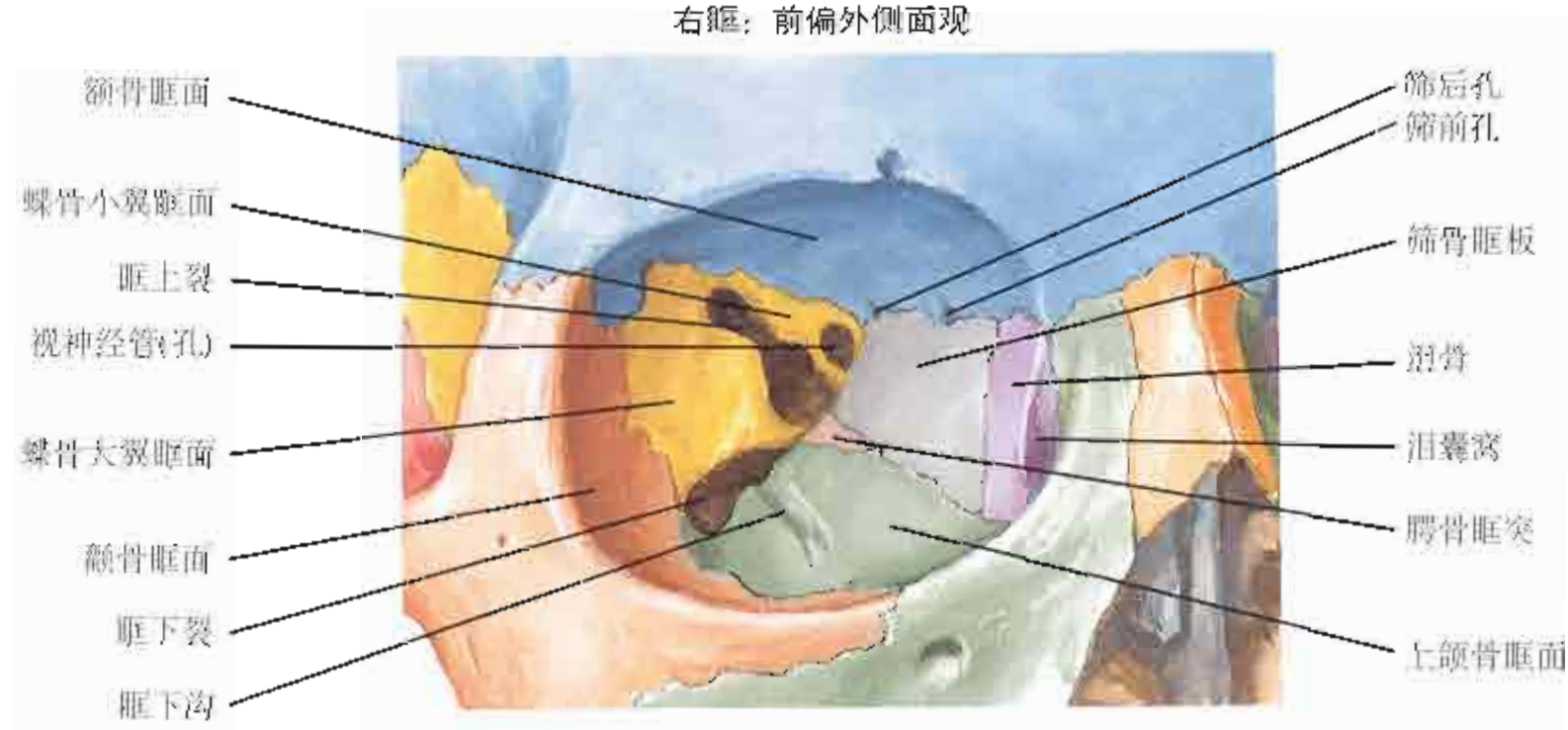


C. Machado
M.D.
© ION
ILLUSTRATIONS

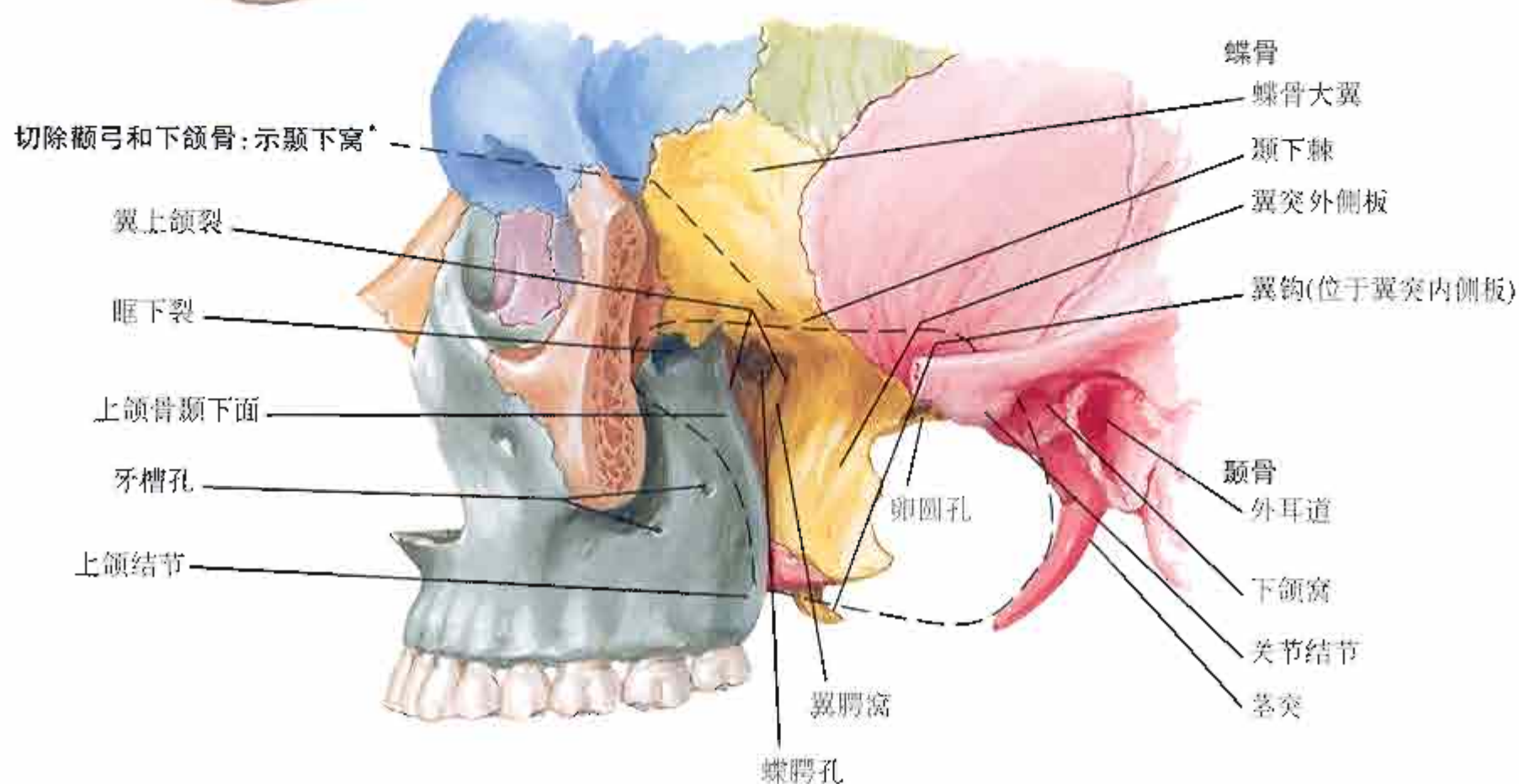
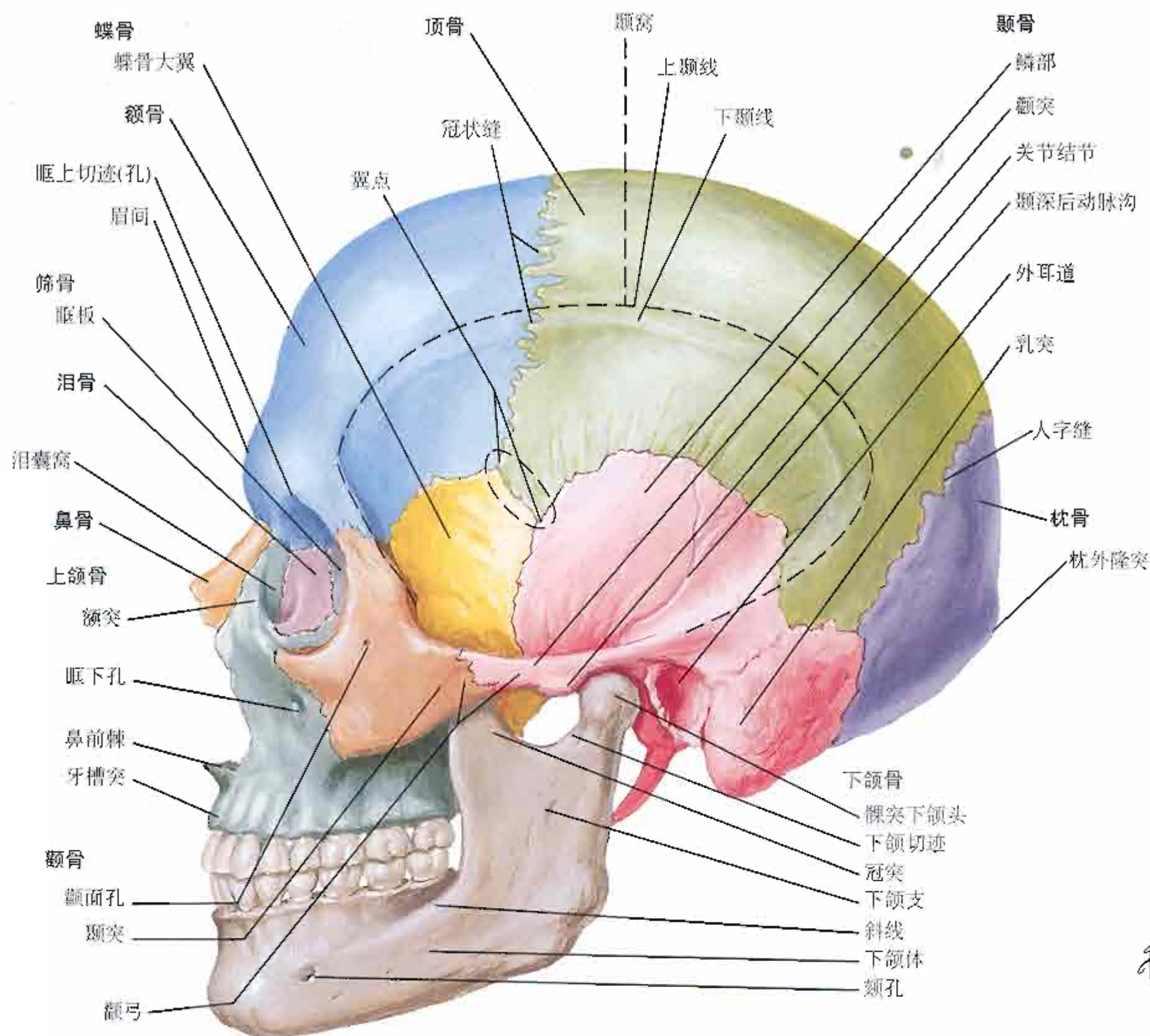
颅：前面观



右眶：前偏外侧面观

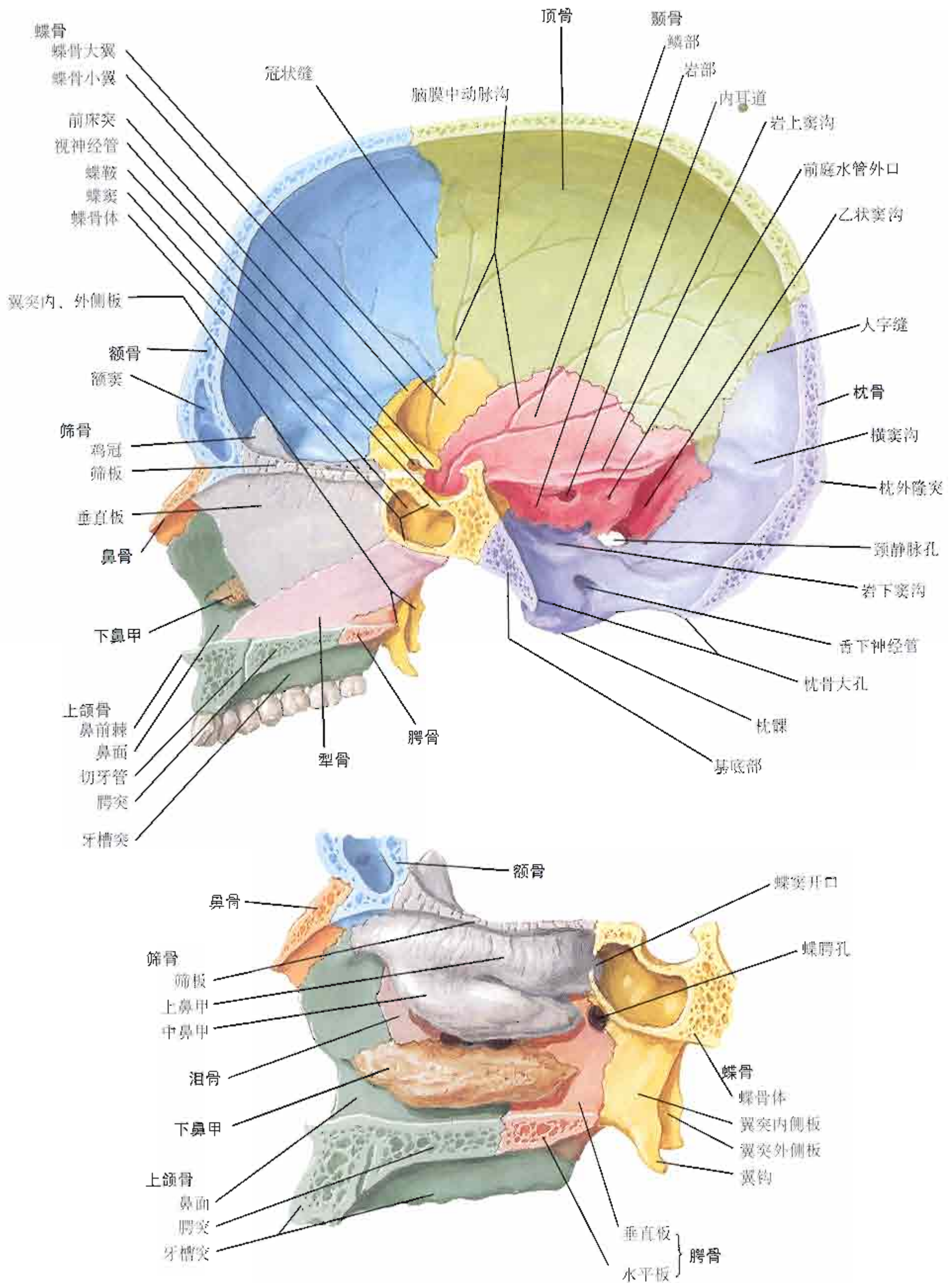


颅：外侧面观

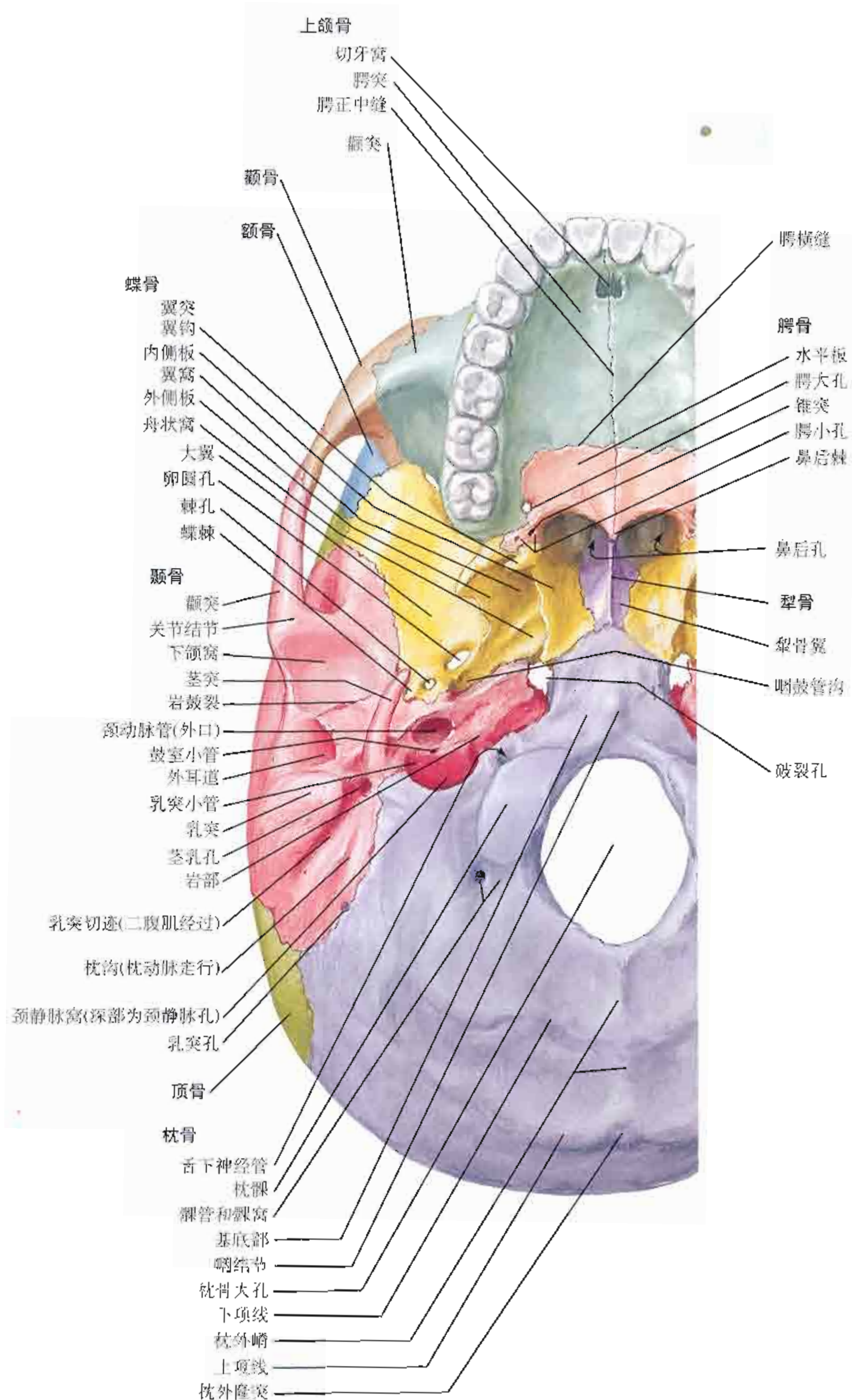


*乳突形成颞下窝后界

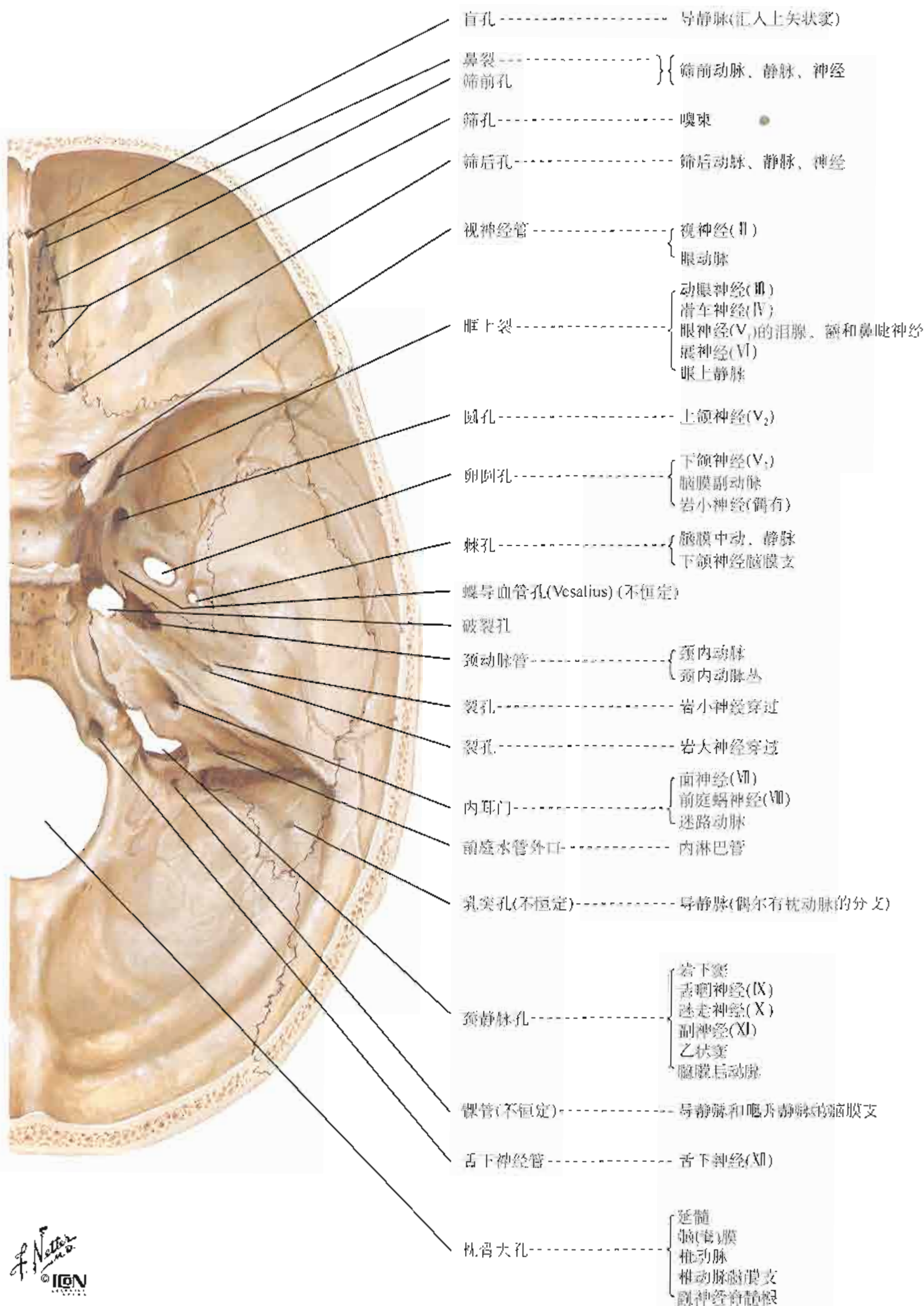
颅：正中矢状断面



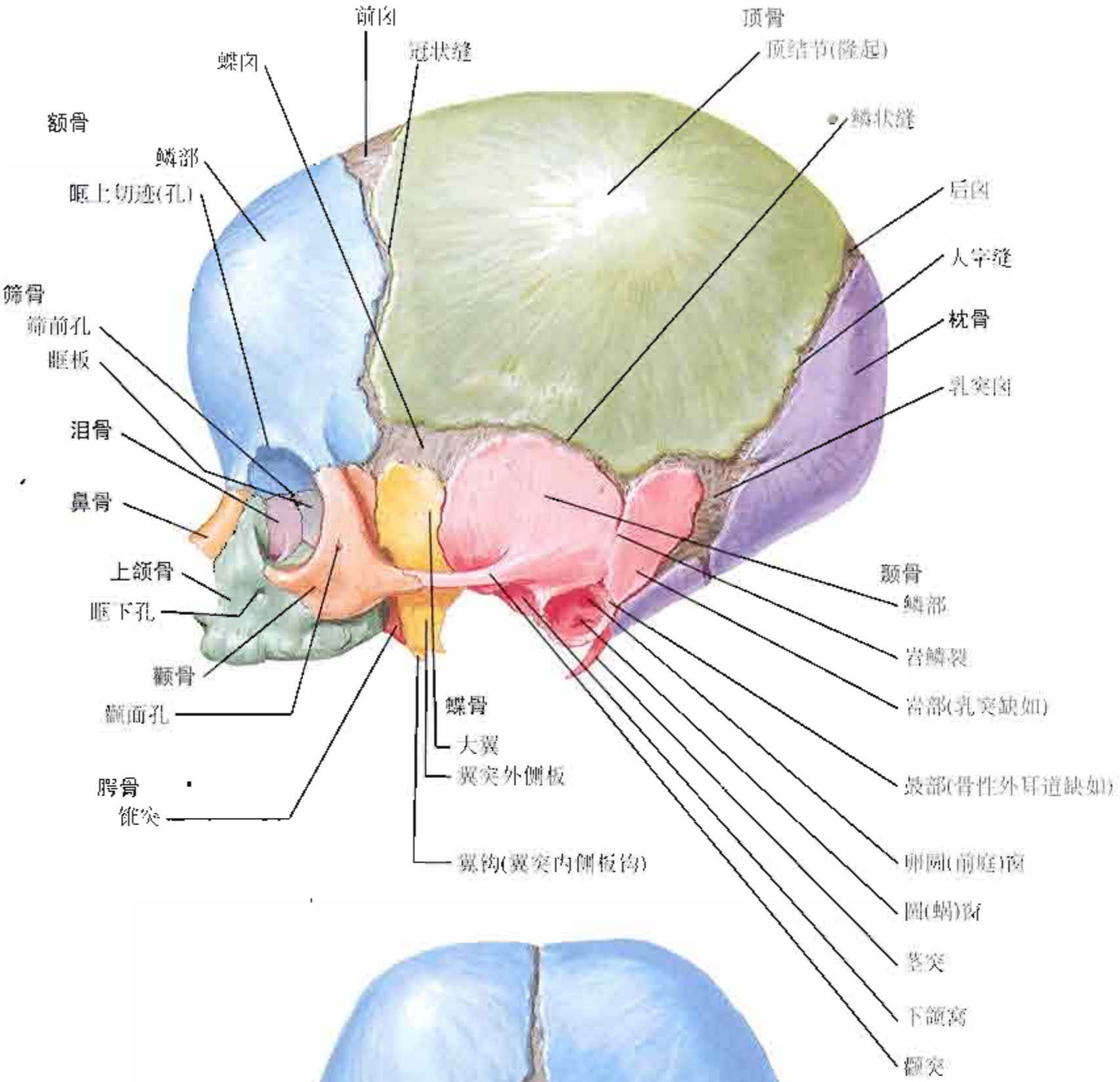
颅底：下面观



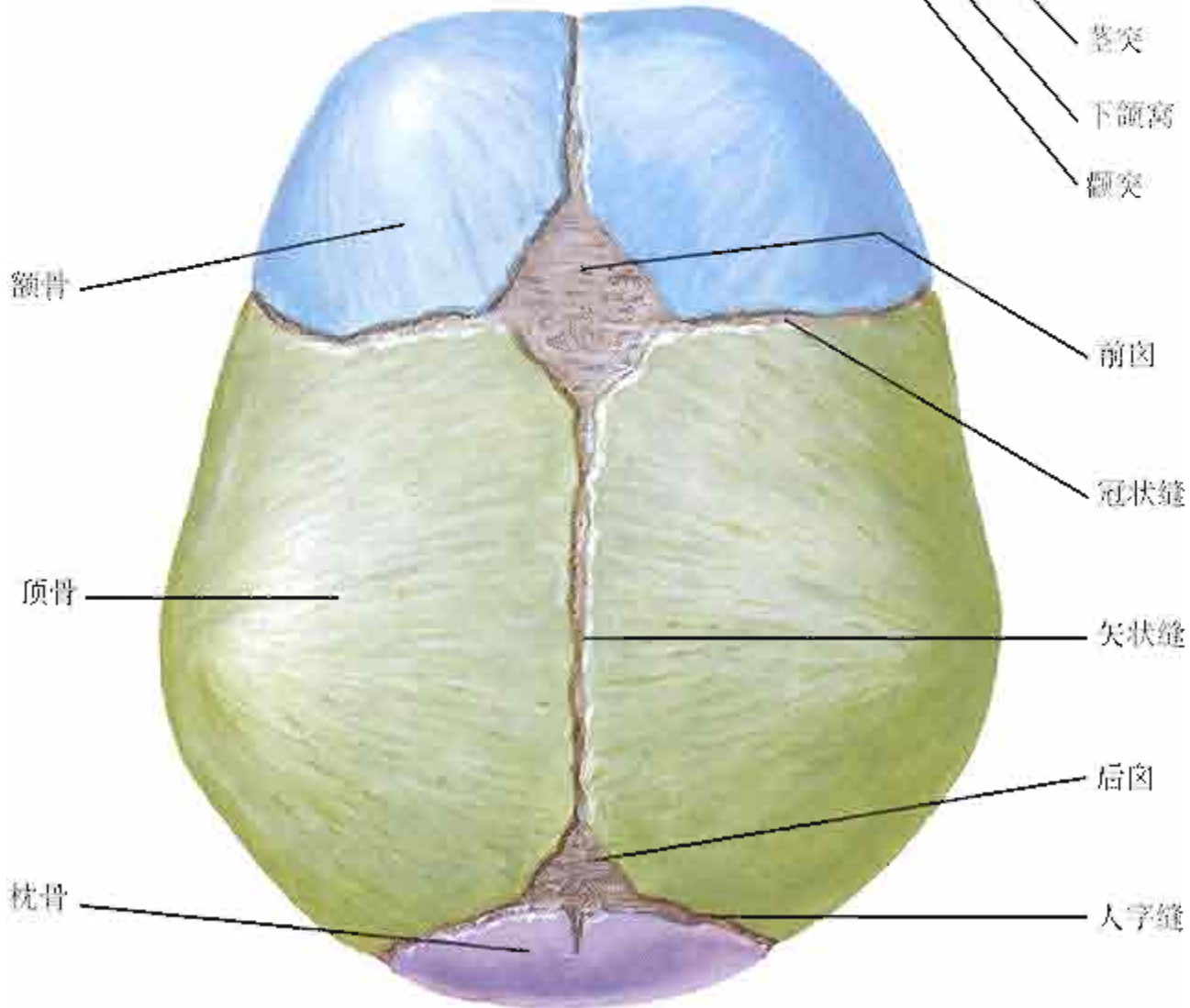
颅底的孔：上面观



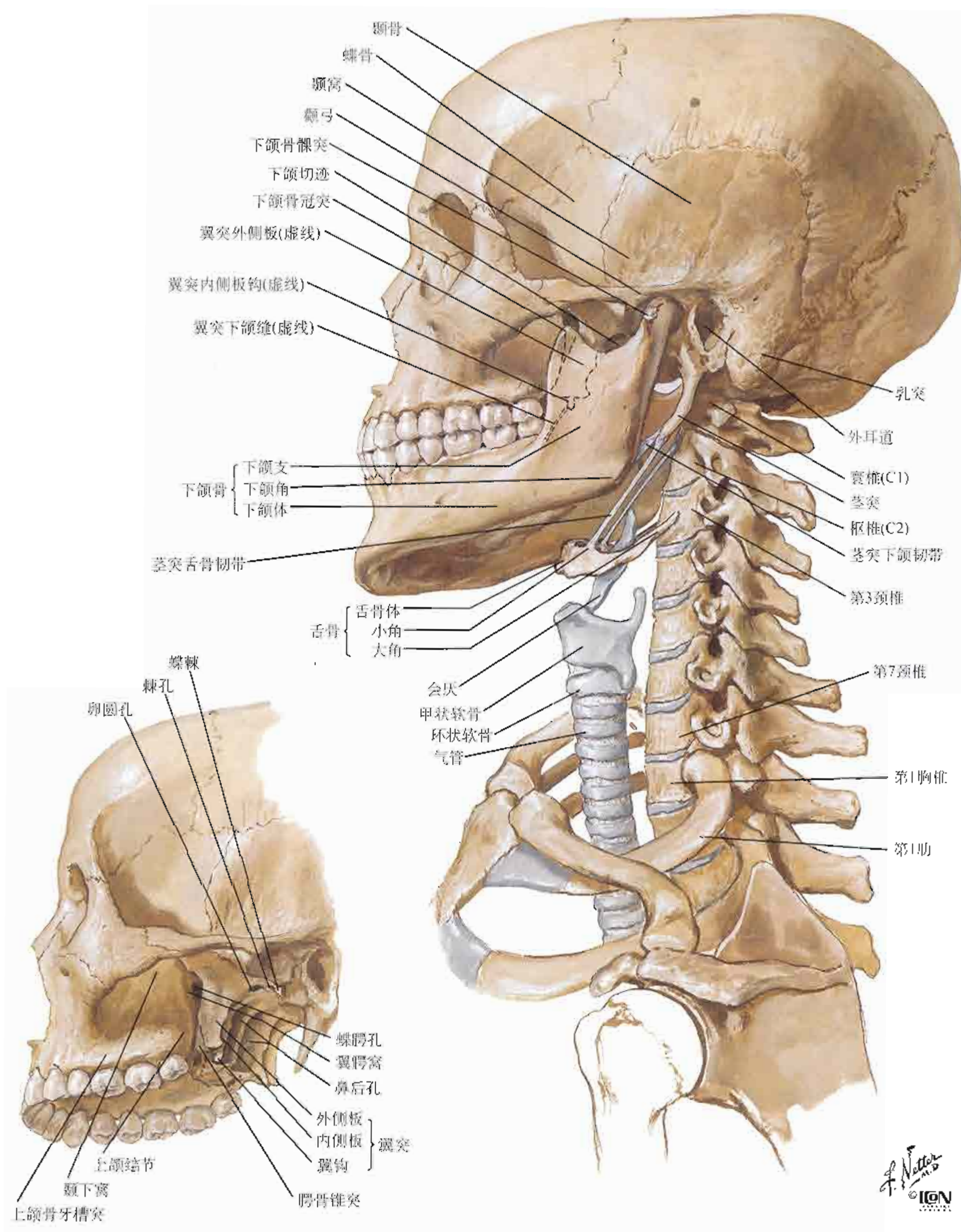
外侧面观

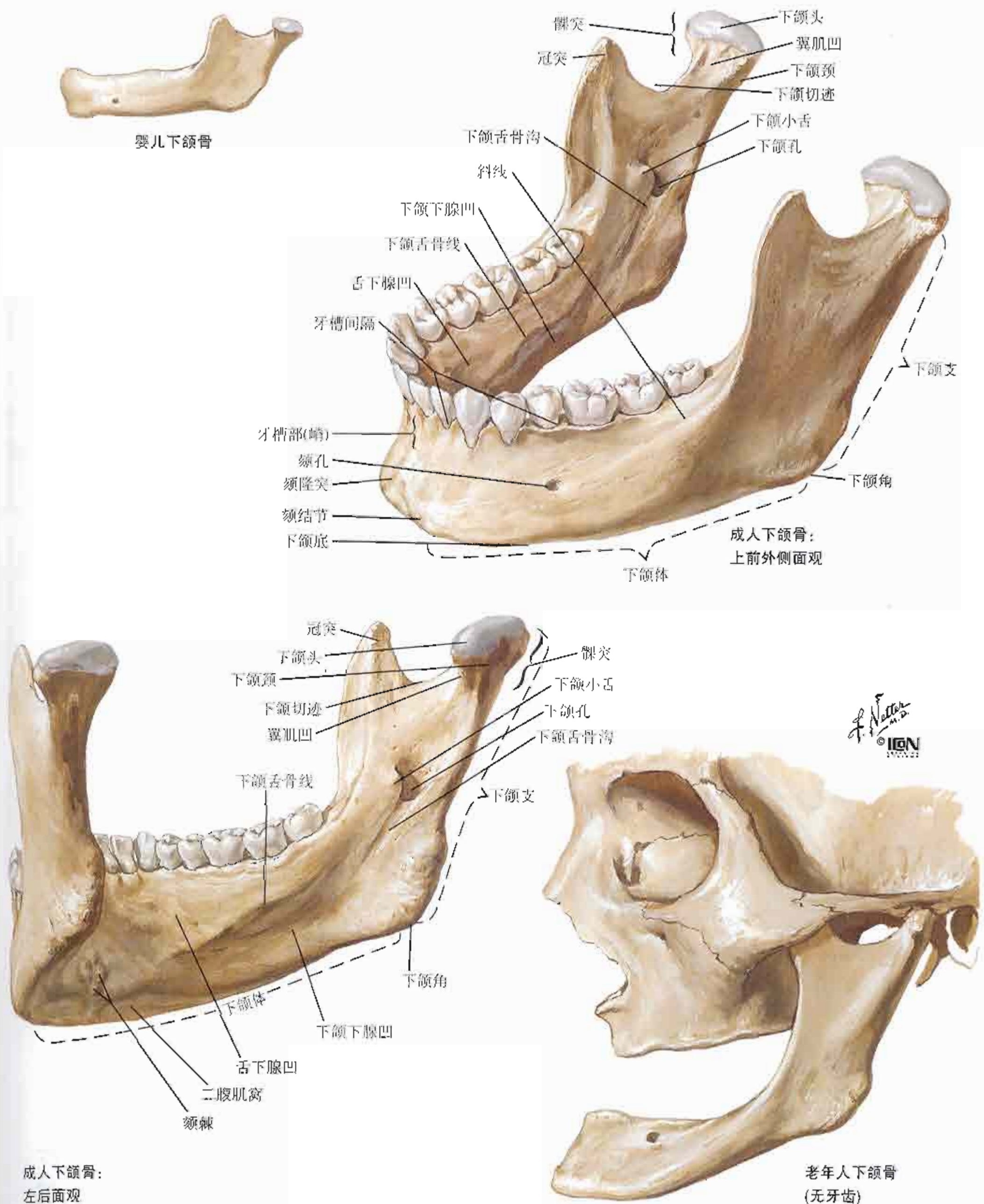


上面观

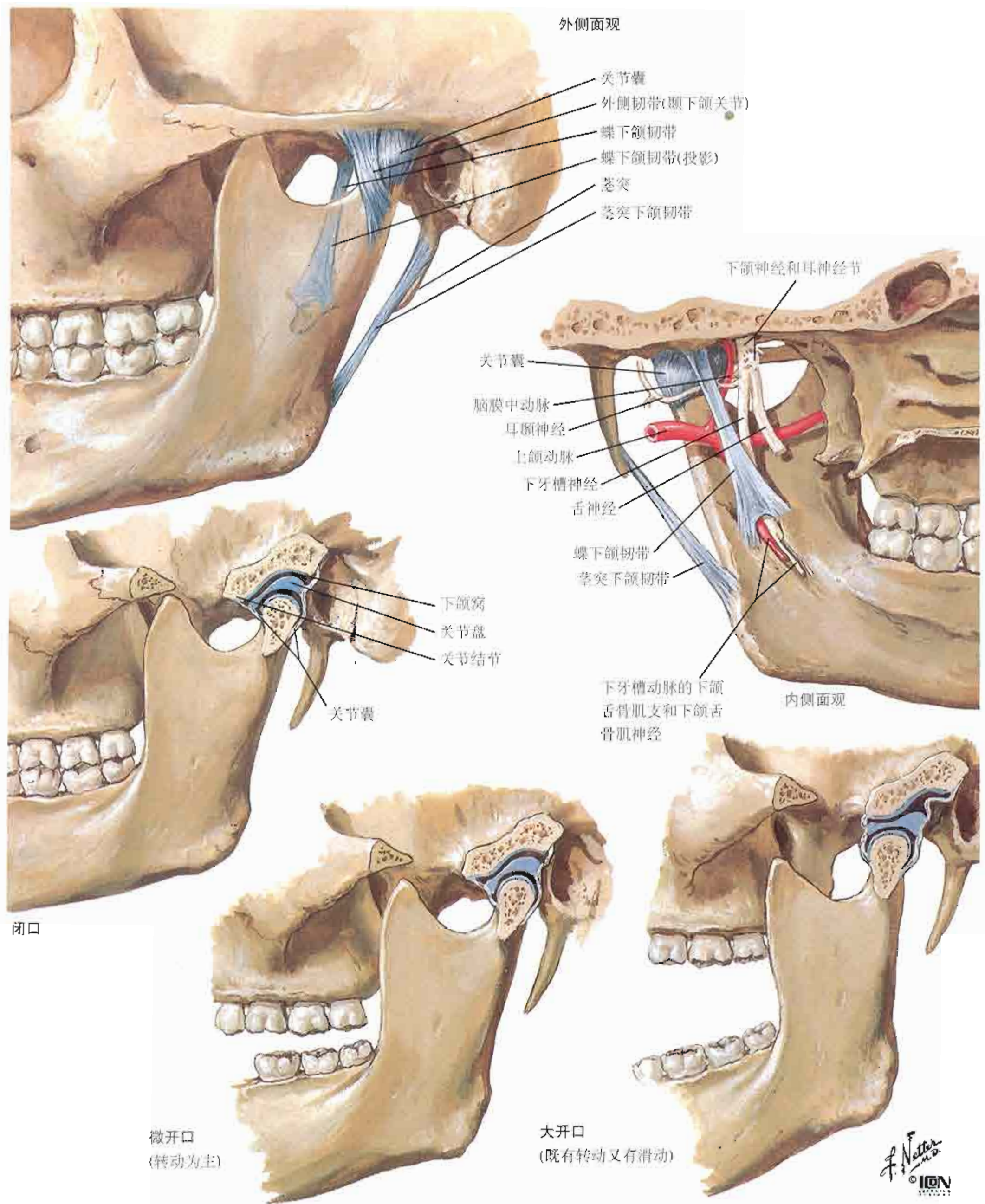


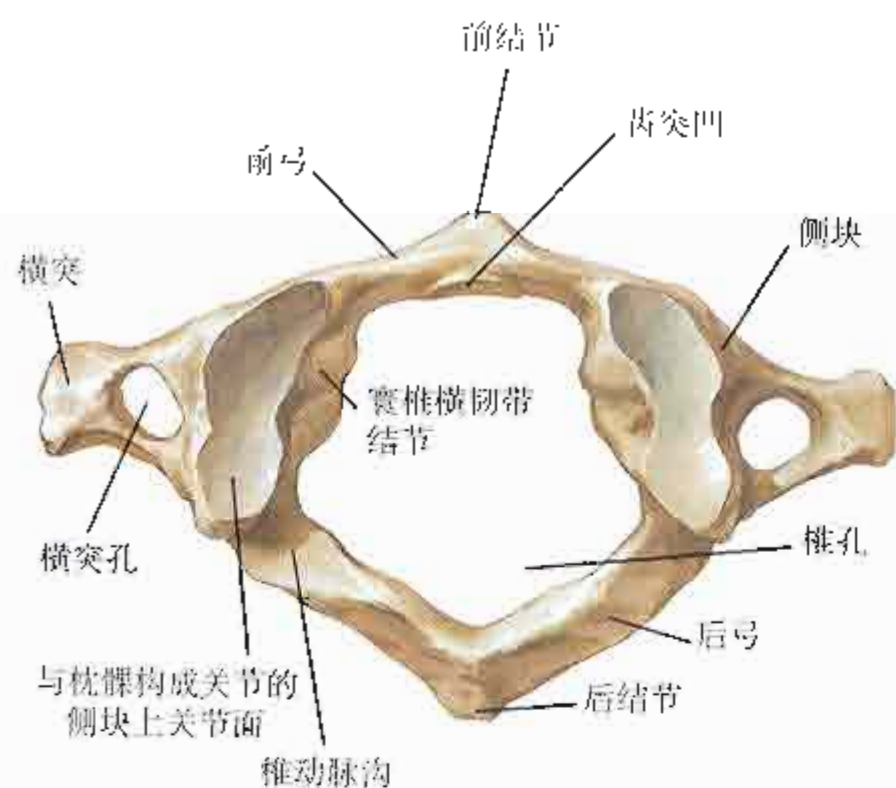
头和颈的骨性支架



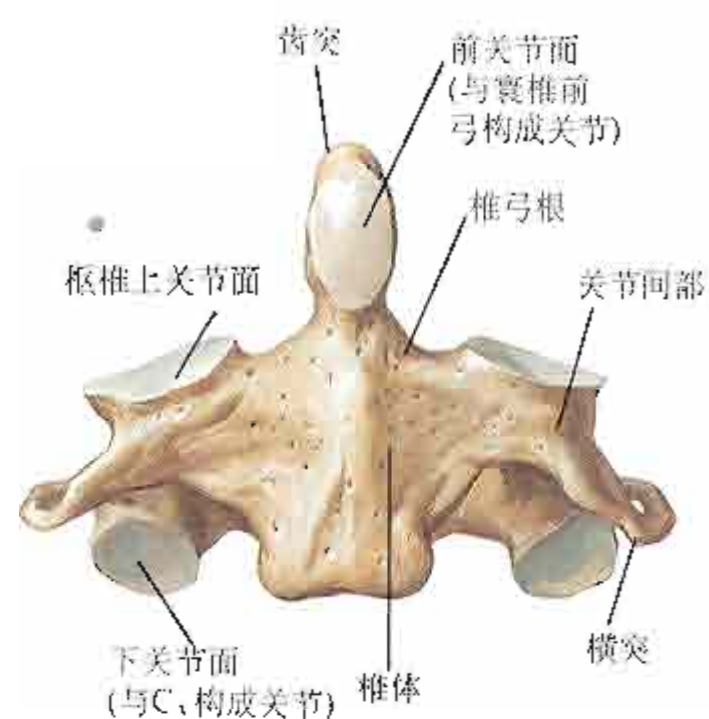


颞下颌关节

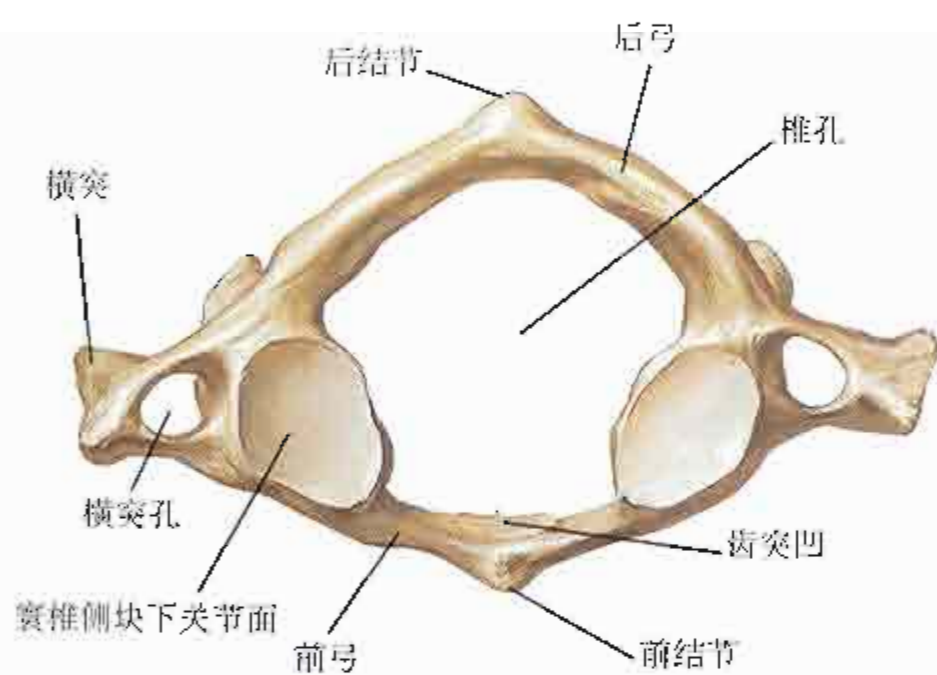




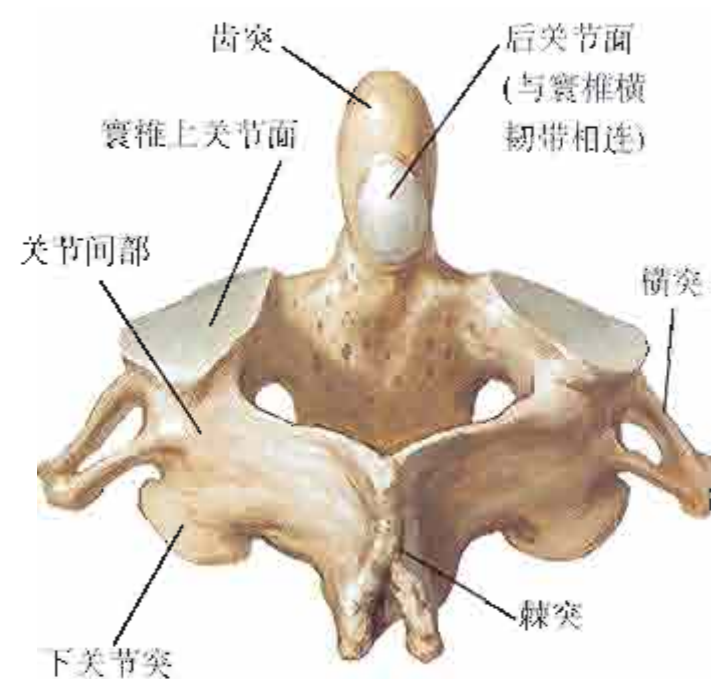
寰椎(C1): 上面观



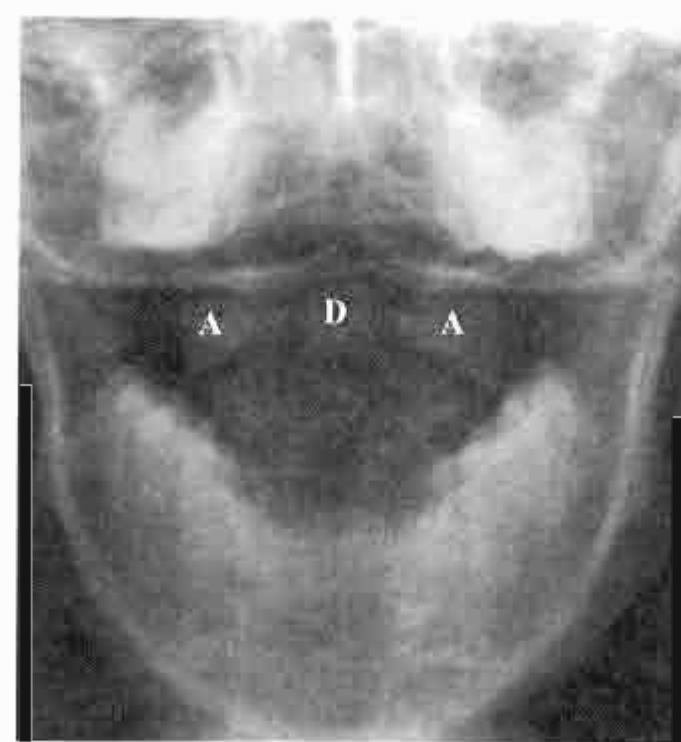
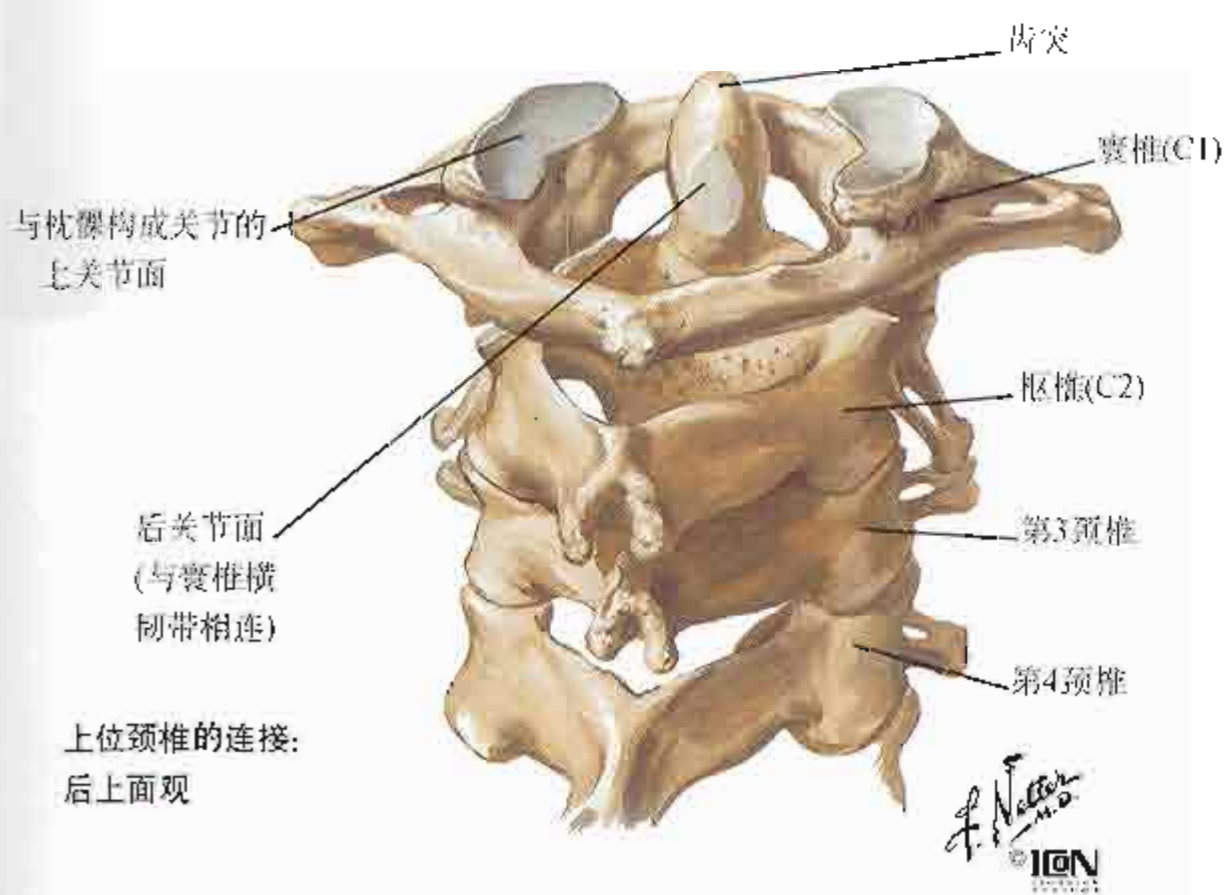
枢椎(C2): 前面观



寰椎(C1): 下面观



枢椎(C2): 后上面观

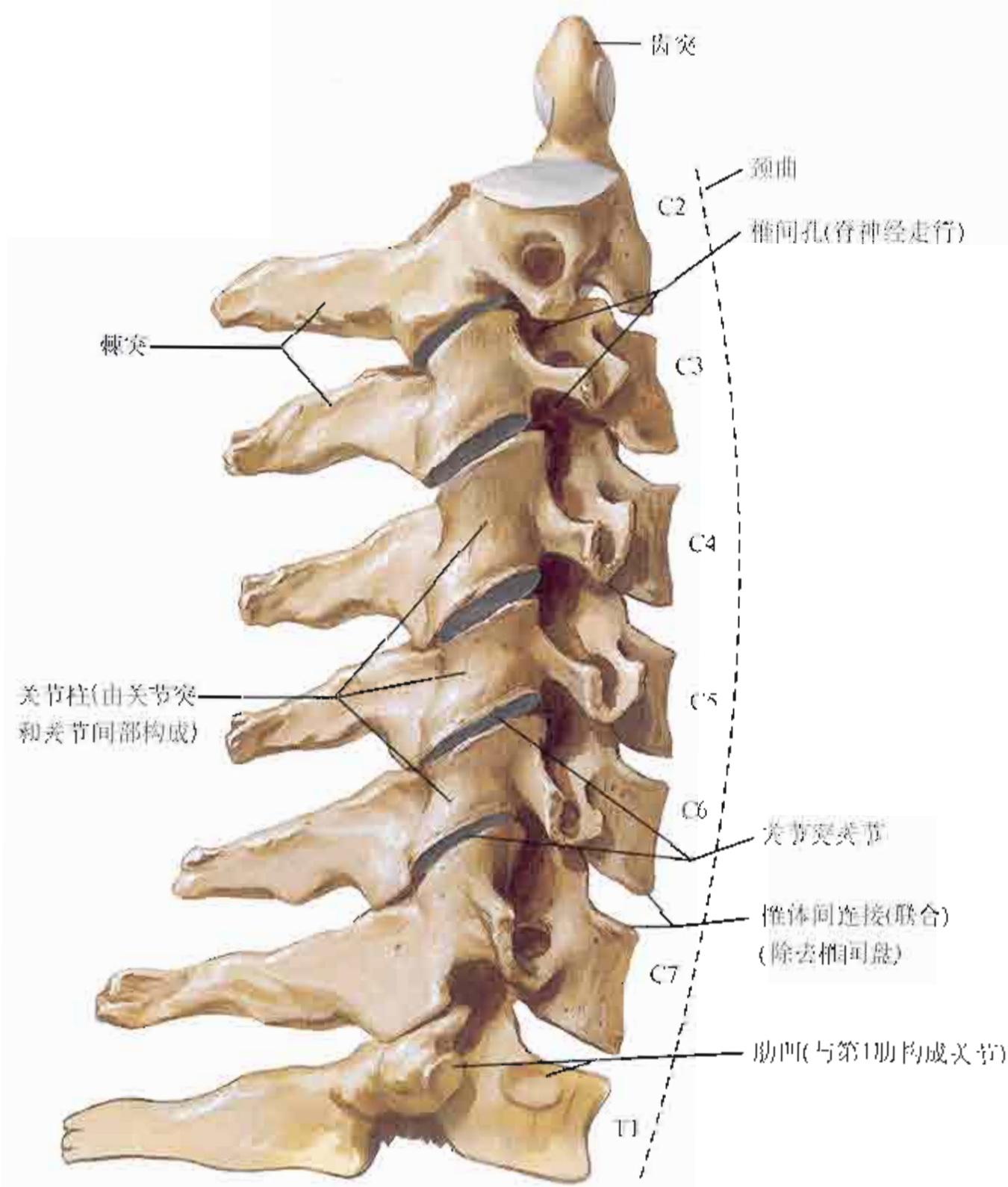
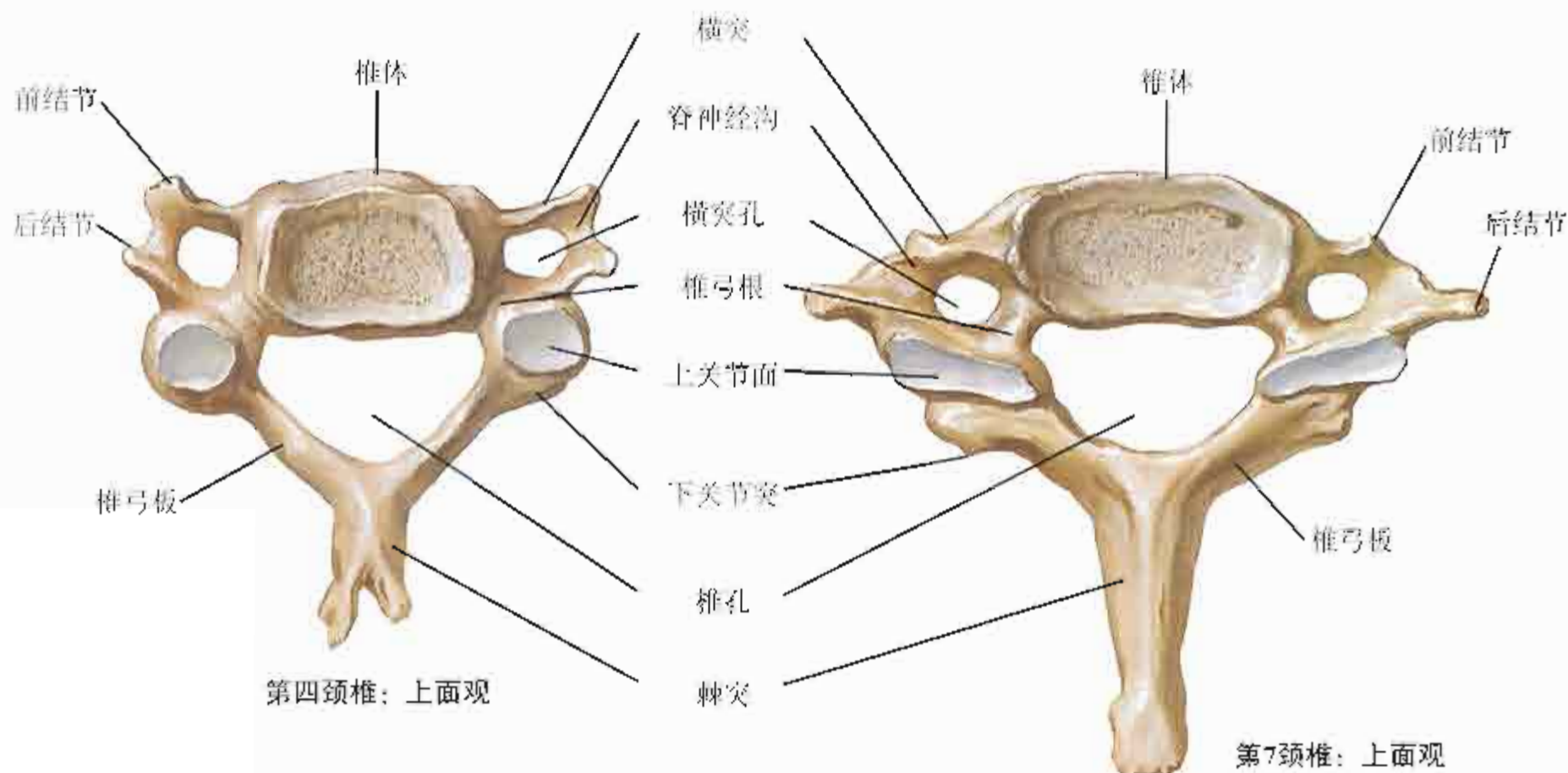


寰枢关节X线平片

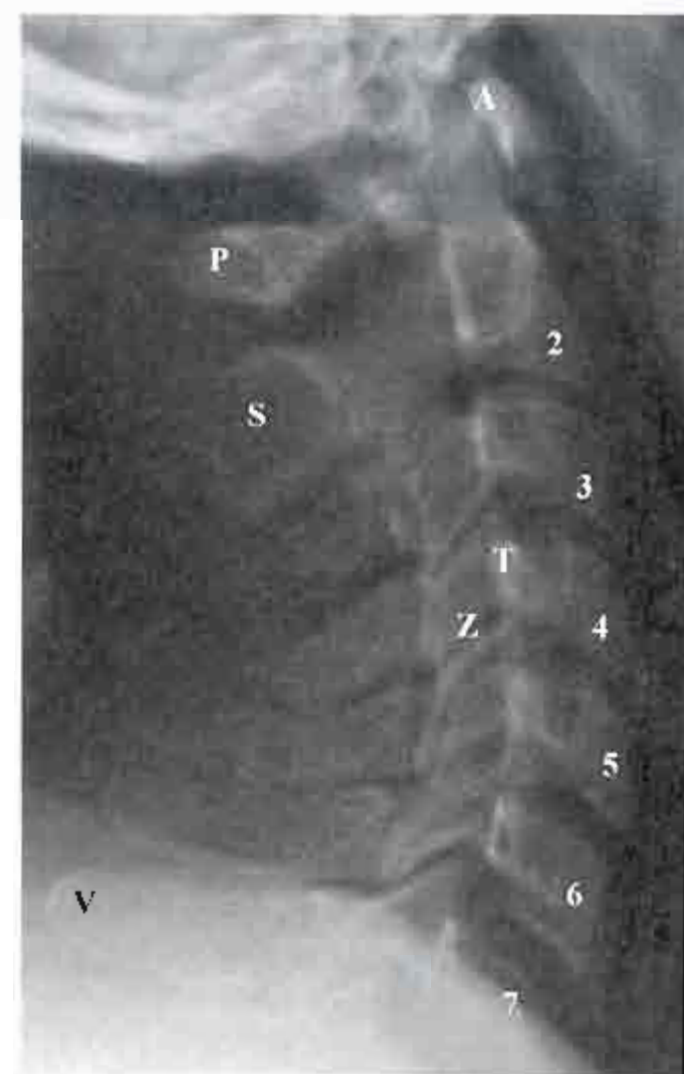- A 寰椎侧块(C1)
- D 枢椎齿突(C2)

颈椎 (续)

参见图 12、146

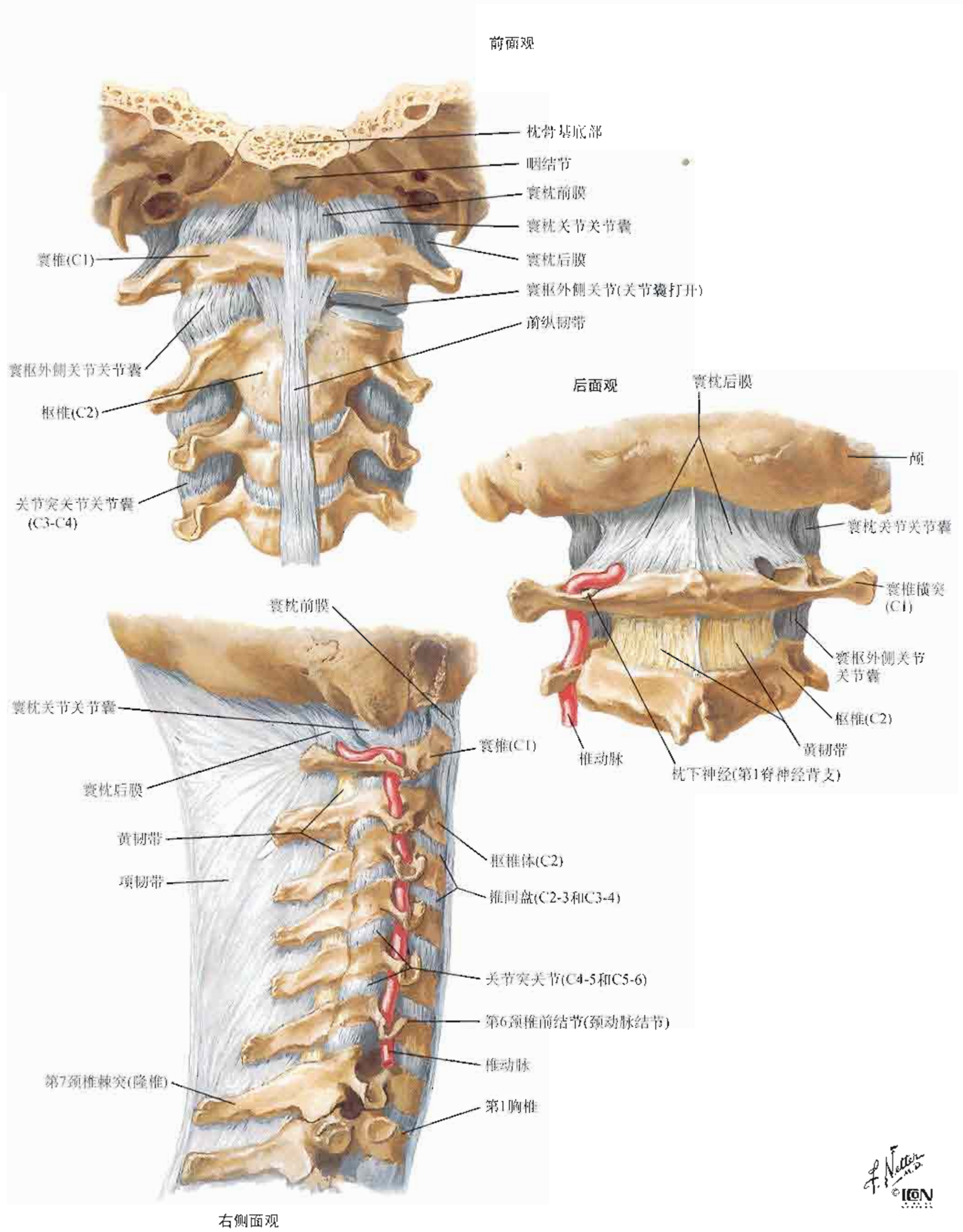


第2颈椎至第1胸椎: 右外侧面观



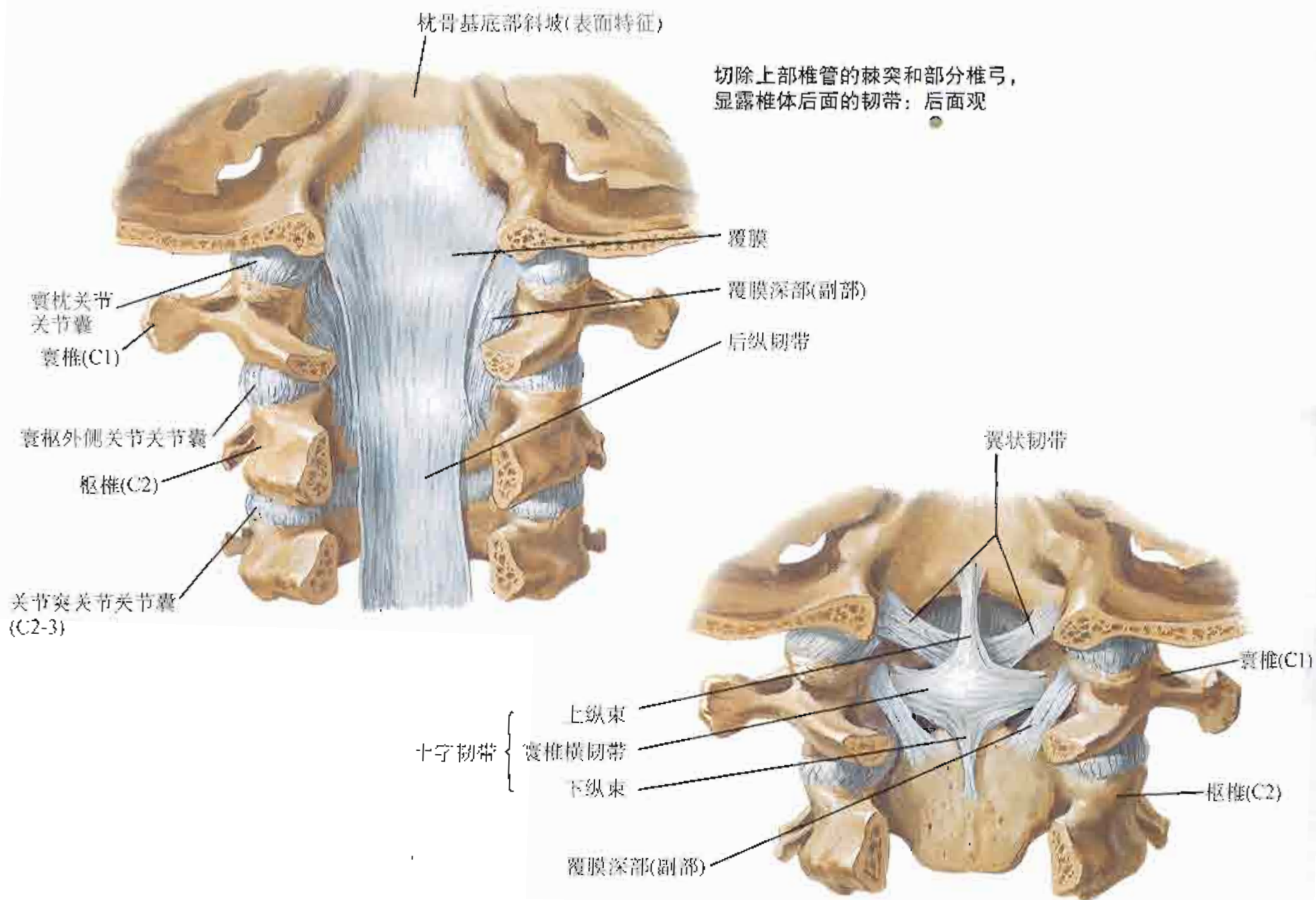
颈椎: 外侧面 X 线平片

- A 寰椎前弓
 - P 寰椎后弓
 - S 棘突
 - T 横突
 - V 隆椎 (第7颈椎棘突)
 - Z 关节突关节
- (第2-7颈椎体上标有数字)

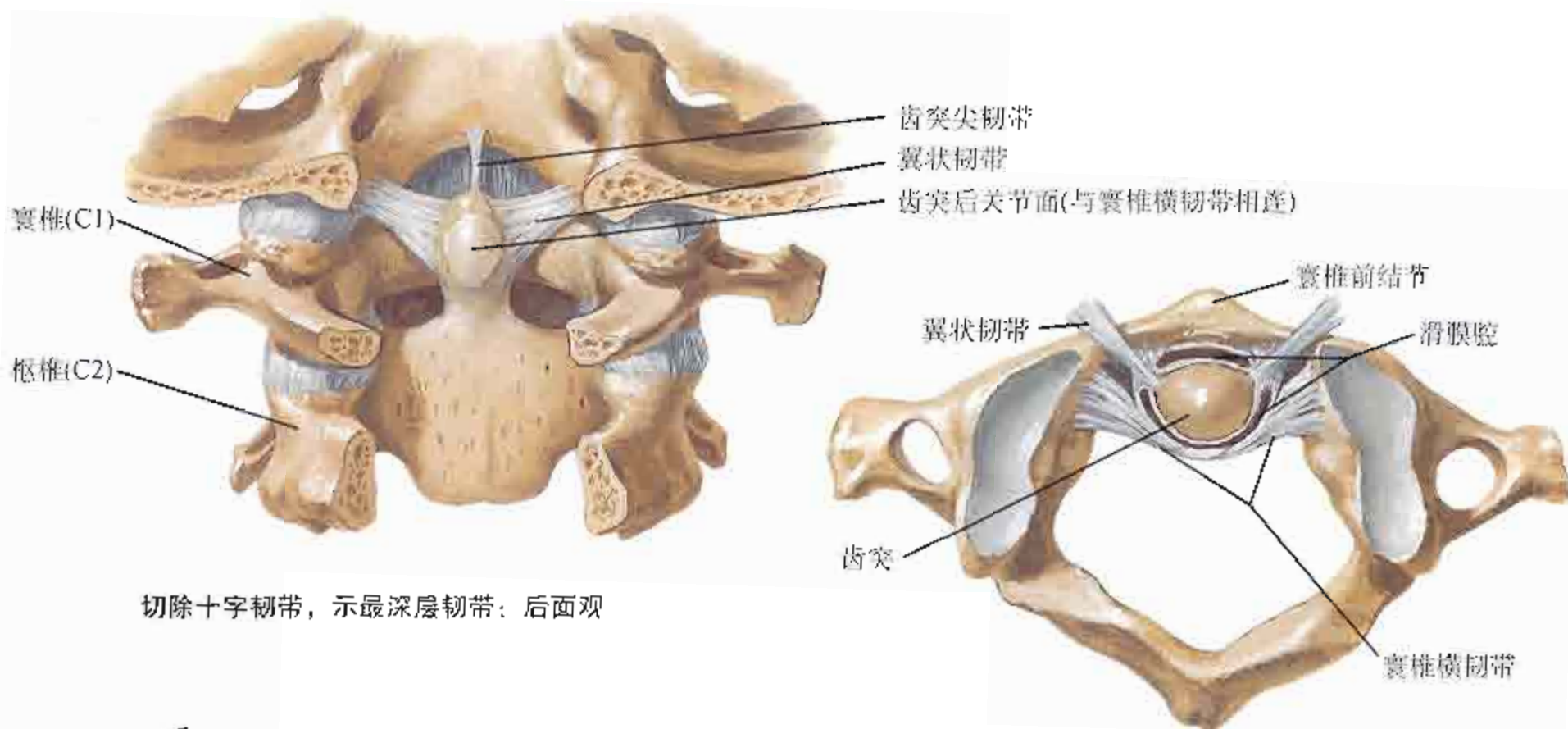


F. Netter M.D. ILLUSTRATIONS

颅颈内韧带



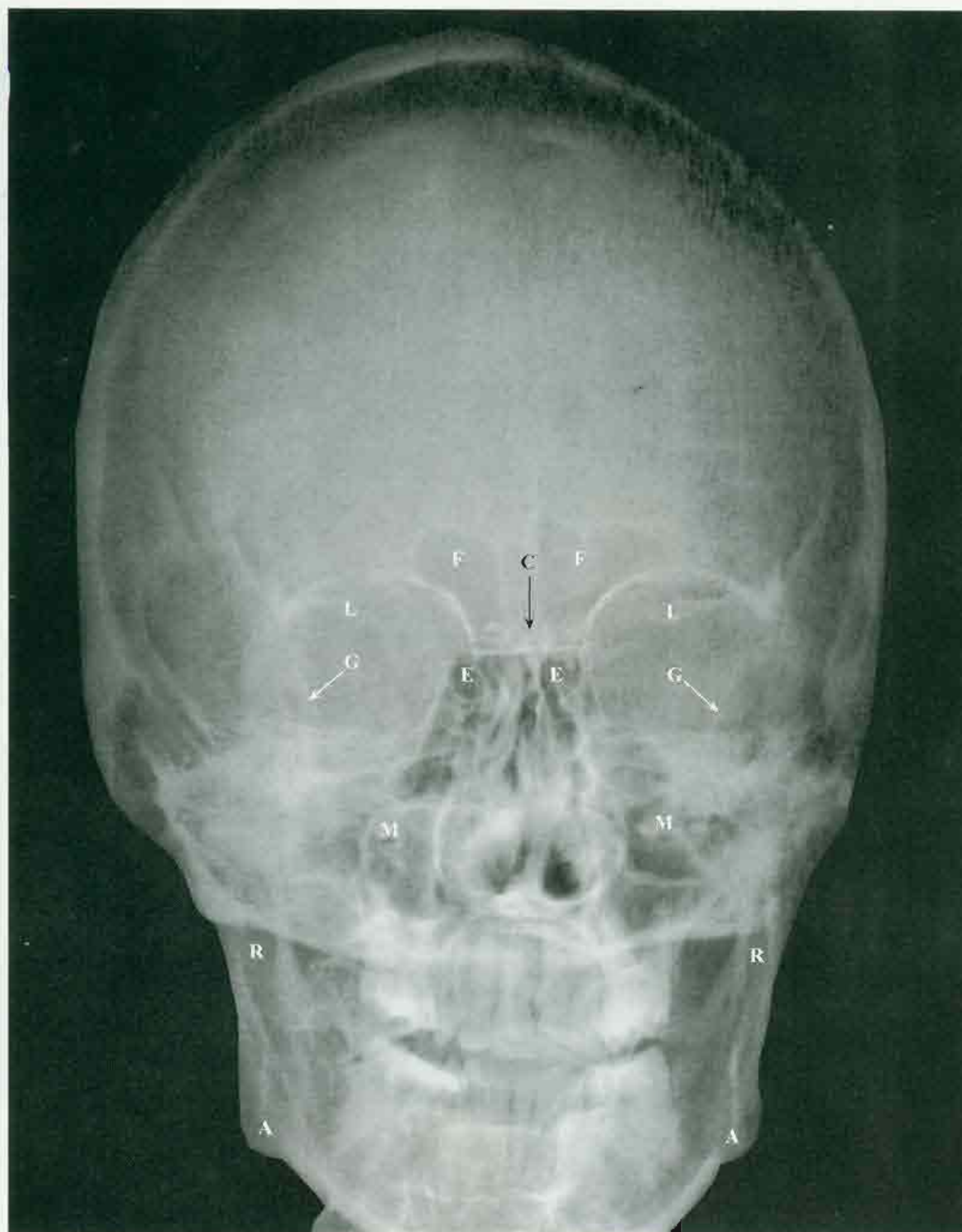
切除覆膜主要部分，显露深部韧带：后面观



切除十字韧带，示最深层韧带：后面观

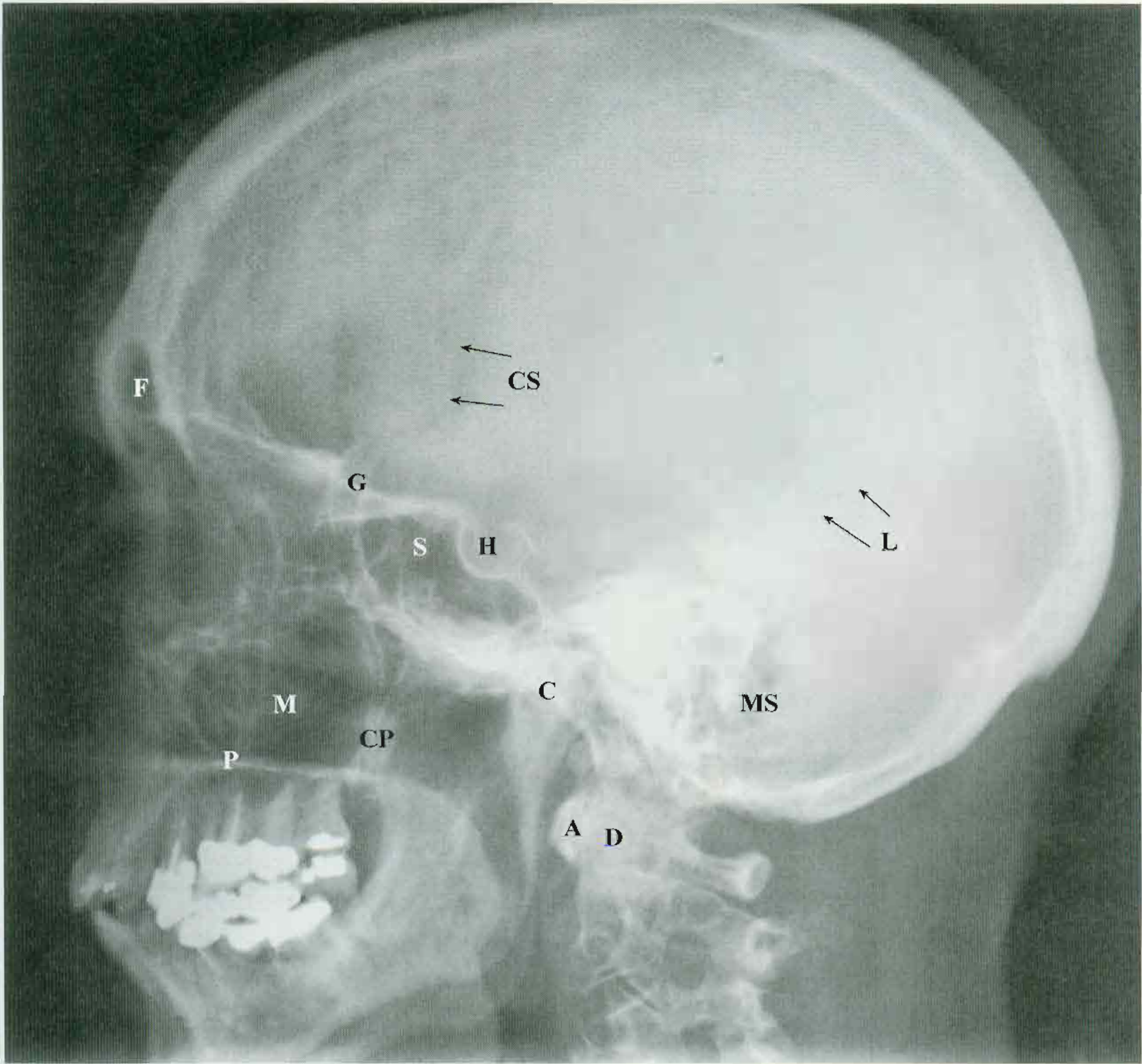
寰枢正中关节：上面观

参见图2

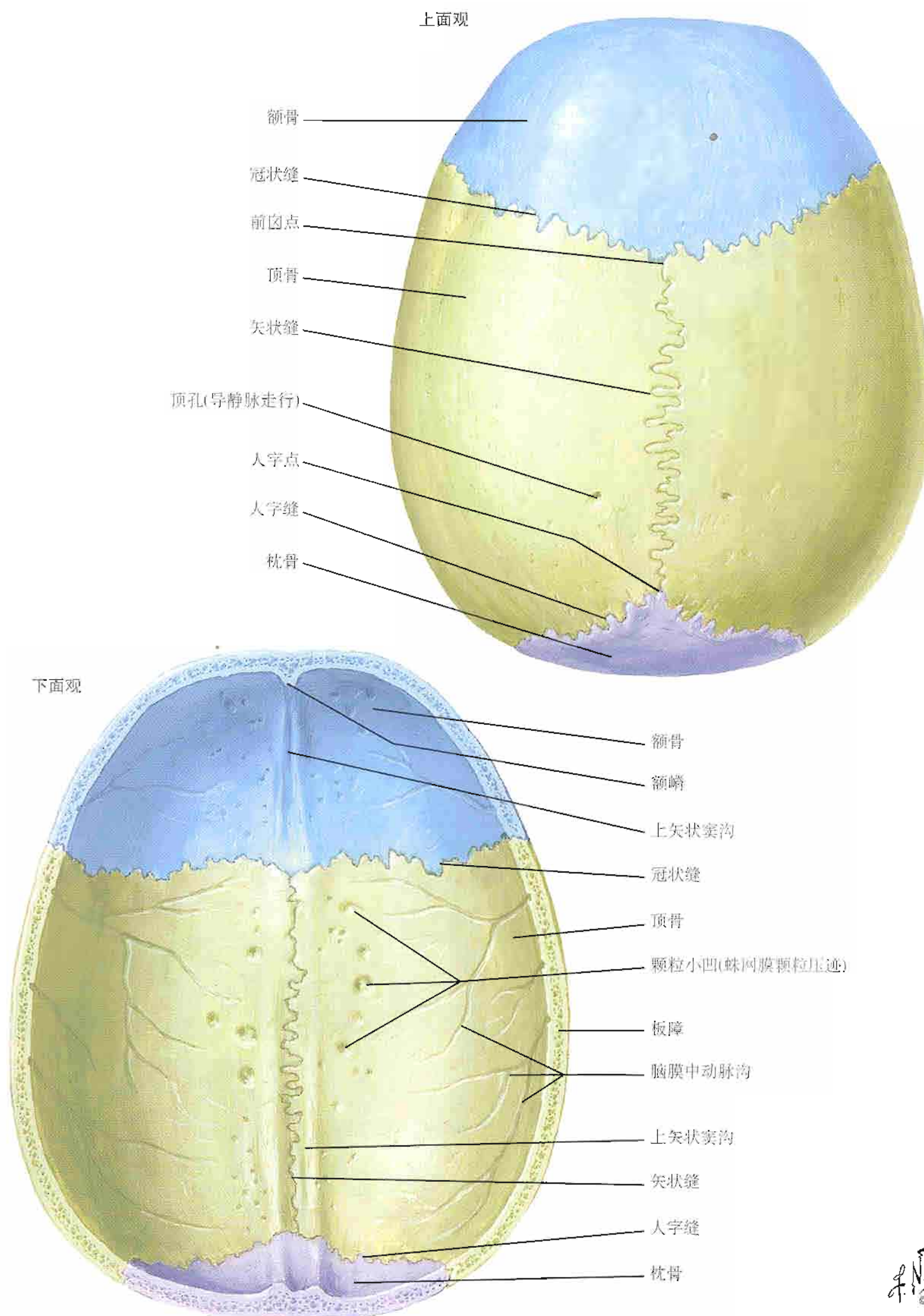


- A 下颌角
- C 鸡冠
- E 筛窦
- F 额窦
- G 蝶骨大翼
- L 蝶骨小翼
- M 上颌窦
- R 下颌支

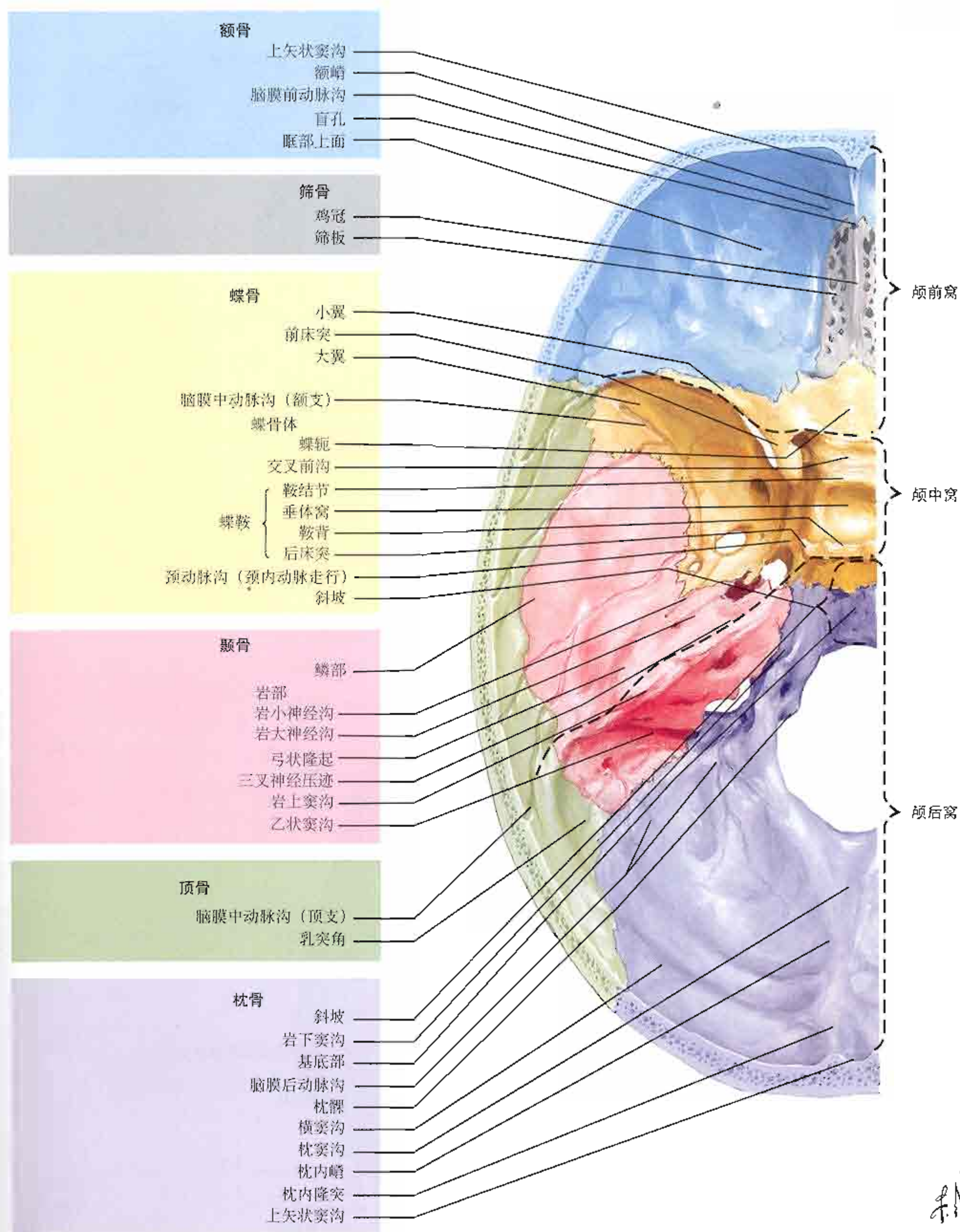
参见图 4



- | | |
|------------|---------|
| A 寰椎前弓(C1) | G 蝶骨大翼 |
| C 下颌骨髁突 | H 垂体窝 |
| CP 下颌骨冠突 | L 人字缝 |
| CS 冠状缝 | M 上颌窦 |
| D 枢椎齿突(C2) | MS 乳突小房 |
| F 额窦 | P 上颌骨腭突 |
| | S 蝶窦 |



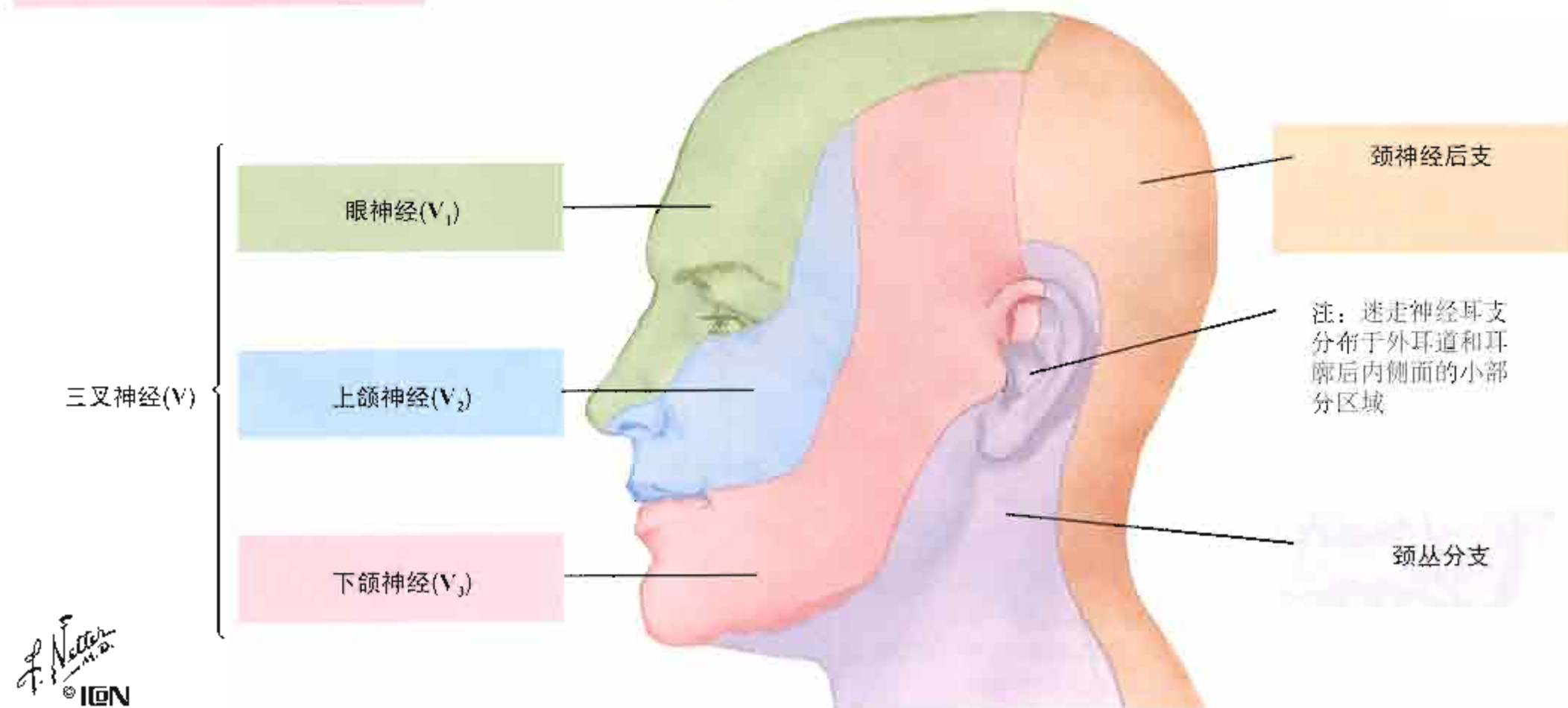
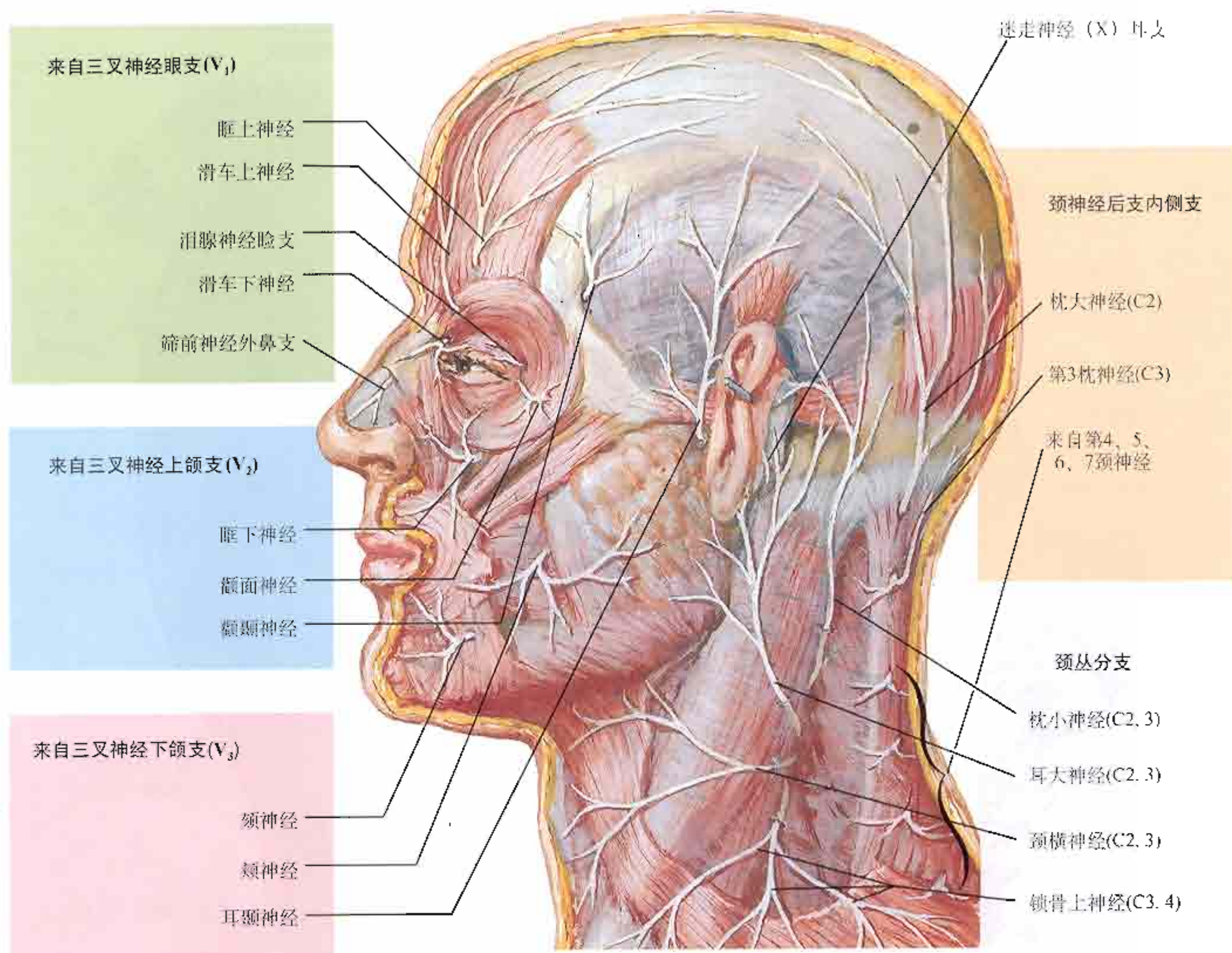
F. Netter M.D. IGV

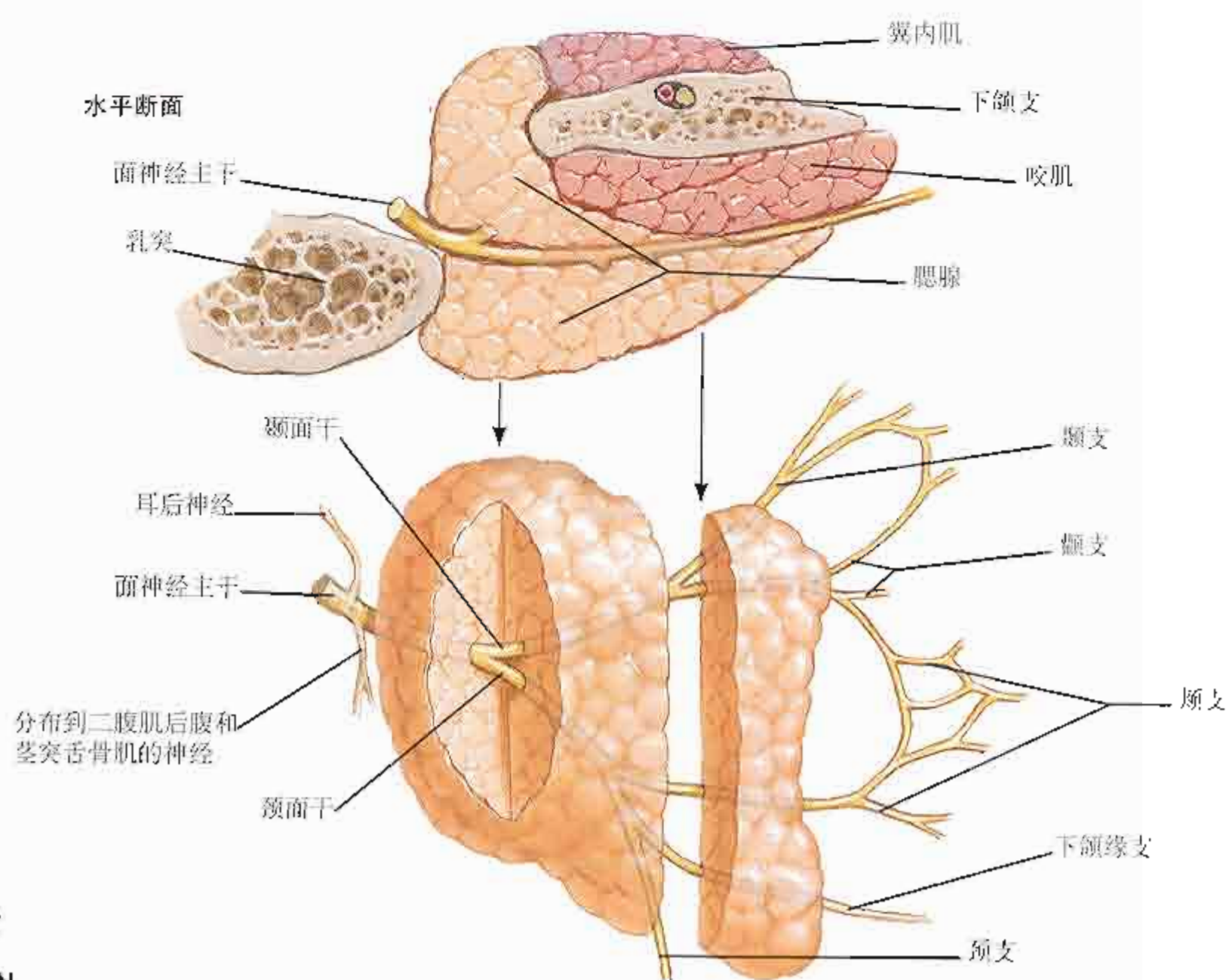
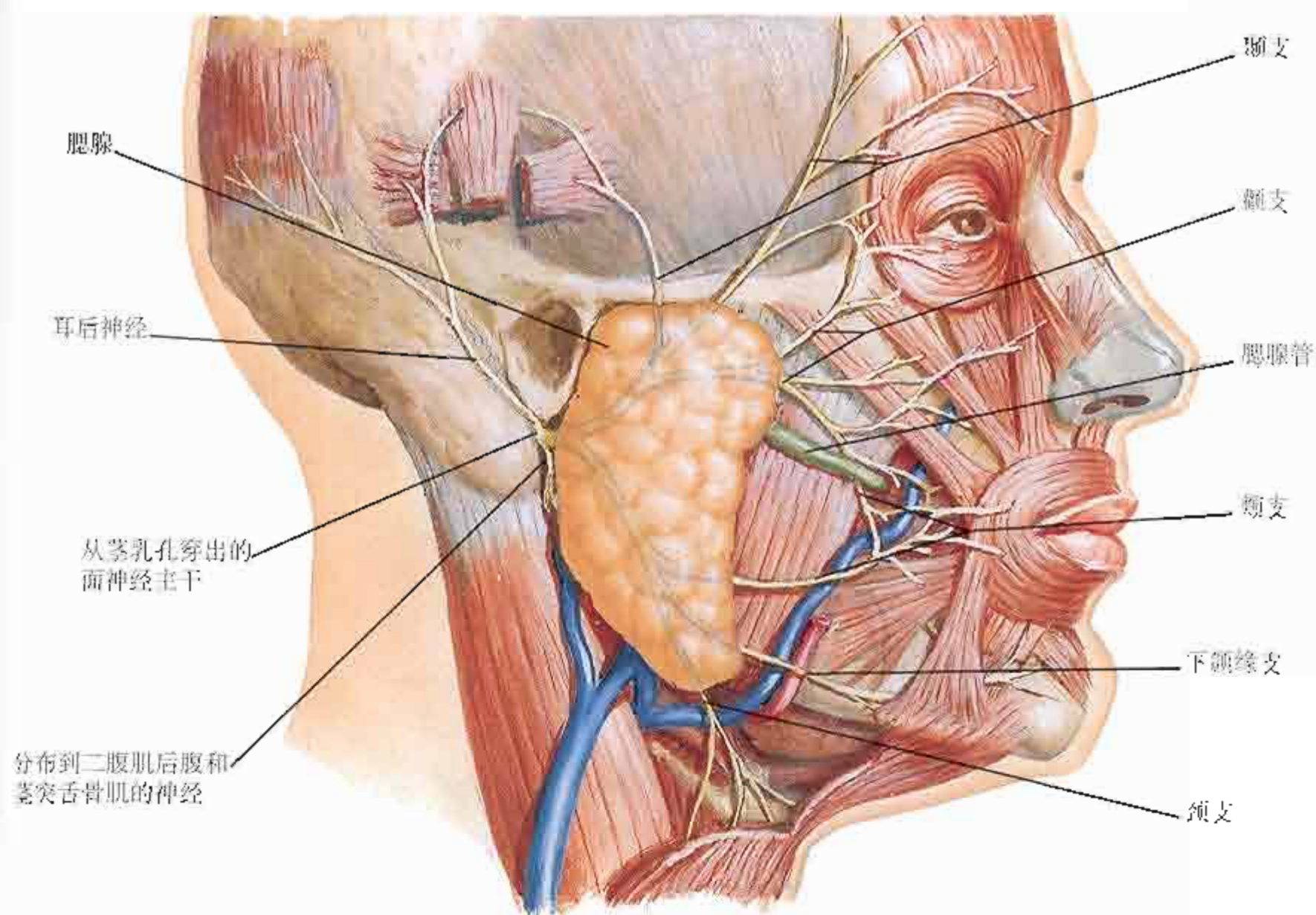


F. Netter M.D.
© IGCN

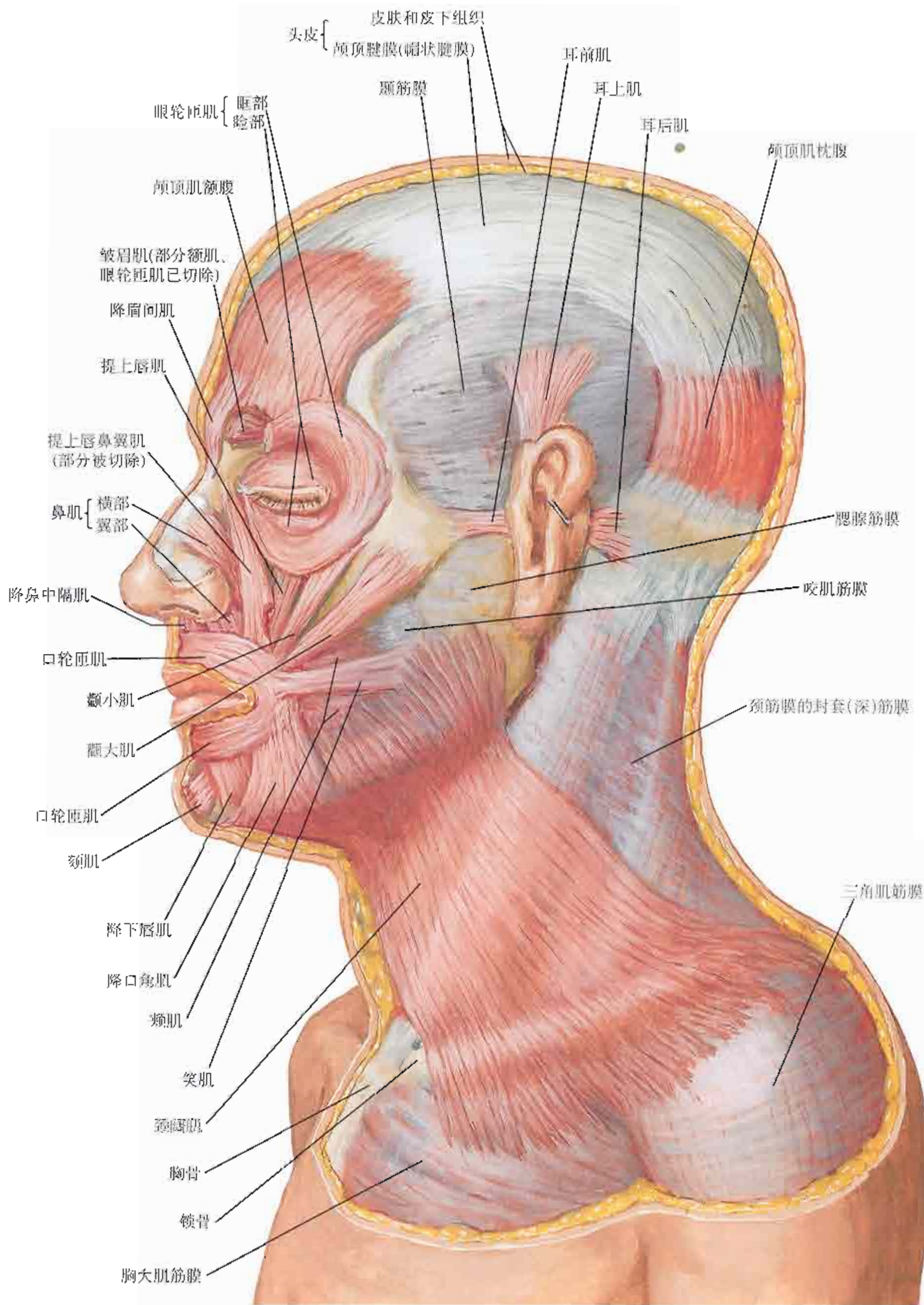
头和颈的皮神经

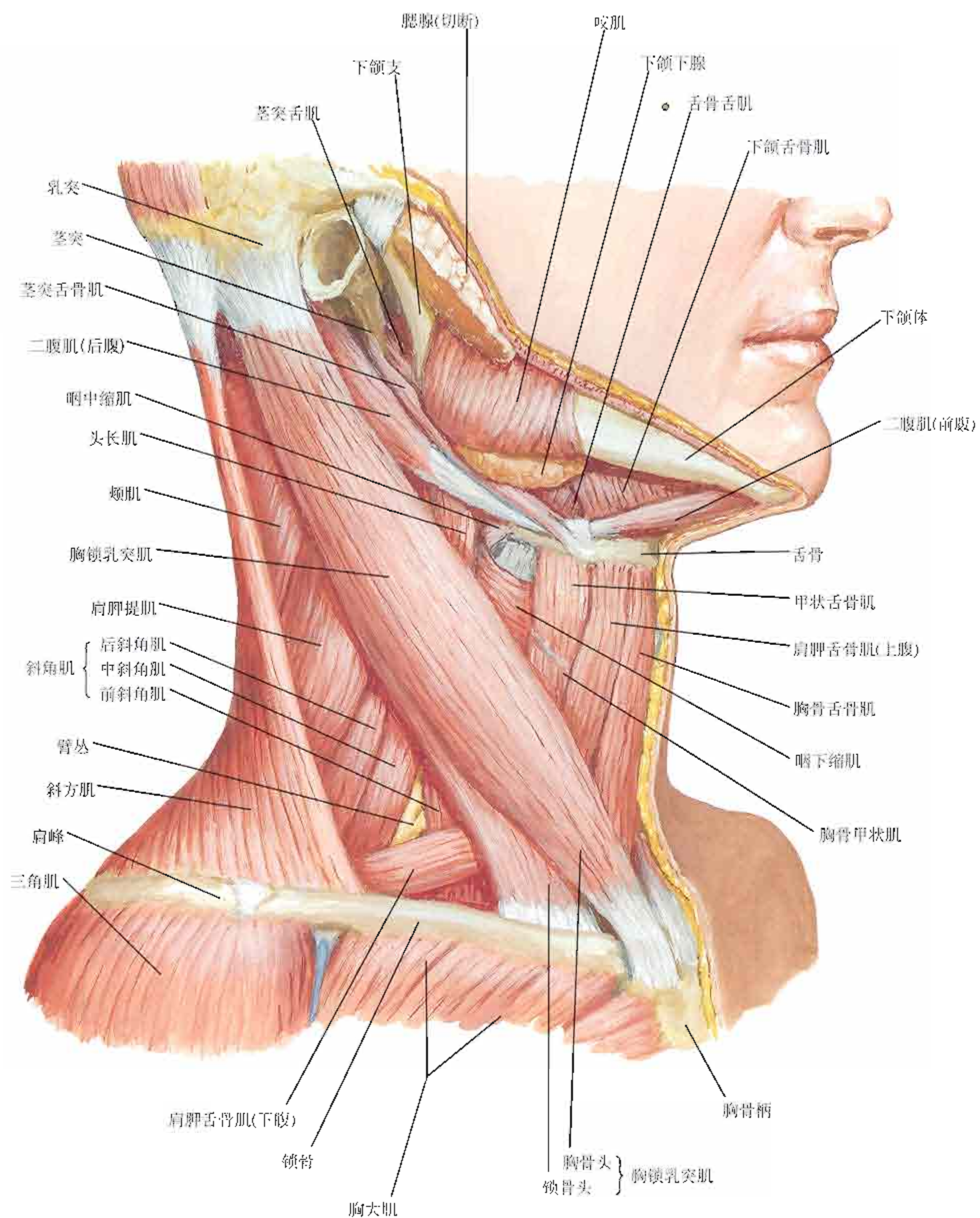
参见图 28、32、41、42、116



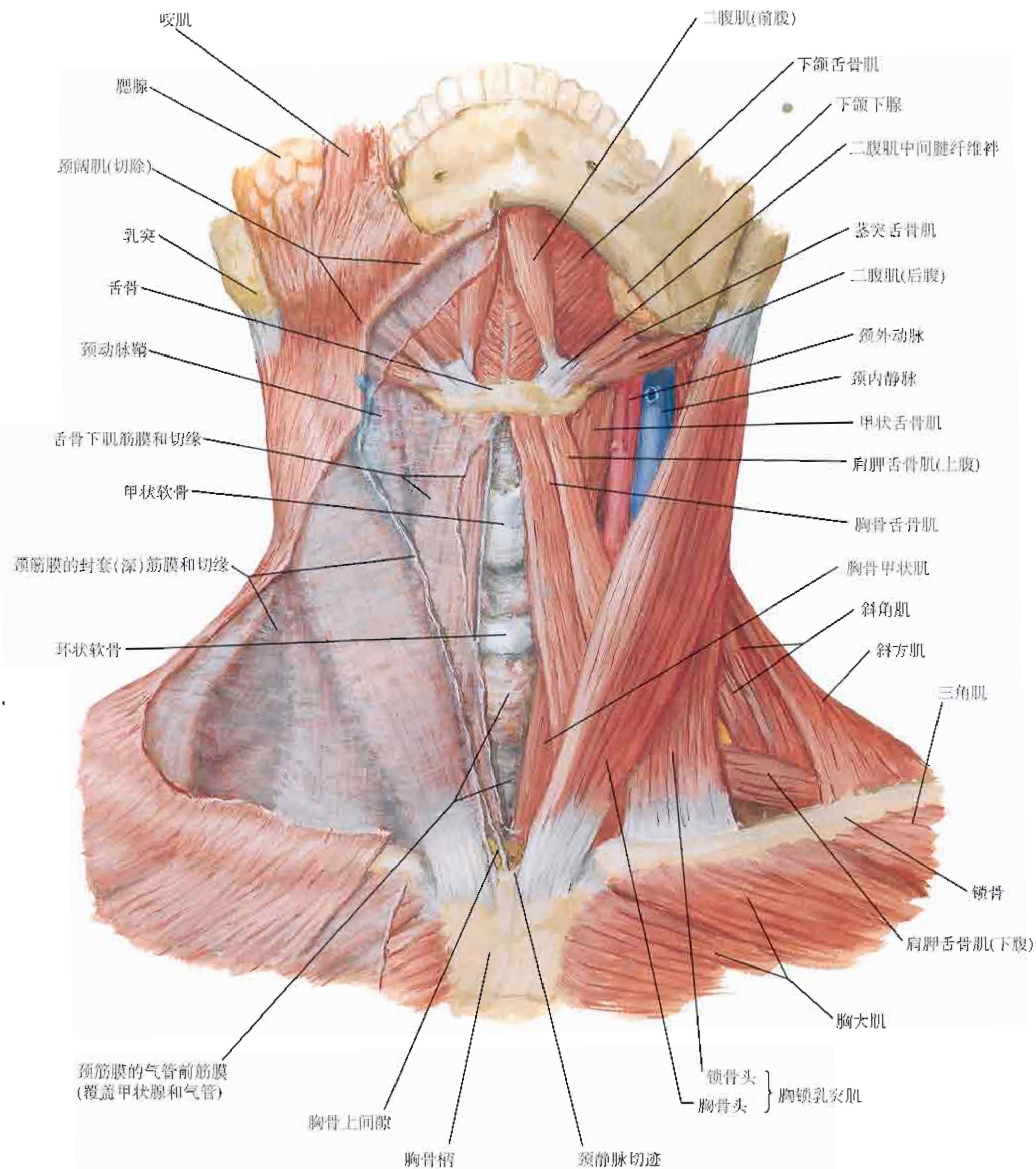


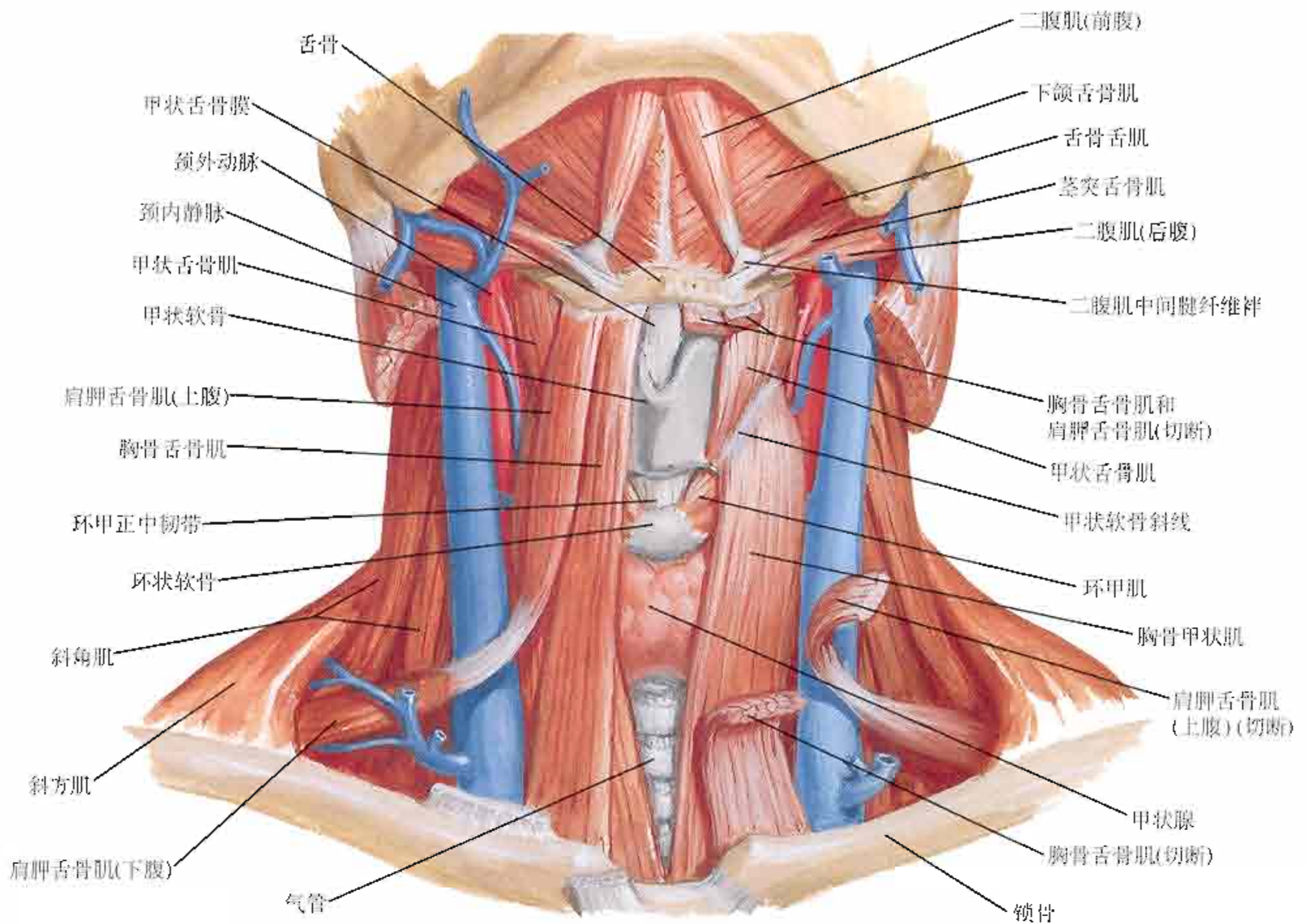
面部表情肌：外侧面观



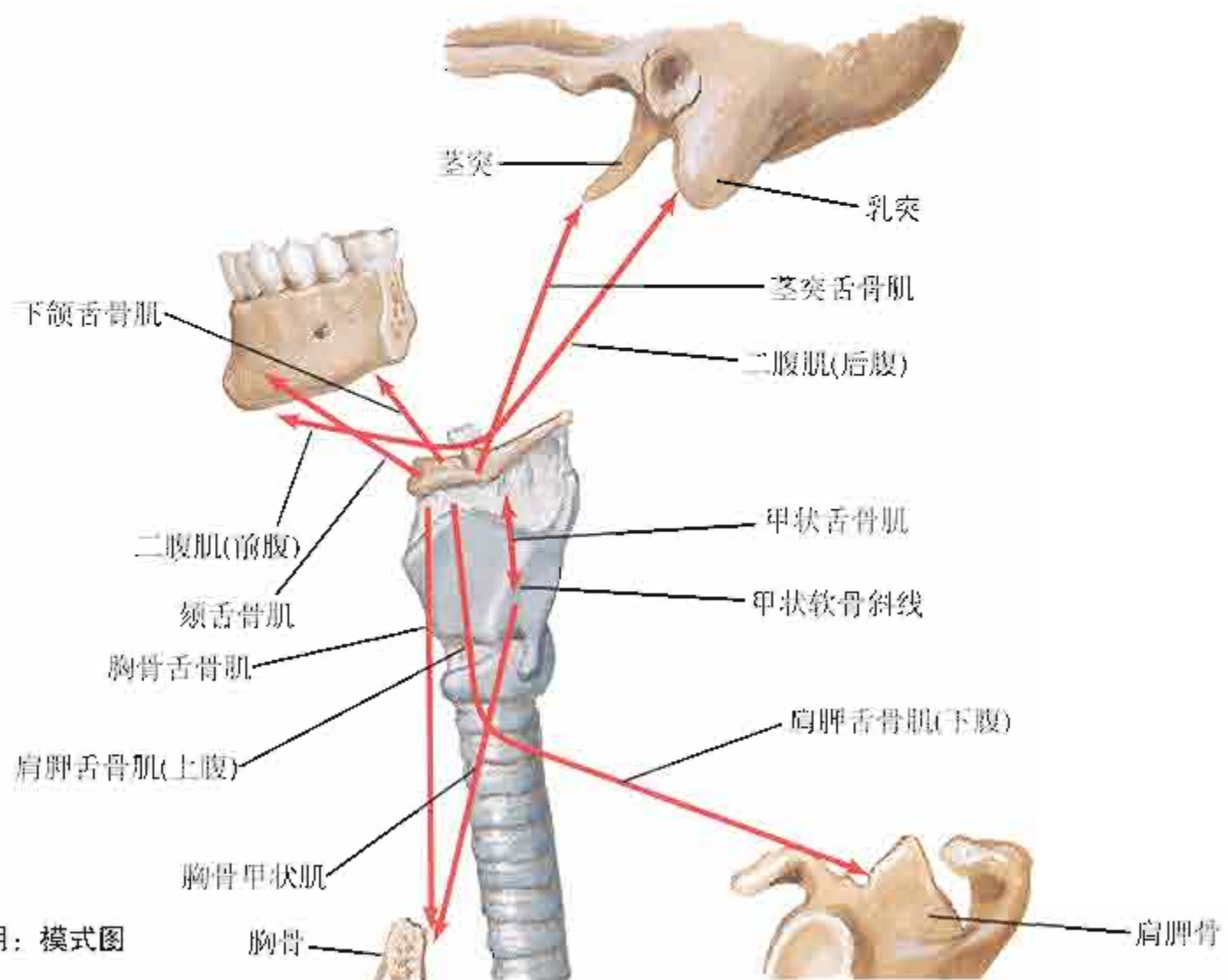


颈肌：前面观



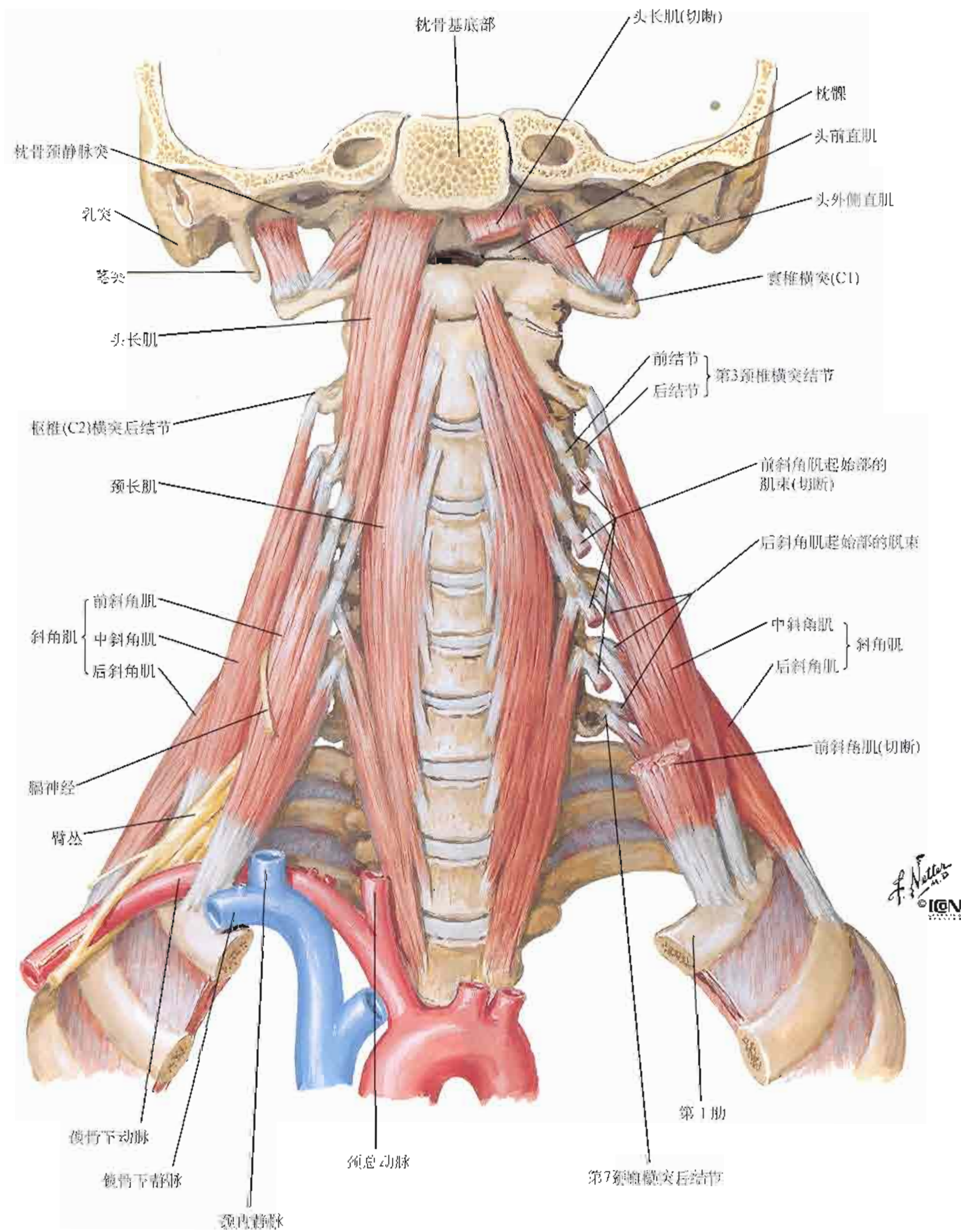


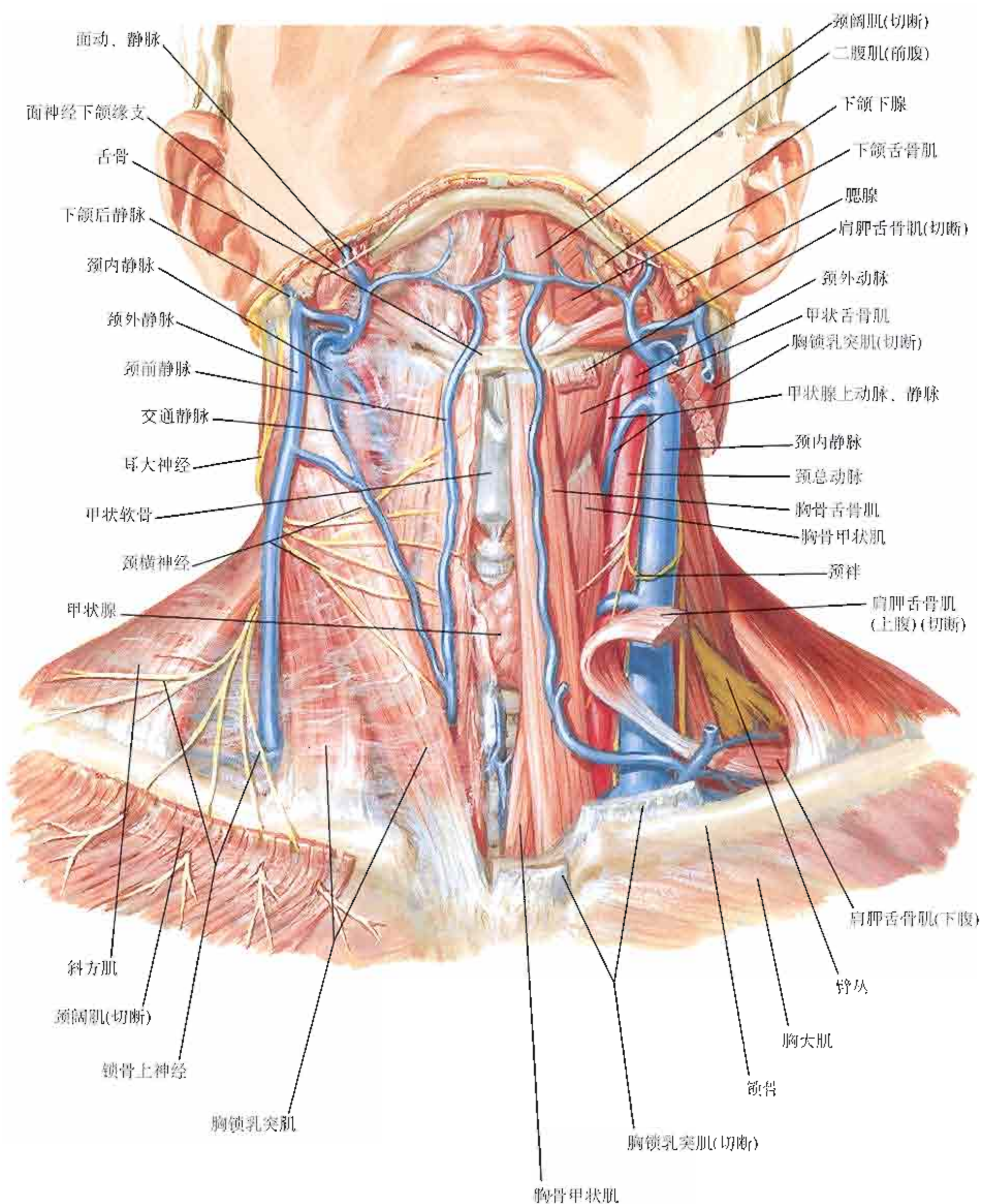
F. Netter M.D.
© 1996



舌骨上、下肌群及其作用：模式图

斜角肌和椎前肌

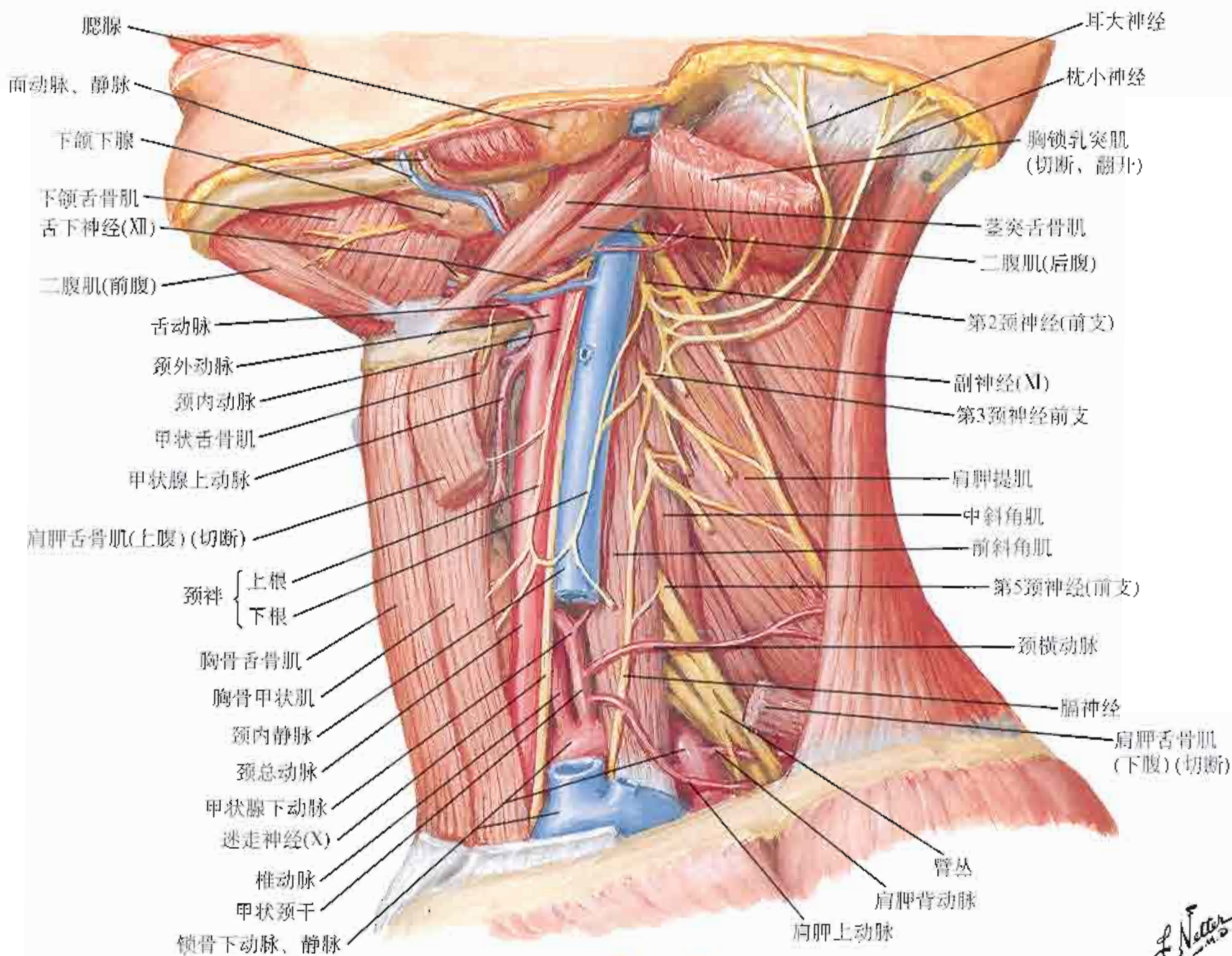




IGN

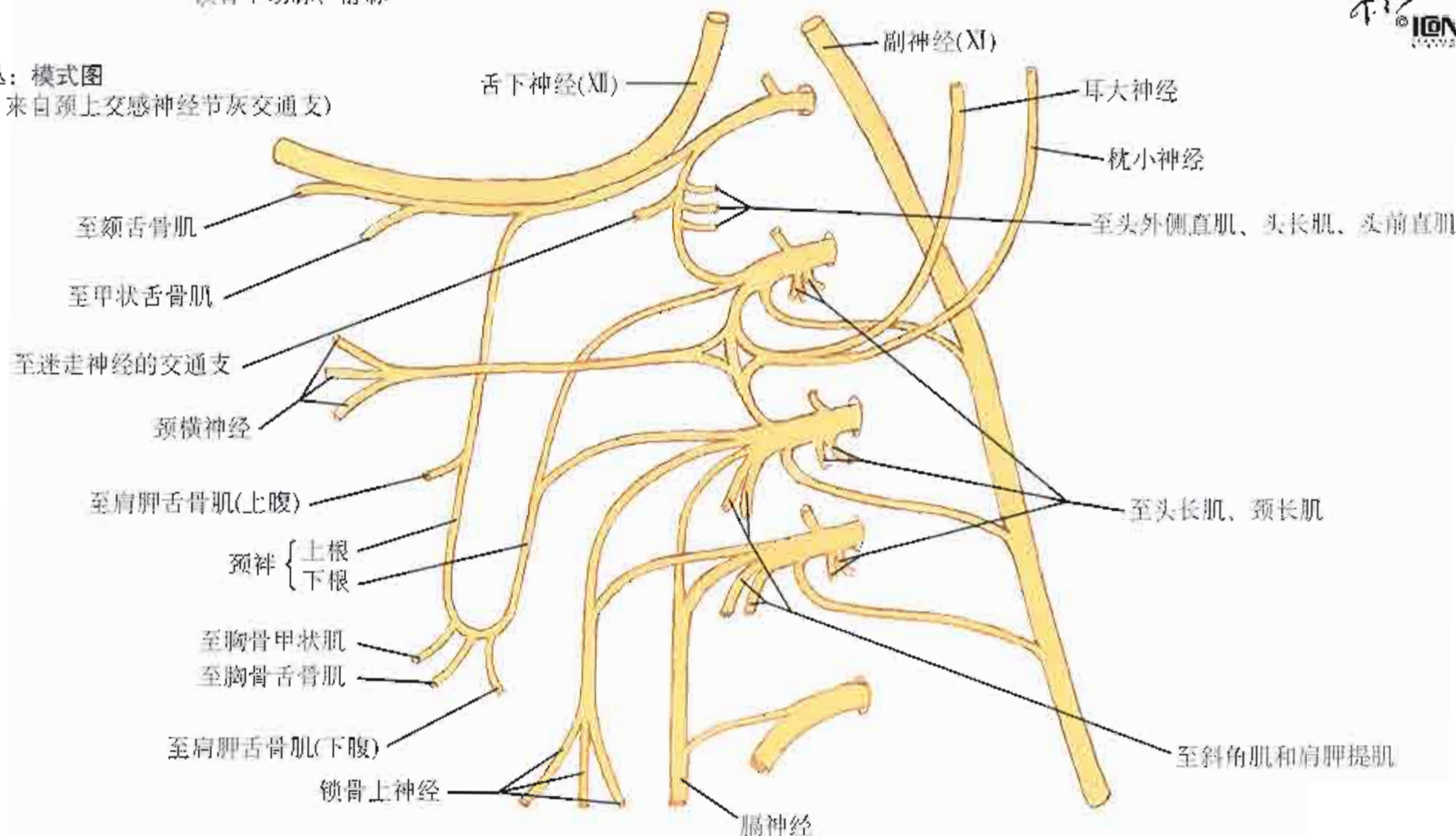
颈丛(原位)

参见图 121~123、190

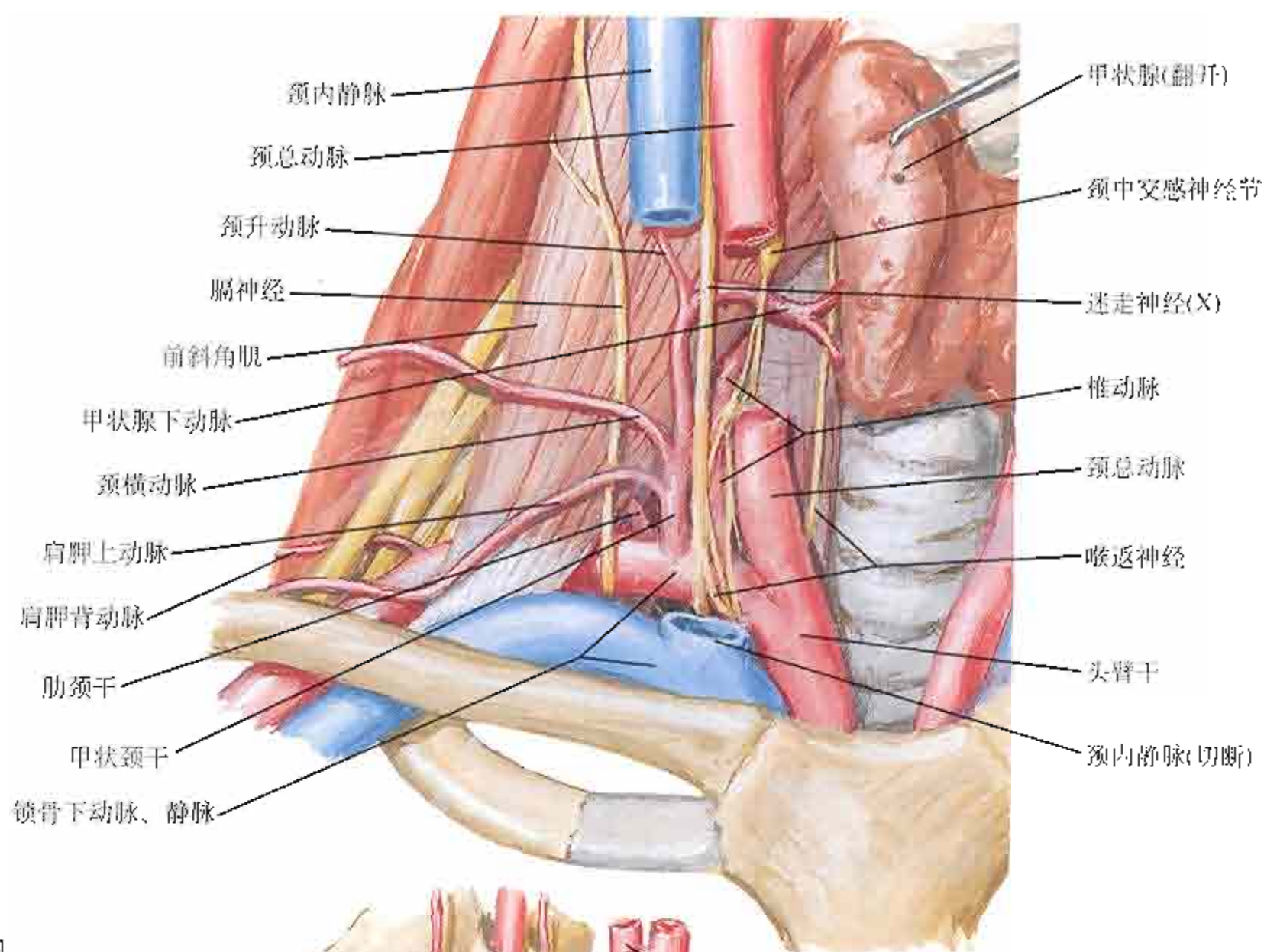


颈丛: 模式图

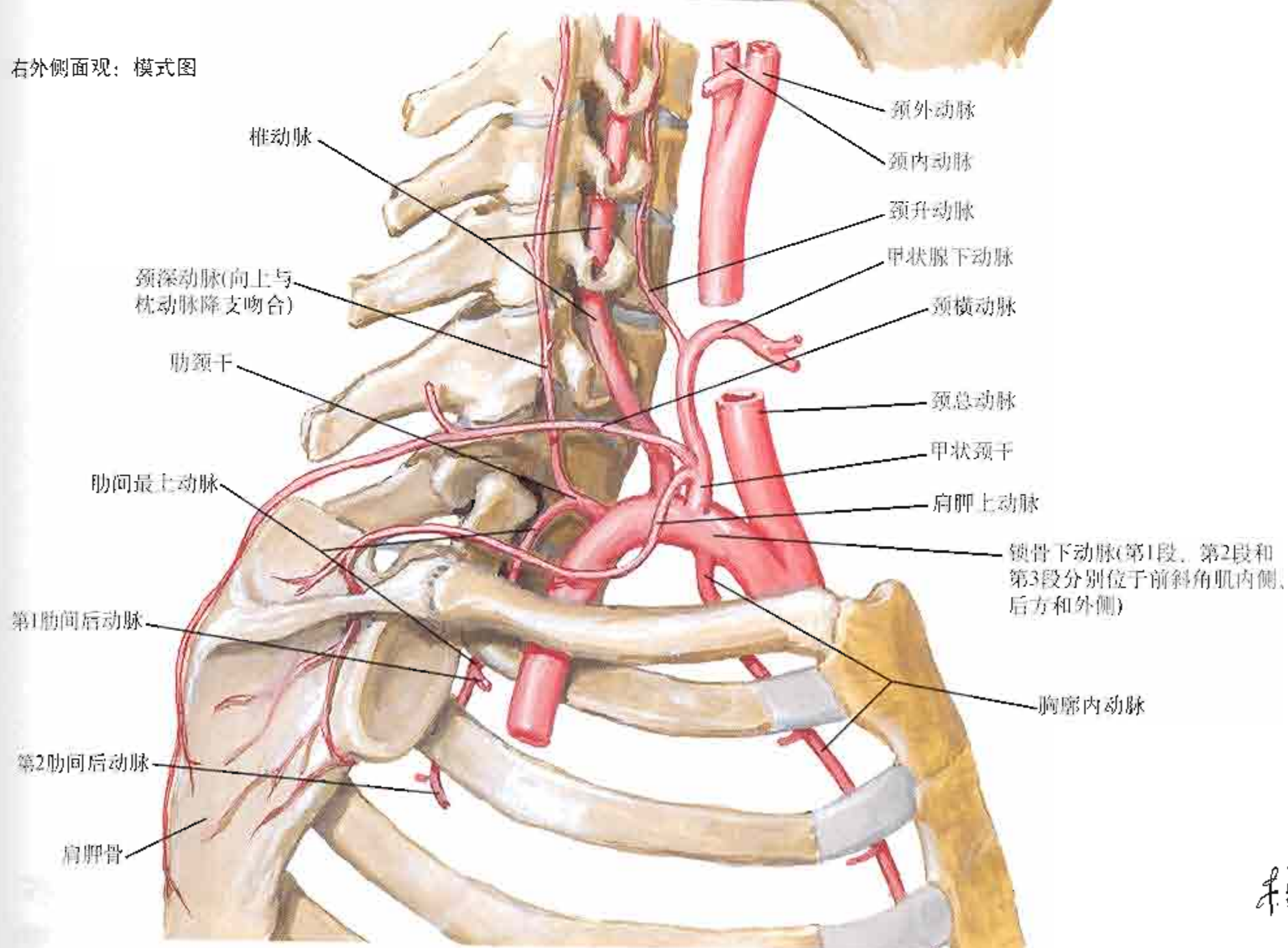
(S: 来自颈上交感神经节灰交通支)



右侧前面解剖



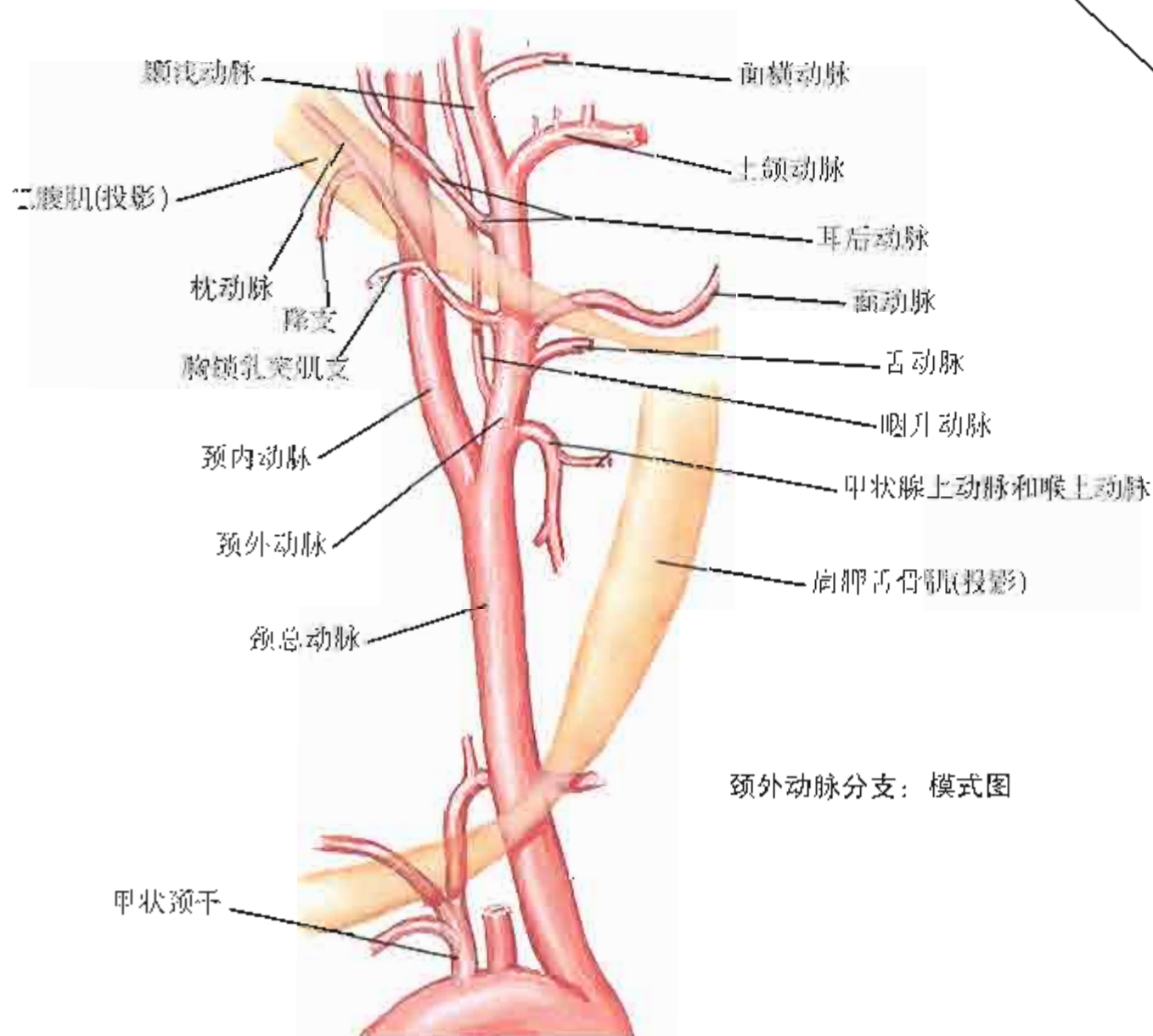
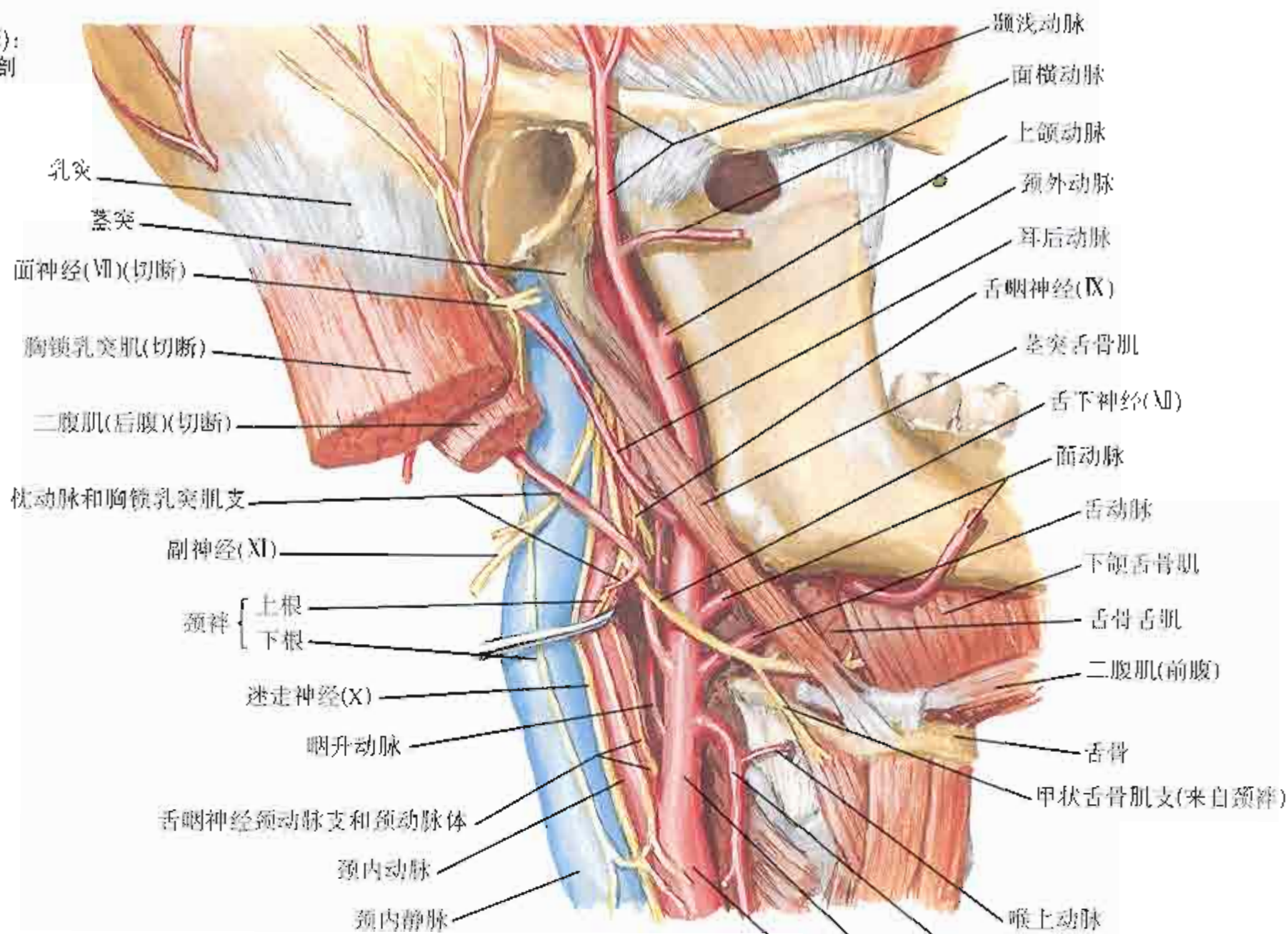
右外侧面观：模式图



颈动脉

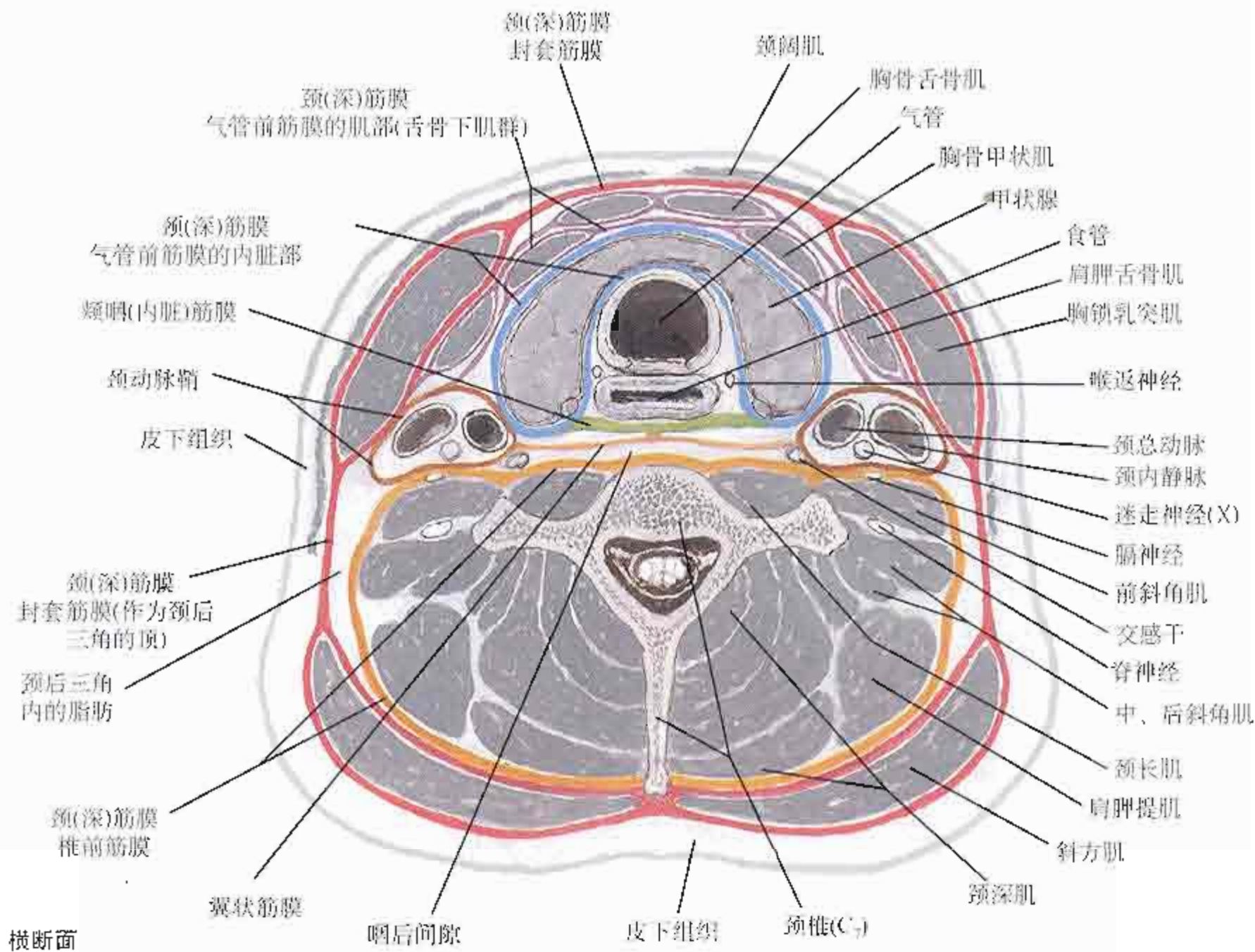
参见图 130、131

腮腺间隙(床):
右外侧面解剖

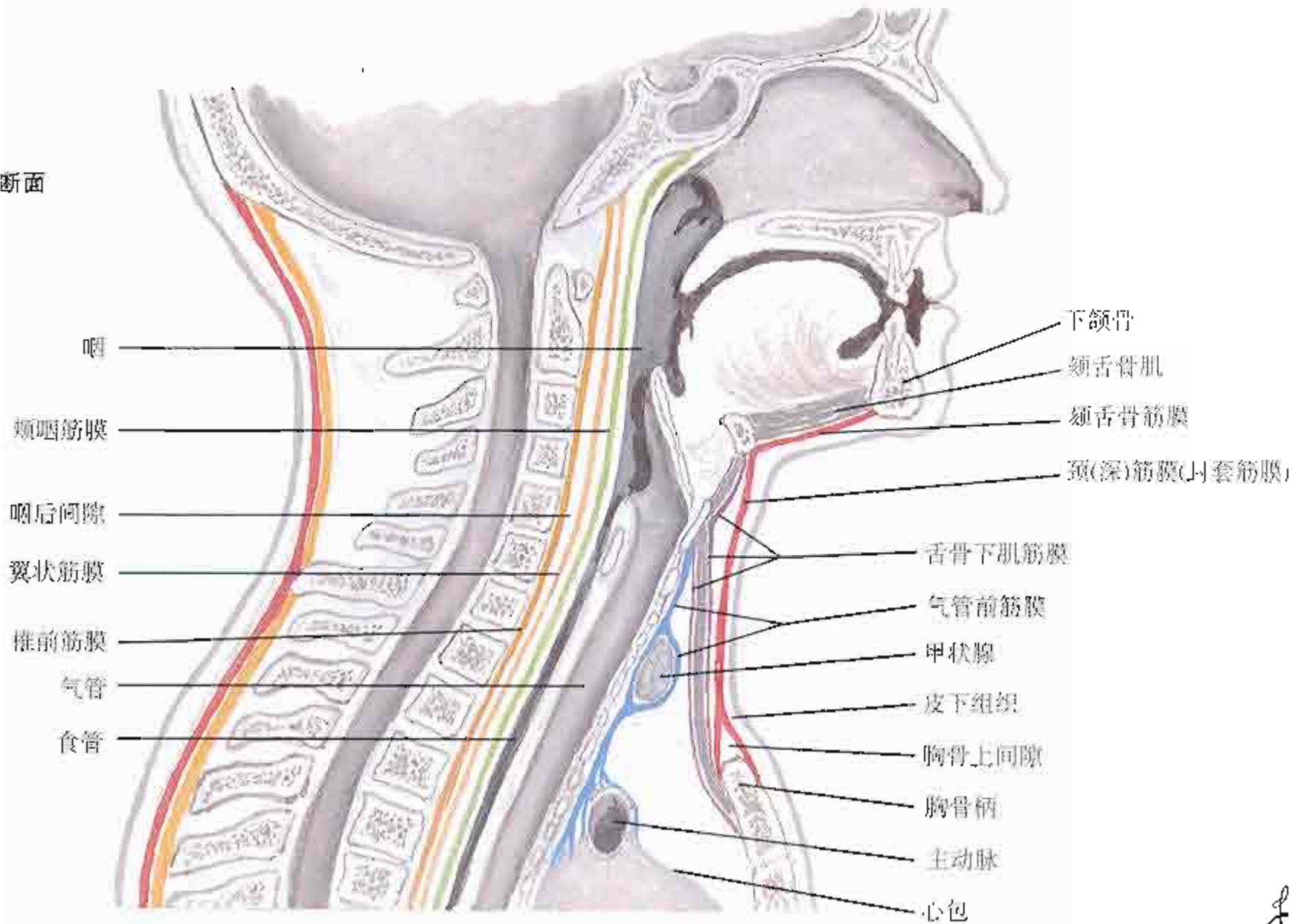


颈外动脉分支: 模式图

颈动脉鞘的内容参见图 65~67

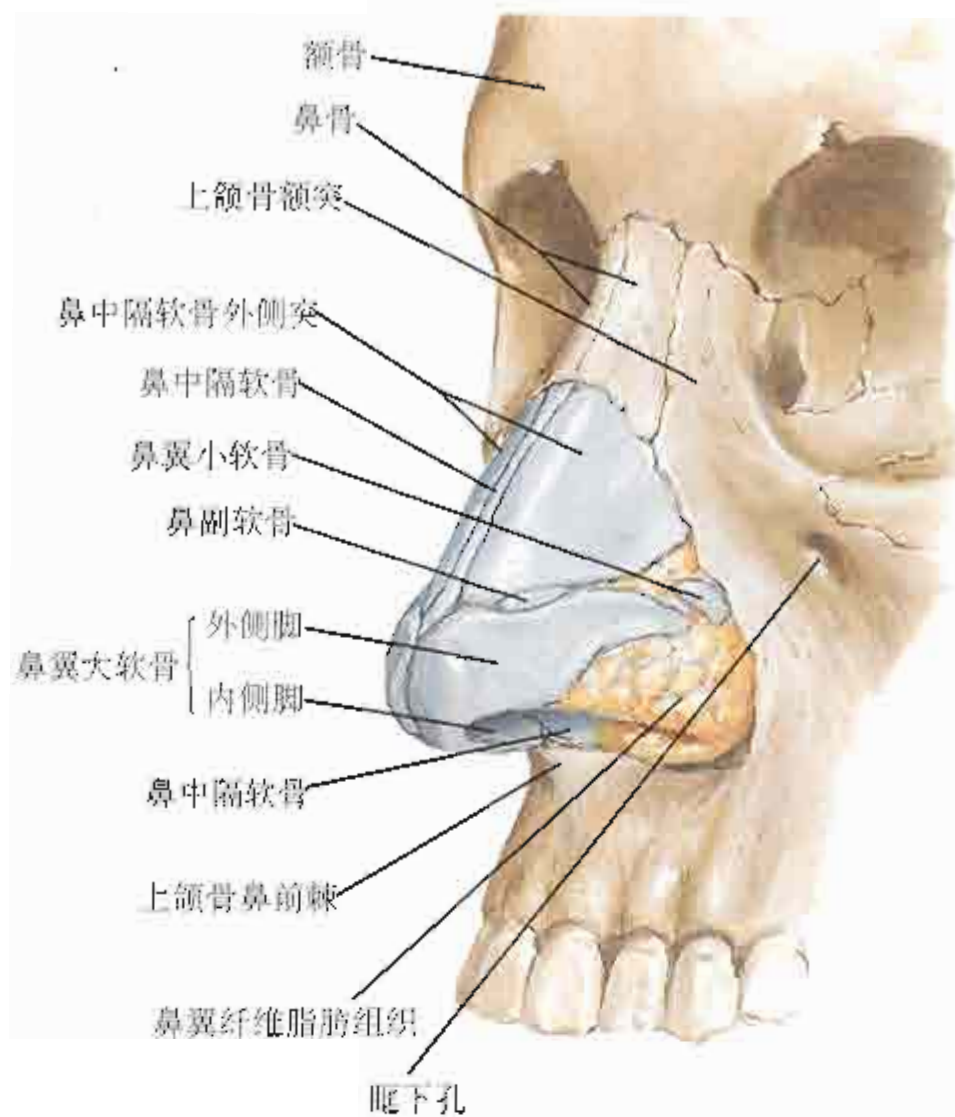


矢状断面

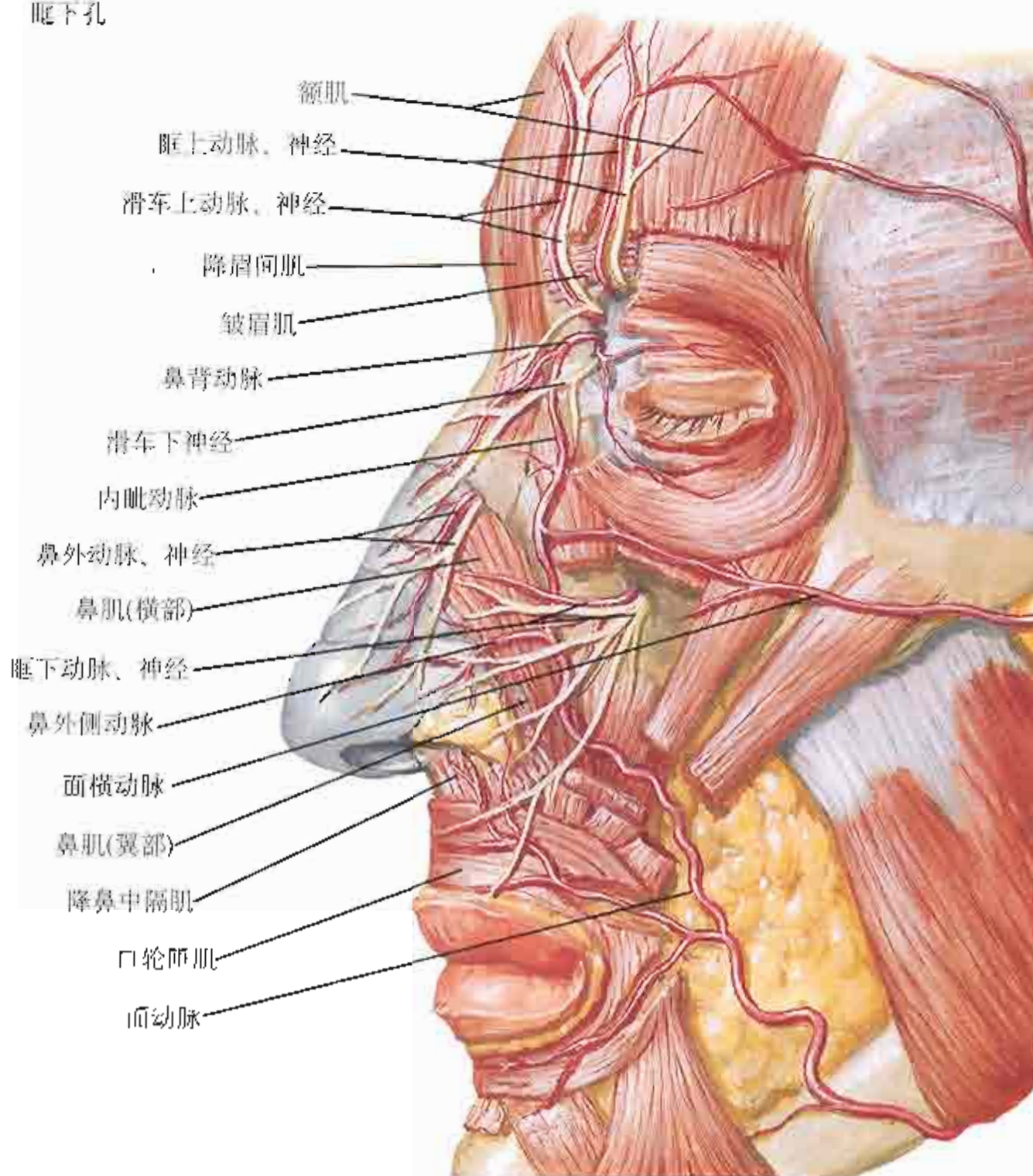
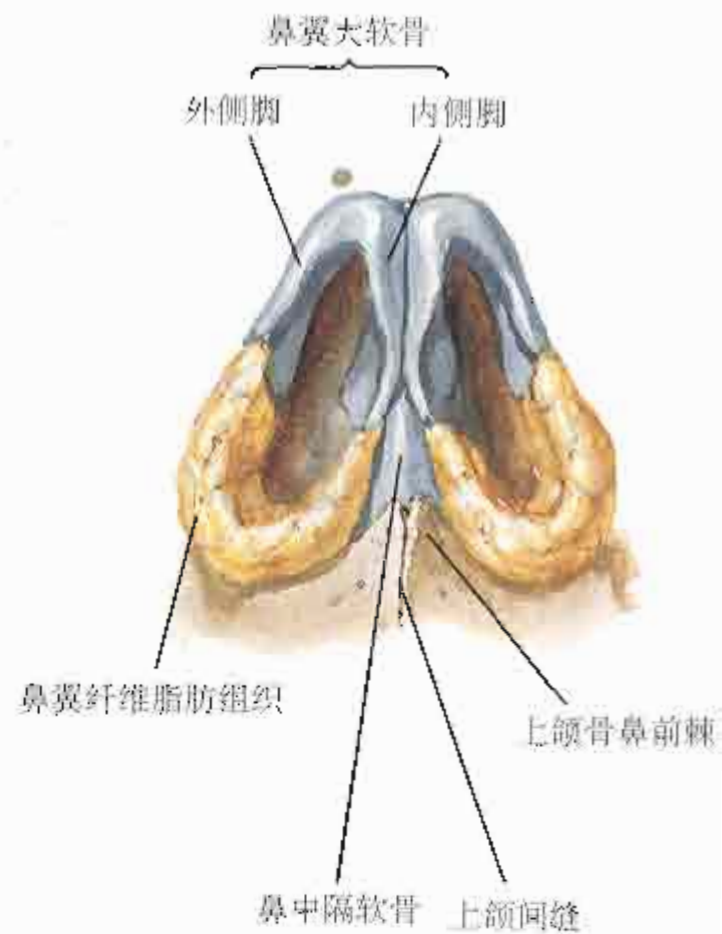


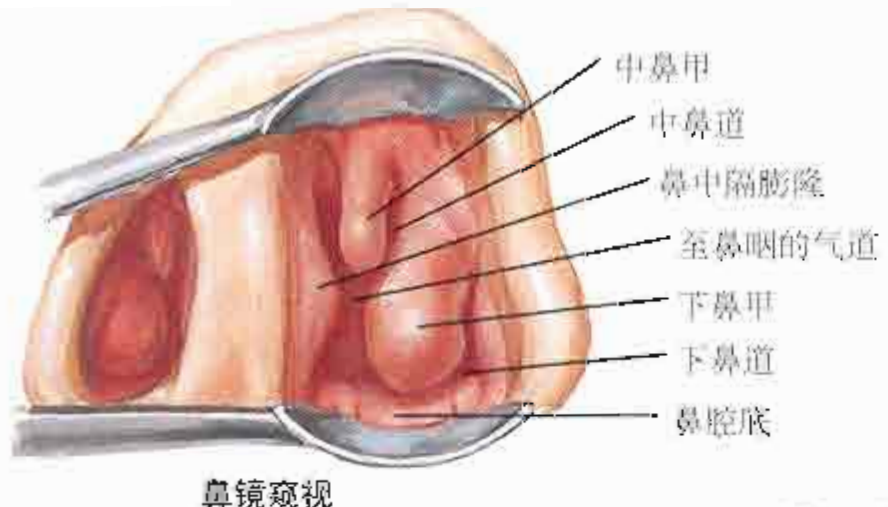
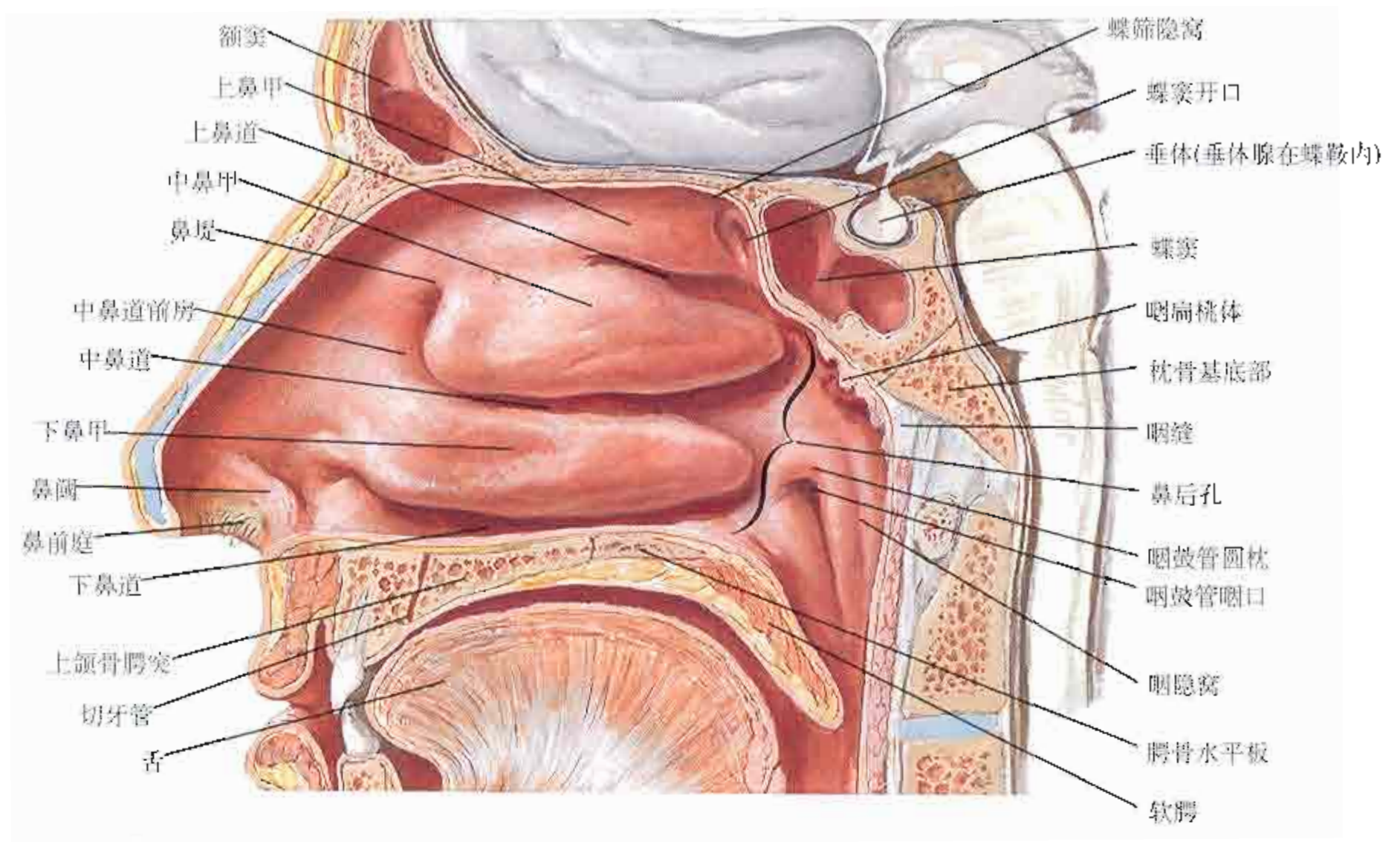
F. Netter M.D.
© IGM

前外侧面观

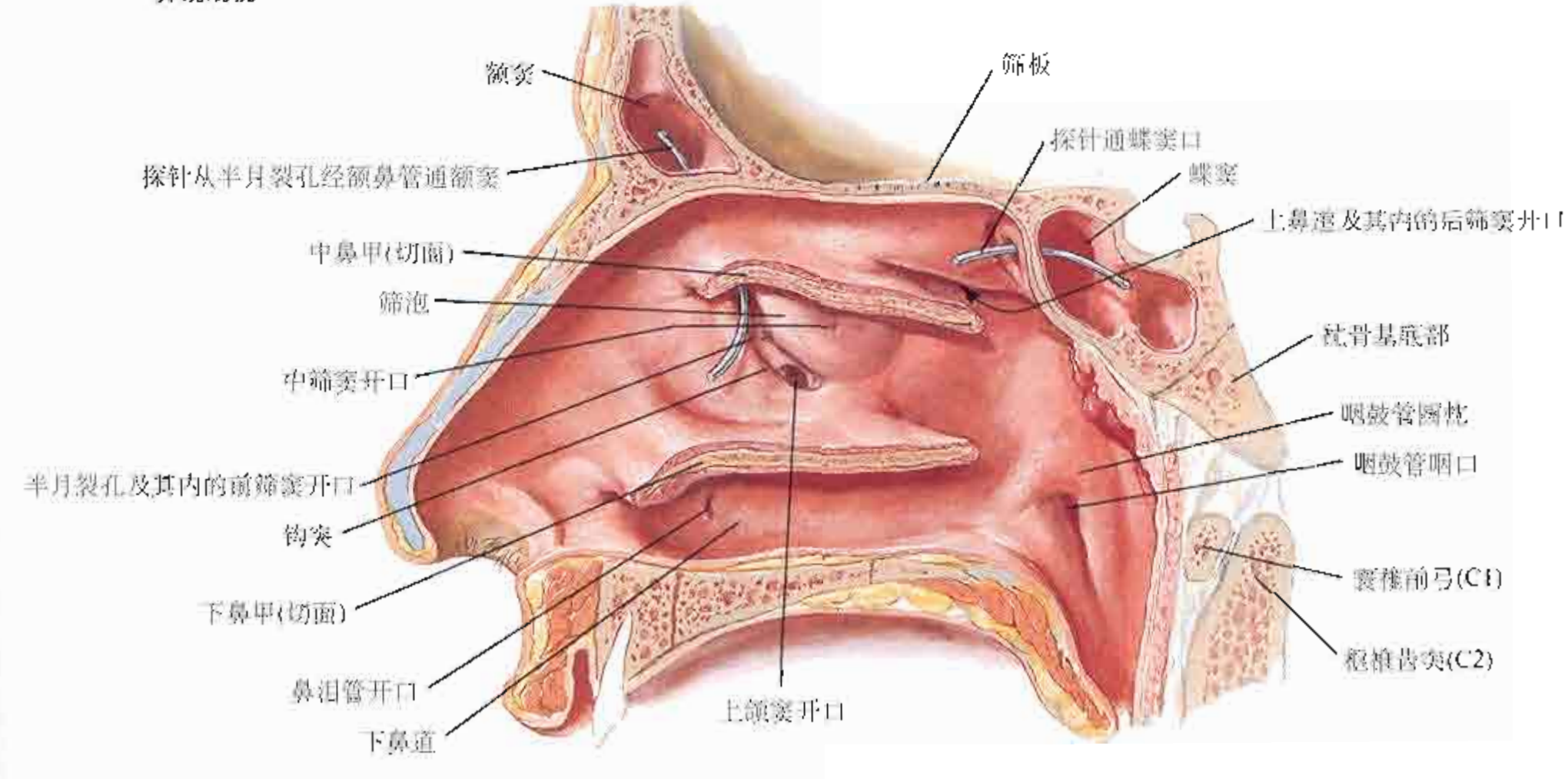


下面观



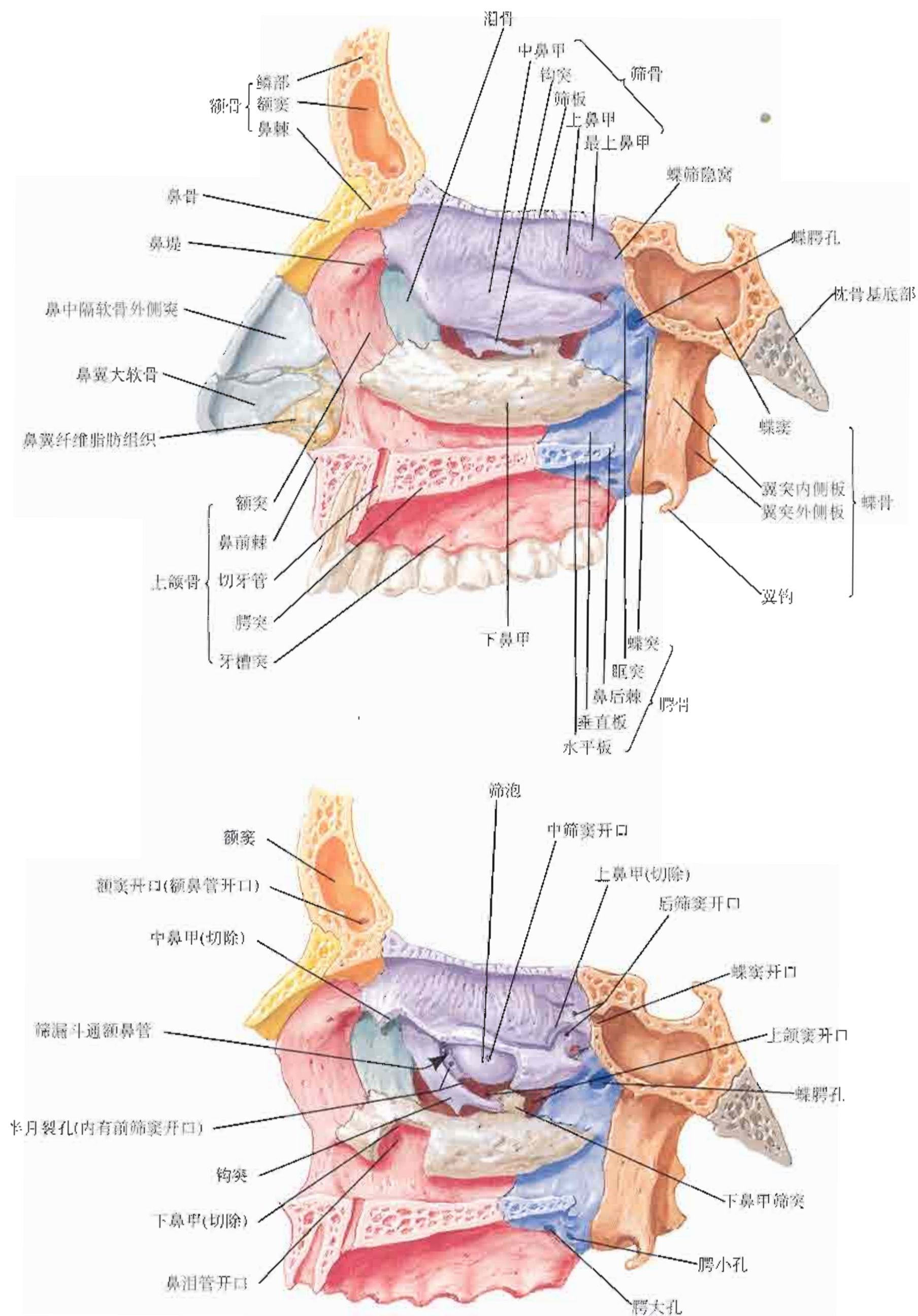


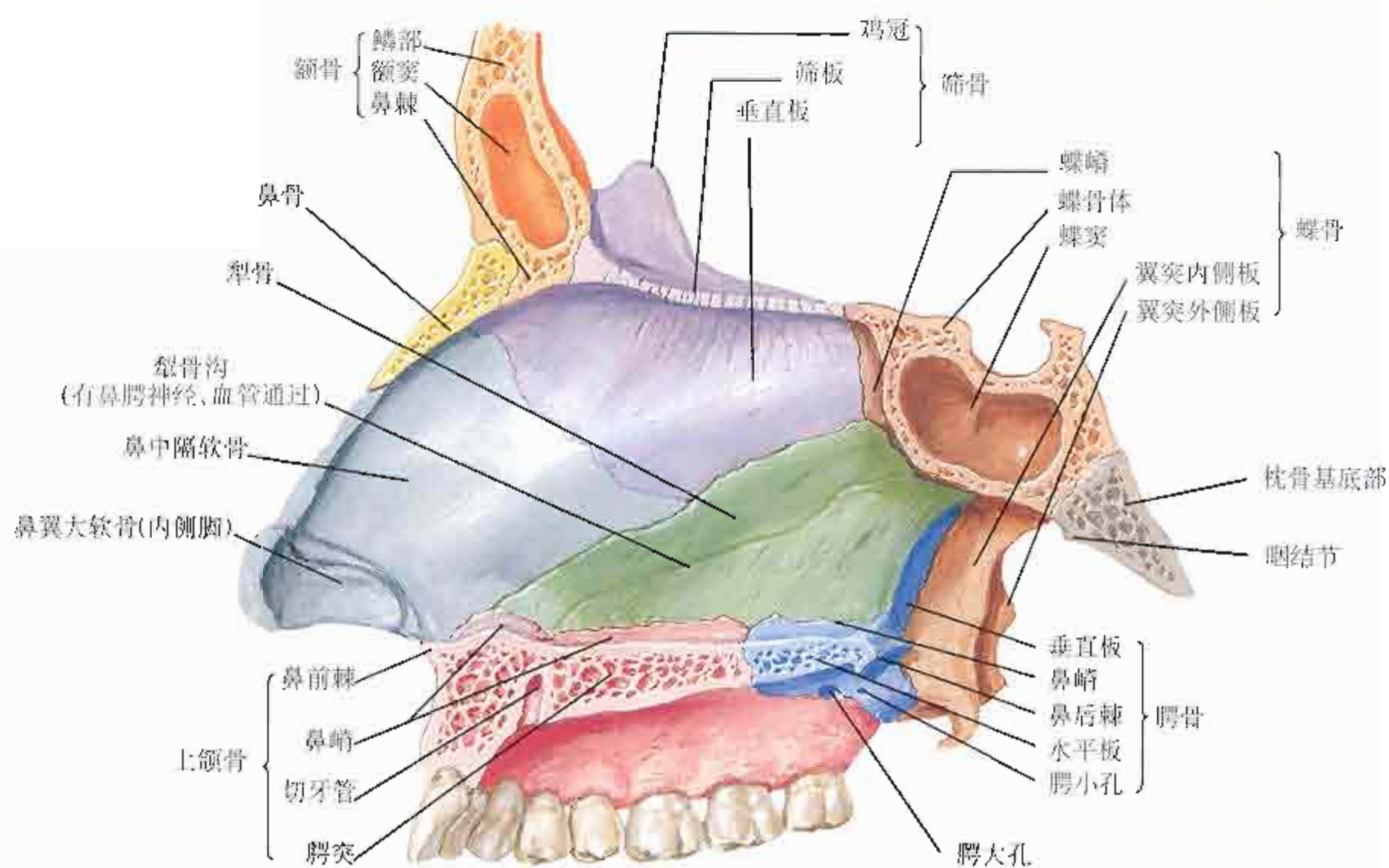
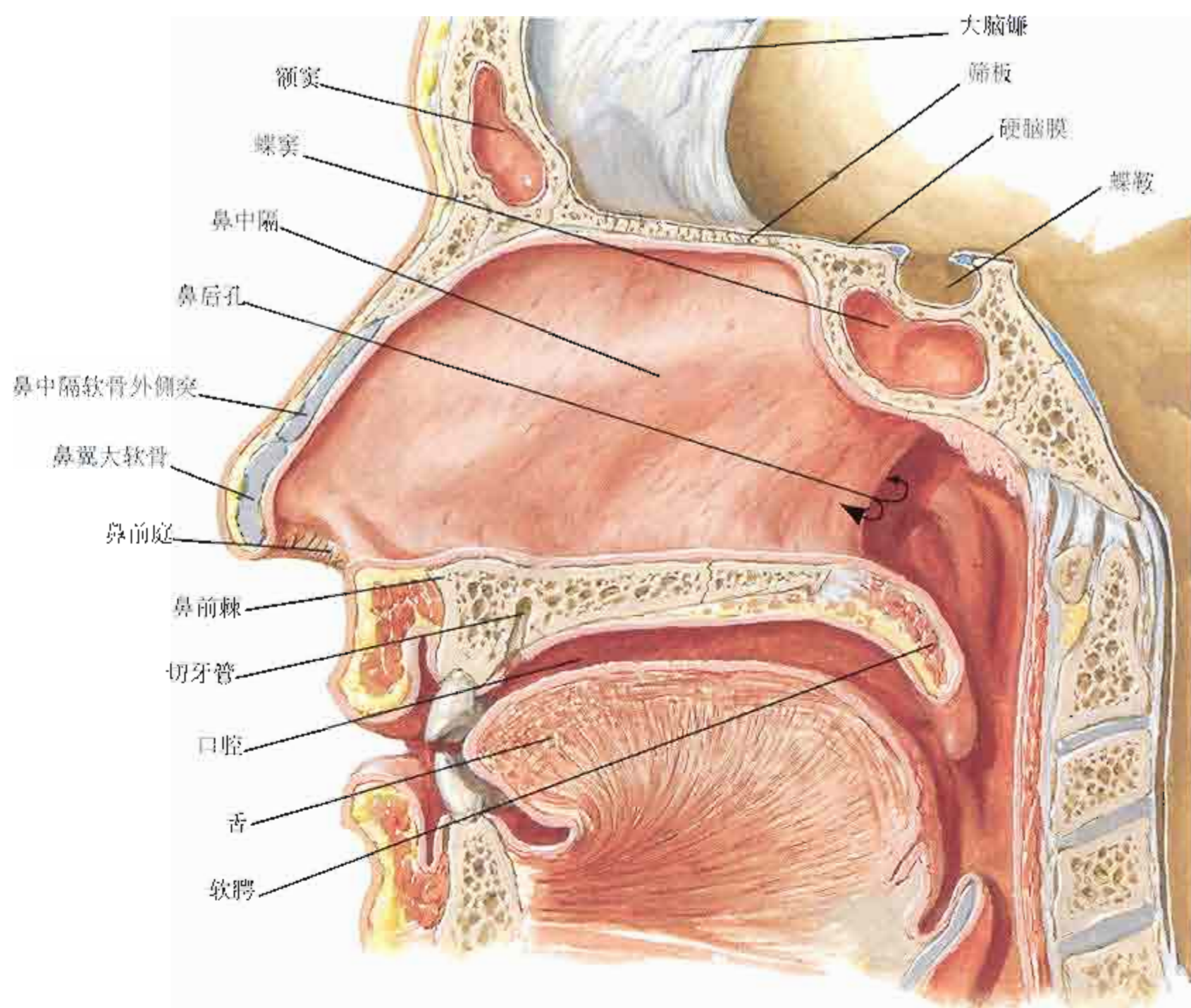
F. Netter M.D.
© 1996



鼻腔外侧壁 (续)

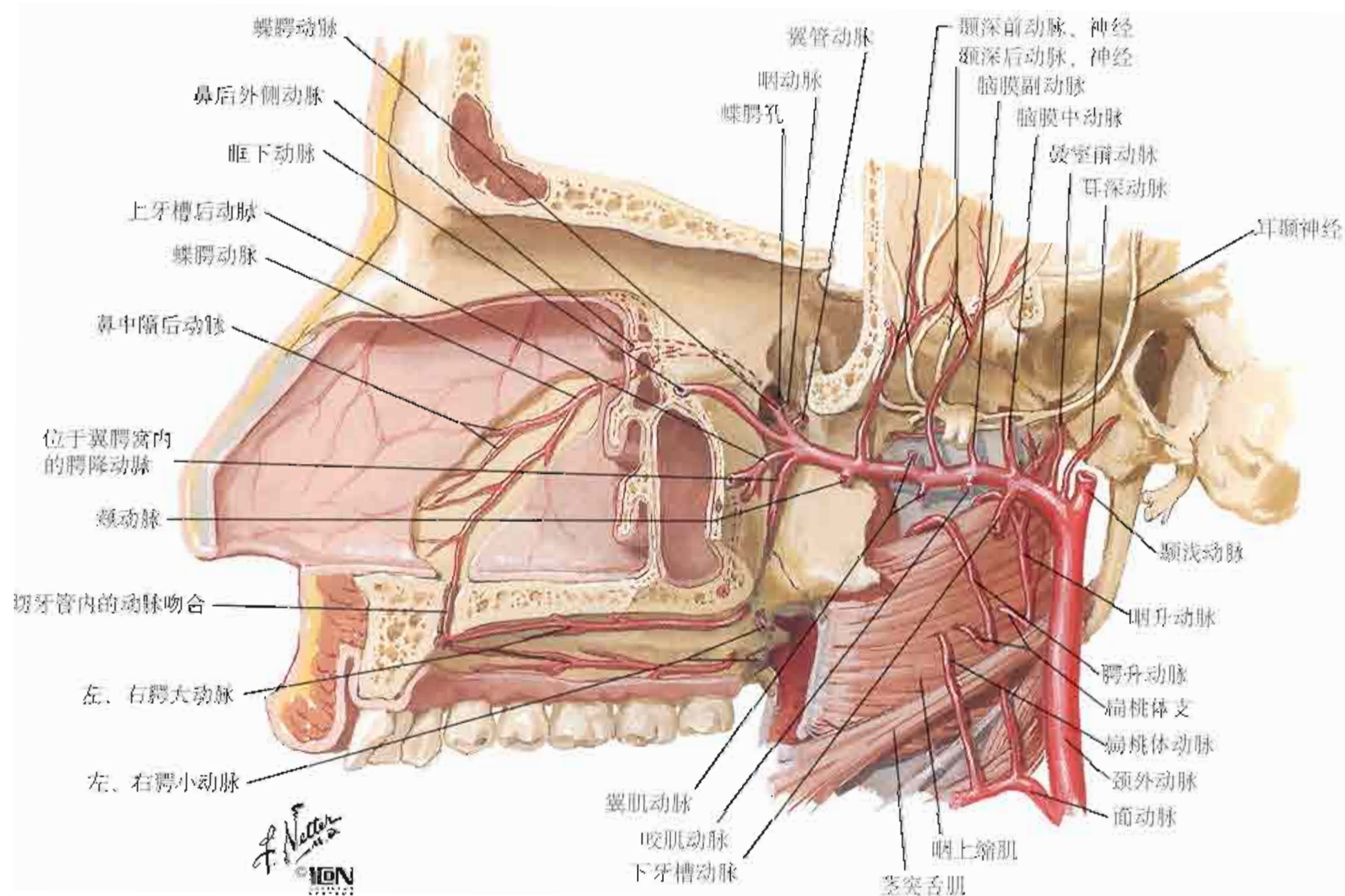
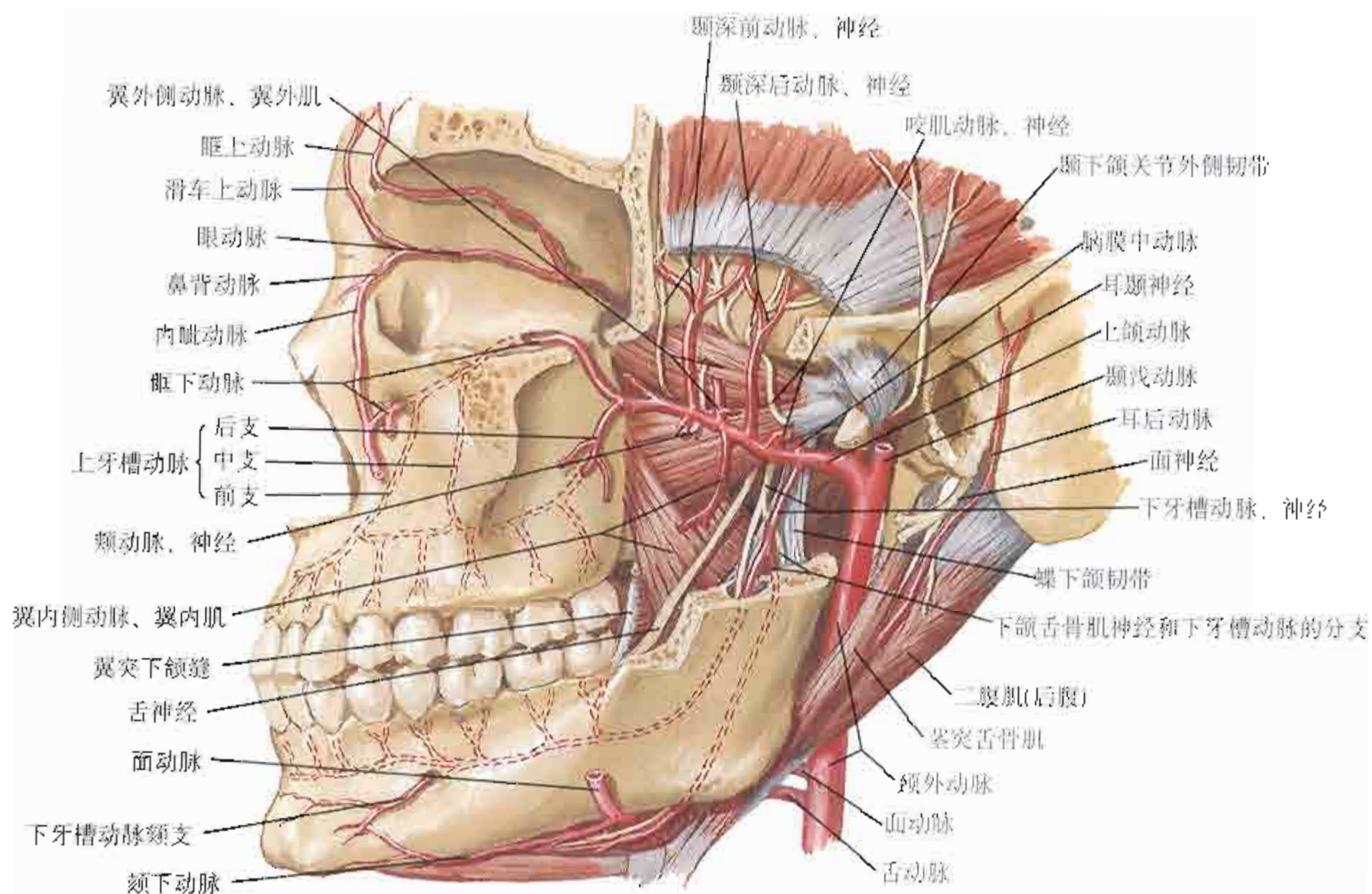
参见图6





上颌动脉

参见图 30



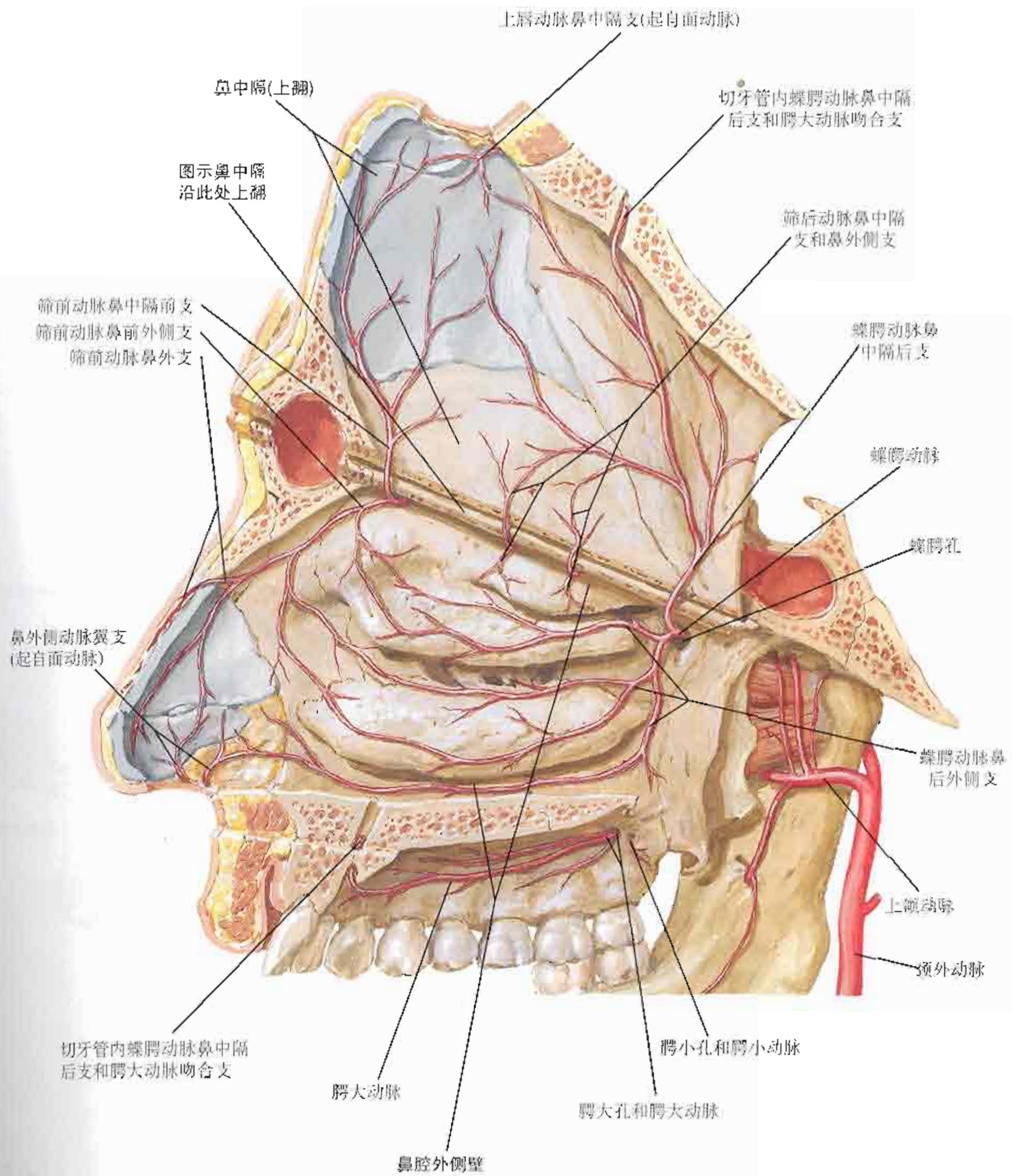
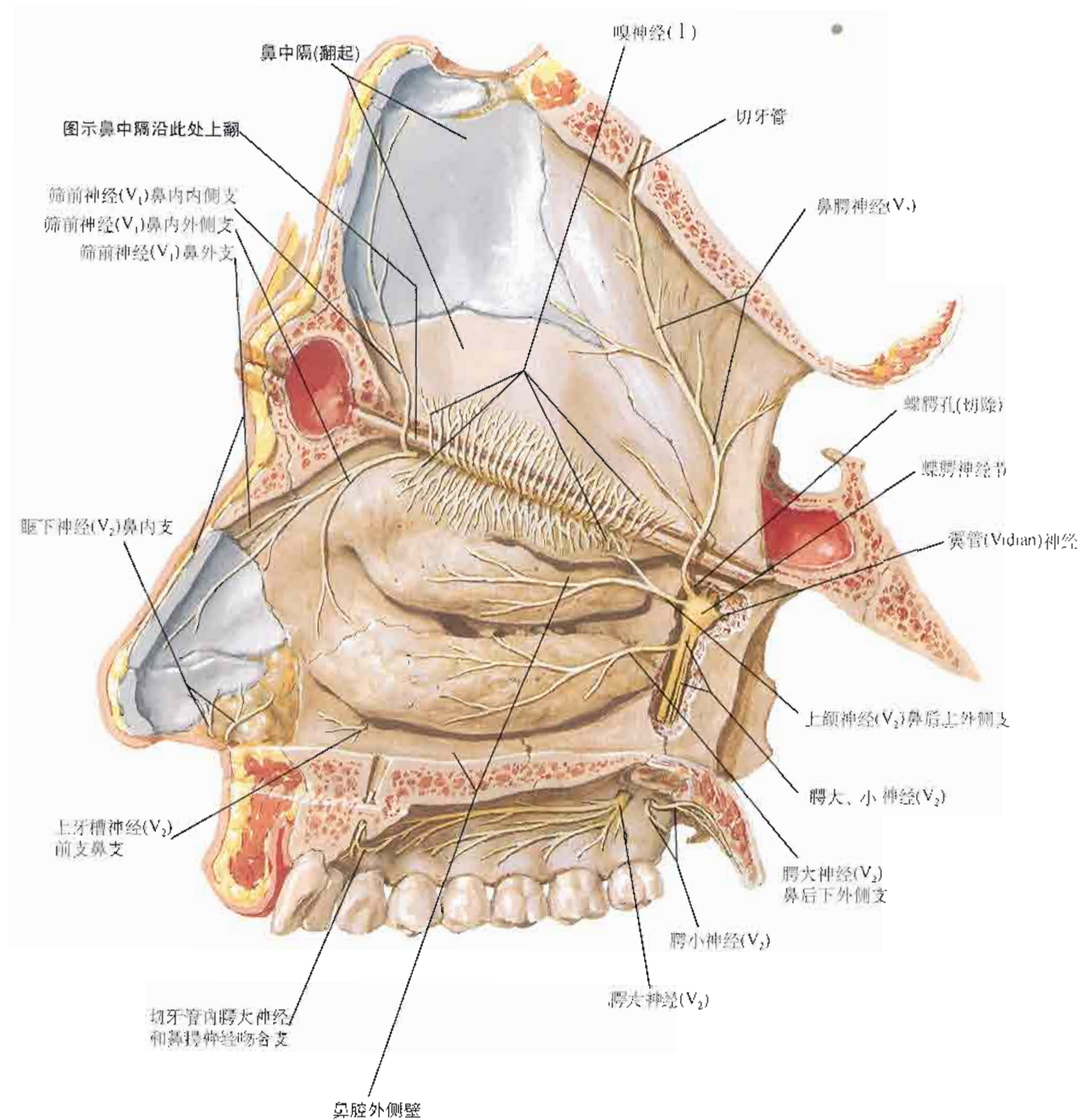
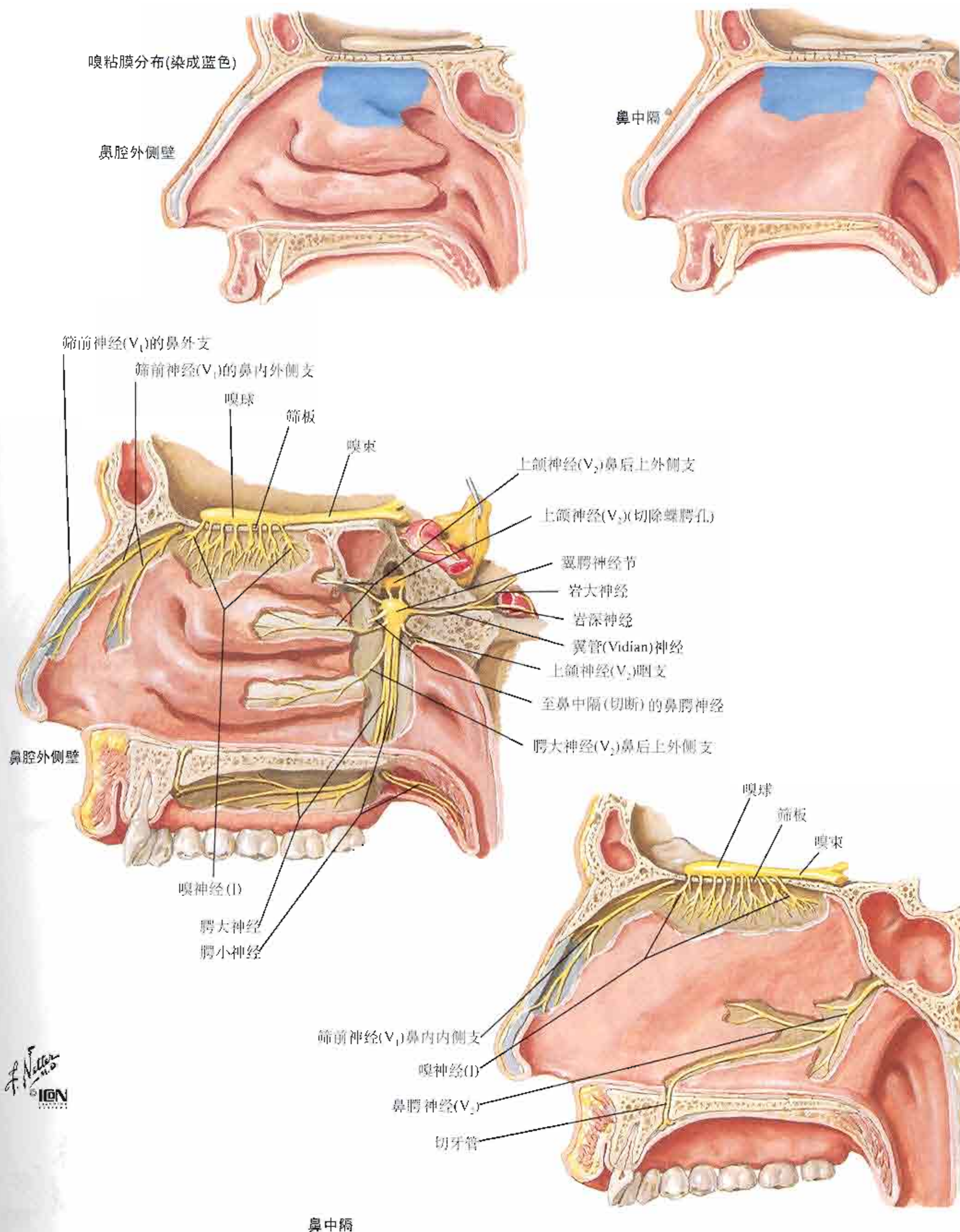


图37

鼻腔神经：鼻中隔上翻

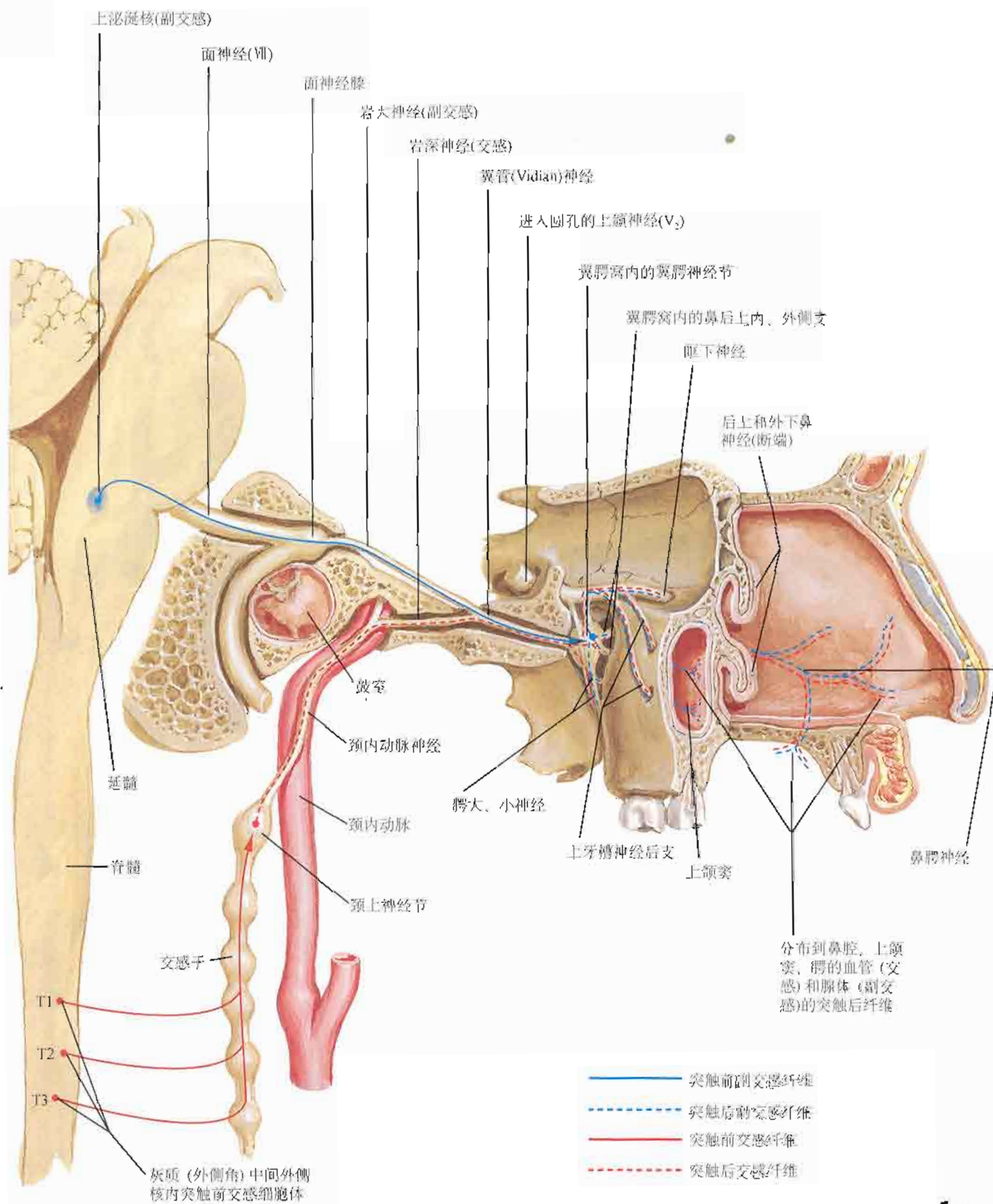
参见图 40、41、113





鼻腔自主神经分布

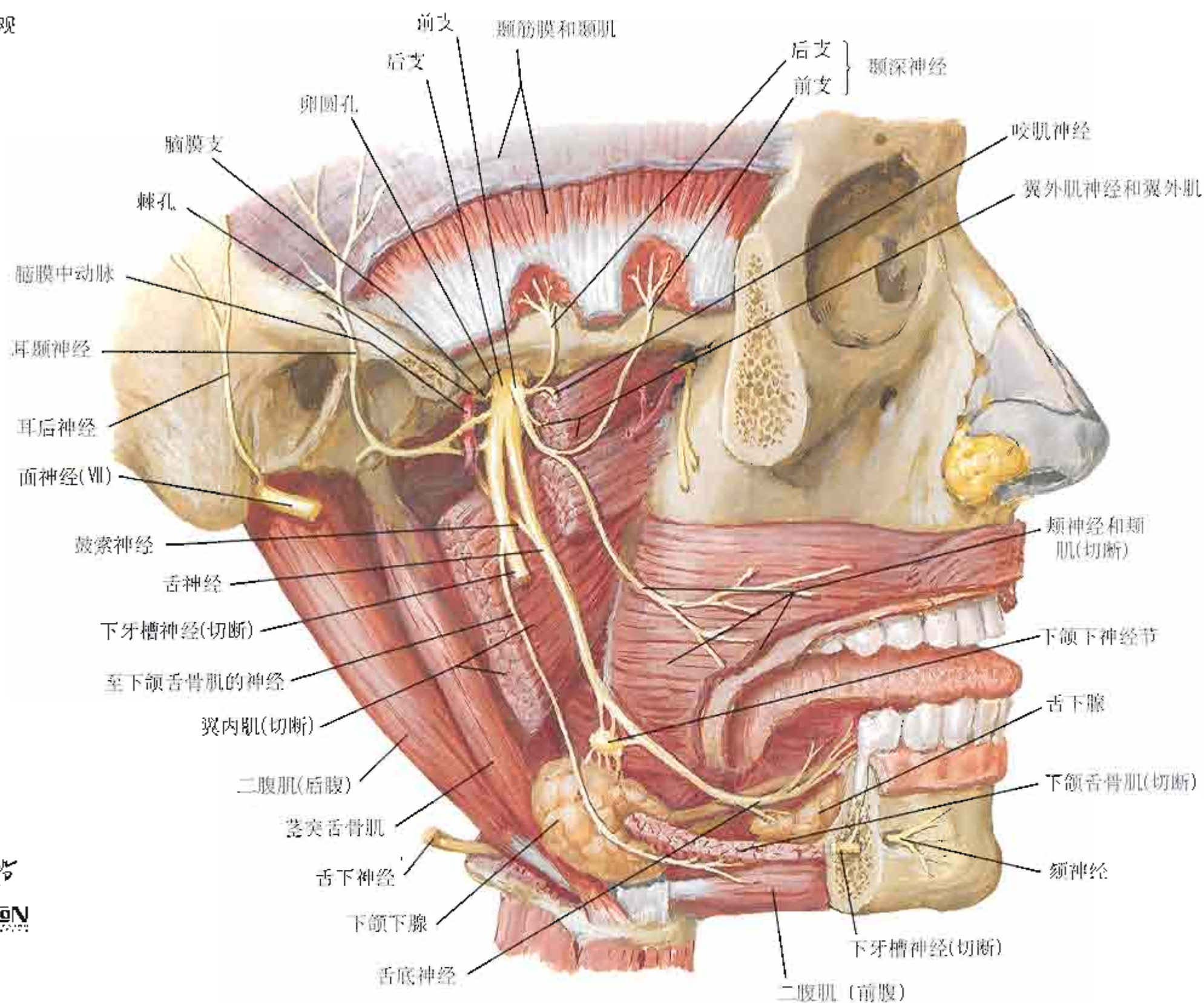
参见图 116、125、127



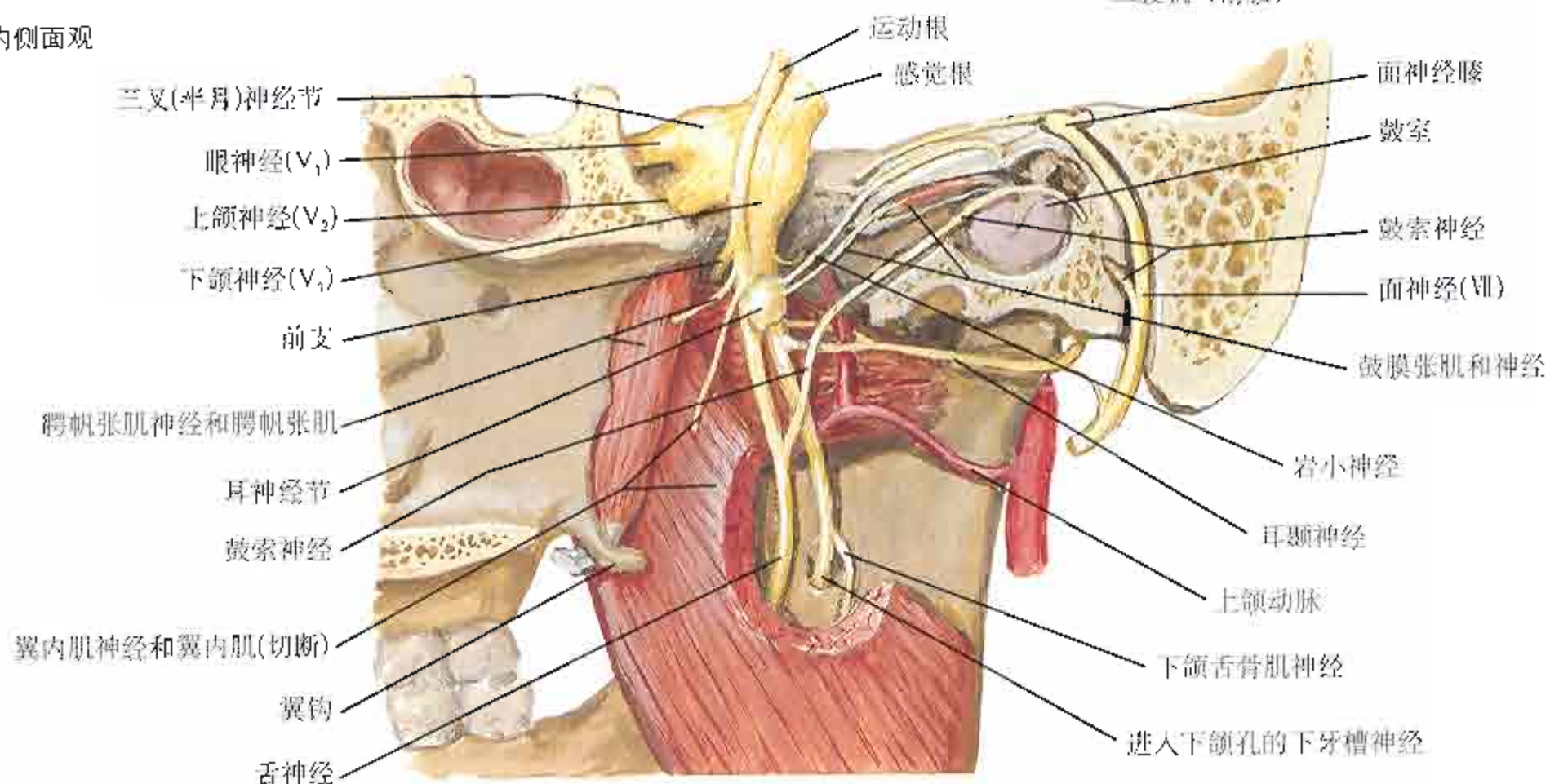
下颌神经(V₃)

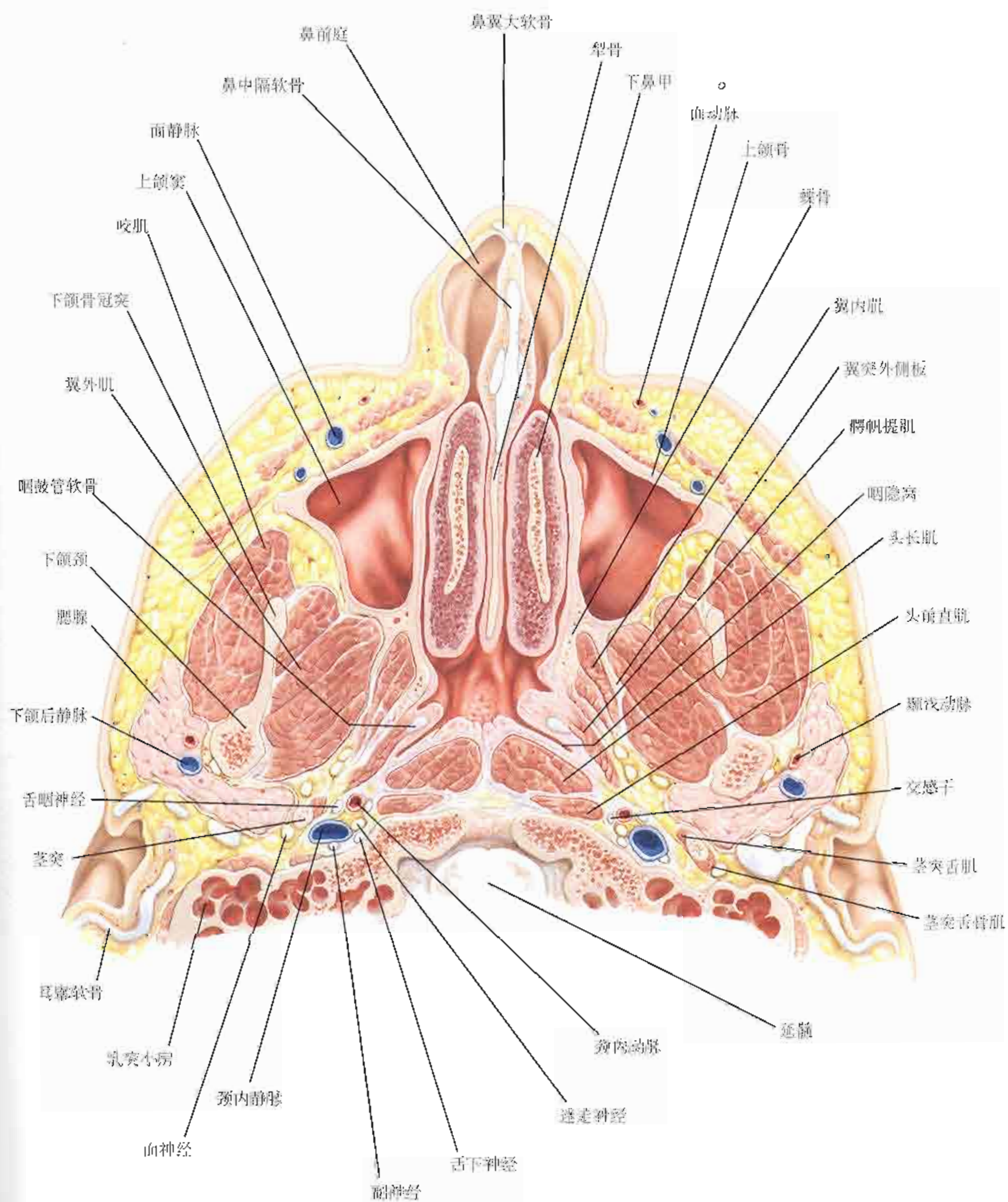
参见图 67、116

外侧面观



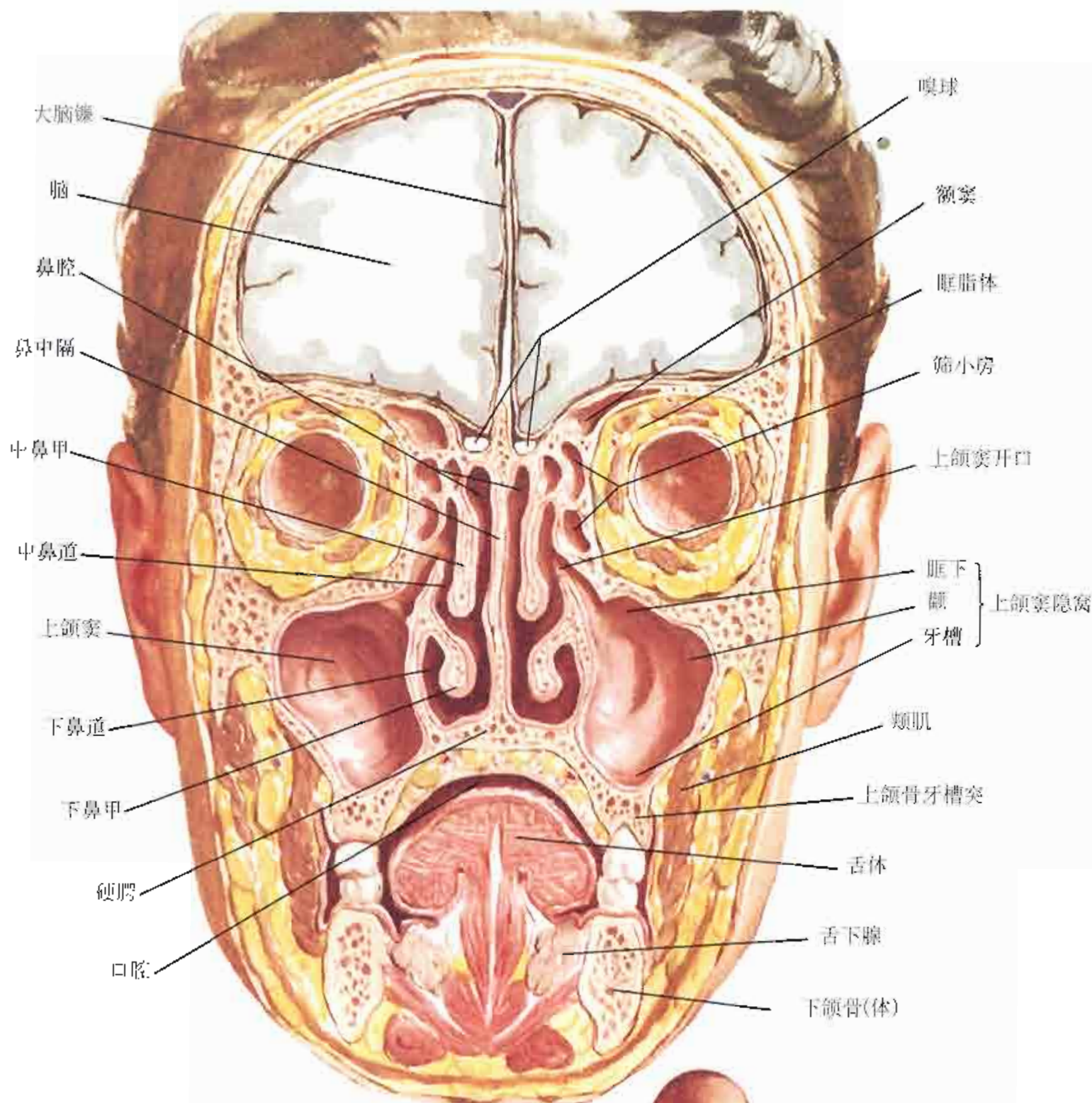
内侧面观



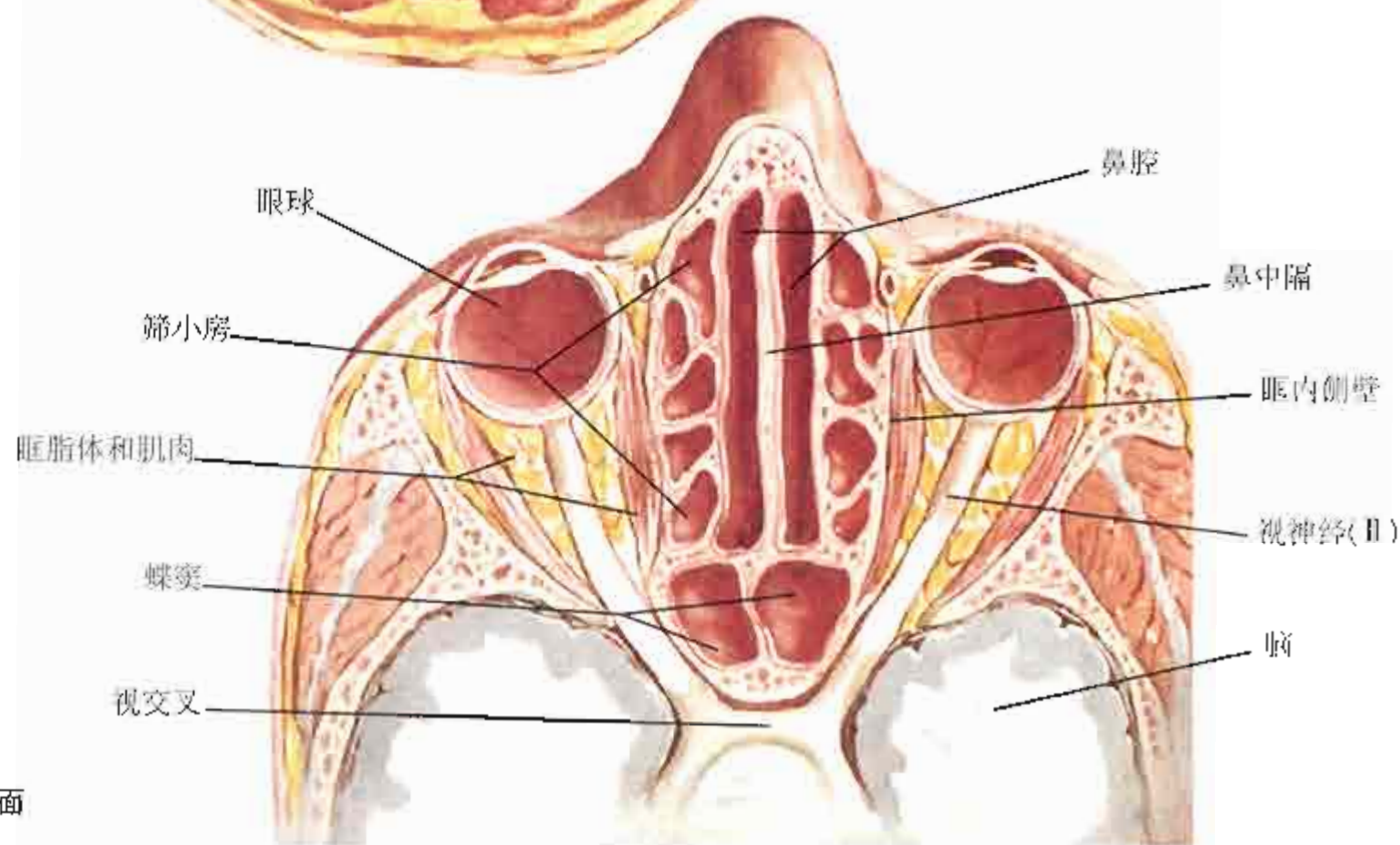


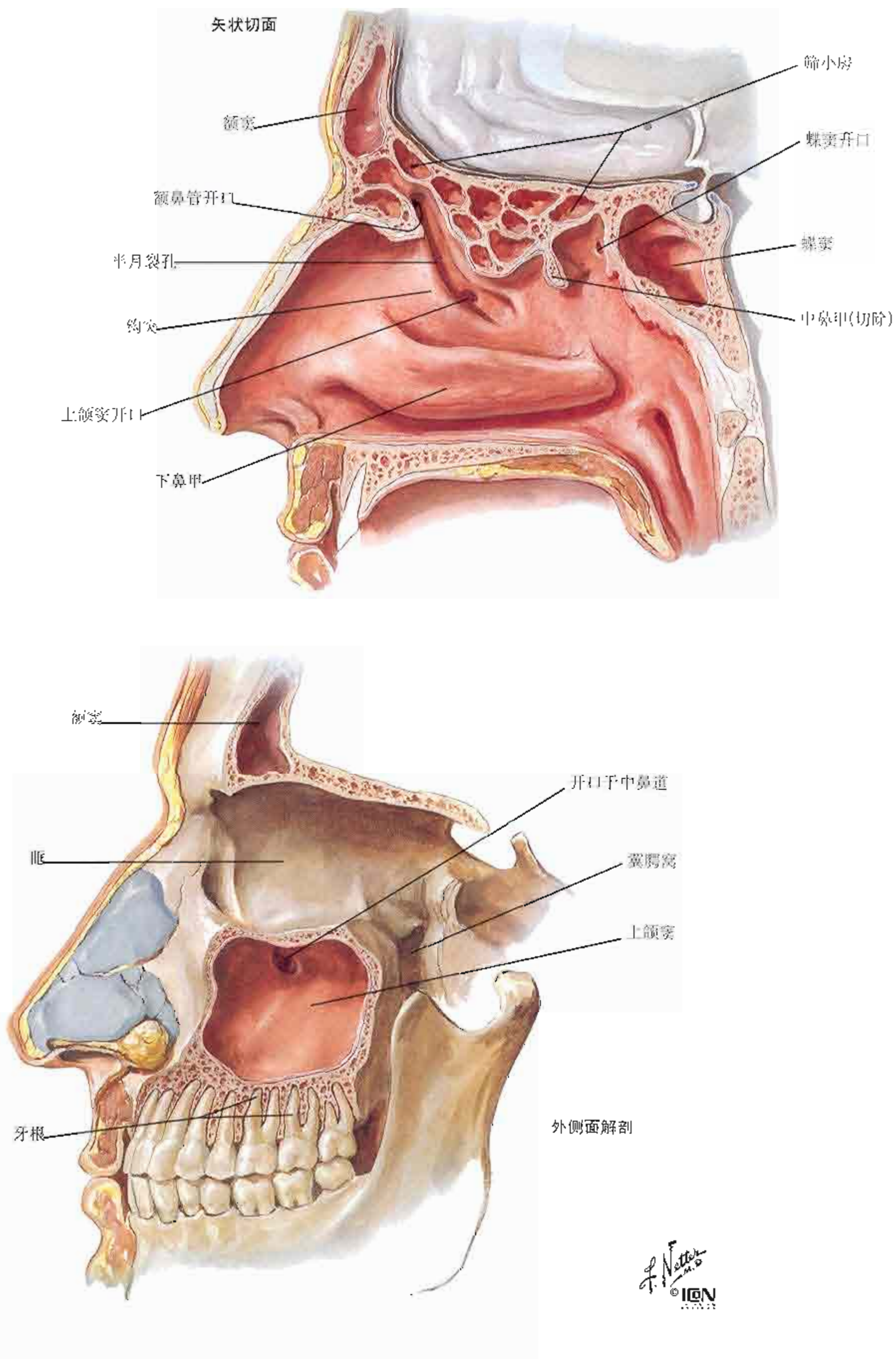
C. Machado
— M.D. —
© ION
LONDON

冠状切面



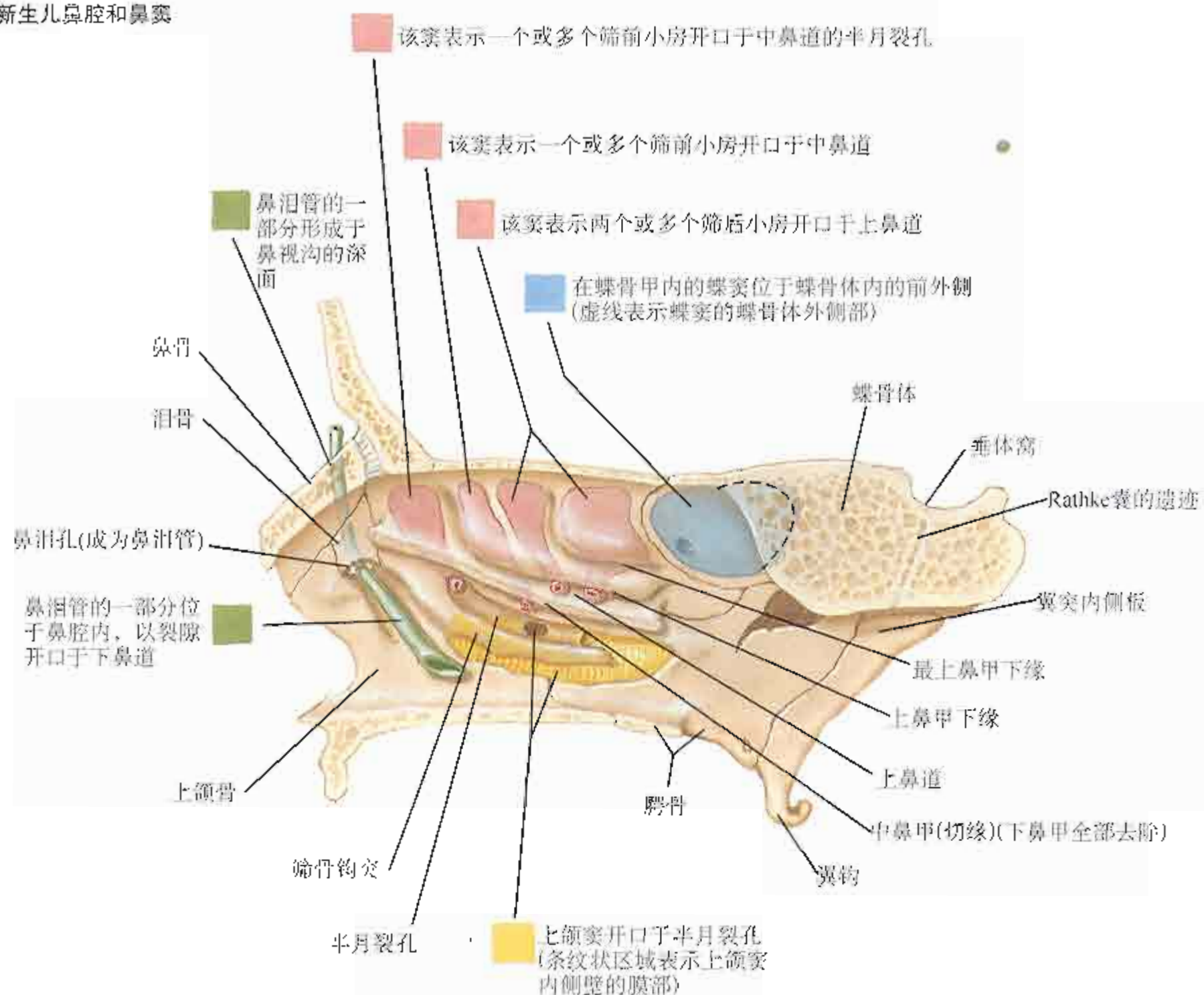
水平切面



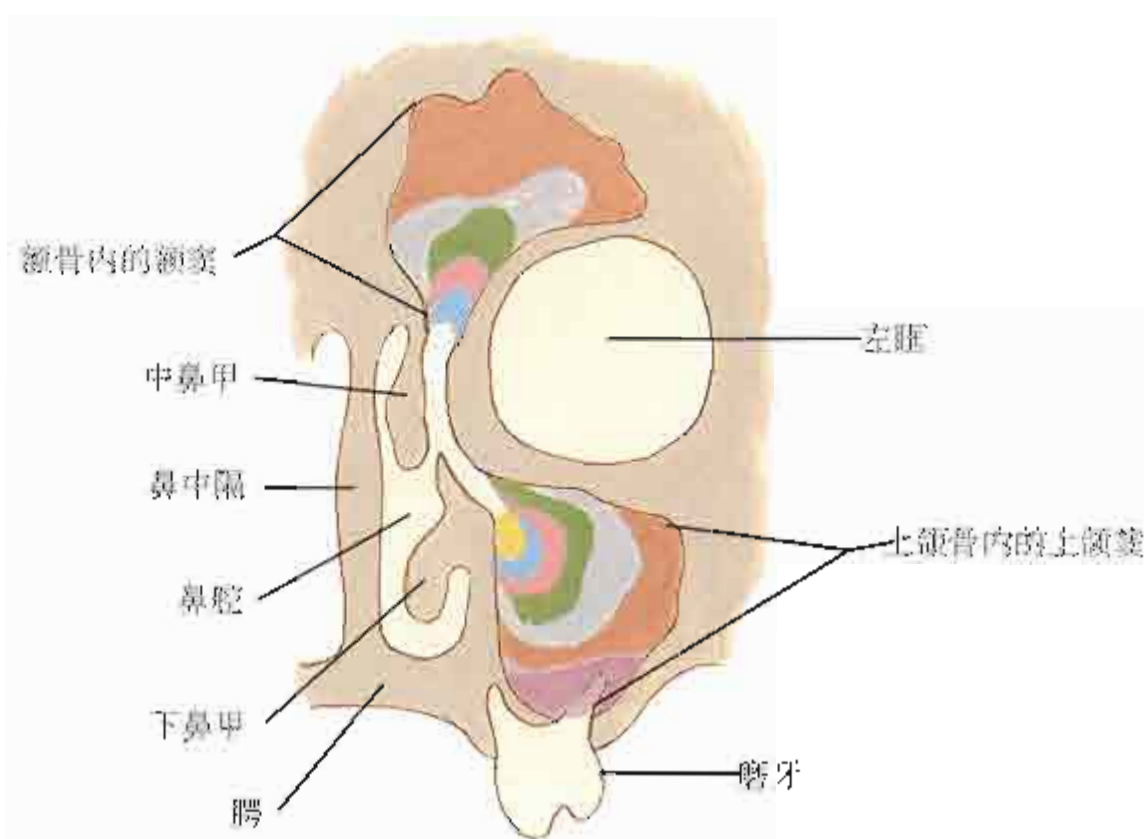


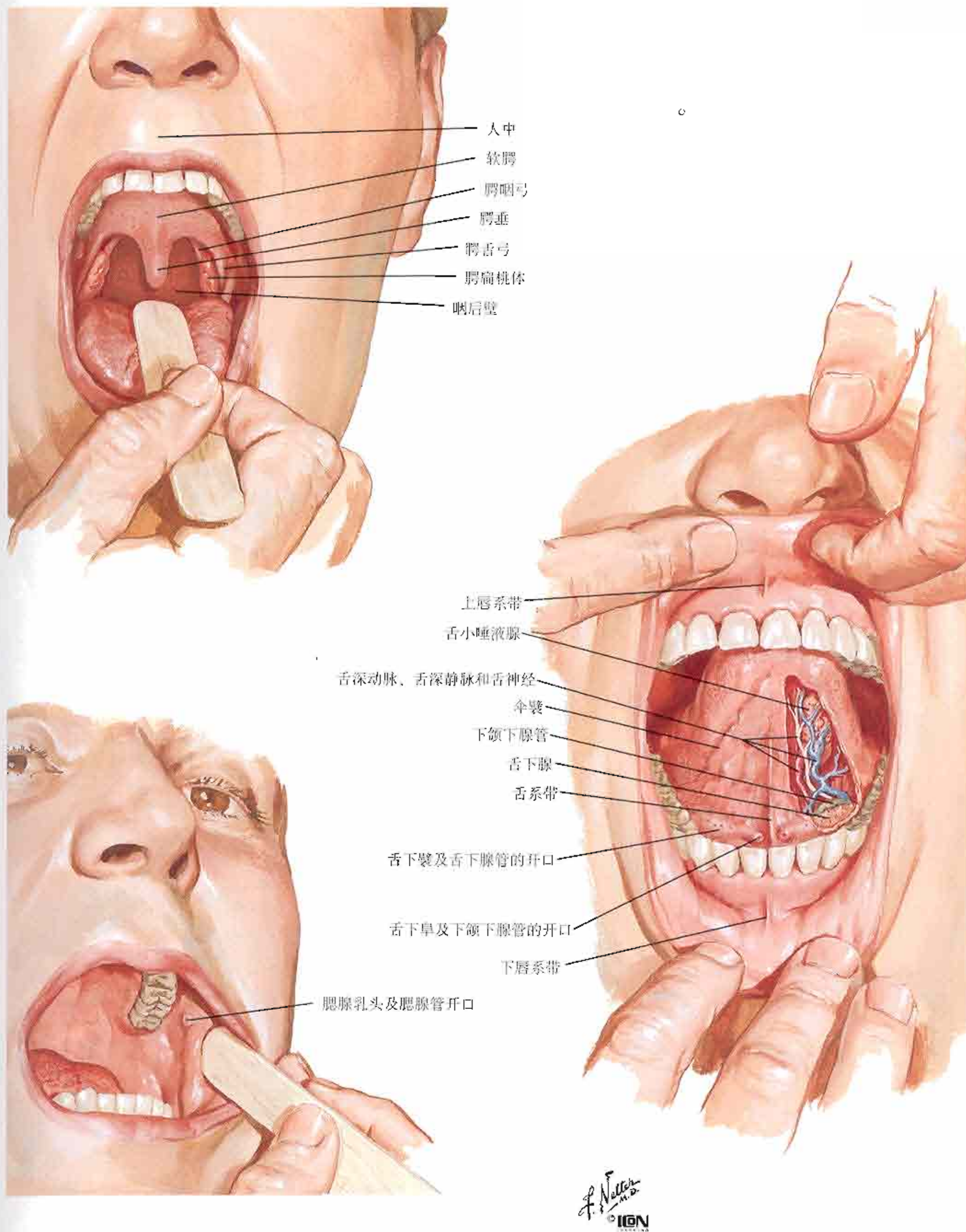
鼻窦：随年龄变化

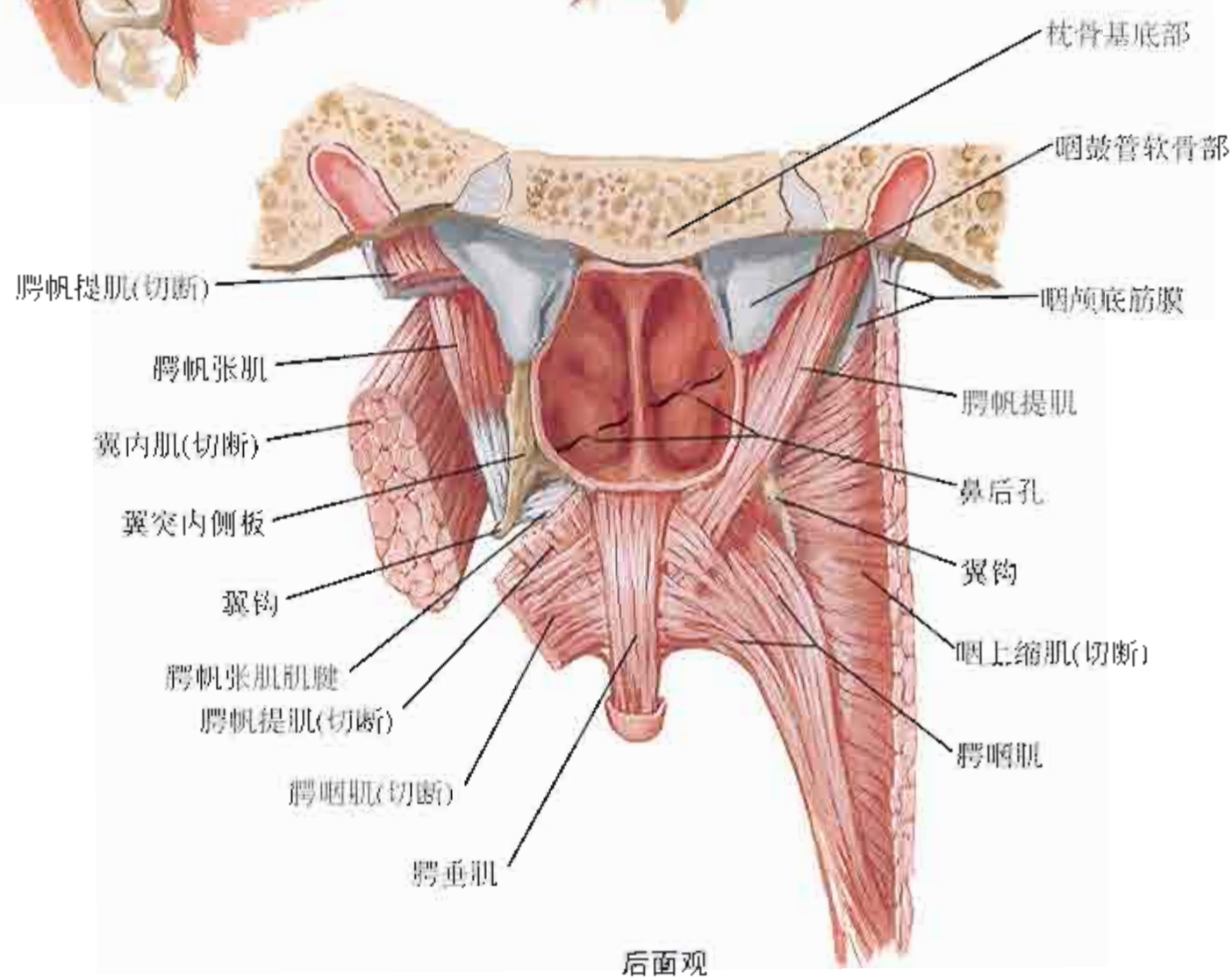
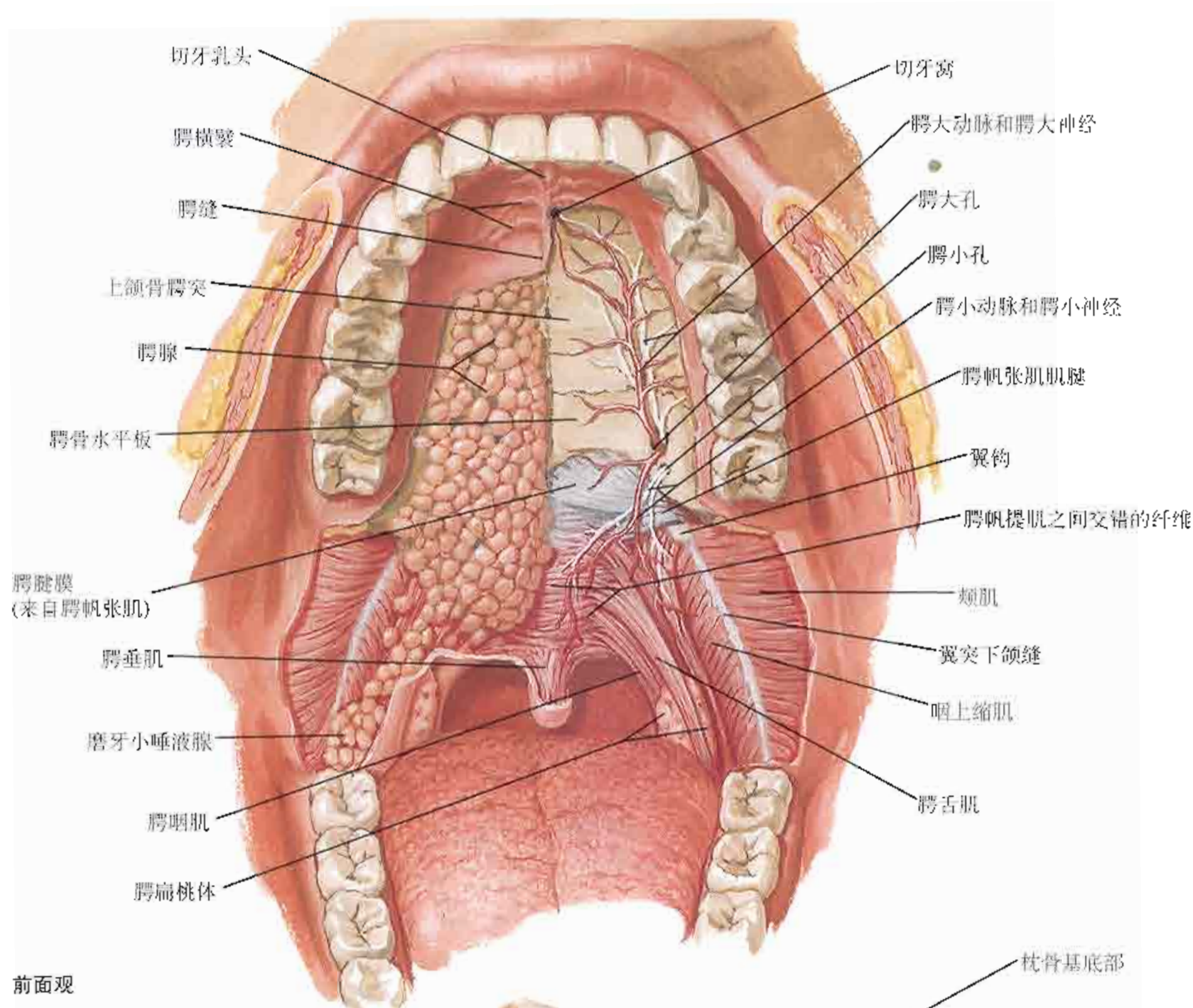
新生儿鼻腔和鼻窦



额窦和上颌窦及出生后变化







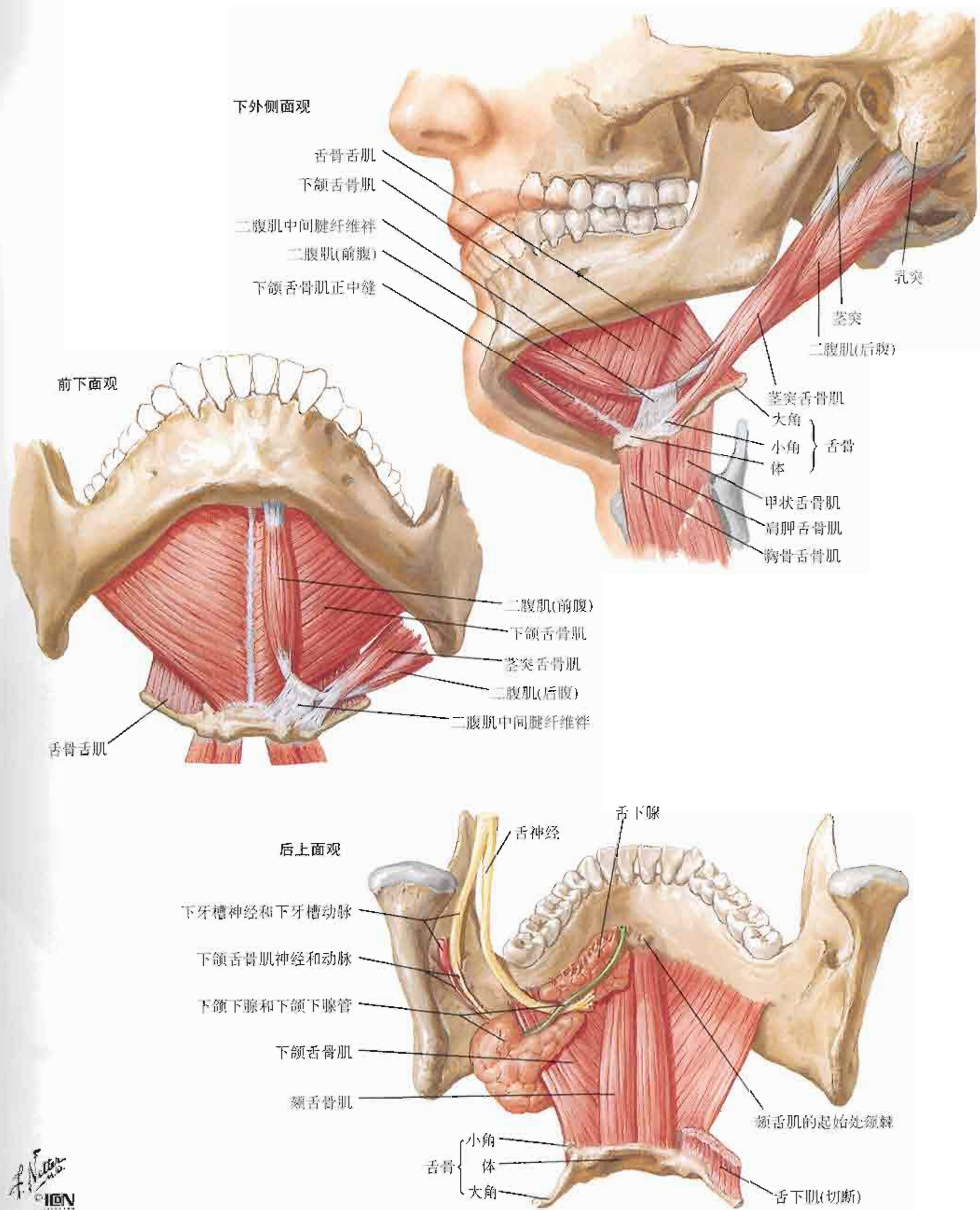
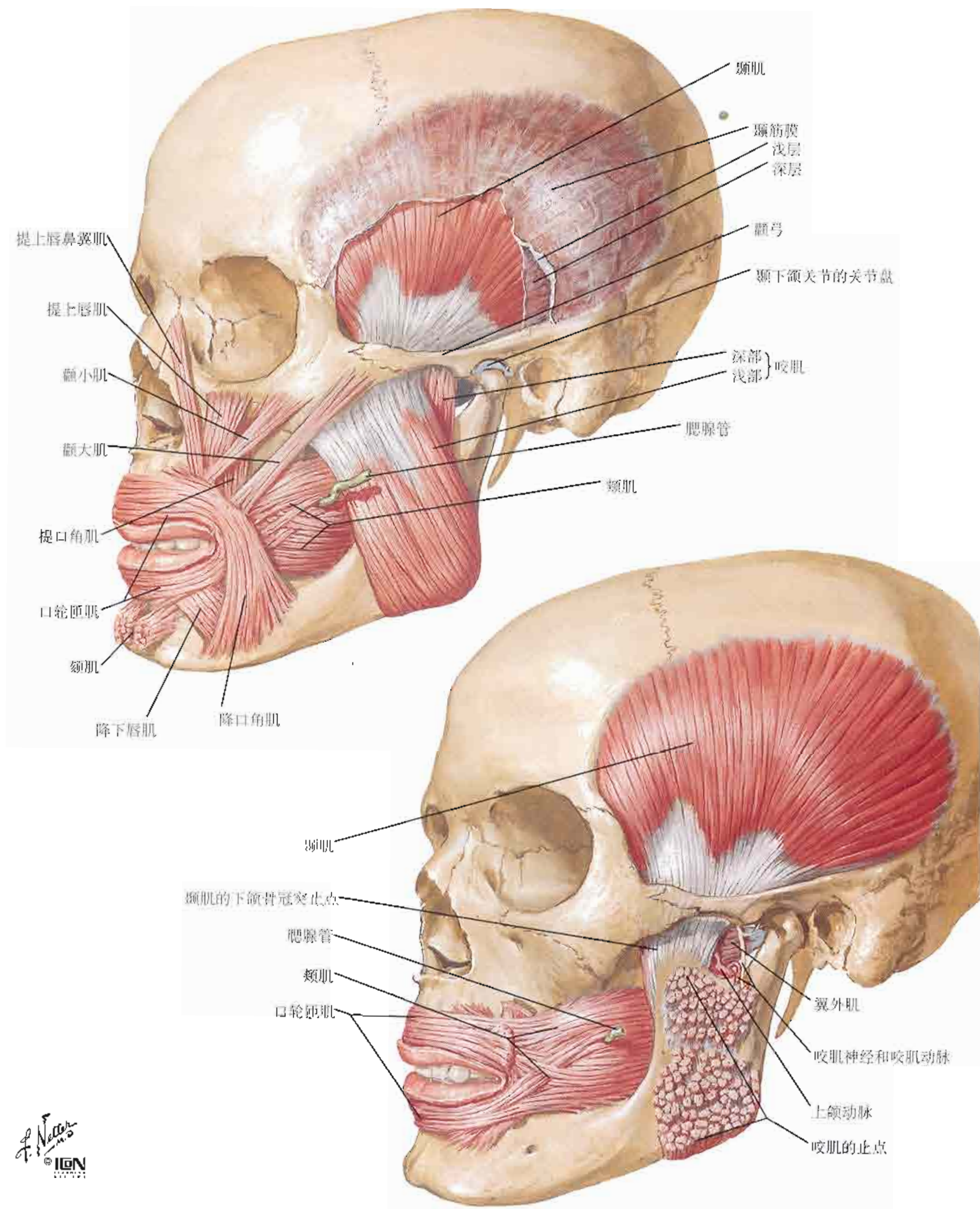


图49

咀嚼肌

面肌参见图 22



颞下颌关节的关节盘

关节结节

翼外肌

蝶下颌韧带

翼内肌

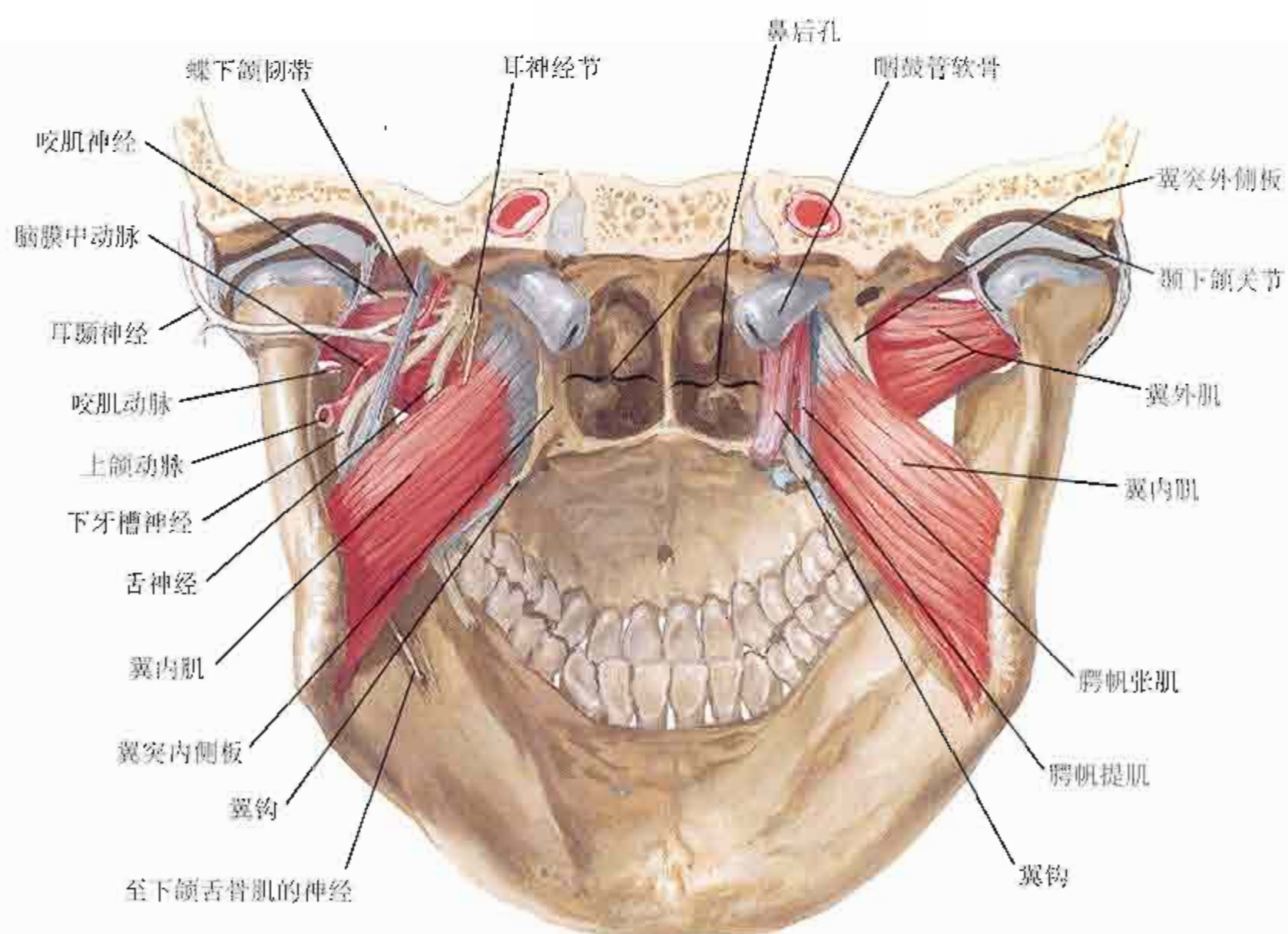
腮腺管

颊肌

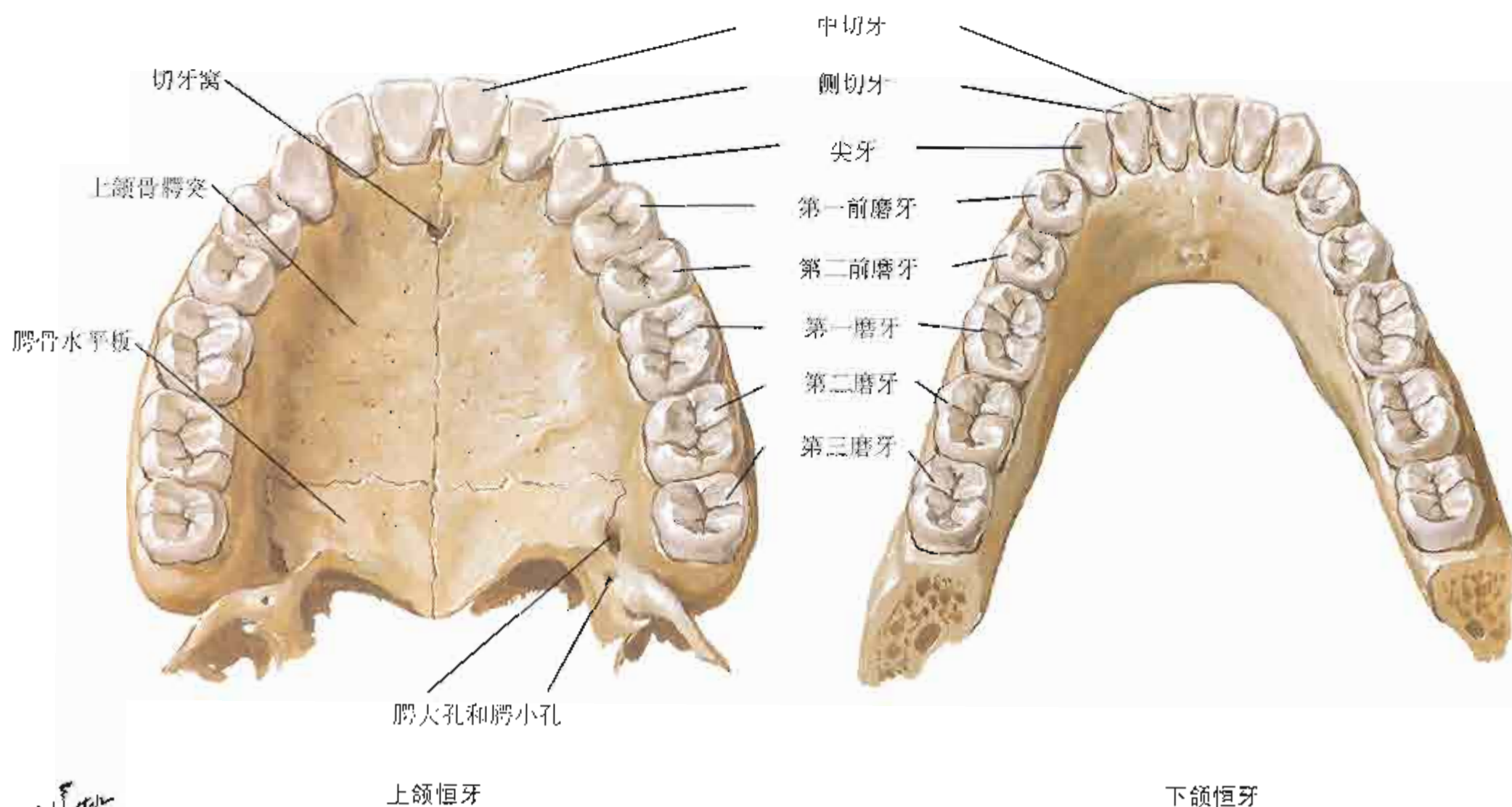
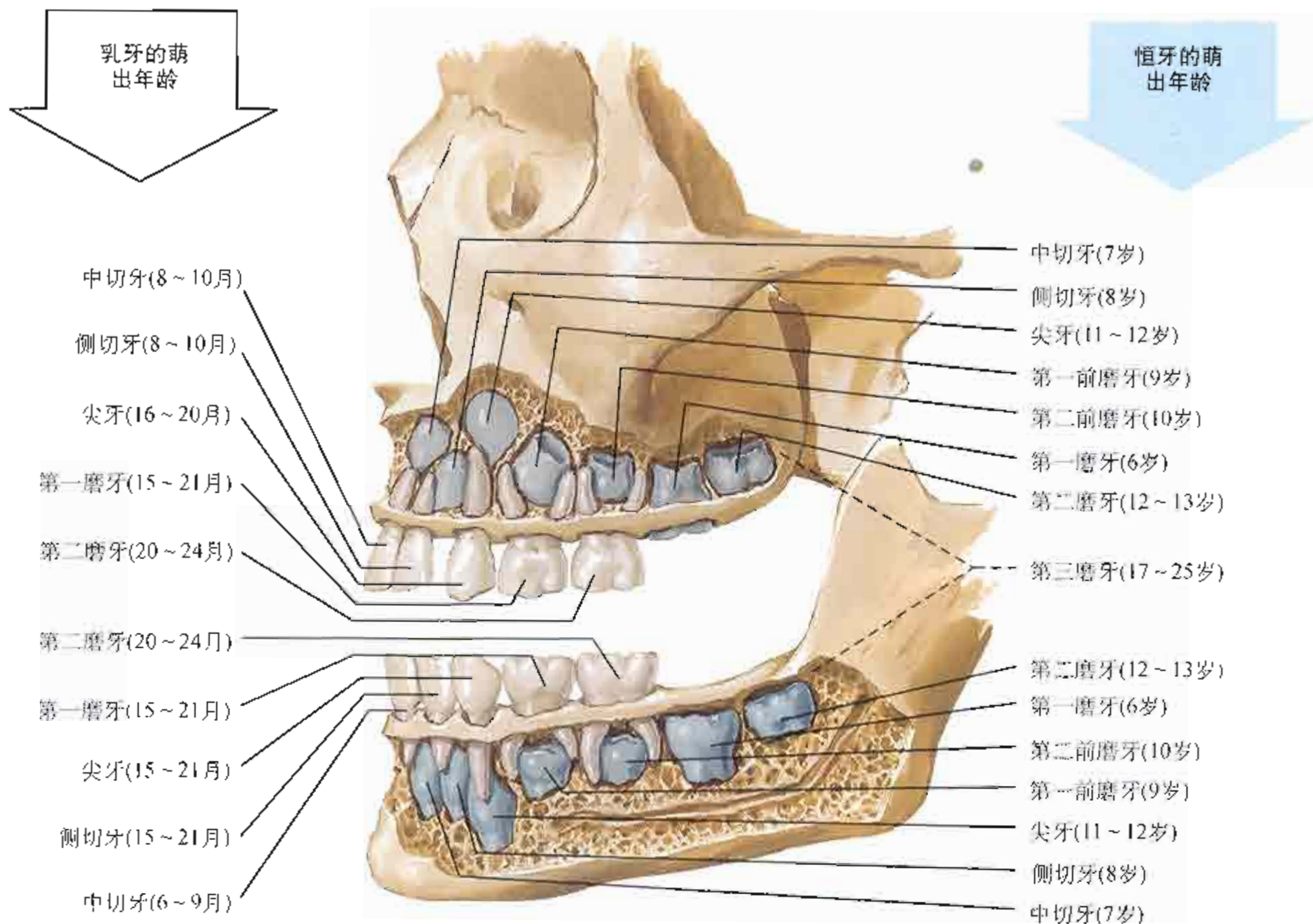
翼突下颌缝

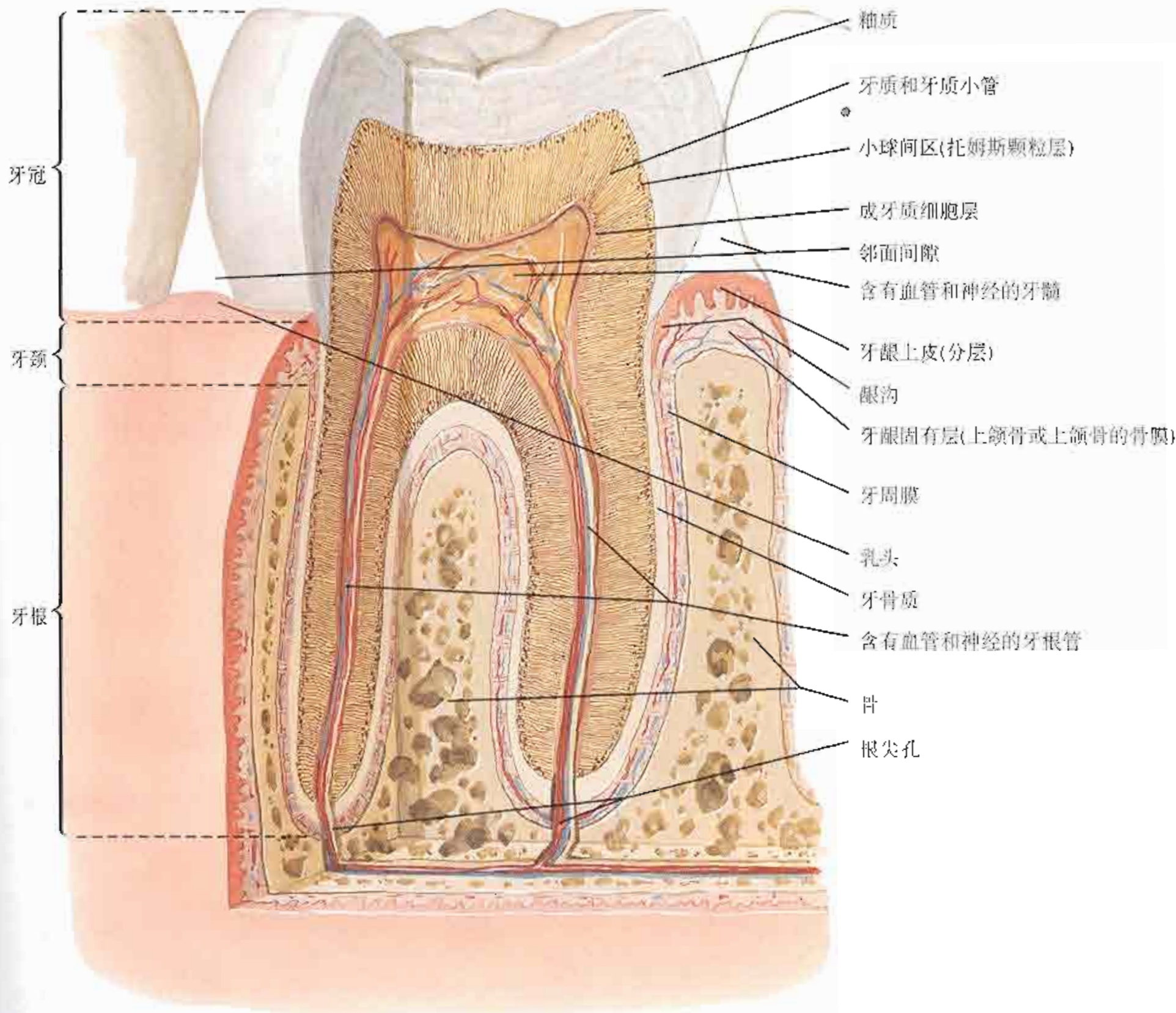
咽上缩肌

外侧面观



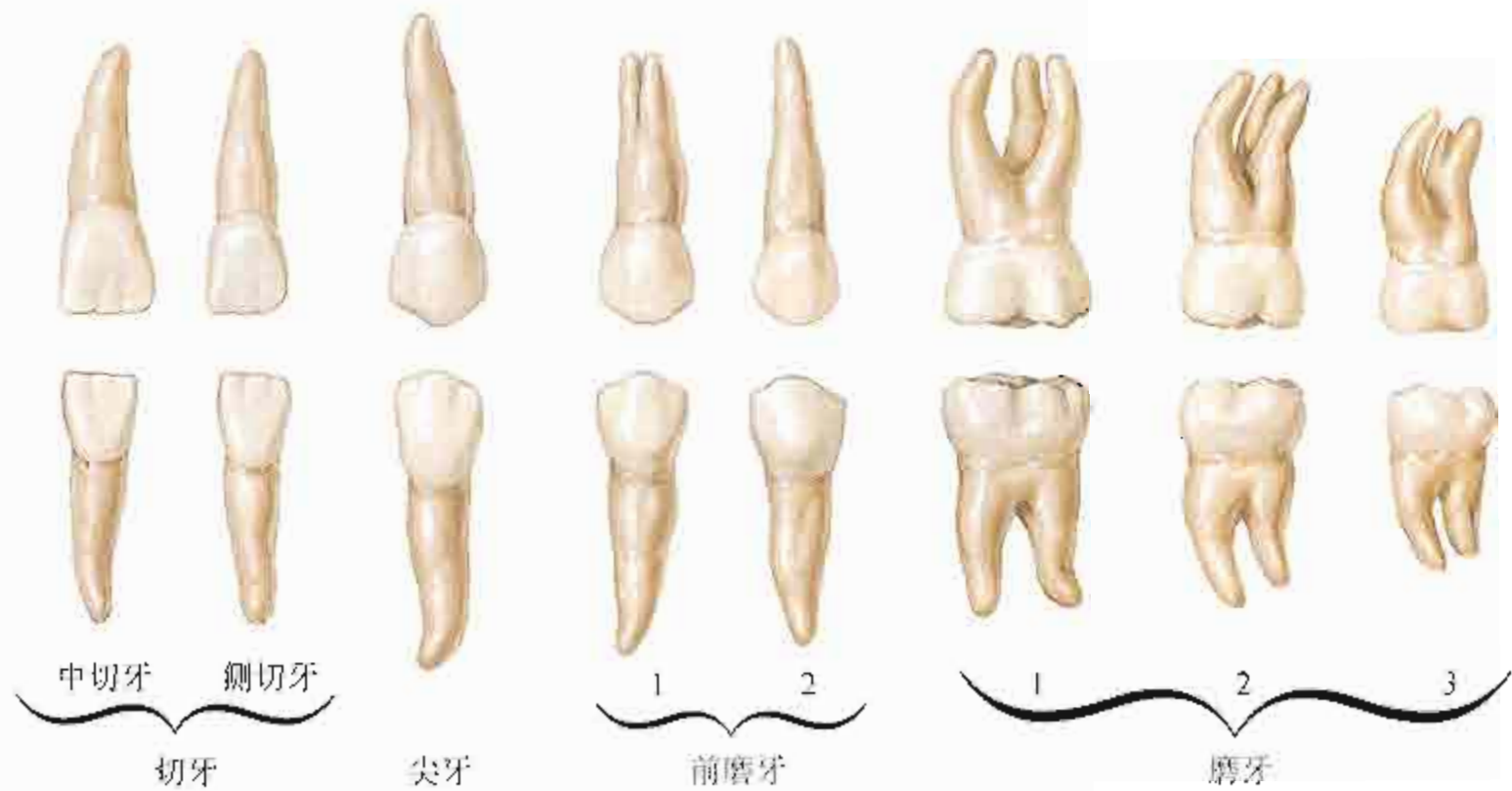后面观





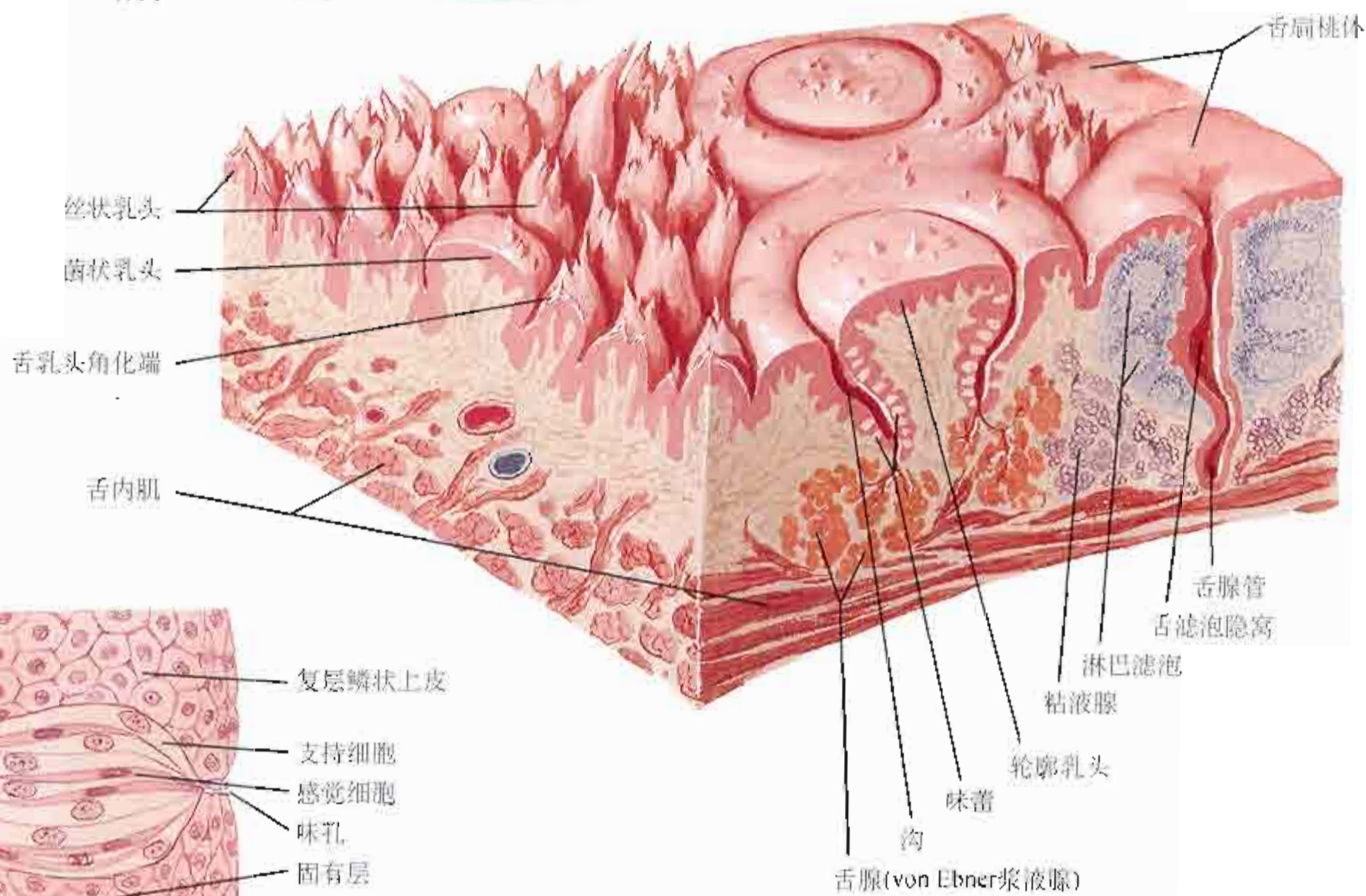
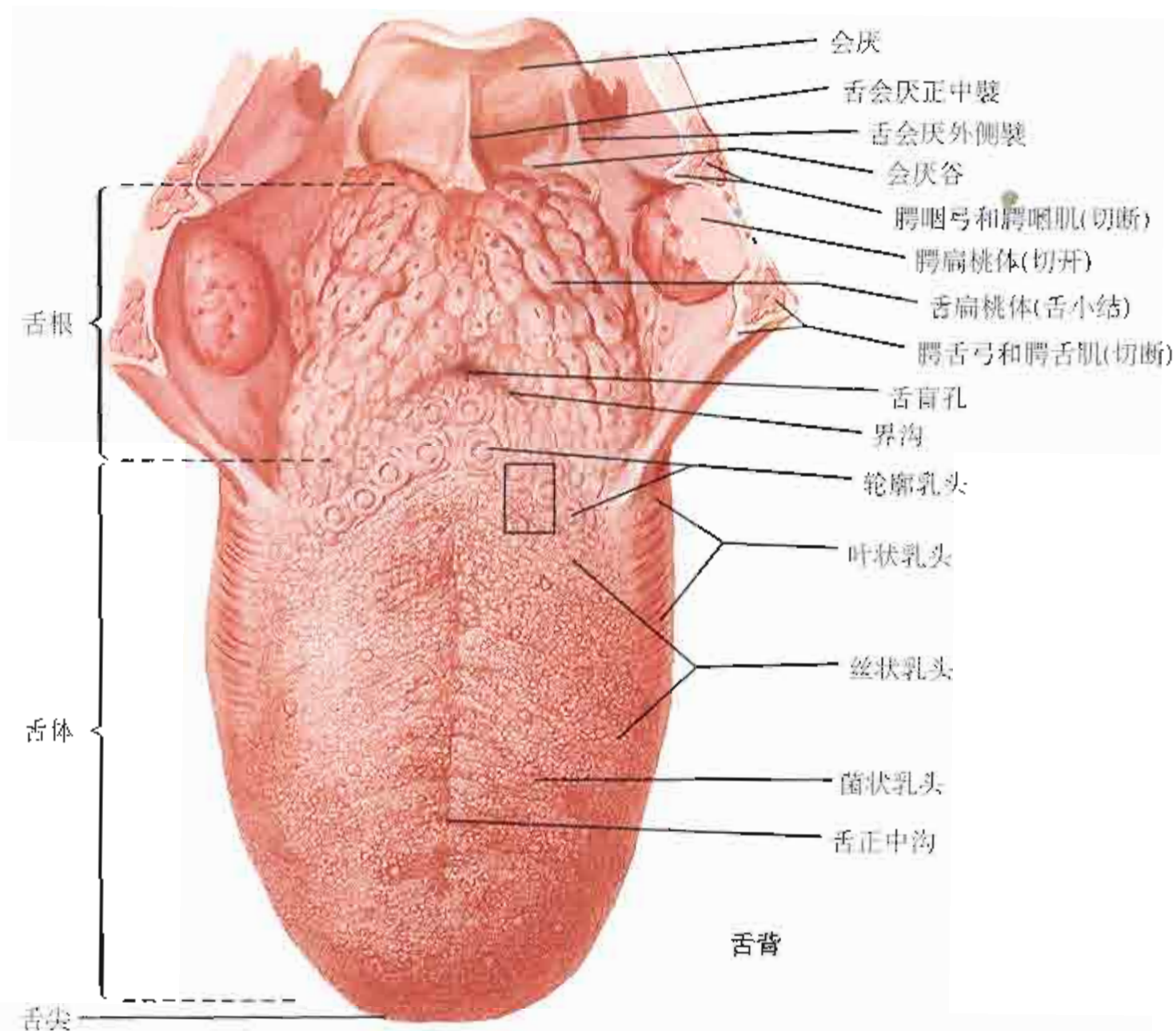
左上恒牙:
唇颊面观

左下恒牙:
唇颊面观



F. Netter
M.D.
© IGV
2000

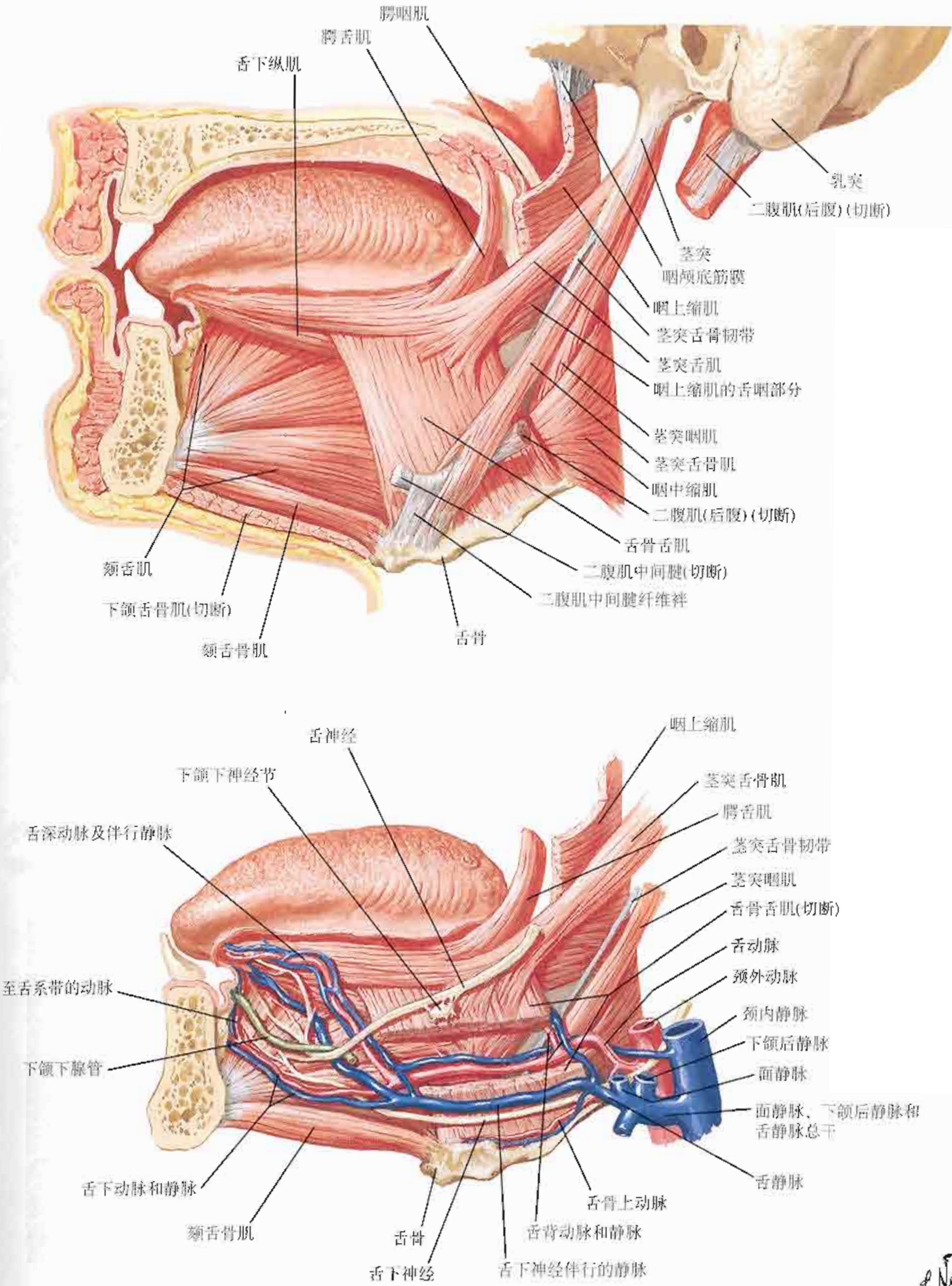
图53



味蕾的断面

立体模式图：上图所标出的区域

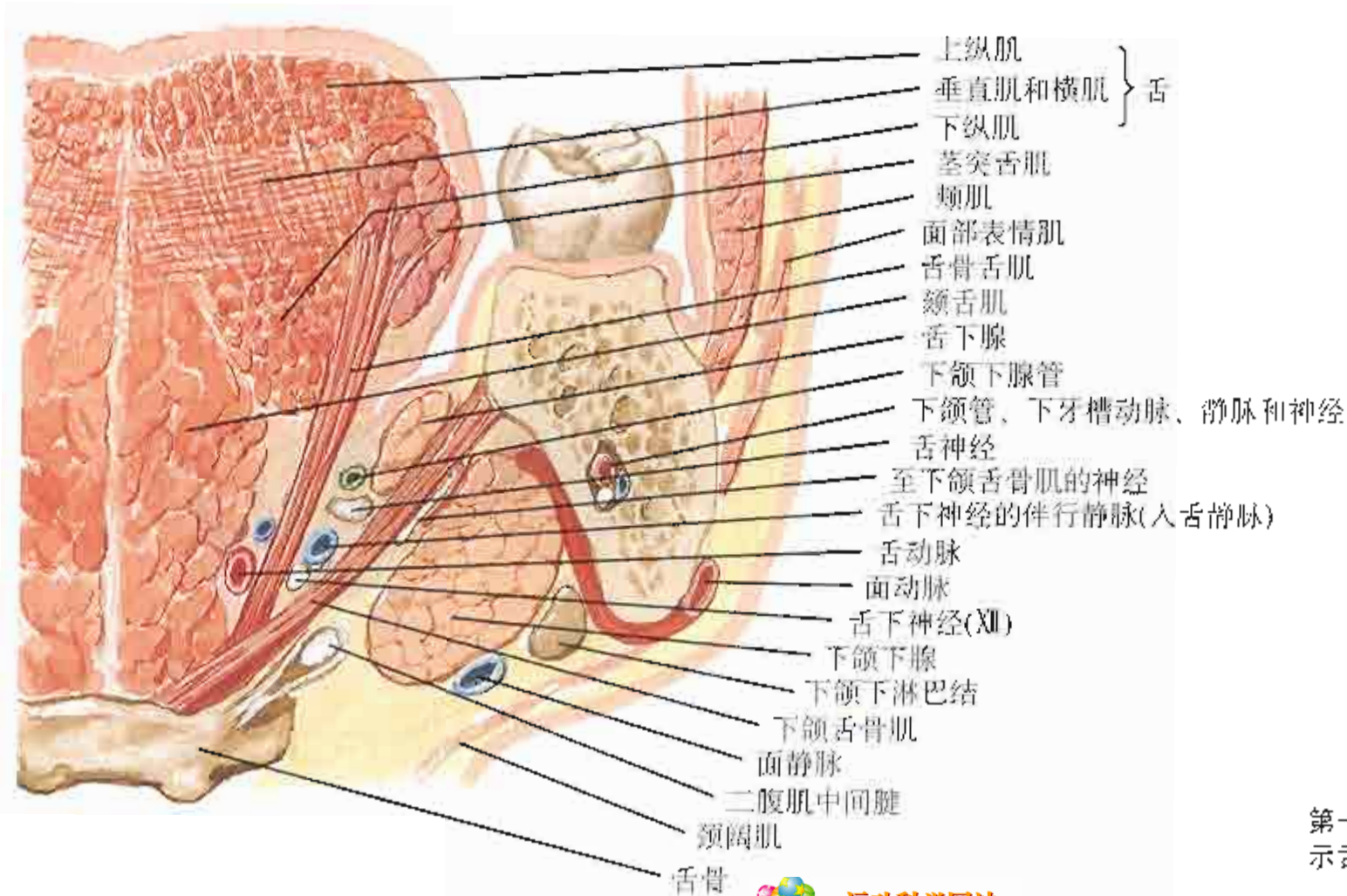
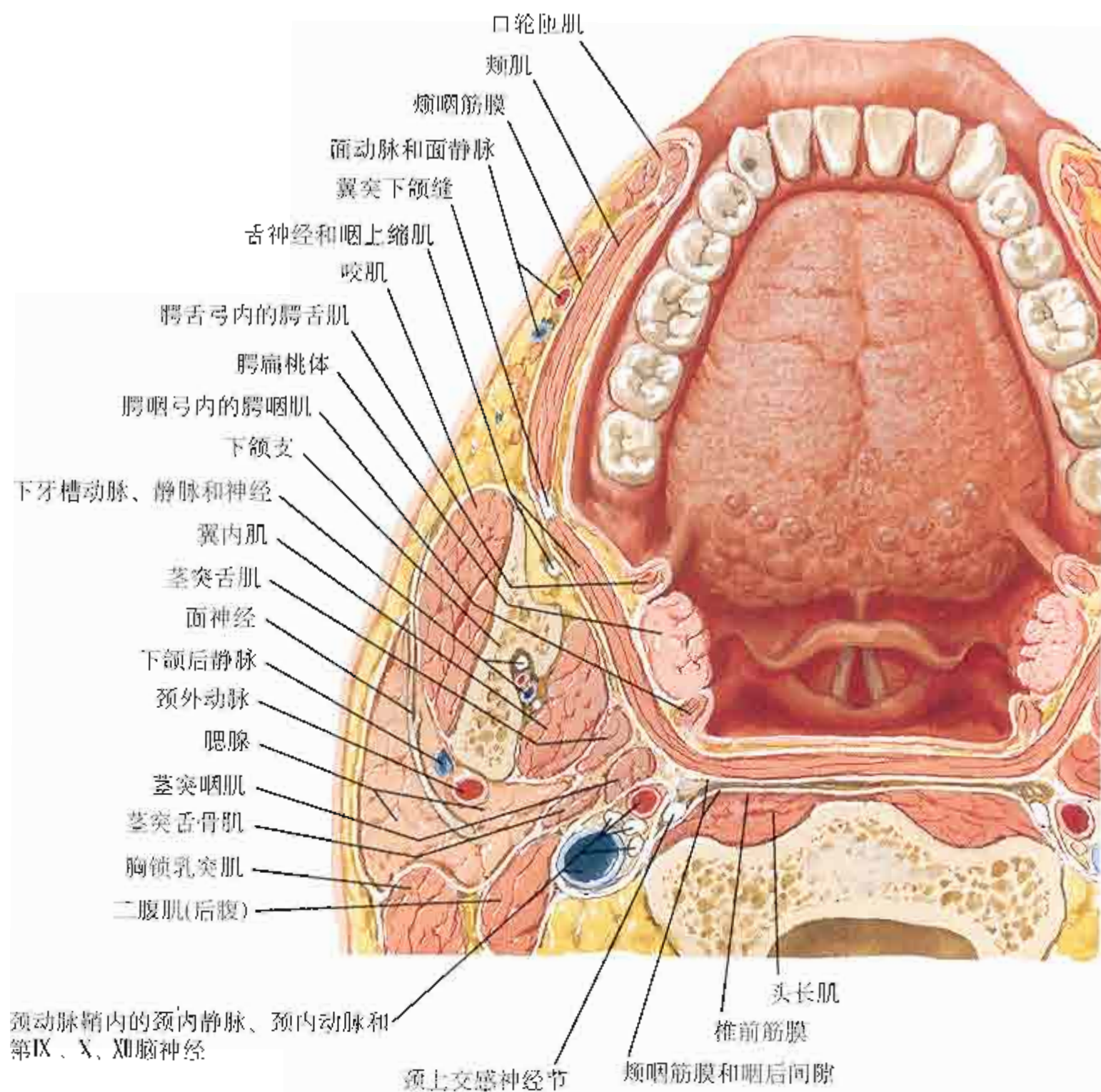
参见图30、42、49、122



F. Netter M.D.
© IGM

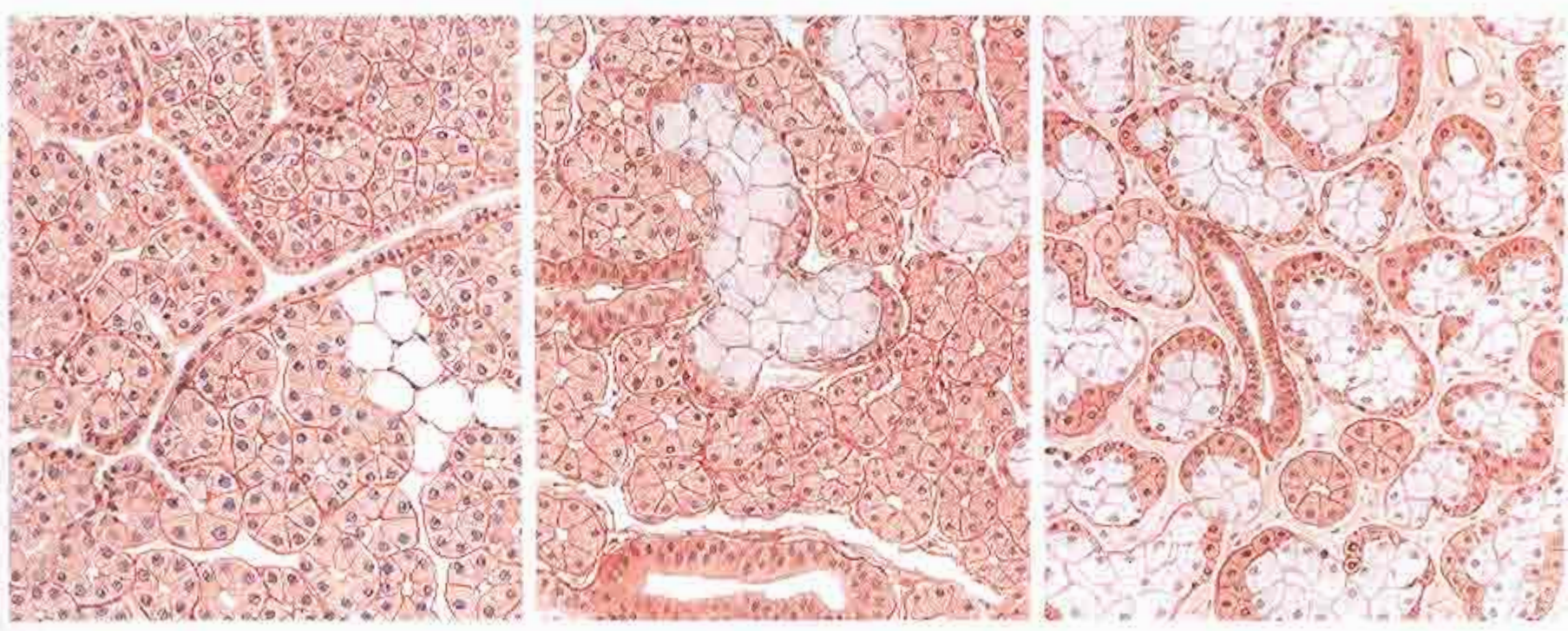
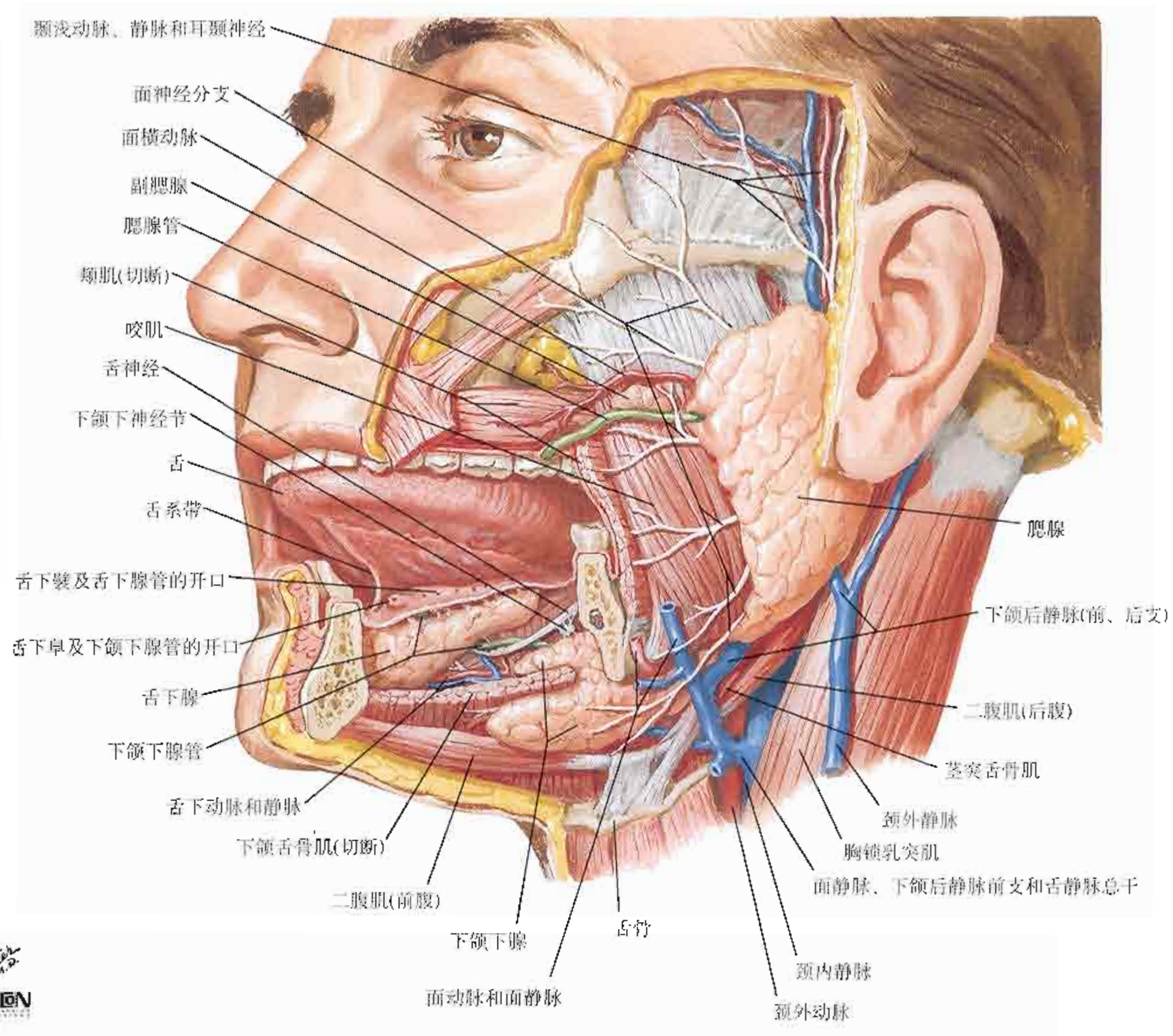
舌和唾液腺：断面

下颌骨舌下部水平切面
(上面观)示腮腺床



第一磨牙后的额状切面(前面观)
示舌下腺和下颌下腺床

参见图21、49、127、128、160



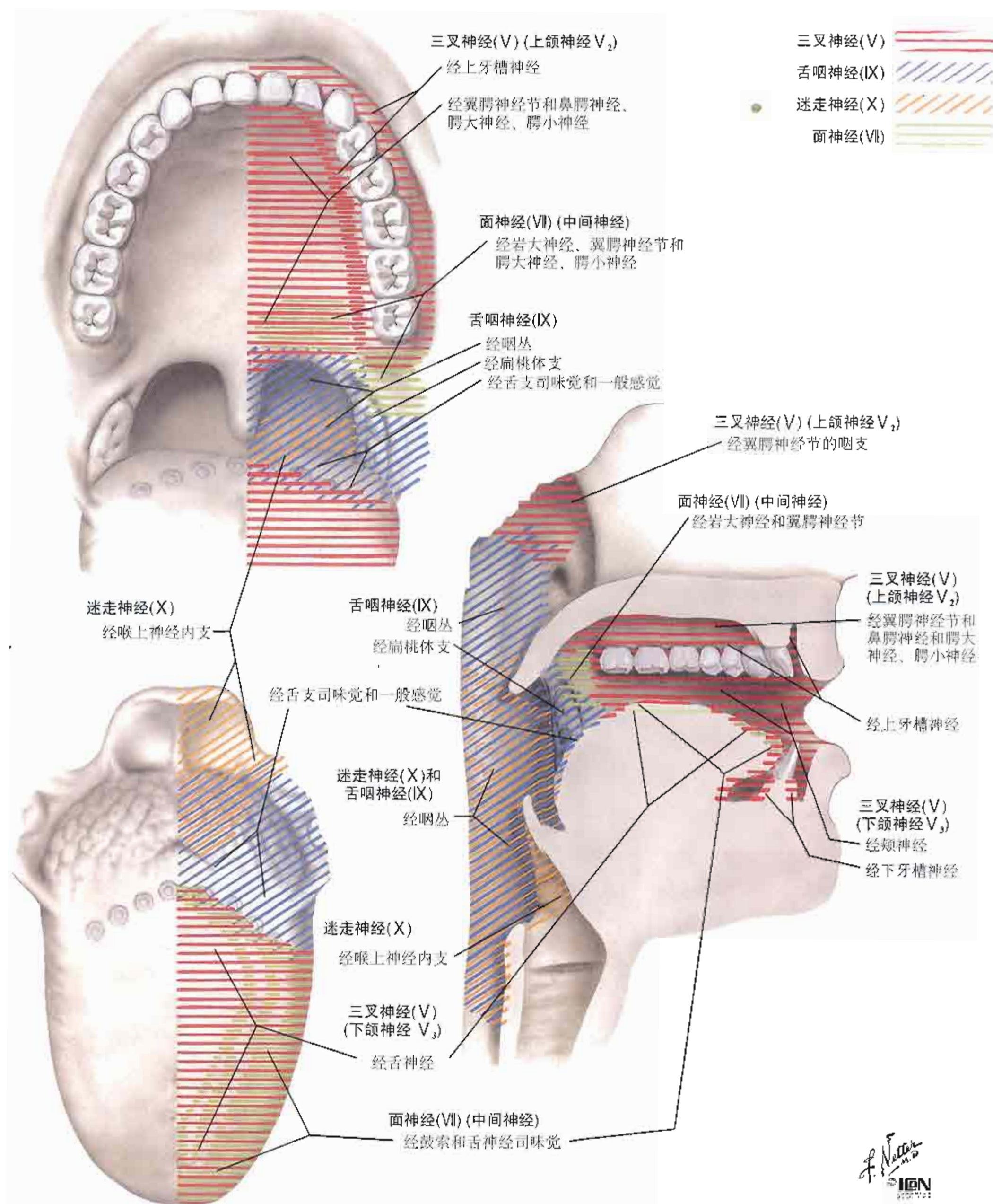
腮腺：全浆液性

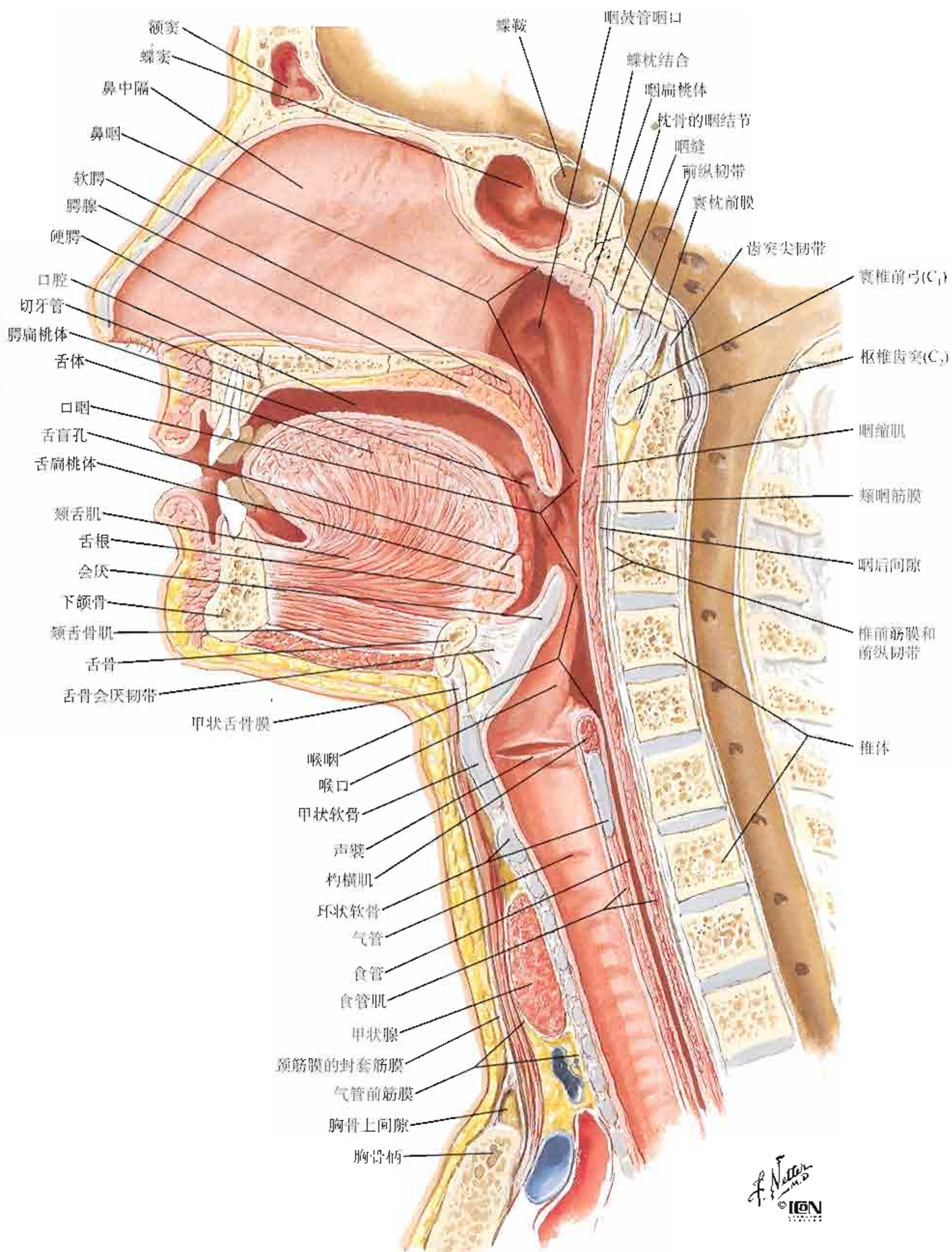
下颌下腺：多为浆液性，
部分为粘液性

舌下腺：几乎全部为粘液性

口和咽传入神经的分布

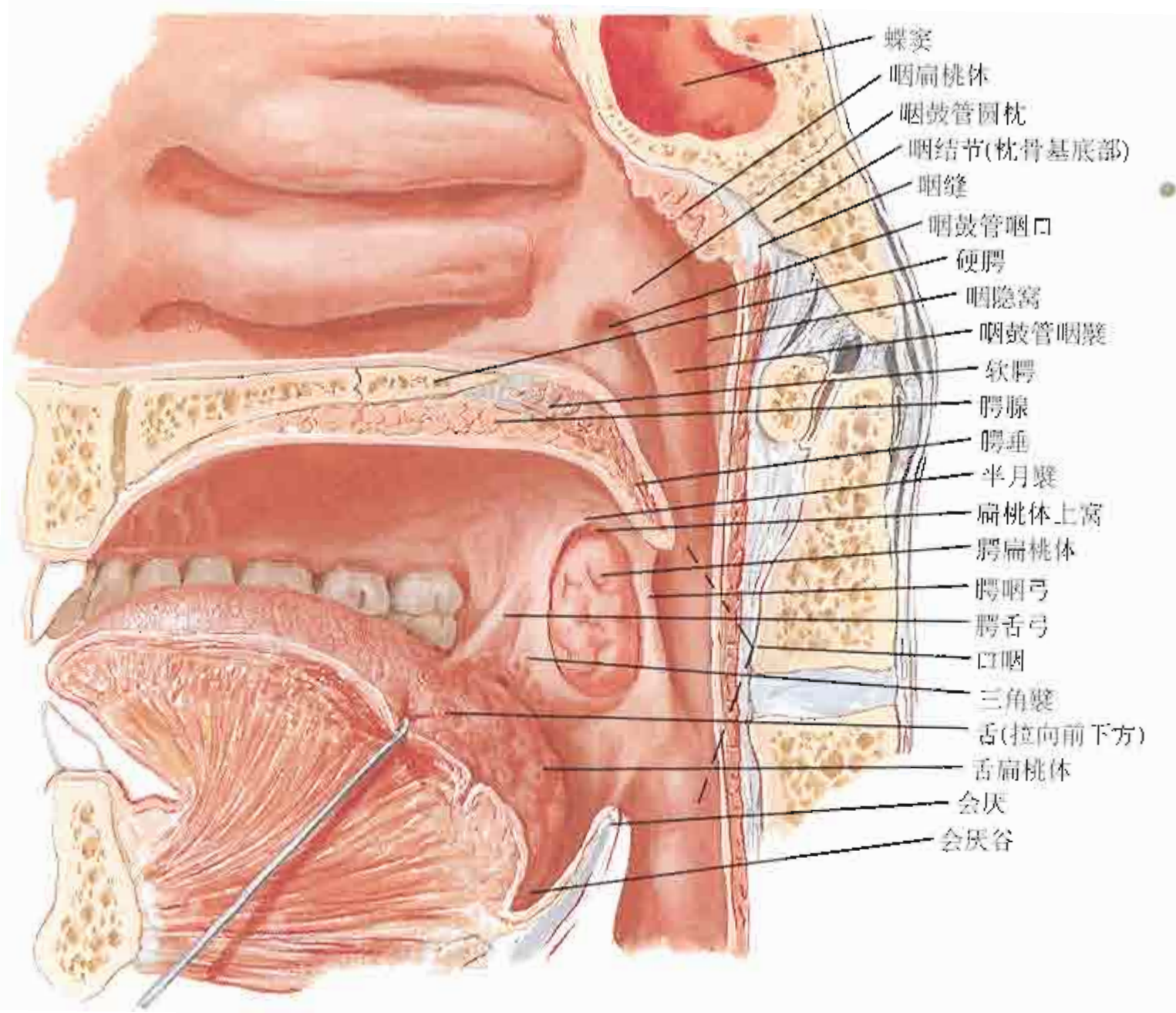
参见图42、48、55、60、116、117、127、129



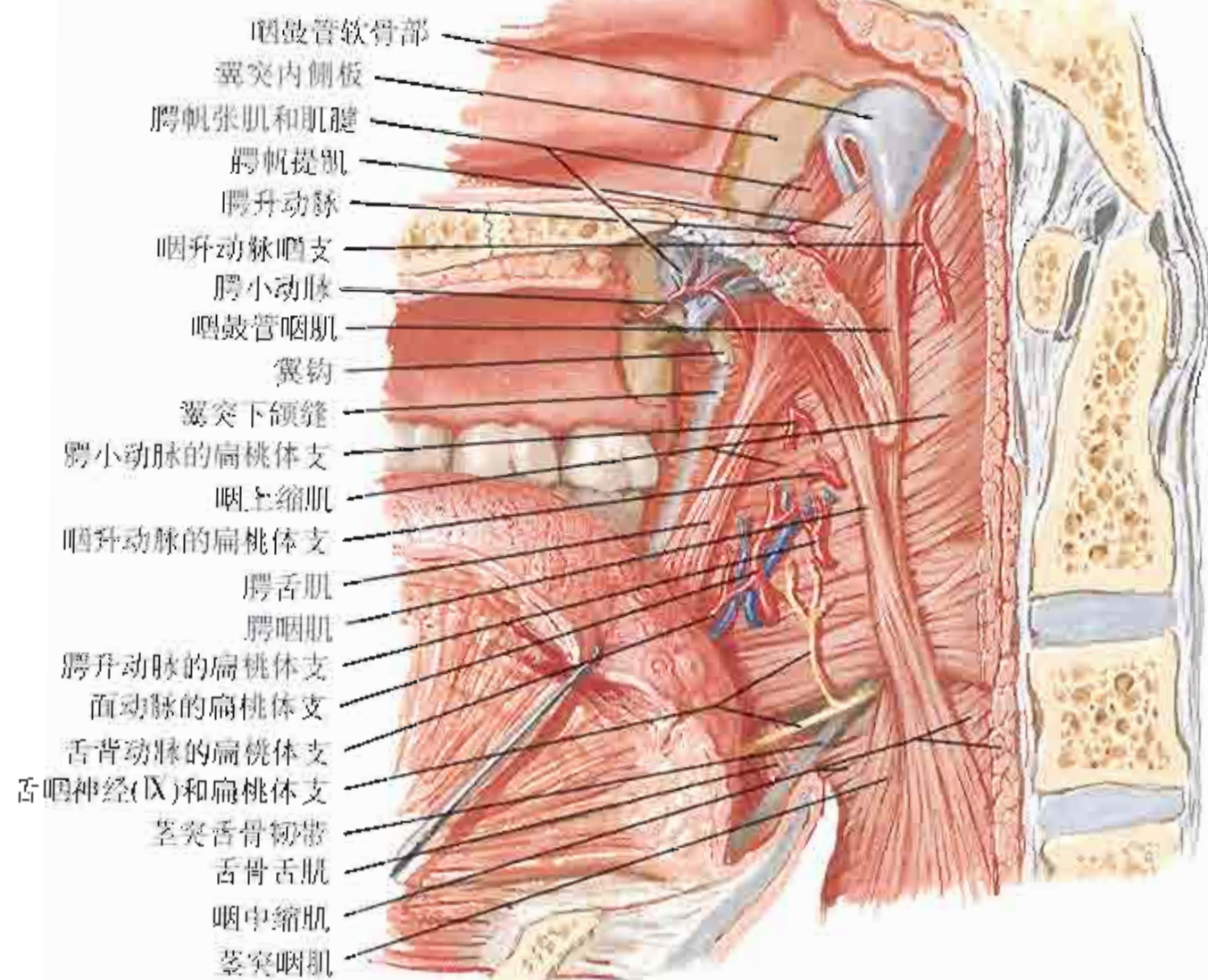


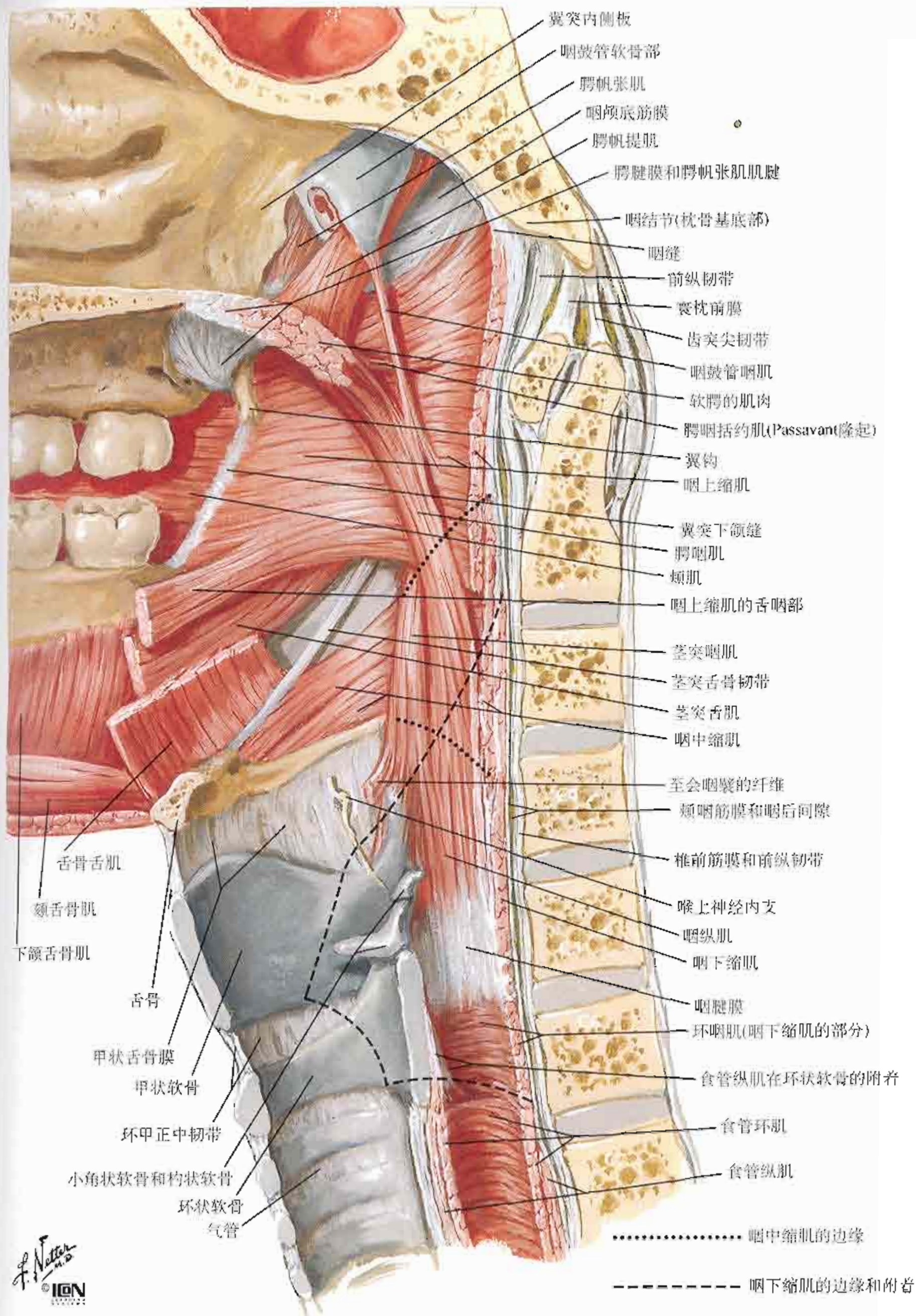
咽门

内面观
(正中矢状切面)

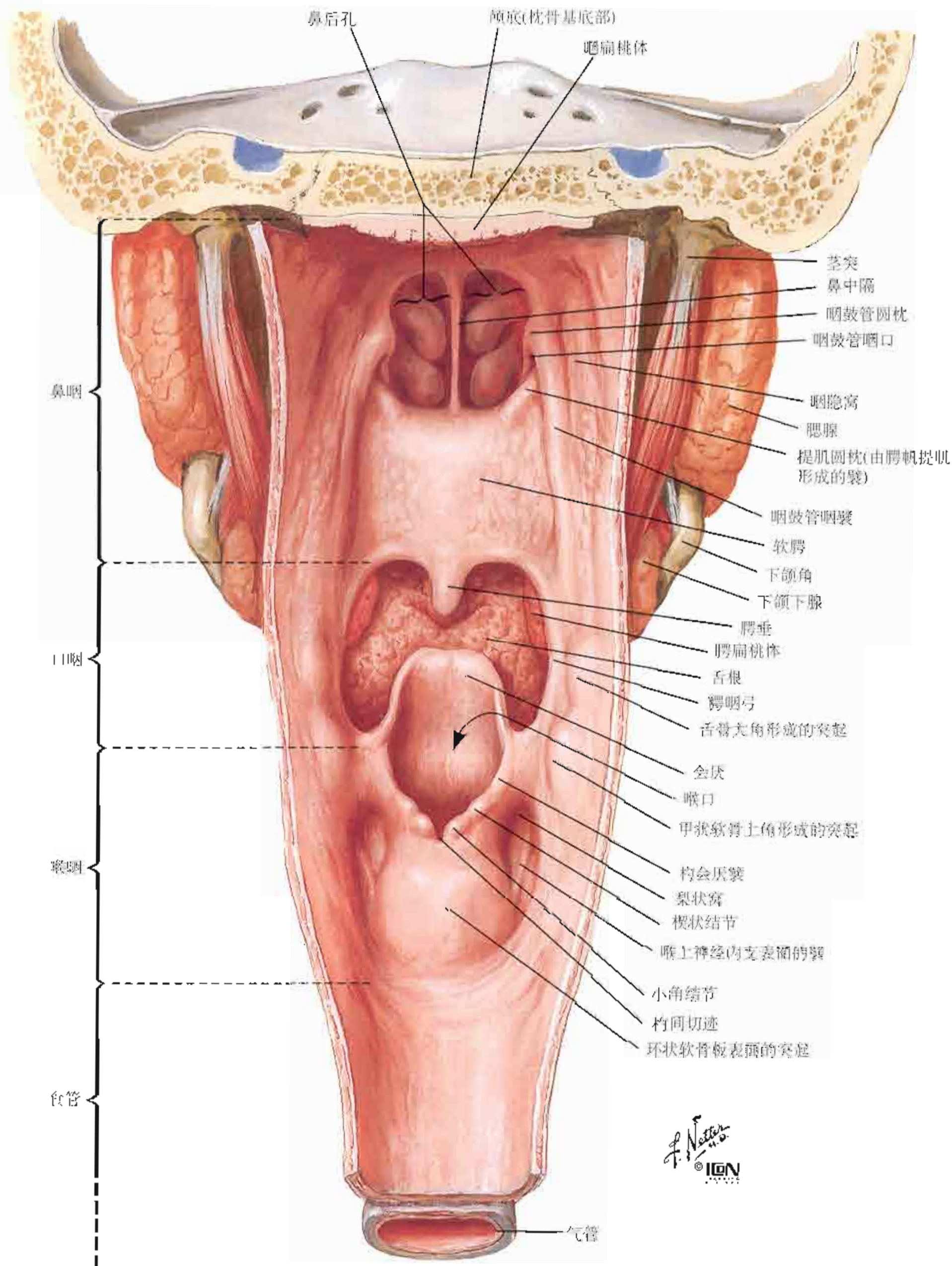


已去除咽粘膜

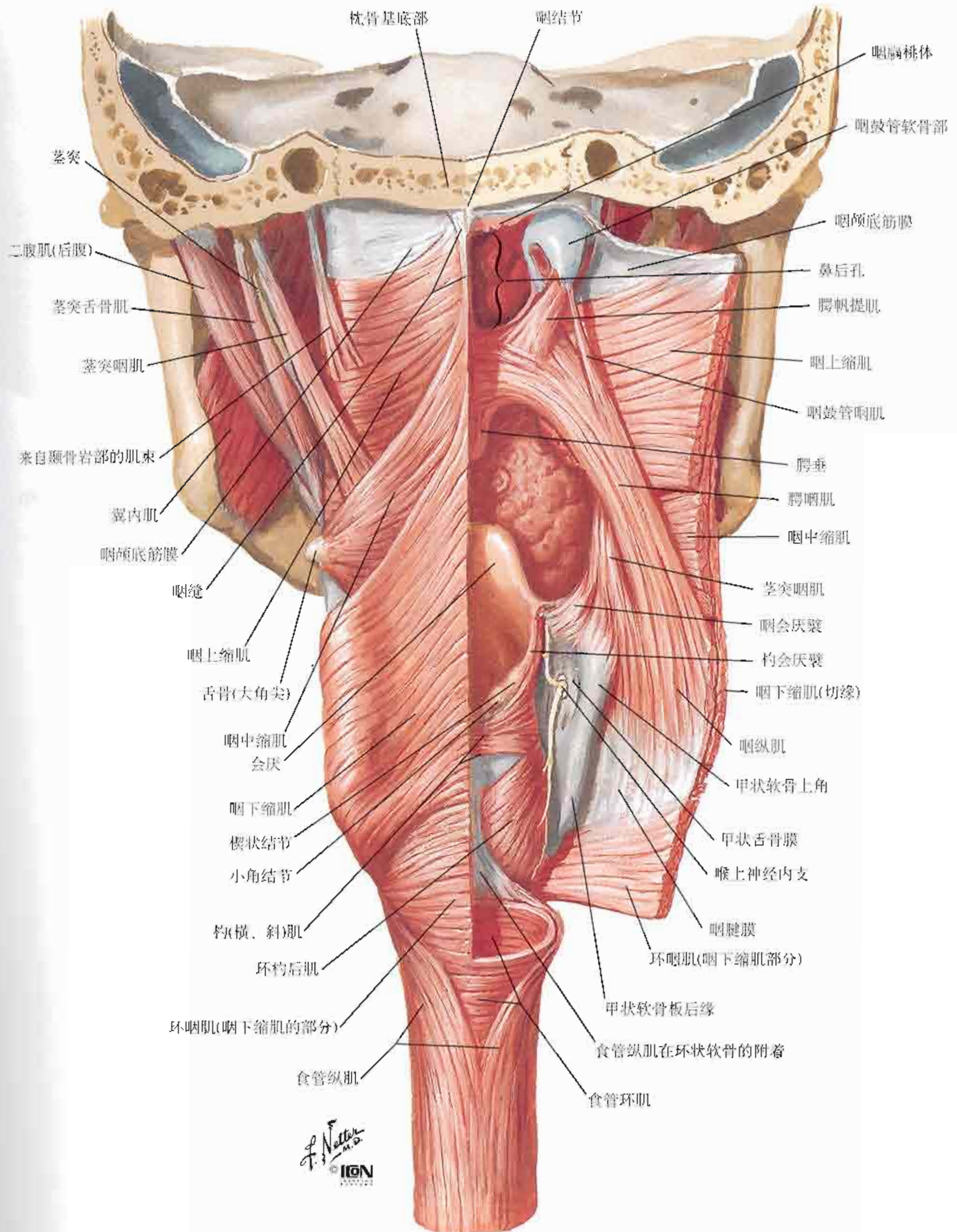




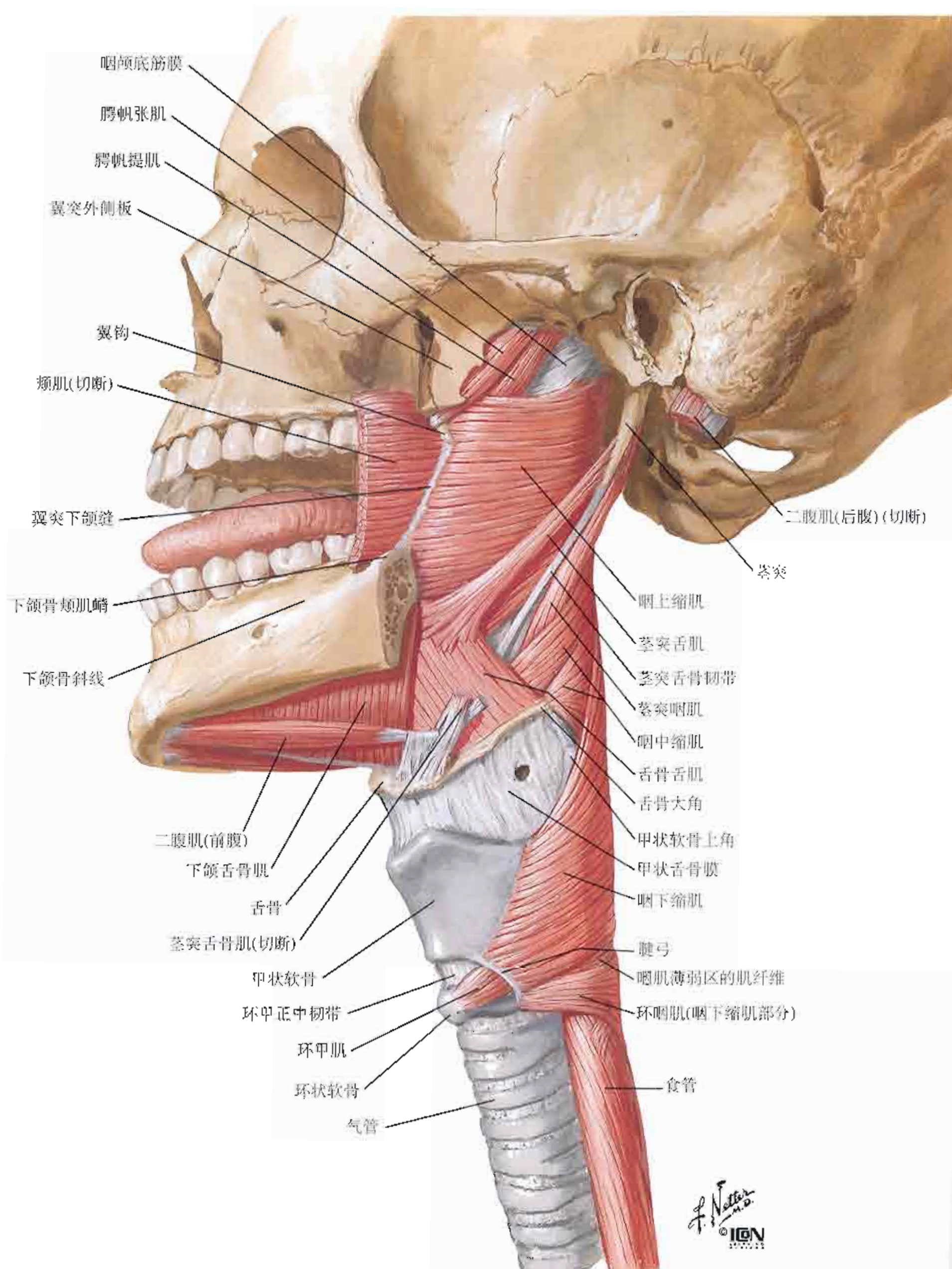
咽：后面观(剖开)

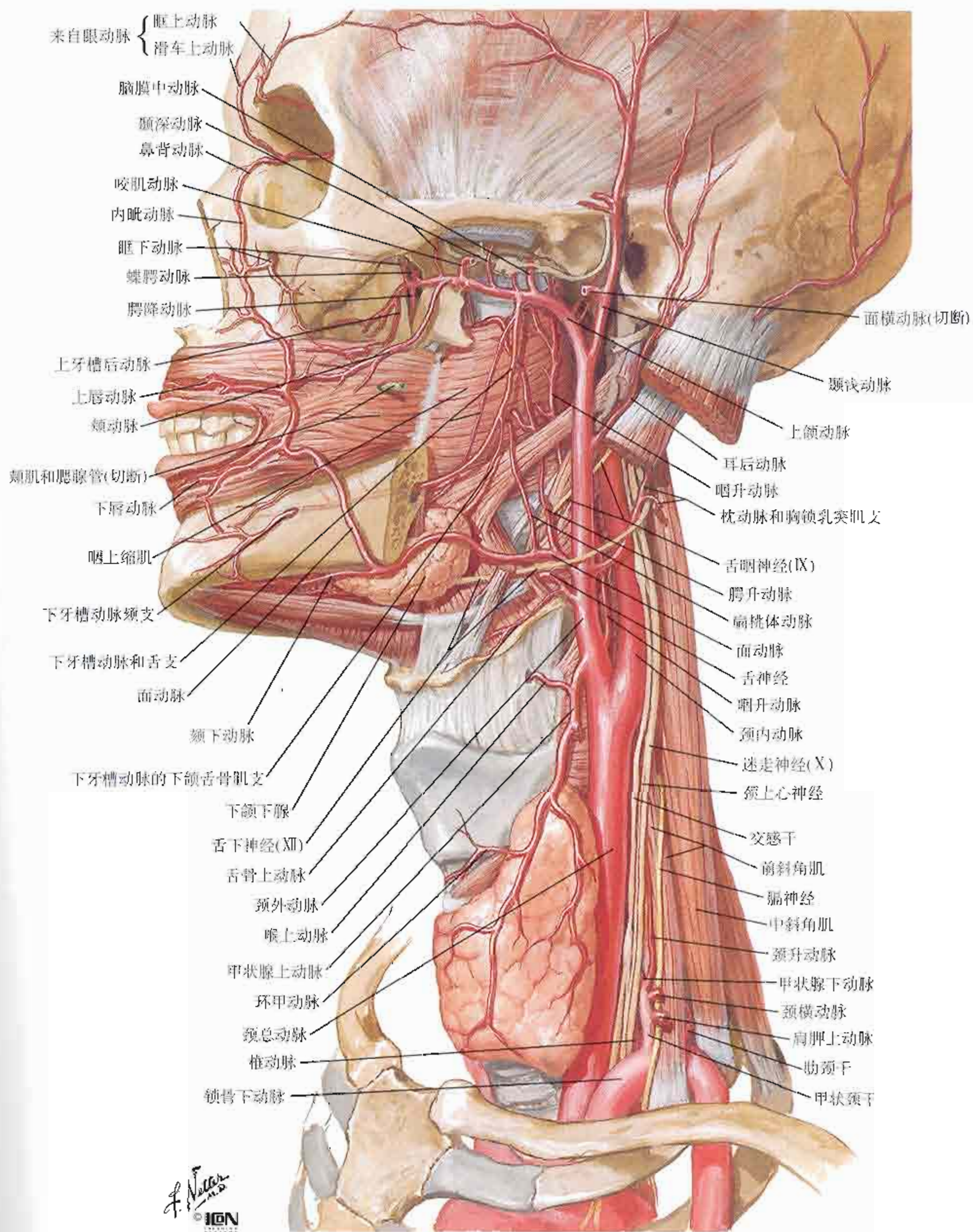


F. Netter M.D.
© 1997



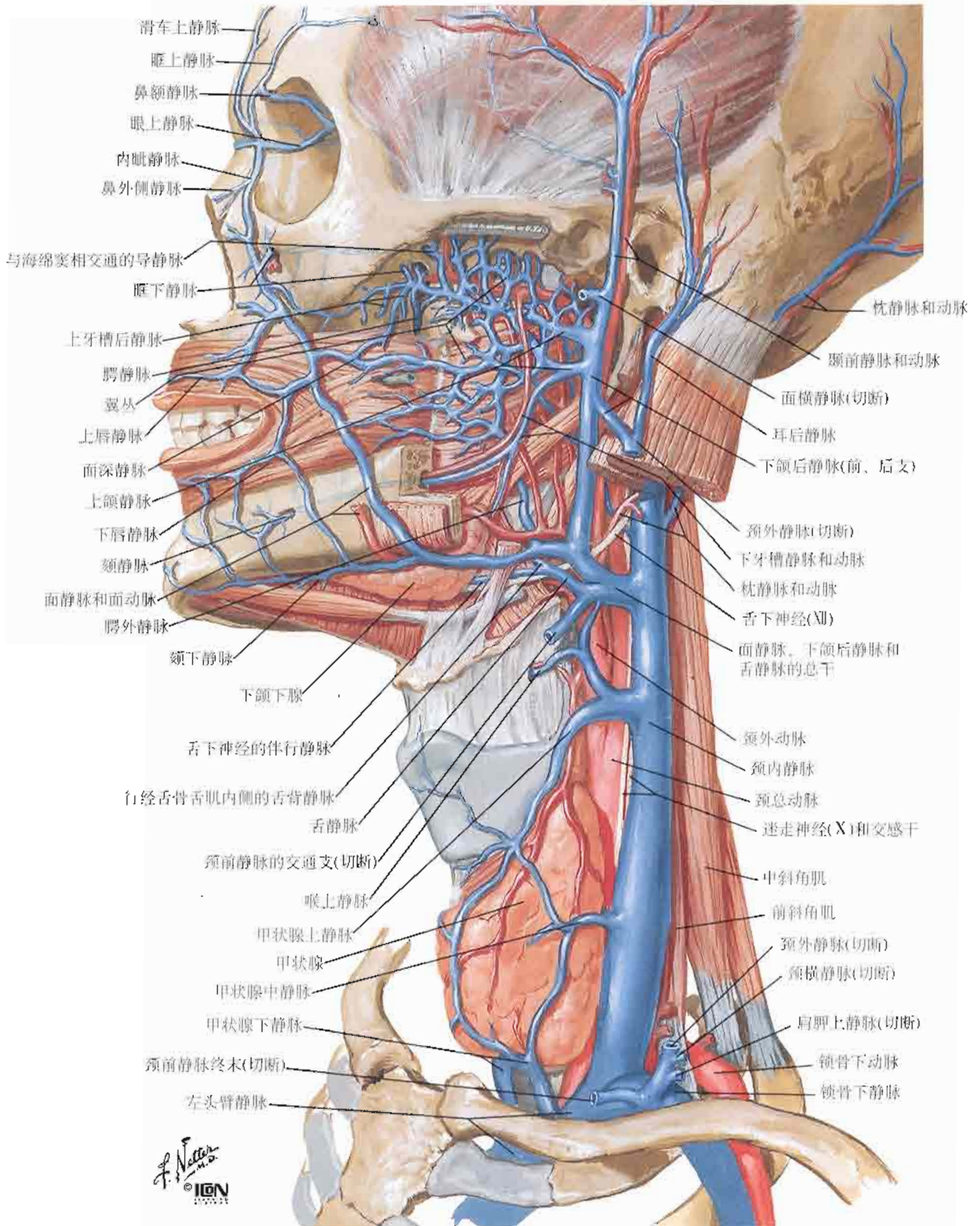
咽肌：外侧面观



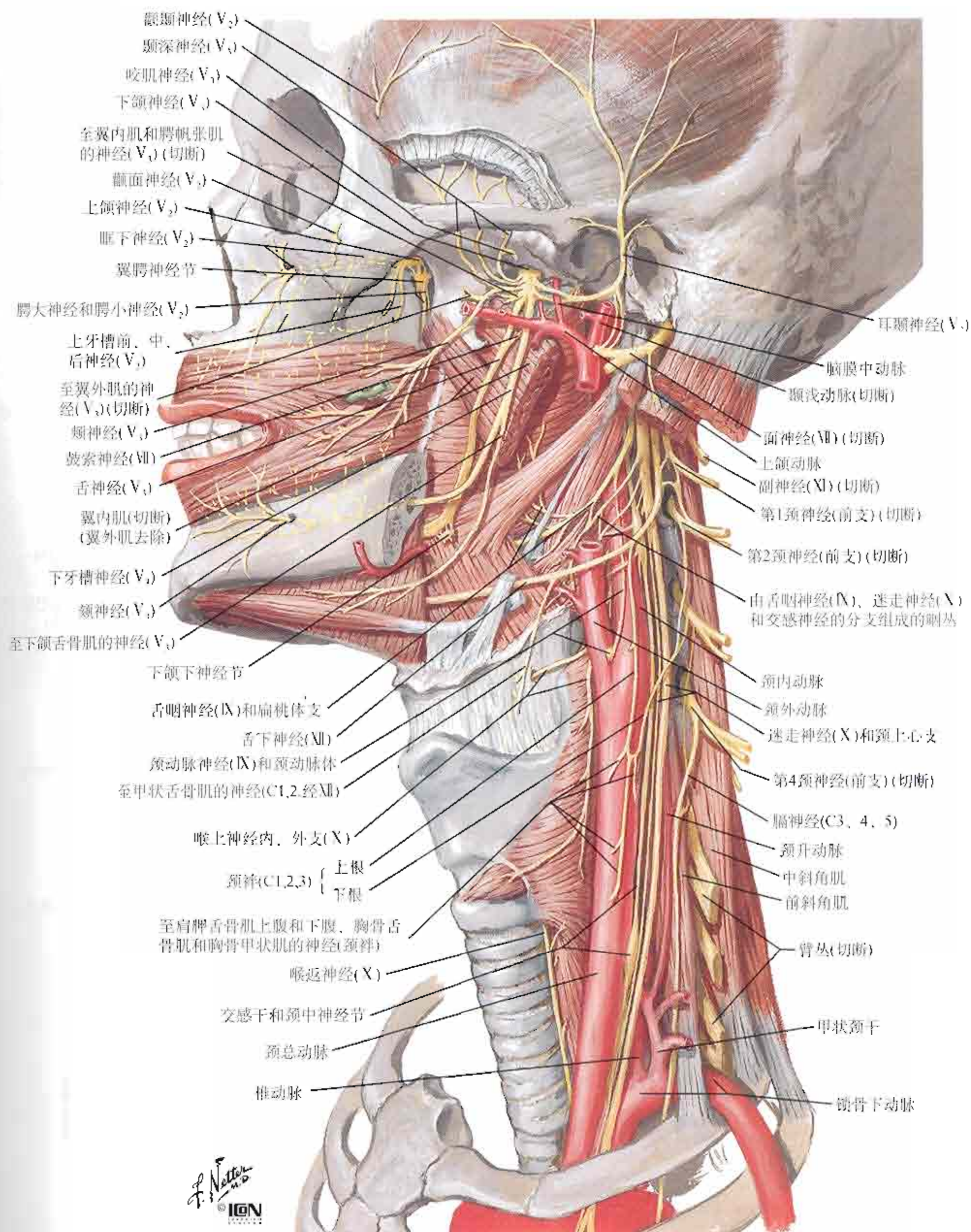


口与咽的静脉

参见图19、27、98

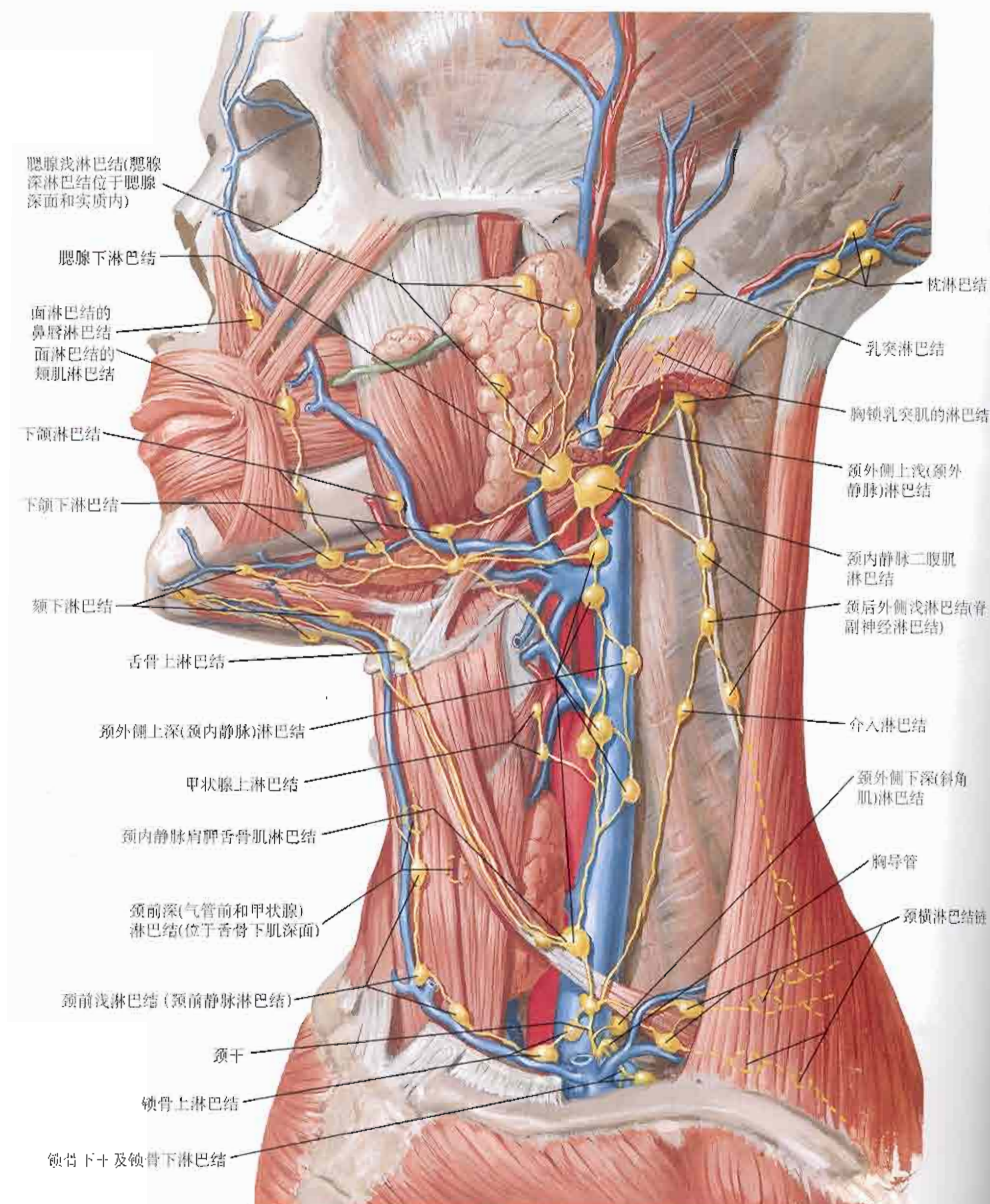


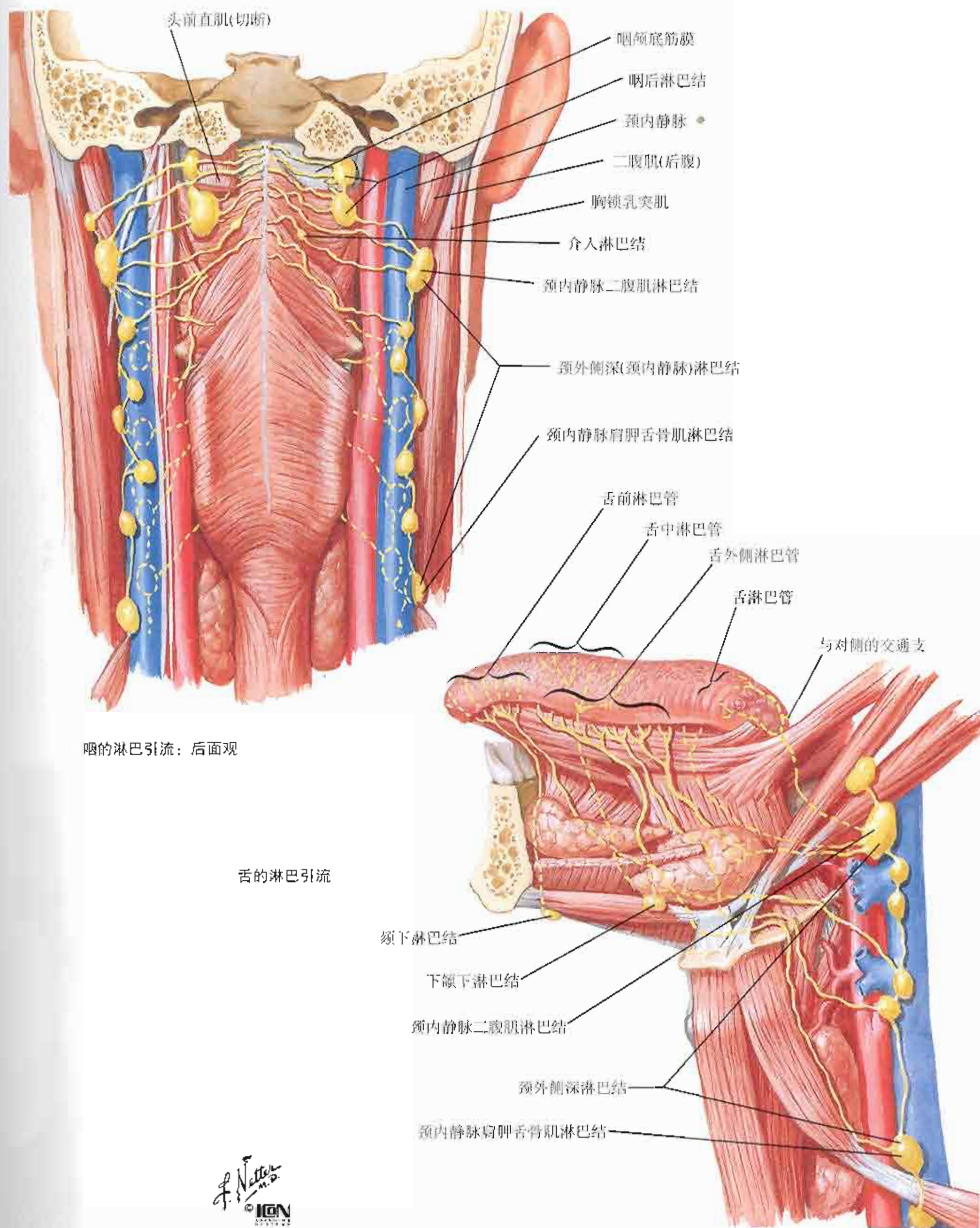
参见图21、41、42、116、119、120



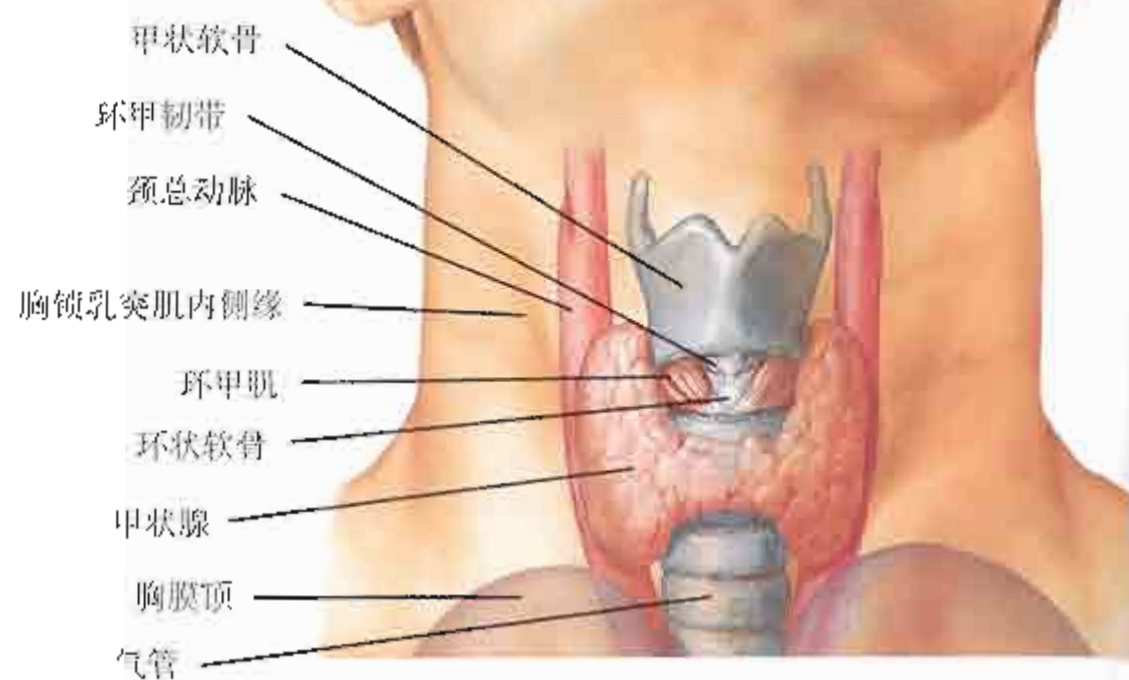
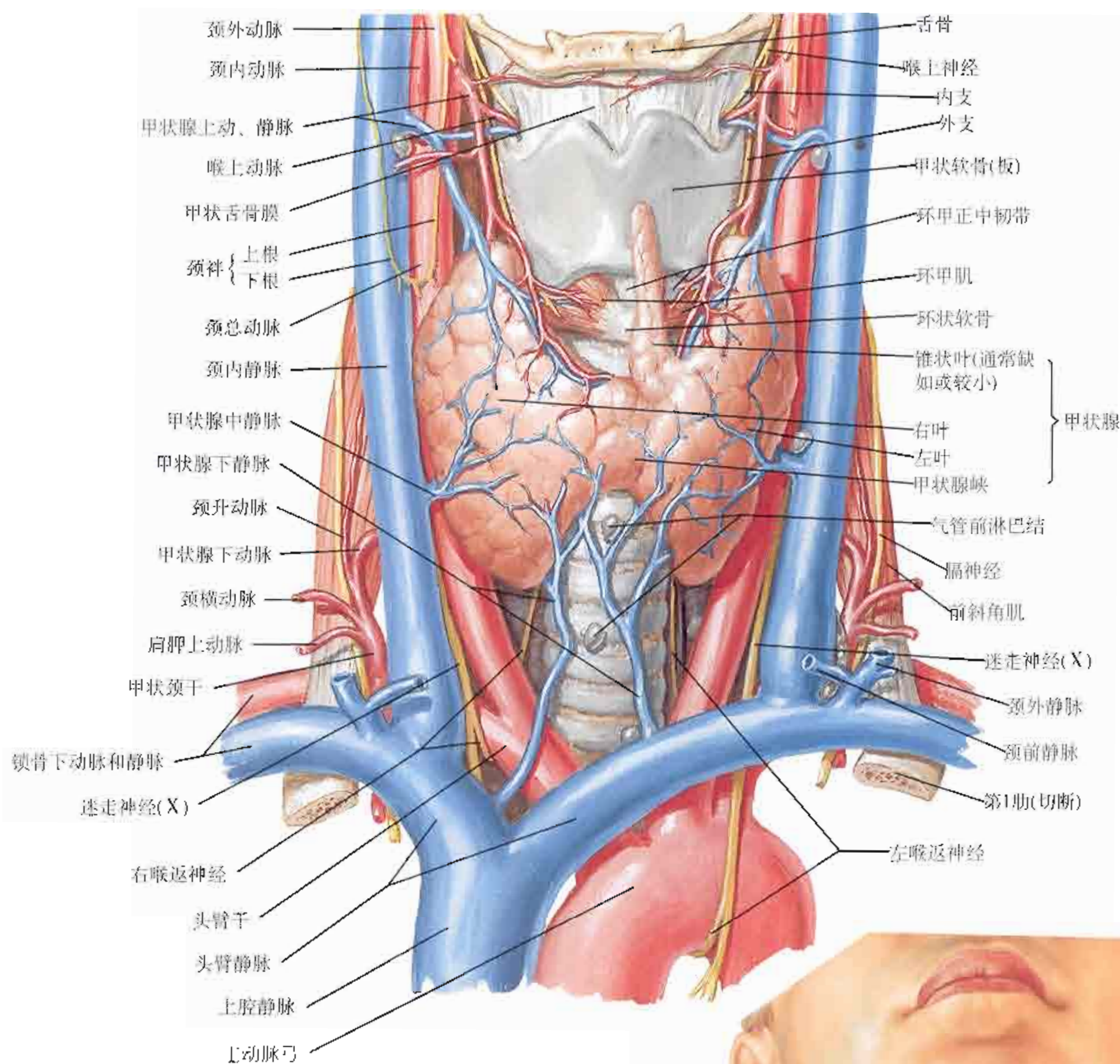
头和颈的淋巴管、淋巴结

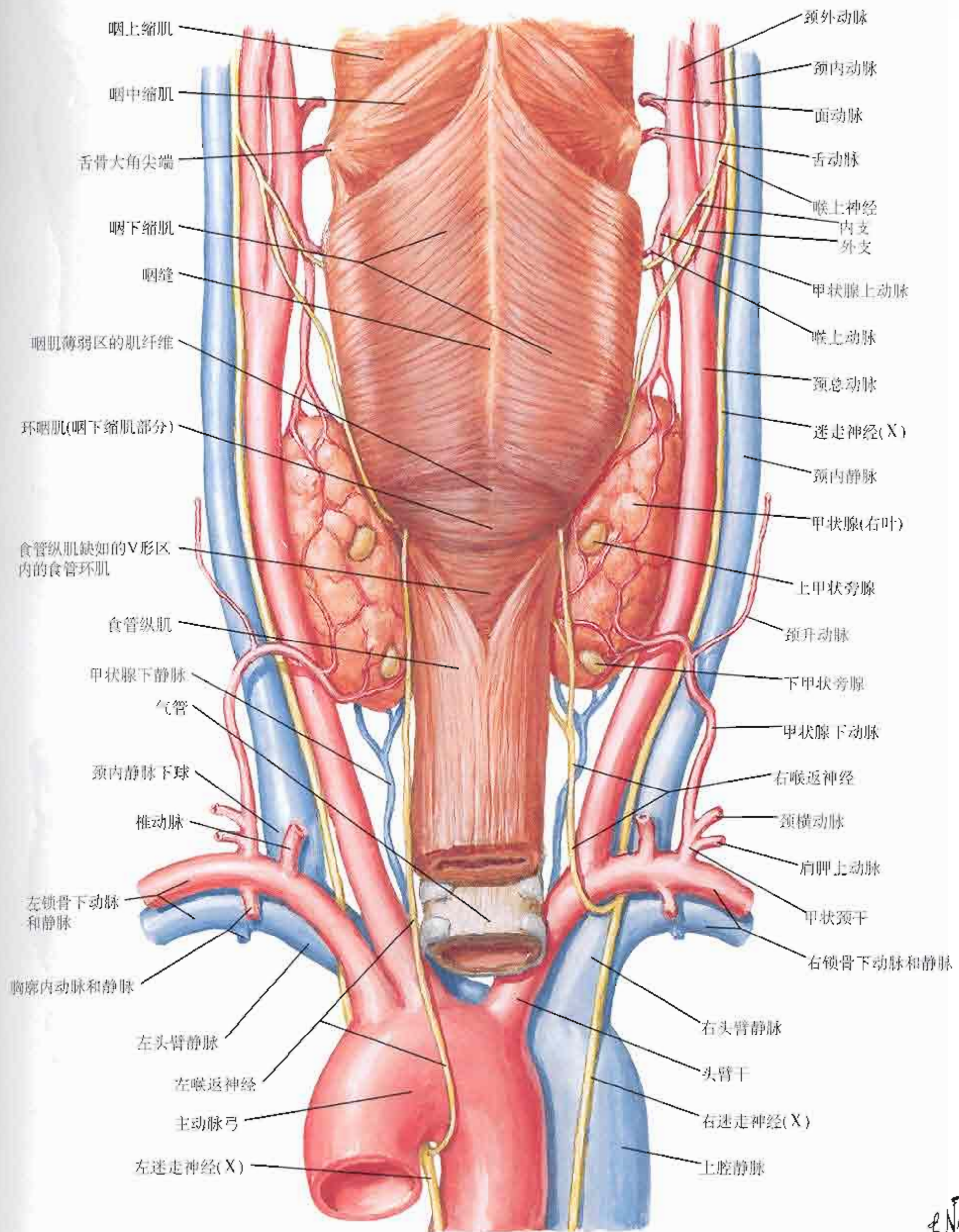
参见图204





甲状腺：前面观



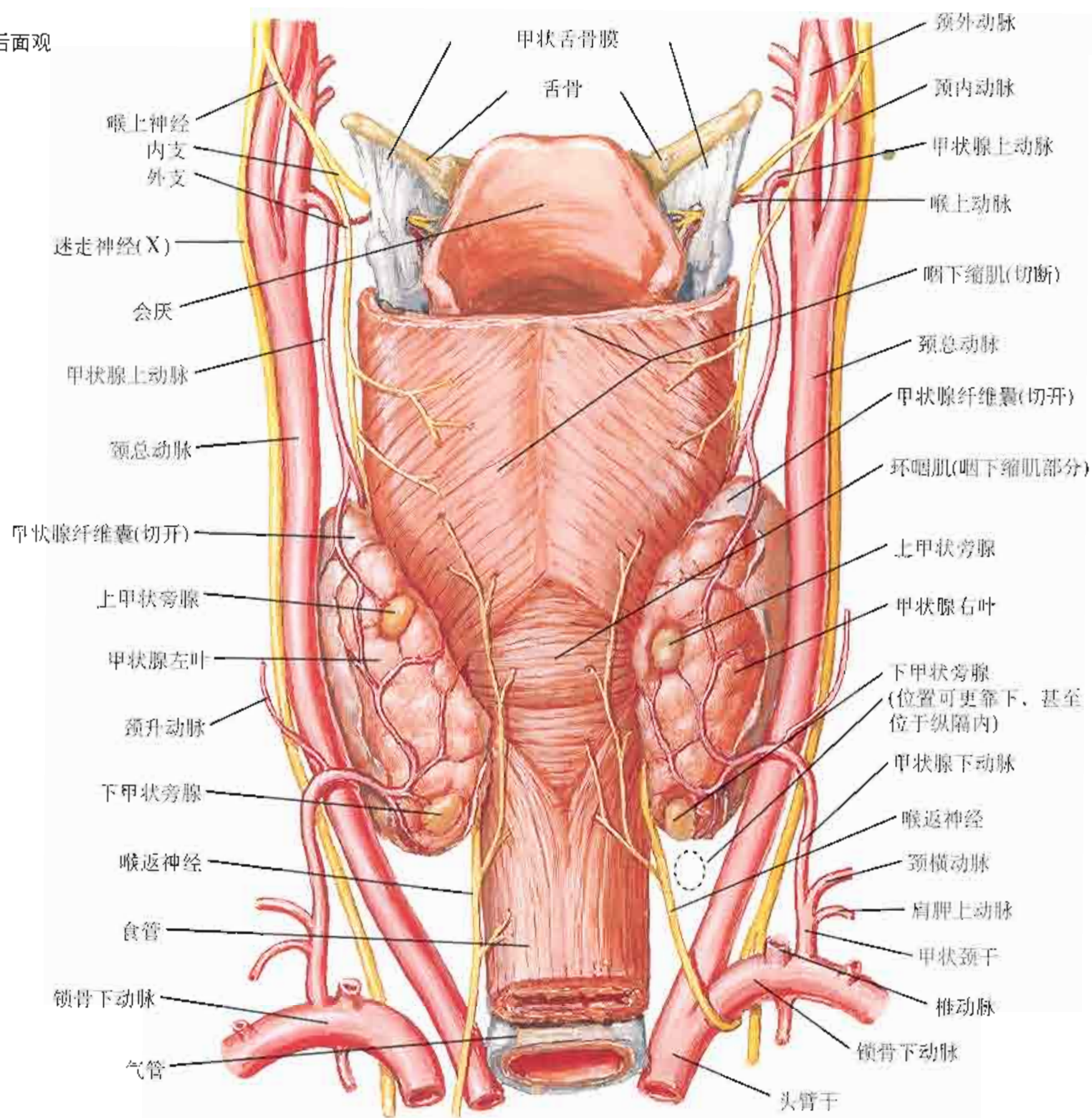


F. Netter M.D.
© IGV

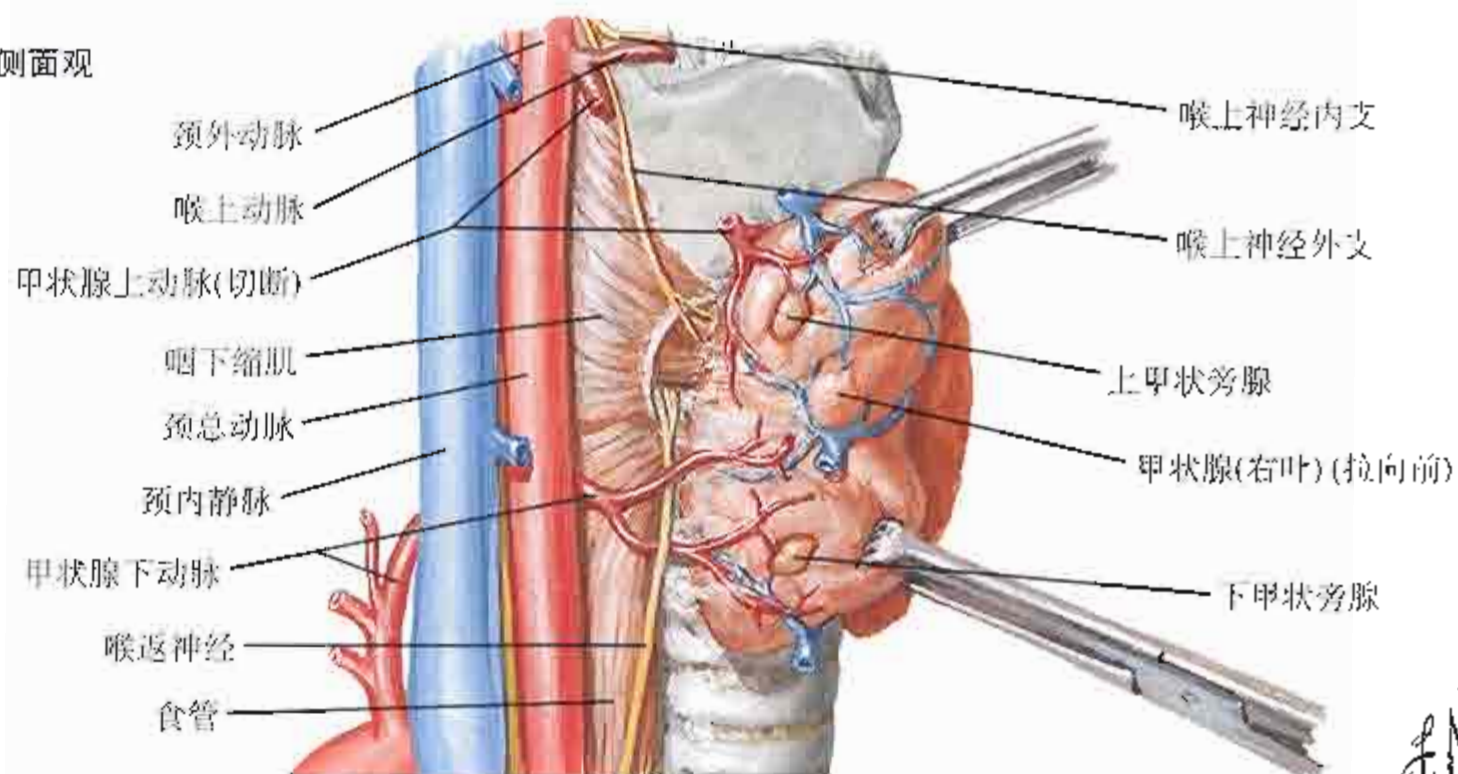
甲状旁腺

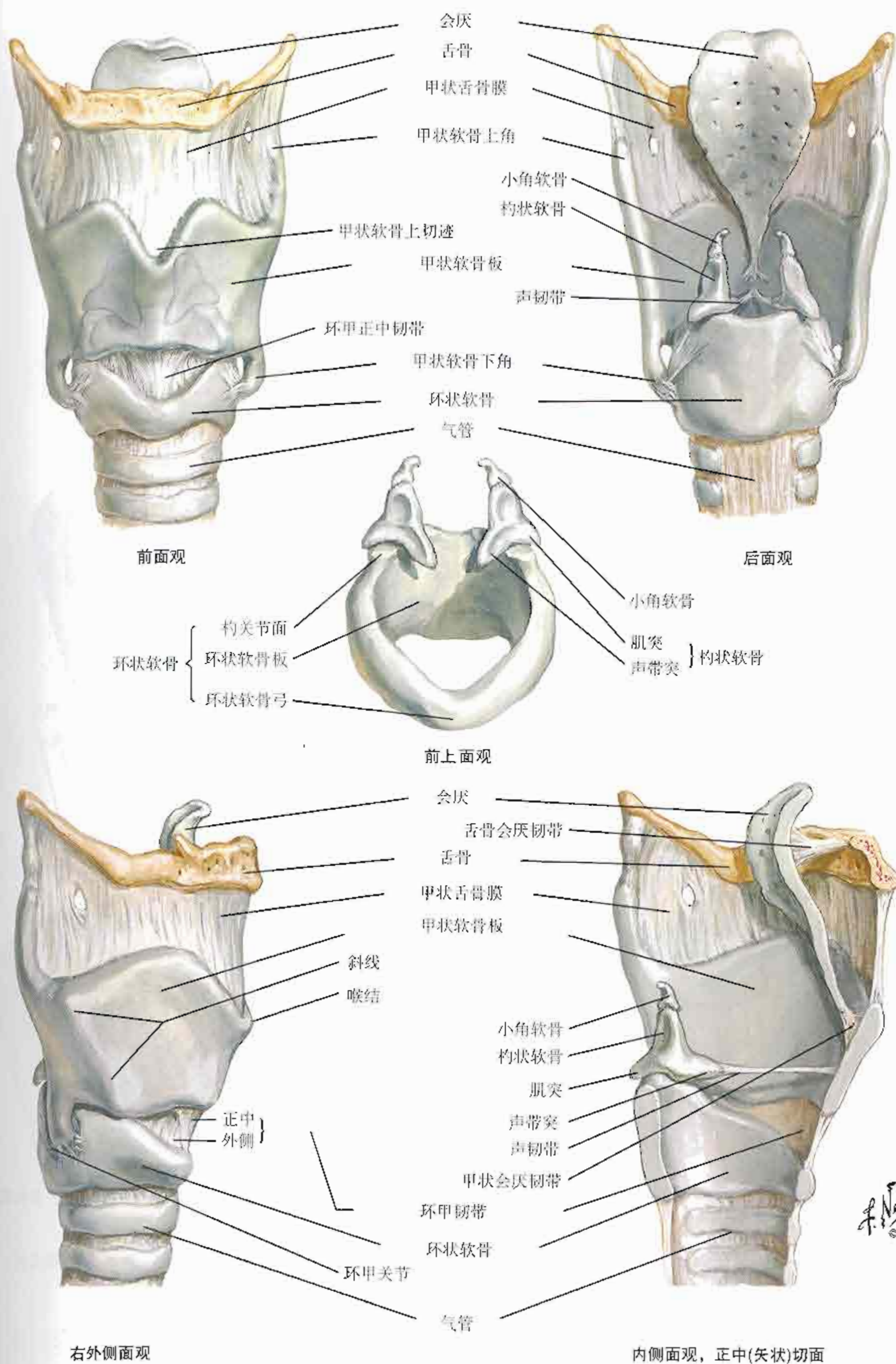
参见图76

后面观

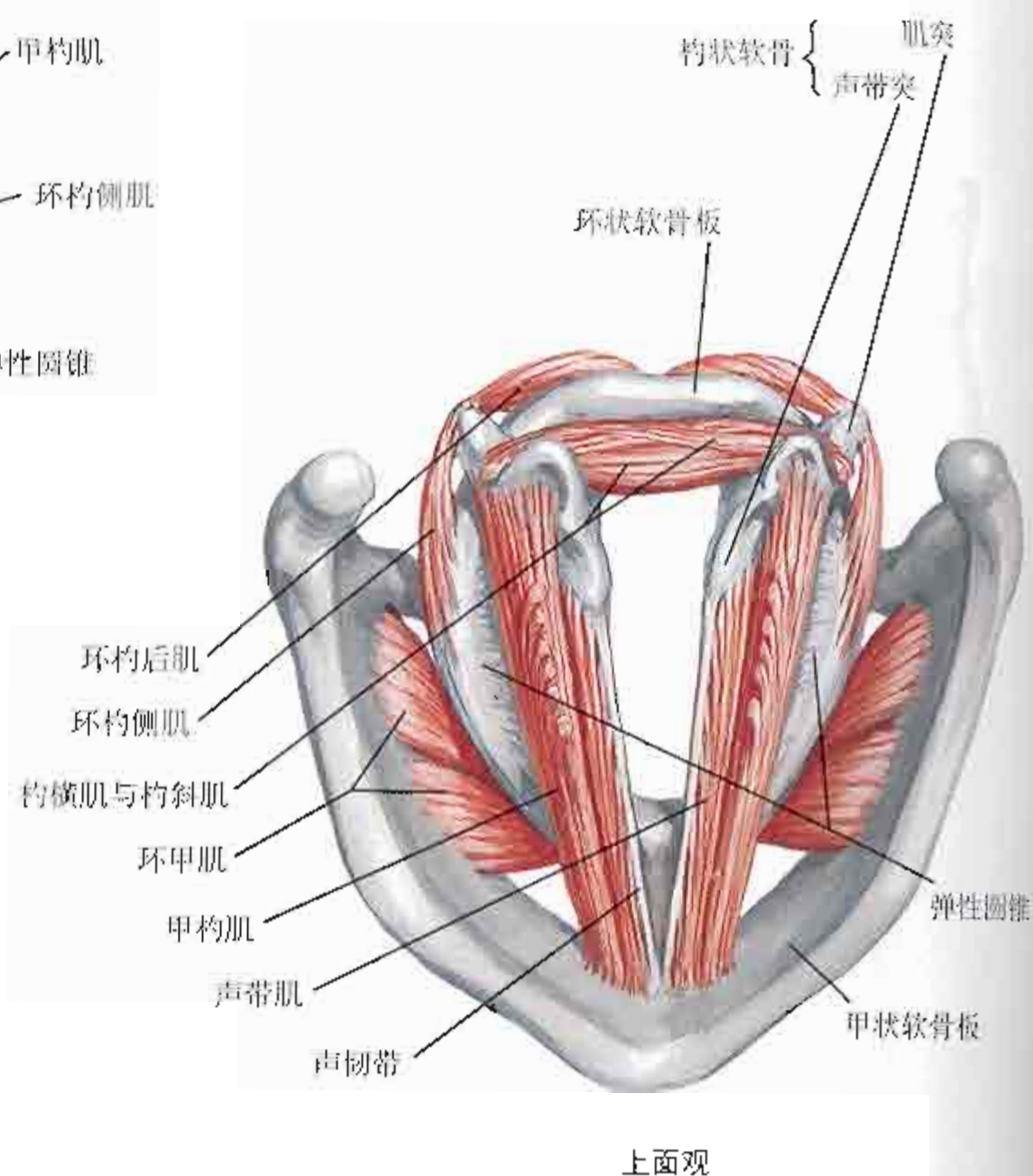
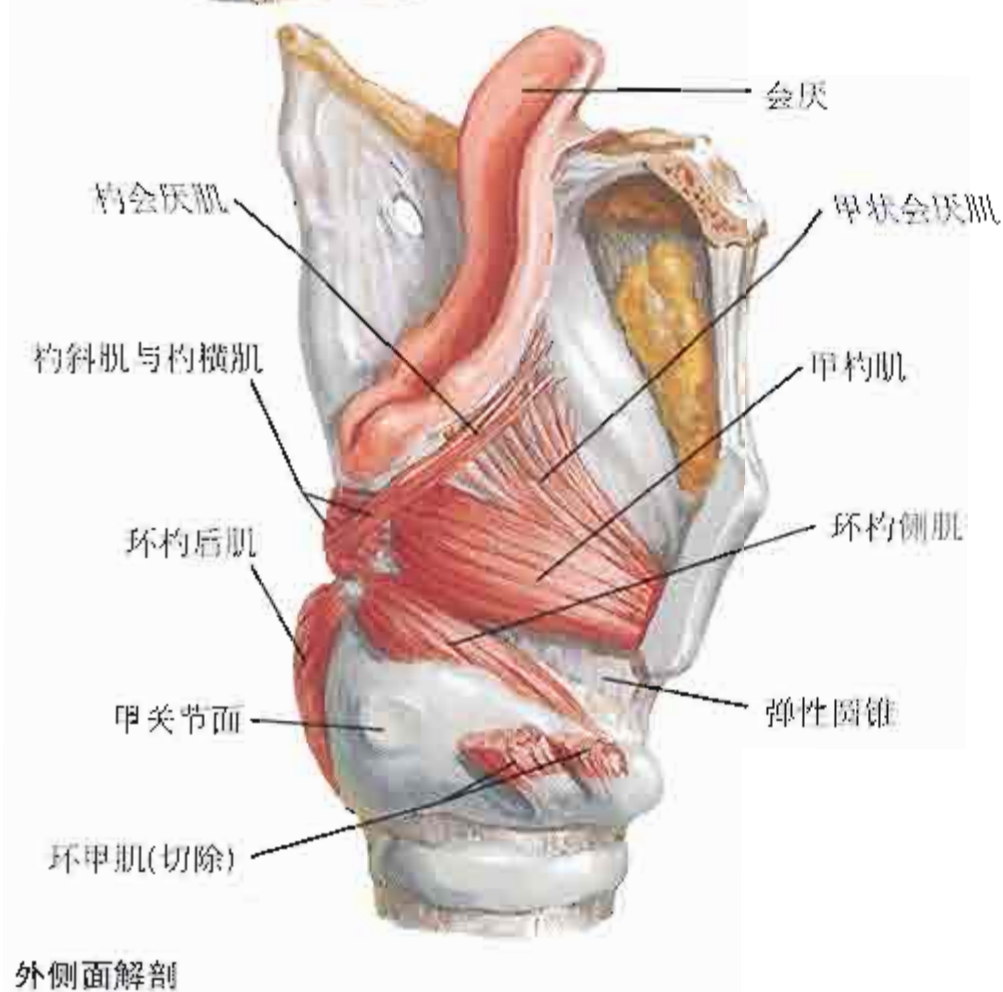
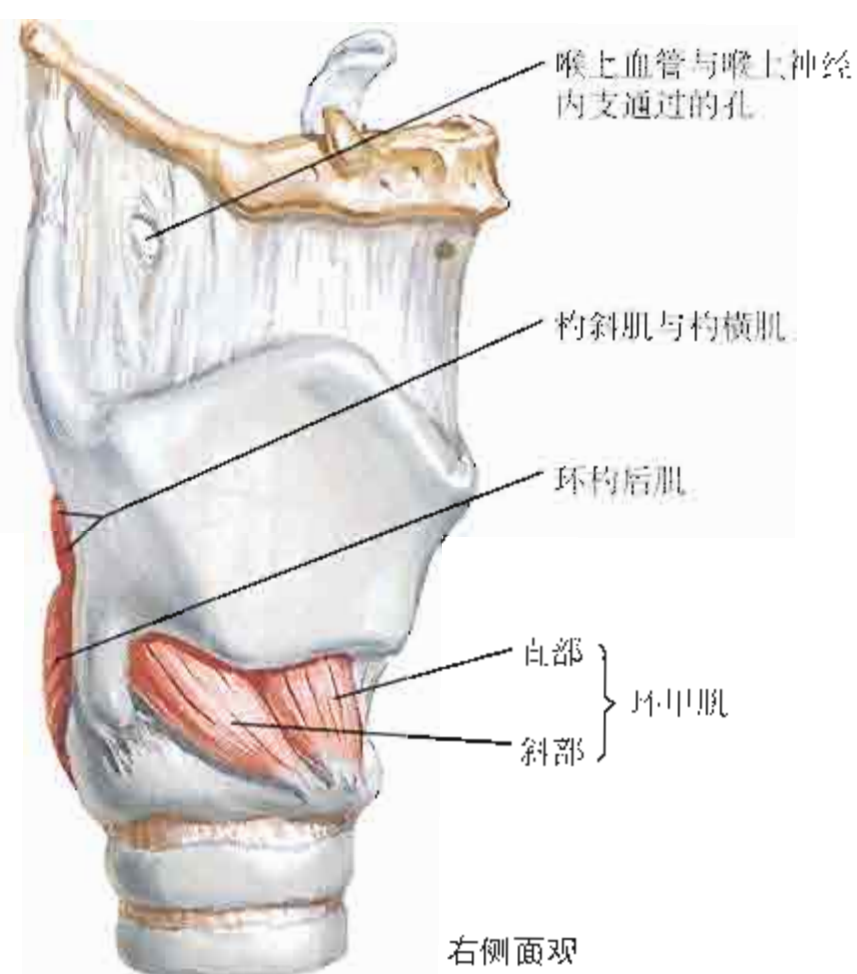
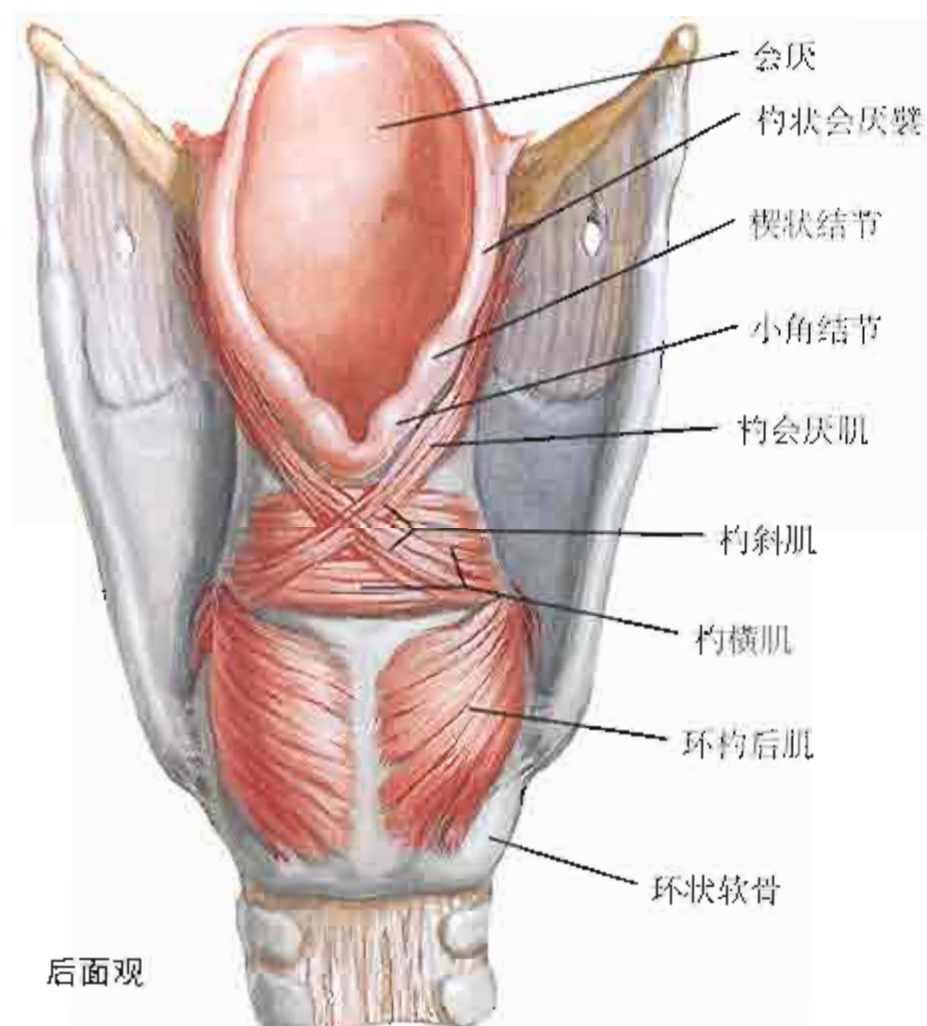


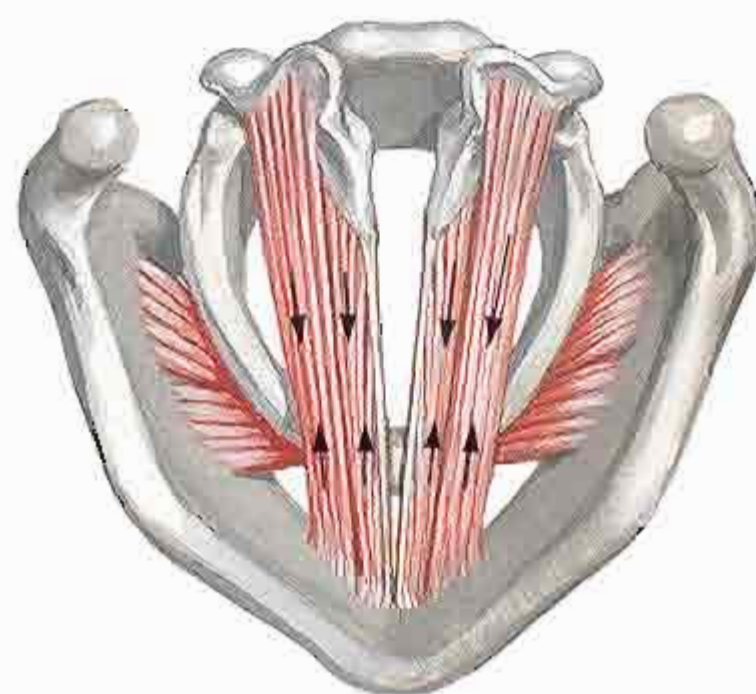
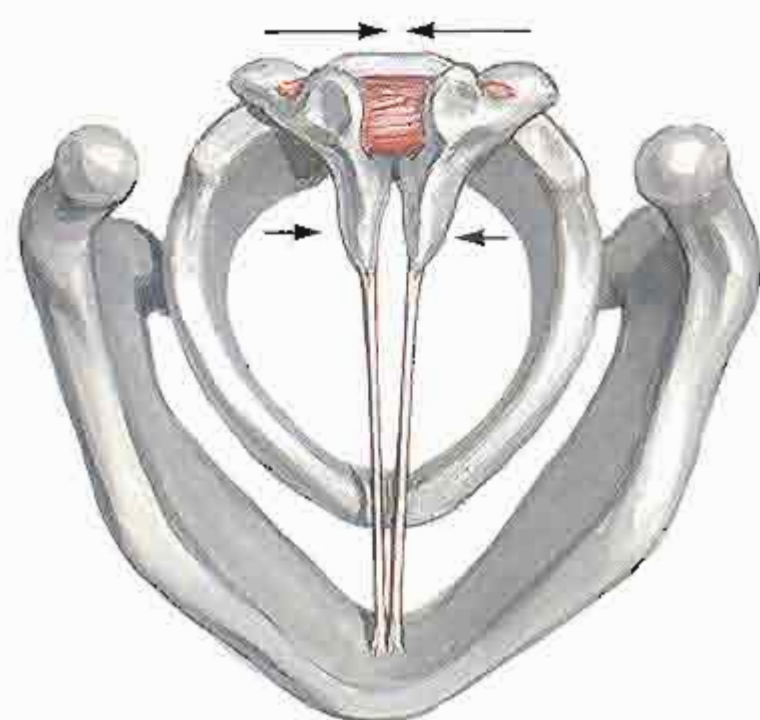
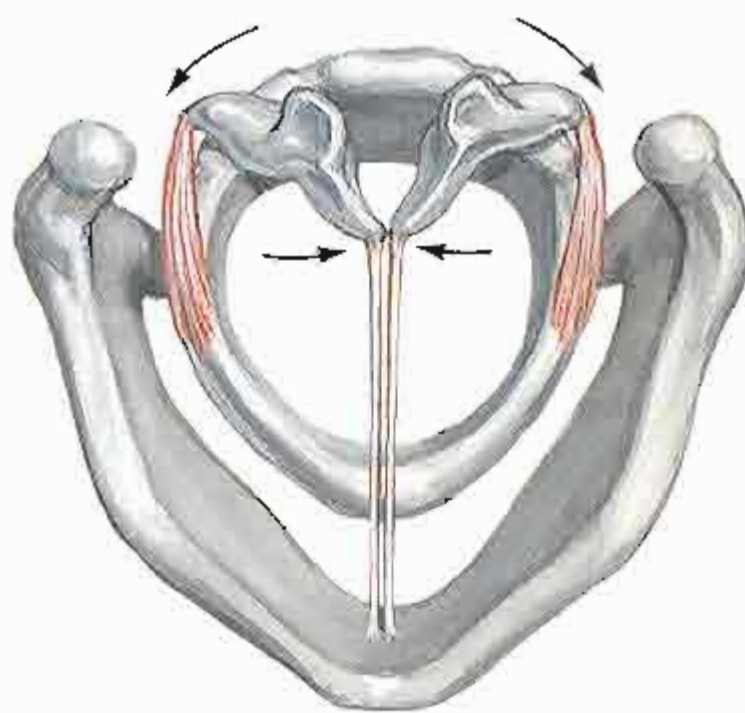
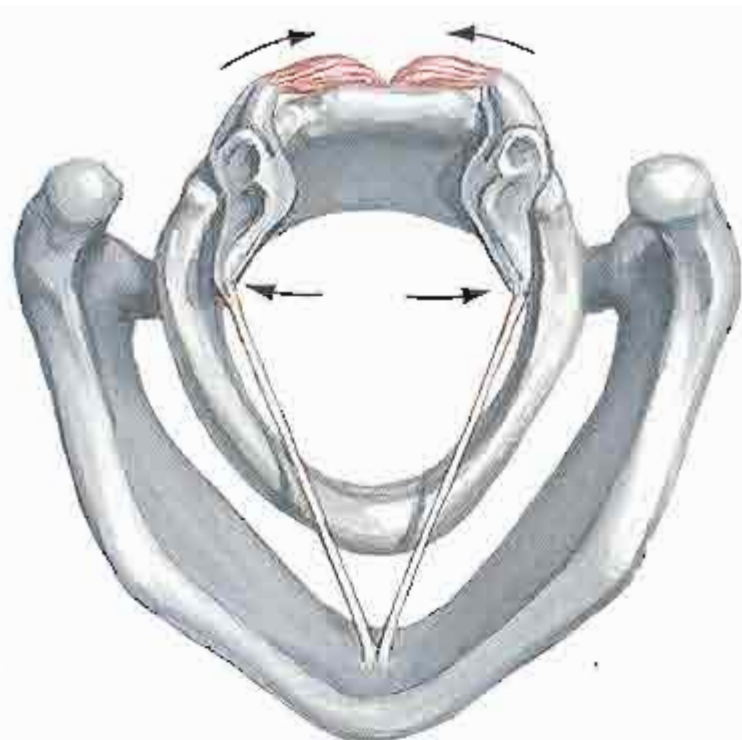
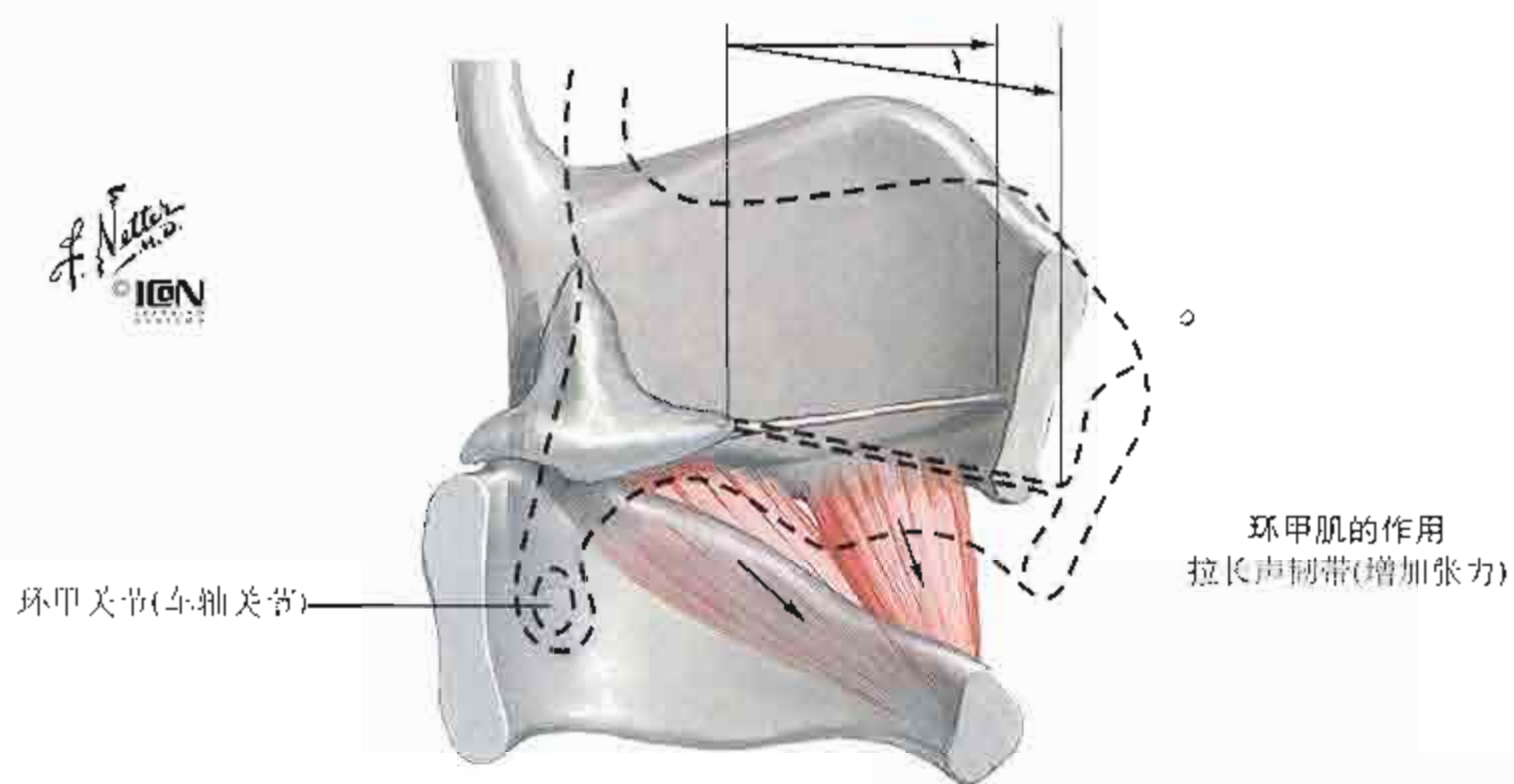
右外侧面观





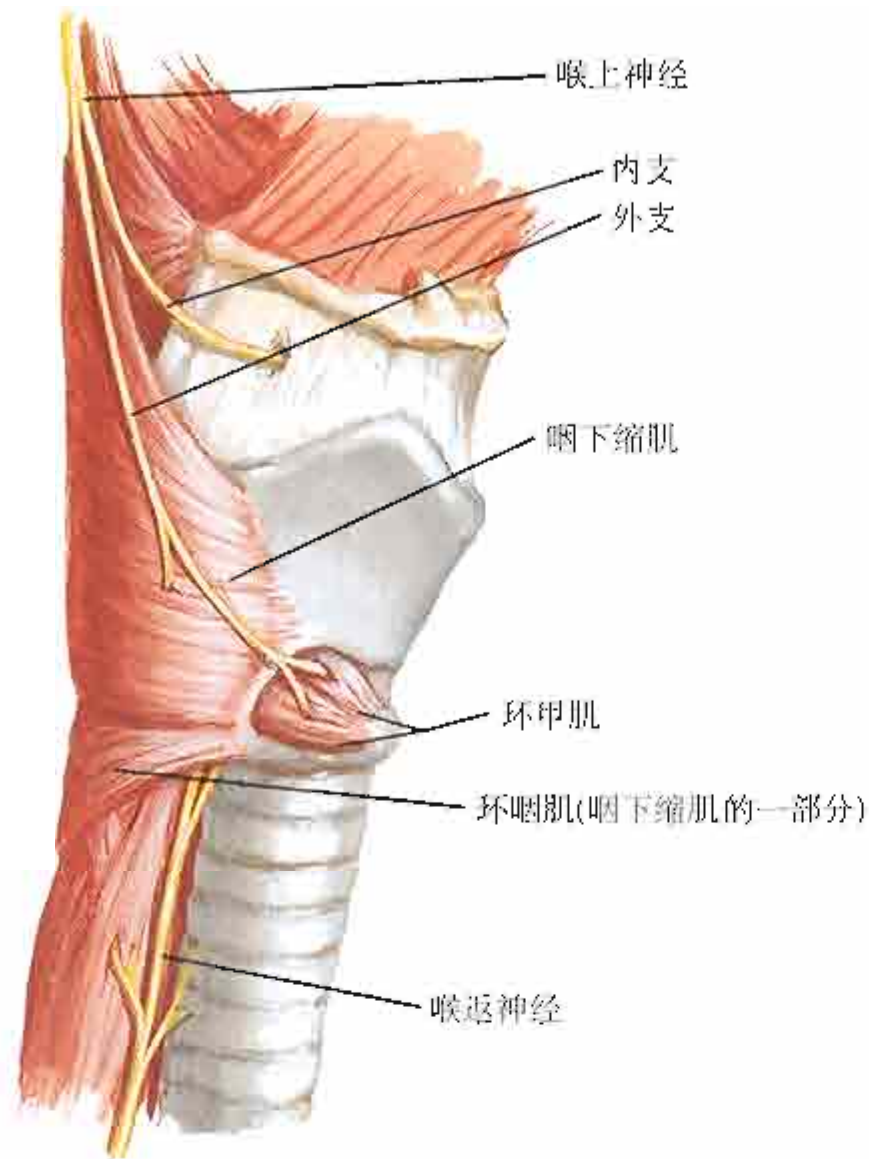
喉内肌



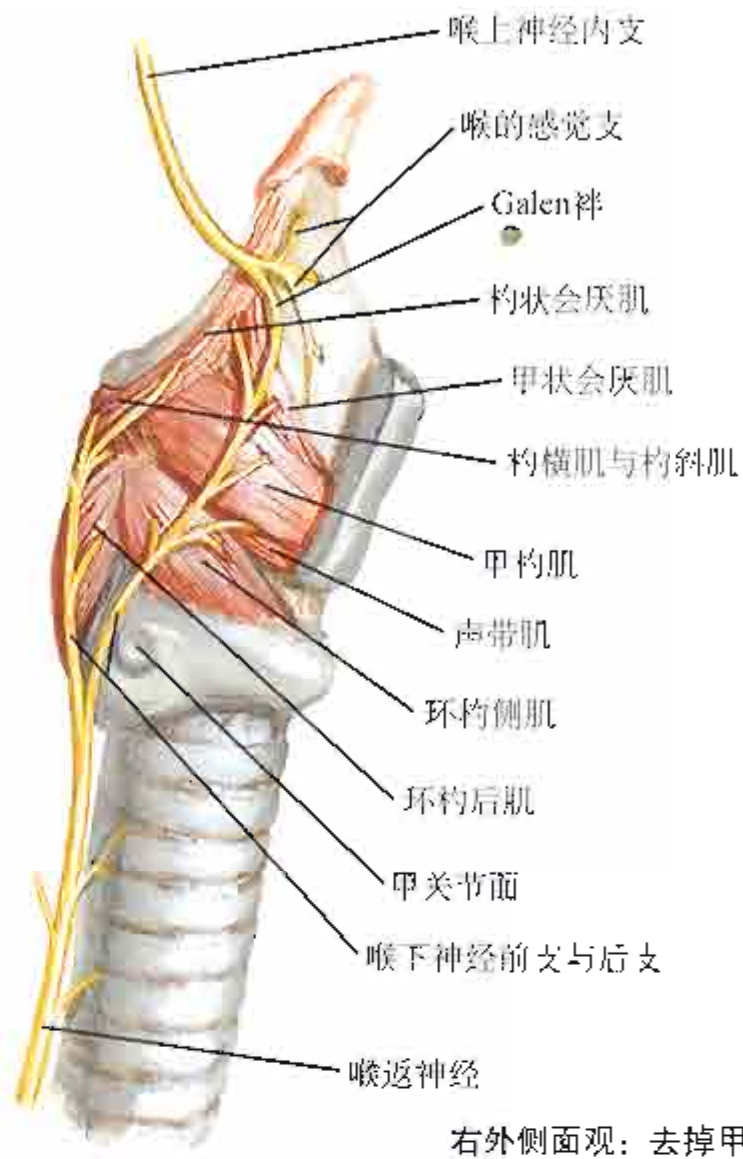


喉的神经

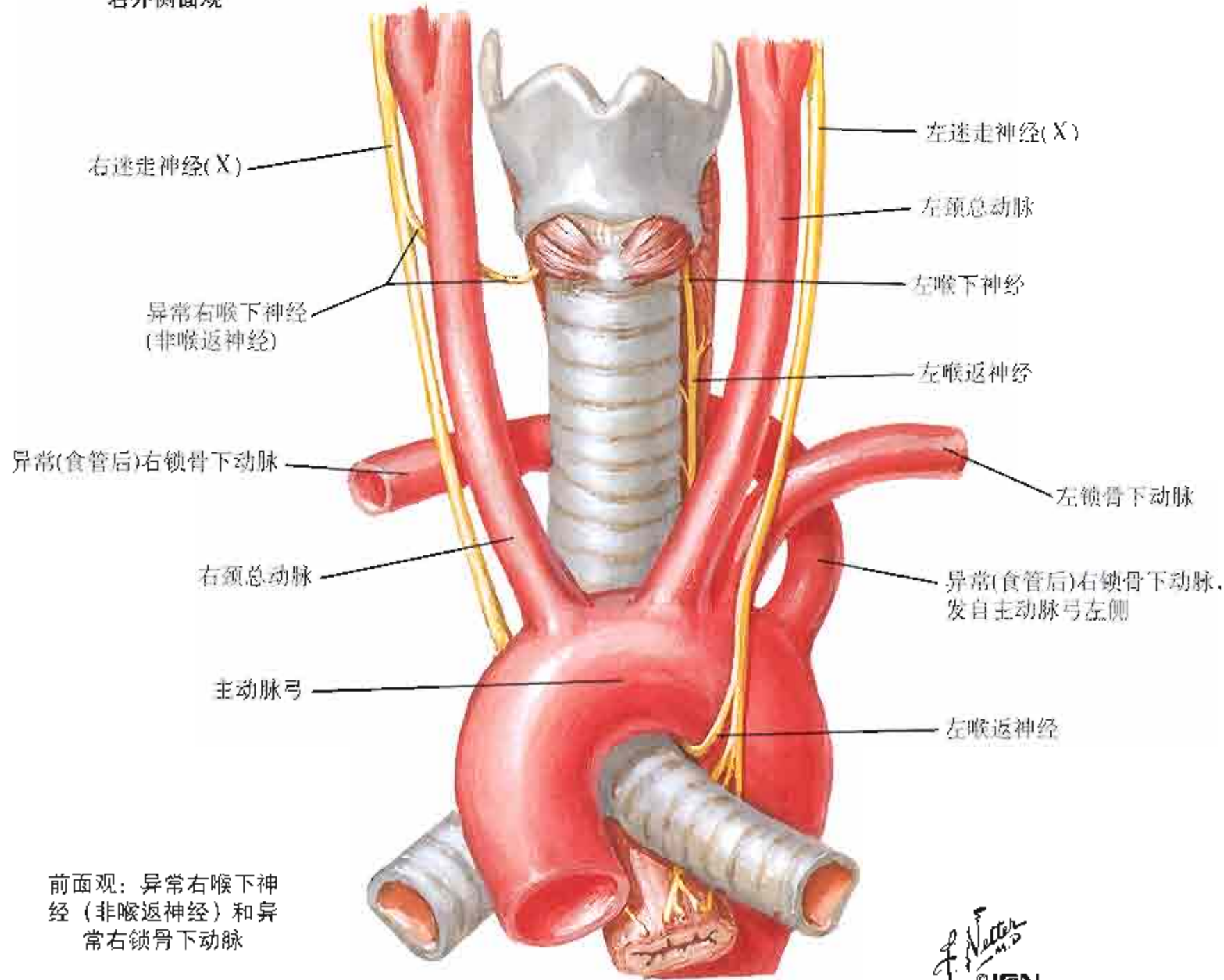
参见图70~72. 231



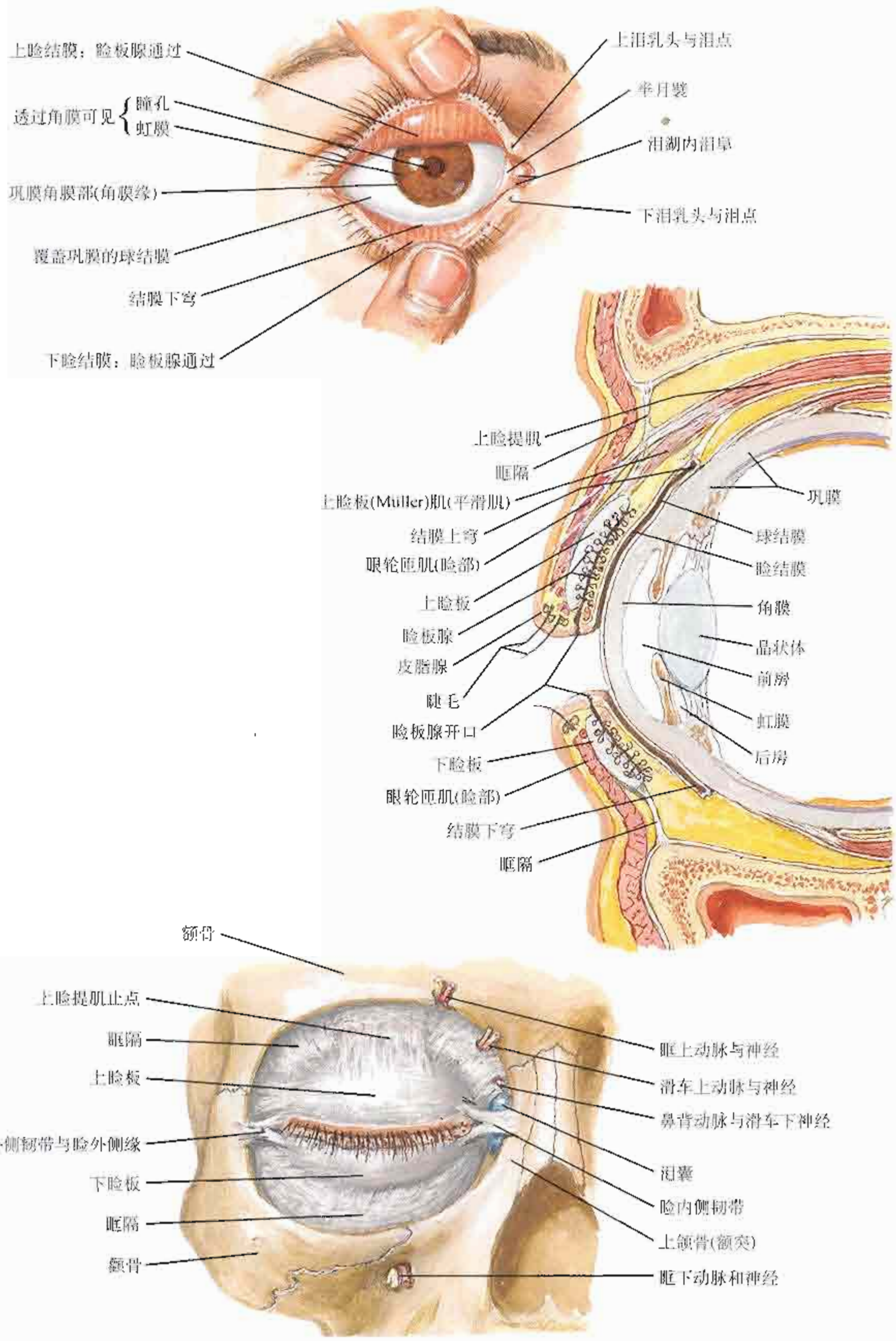
右外侧面观



右外侧面观: 去掉甲状软骨板



前面观: 异常右喉下神经(非喉返神经)和异常右锁骨下动脉

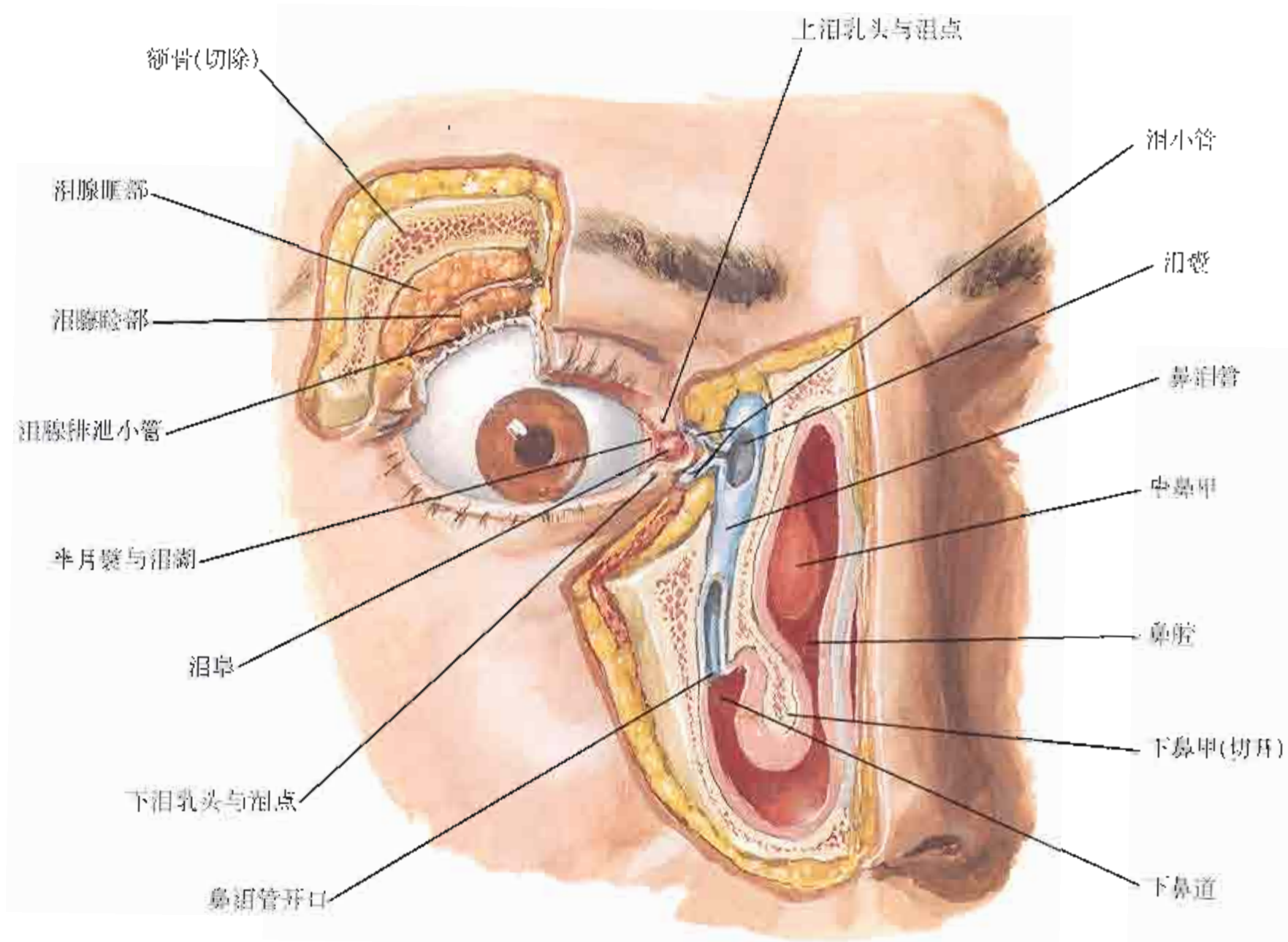
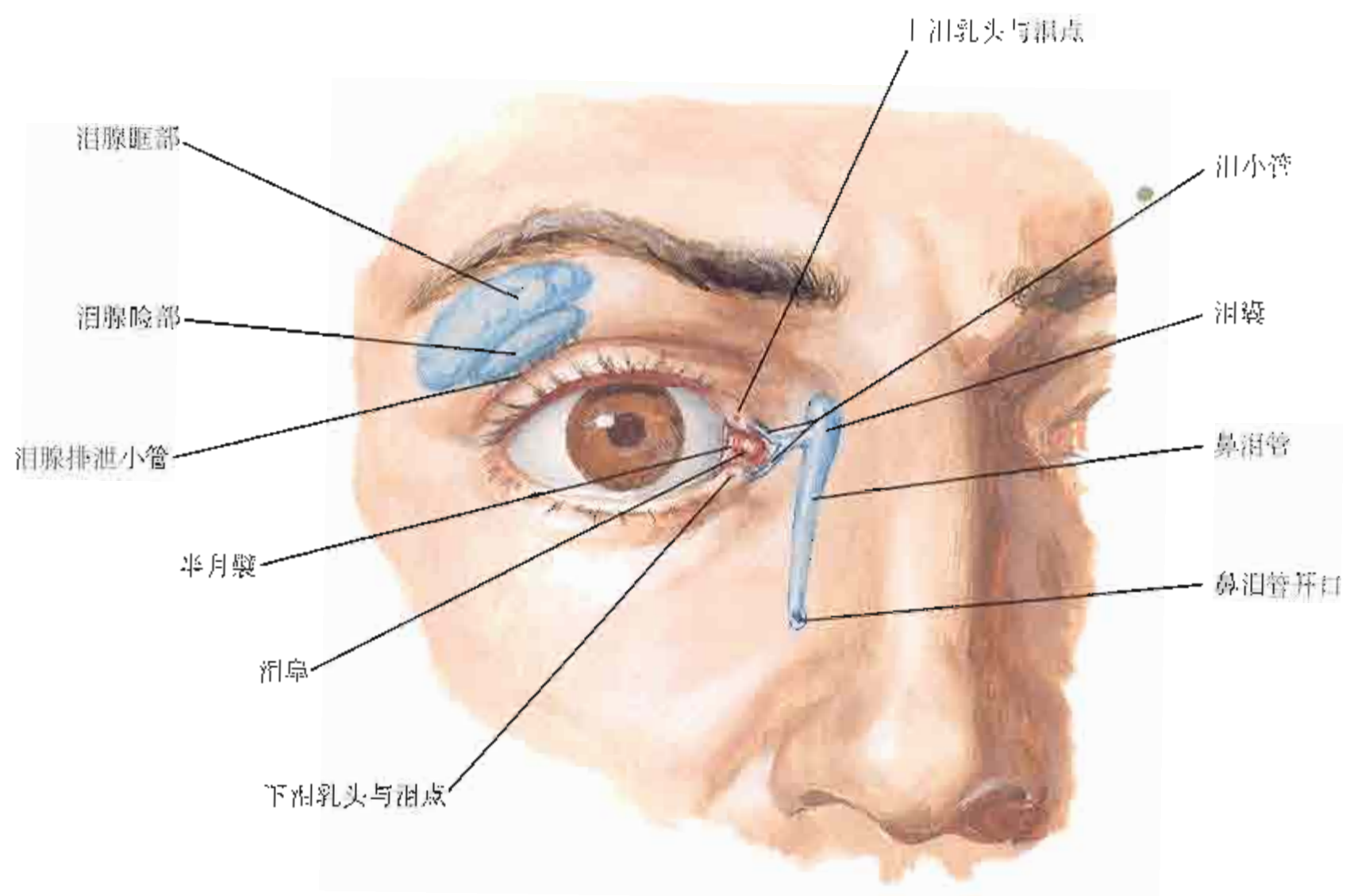


眶及其内容

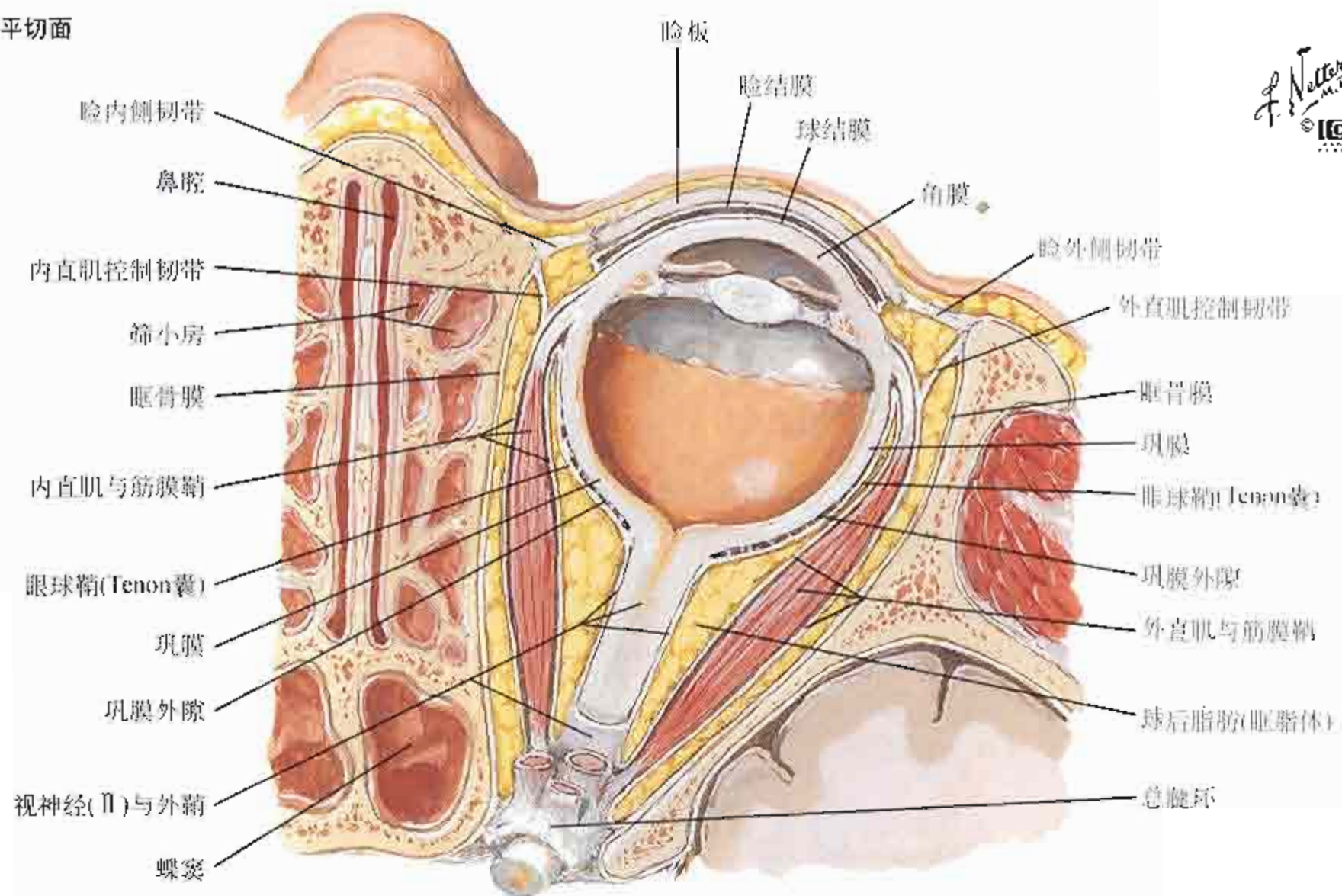
图77

泪器

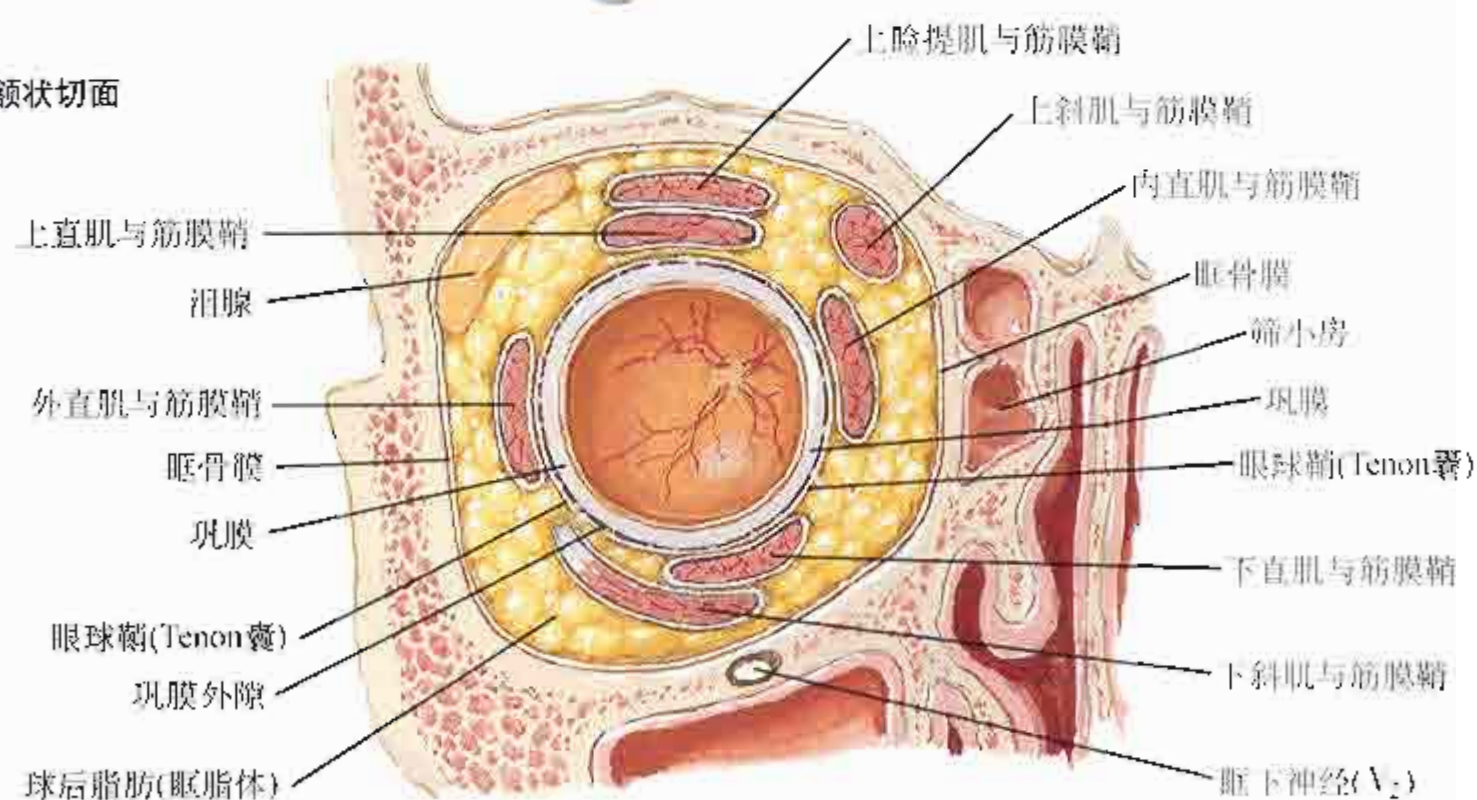
参见图41、127



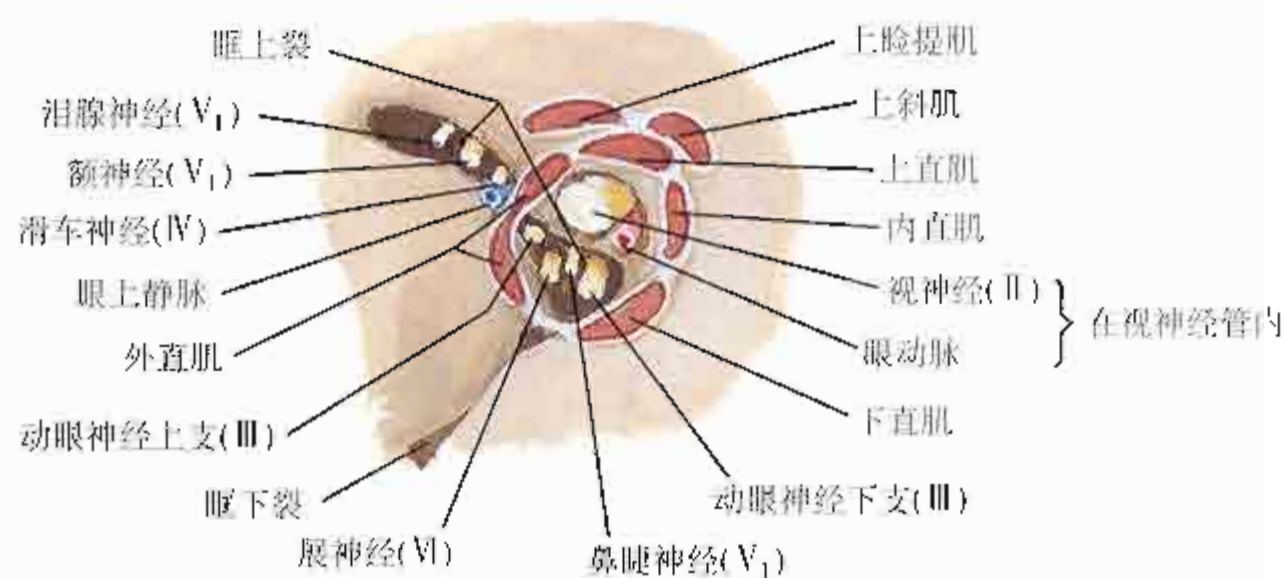
水平切面



额状切面

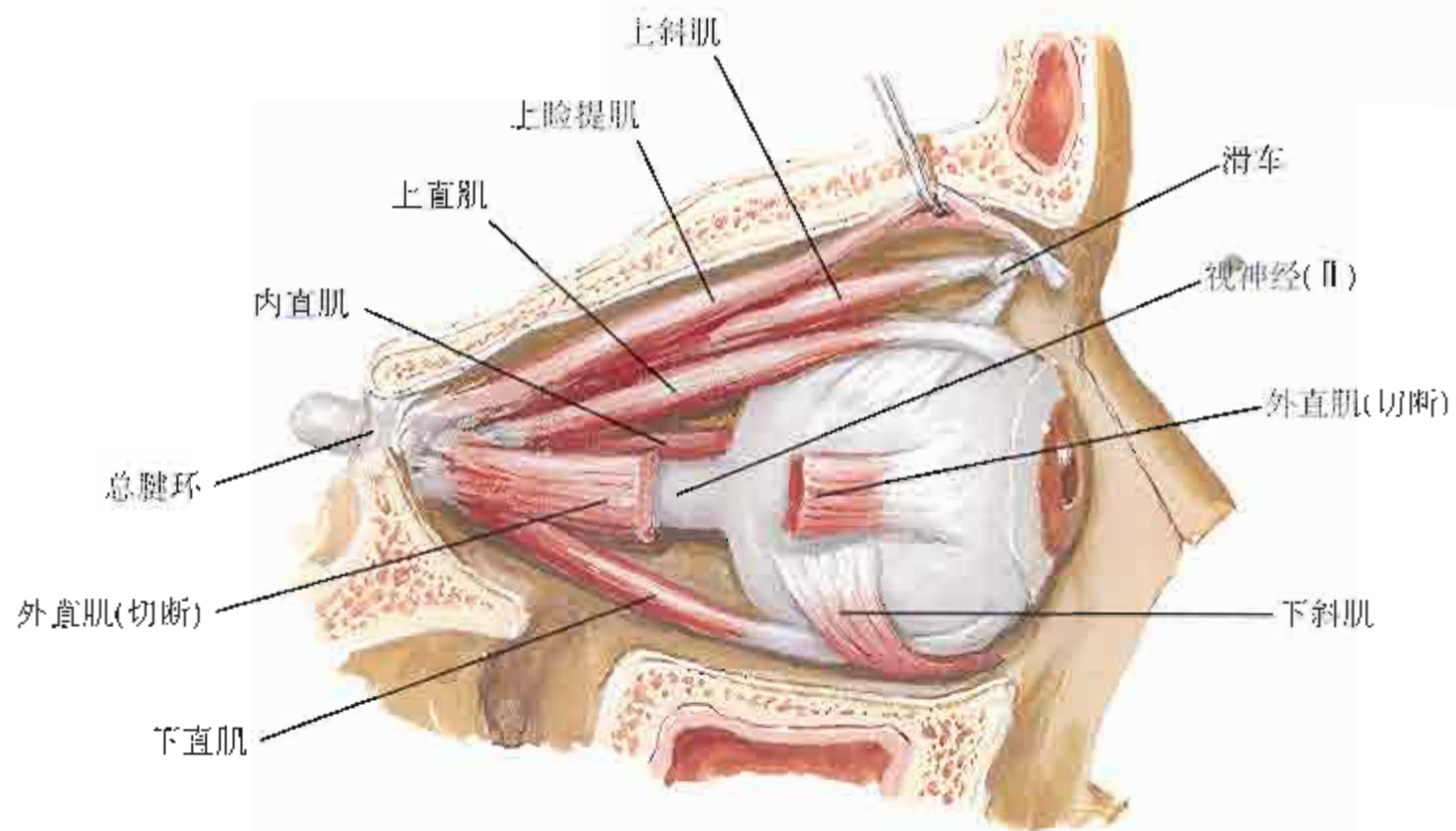


肌肉附着与入眶神经、血管

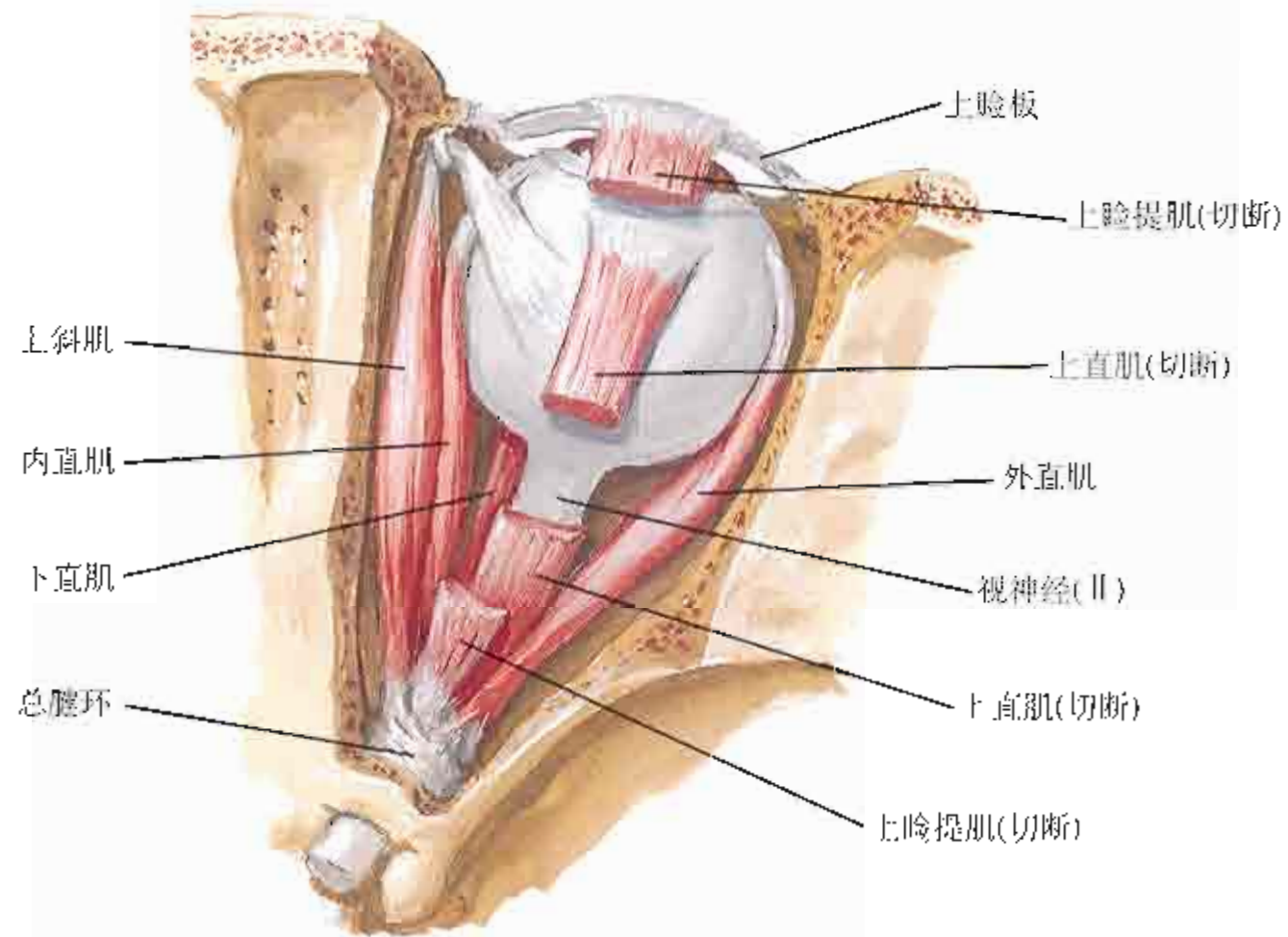


眼外肌

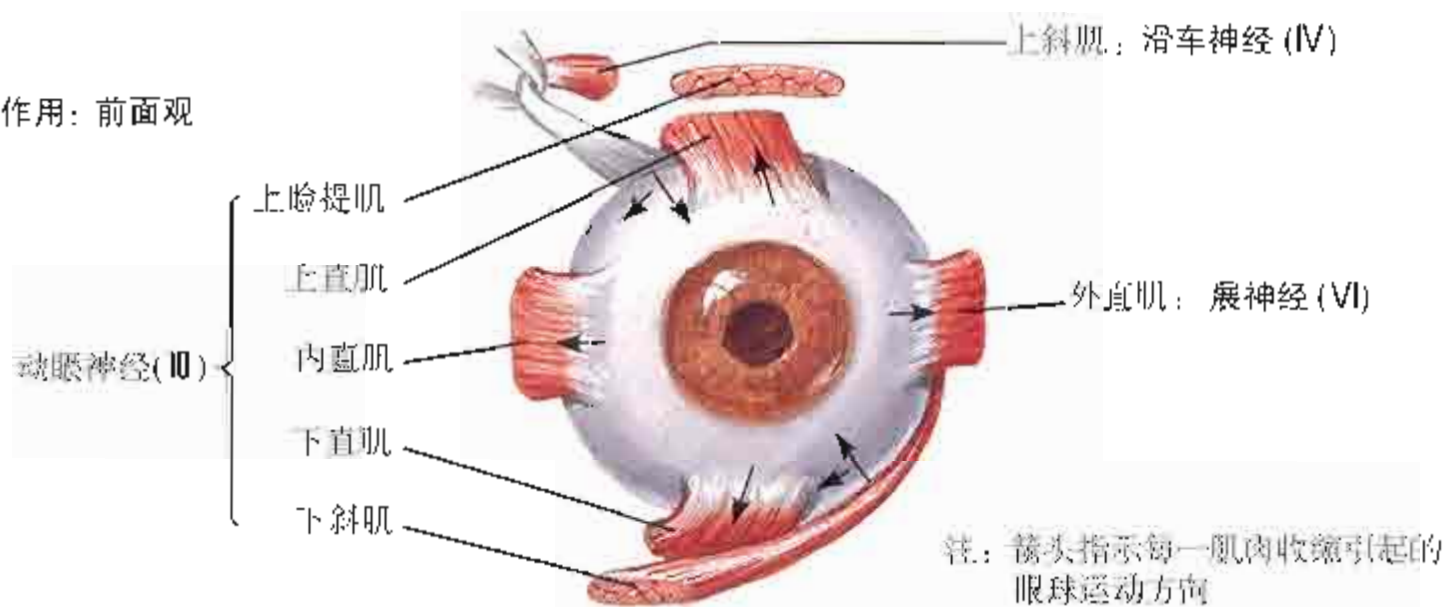
右外侧面观

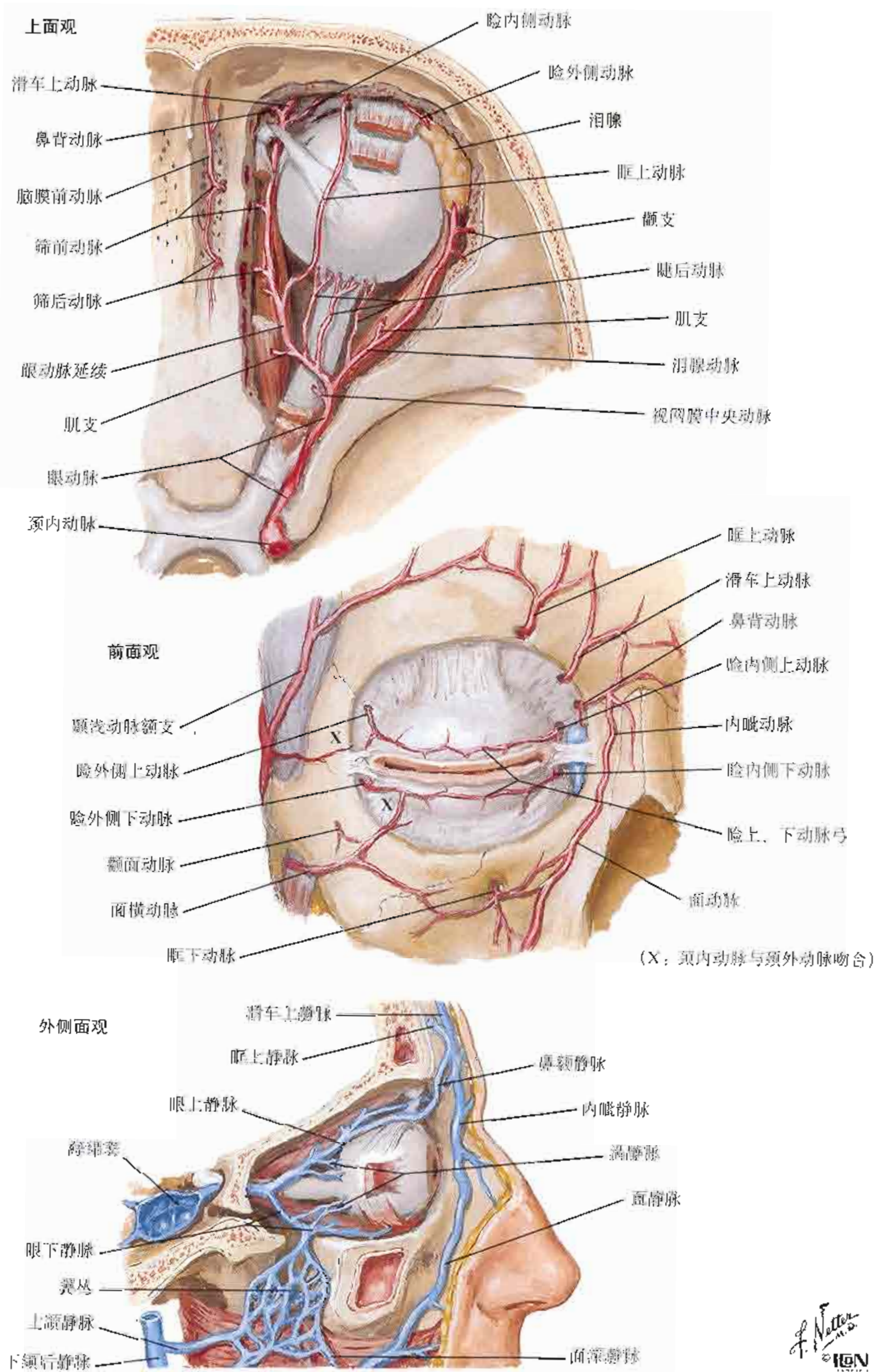


上面观



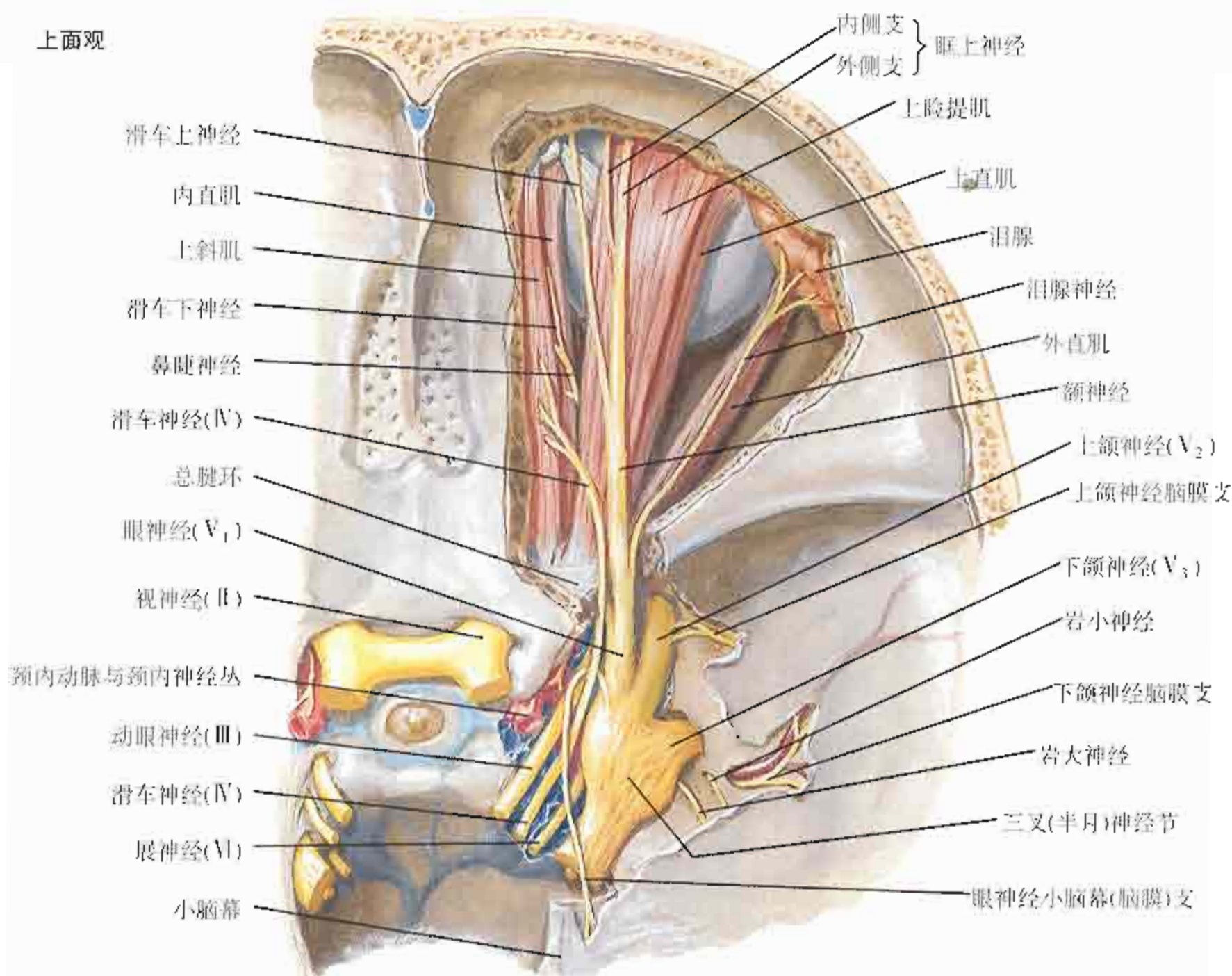
眼外肌的神经支配与作用：前面观



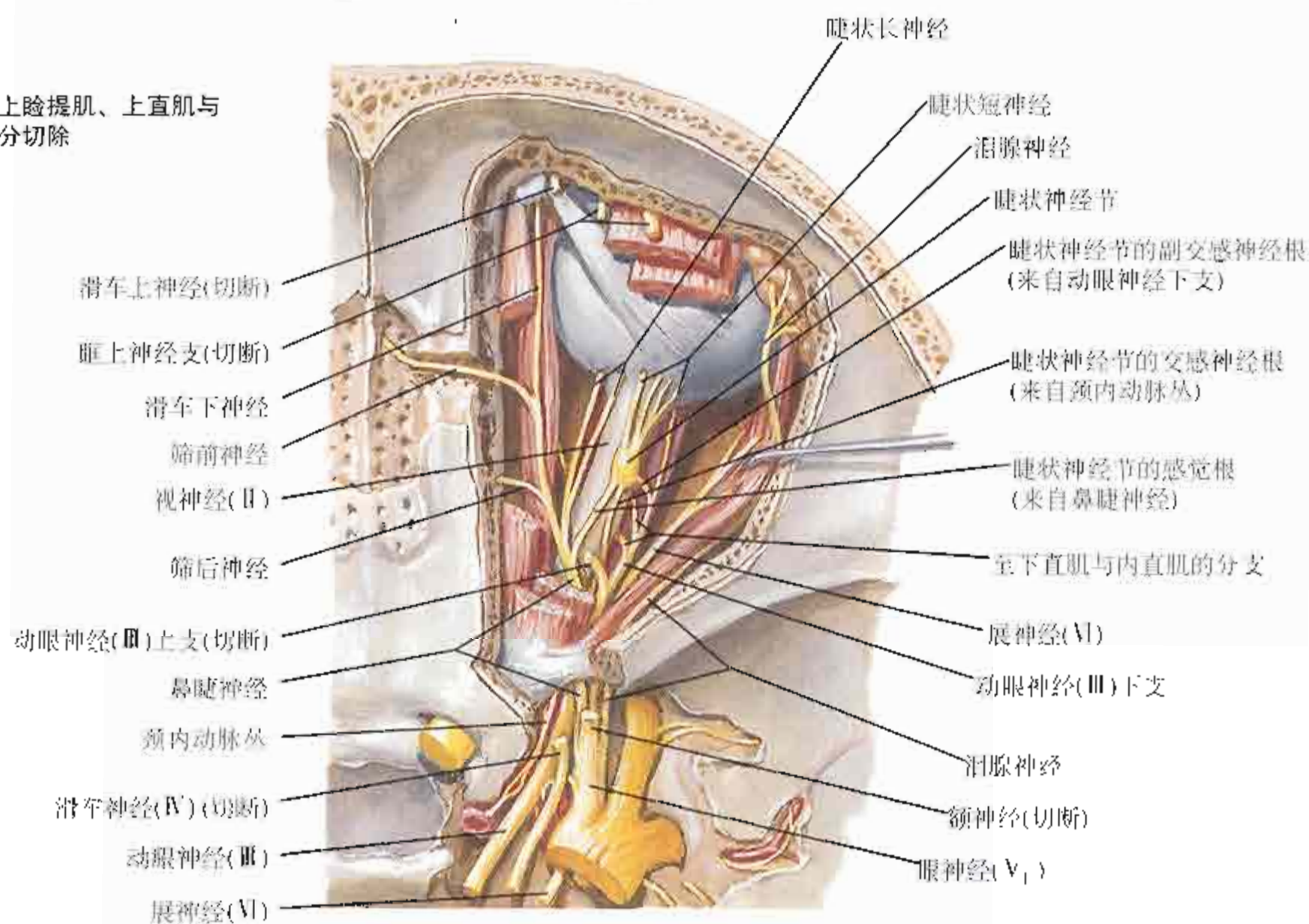


眶的神经

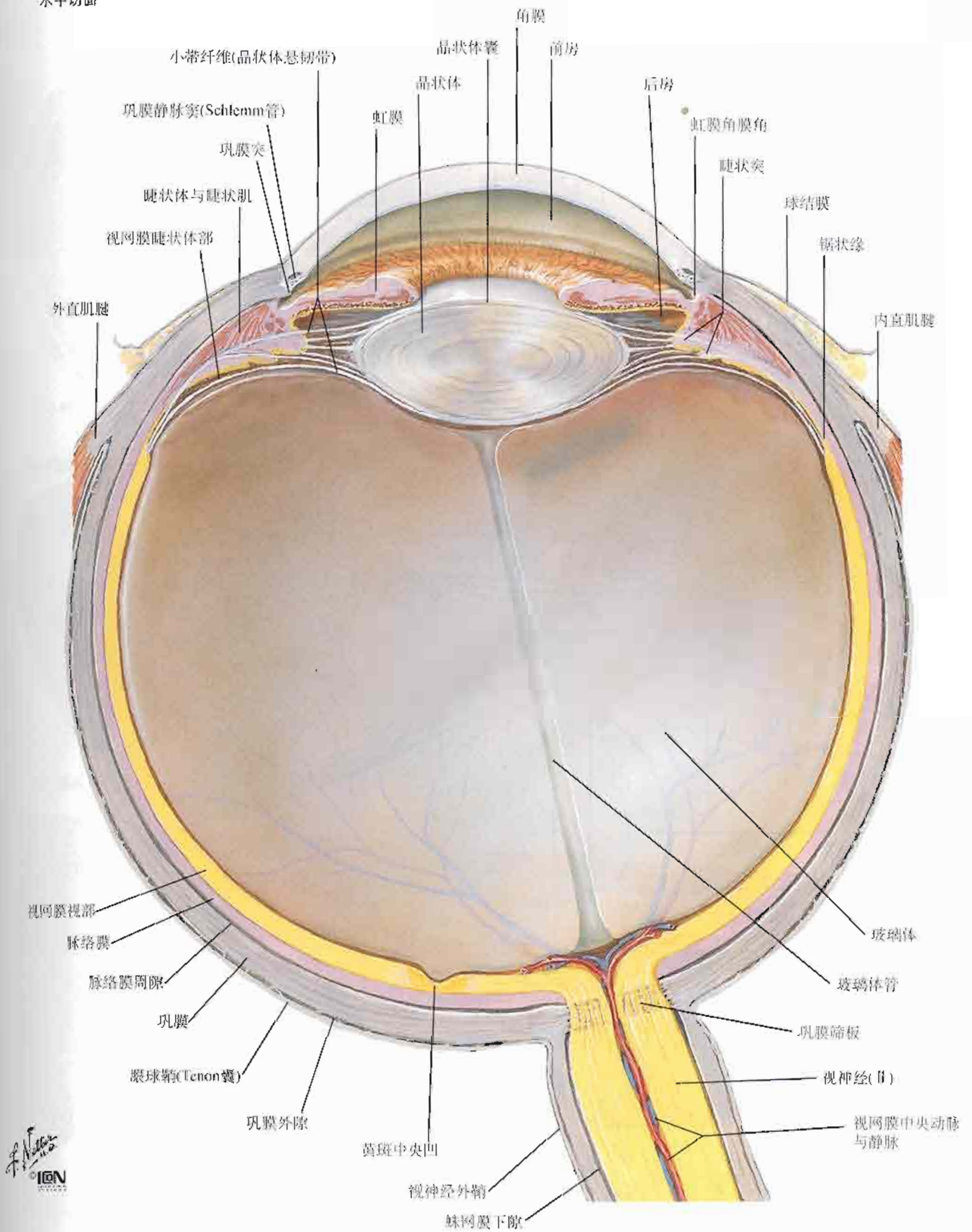
参见图41、115、126



上面观：上睑提肌、上直肌与上斜肌部分切除



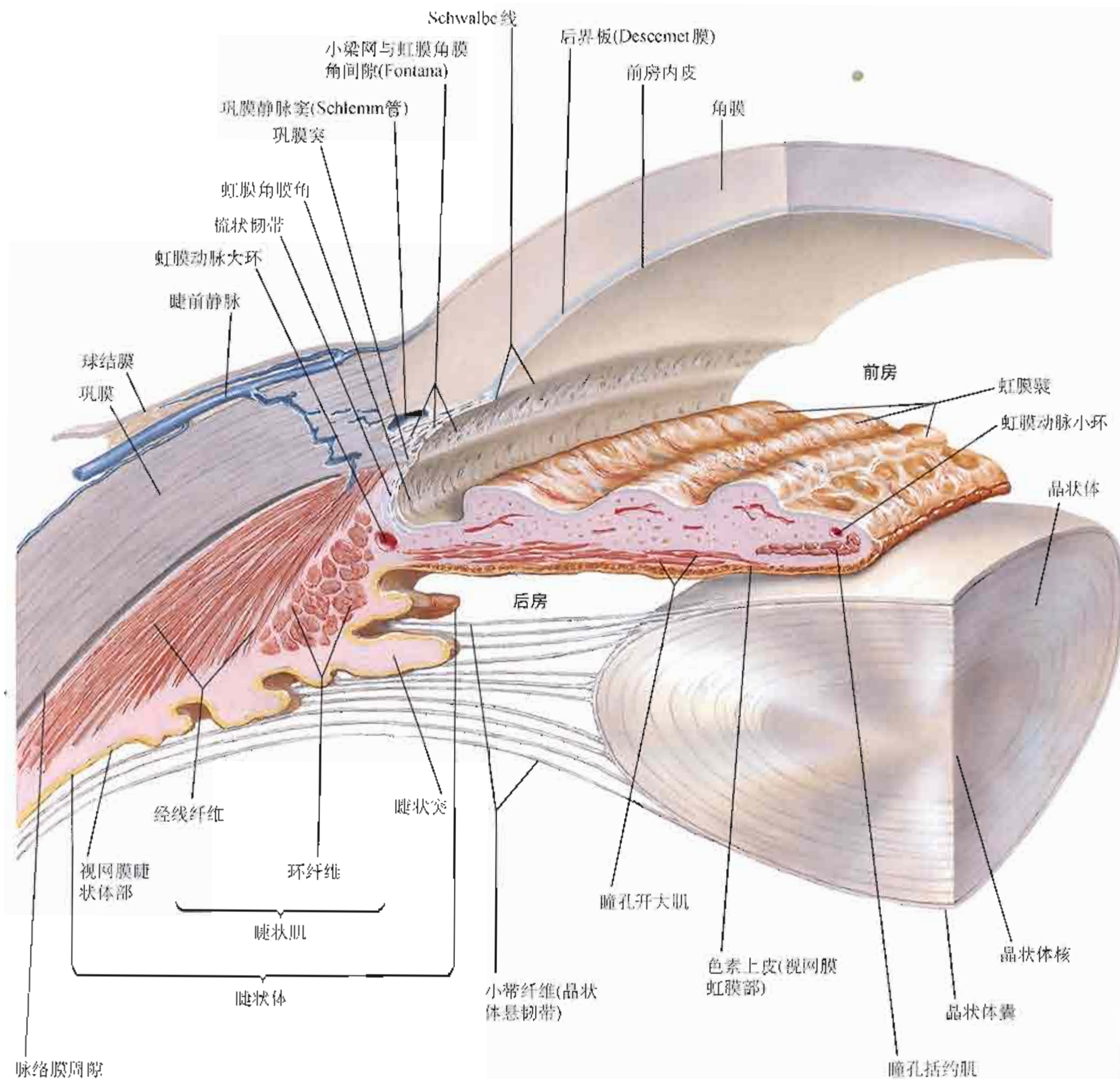
水平切面



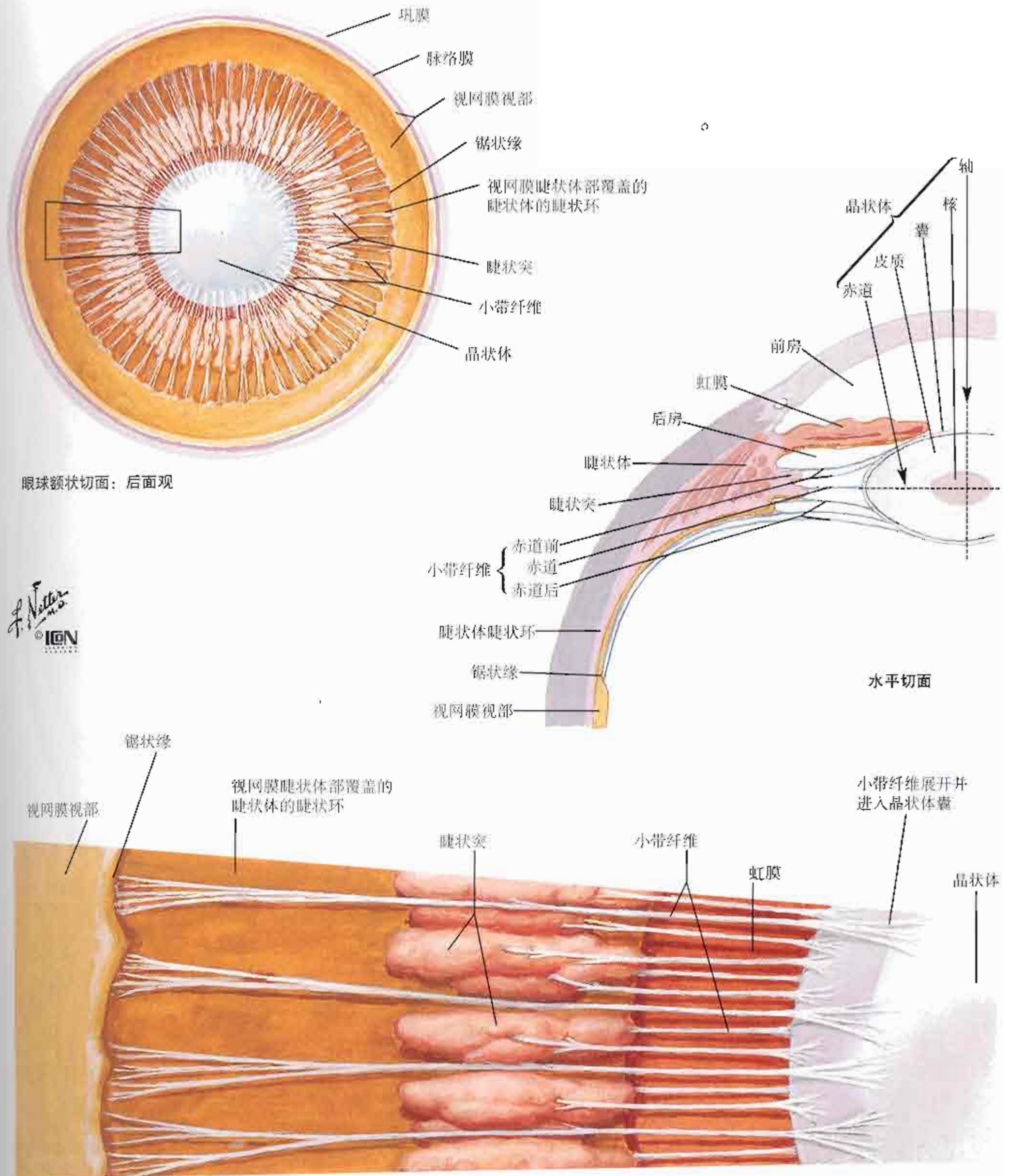
眶及其内容

图83

眼前房与后房



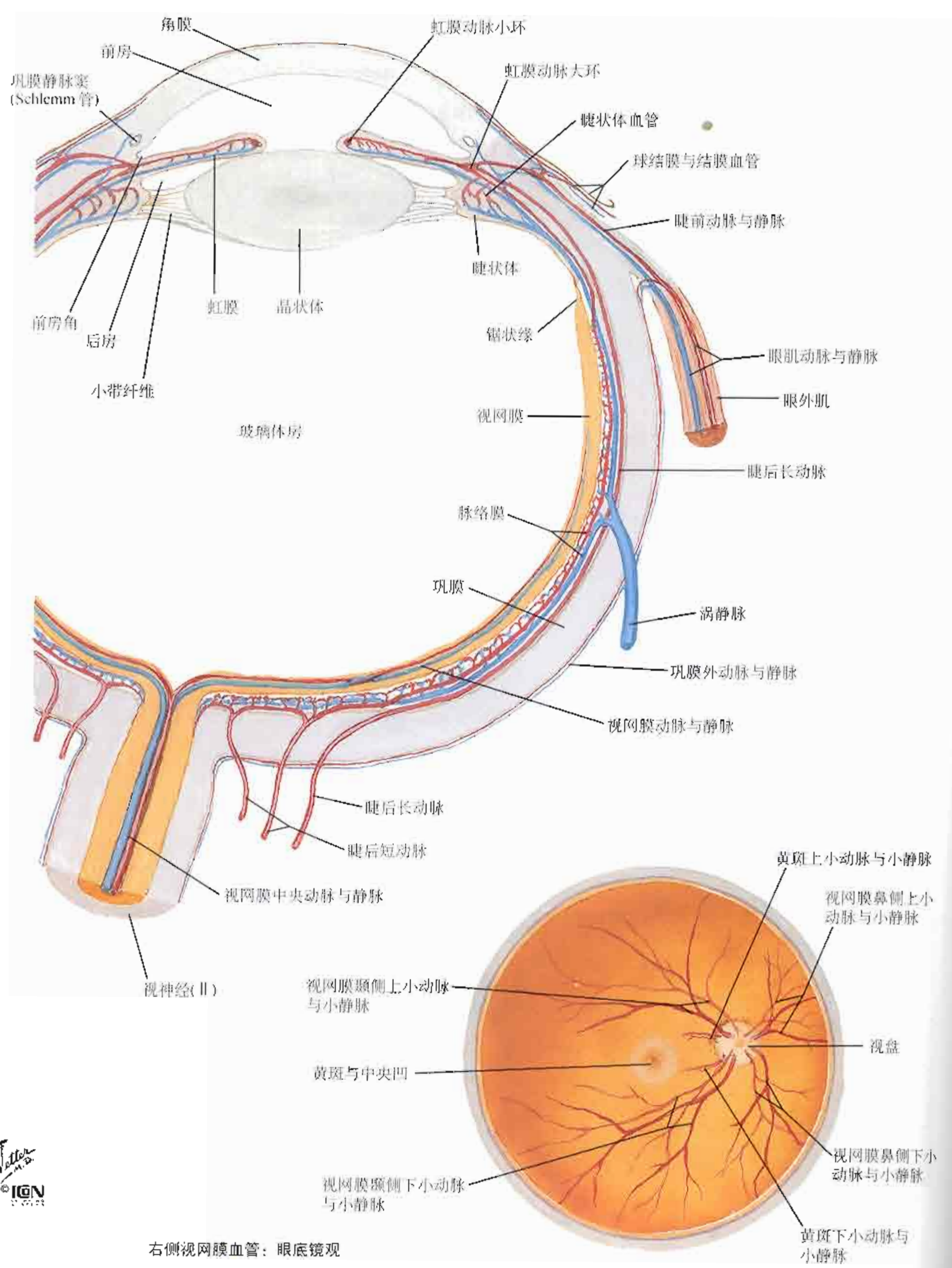
注：需要说明的是仅显示单层小带纤维，实际上纤维完整包绕晶状体



左上图圈出部位放大图 (半示意图)

眼内动脉与静脉

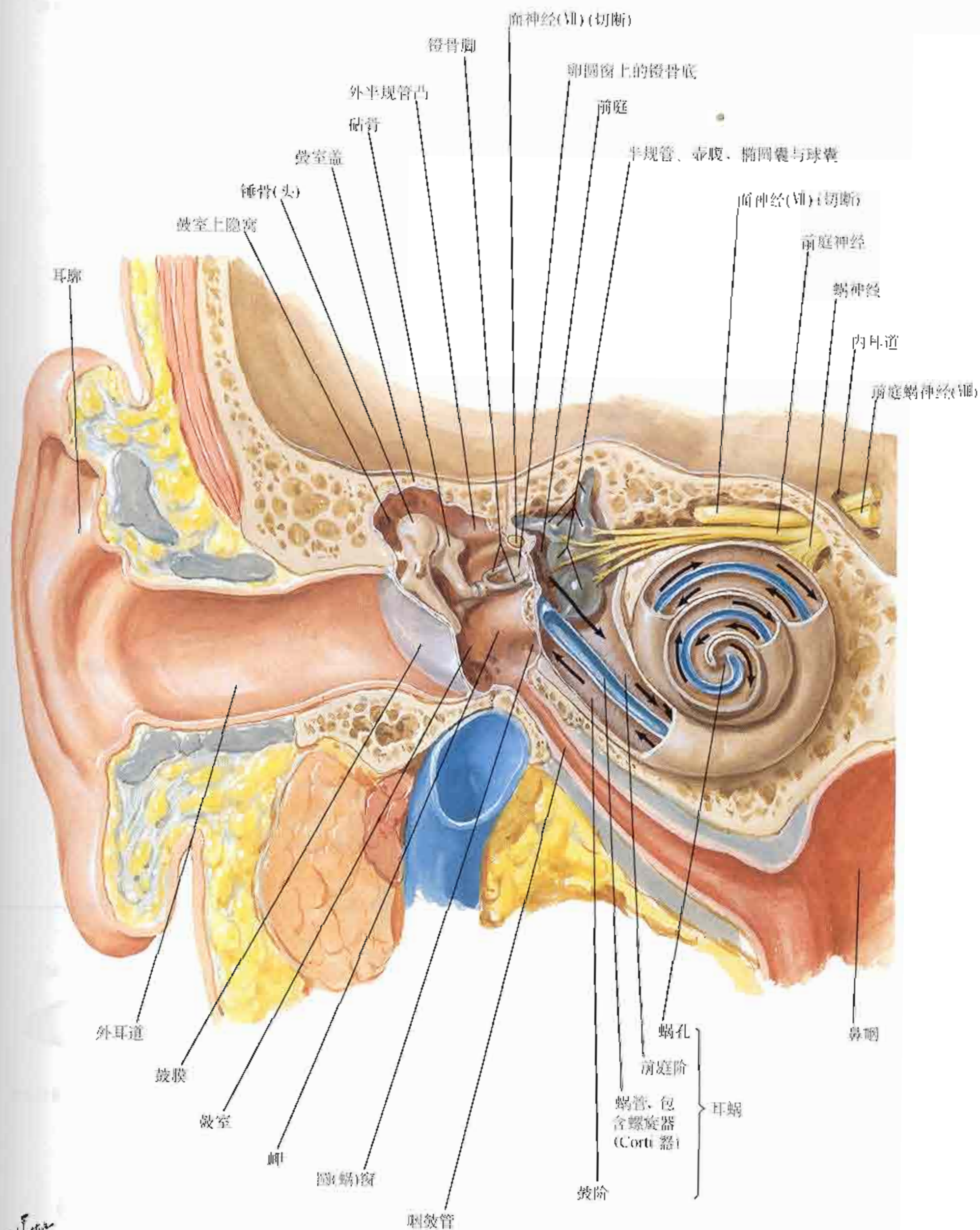
参见图81



右侧视网膜血管：眼底镜观

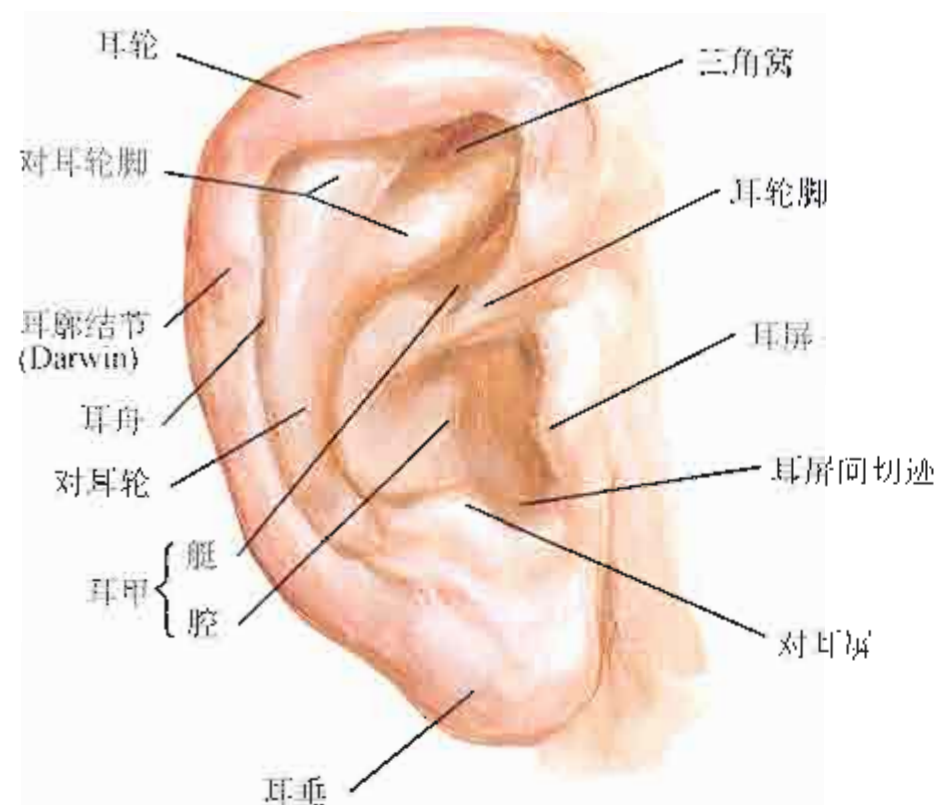
F. Netter M.D.
© 1994

额状切面

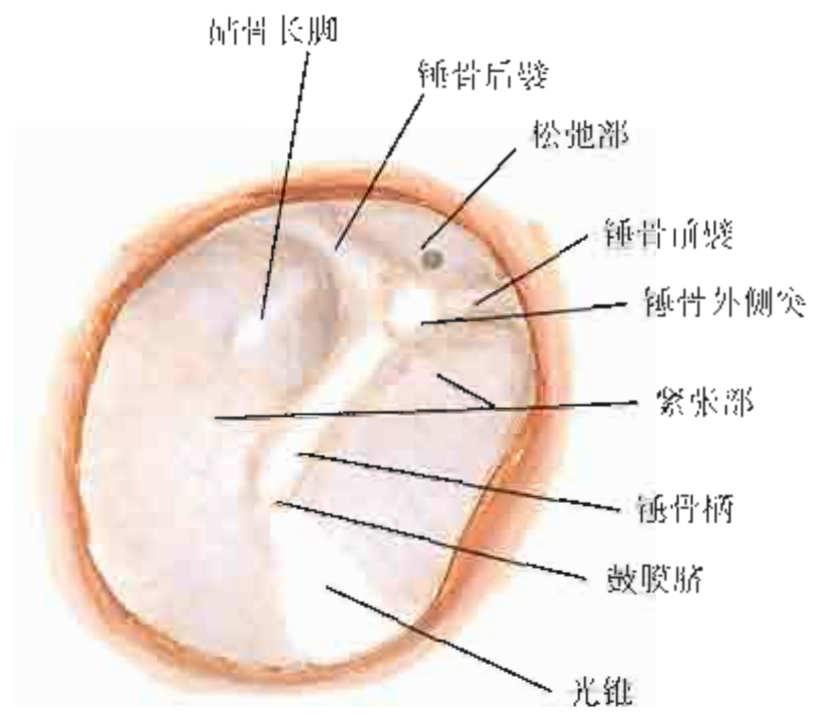


注: 图中箭头示声波传播途径

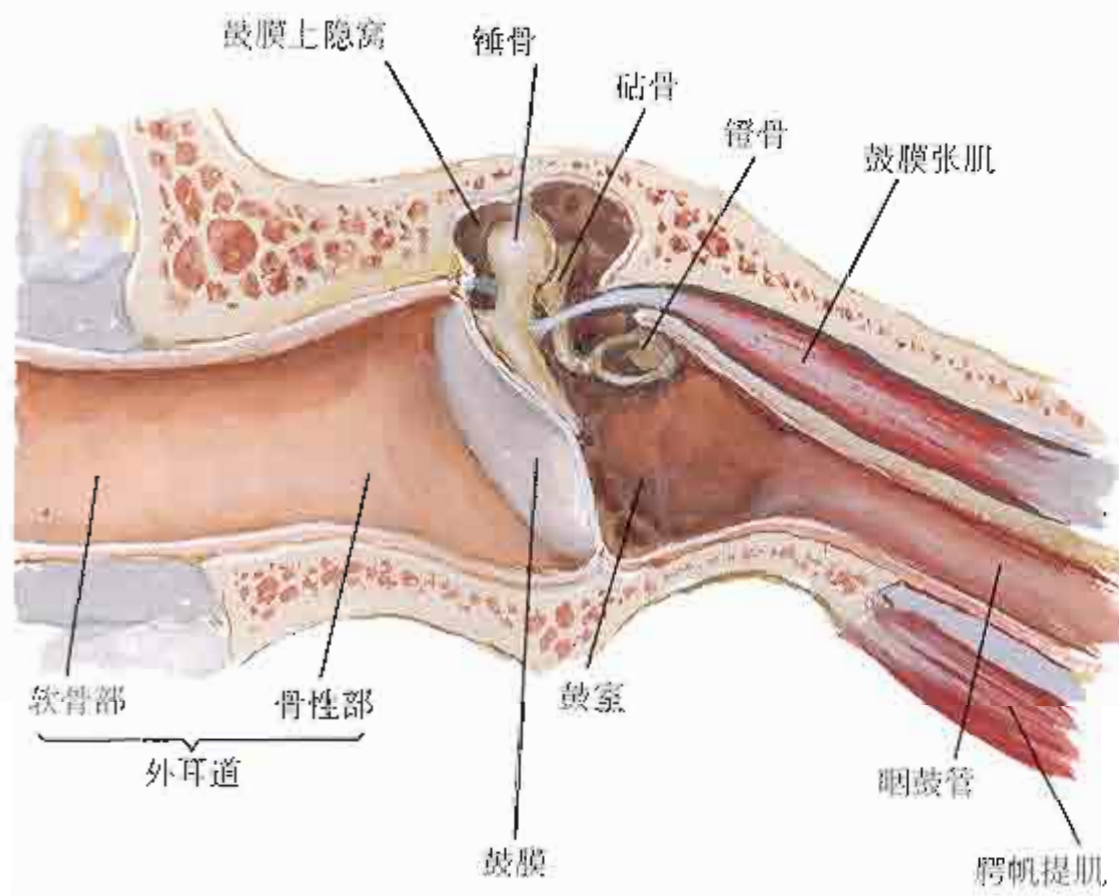
外耳与鼓室



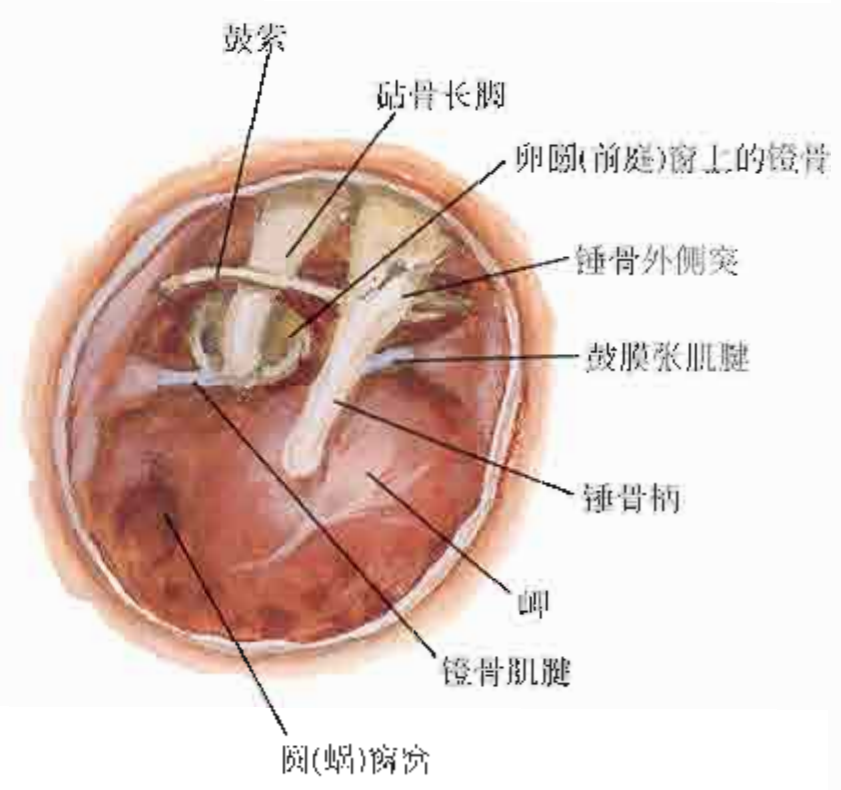
右耳



通过耳镜观察到的右耳鼓膜

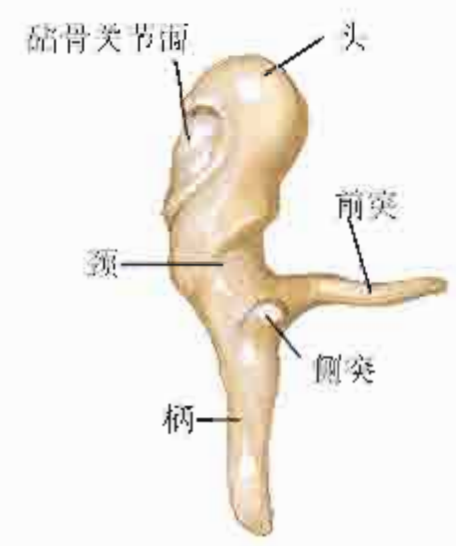

外耳道和中耳的冠状斜切面

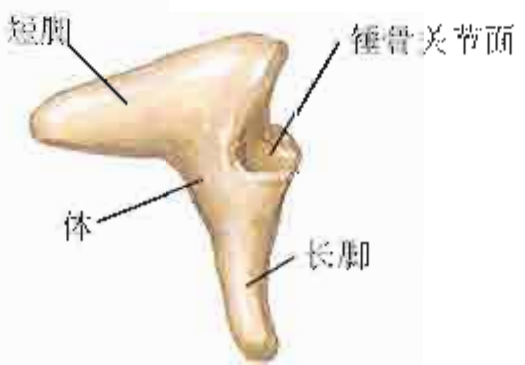


鼓膜切除后观察鼓室

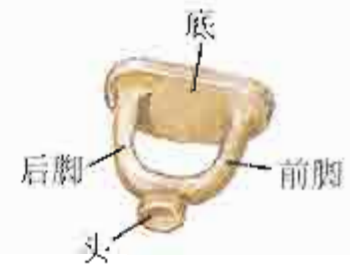听小骨



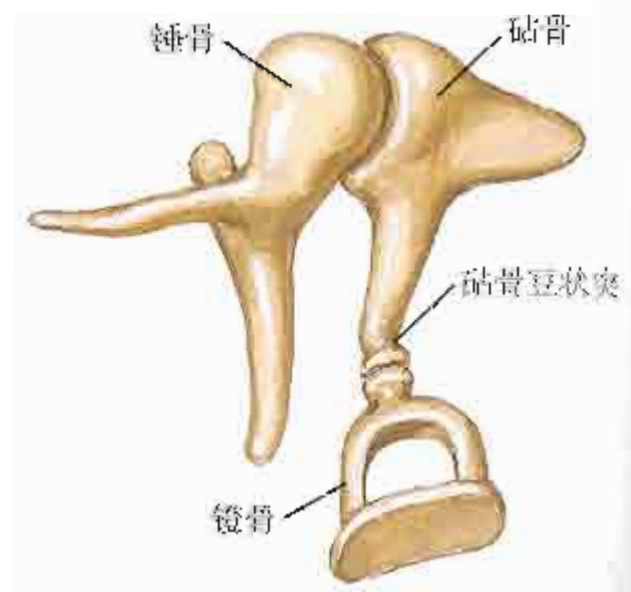
锤骨侧面观



砧骨：外侧面观



镫骨：上外侧面观

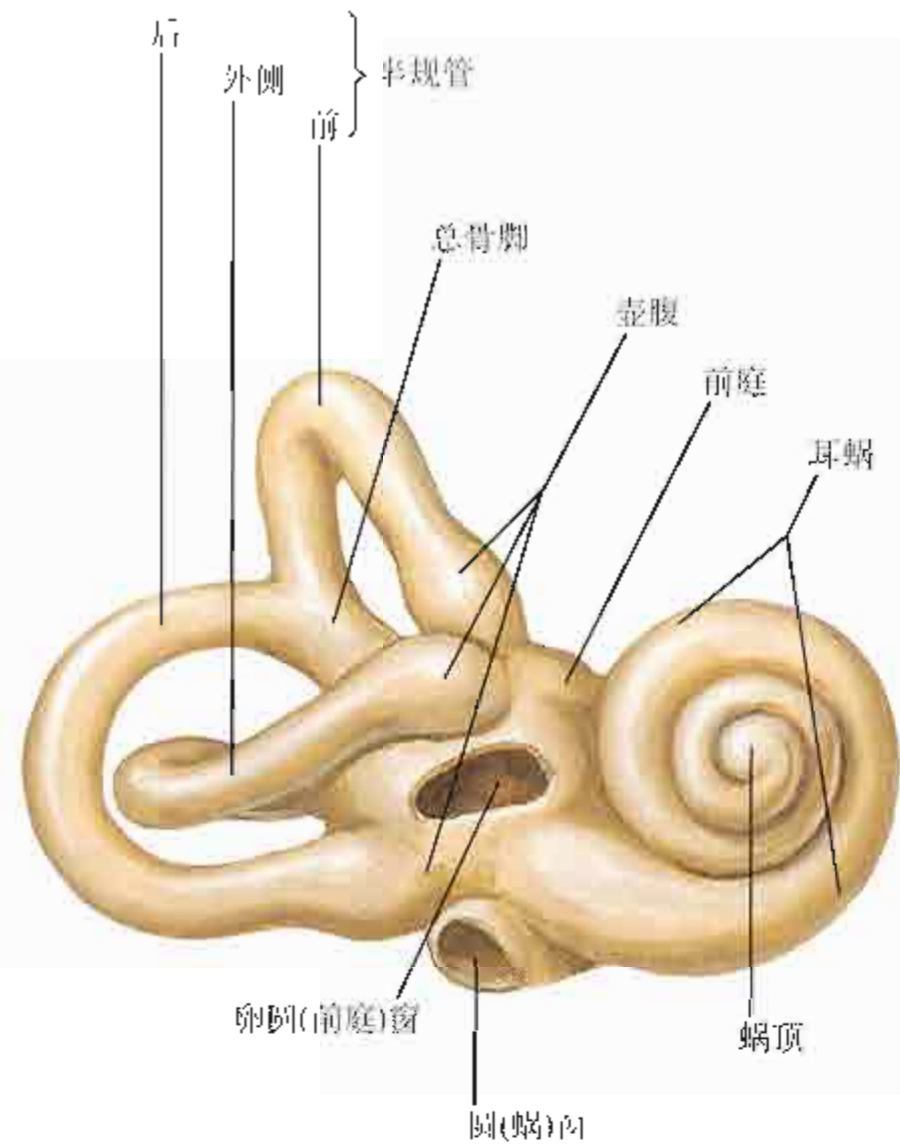


听小骨连接：内侧面观

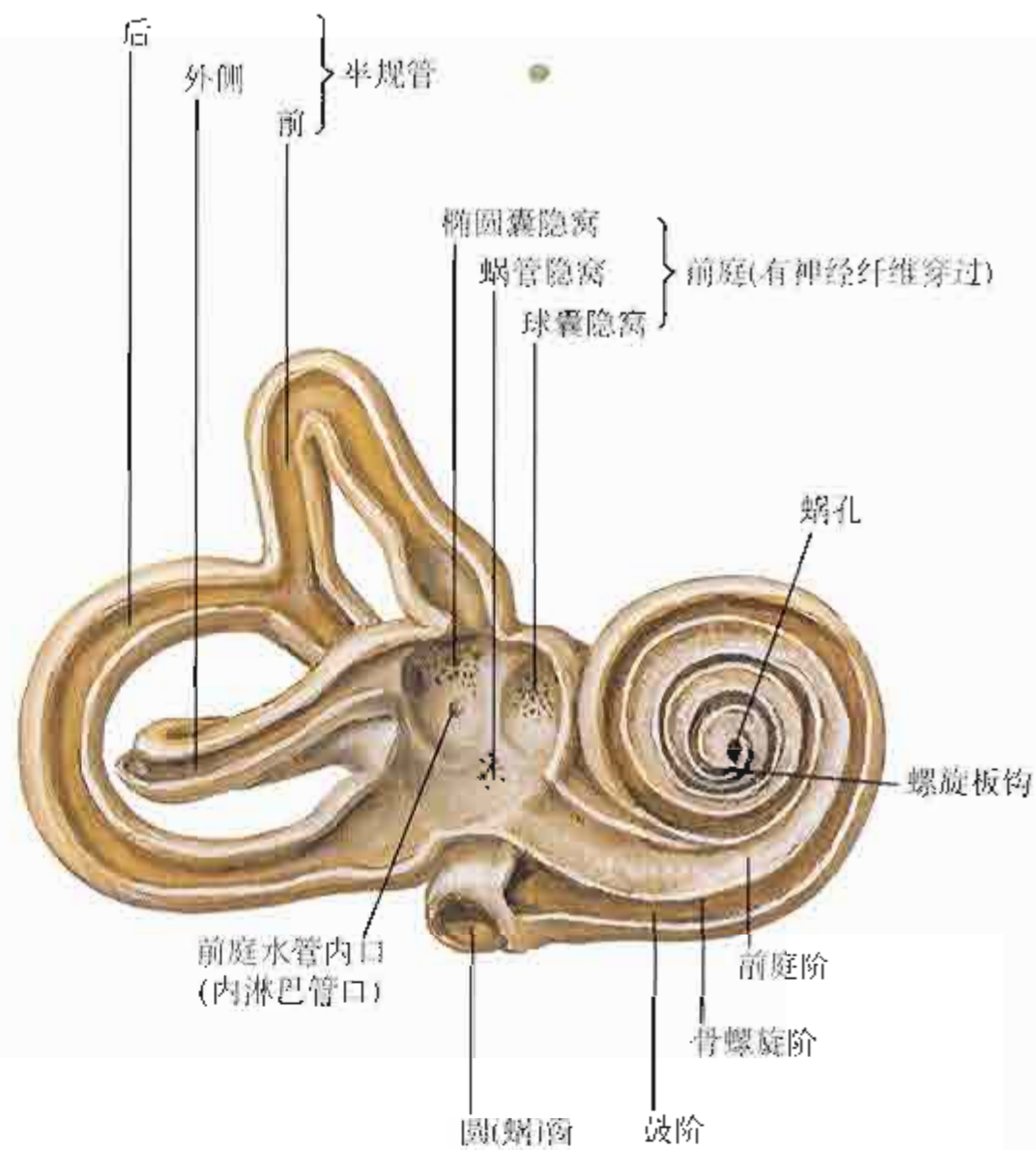
骨迷路与膜迷路

参见图118

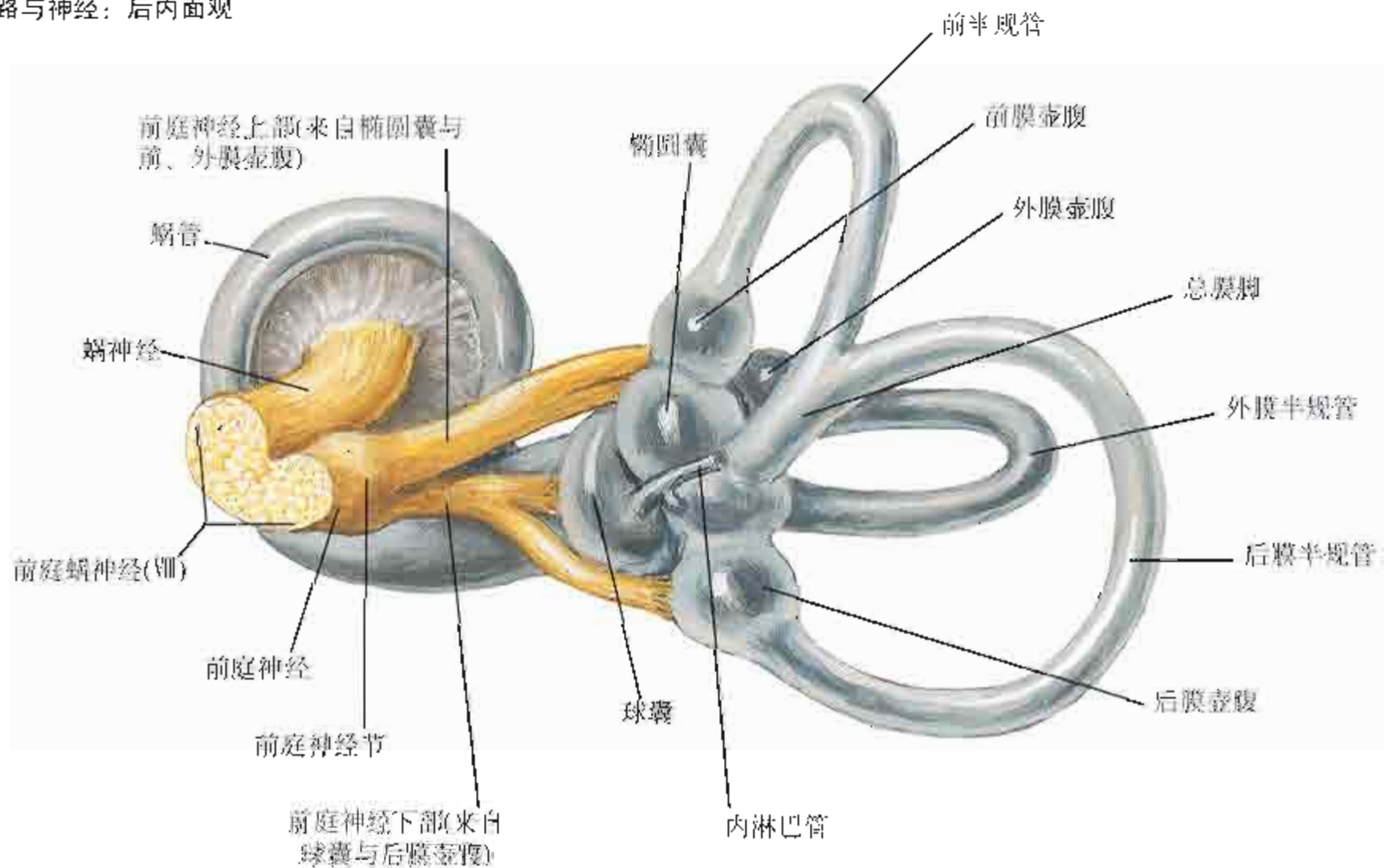
右侧骨迷路(Otic囊)的前外侧面观:
去掉周围多孔骨组织



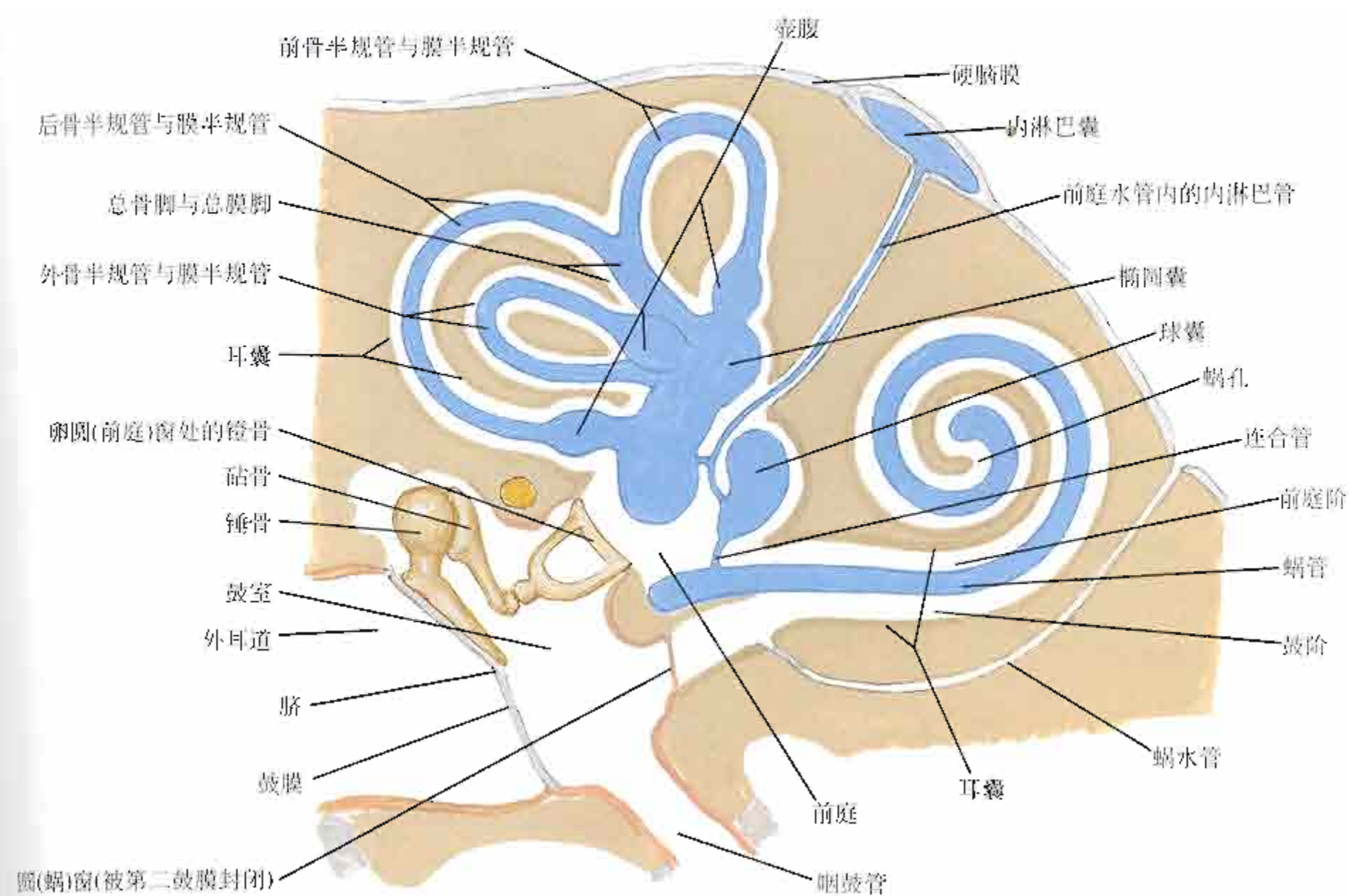
右侧骨迷路: 膜迷路已去除



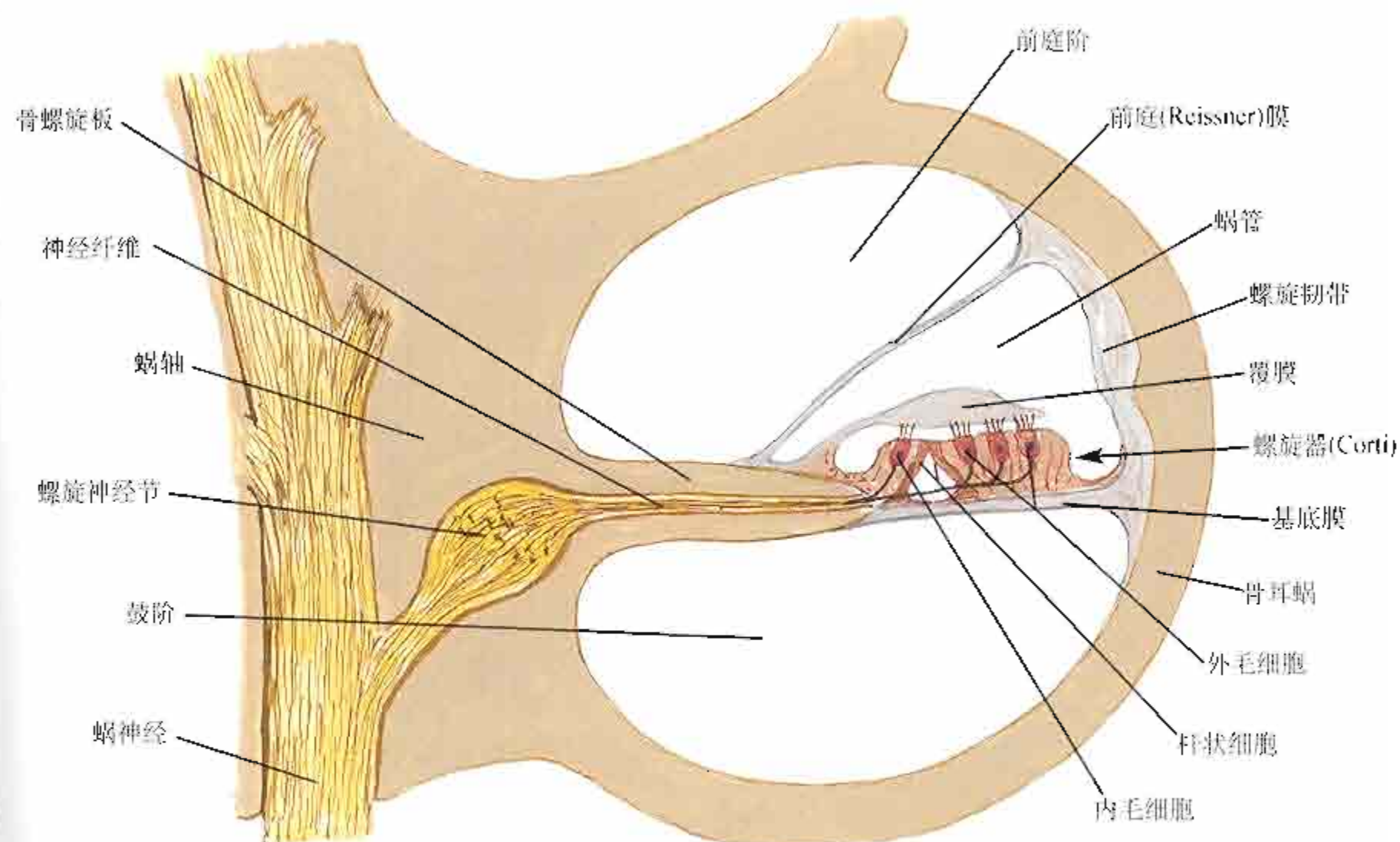
右侧膜迷路与神经: 后内面观



骨迷路与膜迷路: 示意图

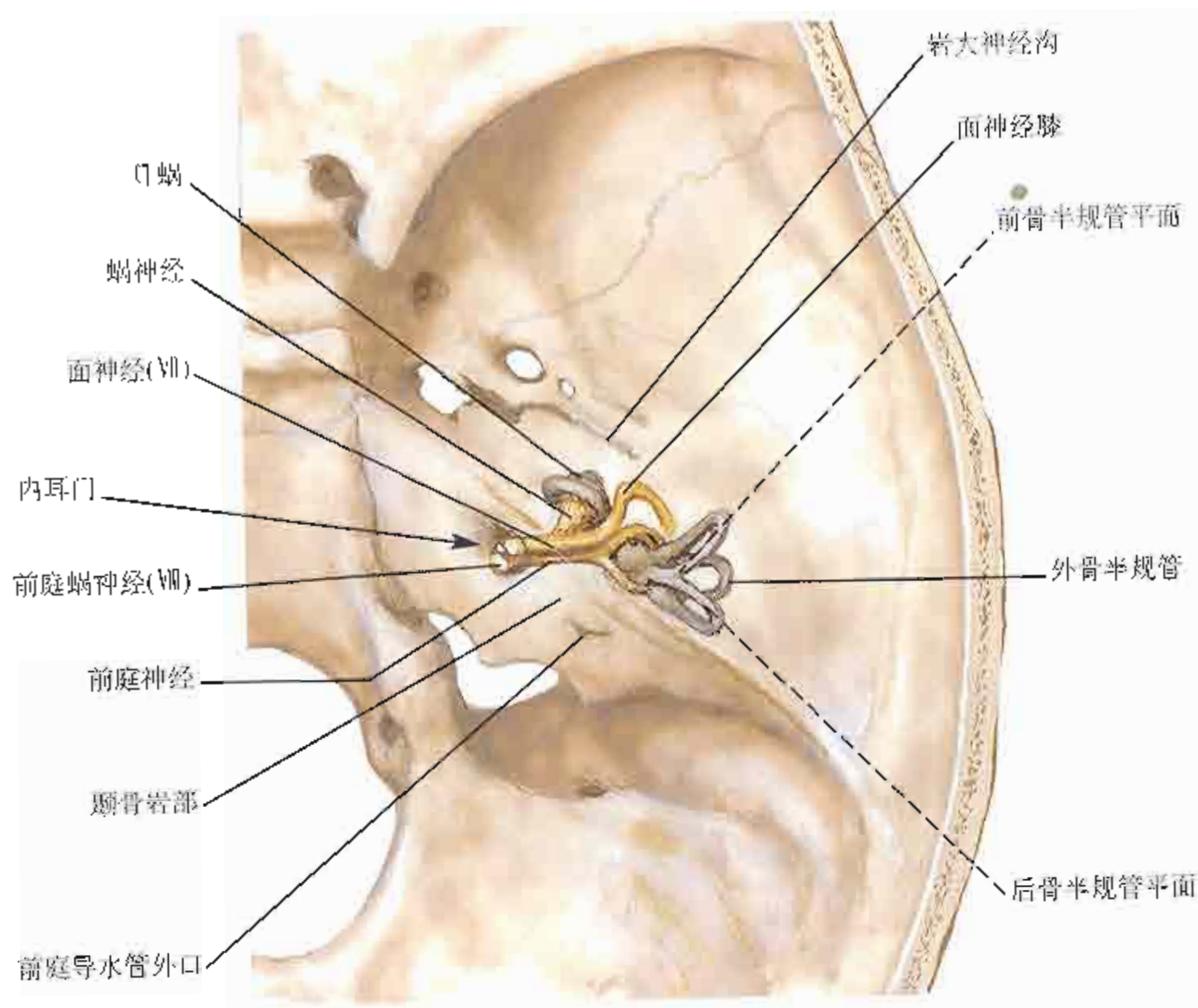


耳蜗弯曲处断面

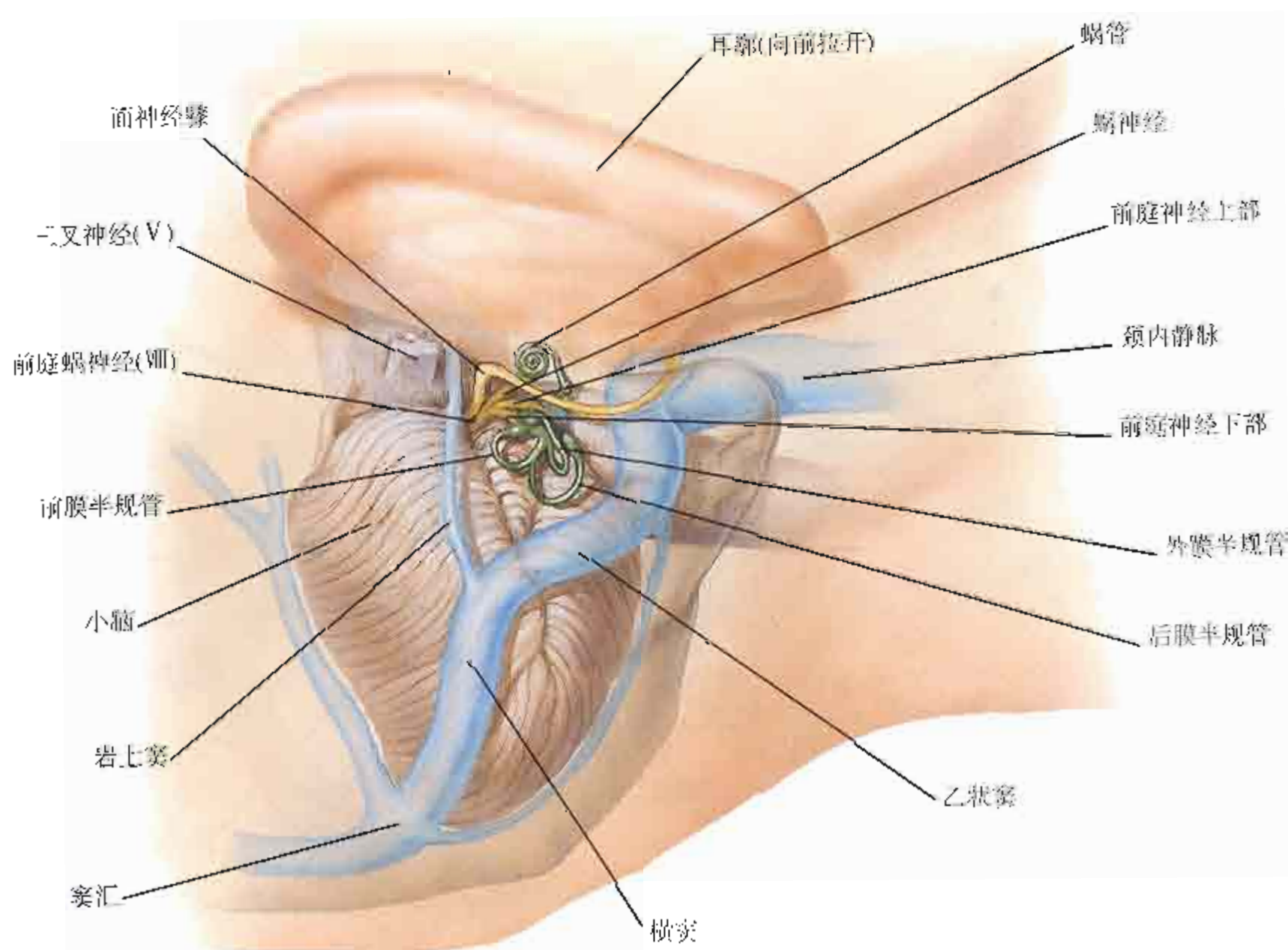


迷路在颅内的定位

颅底右侧骨迷路在上方的投影

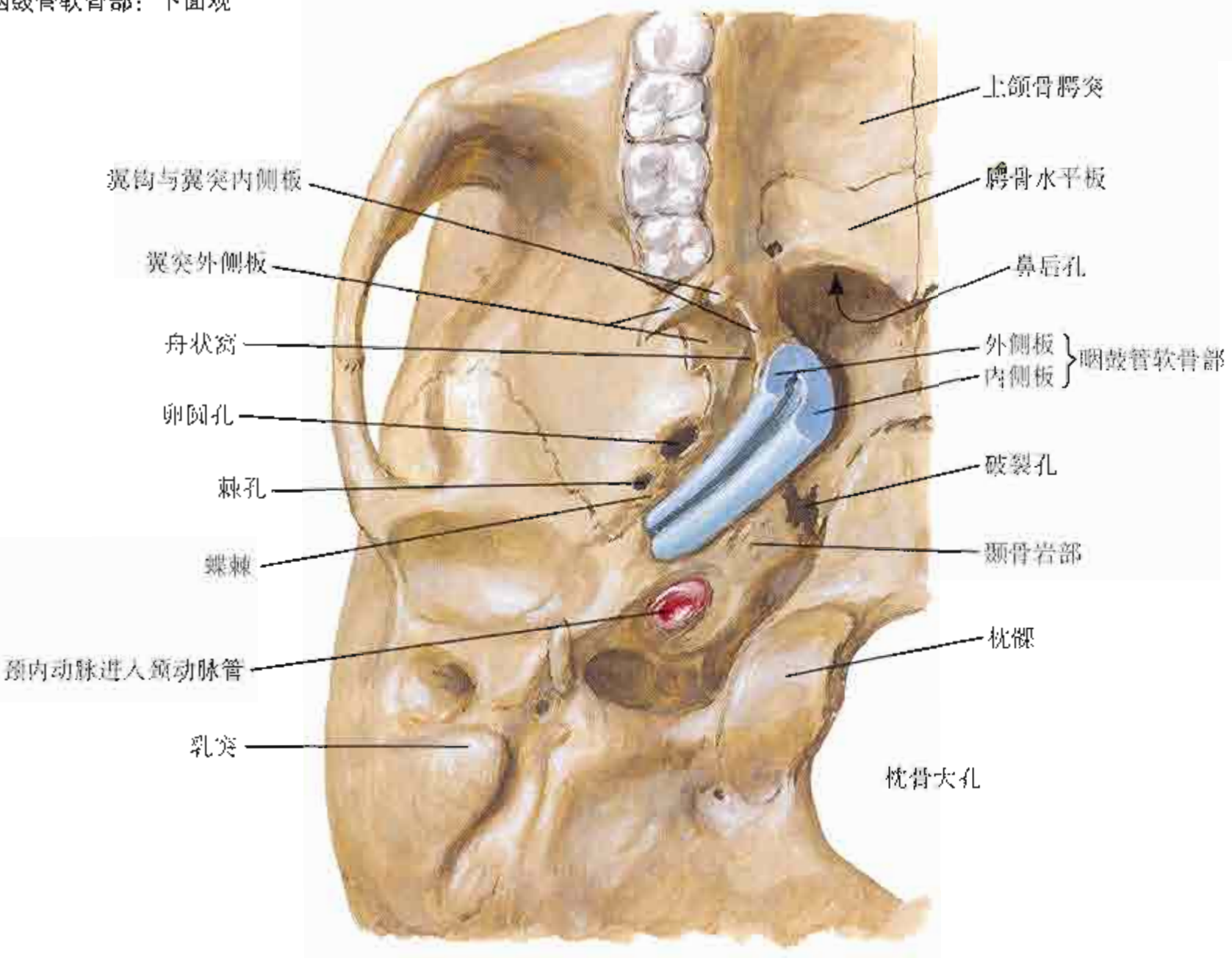


右侧膜迷路在外侧的投影

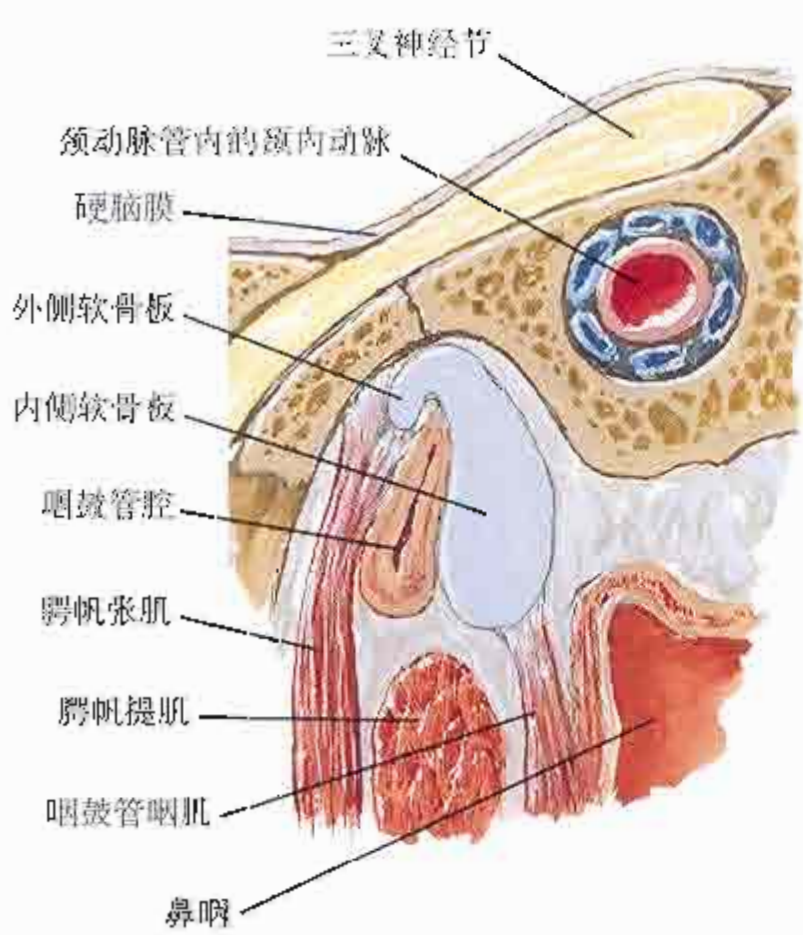


参见图48、51、61

颅底咽鼓管软骨部：下面观

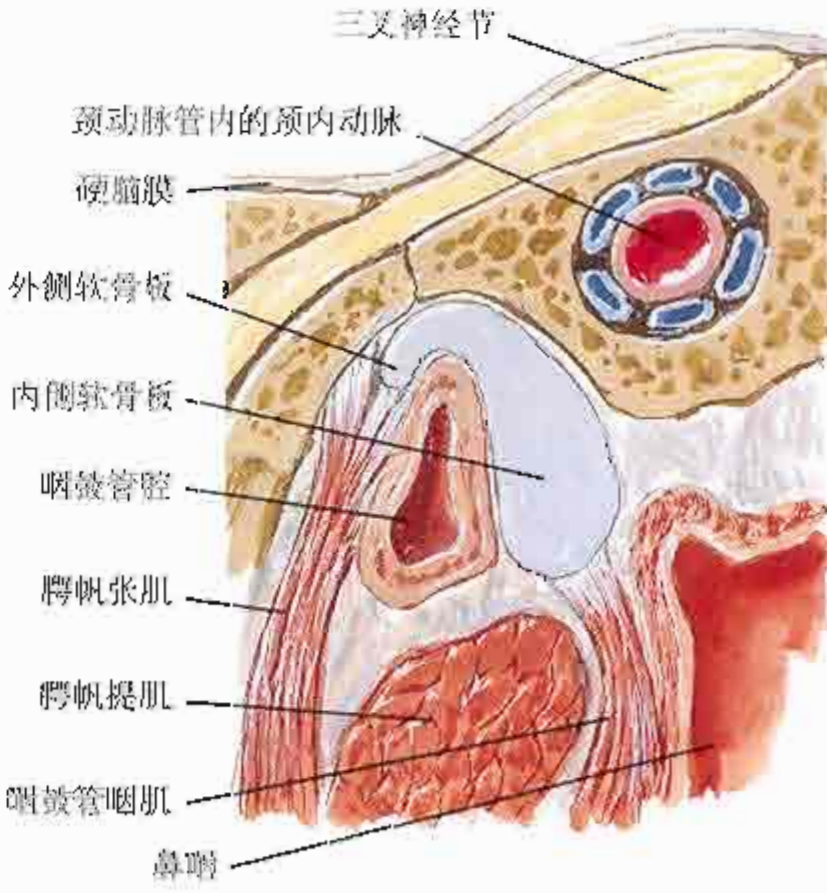


通过封闭的咽鼓管软骨部切面



咽鼓管被软骨的弹性回缩、组织肿胀以及咽鼓管咽肌的紧张所封闭

通过开放的咽鼓管软骨部切面



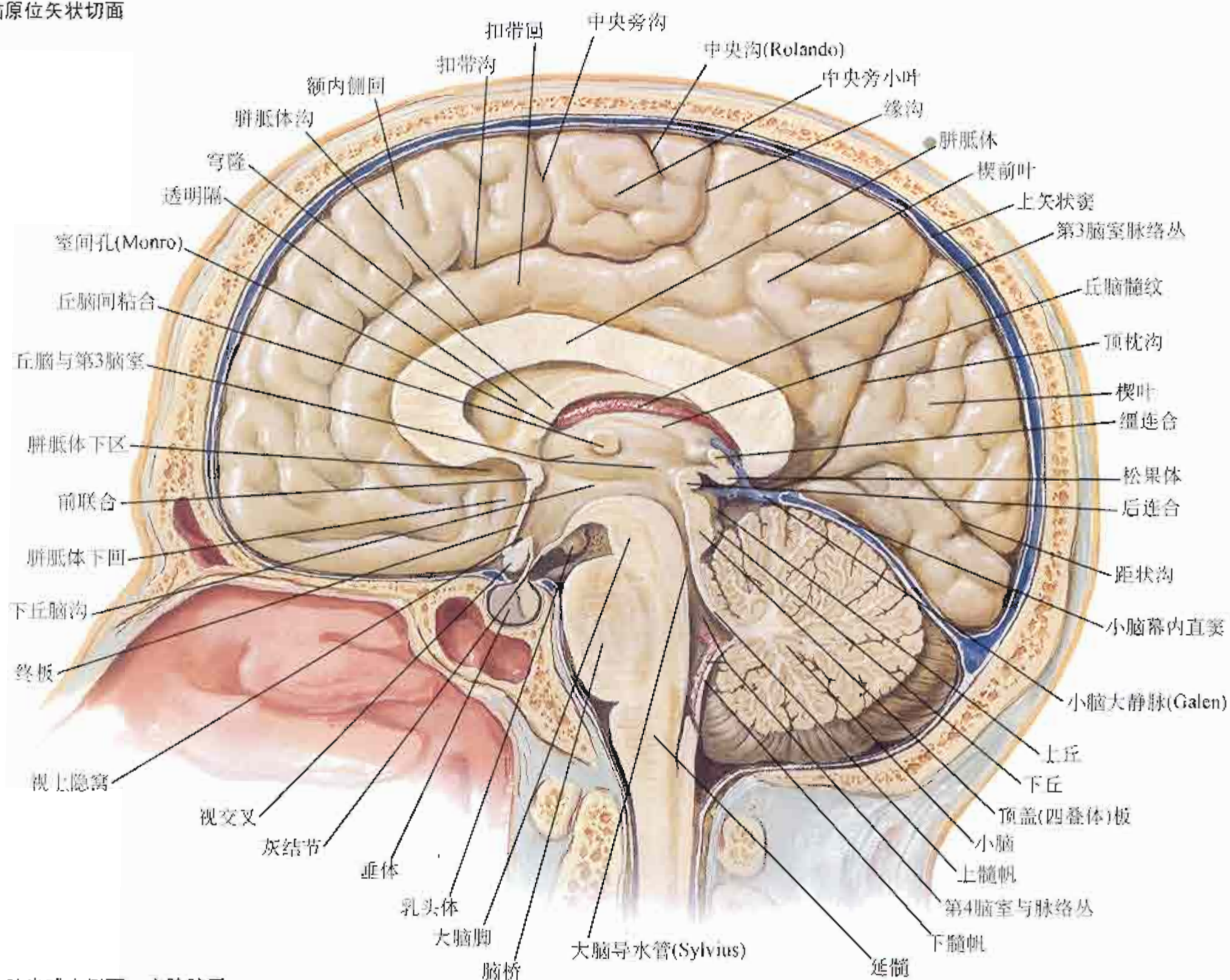
管腔开放主要是由于吞咽过程中腭帆张肌附着部向外侧牵拉管壁造成



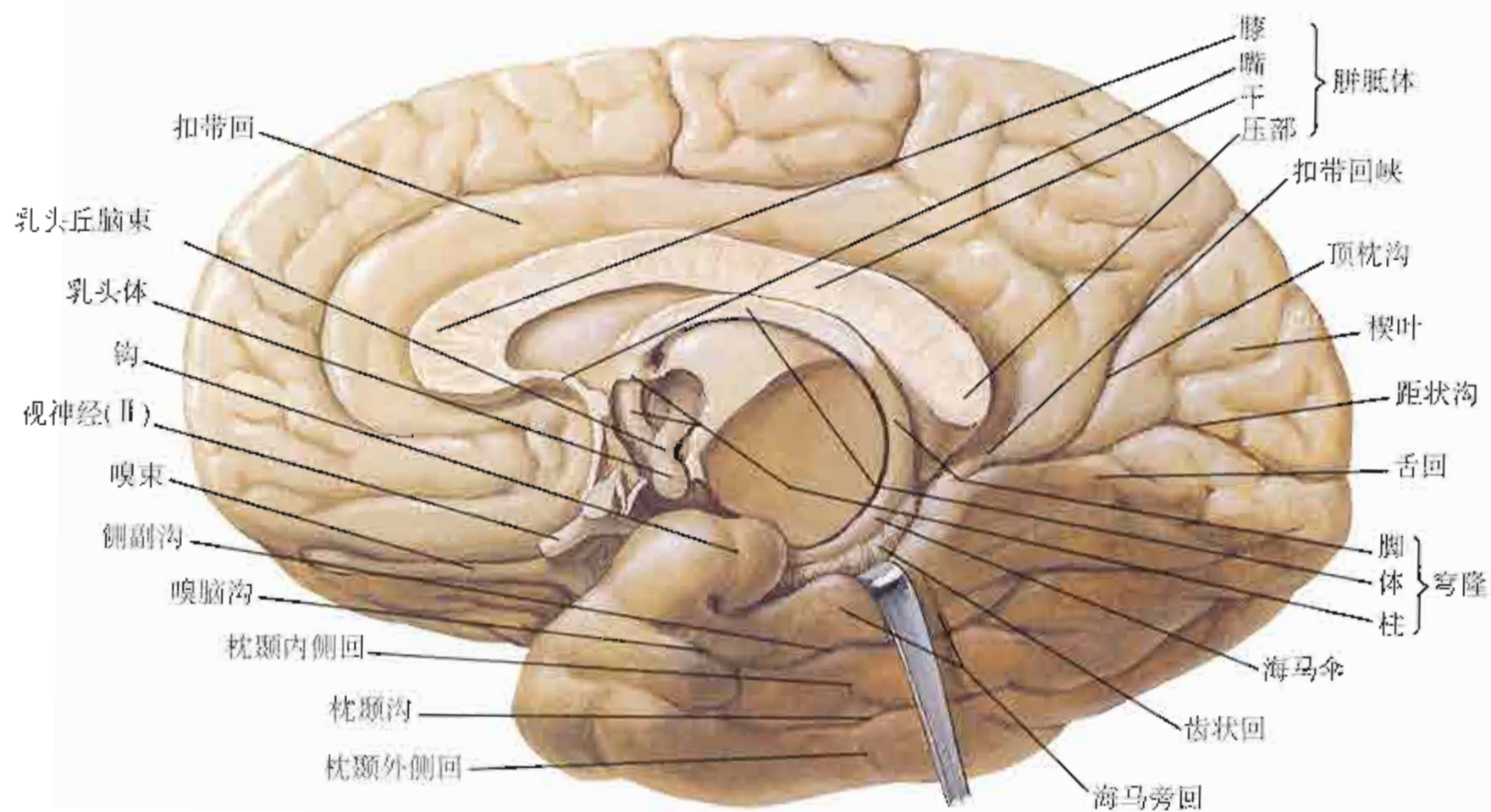
大脑：内侧面观

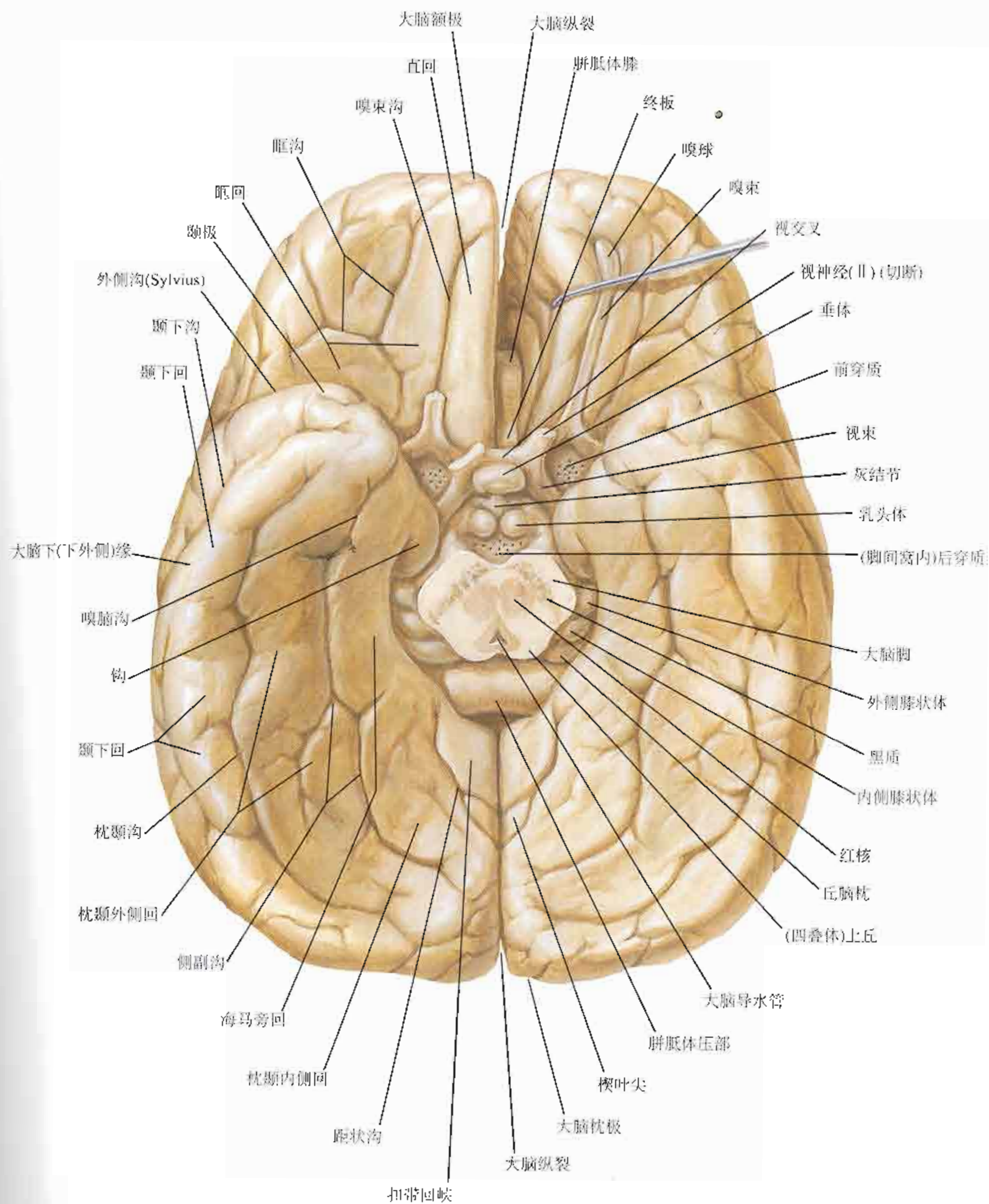
垂体参见图140

脑原位矢状切面



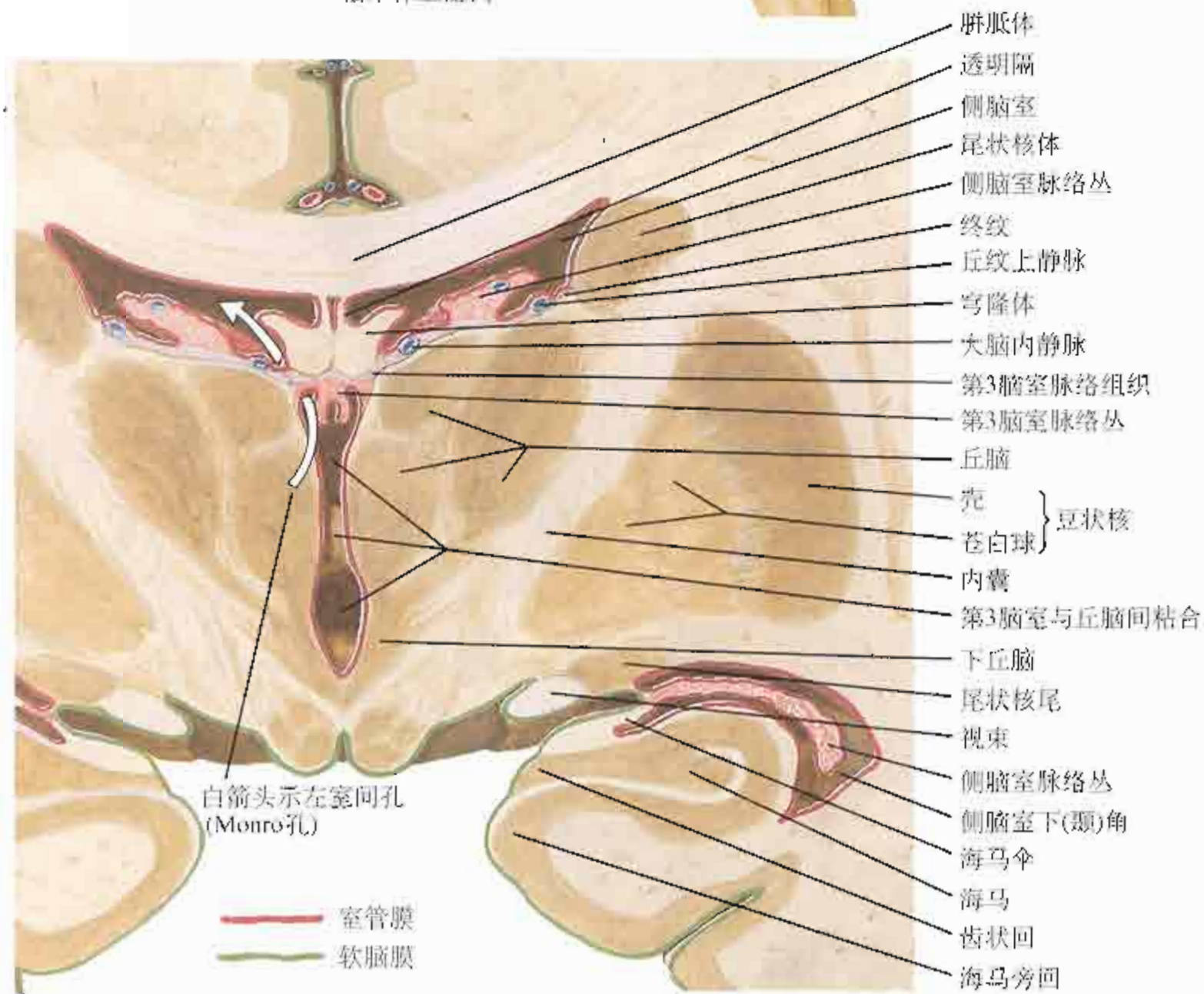
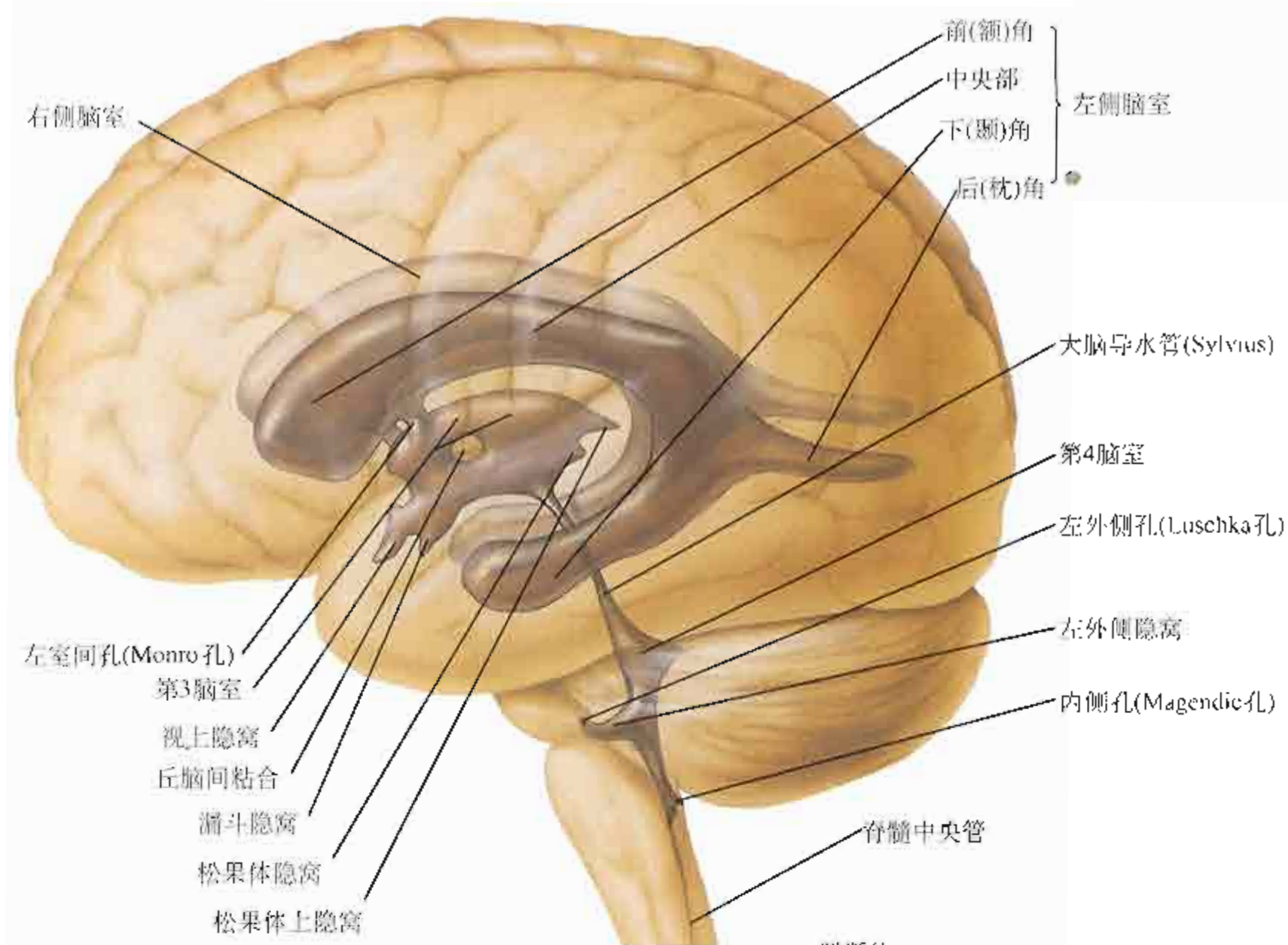
大脑半球内侧面：去除脑干





脑室

左外侧面投影观



脑冠状切面：后面观



运动科学网站



运动科学网站



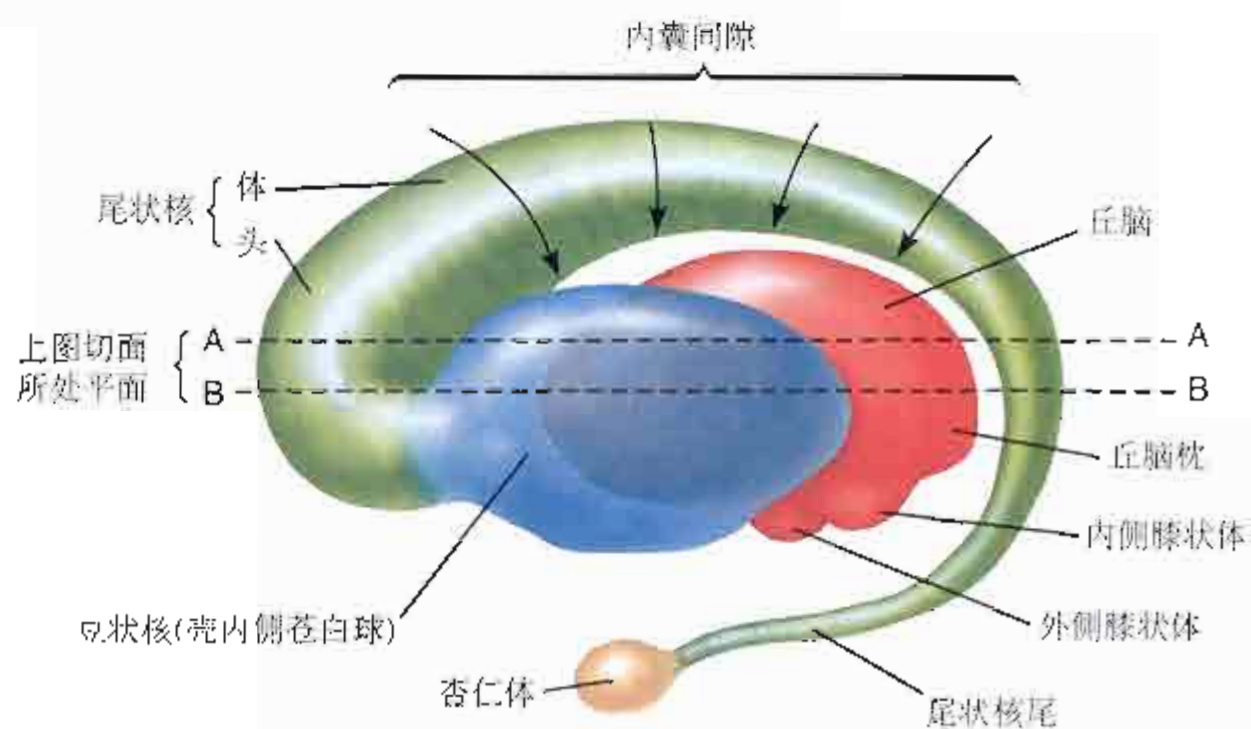
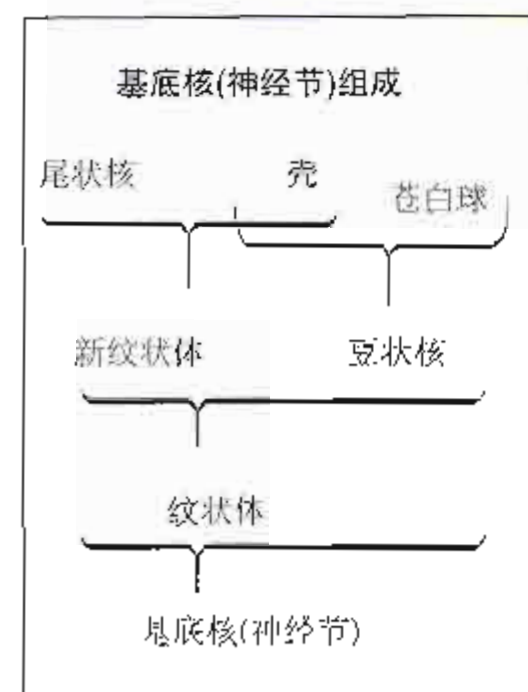
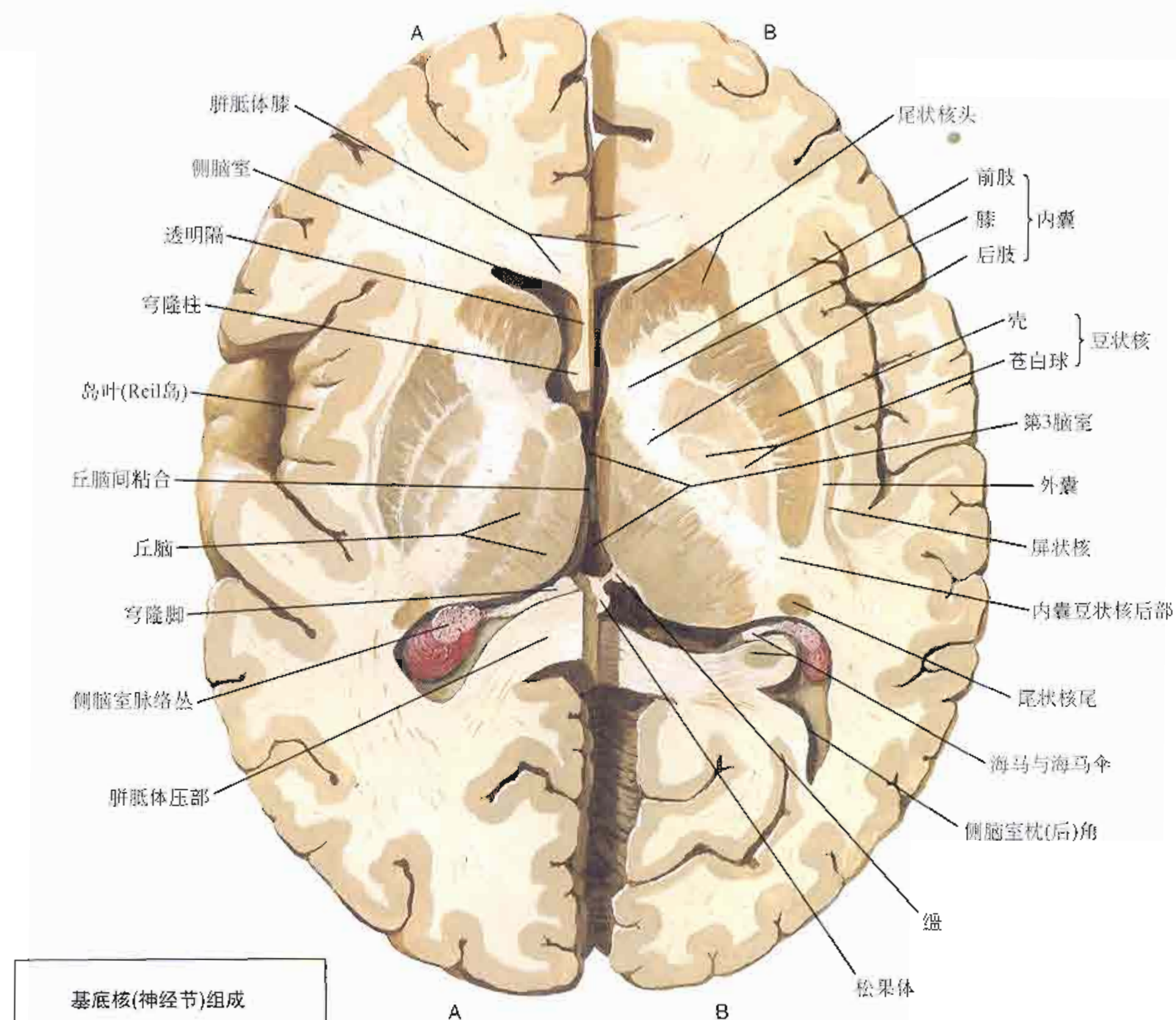
运动科学网站

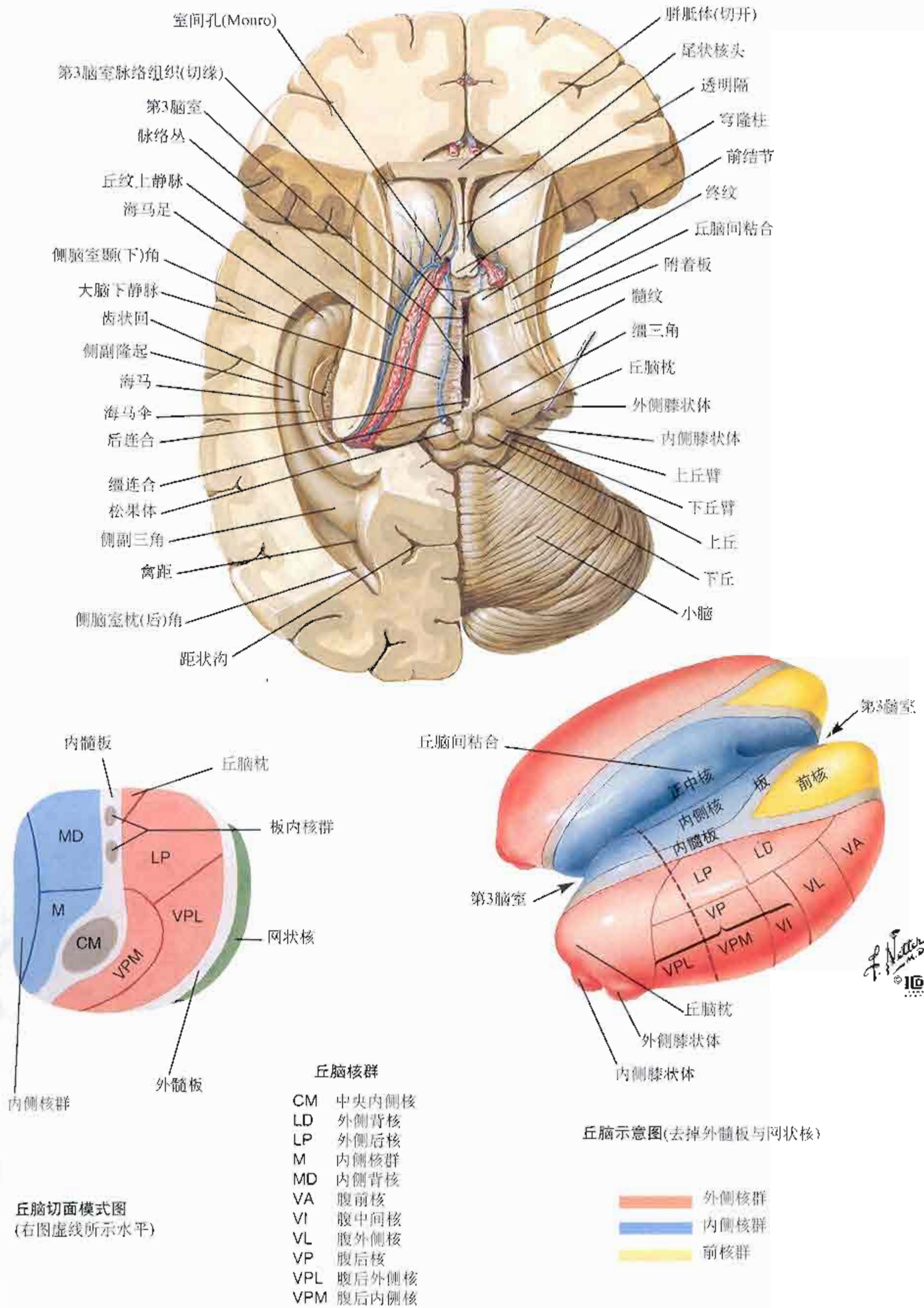


运动科学网站
www.vo2maxcn.com

基底核 (基底神经节)

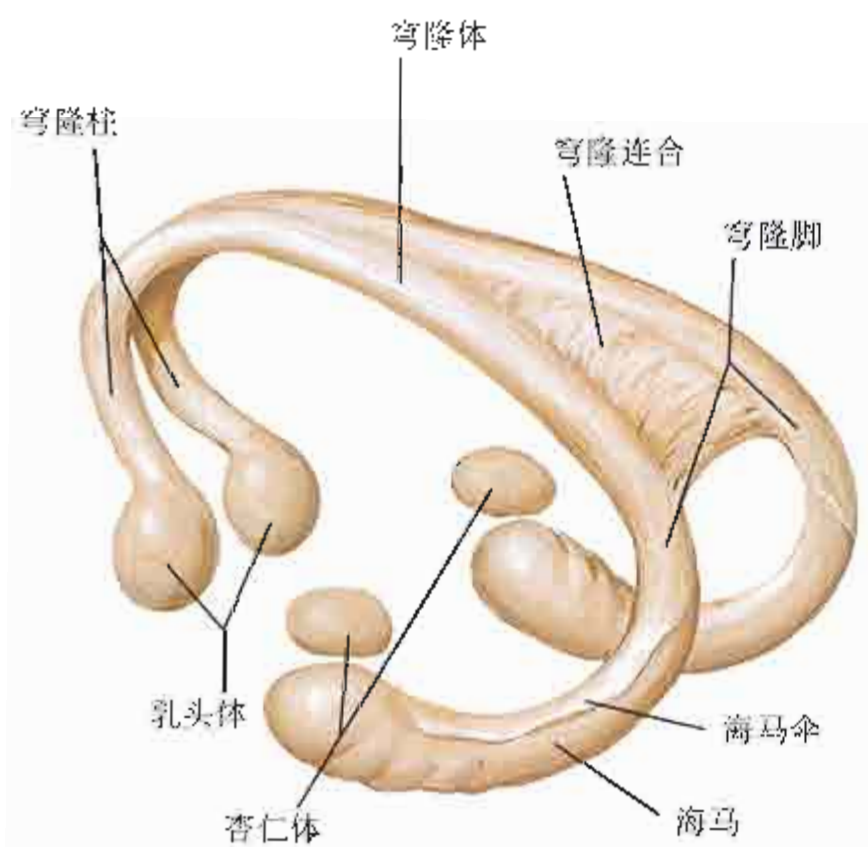
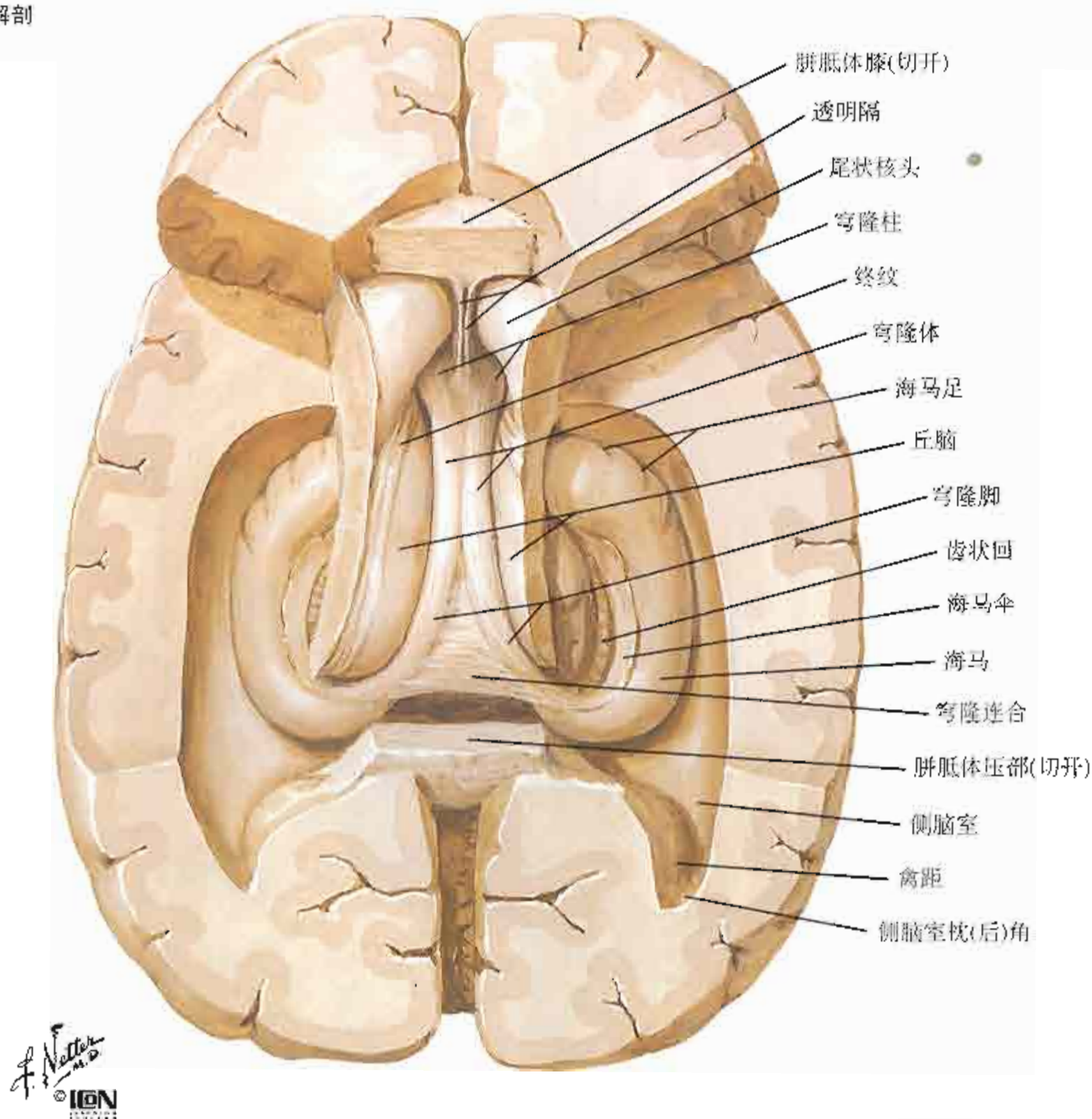
大脑水平切面



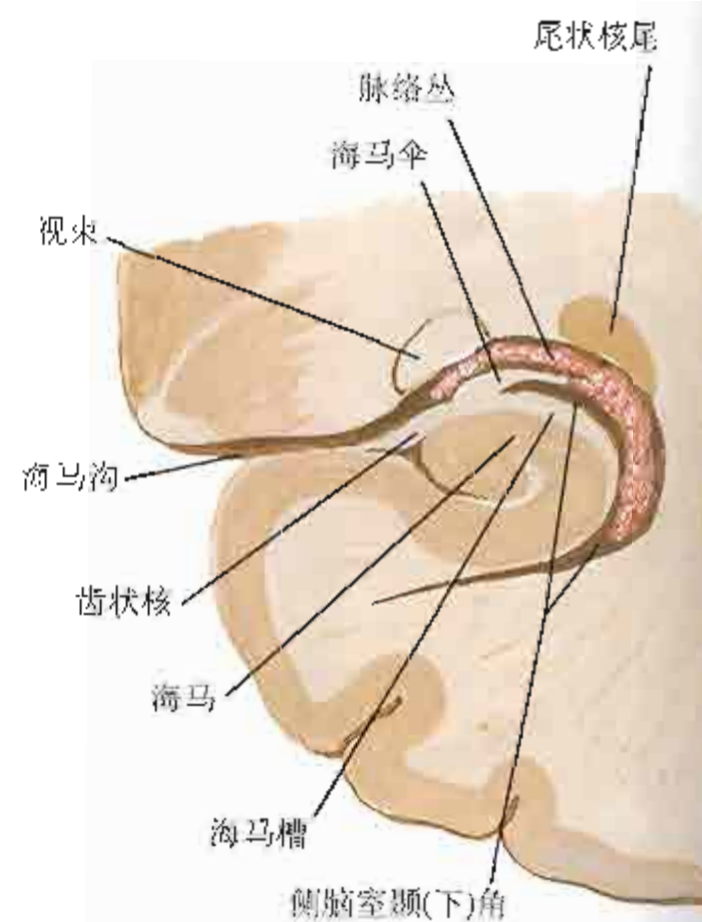


海马与穹隆

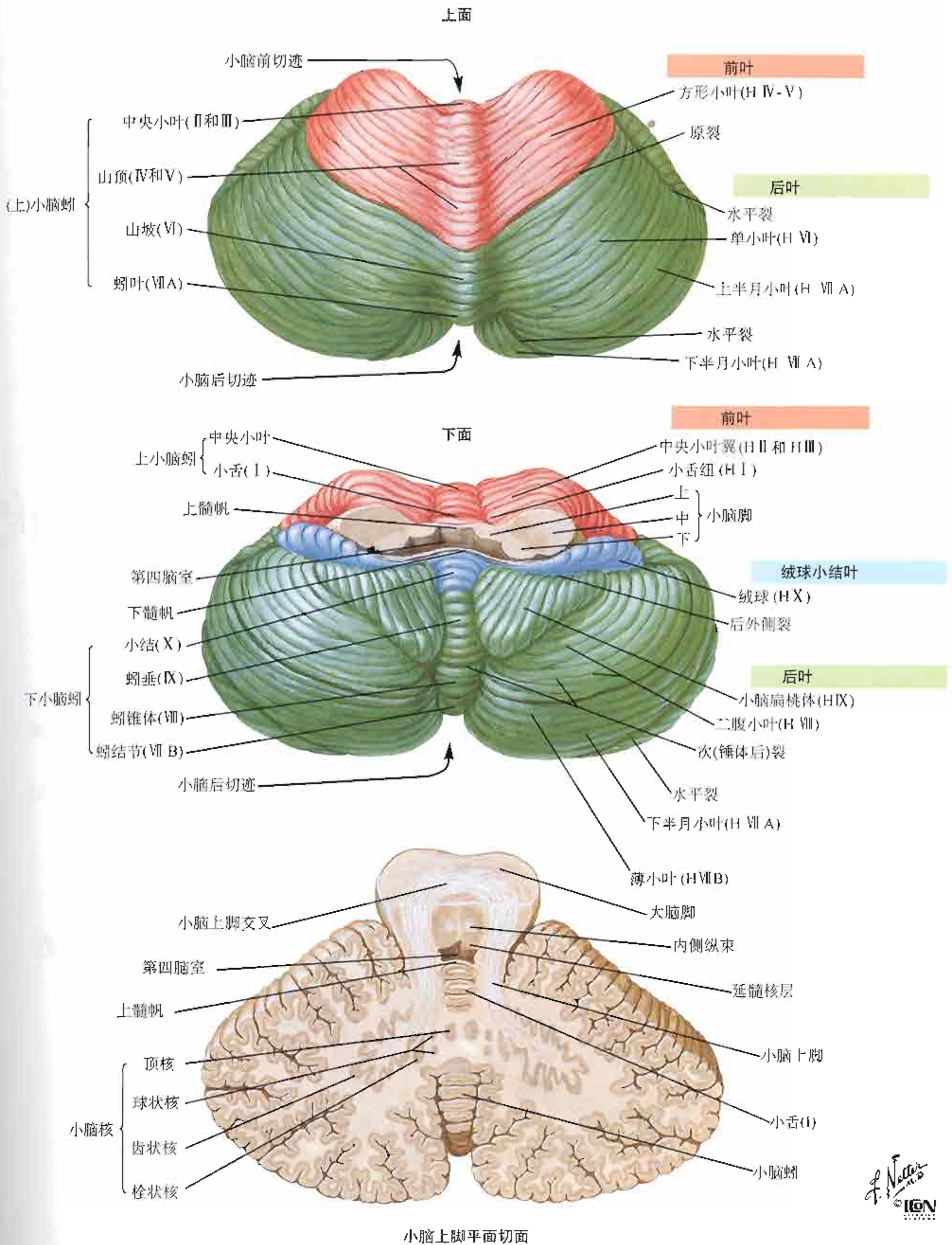
上面解剖



穹隆：模式图



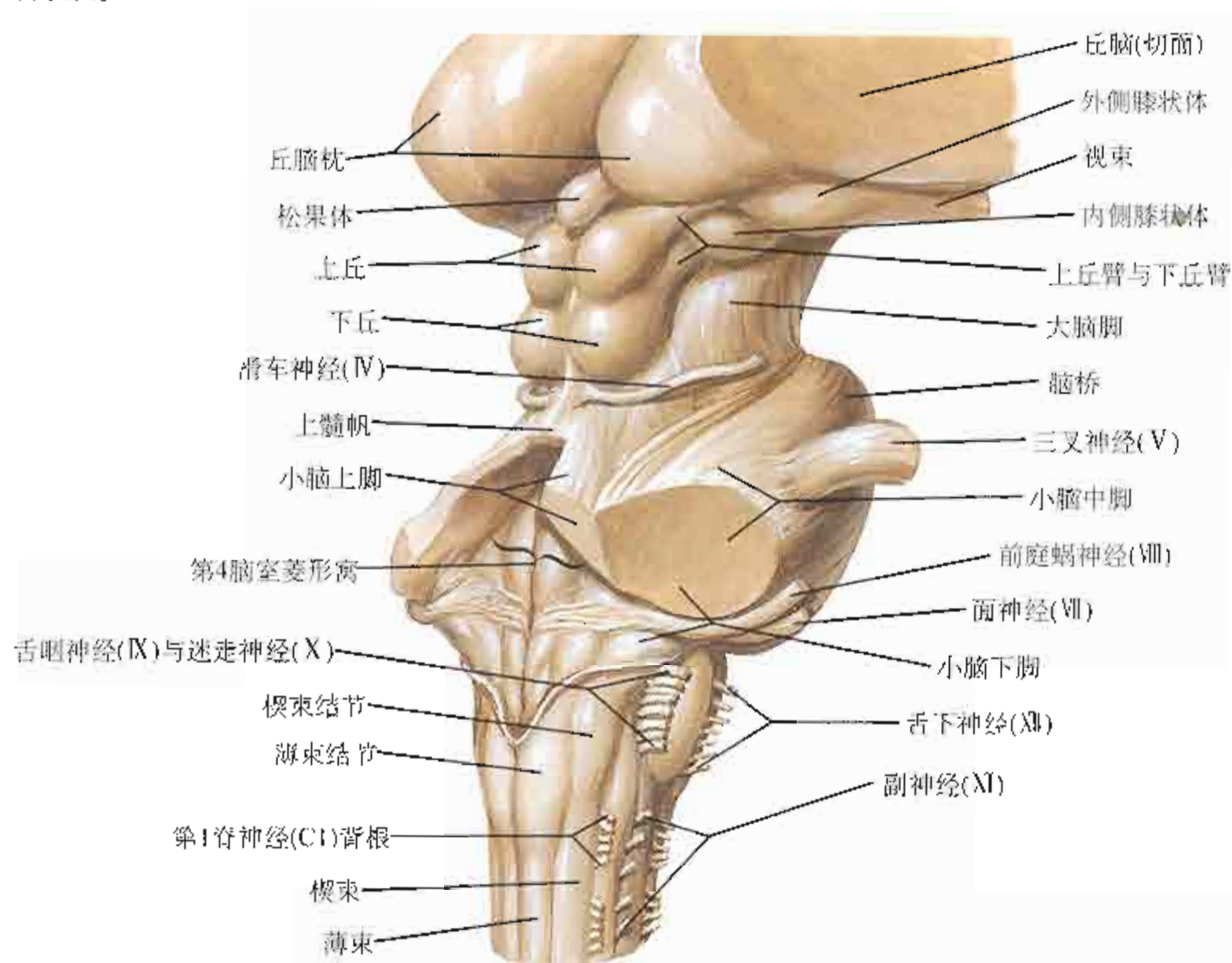
冠状切面：后面观



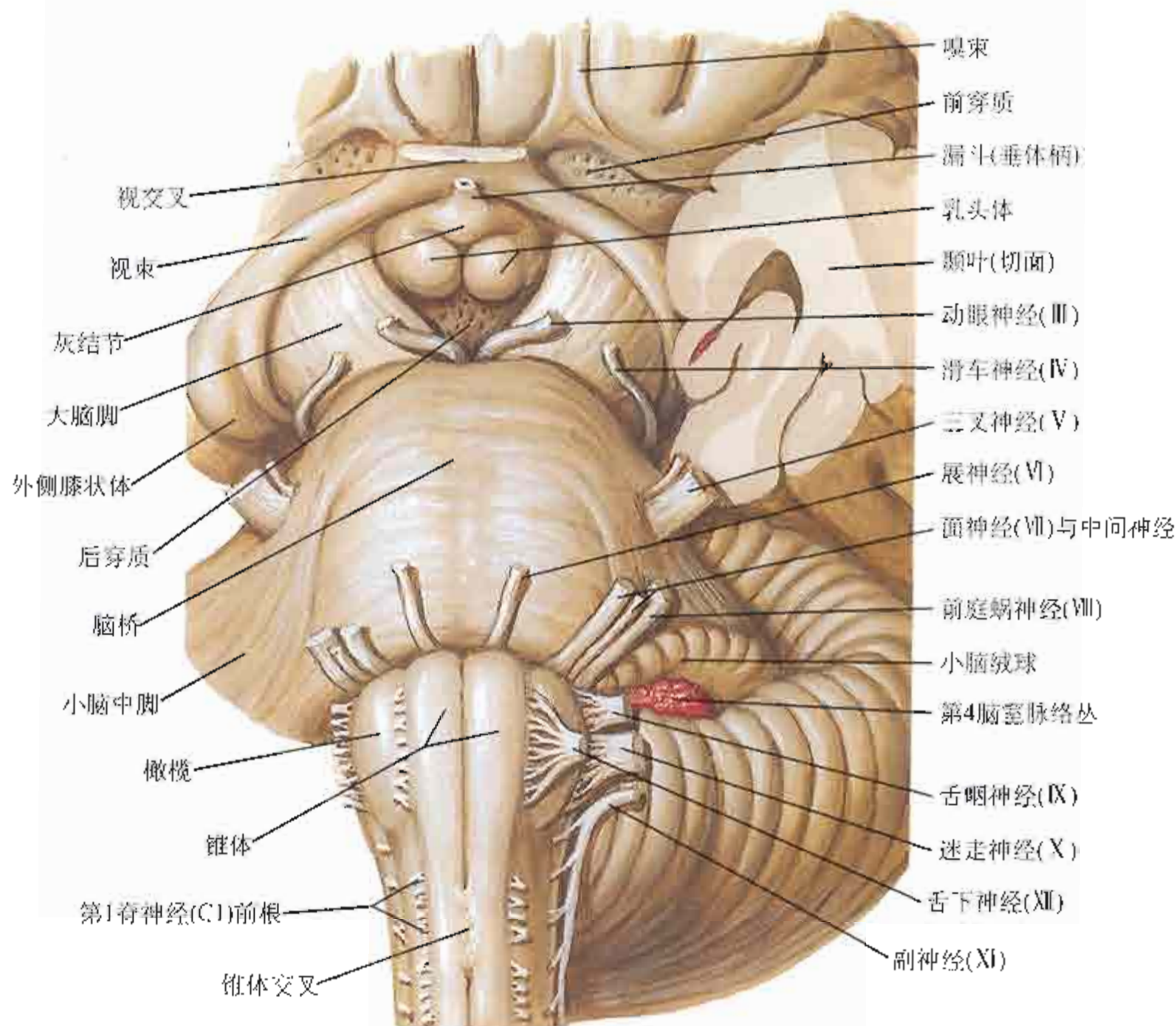
F. Netter M.D.
© IGV

脑干

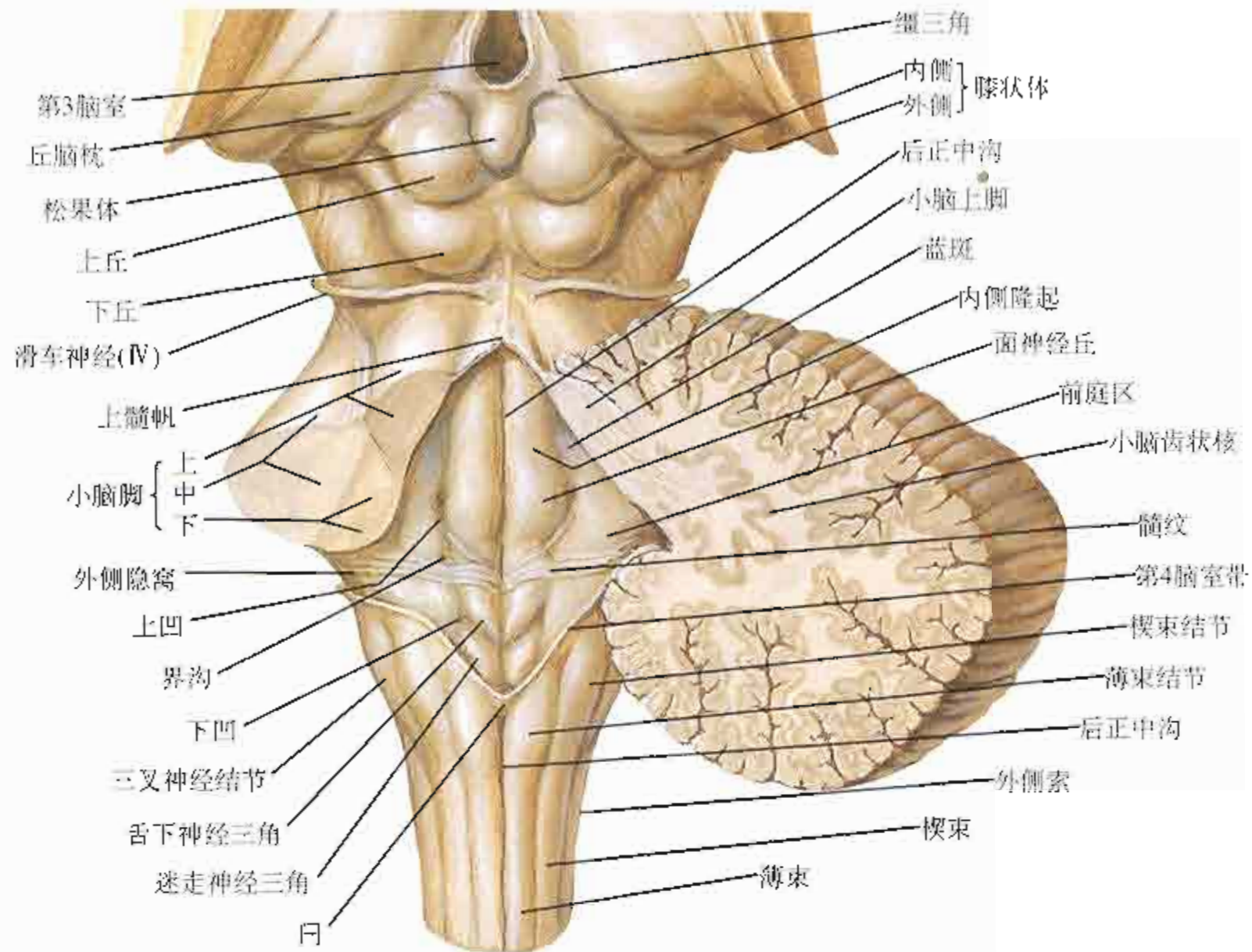
后外侧观



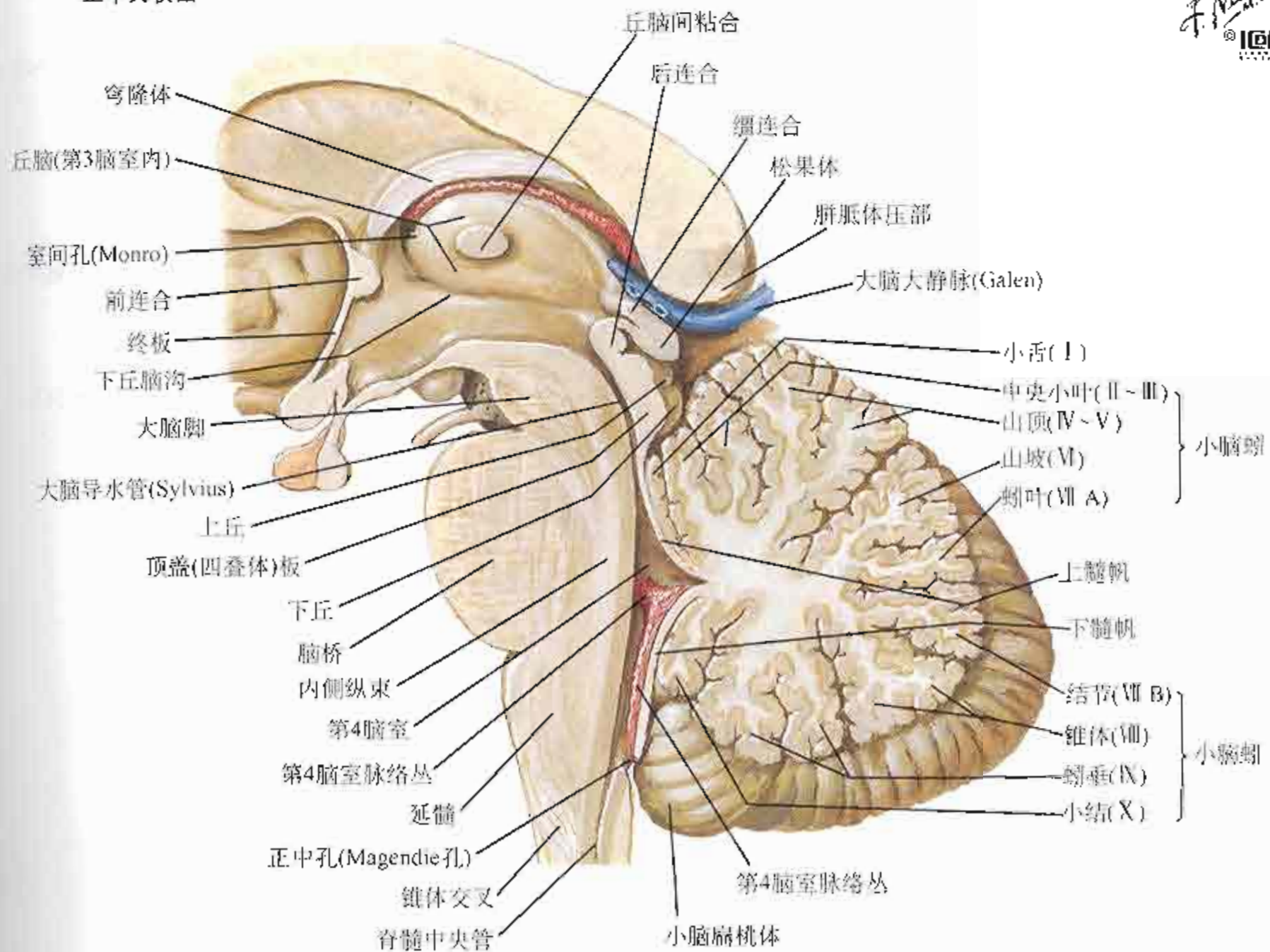
前面观



后面观



正中矢状面

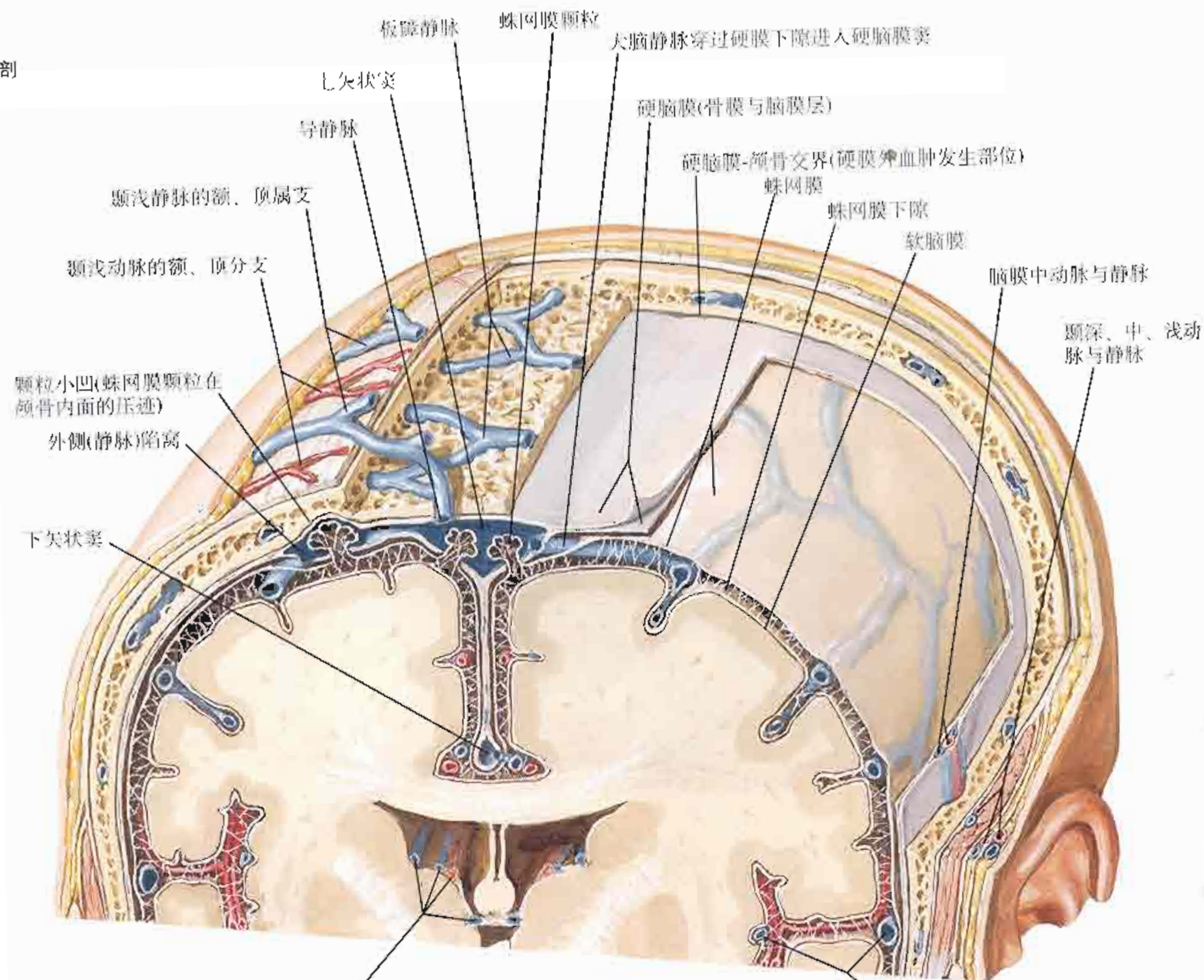


F. Netter M.D. IGM

脑膜与板障静脉

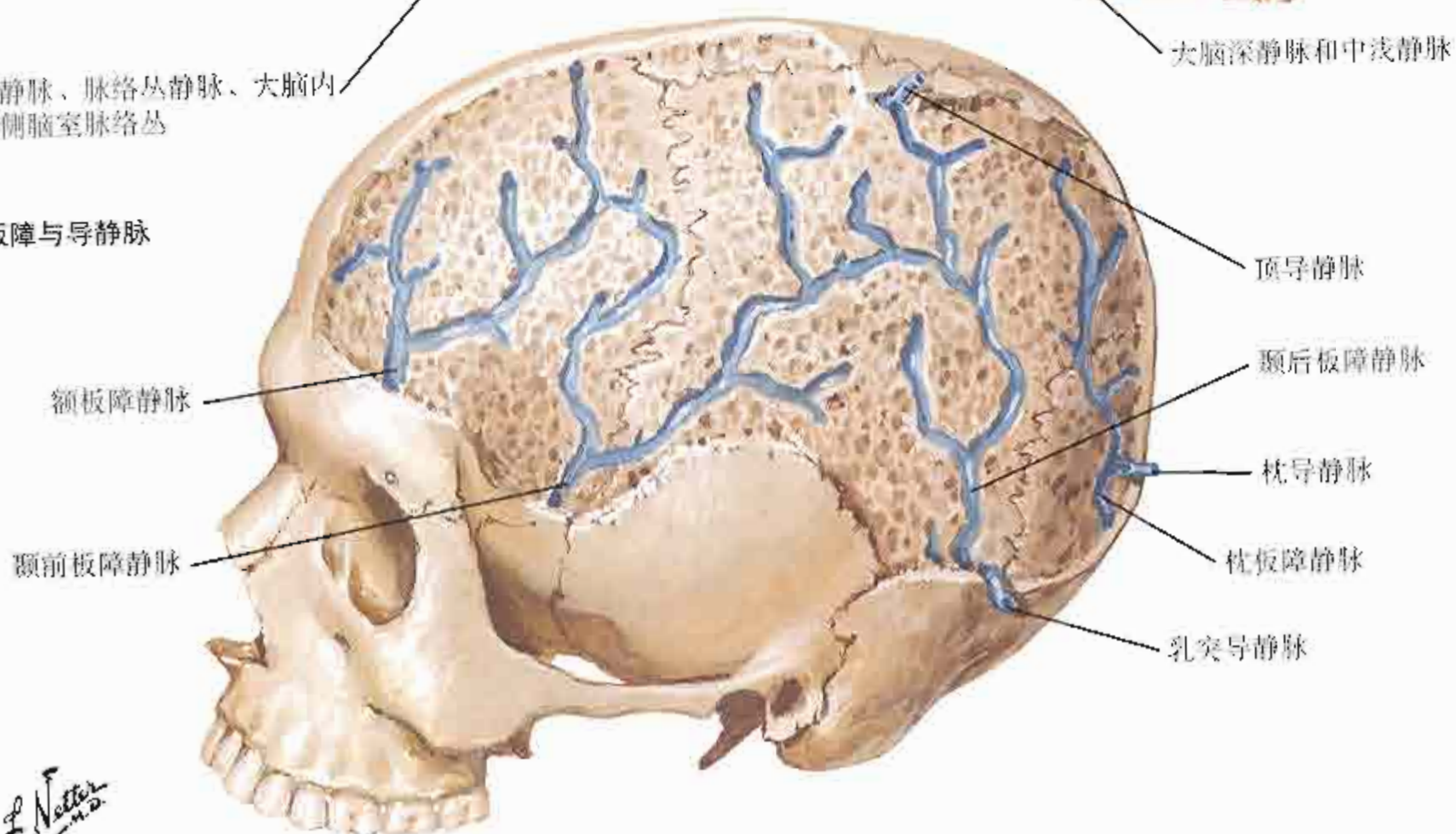
参见图19

冠状解剖

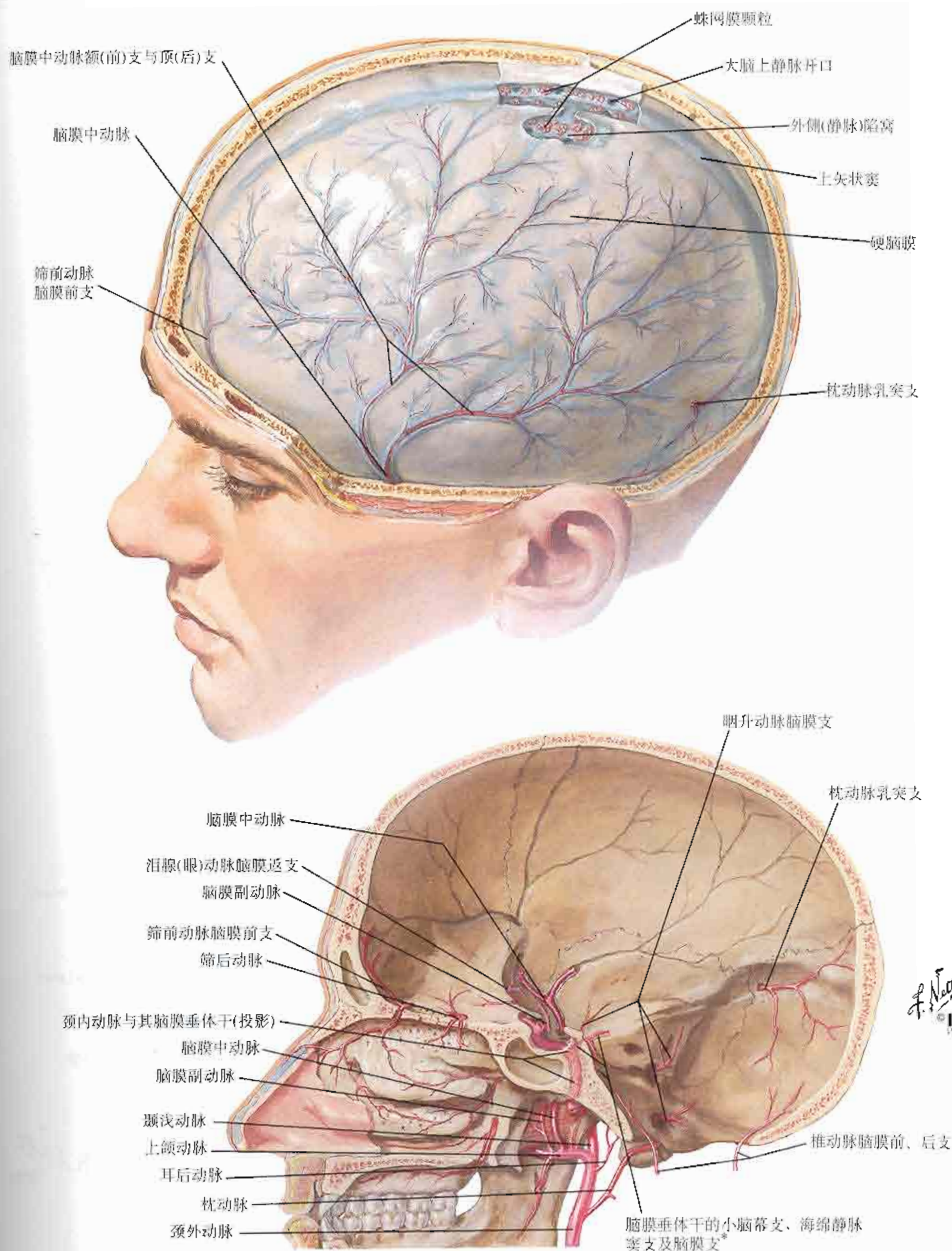


丘纹上静脉、脉络丛静脉、大脑内静脉和侧脑室脉络丛

颅骨板障与导静脉



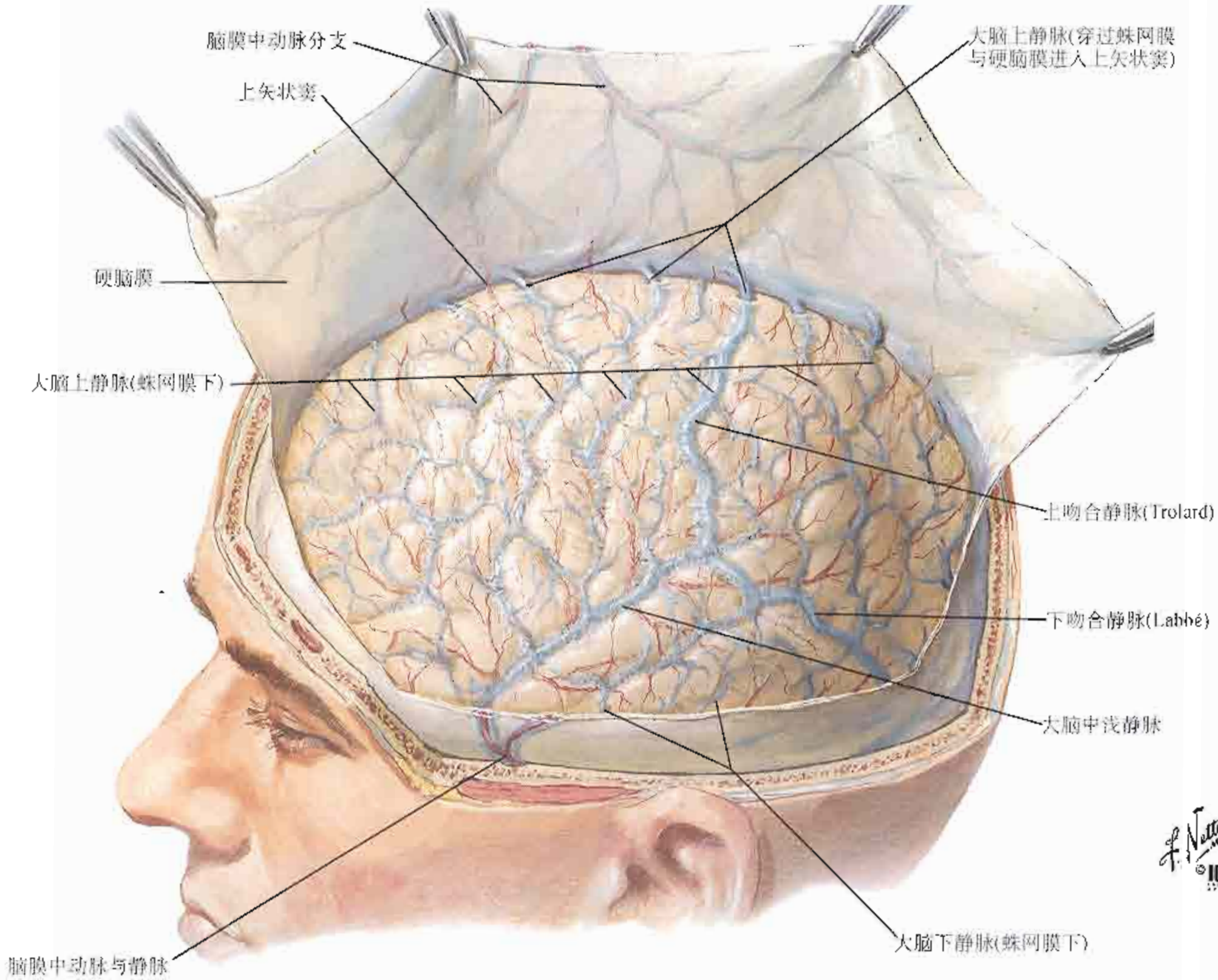
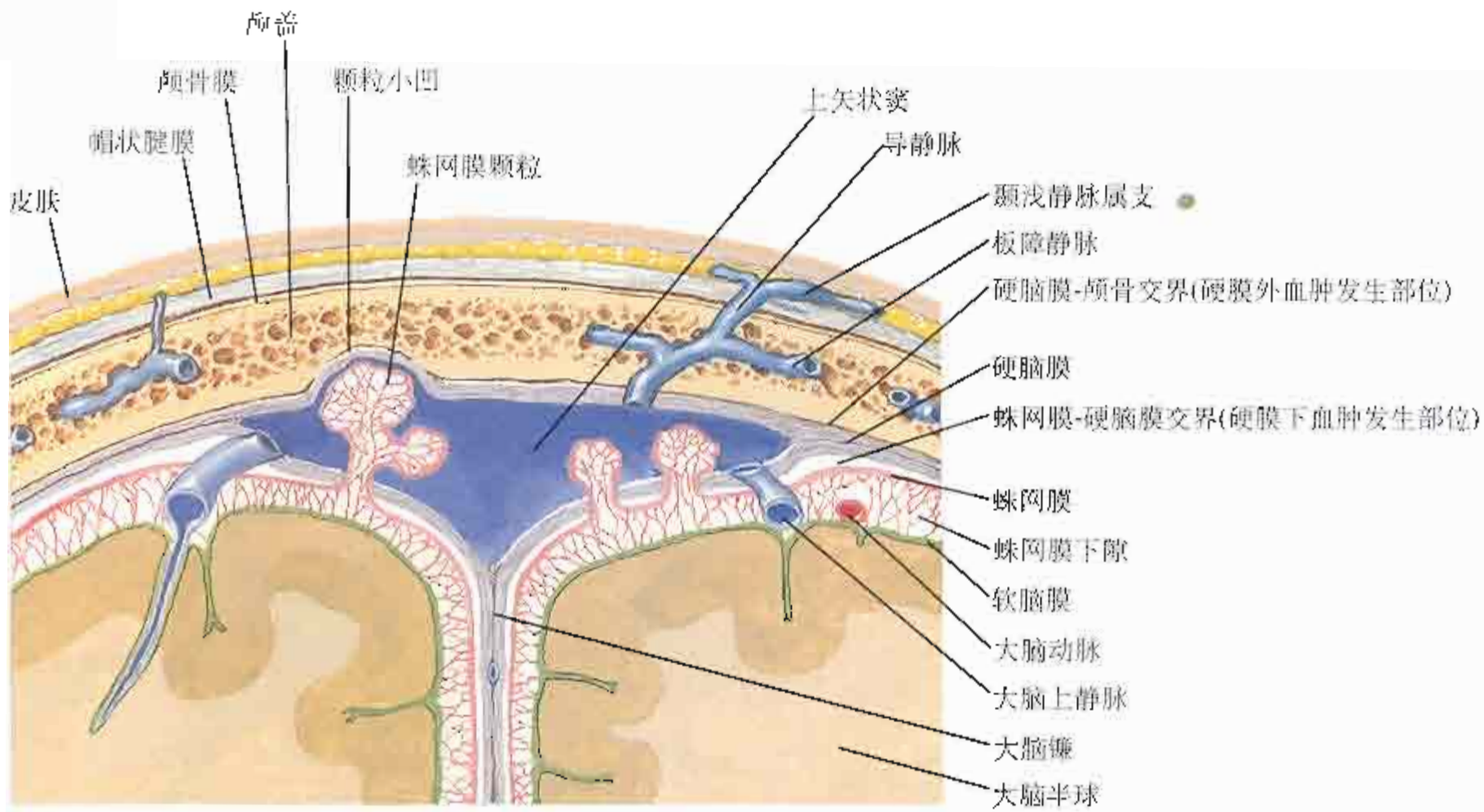
F. Netter M.D. IGV



*有变异，最常见的是这些分支直接发自颈内动脉

脑膜与大脑浅静脉

脑深静脉参见图138





运动科学网站



运动科学网站



运动科学网站

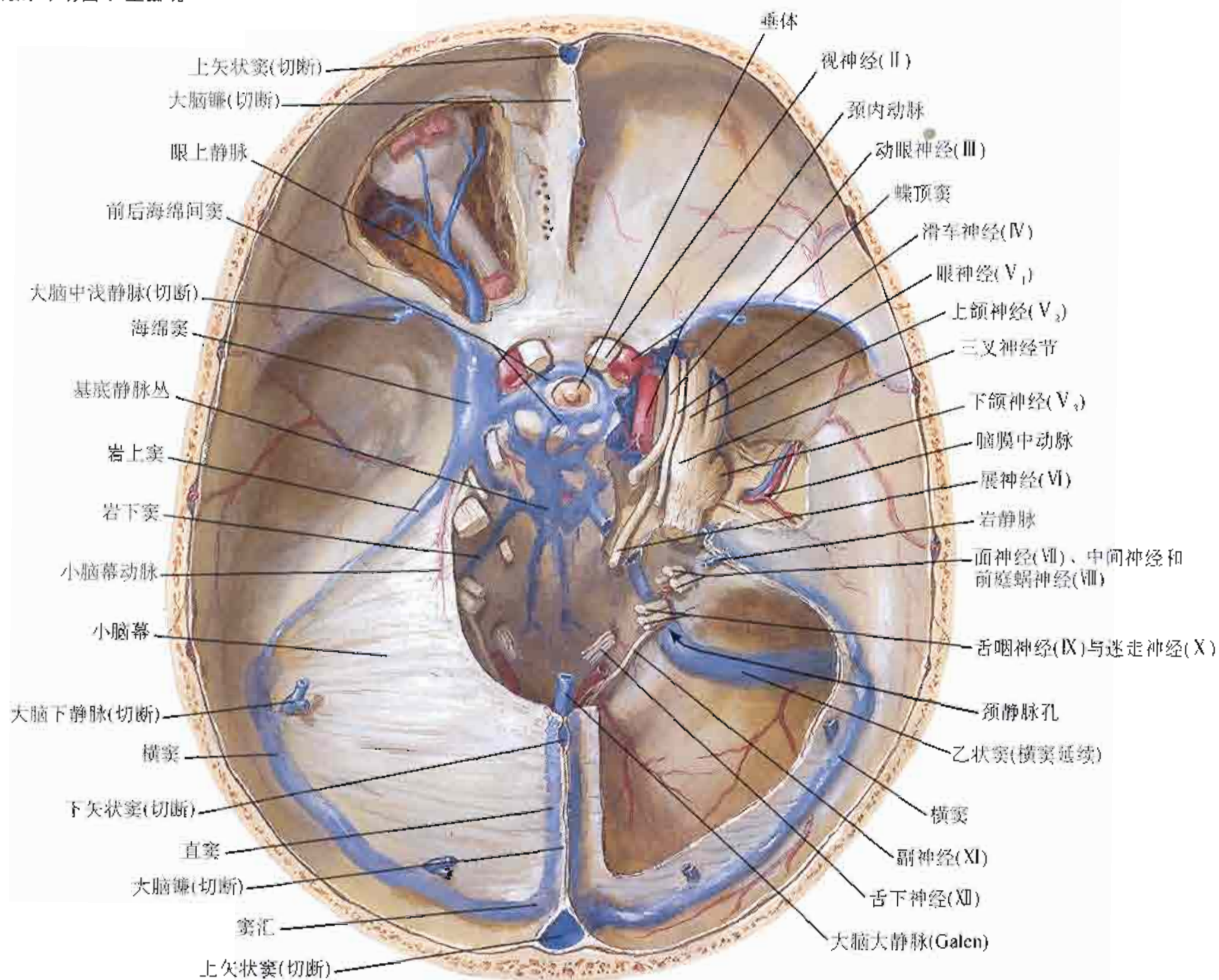


运动科学网站
www.vo2maxcn.com

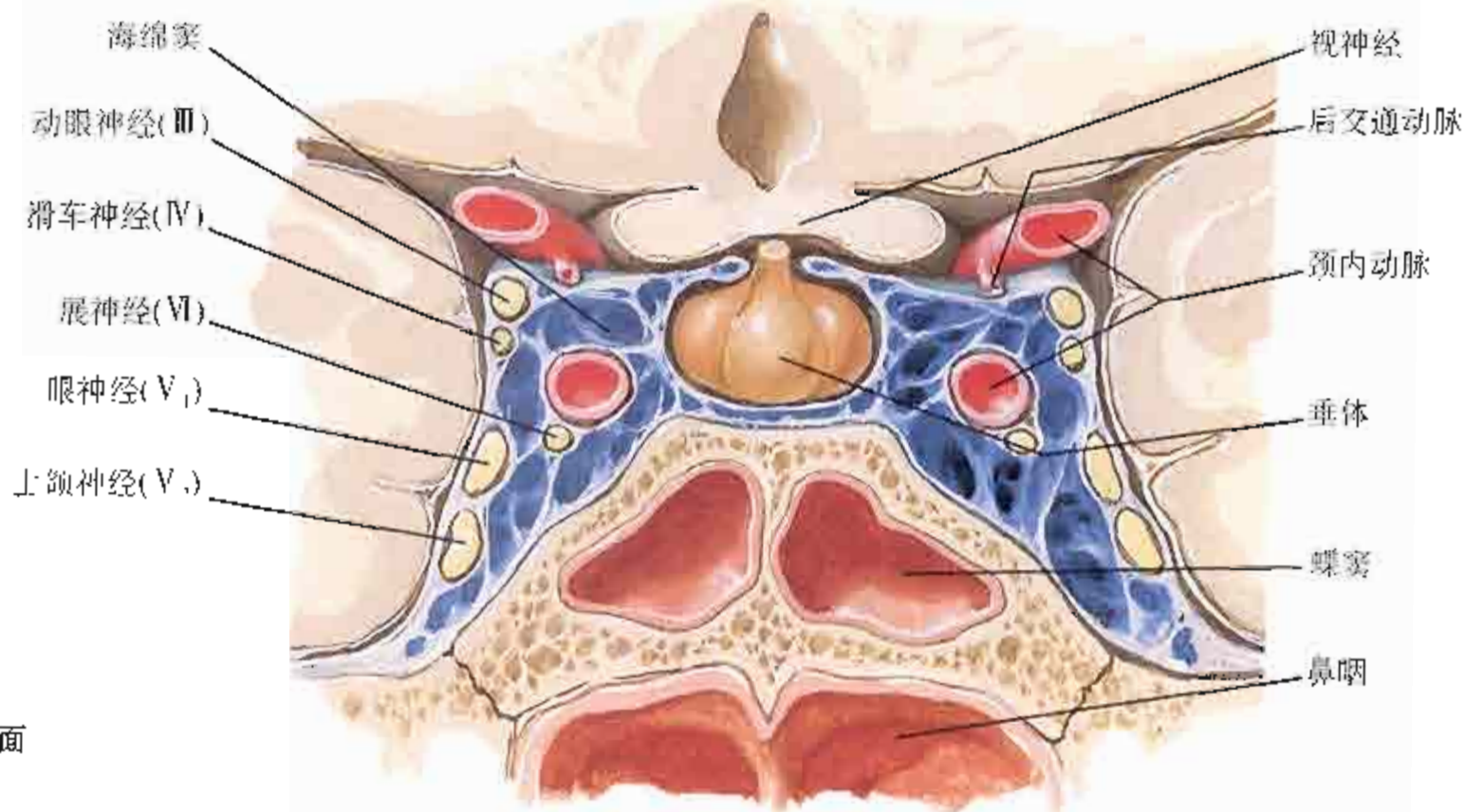
硬脑膜静脉窦(续)

参见图81

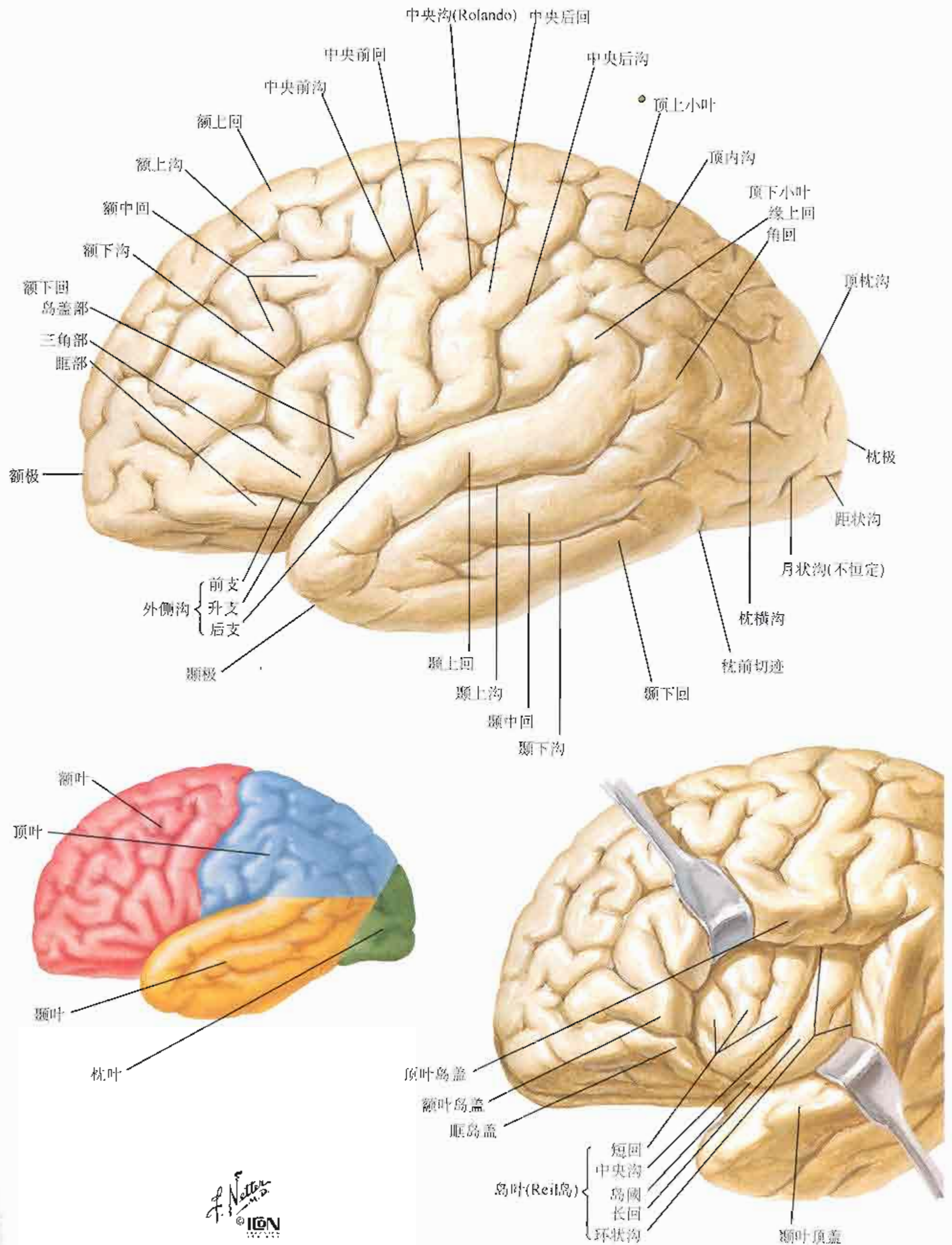
颅水平切面：上面观



F. Netter M.D. © IGM

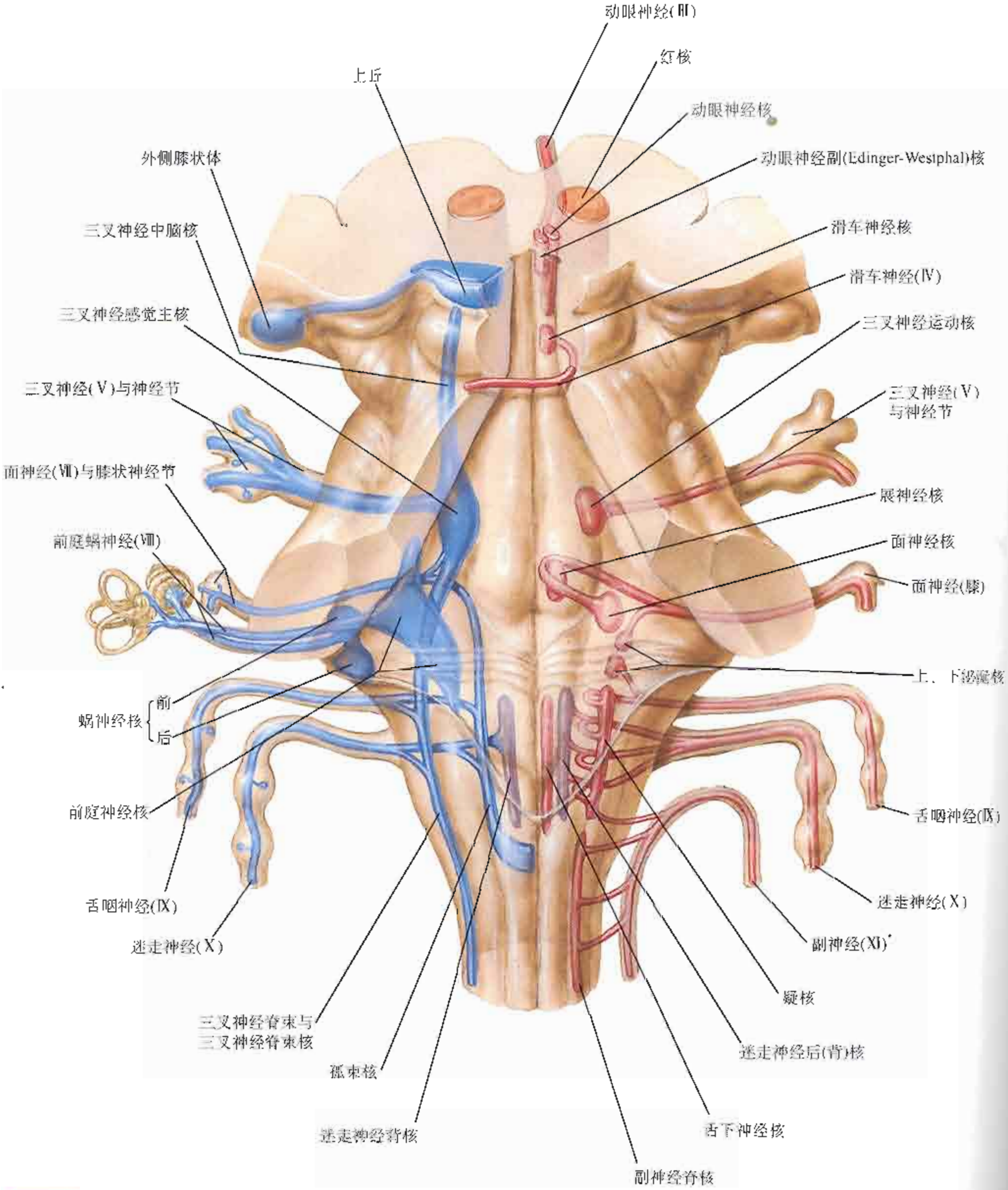


经海绵窦冠状切面



脑干内脑神经核：示意图

后面观(投影)

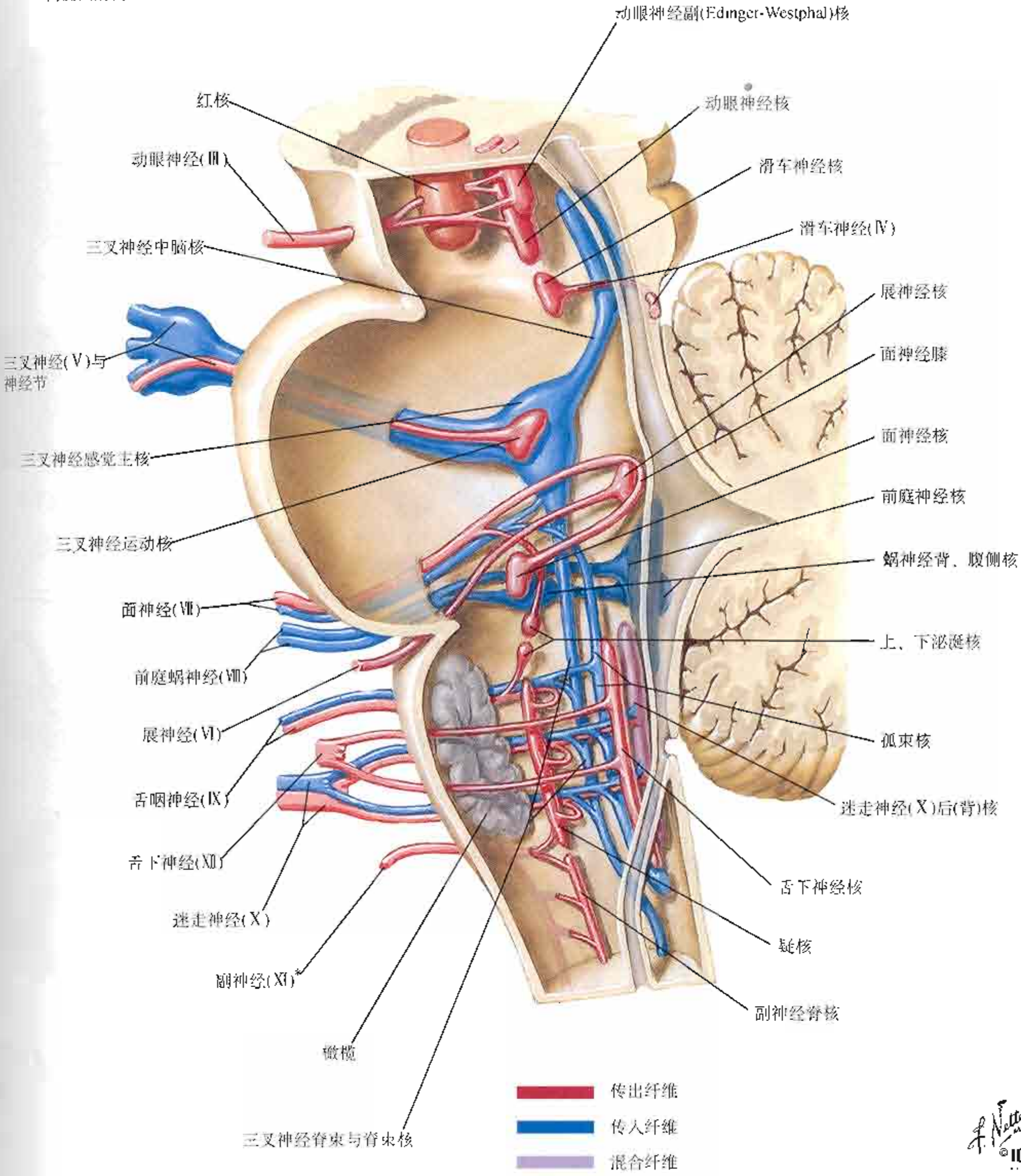


- 传出纤维
- 传入纤维
- 混合纤维

最近有证据表明,副神经缺少脑神经根,且与迷走神经无联系。确证这一发现需要进一步研究。

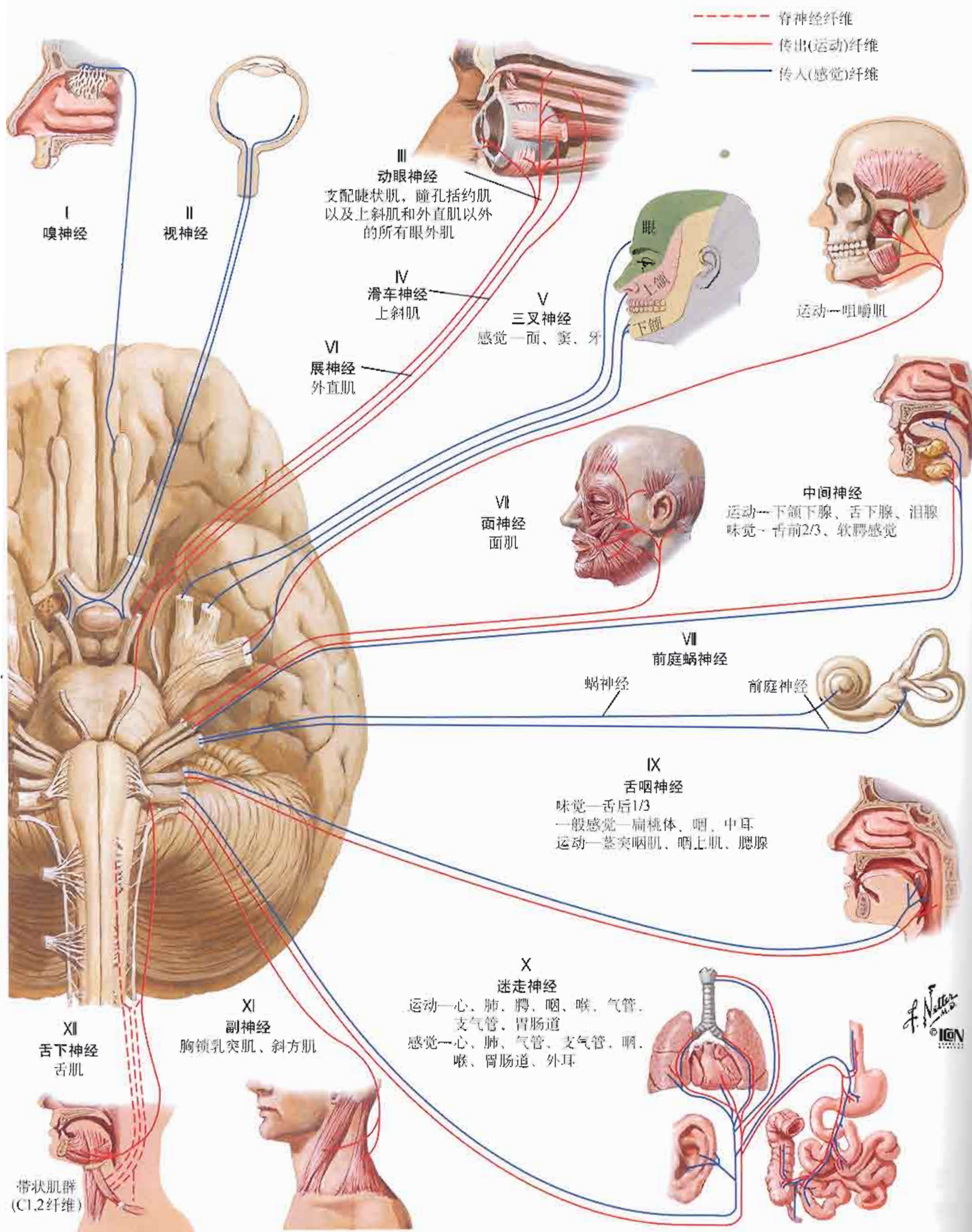


内侧面解剖



*最近有证据表明，副神经缺少脑神经根，且与迷走神经无联系。确证这一发现需要进一步研究。

脑神经(运动与感觉神经分布): 示意图





运动科学网站



运动科学网站

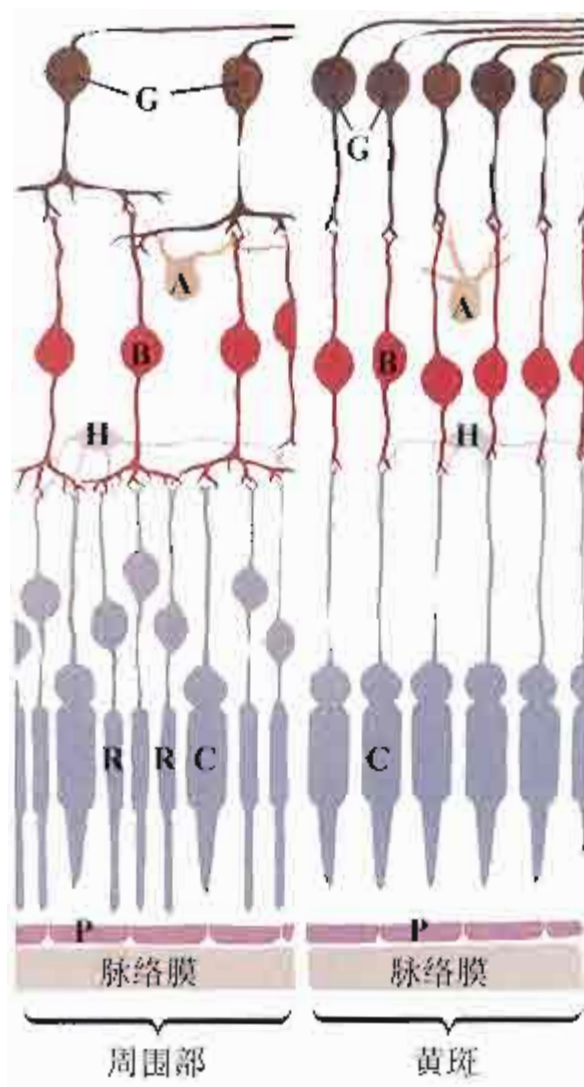


运动科学网站



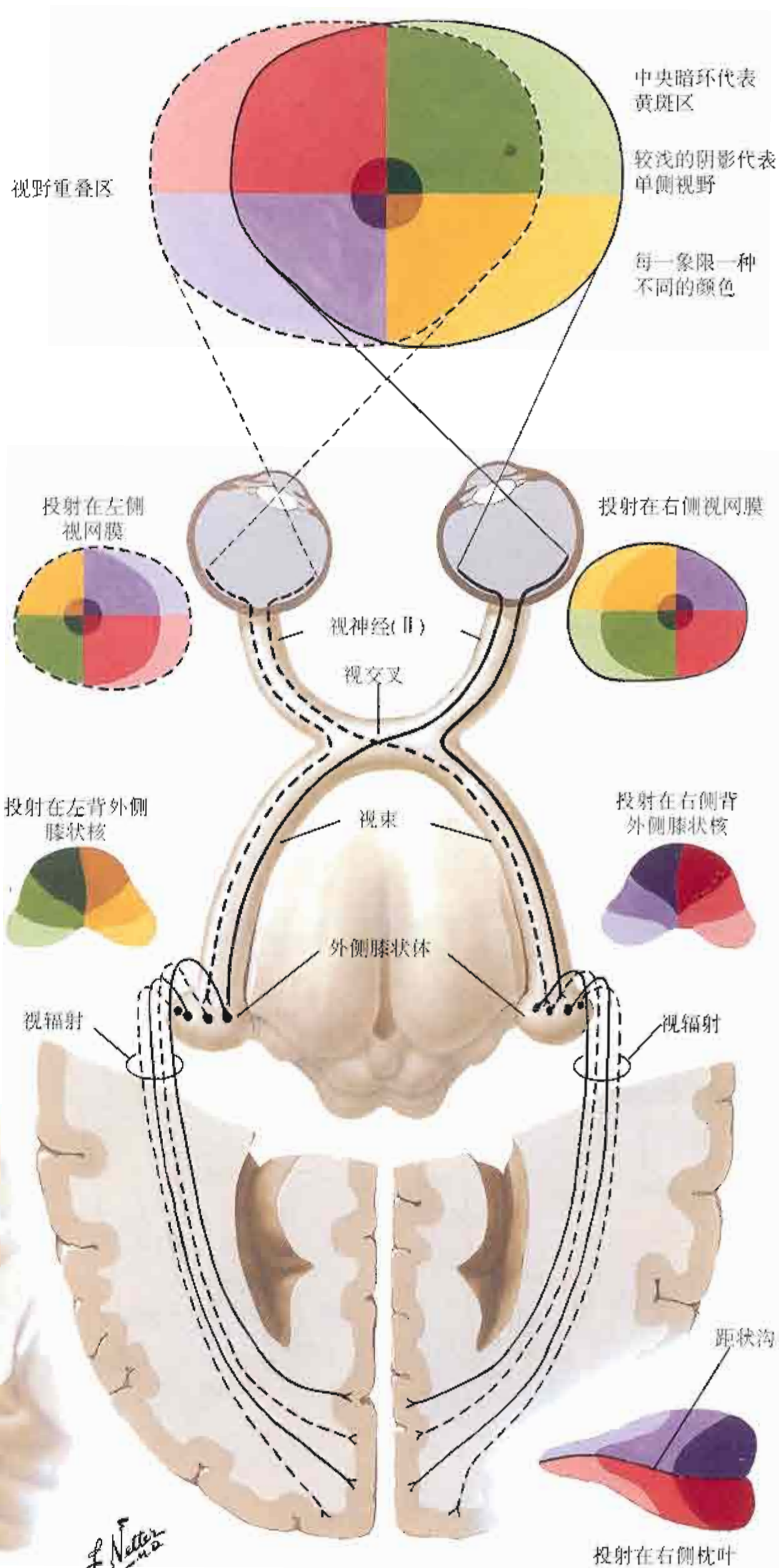
运动科学网站
www.vo2maxcn.com

视神经(Ⅱ)(视觉通路): 示意图

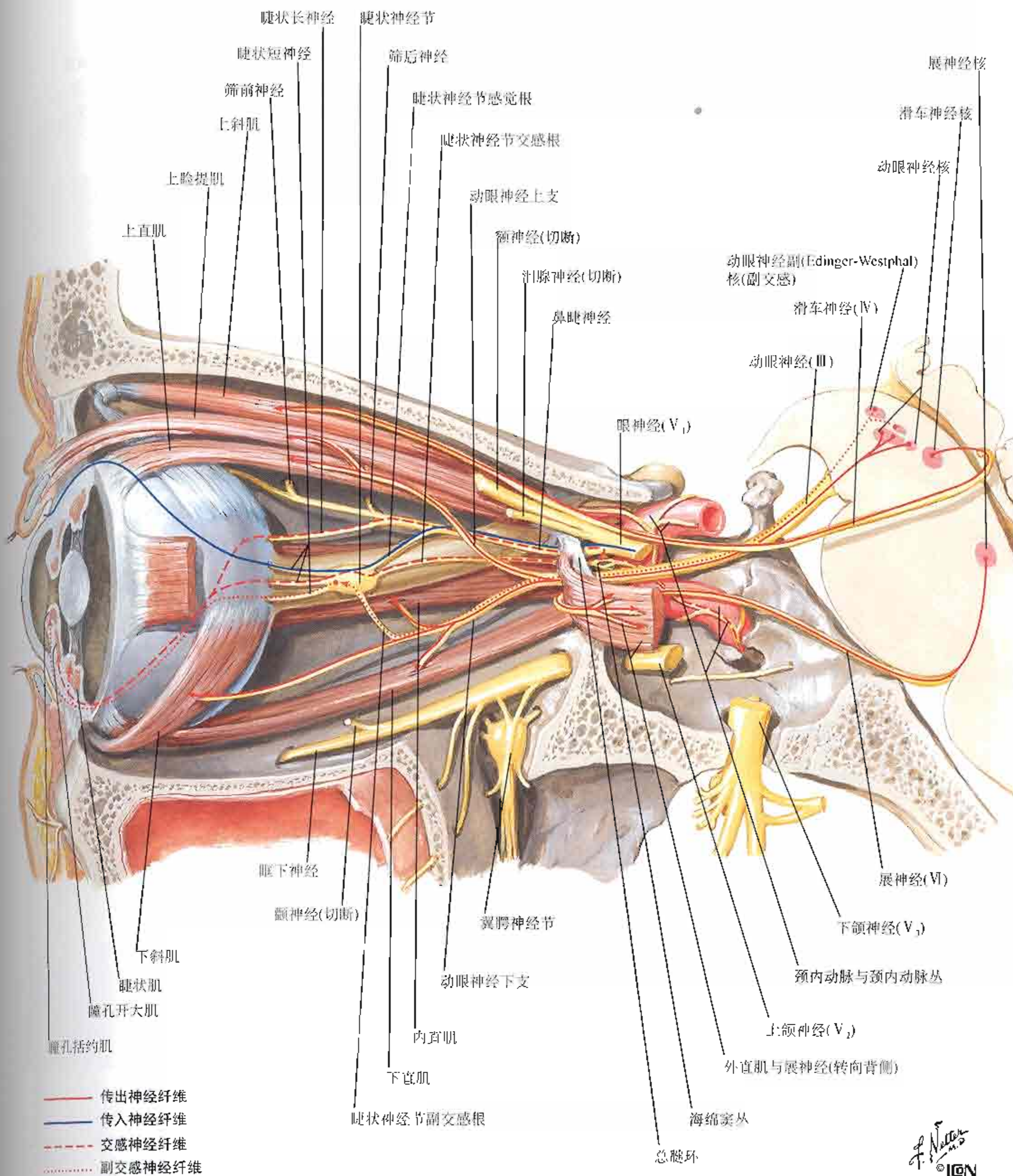


视网膜结构: 示意图

- A 无长突细胞
- B 双极细胞
- C 视锥细胞
- G 节细胞
- H 水平细胞
- P 色素细胞
- R 视杆细胞



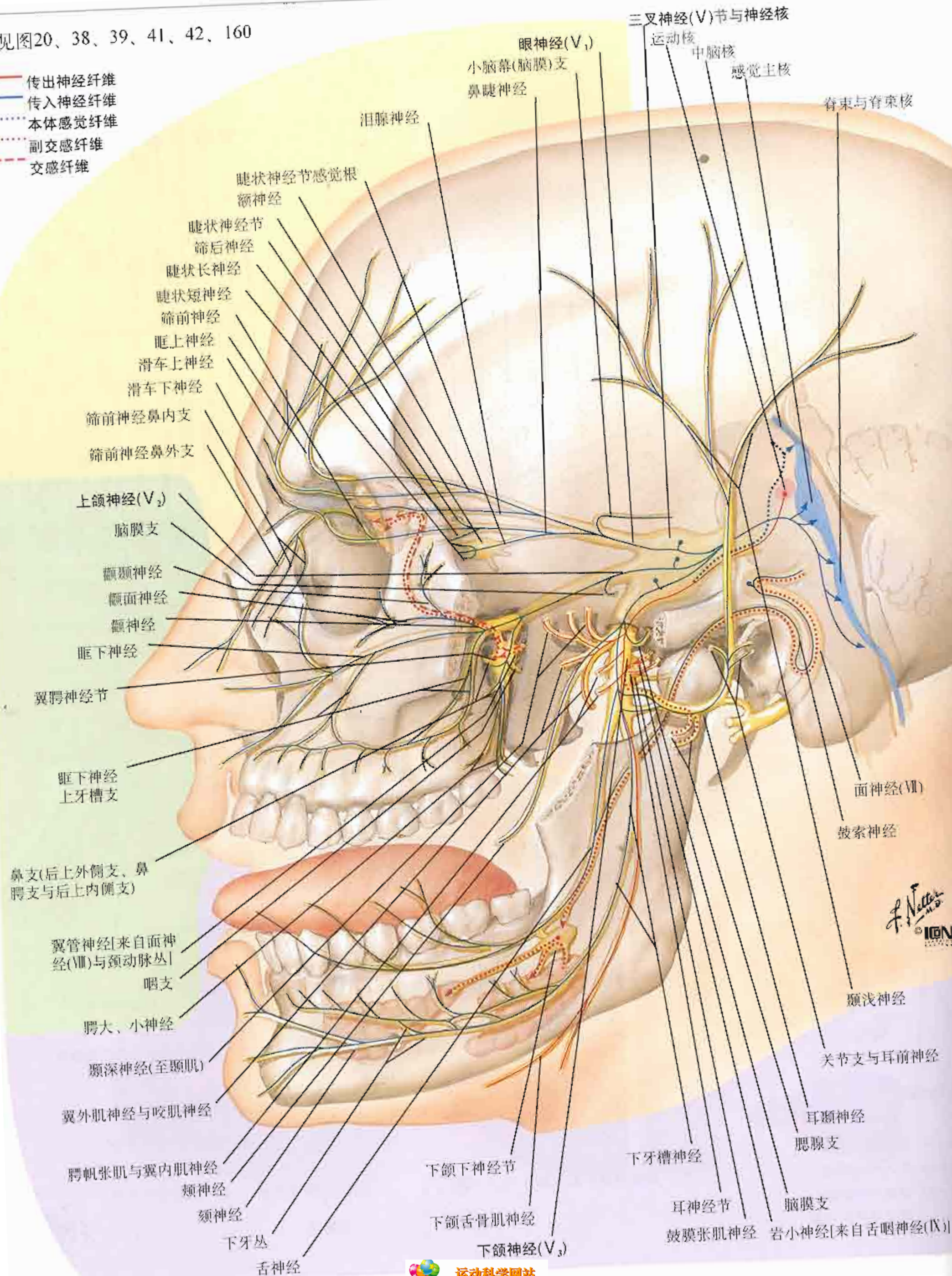
F. Netter
© ION

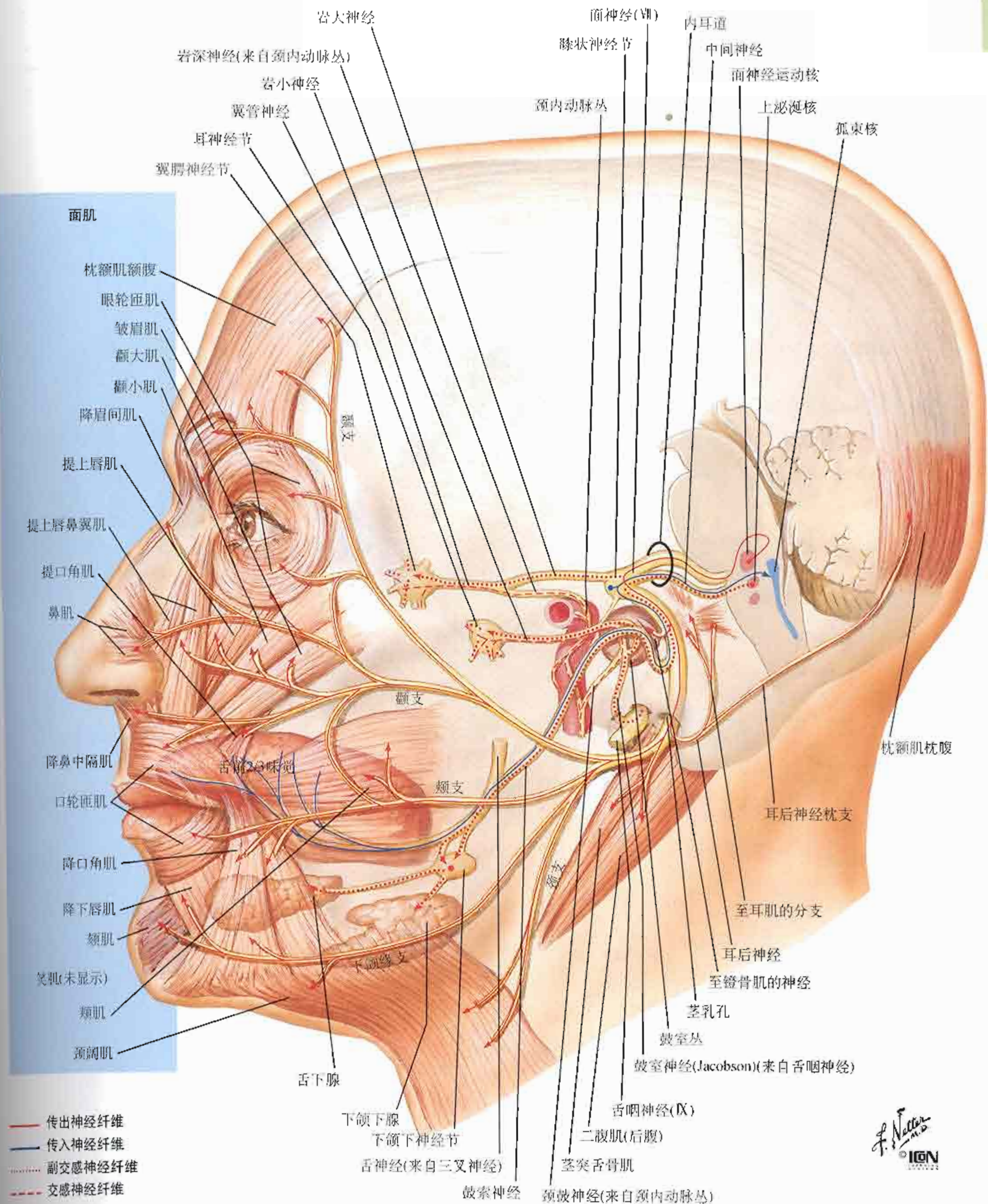


三叉神经(V): 示意图

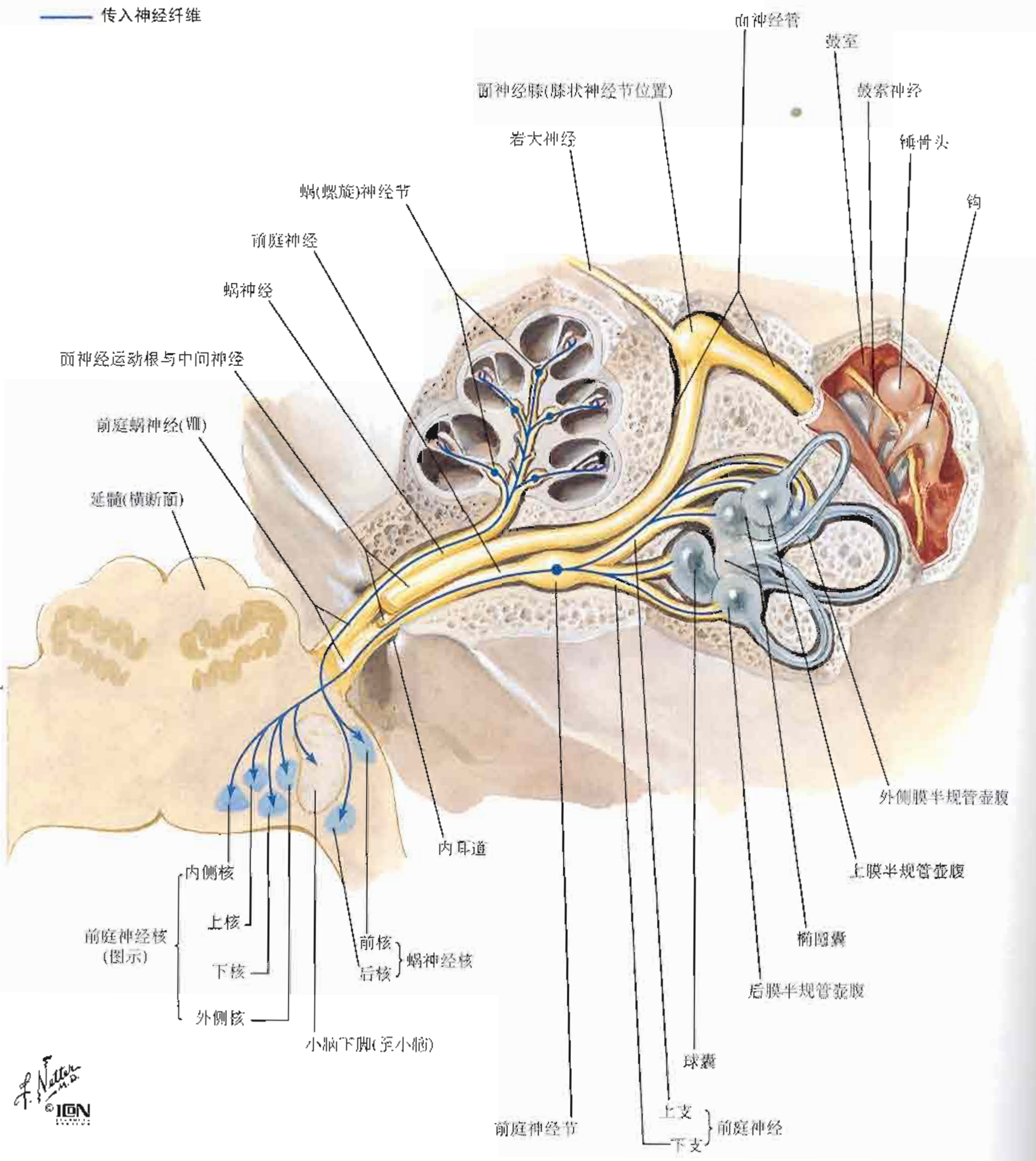
参见图20、38、39、41、42、160

- 传出神经纤维
- 传入神经纤维
- 本体感觉纤维
- 副交感纤维
- - - 交感纤维

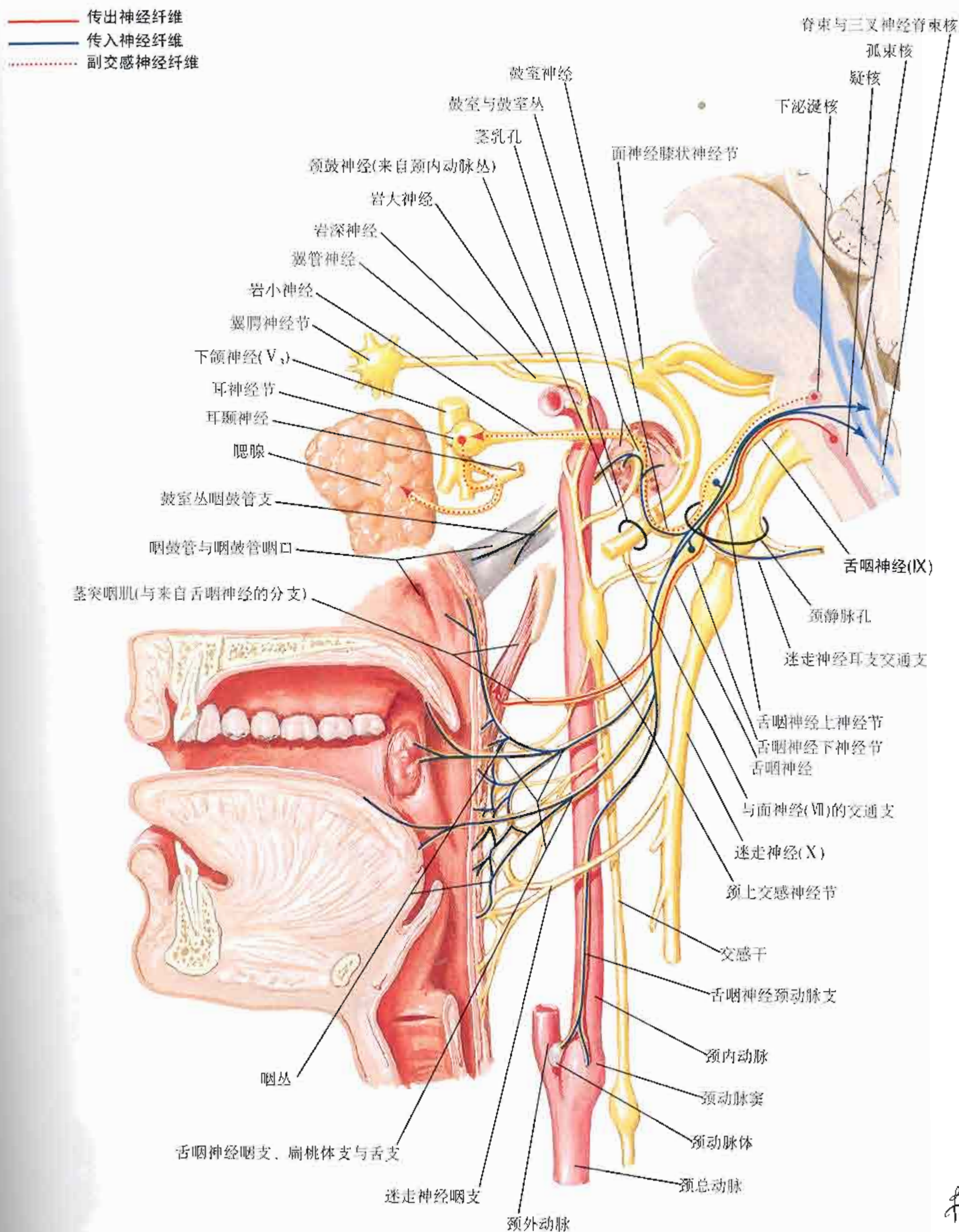




前庭蜗神经(VIII): 示意图



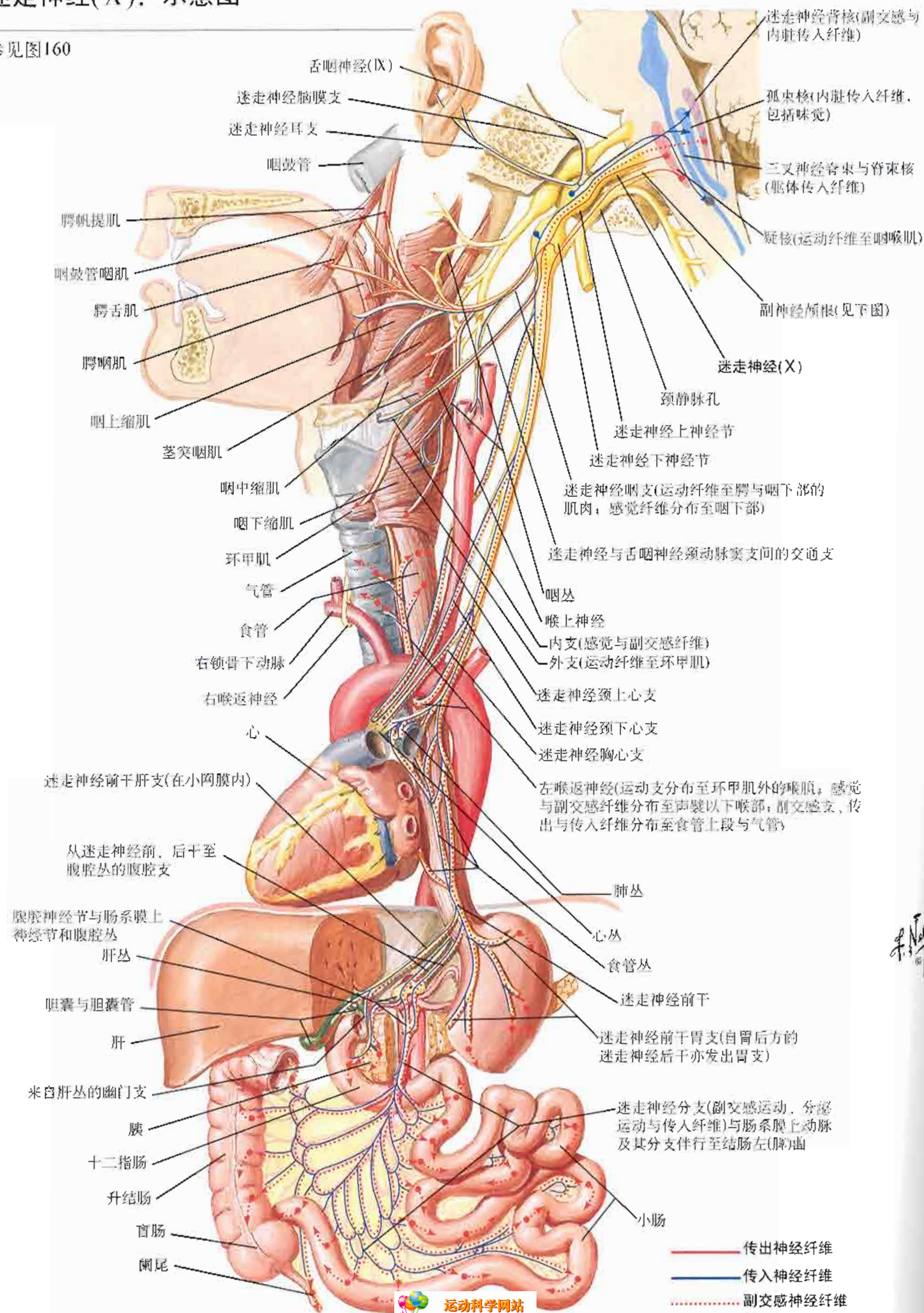
F. Netter M.D.
© ION



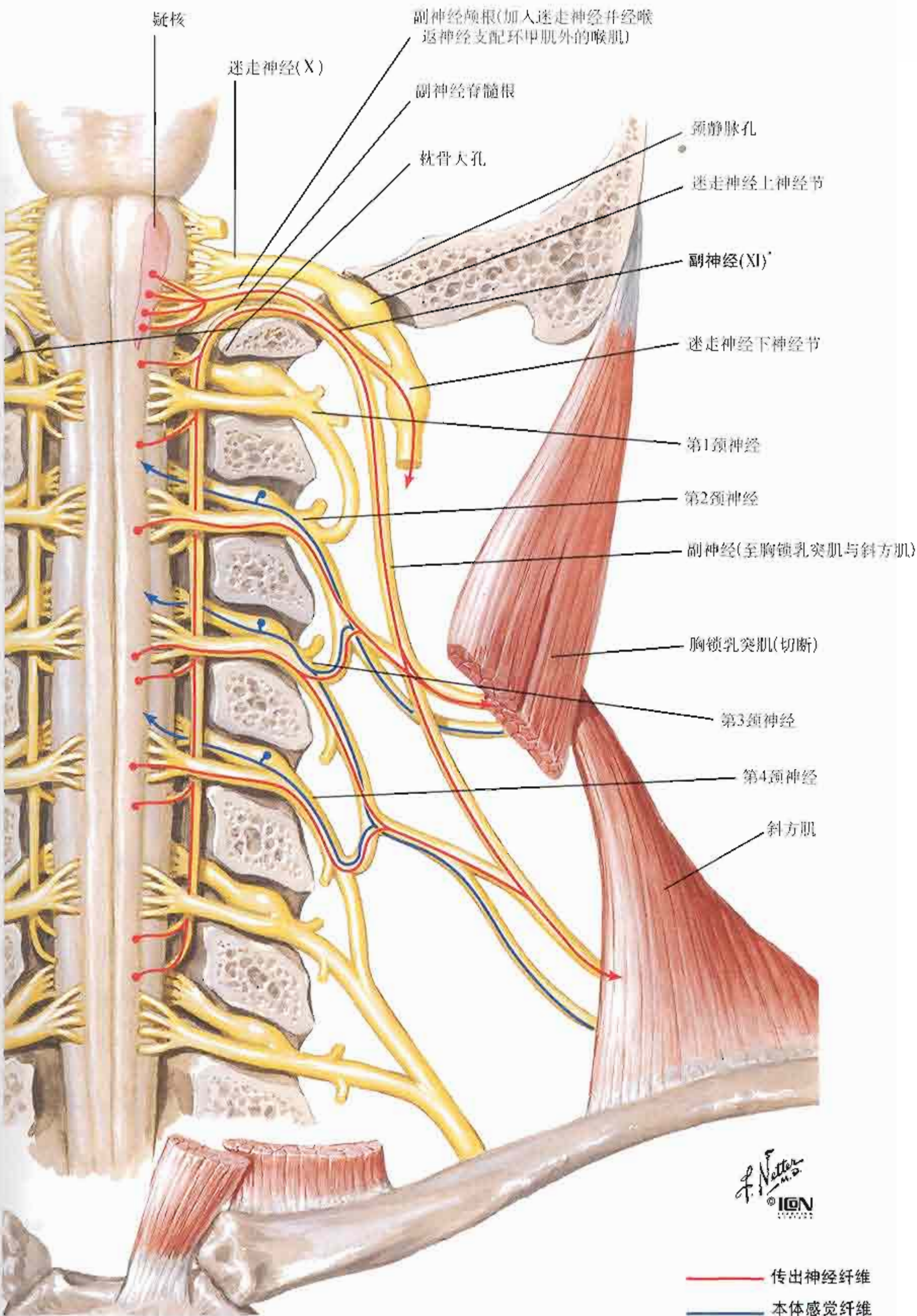
F. Netter M.D.
© 1996

迷走神经(X): 示意图

参见图160



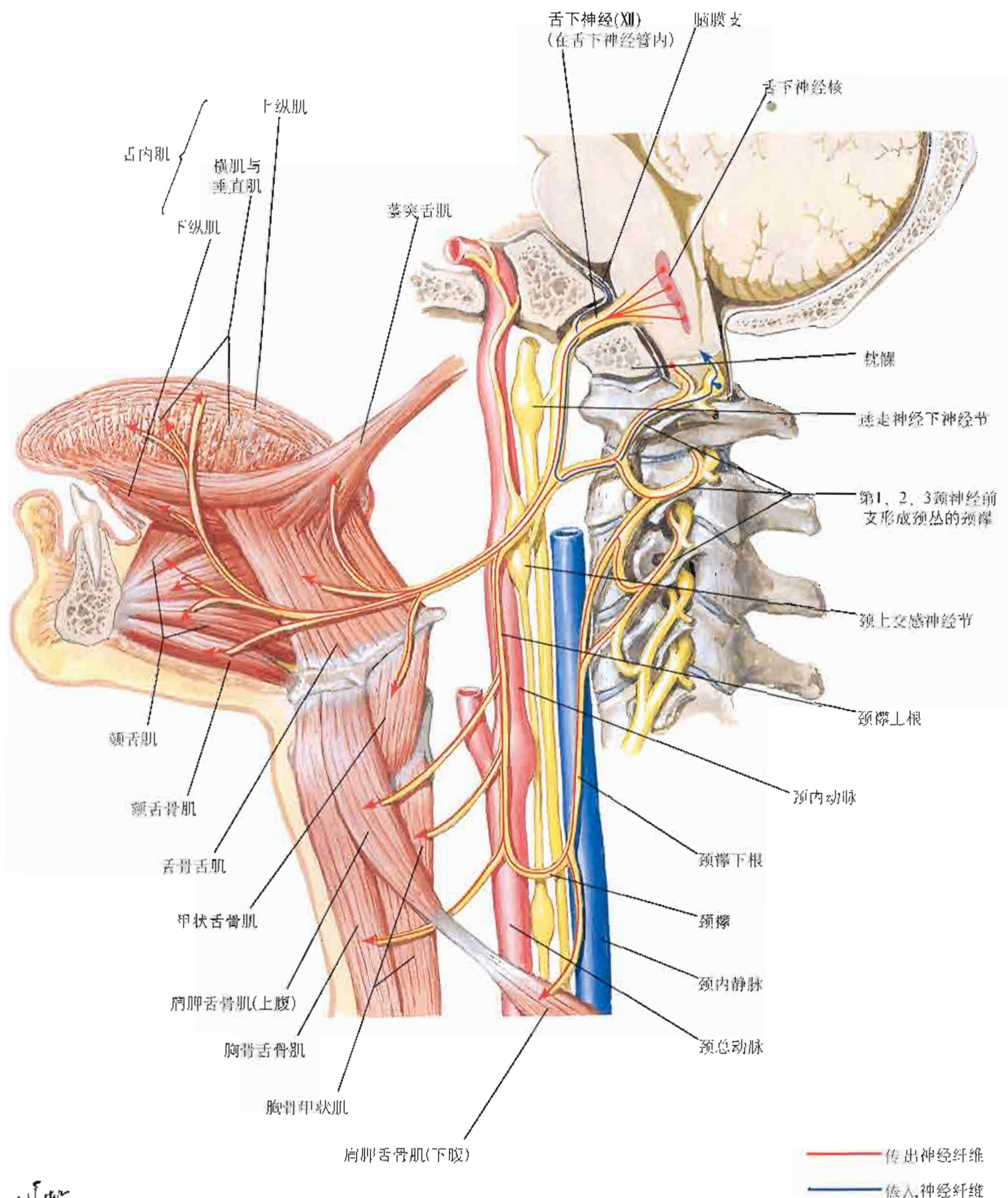
参见图28

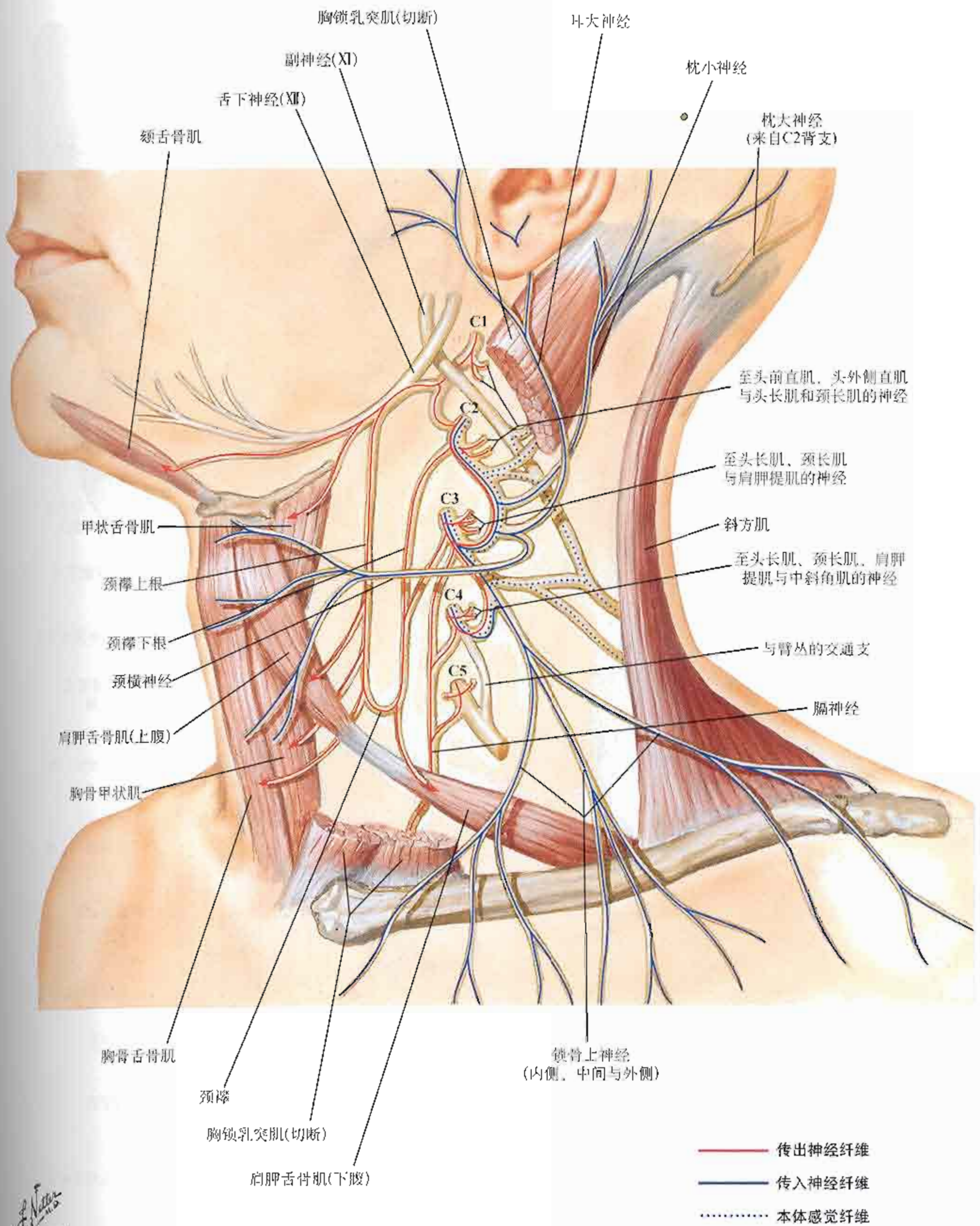


*最近有证据表明，副神经缺少脑神经根，且与迷走神经无联系。确证这一发现需要进一步研究。

舌下神经(XII): 示意图

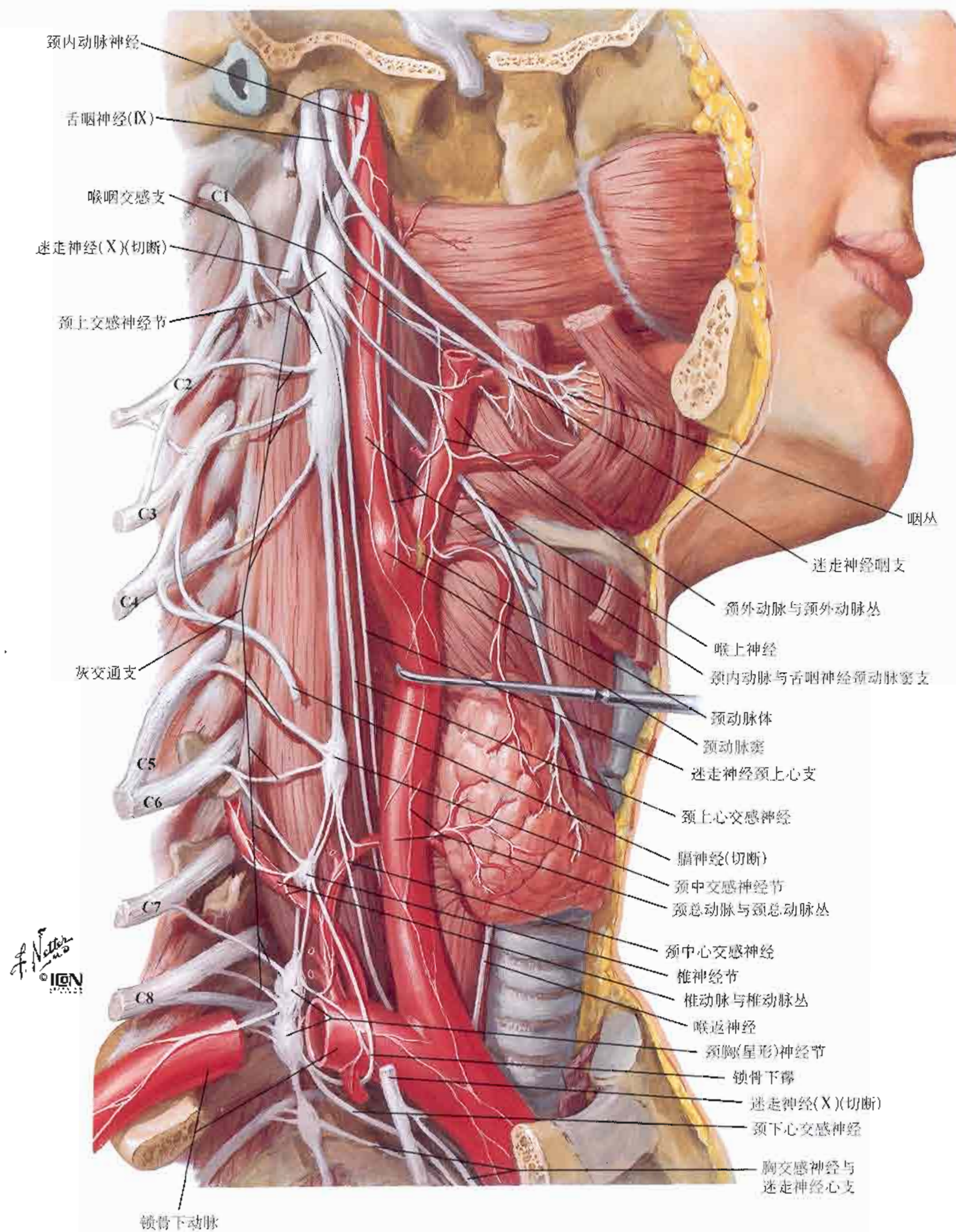
参见图28





颈部自主神经

参见图67、119、120、159、205、222、236、308



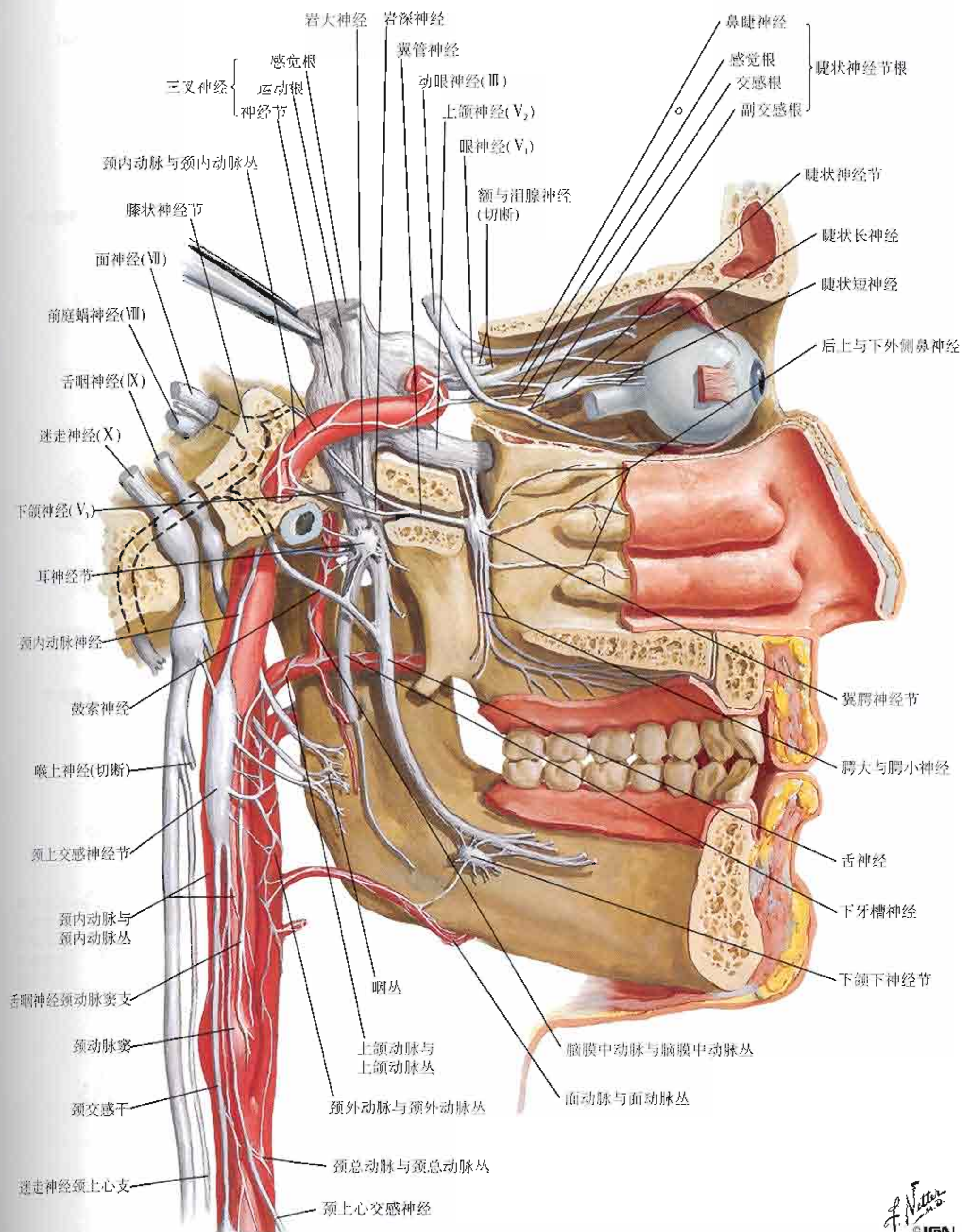
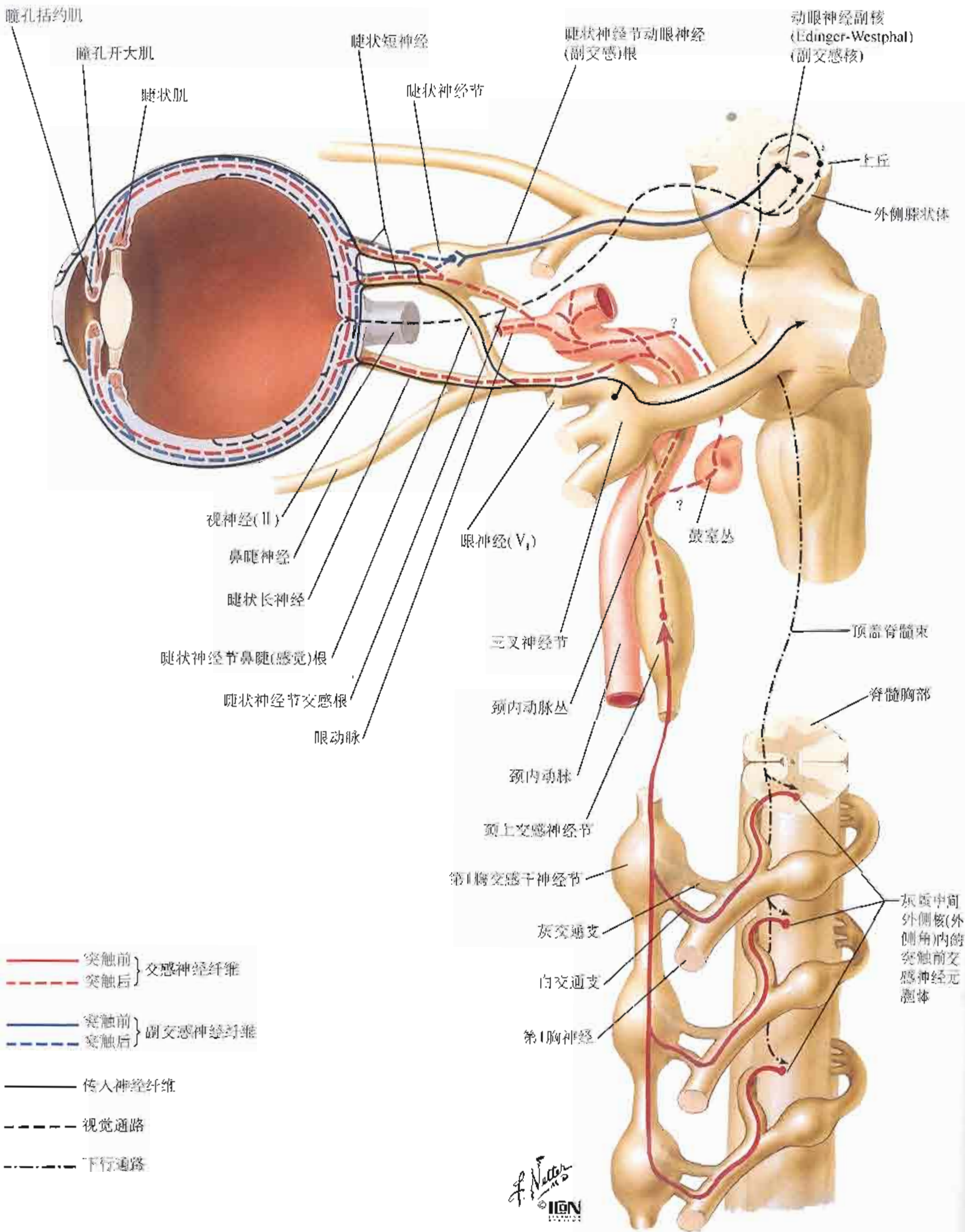
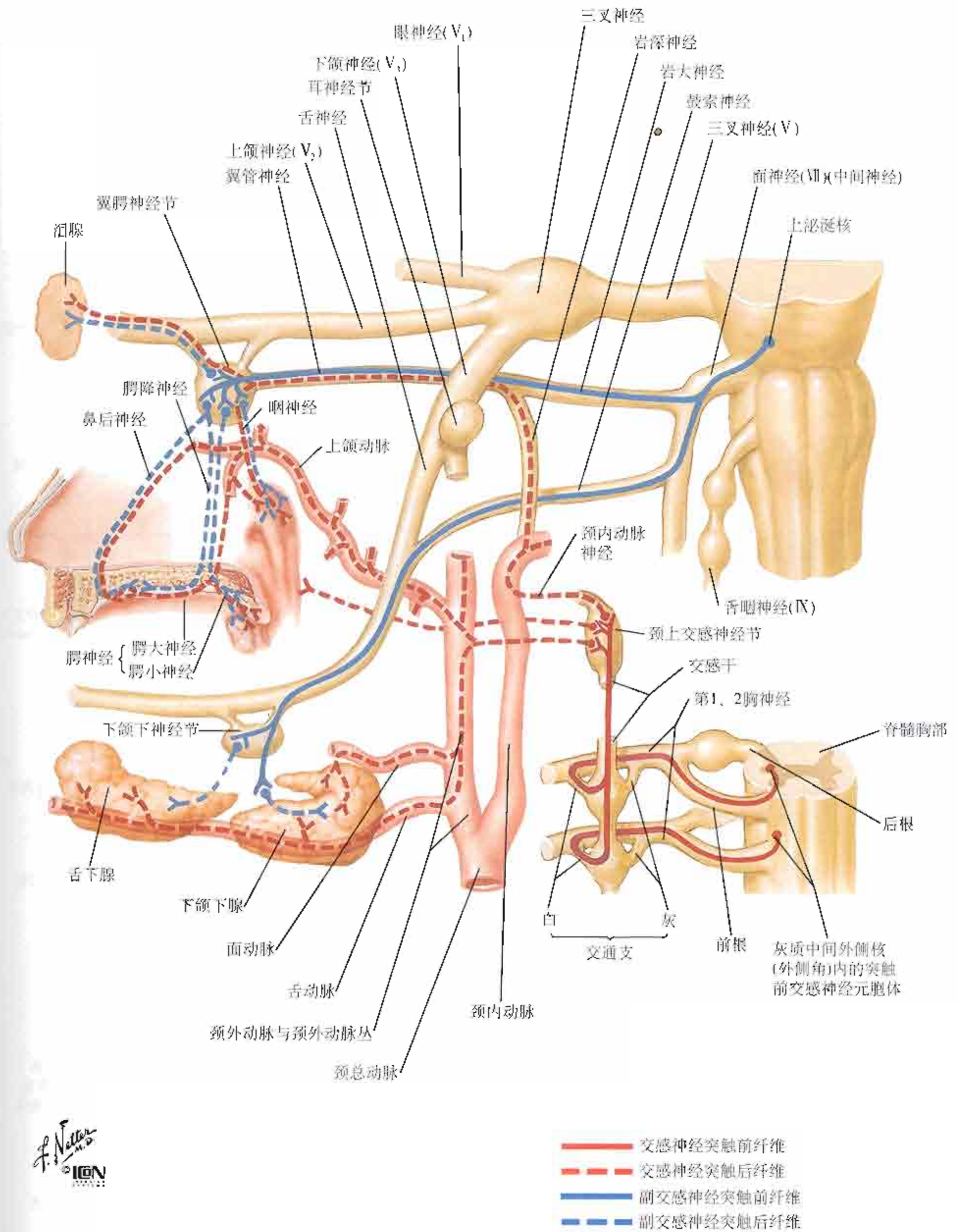


FIG. 125

睫状神经节：示意图

参见图160





耳神经节：示意图

参见图160

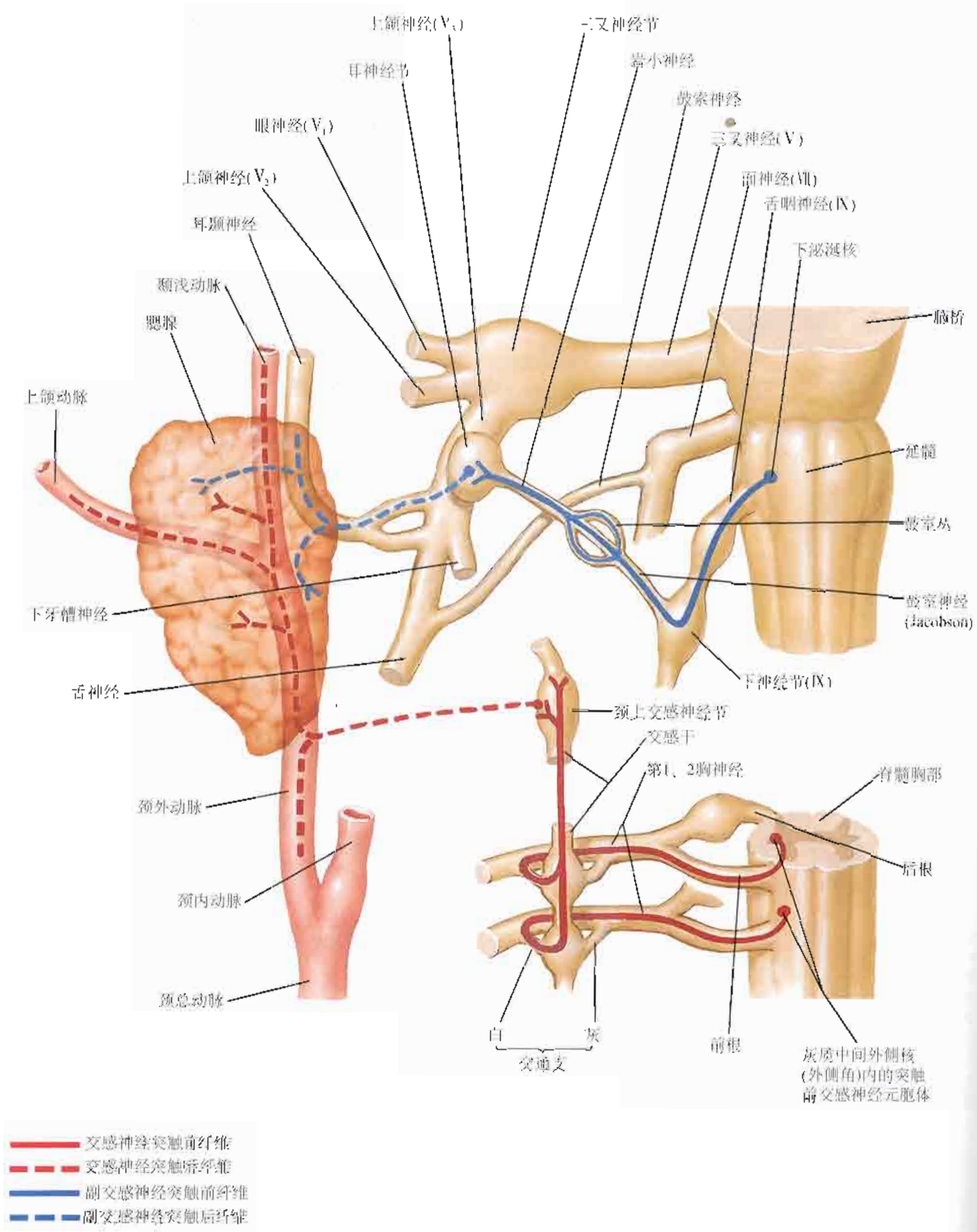
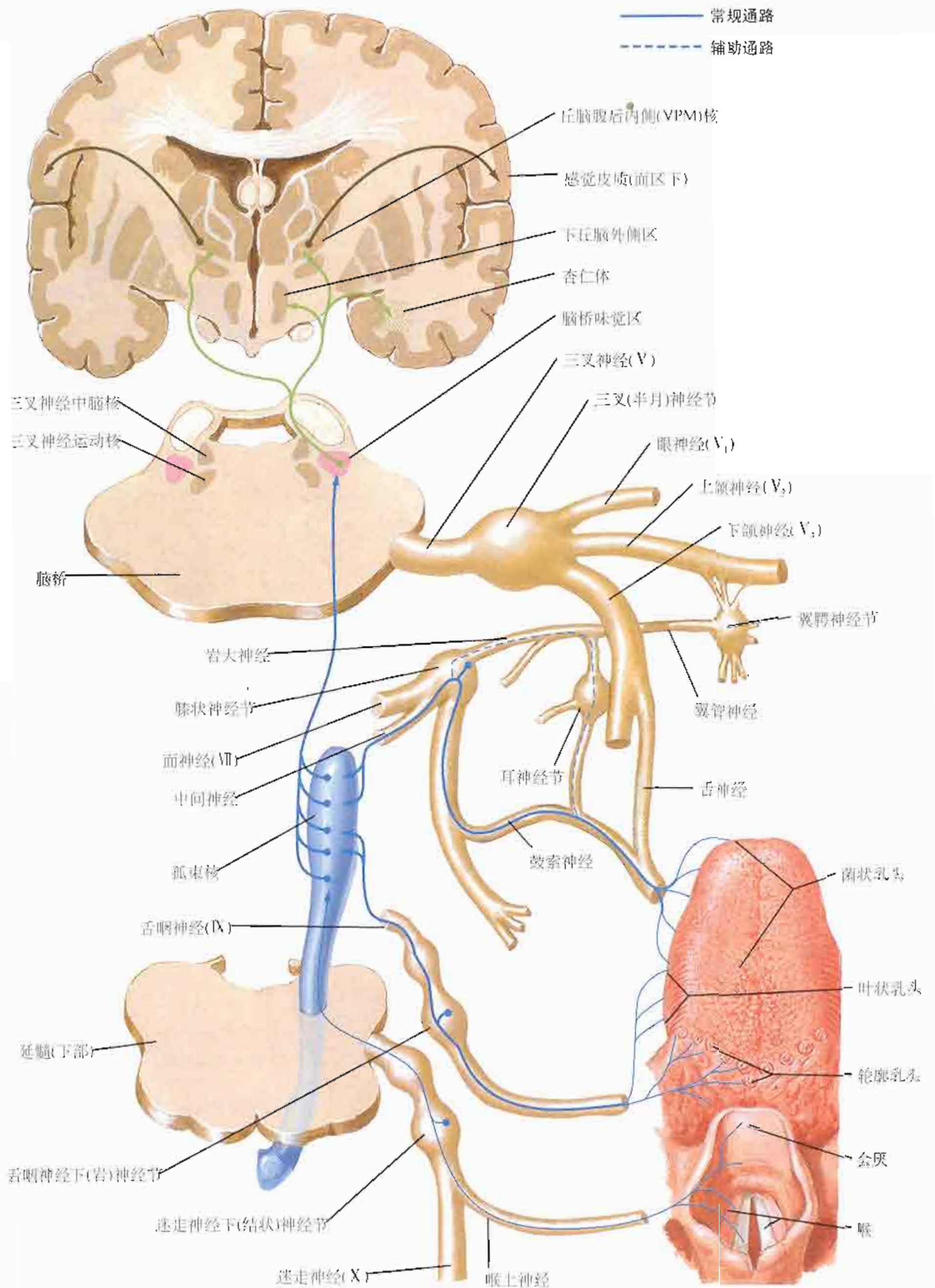


图128

参见图42、89、117、119、120



至脑与脑膜的动脉

参见图29、30

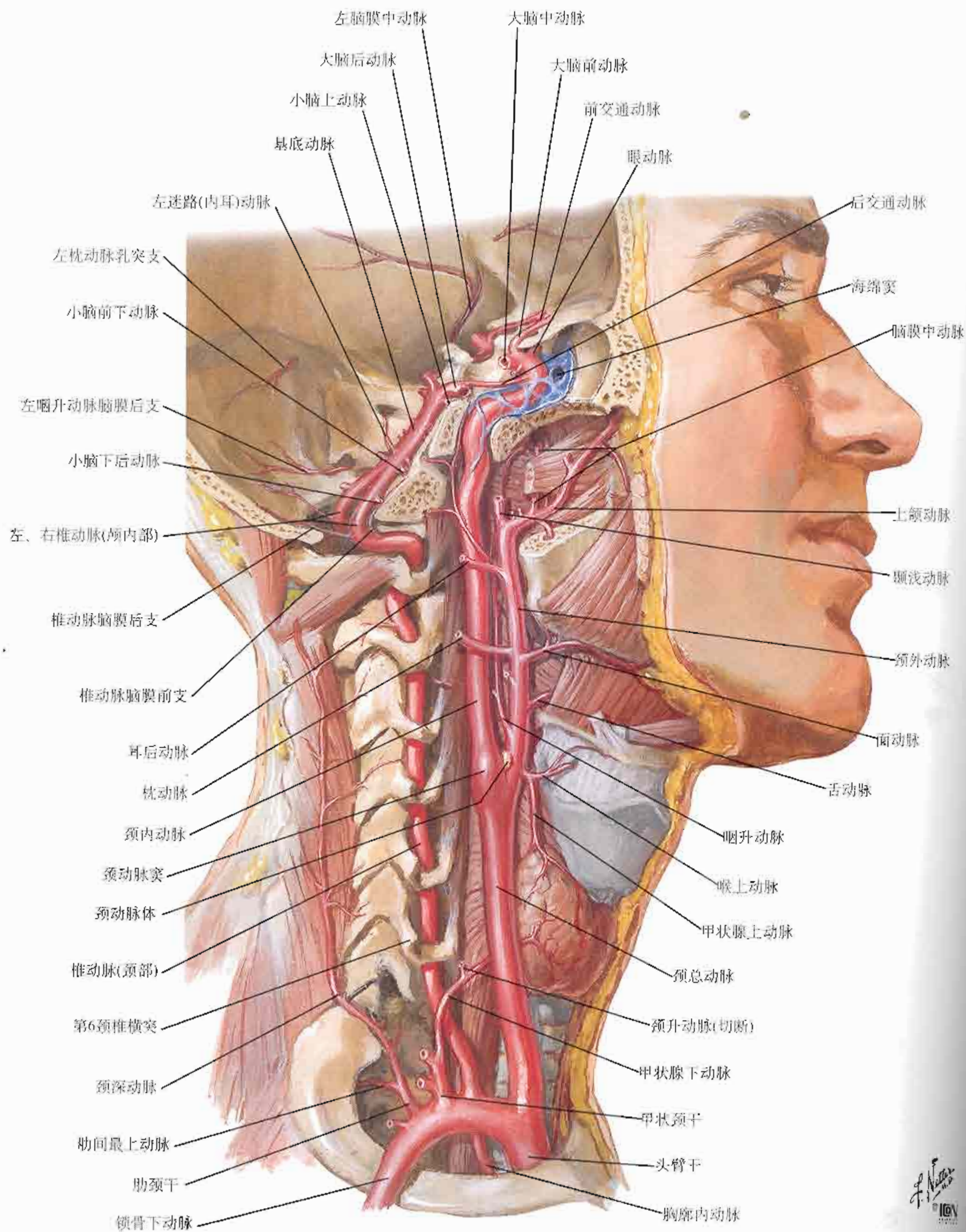
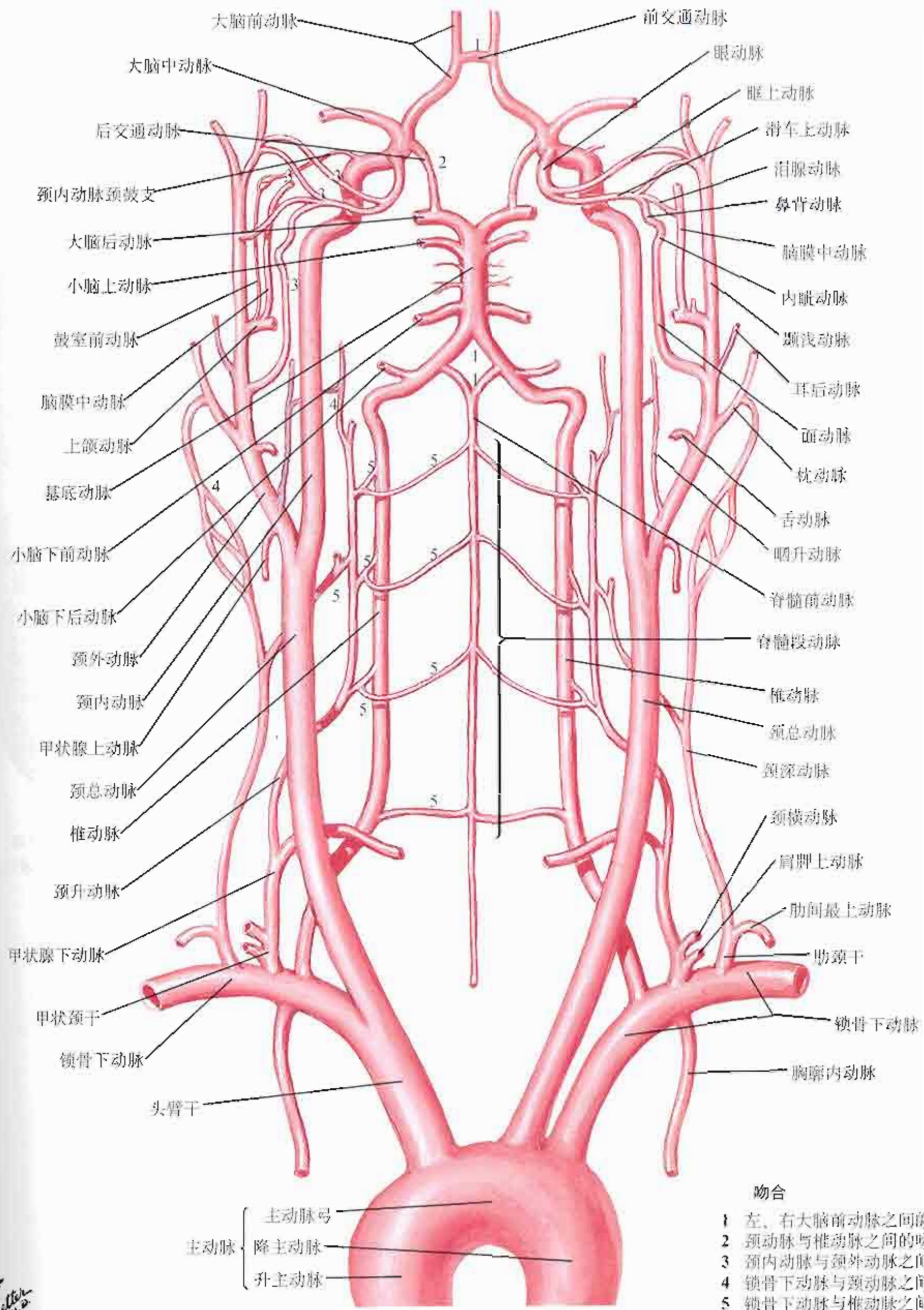


图130

头和颈



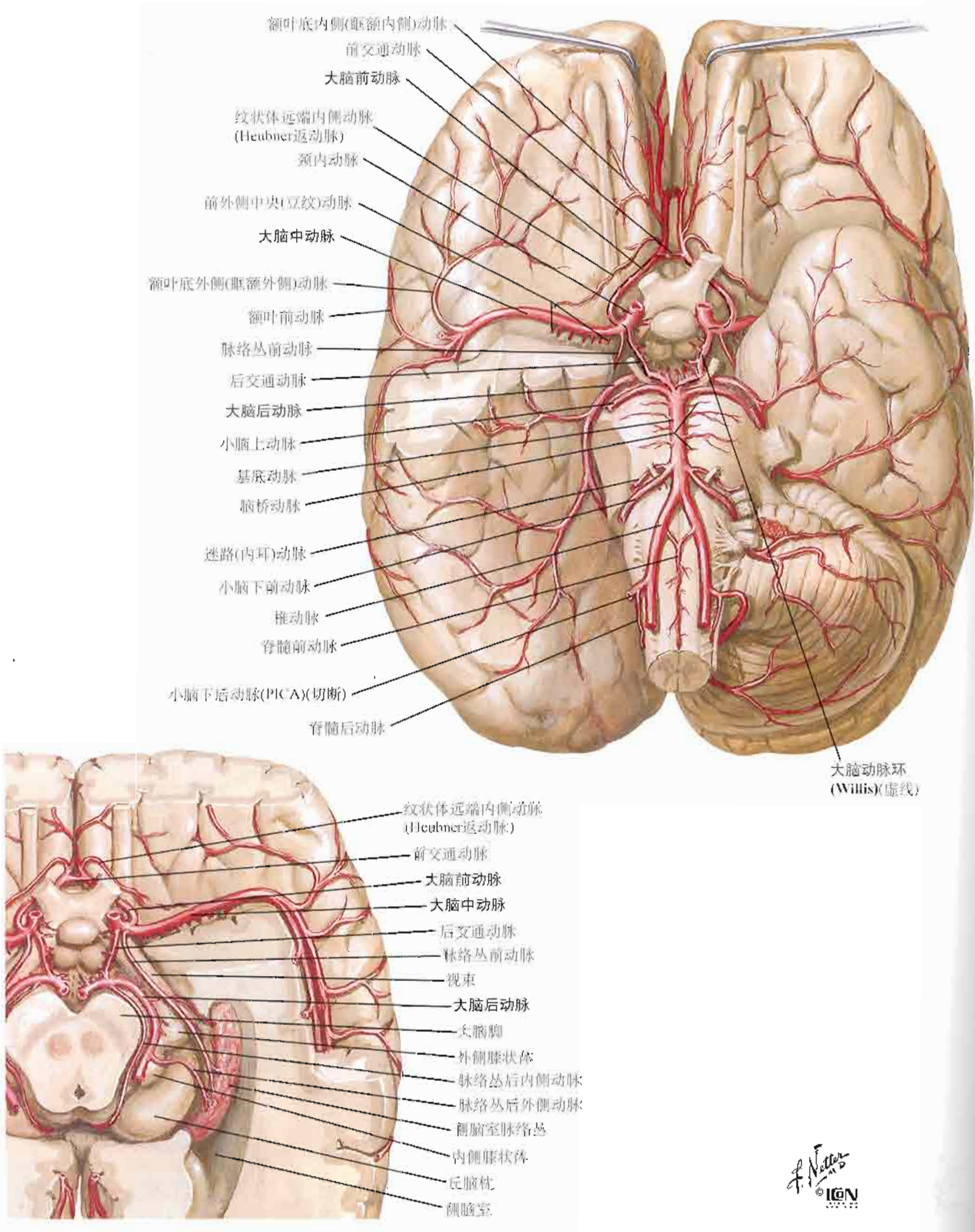
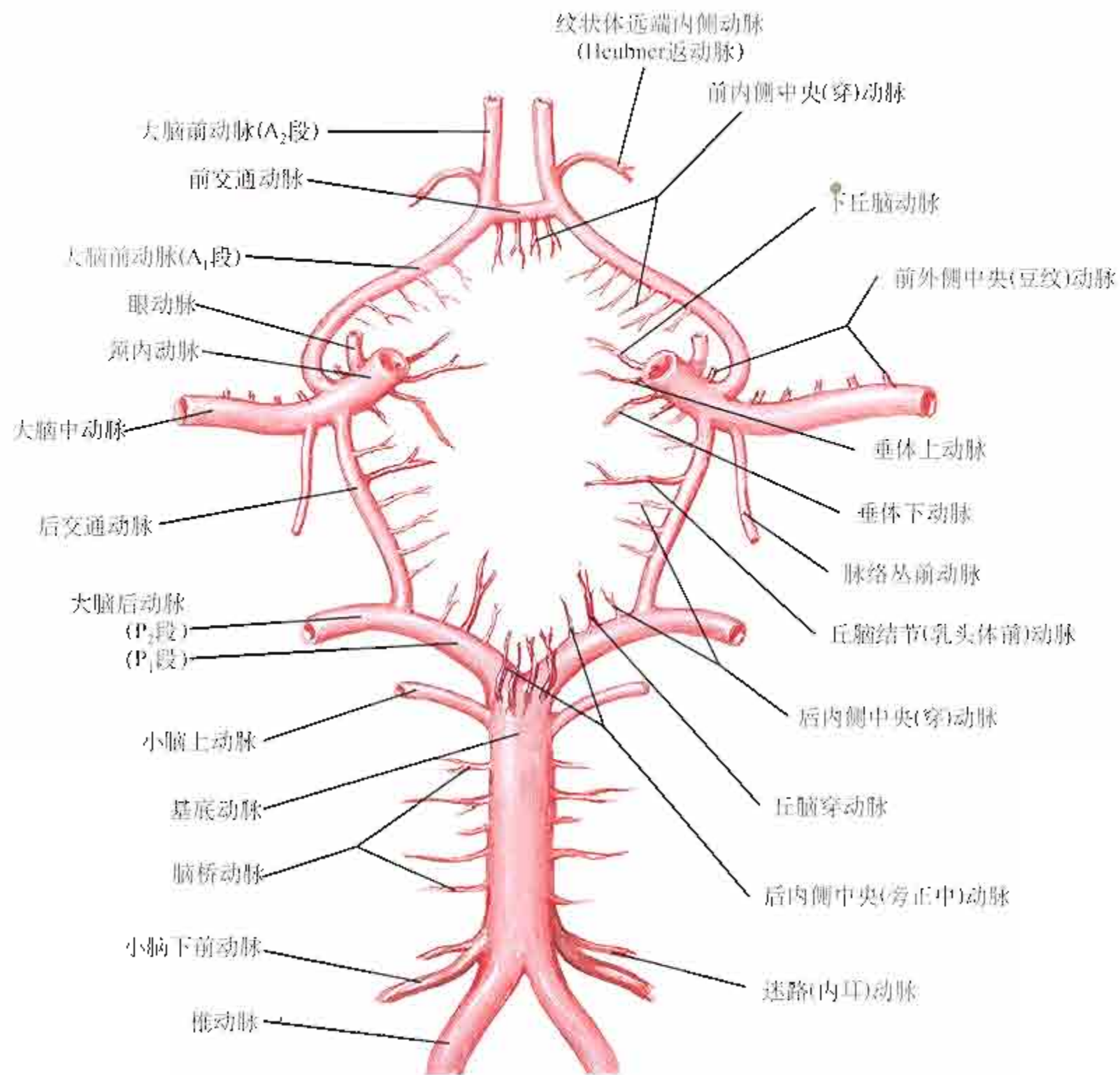


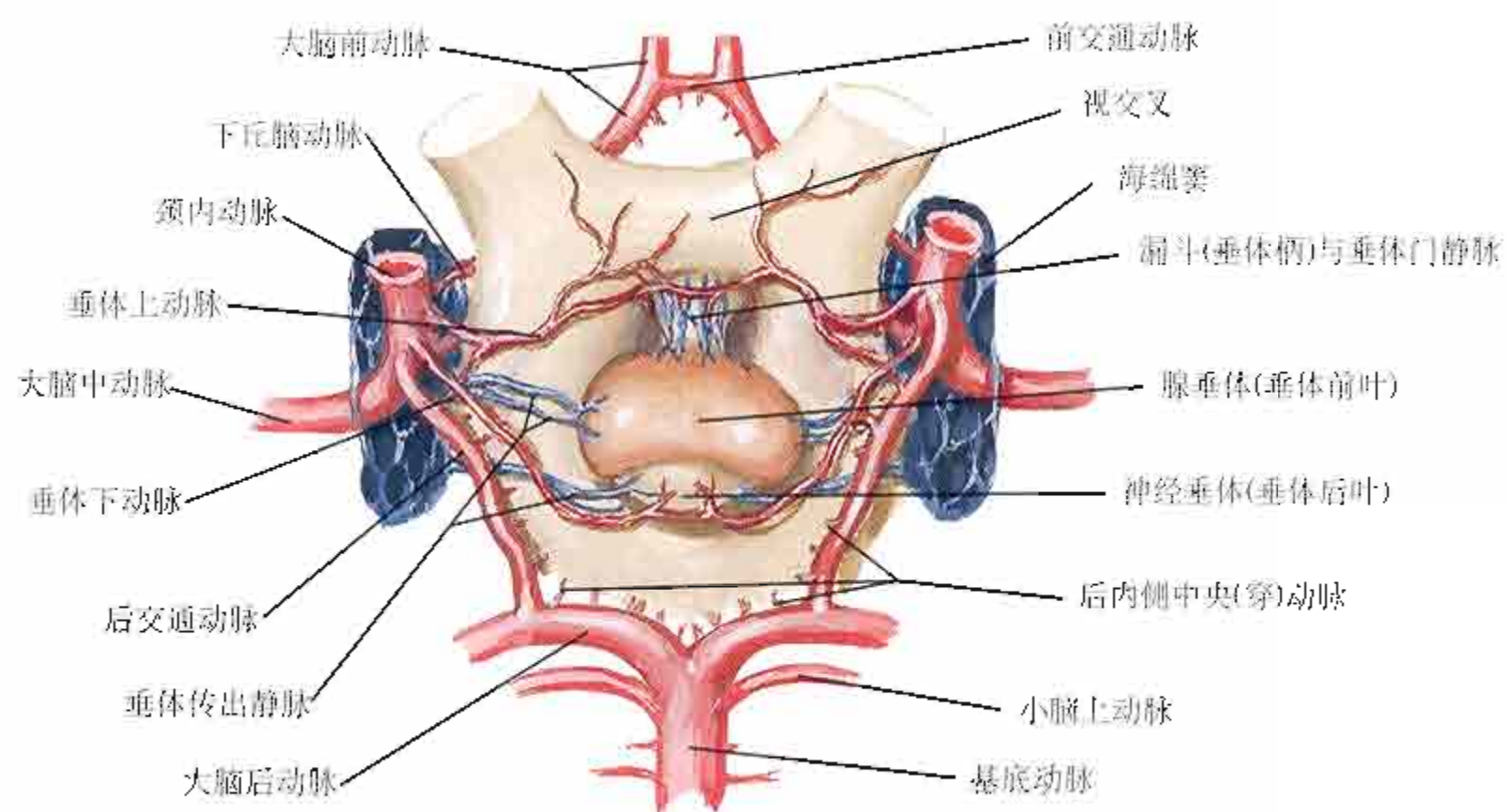
图132

分离出的血管：下面观

垂体动脉参见图141



原位血管：下面观



F. Netter M.D.
© ILEN

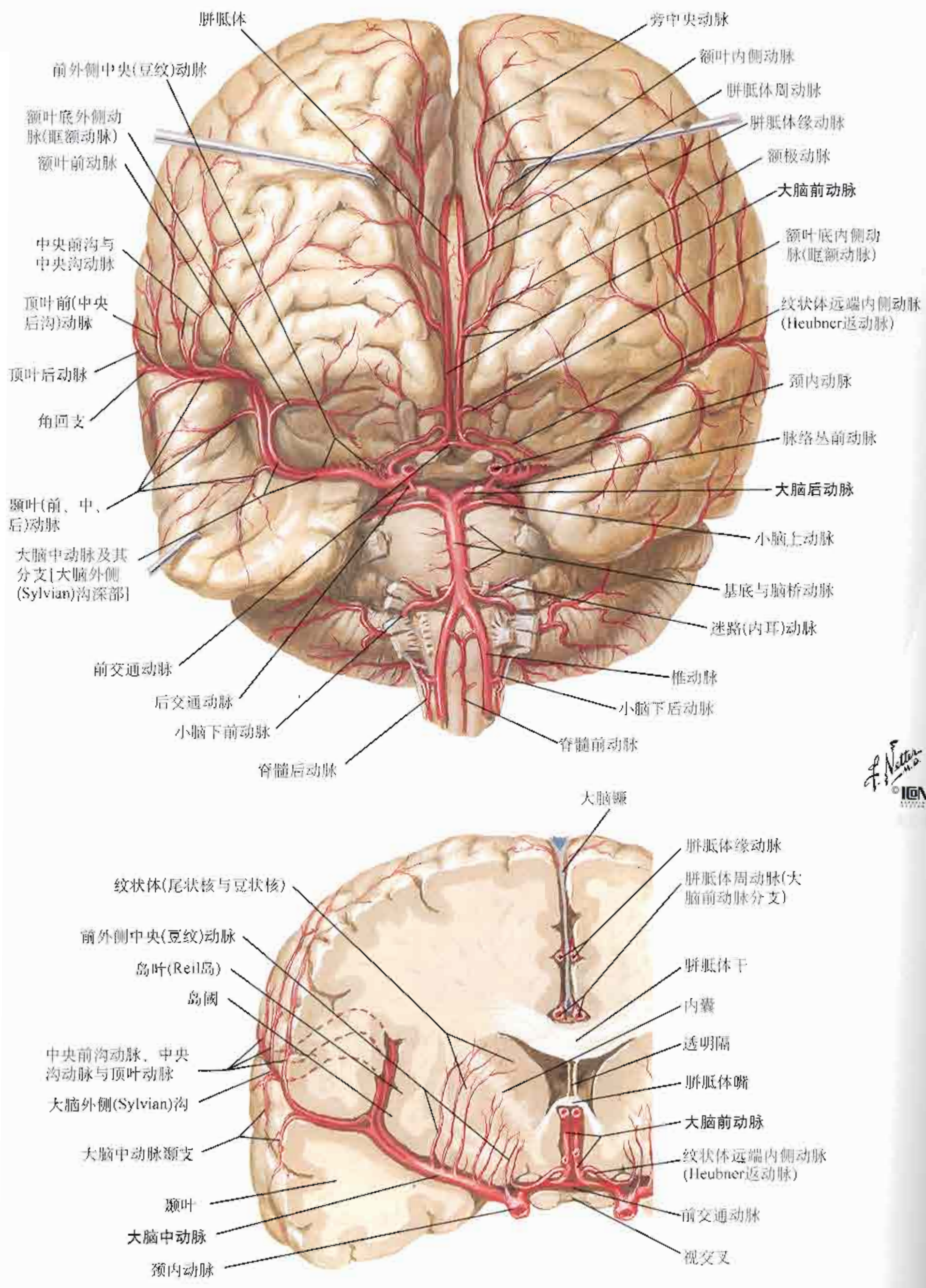
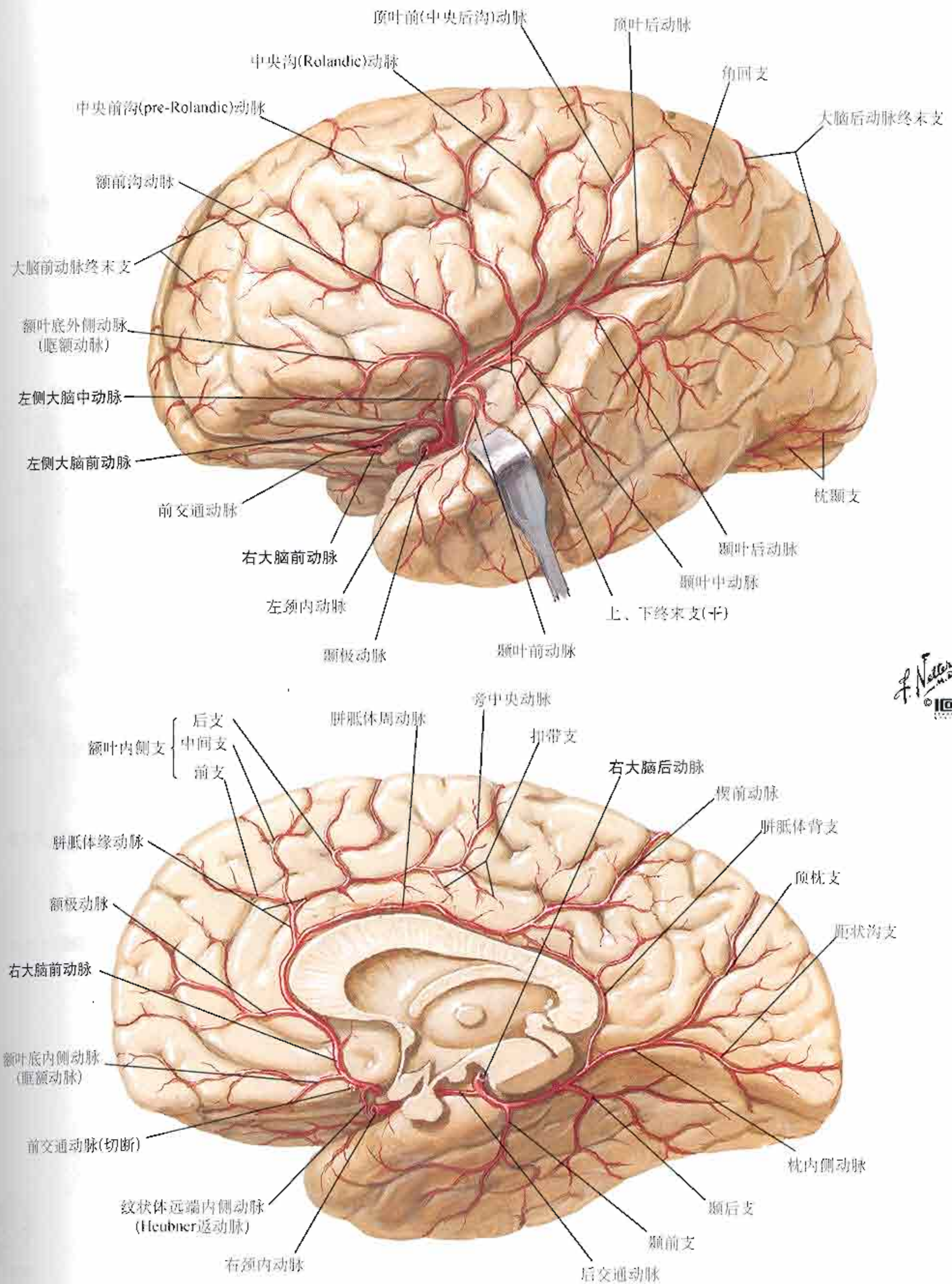


图134



F. Netter M.D.
© IGM

注: 顶叶前(中央后沟)动脉也可以分为单独的顶前动脉与中央后沟动脉

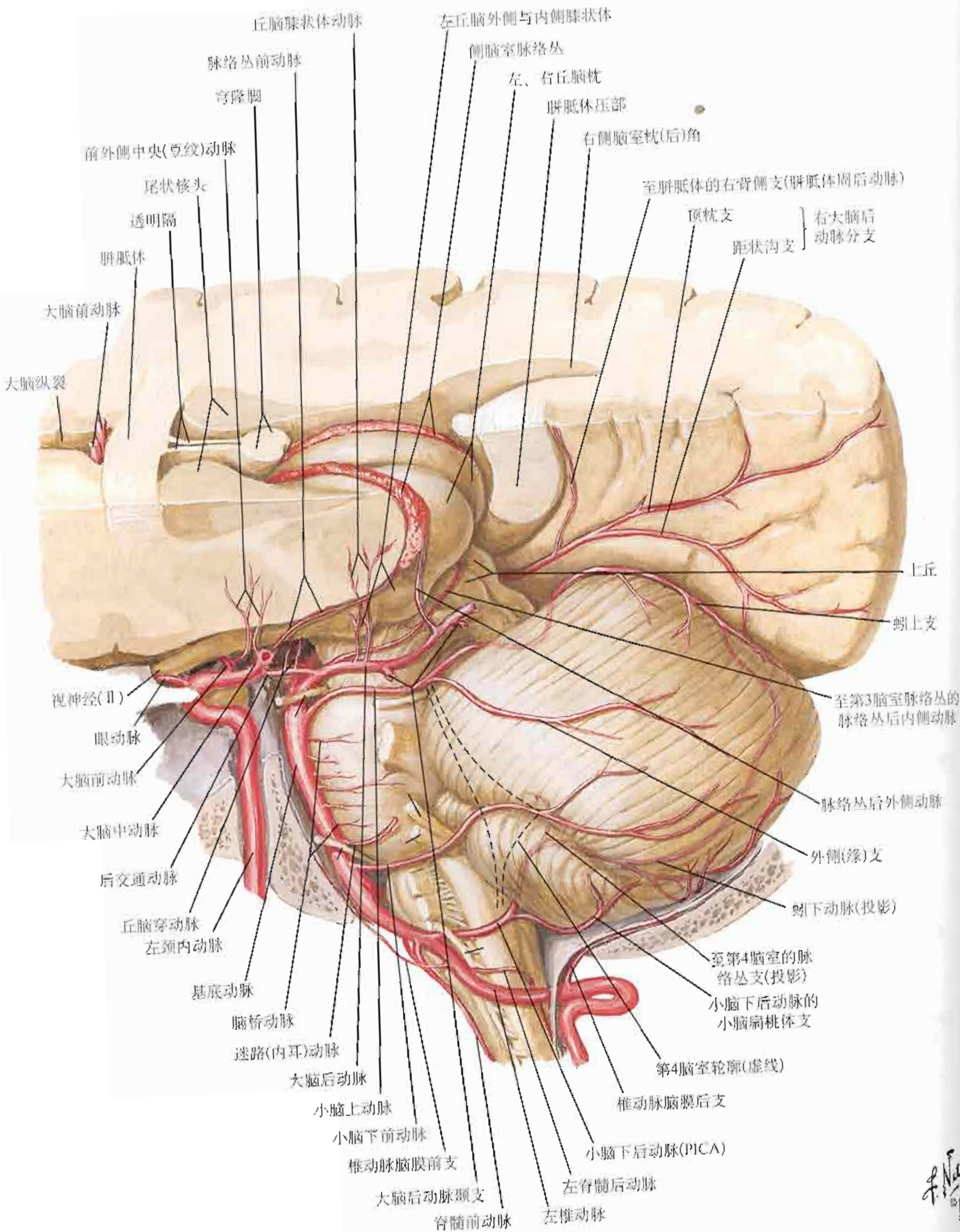
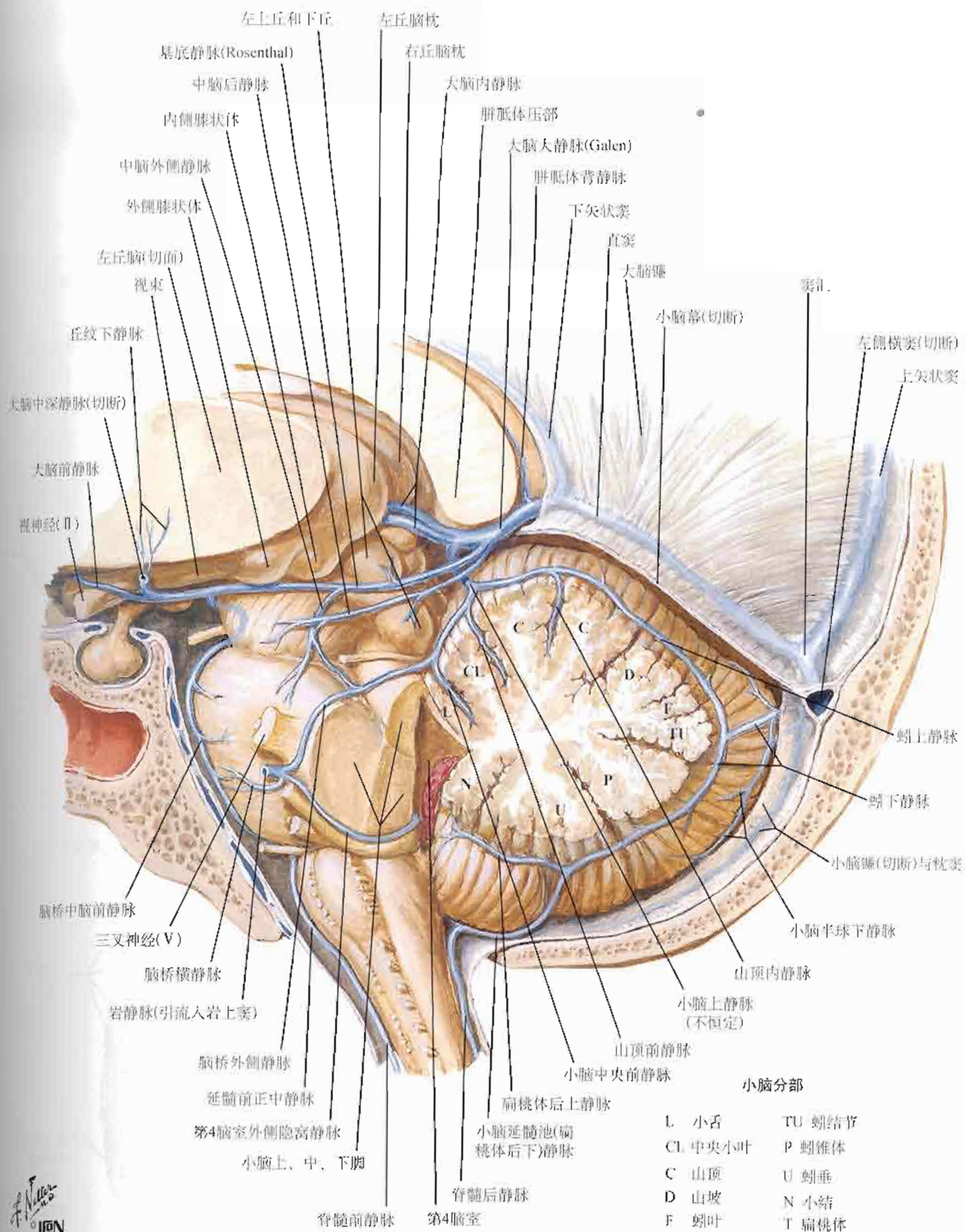
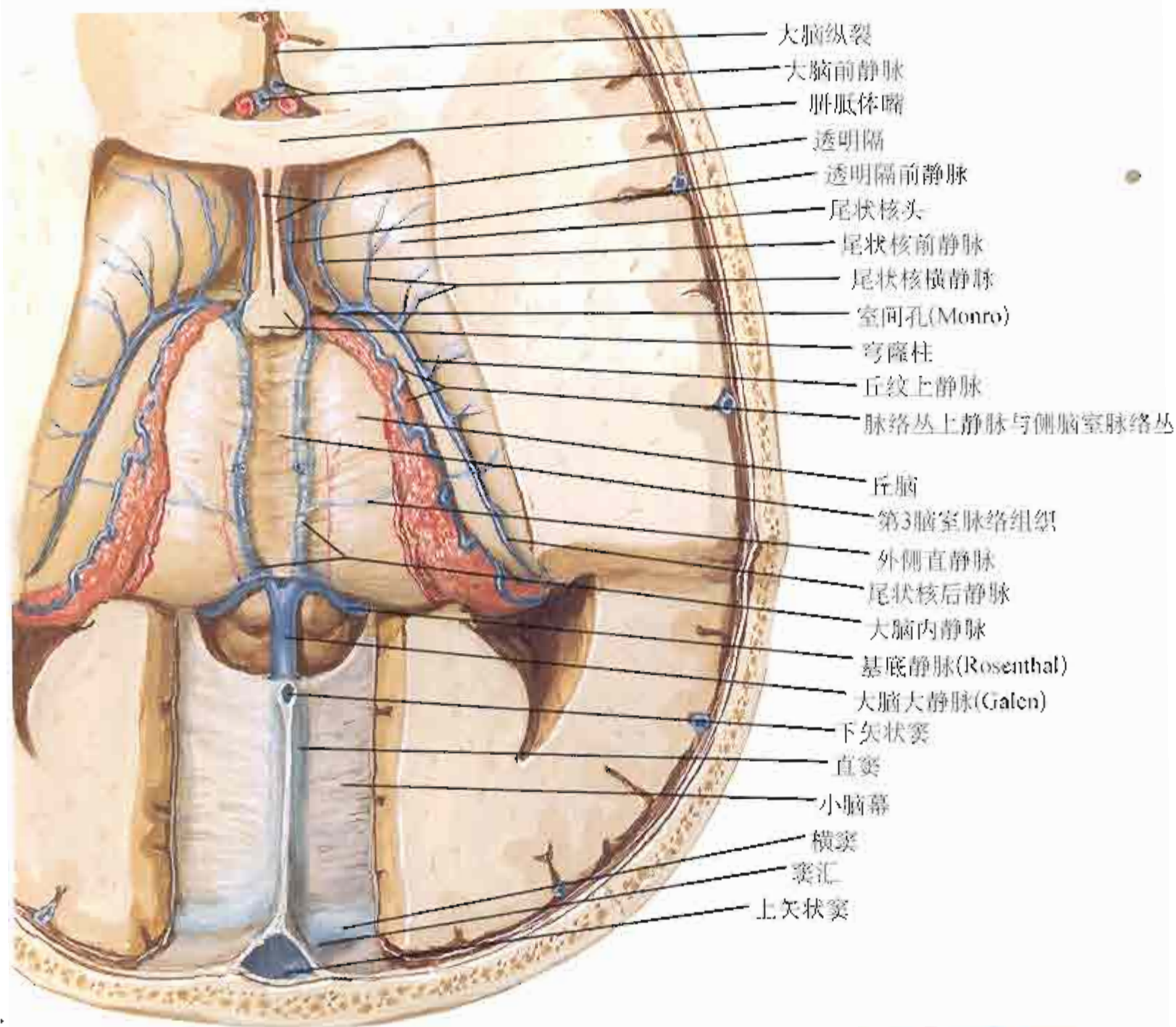


图136

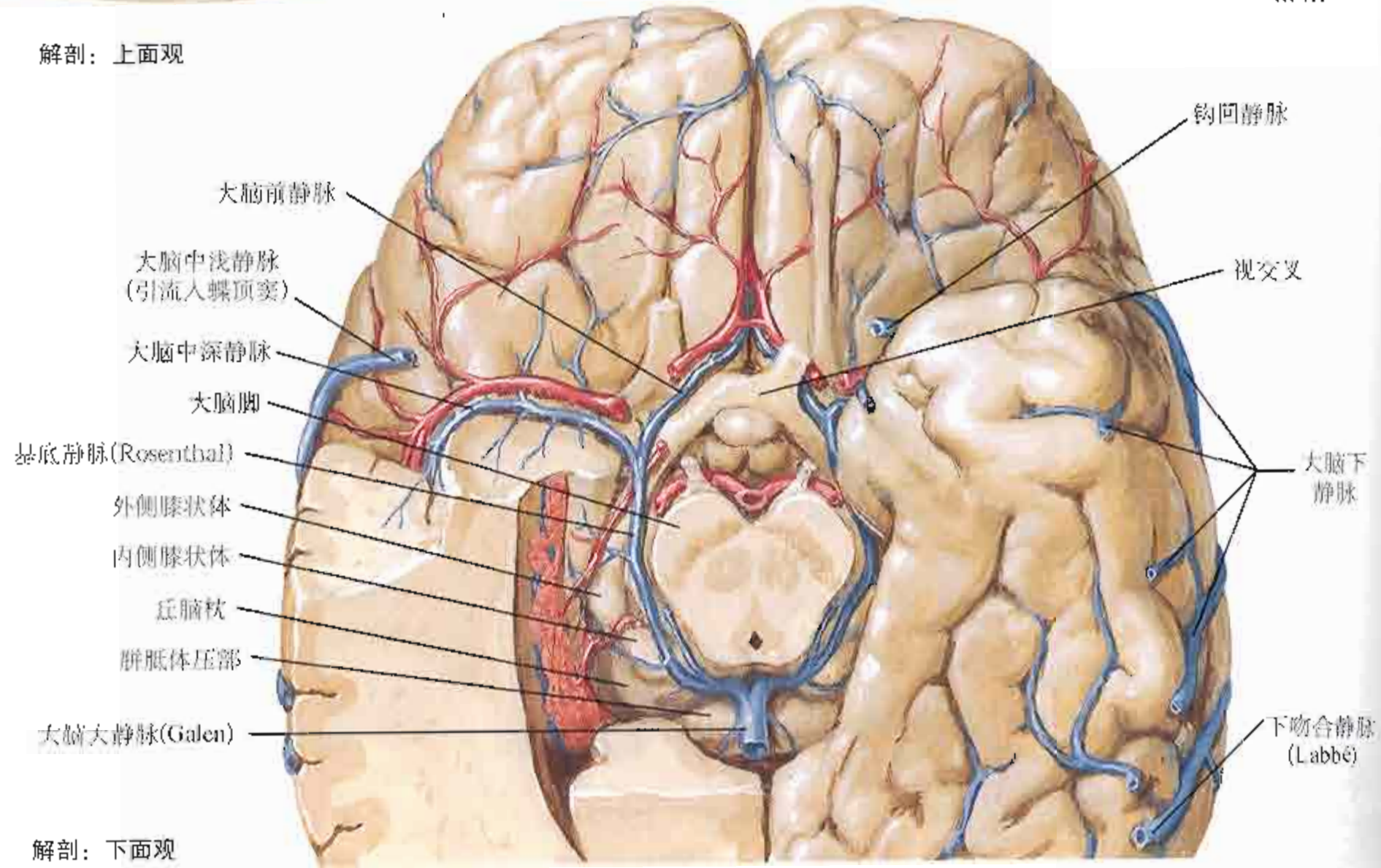


脑的深静脉

脑浅静脉参见图96

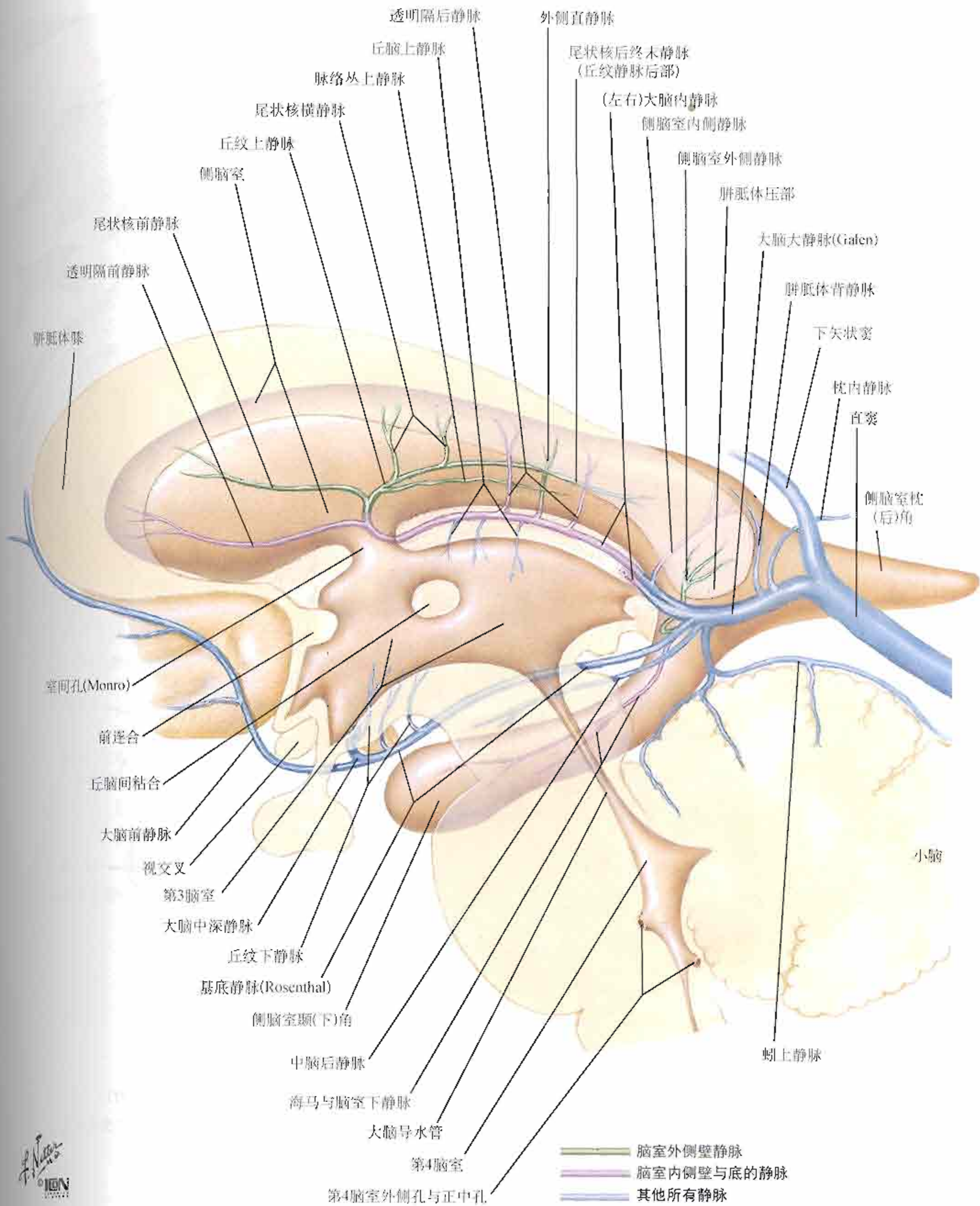


解剖：上面观



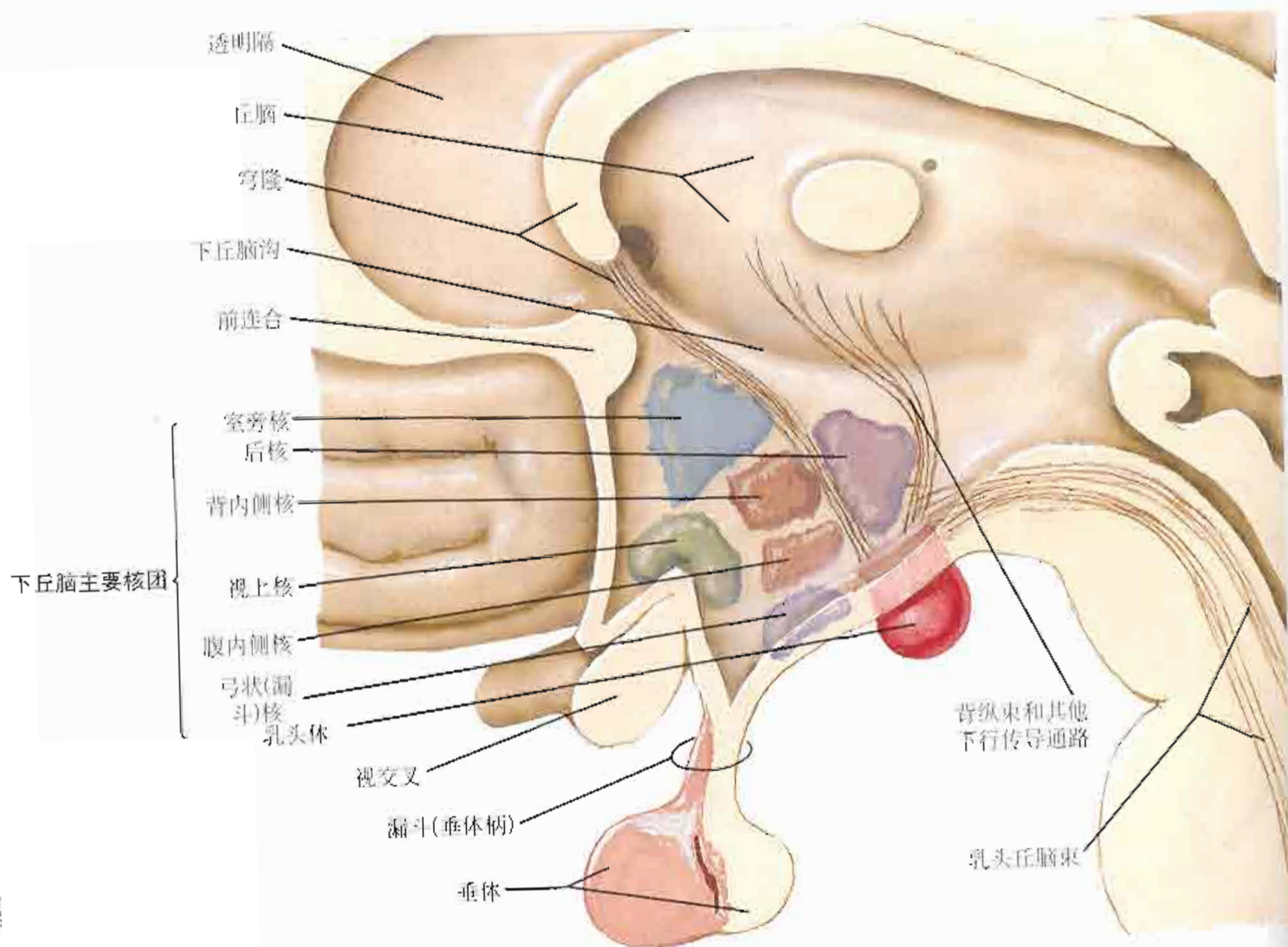
解剖：下面观

图138



下丘脑和垂体

参见图100、101



F. Netter M.D.
© IGM

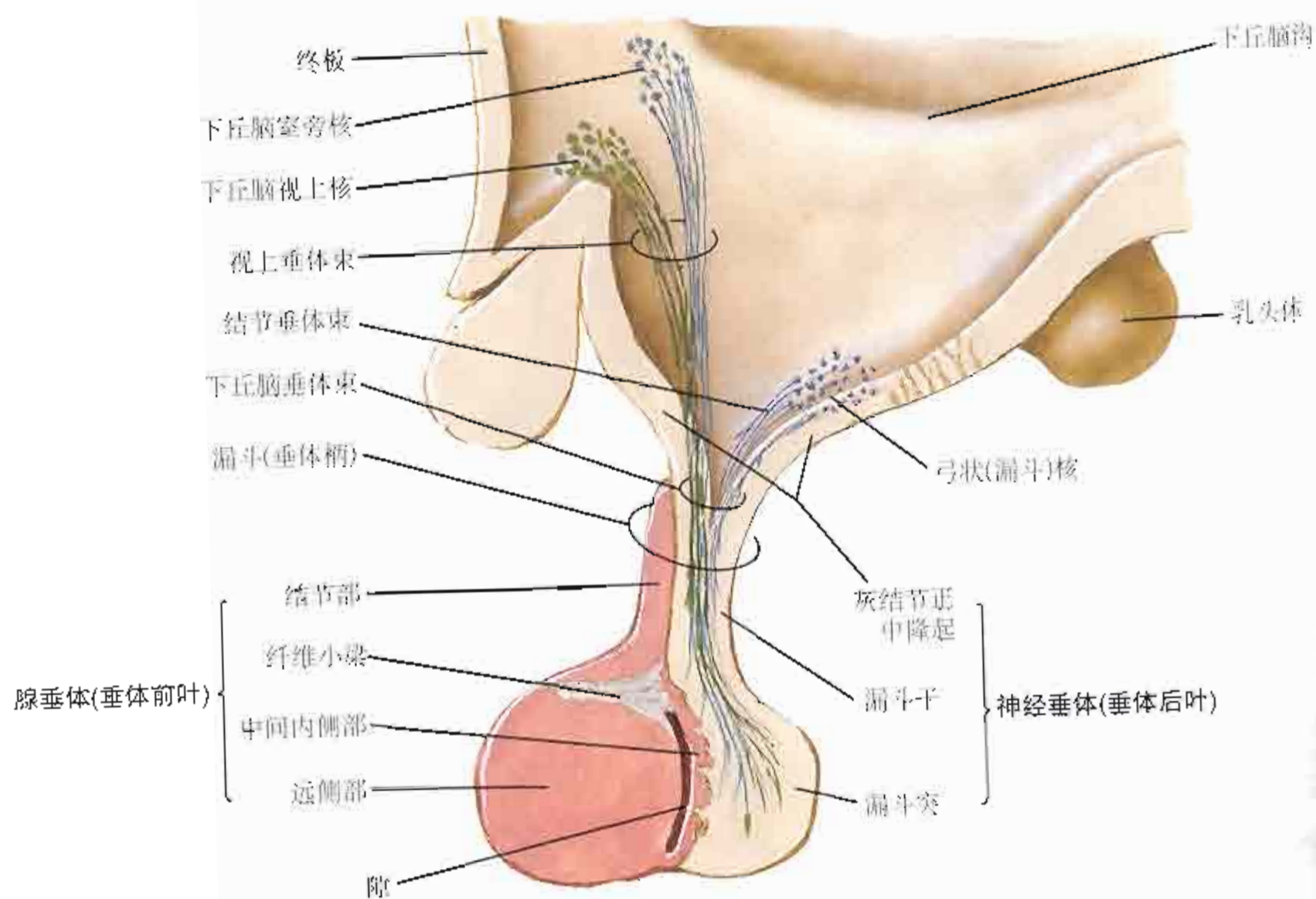
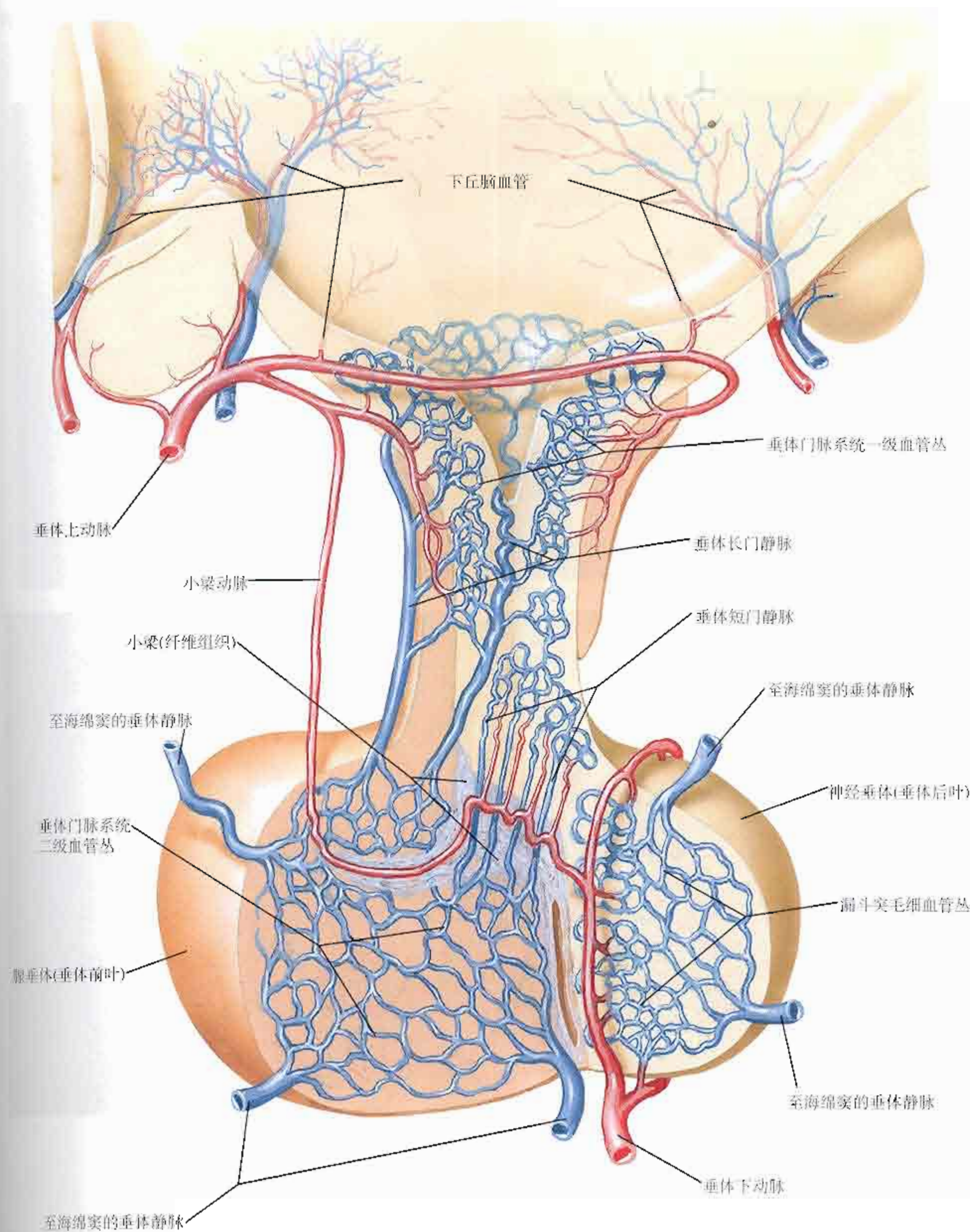


图140



F. Netter M.D. ILLUSTRATIONS

头部扫描：矢状位MRI影像

参见图100

正中(A)与旁正中(B,C)矢状位MRI影像

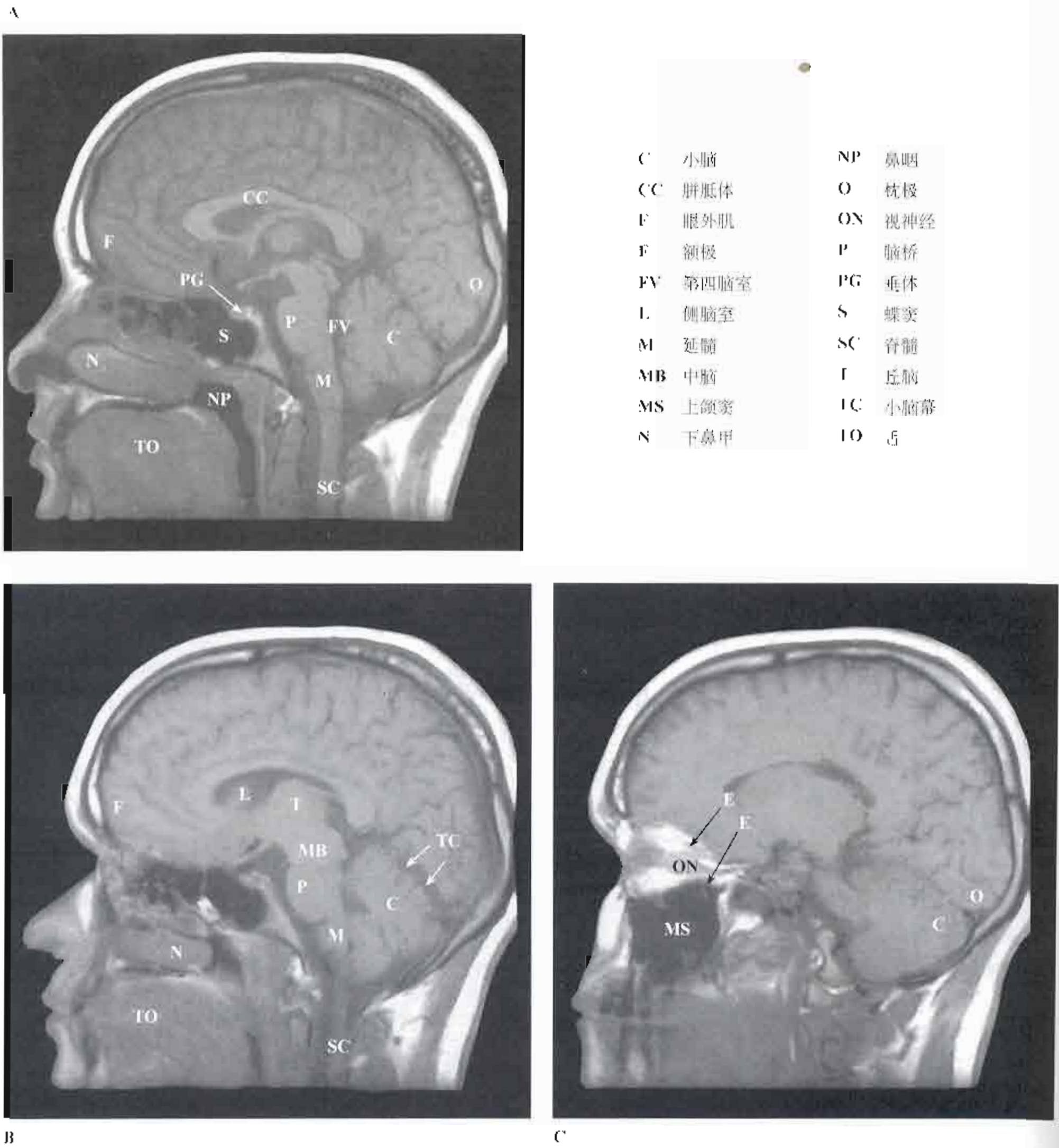
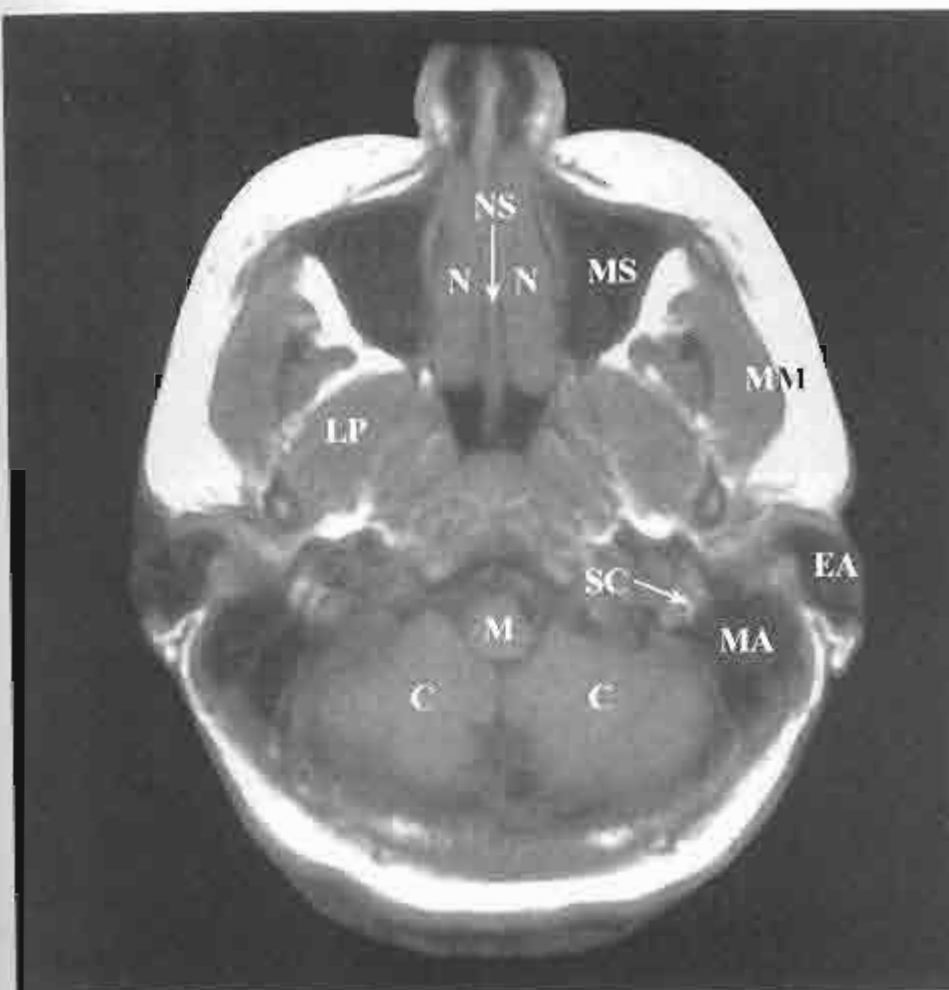


图142

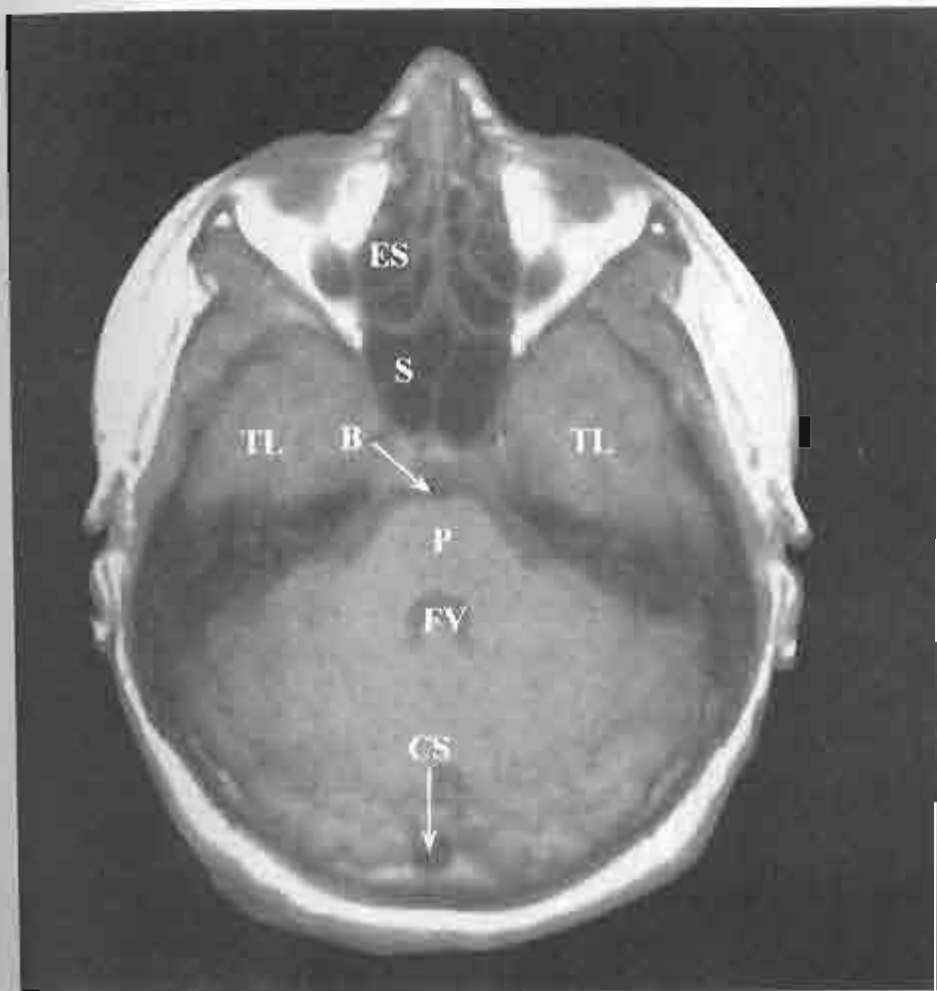
头和颈

从下(A)向上(C)头部轴位CT影像

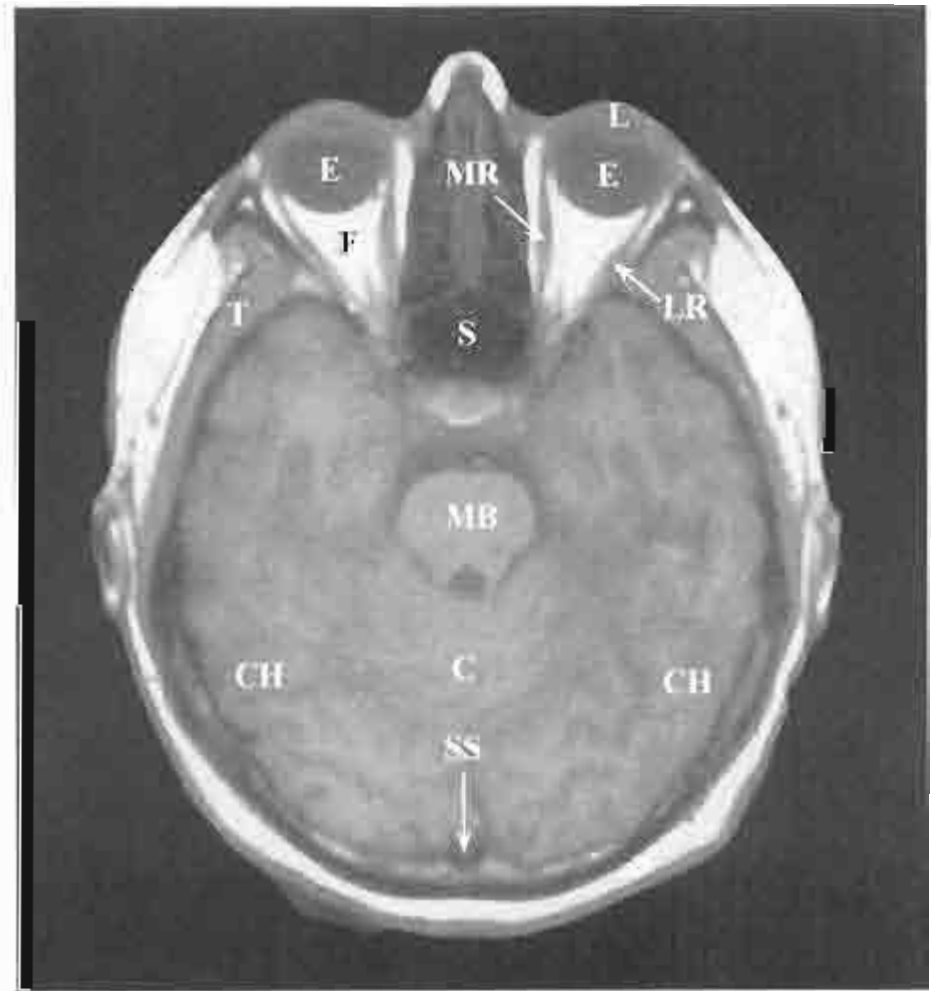
A



B	基底动脉	MA	乳突小房
C	小脑	MB	中脑
CH	大脑半球	MM	咬肌
CS	窦汇	MR	内直肌
E	眼	MS	上颌窦
EA	外耳道	N	鼻甲
ES	筛窦	NS	鼻中隔
F	眶脂体	P	脑桥
FV	第四脑室	S	蝶窦
L	晶状体	SC	半规管
LP	翼外肌	SS	上矢状窦
LR	外直肌	T	颞肌
M	延髓	TL	颞叶



B



C

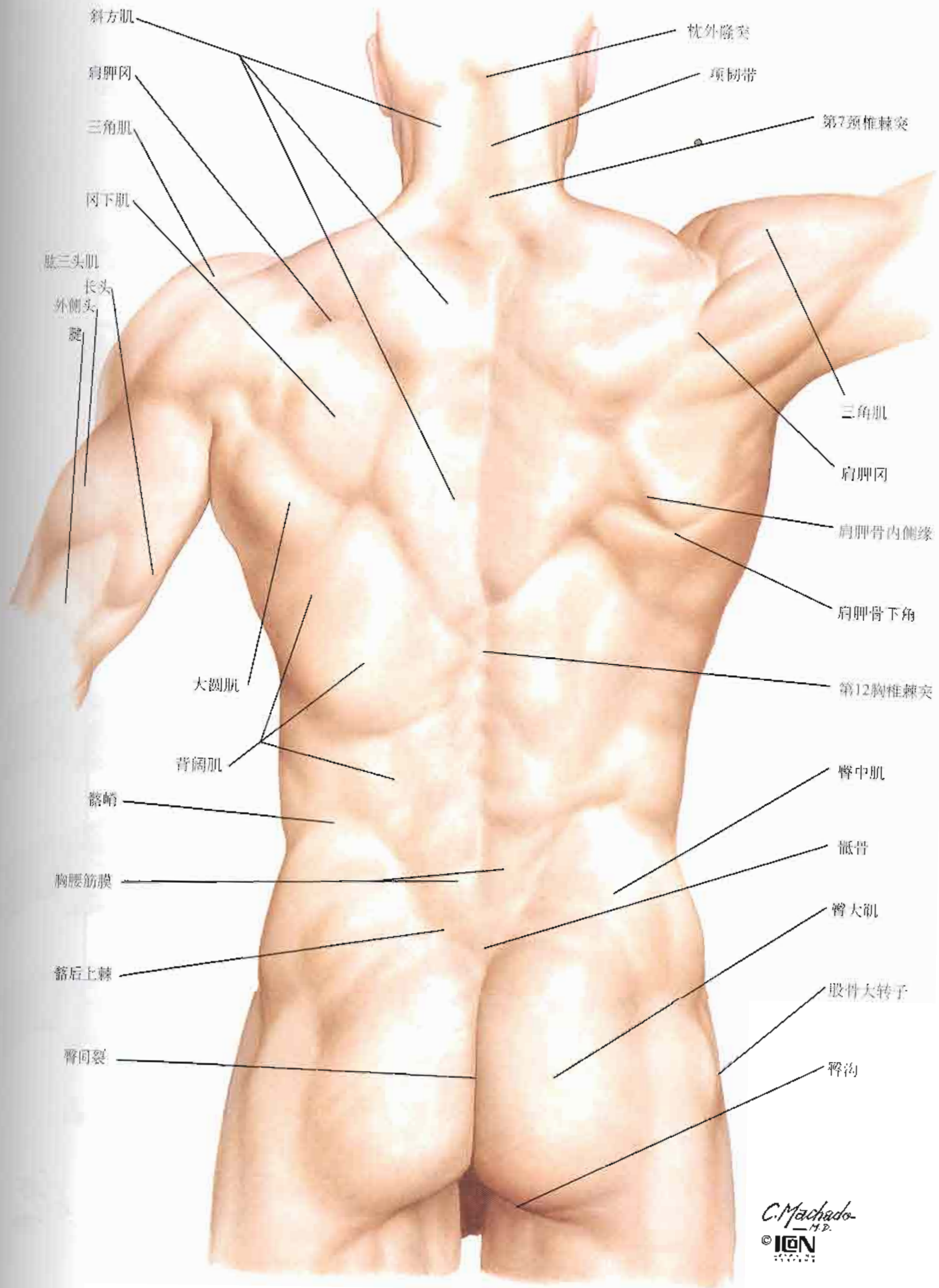
头部扫描：冠状位CT影像

参见图44、79

从前(A)向后(C)的头部冠状位CT影像

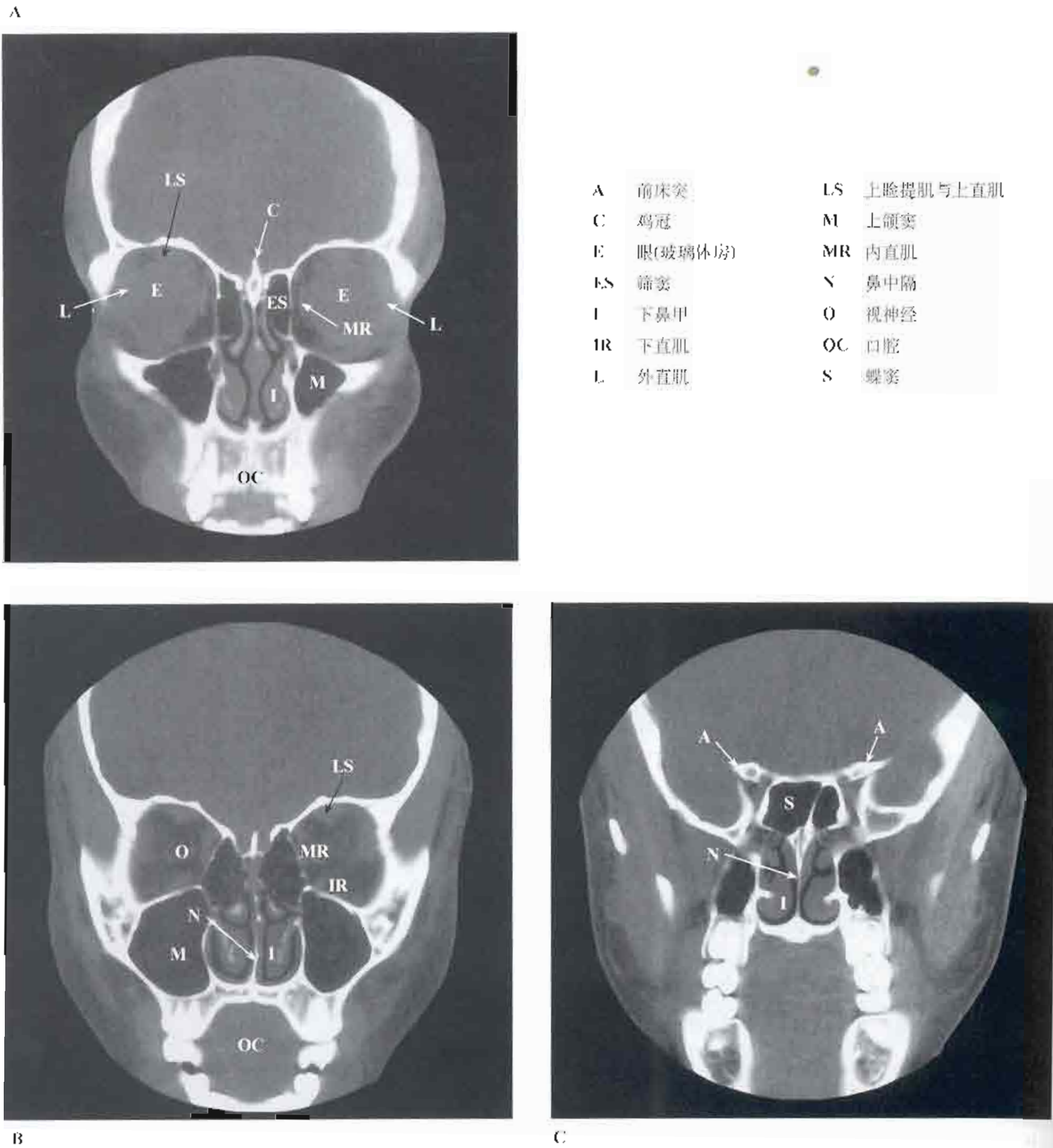

图144



参见图12、15、16、147、148、150、178、240

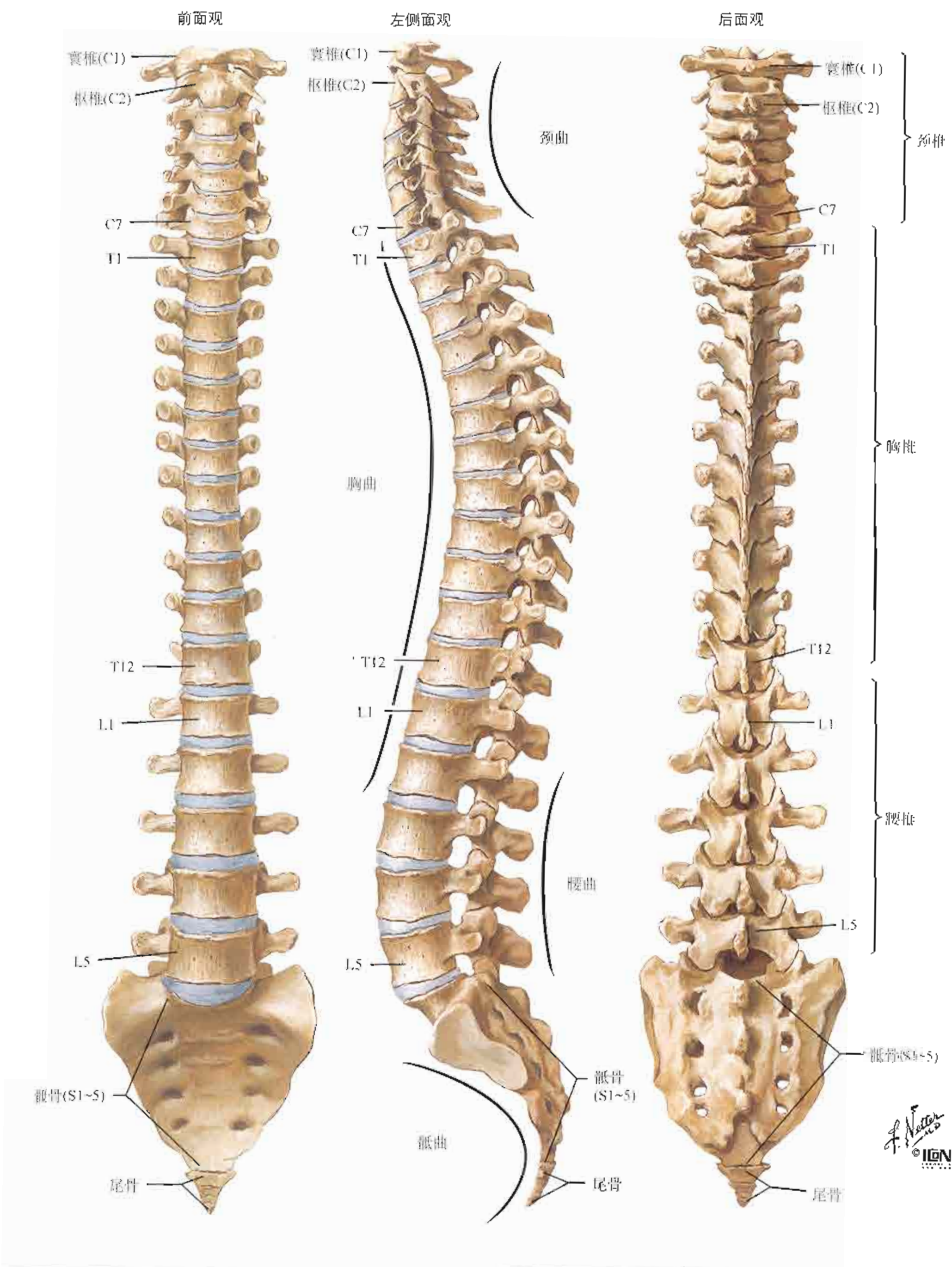
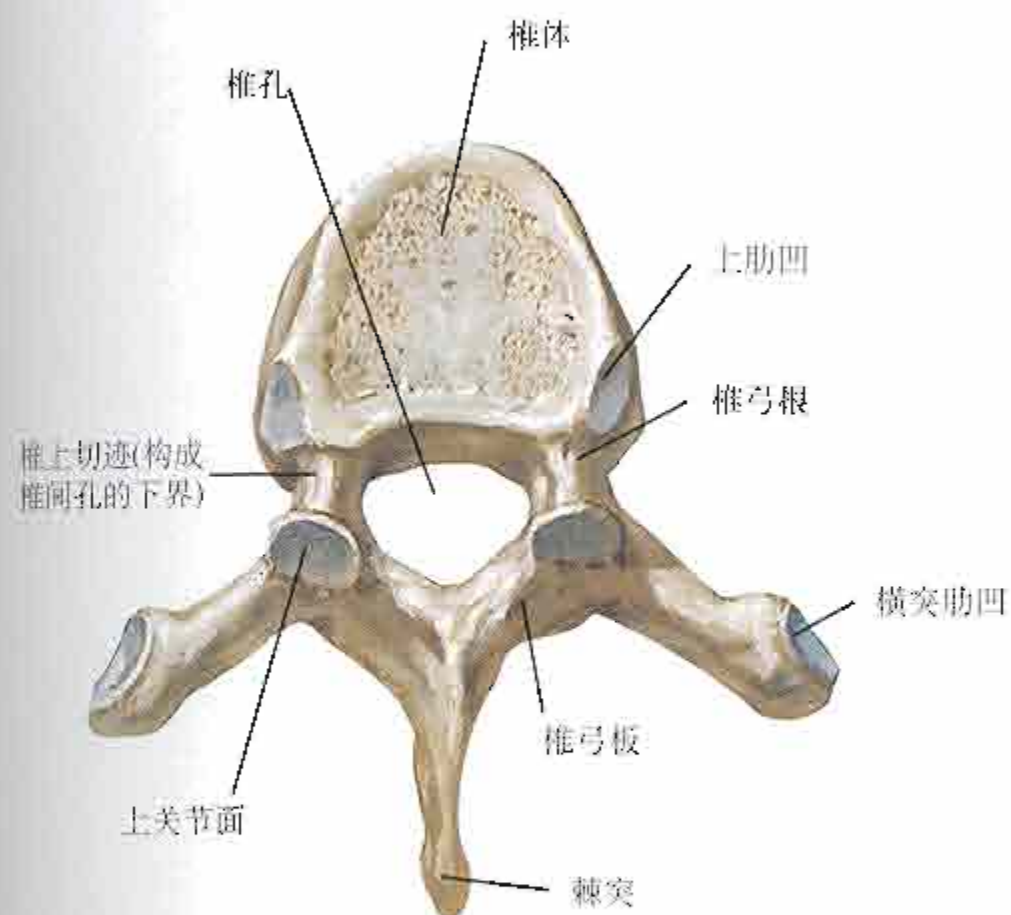
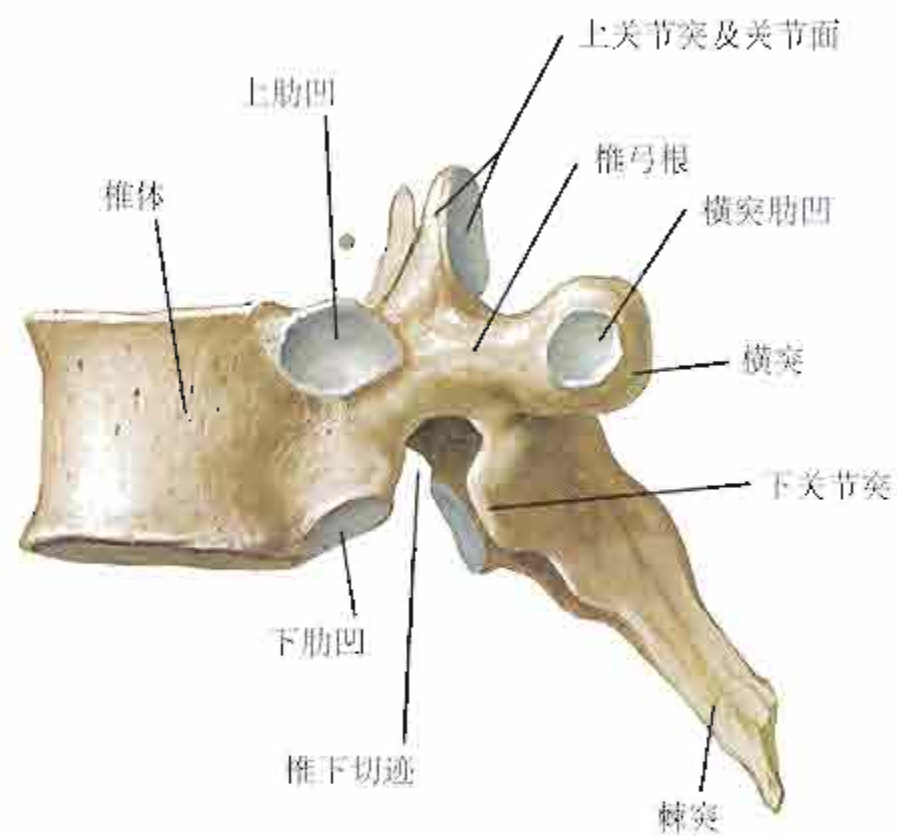


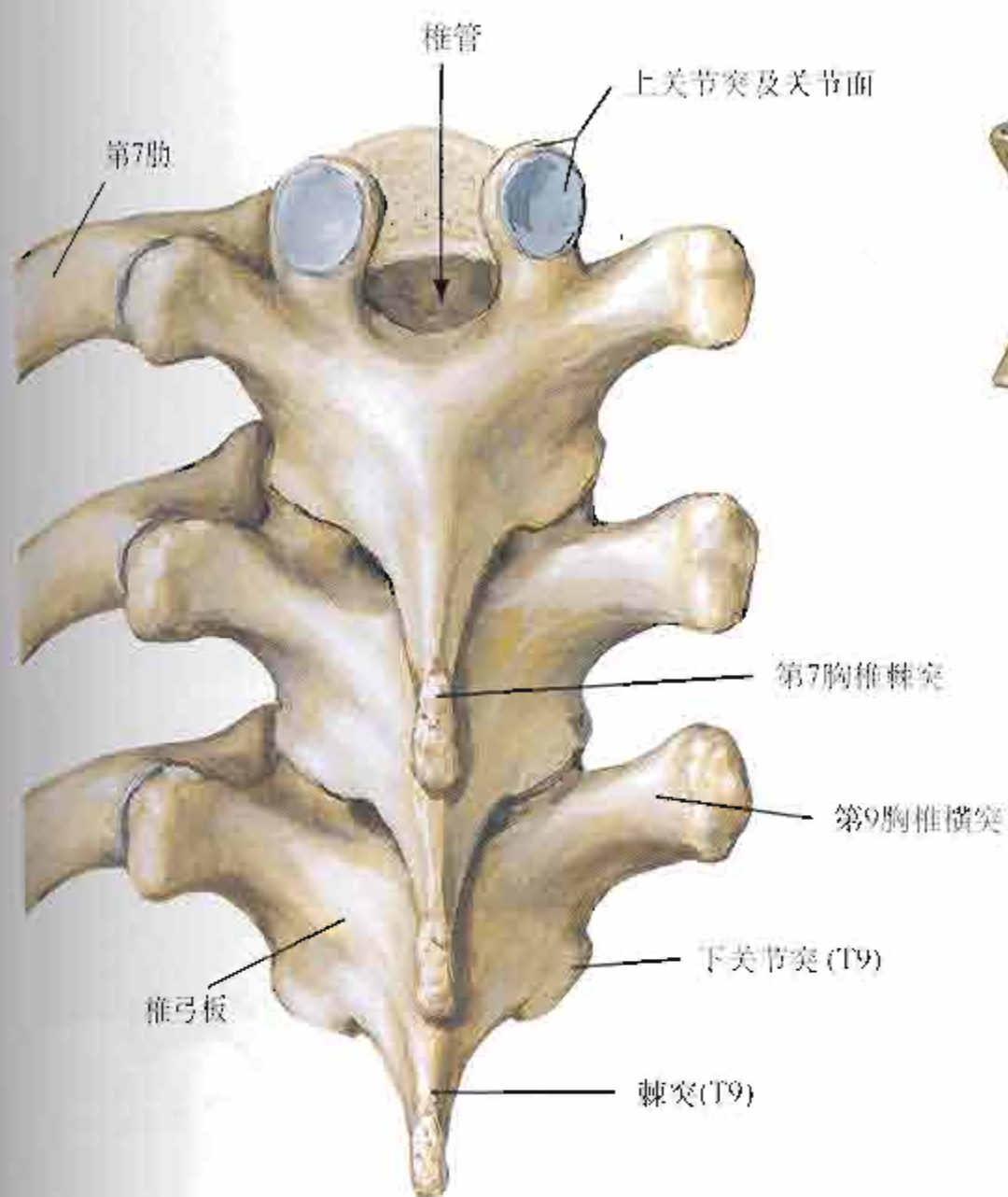
图146



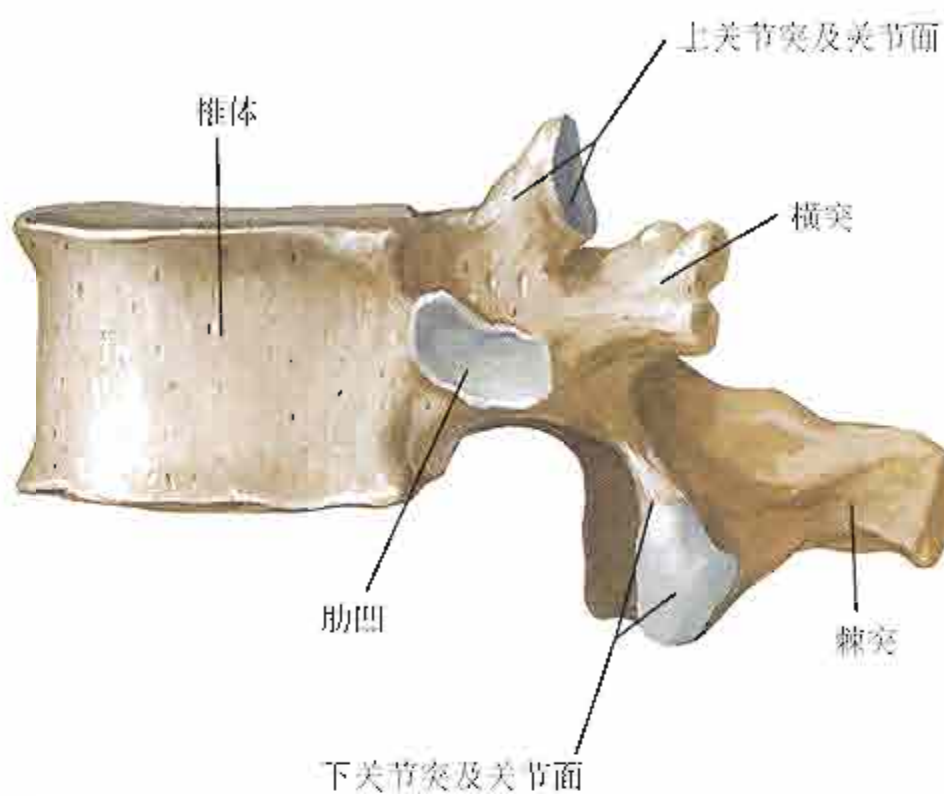
第6胸椎：上面观



第6胸椎：外侧面观



第7、8、9胸椎：后面观



第12胸椎：外侧面观

F. Netter M.D.
© IGV

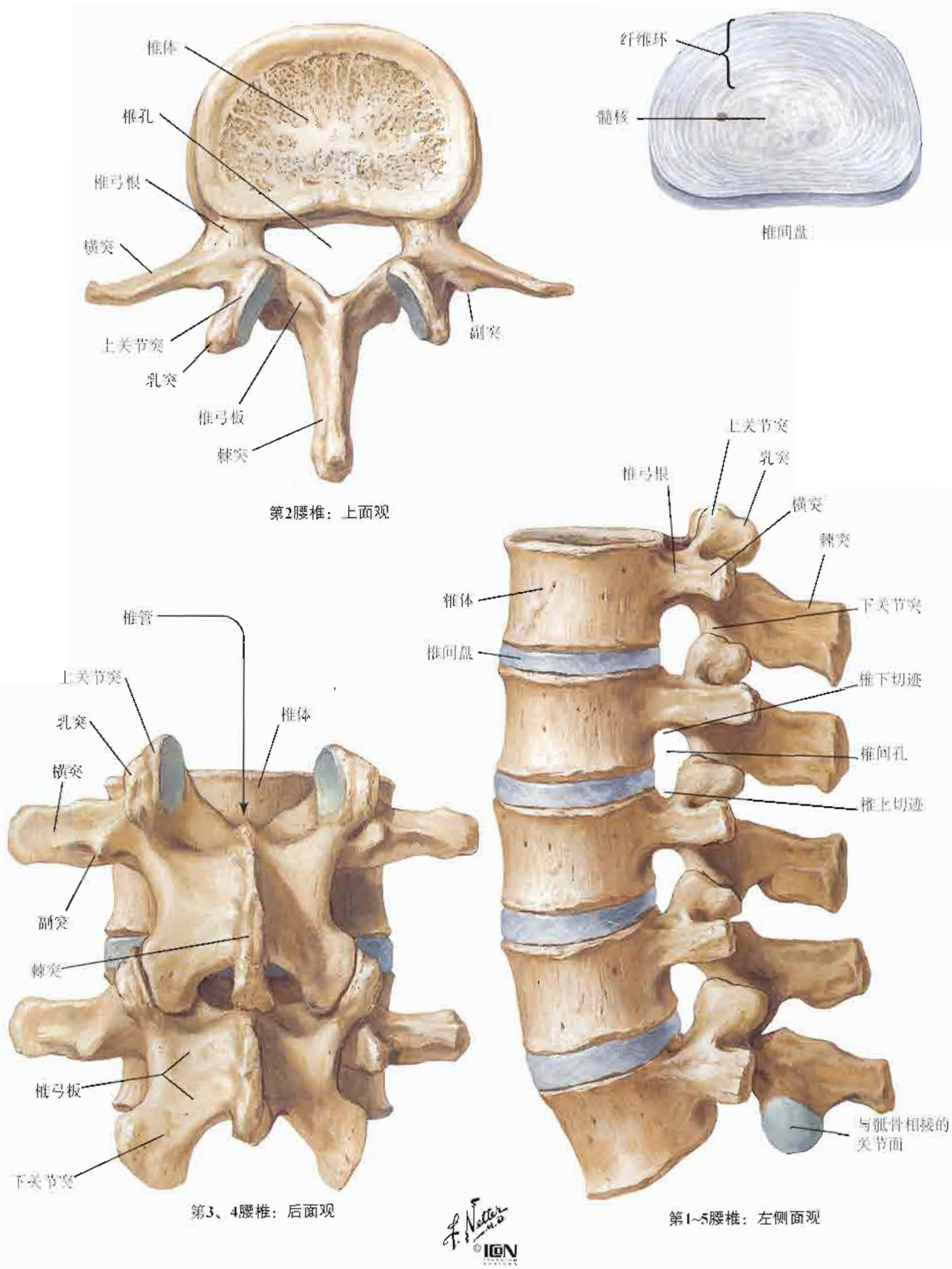
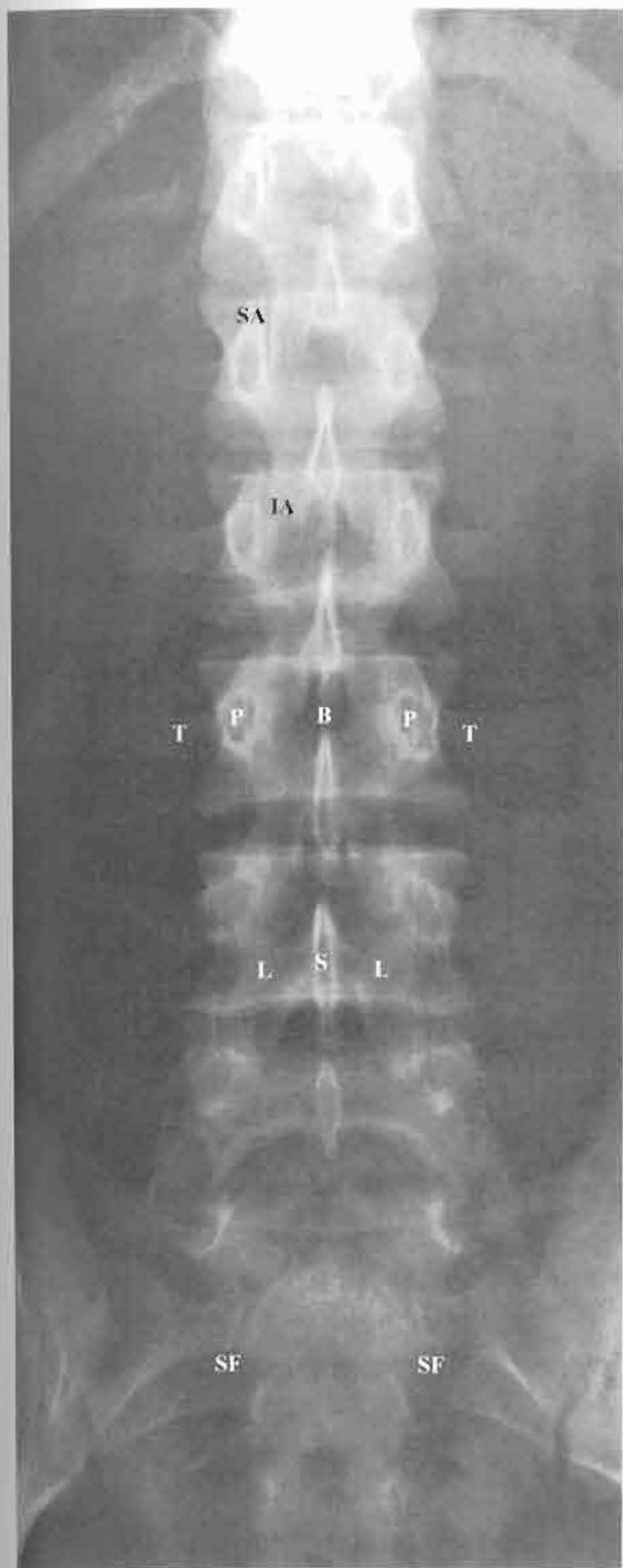


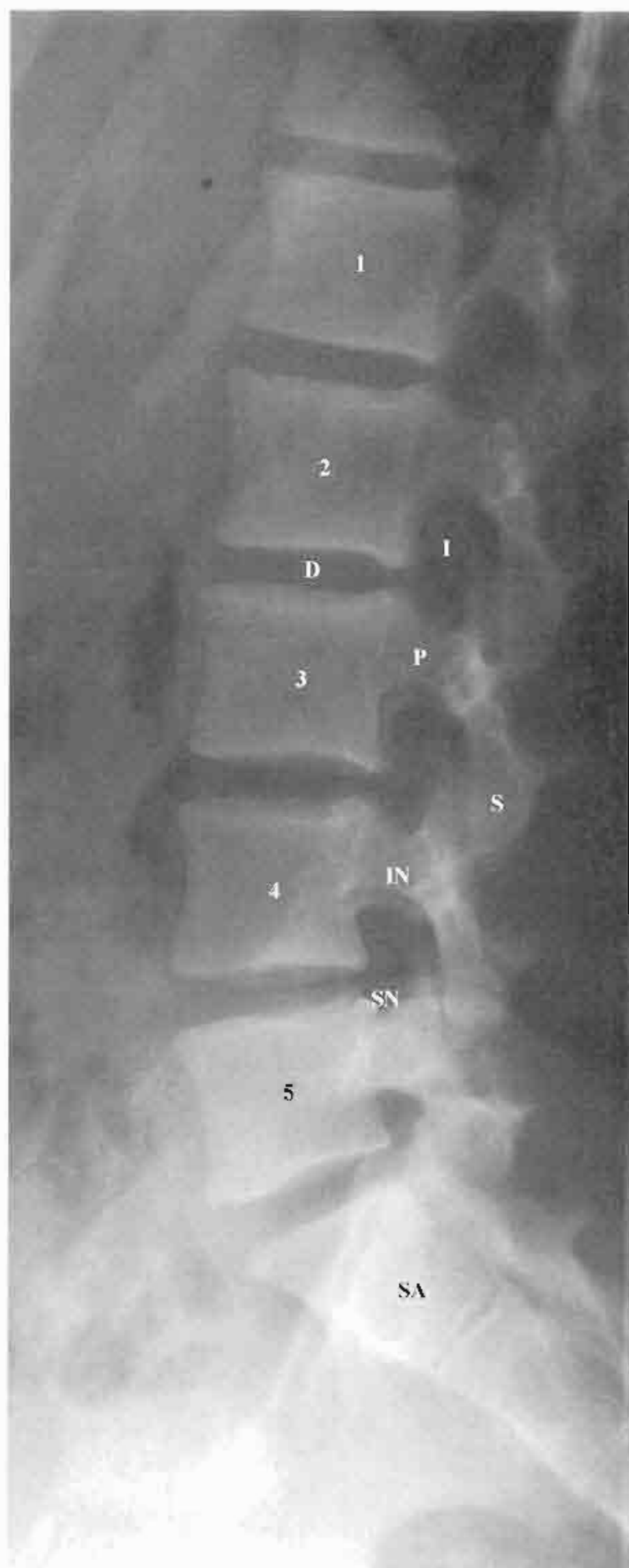
图148

前后位X线平片



- B 第3腰椎体
- IA 第1腰椎下关节突
- L 第4腰椎椎弓板
- P 第3腰椎椎弓根
- S 第4腰椎棘突
- SA 第7腰椎上关节突
- SF 骶孔
- T 第3腰椎横突

侧位X线平片



- D 椎间盘间隙
 - I 椎间孔
 - IN 第4腰椎椎下切迹
 - P 第3腰椎椎弓根
 - S 第3腰椎棘突
 - SA 骶骨
 - SN 第5腰椎椎上切迹
- 注释：椎体数字为腰椎序数

骶骨和尾骨

参见图146、152、240、340~342

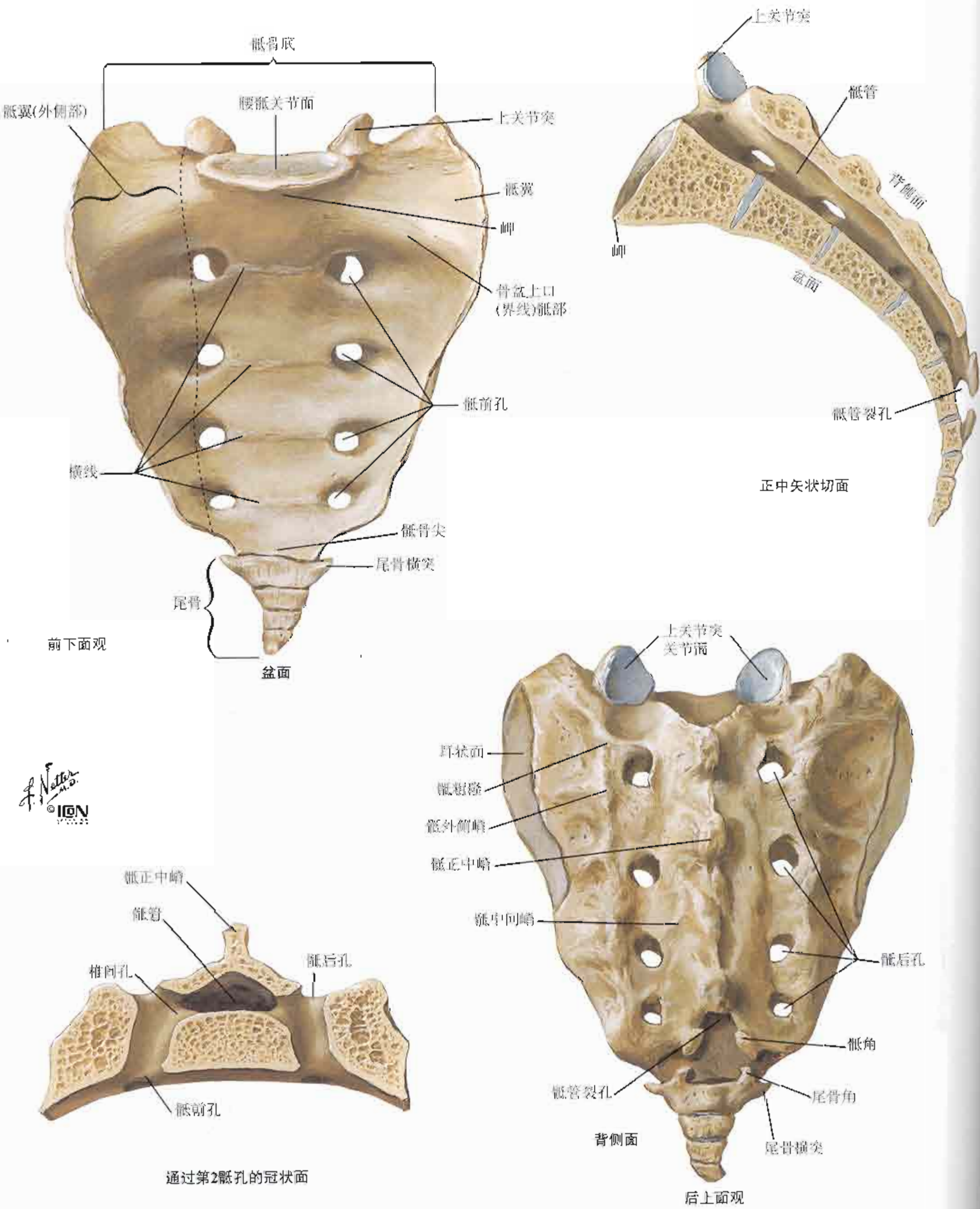
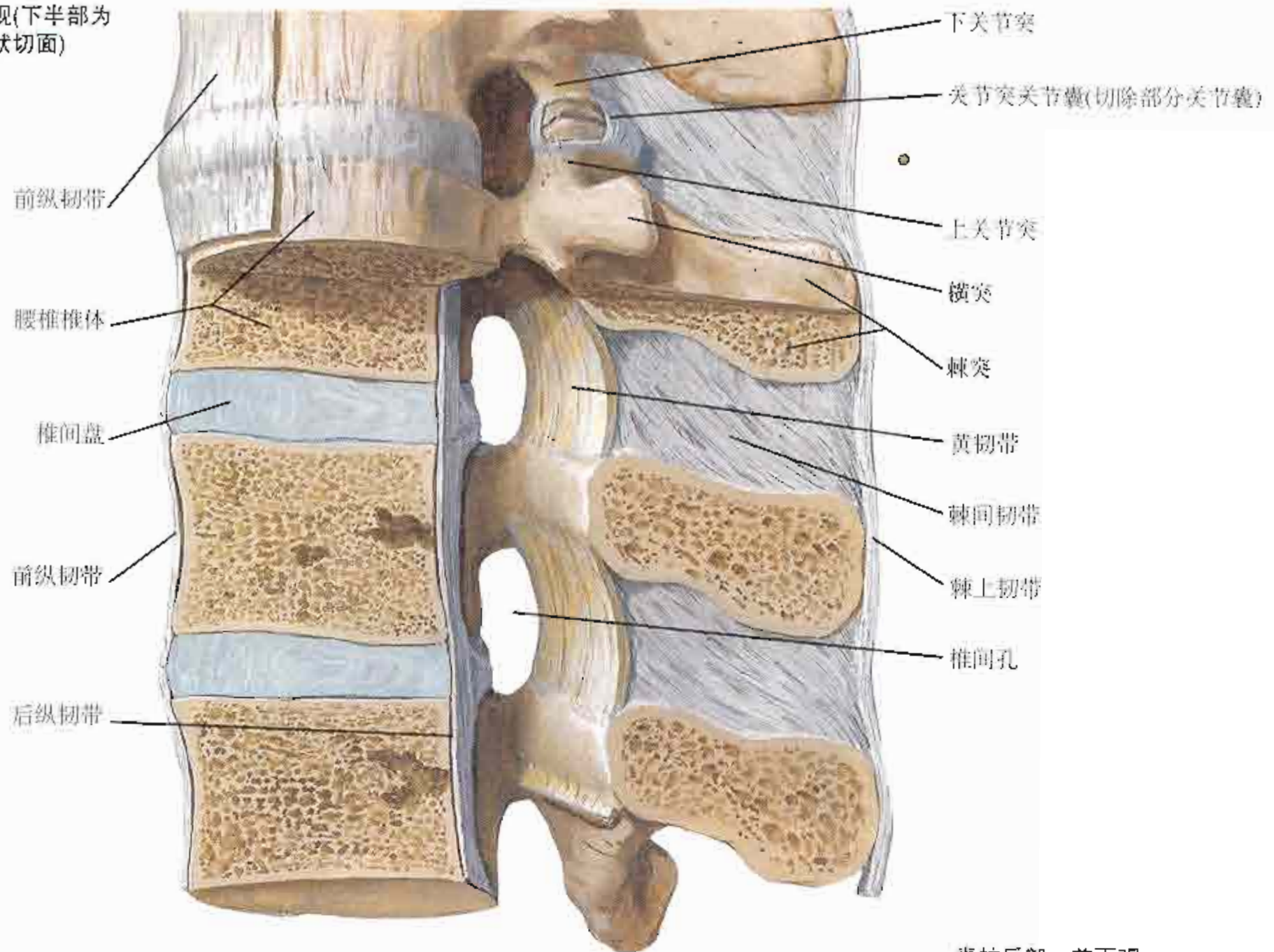


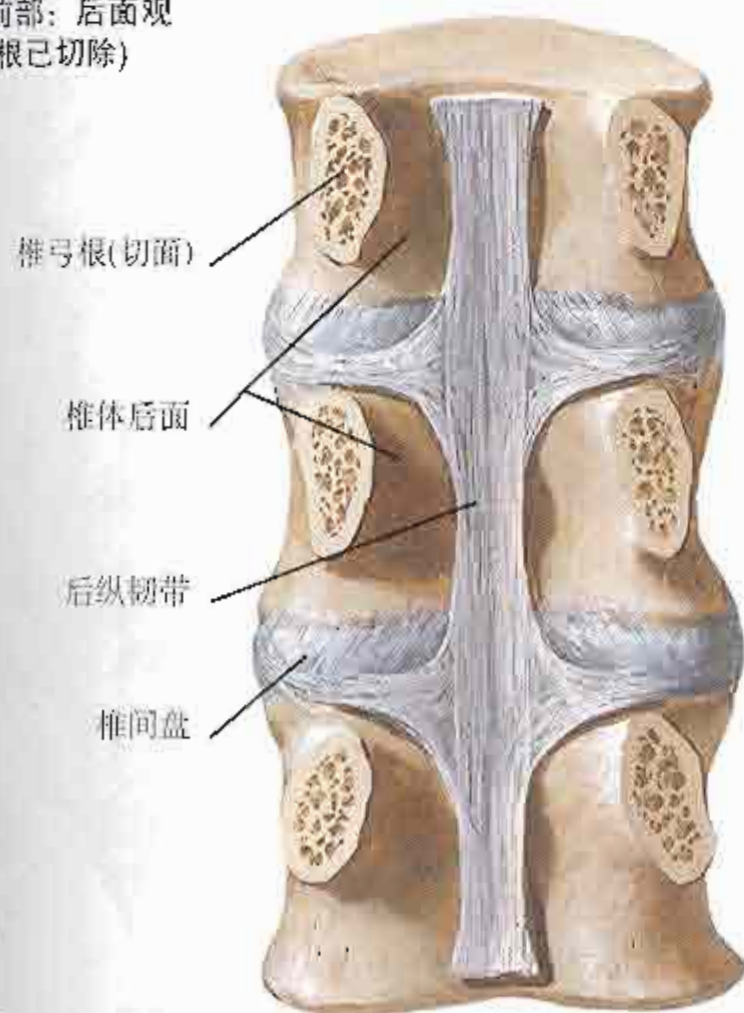
图150

左侧面观(下半部为正中矢状切面)

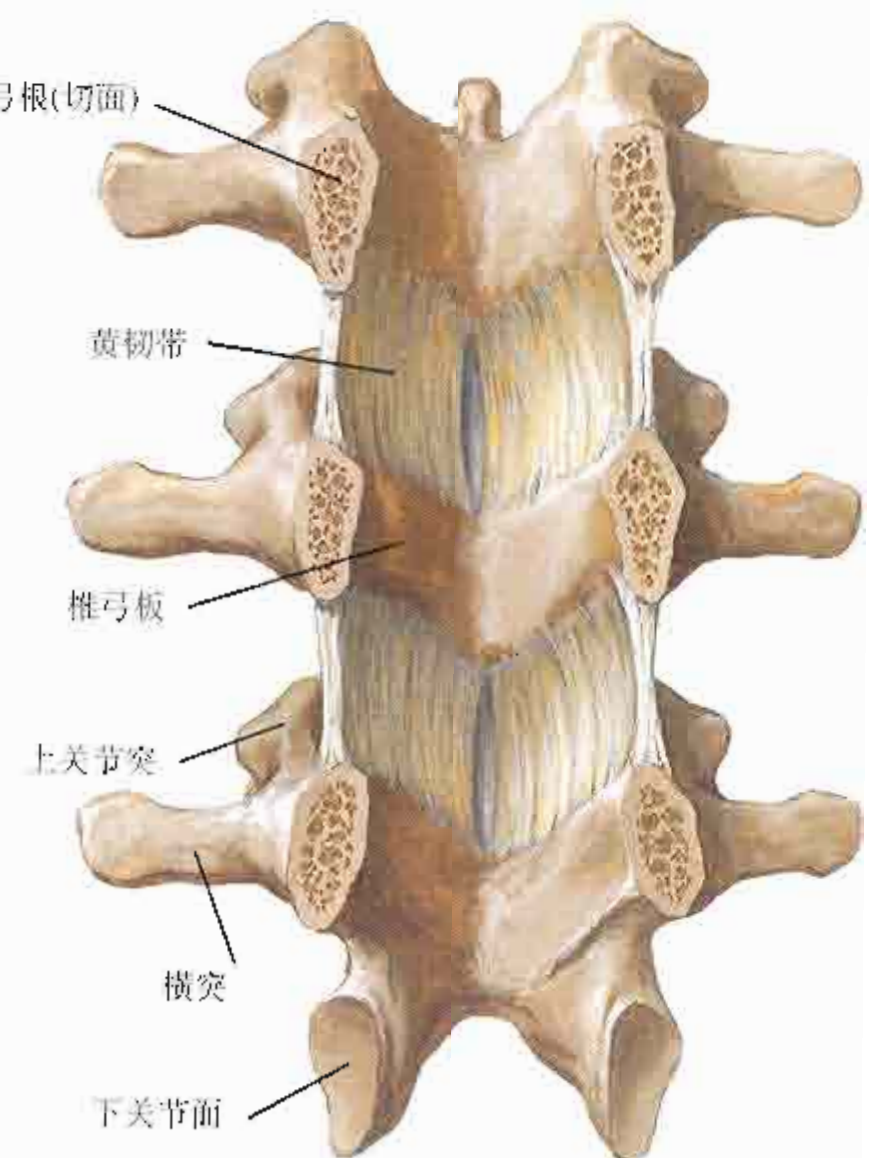


脊柱后部：前面观

脊柱前部：后面观
(椎弓根已切除)



椎弓根(切面)



运动科学网站
www.vo2max.cn

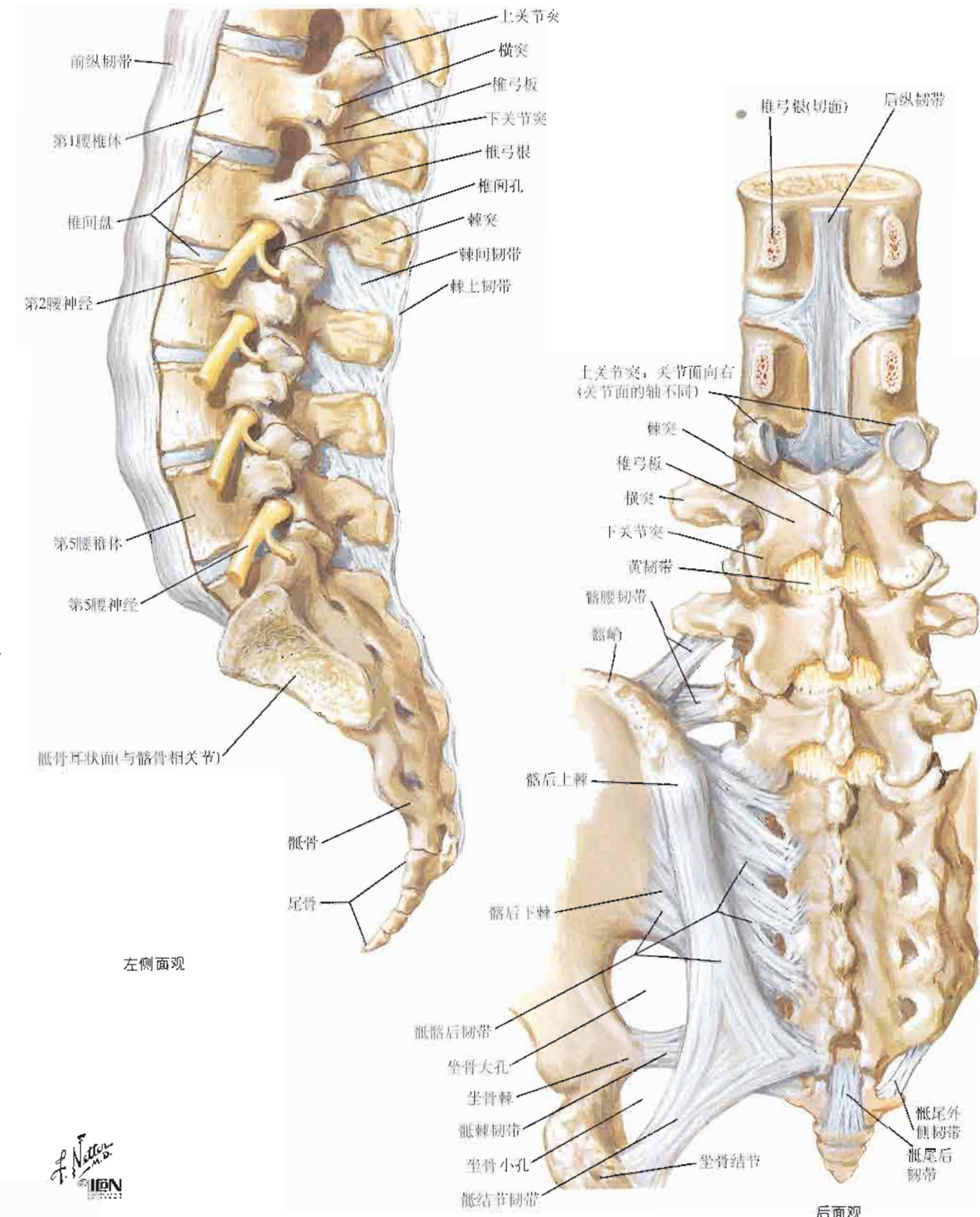
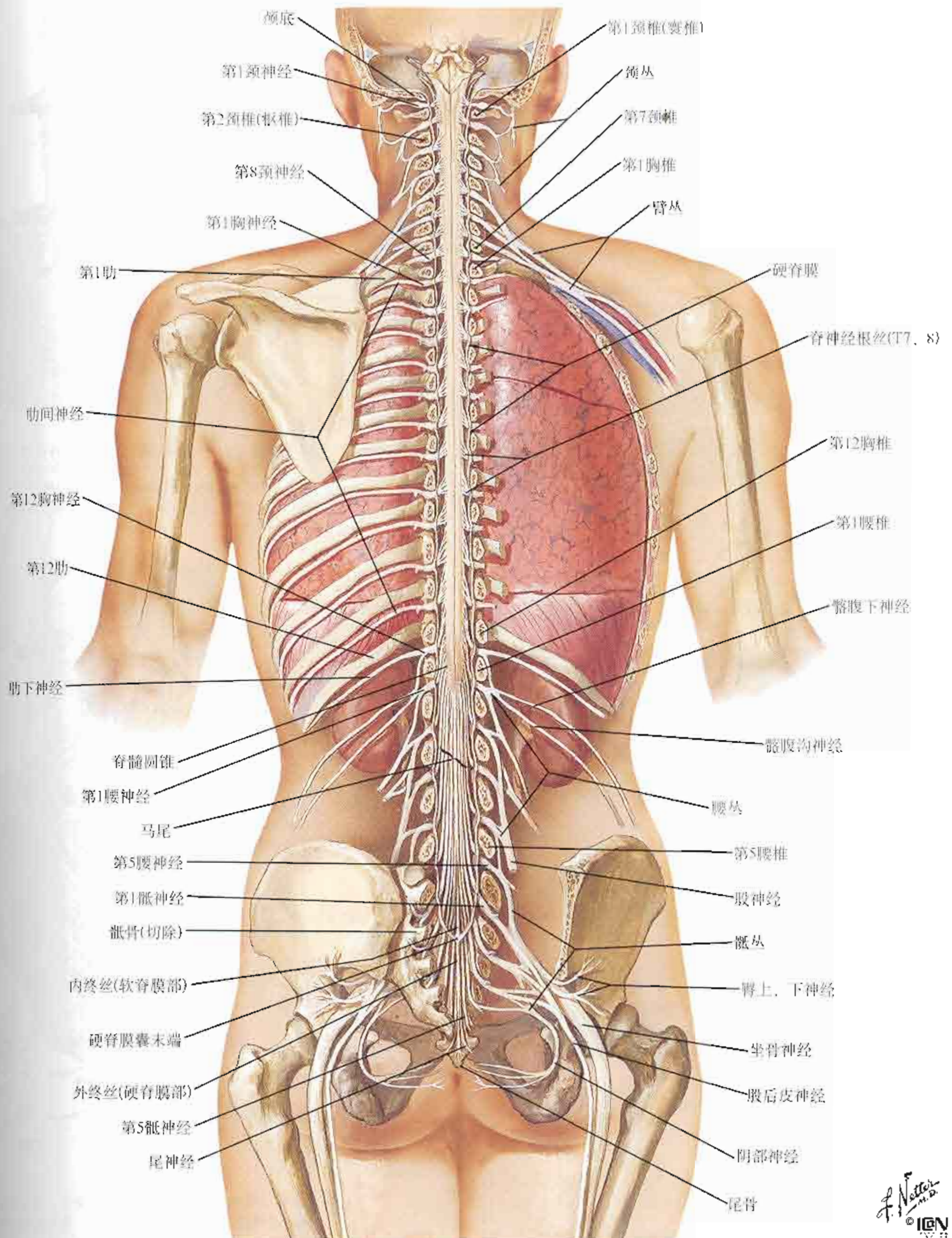
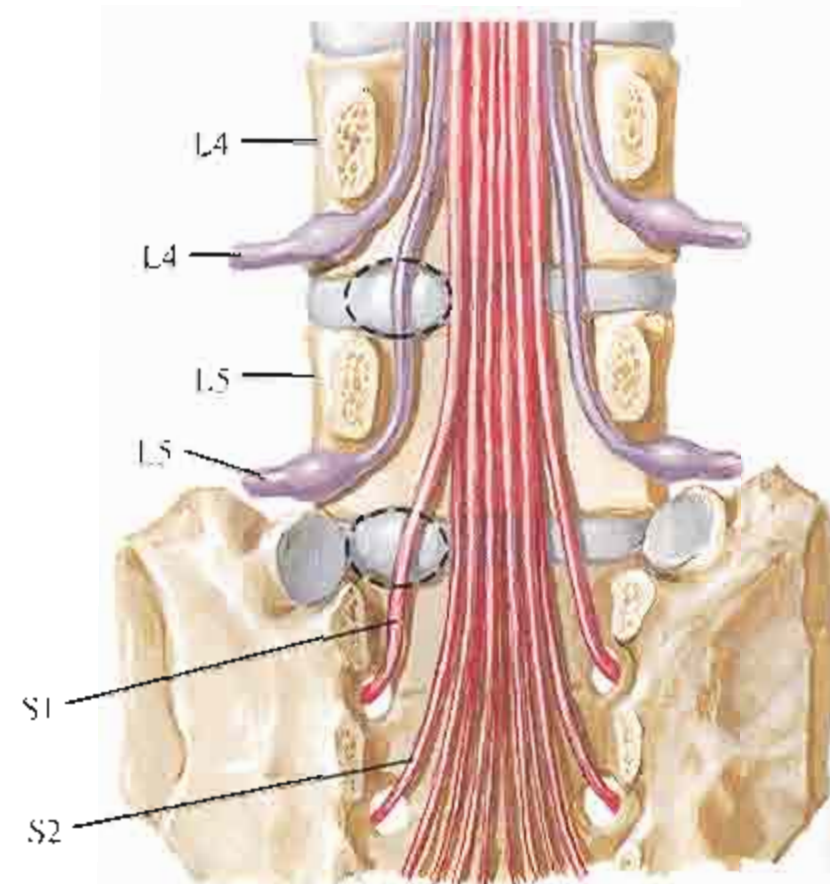
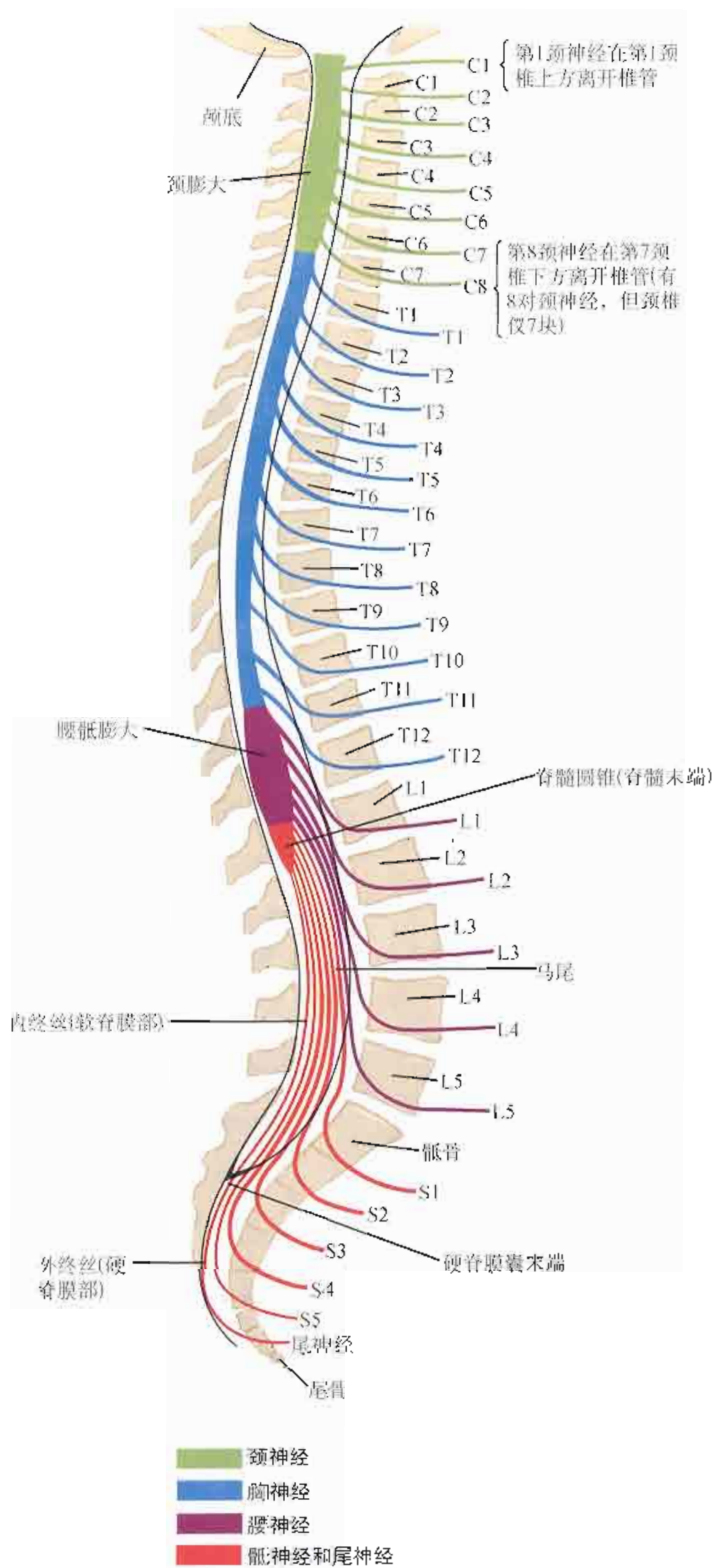


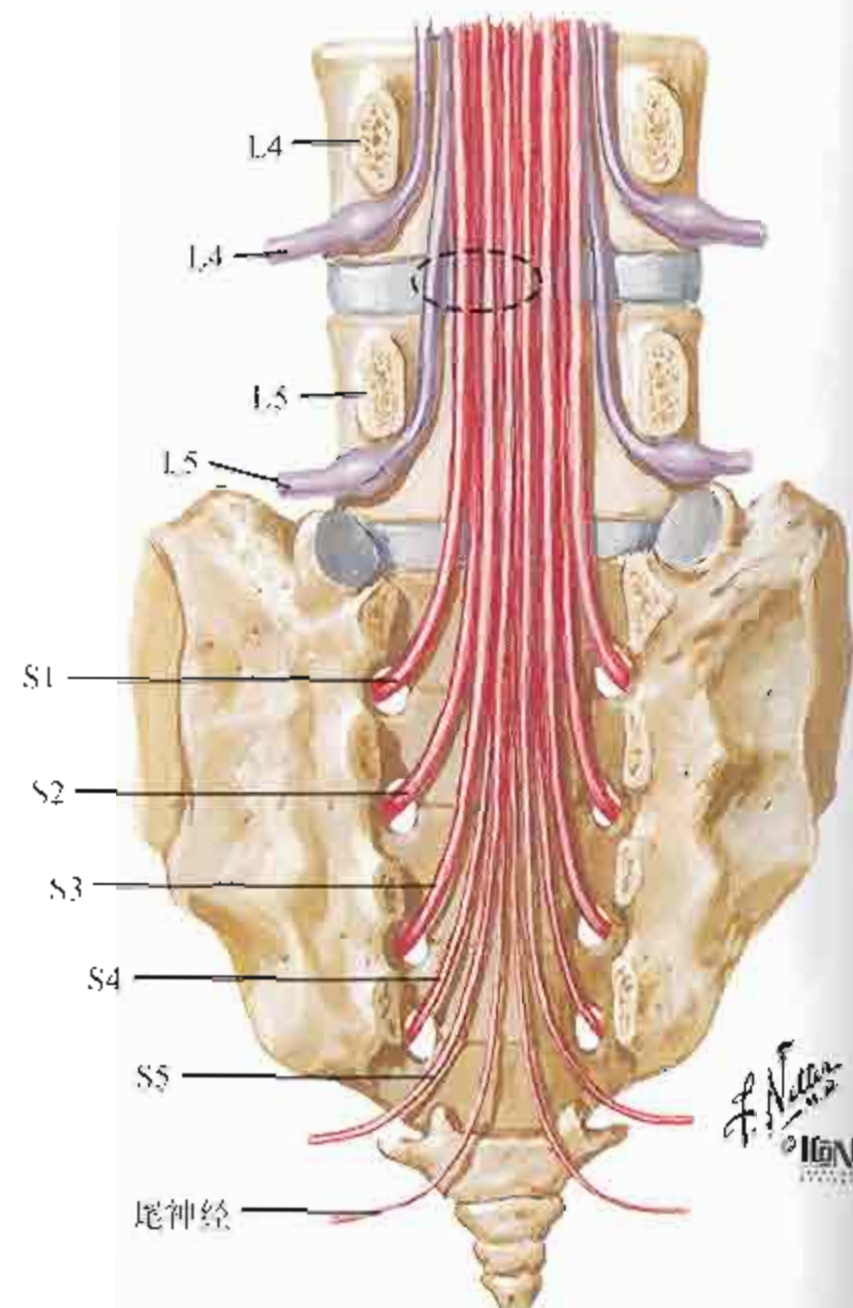
图152



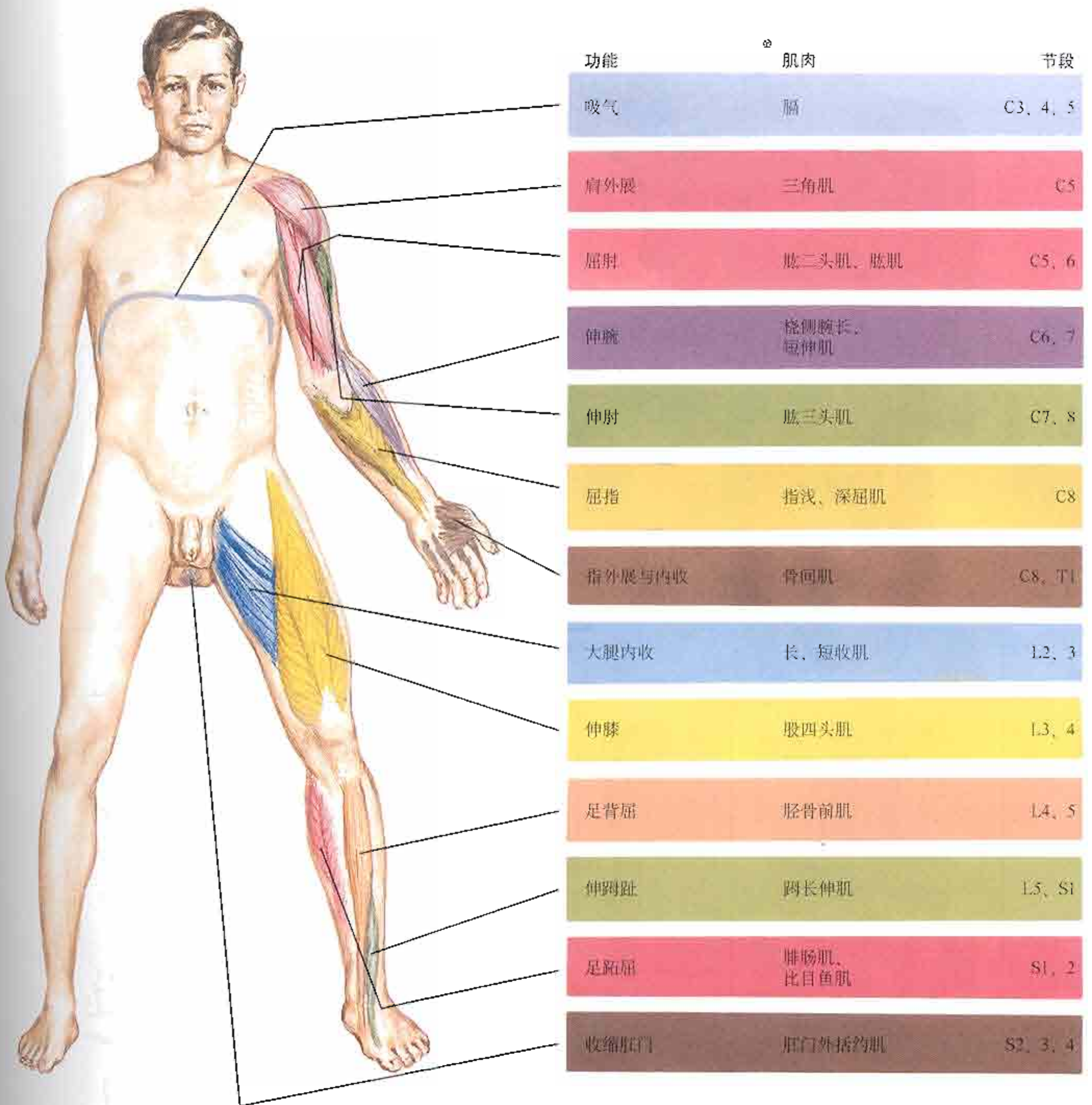
F. Netter M.D.
© IGV



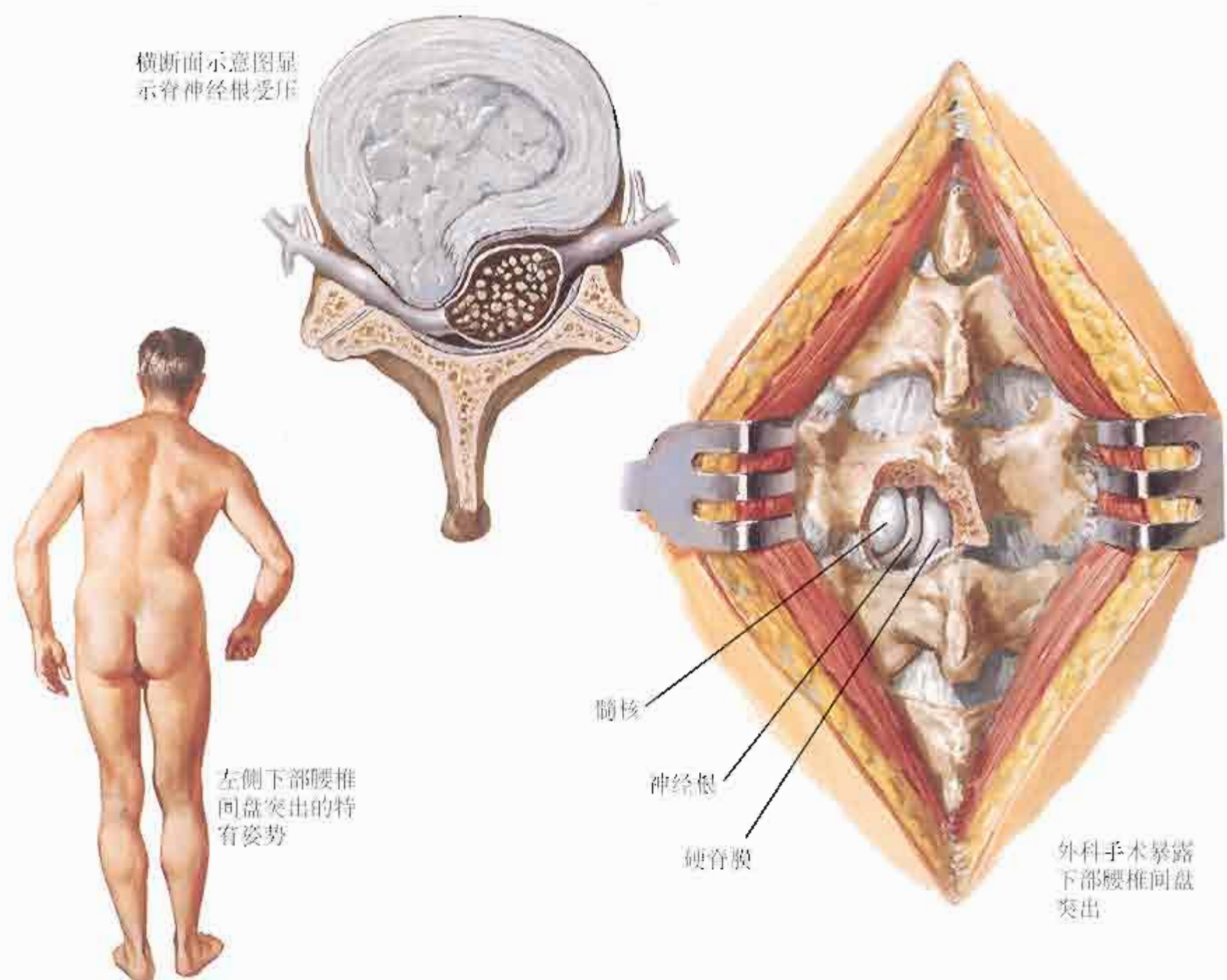
腰椎间盘突出通常不压迫经其上方离开椎管的脊神经。第4、5腰椎之间的椎间盘向后外方突出,压迫第5腰神经而不是第4腰神经。第5腰椎与第1骶椎之间的椎间盘突出,压迫第1骶神经而不是第5腰神经



第4、5腰椎之间的椎间盘向后方突出,极少压迫第4腰神经,主要压迫第5腰神经,有时可同时压迫第1~4骶神经



F. Netter M.D.
© ION



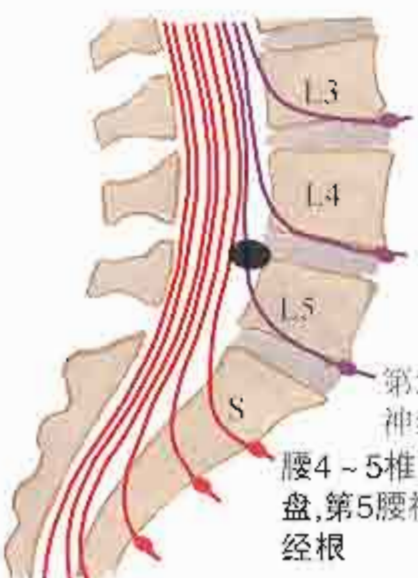



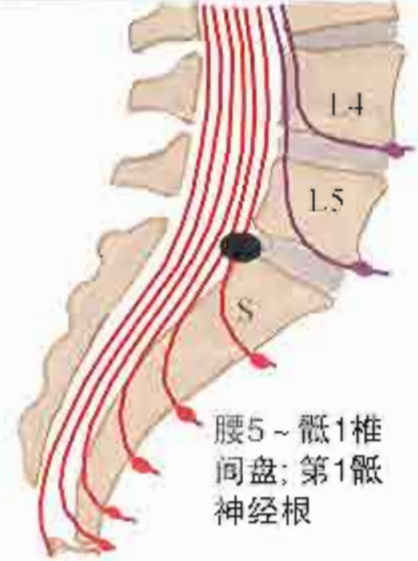





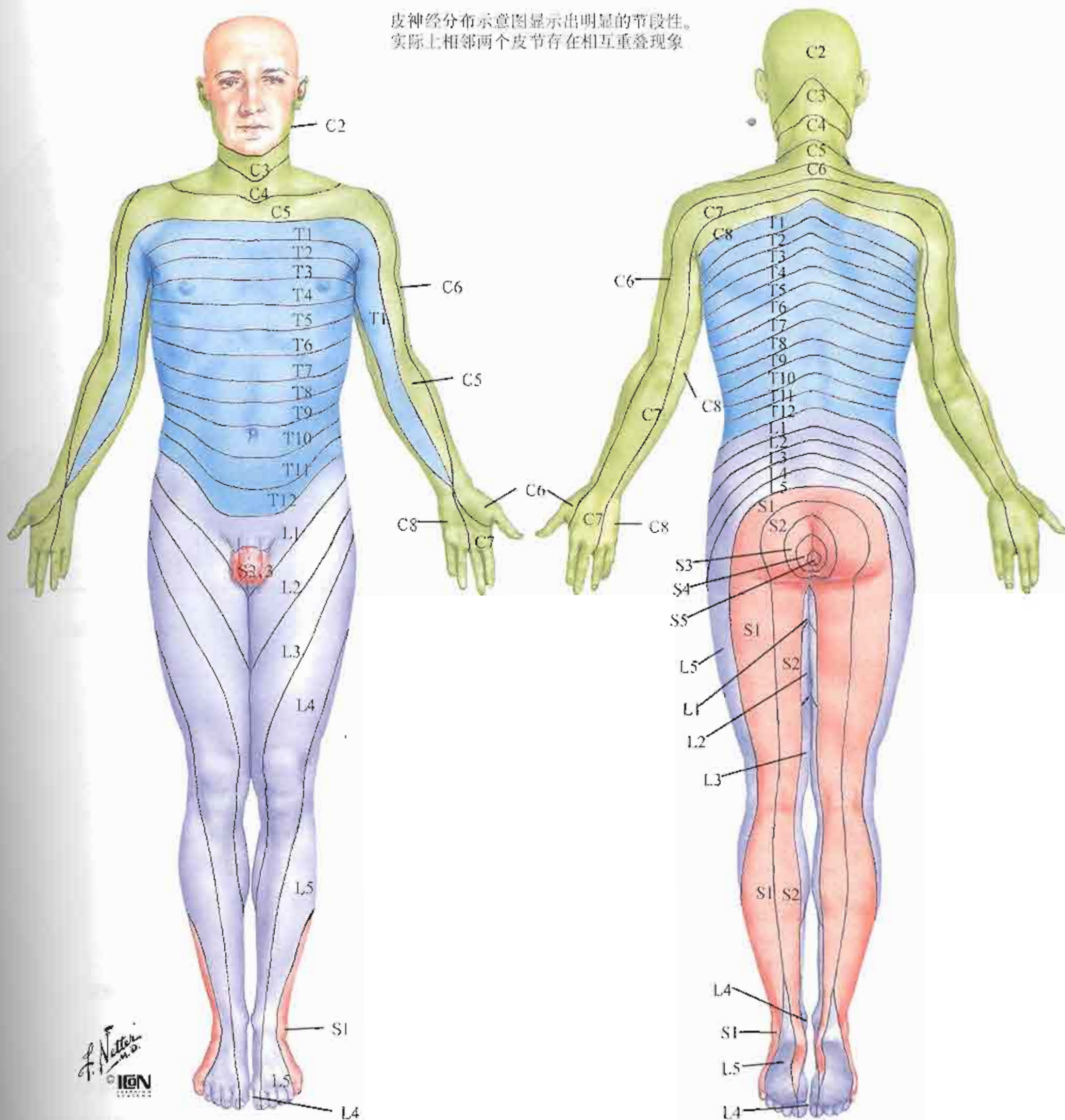
腰部椎间盘髓核突出的临床特征					
髓核突出的平面	疼痛	麻木	无力	肌萎缩	反射
 <p>第5腰神经 腰4~5椎间盘,第5腰神经根</p>	 <p>出现在髋关节、膝关节、大腿和小腿外侧面</p>	 <p>小腿外侧面,第1~3趾</p>	 <p>足与脚趾背屈;用足跟行走困难;可出现足下垂</p>	不明显	膝腱和跟腱反射改变少见,但内侧腓肠肌腱反射减弱或消失
 <p>腰5~骶1椎间盘;第1骶神经根</p>	 <p>出现在髋关节、臀部、大腿和小腿后至足跟</p>	 <p>小腿后面,足跟、足与趾外侧面</p>	 <p>足与脚趾跖屈受影响,用足趾行走困难</p>	 <p>腓肠肌和比目鱼肌</p>	 <p>跟腱反射减弱或消失</p>

图156

参见图465、525；皮神经的分布图参见图20、455、457~459、461、464、520~524

皮神经分布示意图显示出明显的节段性。
实际上相邻两个皮节存在相互重叠现象



主要皮神经的分布平面

C5 锁骨
C5,6,7 上肢外侧部
C8,T1 上肢内侧部
C6 拇指
C6,7,8 手
C8 环指和小指
T4 乳头平面

T10 脐平面
T12 腹股沟区
L1,2,3,4 下肢前面和内侧
L4, 5, S1 足
L4 跖趾内侧
S1, 2, L5 下肢后面和外侧
S1 足和小趾外侧缘
S2,3,4 会阴

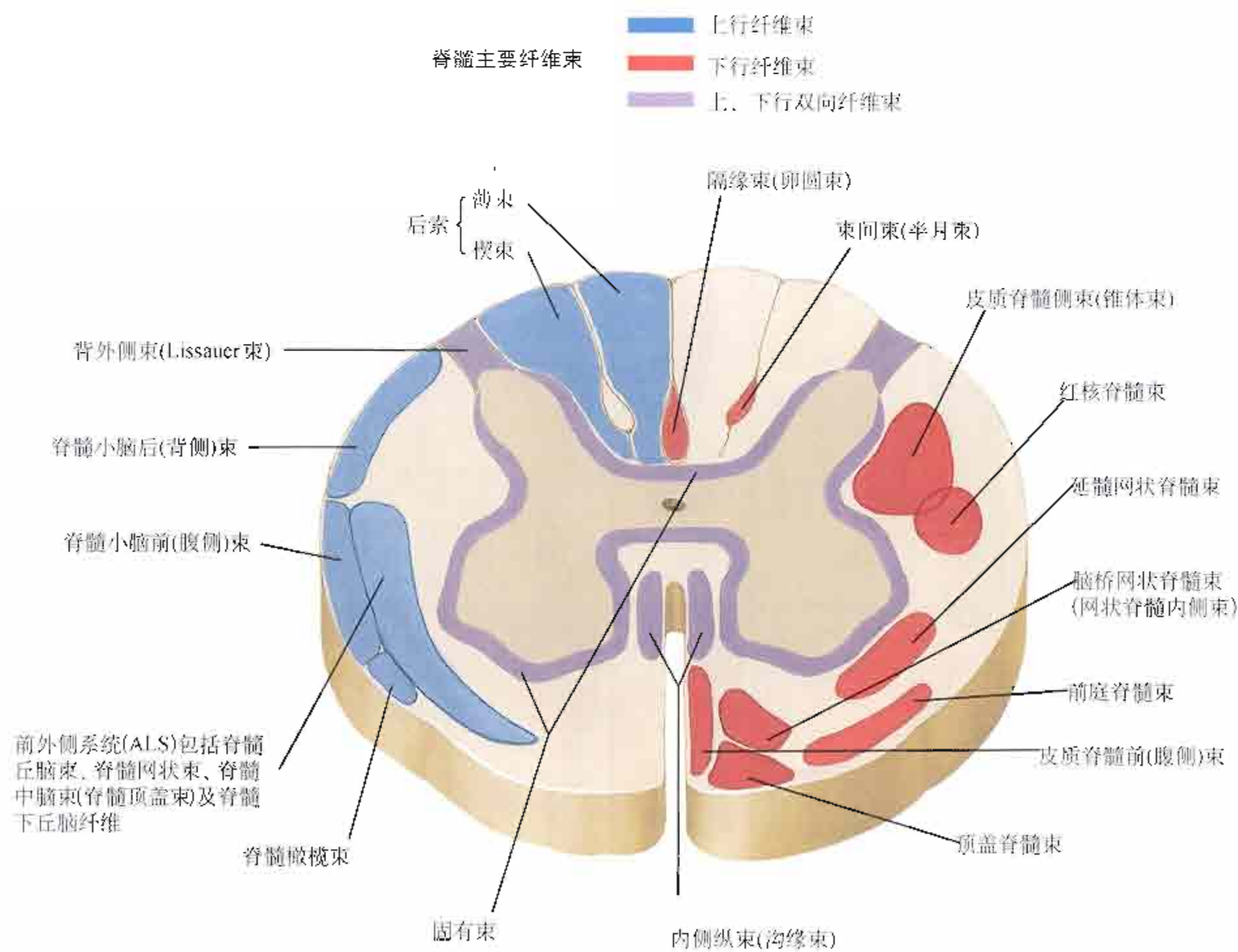
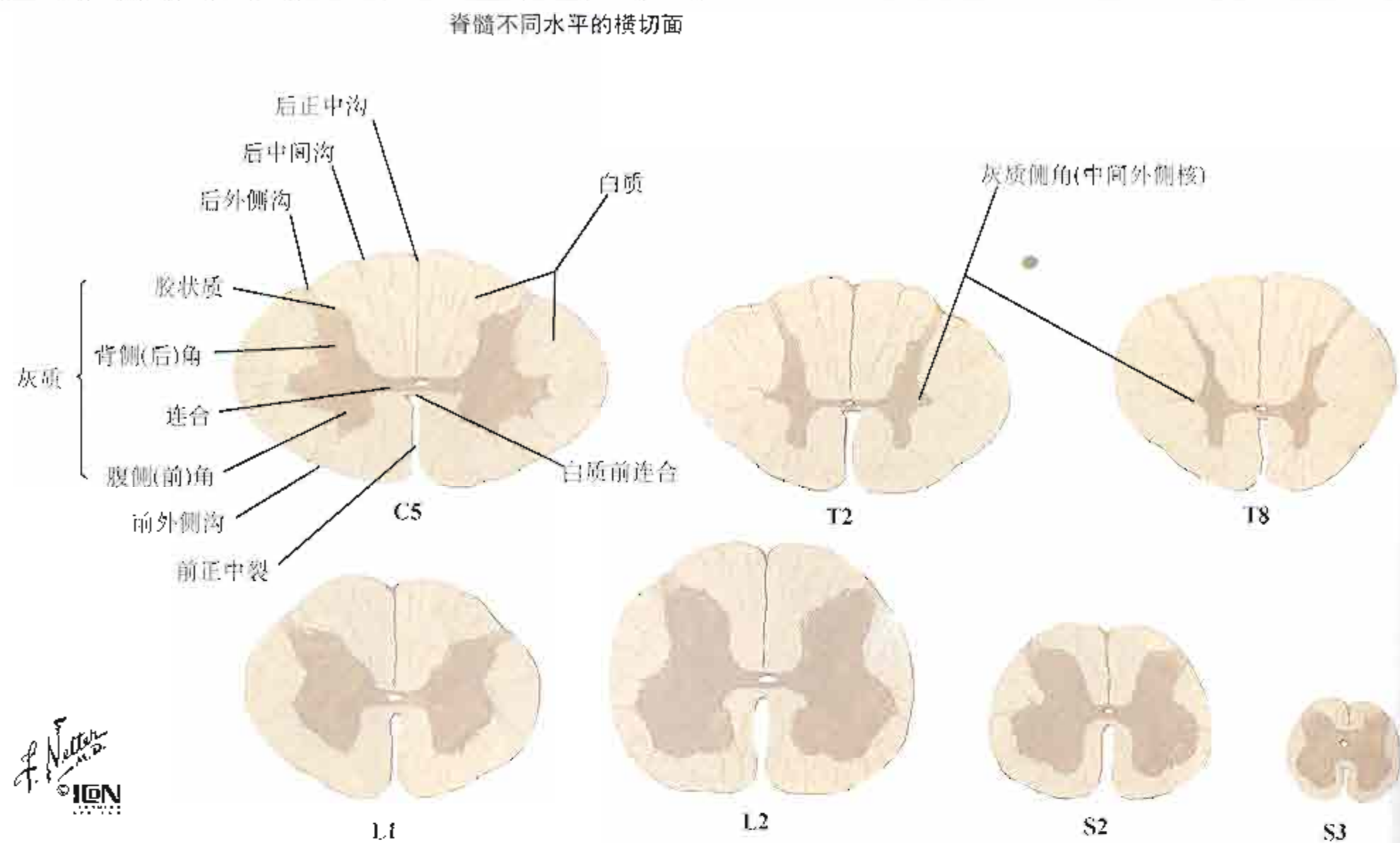
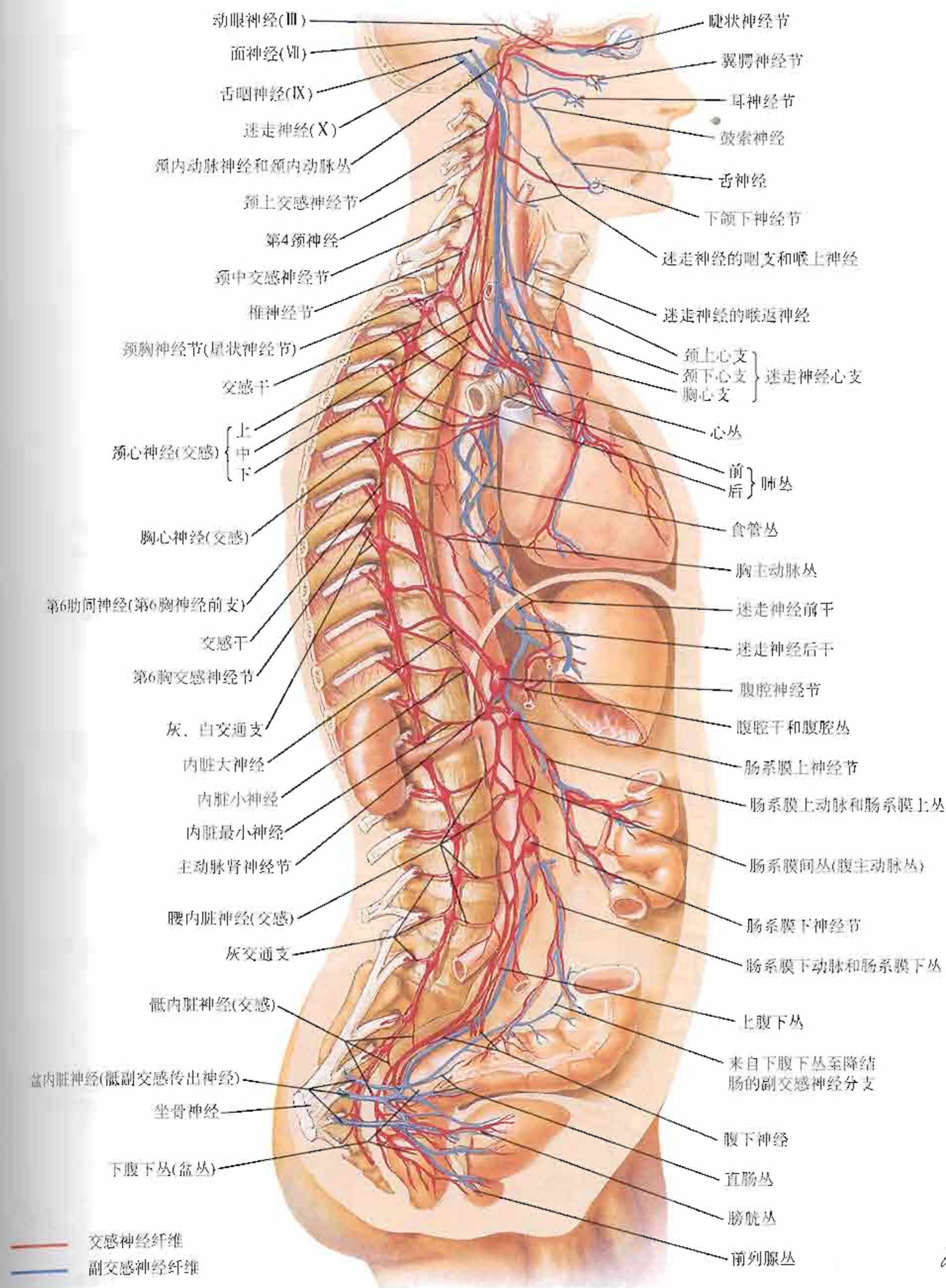


图158



F. Netter
M.D.
ION

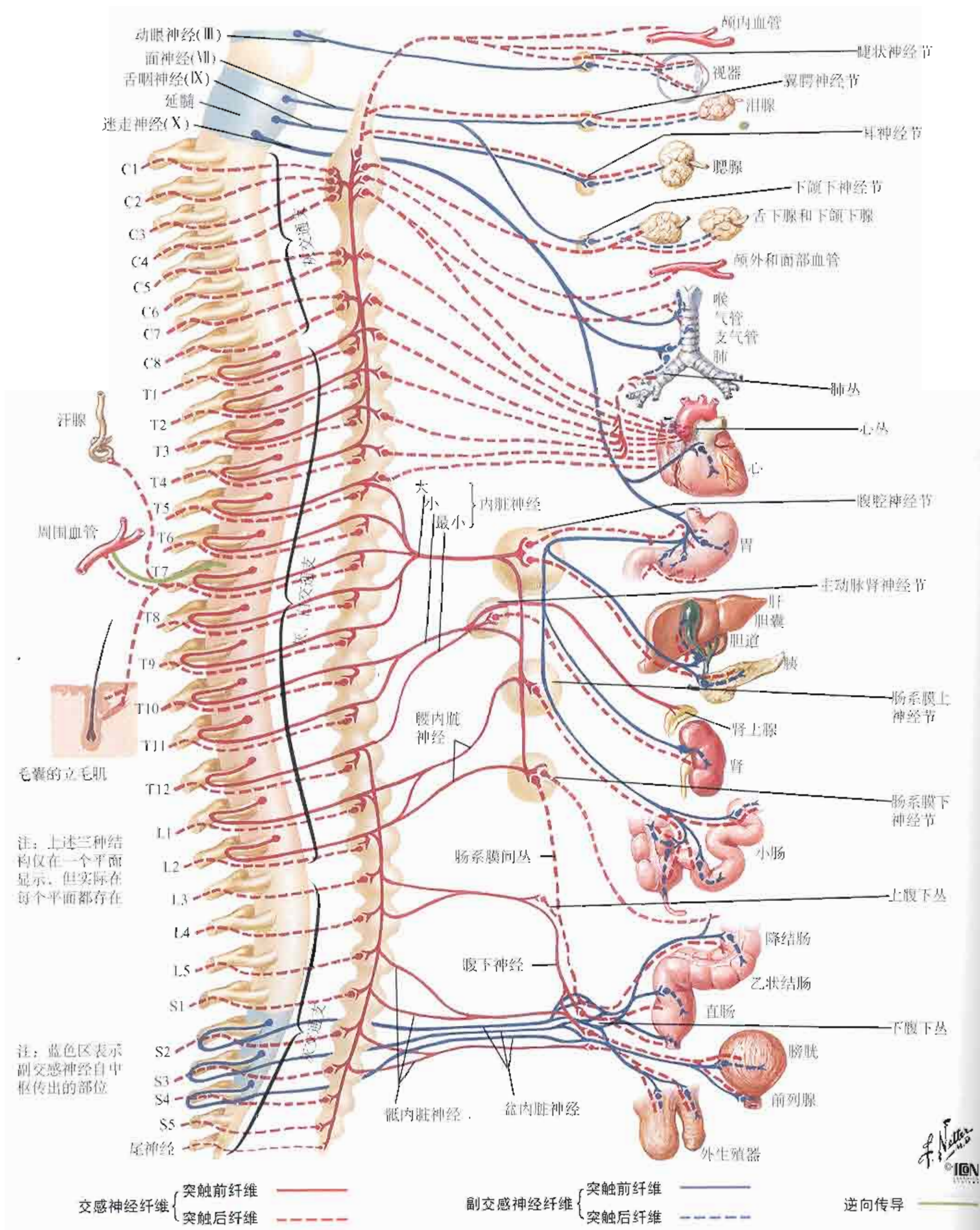
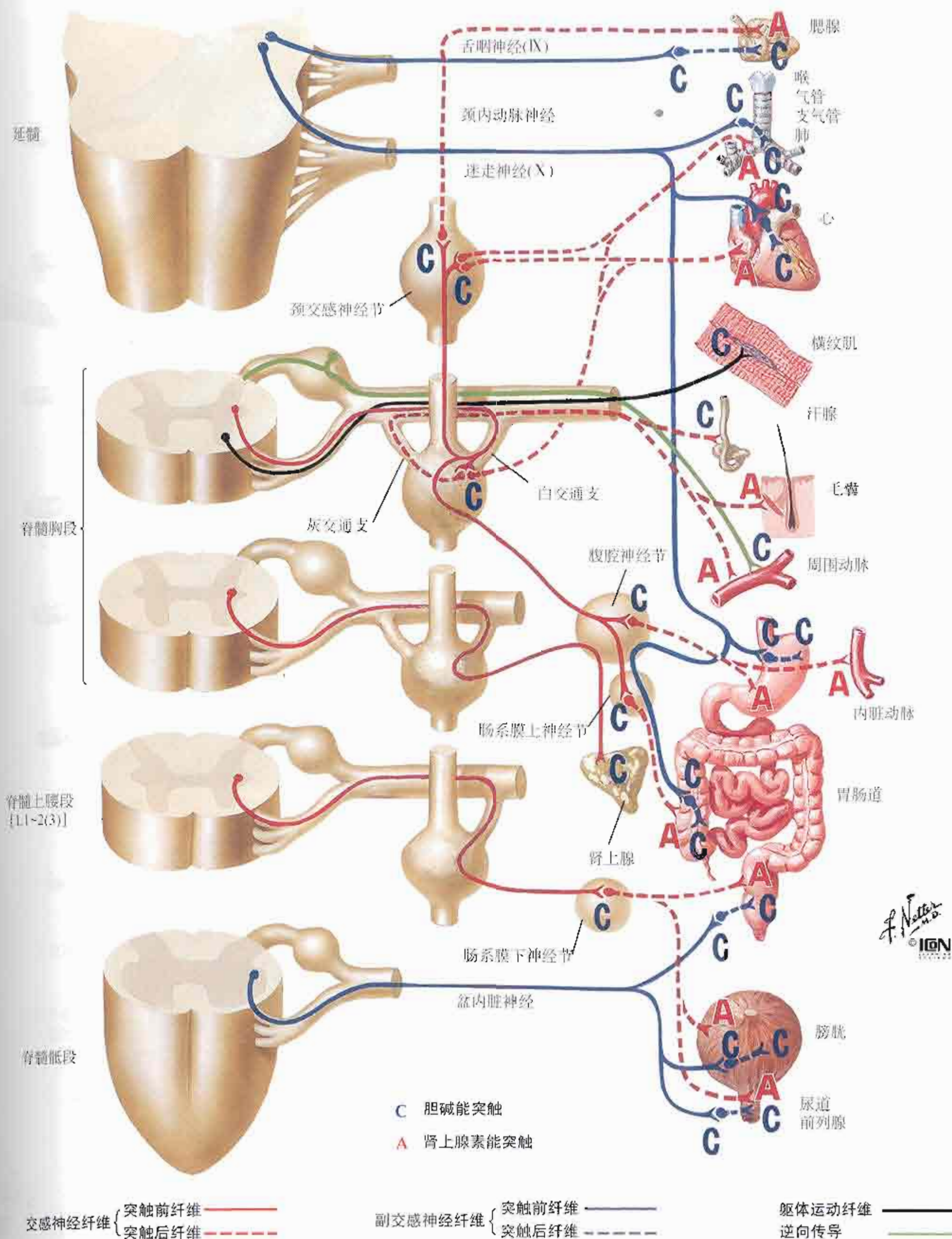
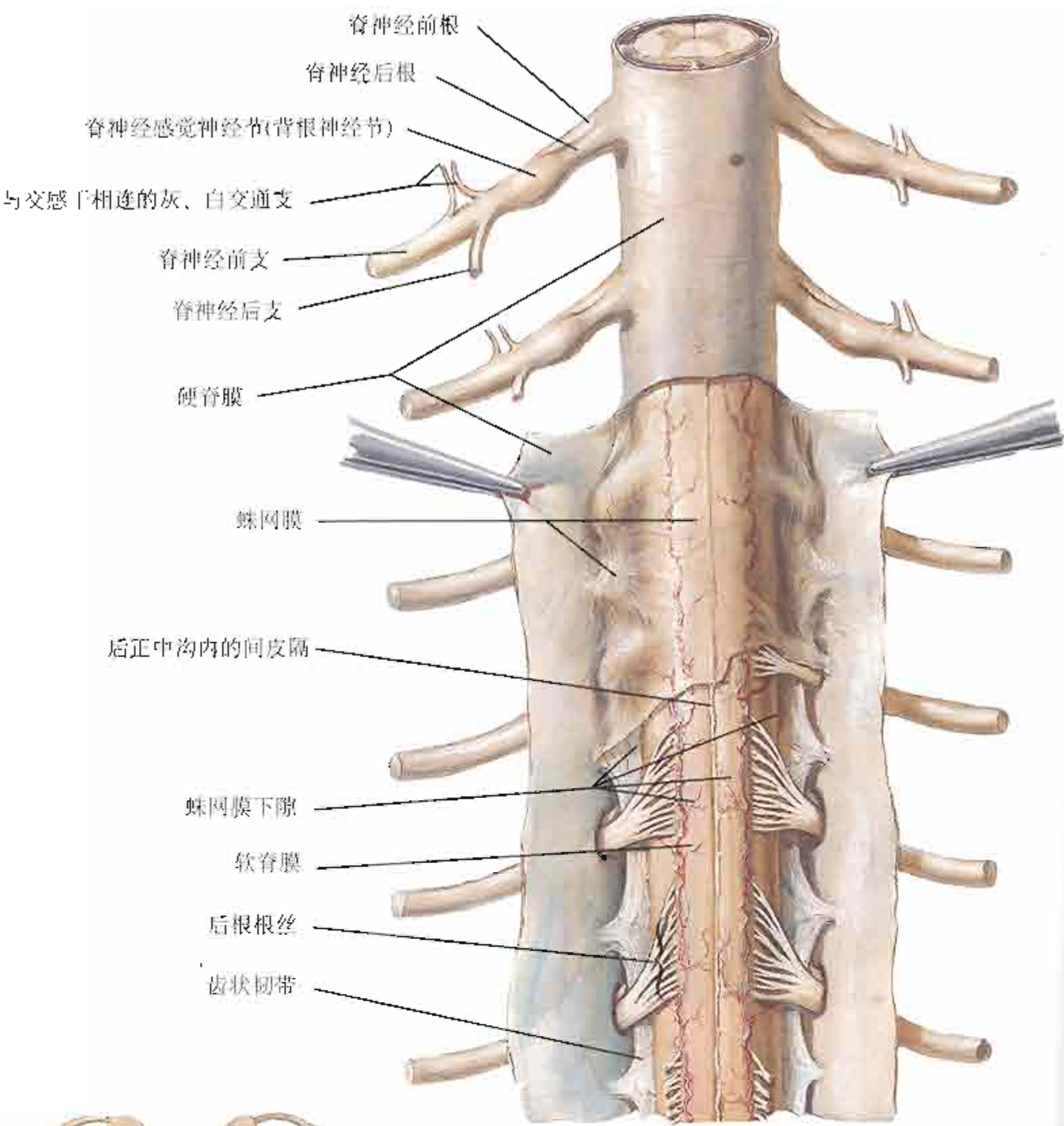


图160



F. Netter M.D. ILLUSTRATIONS

后面观



除去被膜：前面观(已放大)

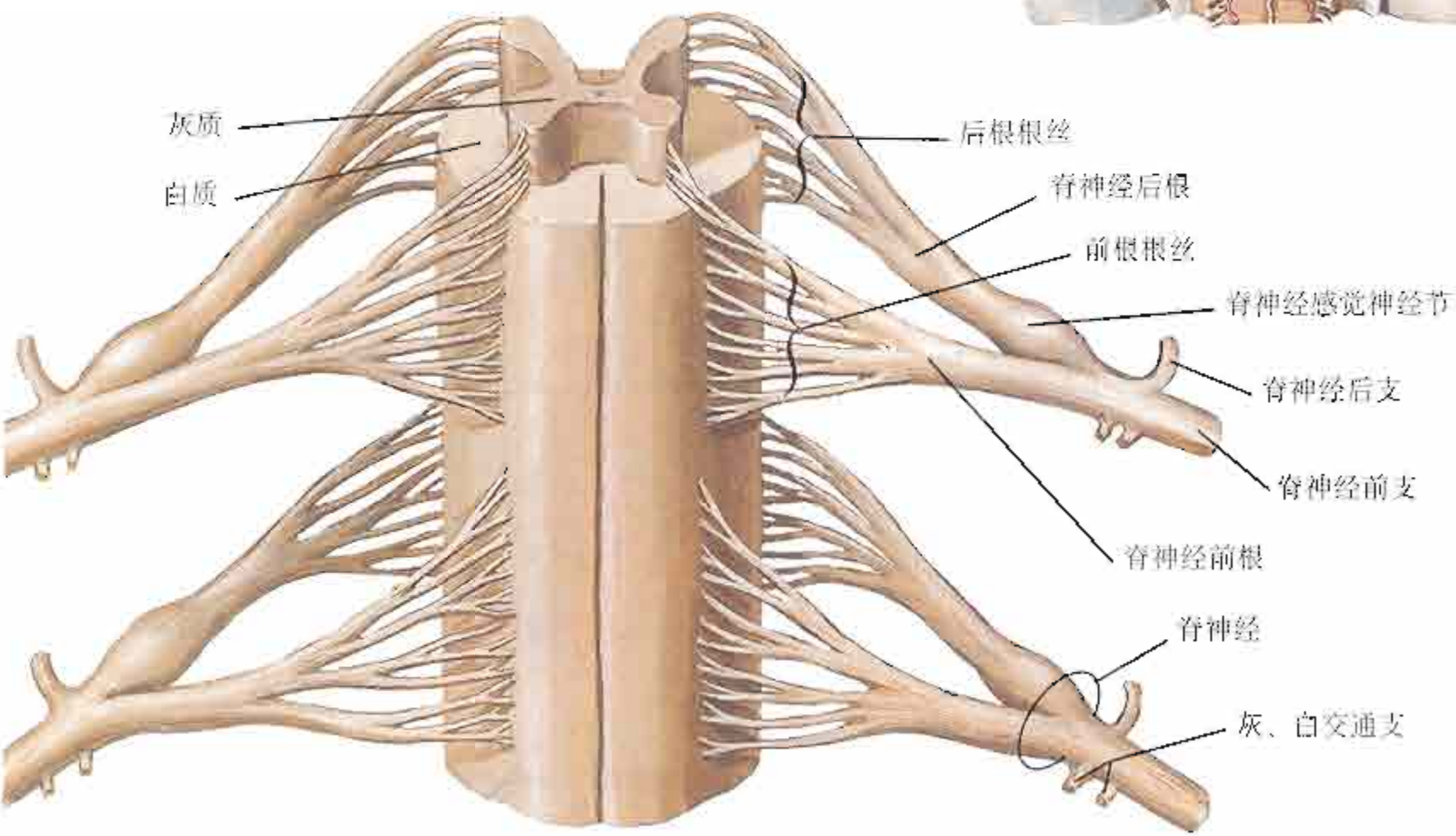


图162

脊髓的动脉：示意图

参见图131

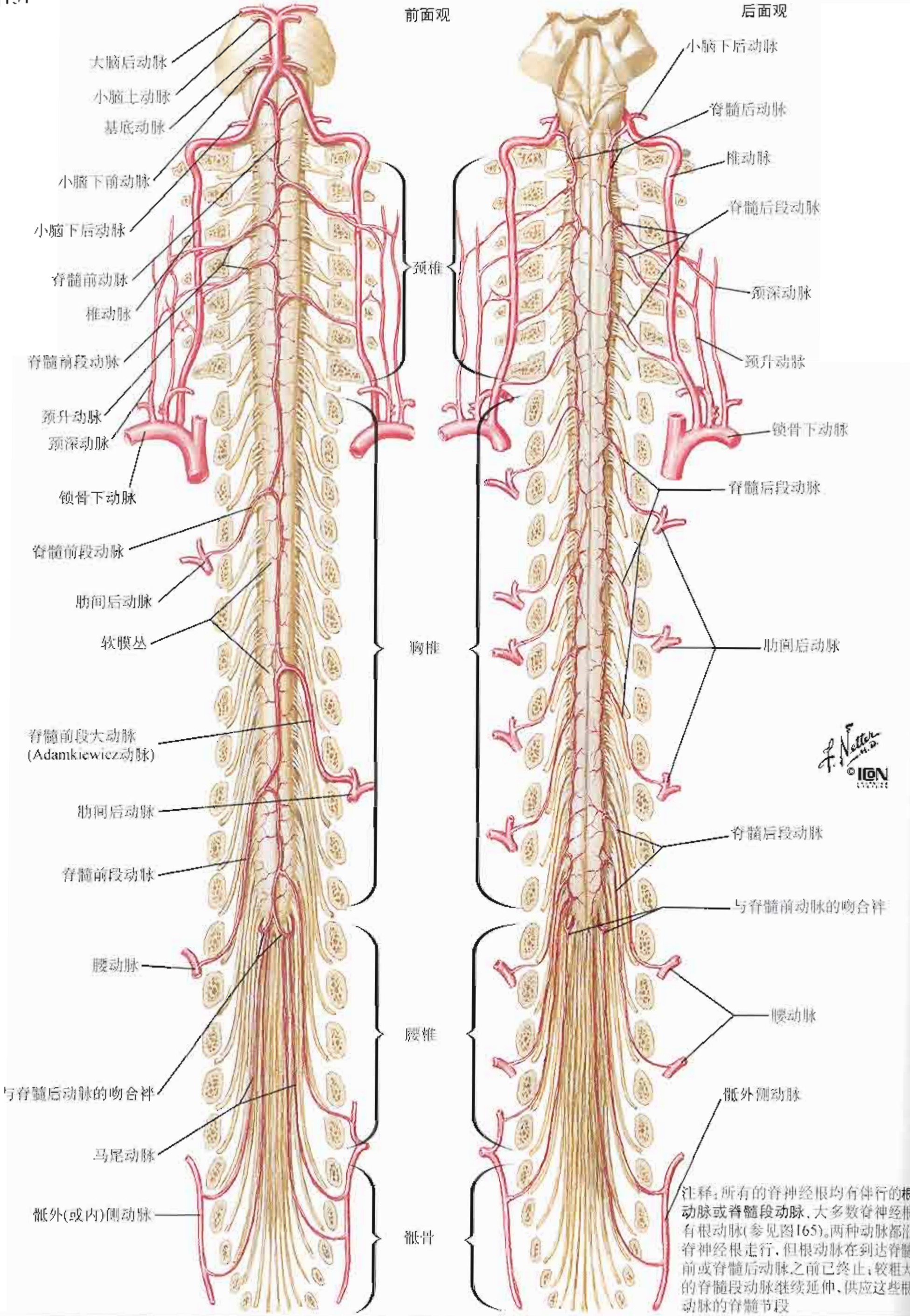
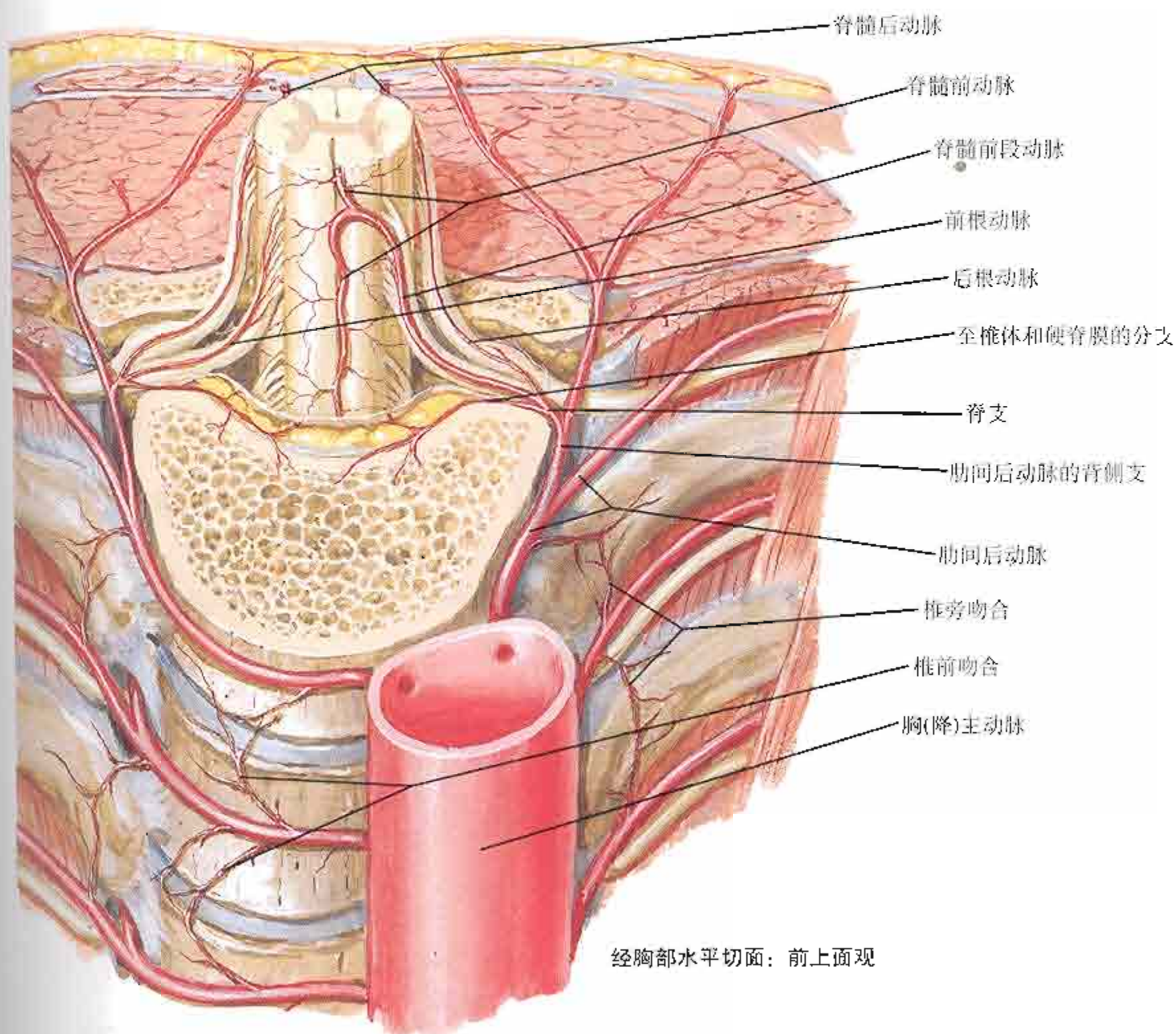
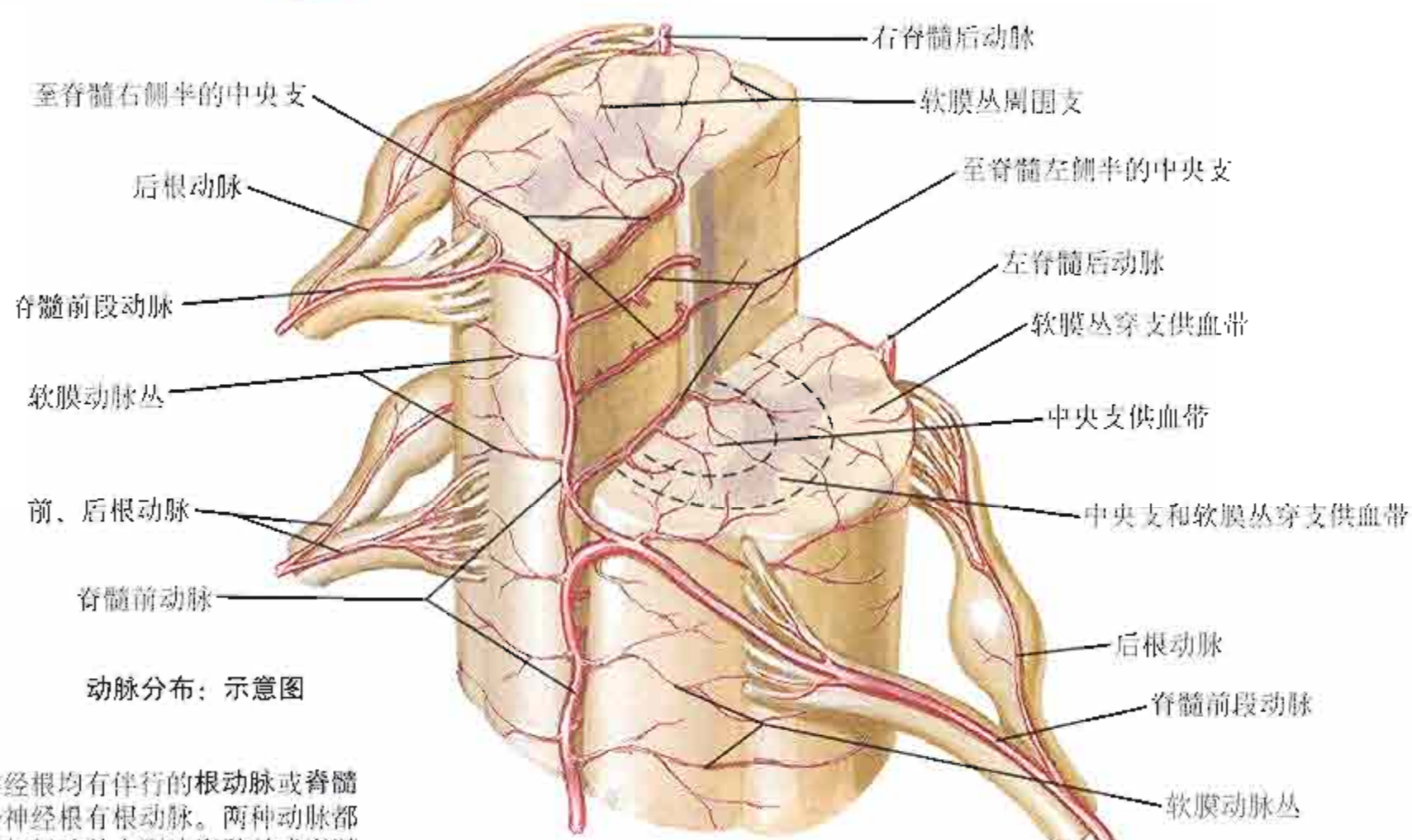


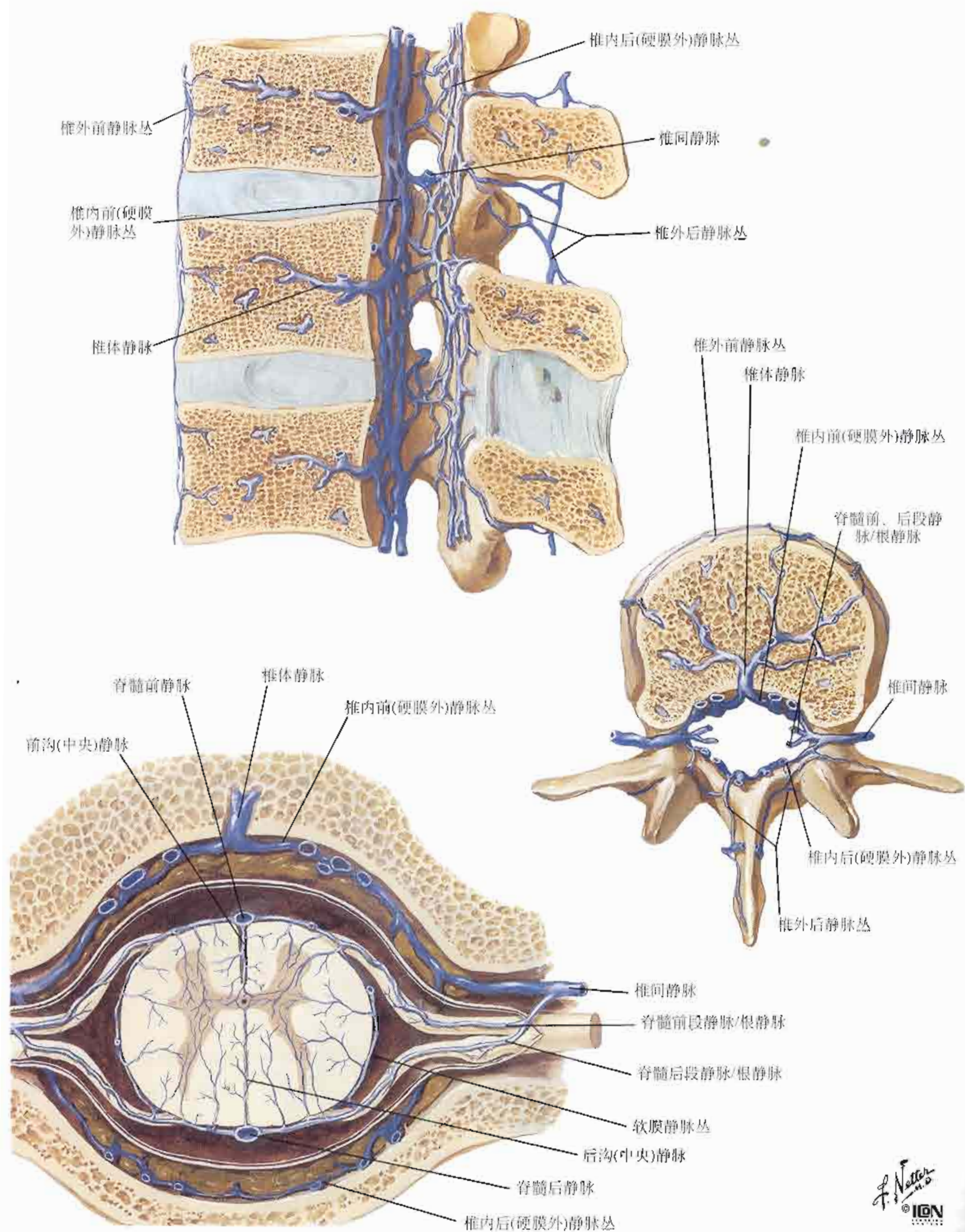
图164



F. Netter M.D.
© IGM

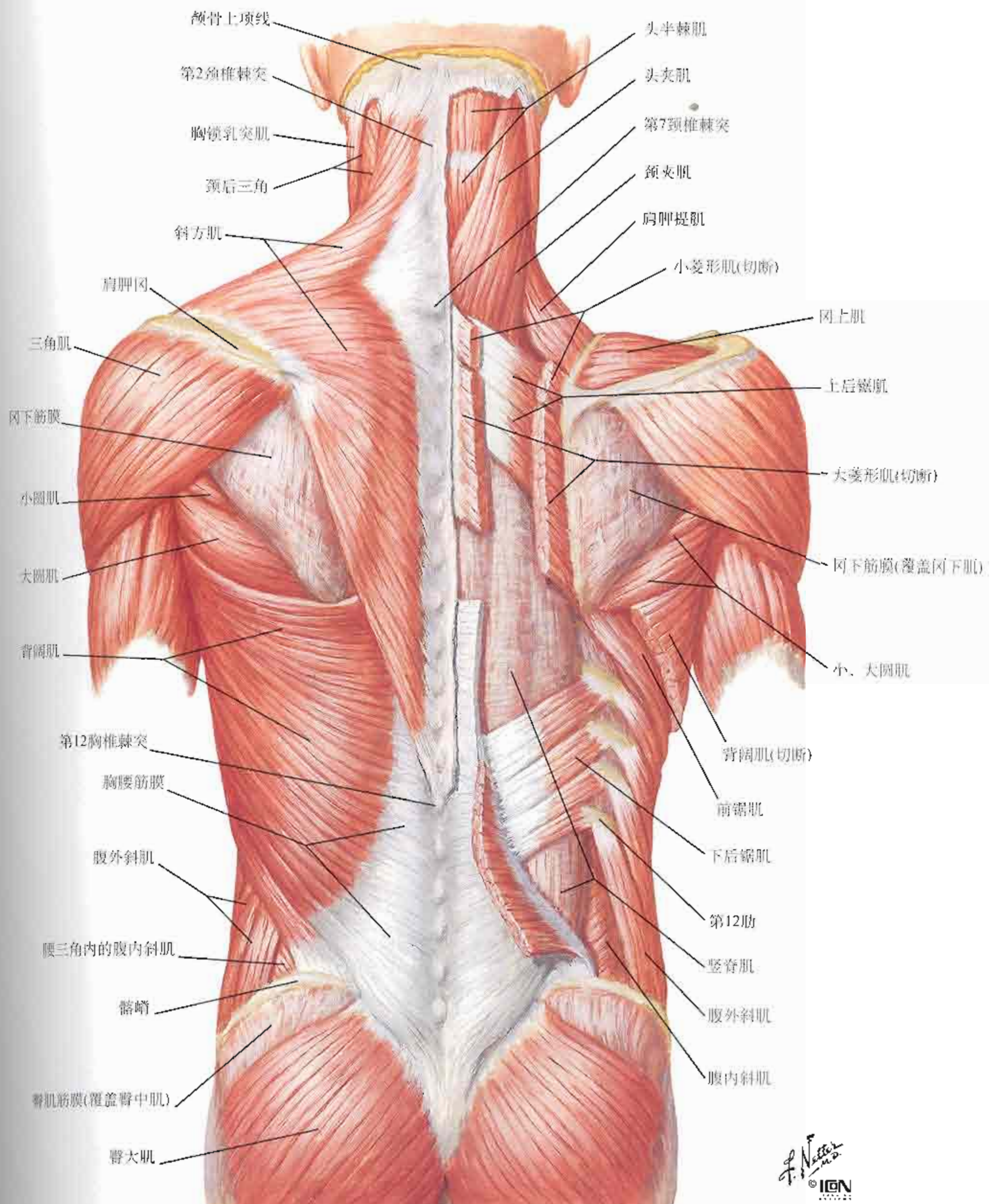


注释：所有的脊神经根均有伴行的根动脉或脊髓段动脉，大多数脊神经根有根动脉。两种动脉都沿脊神经根走行，但根动脉在到达脊髓前或脊髓后动脉之前已终止；较粗大的脊髓段动脉继续延伸，供应这些根动脉的脊髓节段



F. Netter M.D.
© IGM

图166



F. Netter M.D. © ION

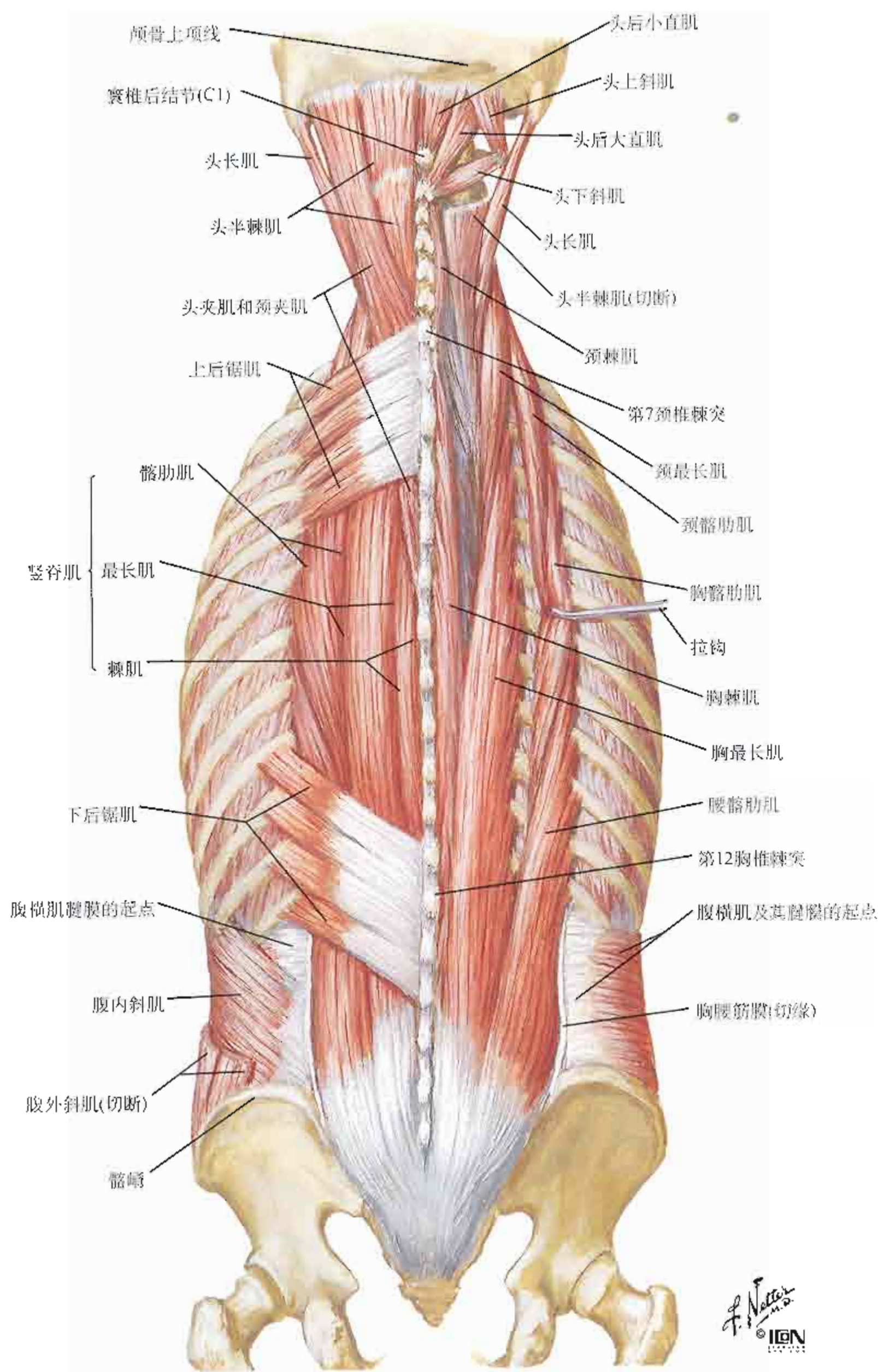


图168



运动科学网站



运动科学网站



运动科学网站



运动科学网站

www.vo2maxcn.com

背部的神经

参见图173、187、246、250

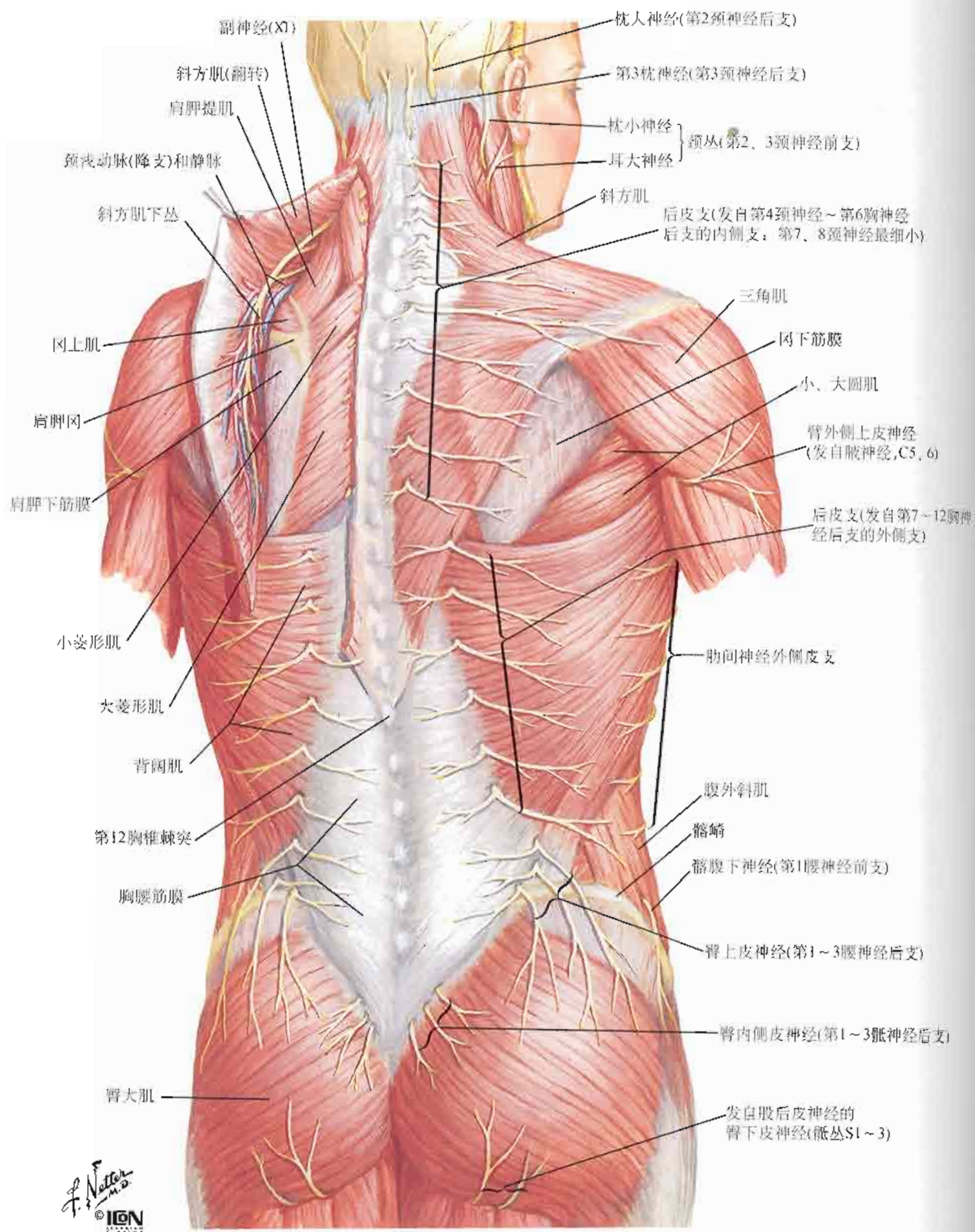


图170



运动科学网站



运动科学网站



运动科学网站



运动科学网站

www.vo2maxcn.com

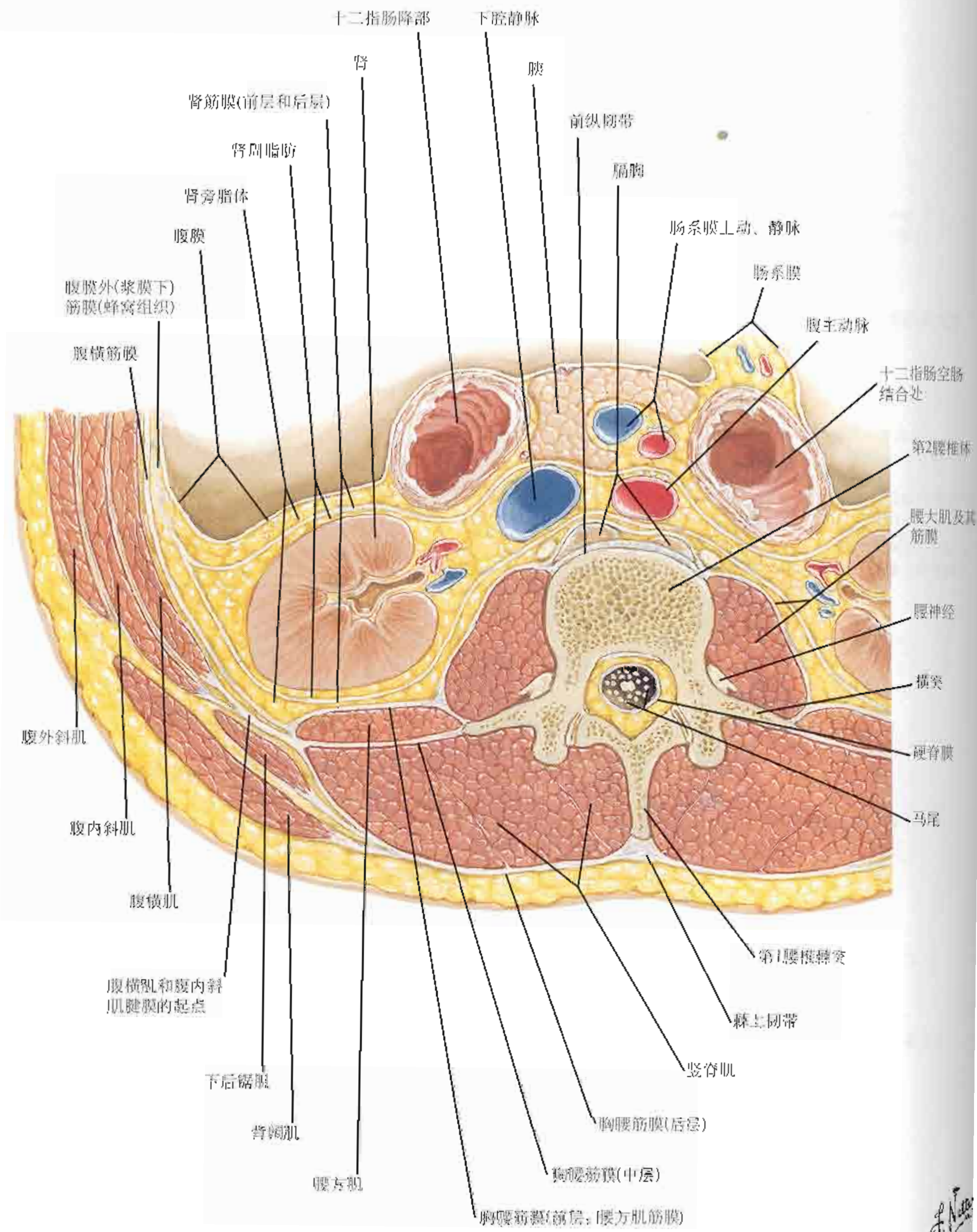
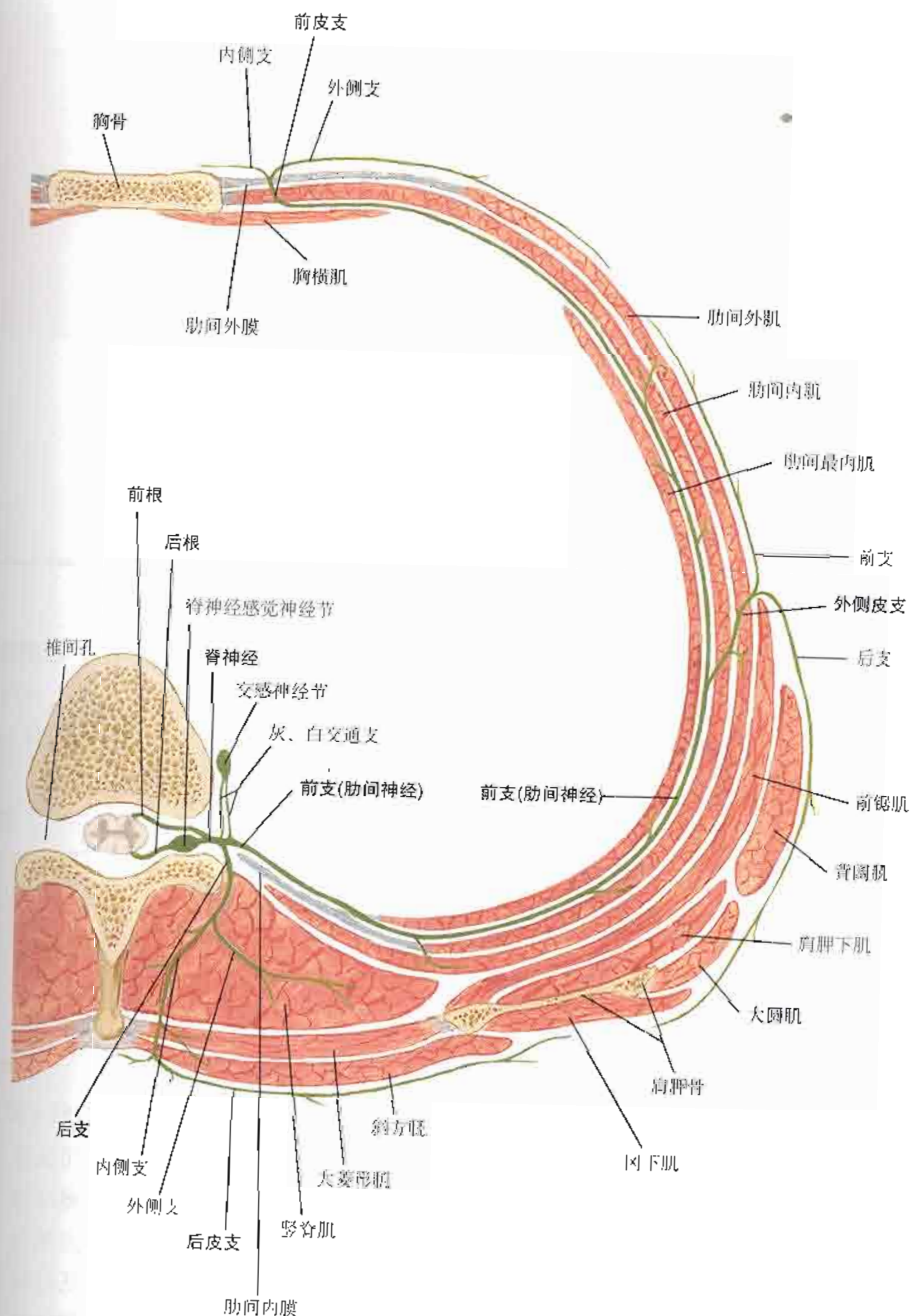
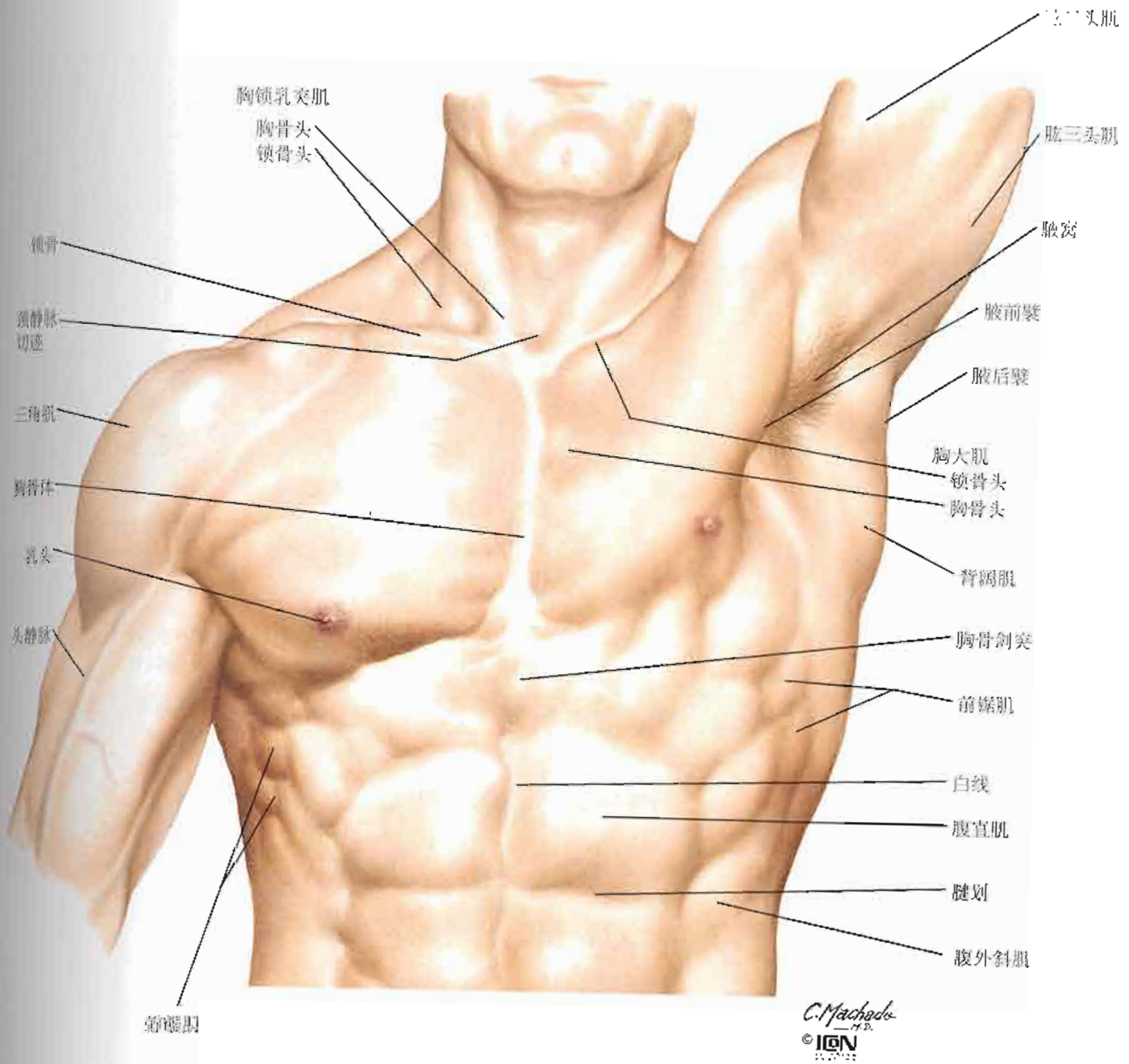


图172



注释：在胸下区，脊神经后支发出的外侧支的运动支和皮支均较长；内侧支的运动支较短

F. Netter M.D.



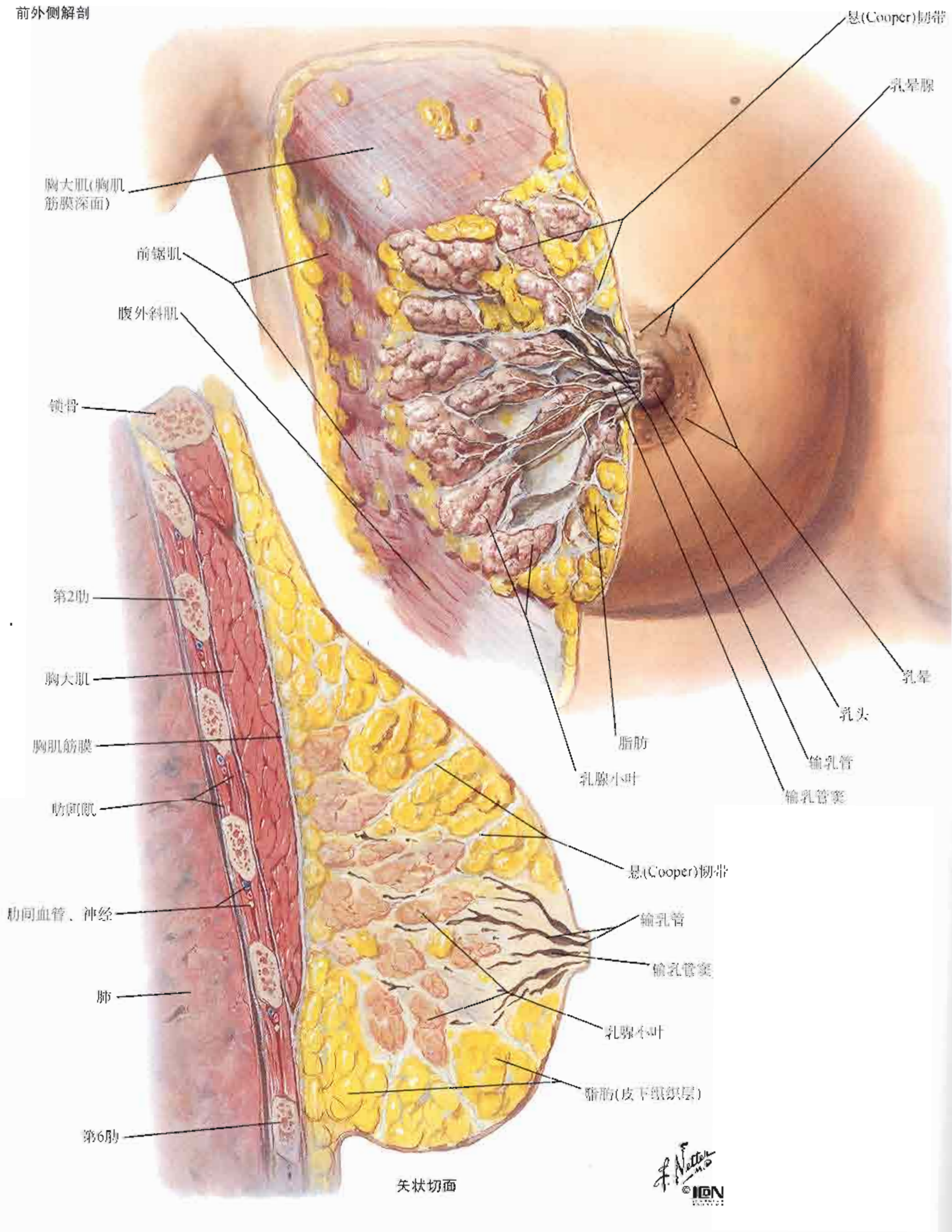
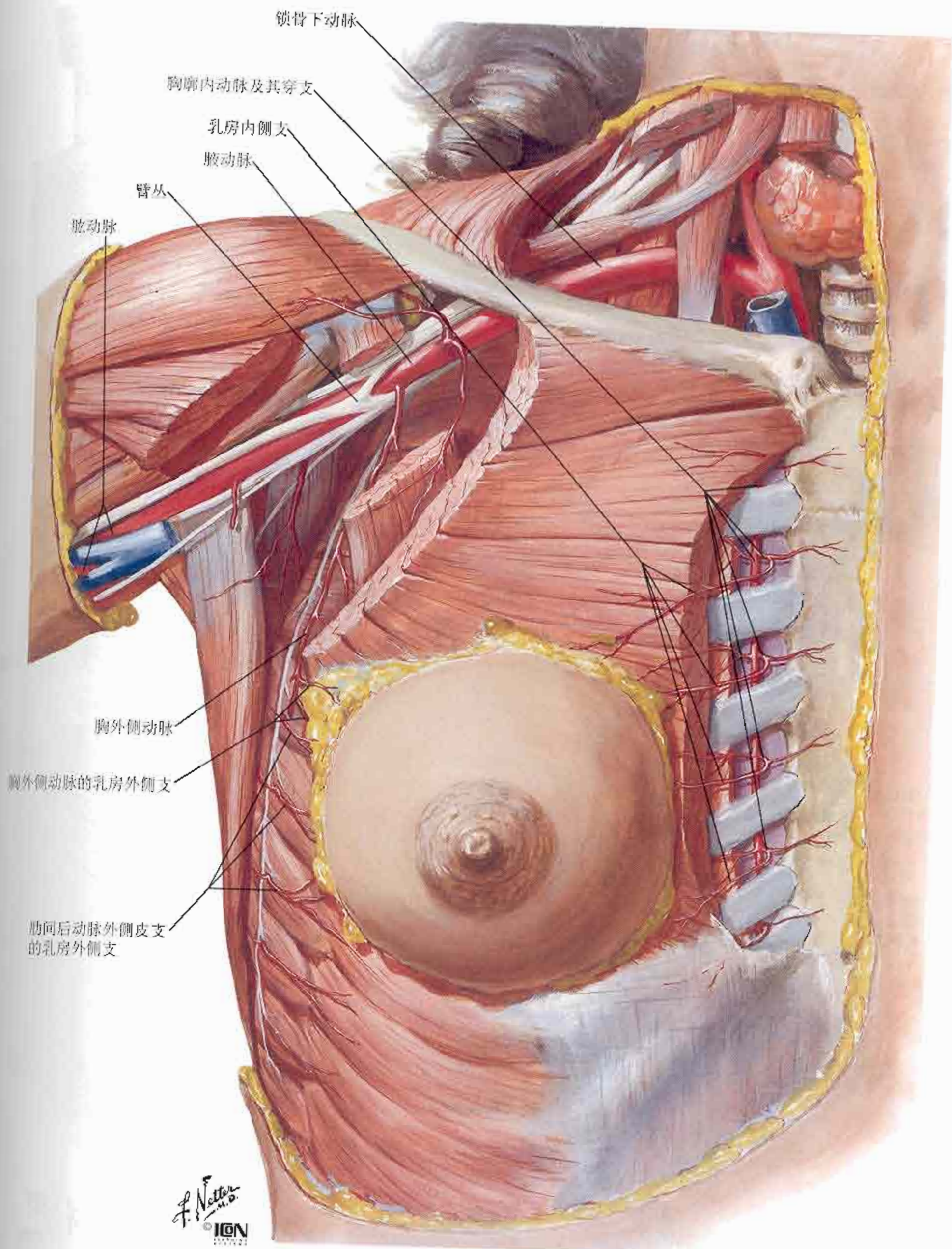


图175



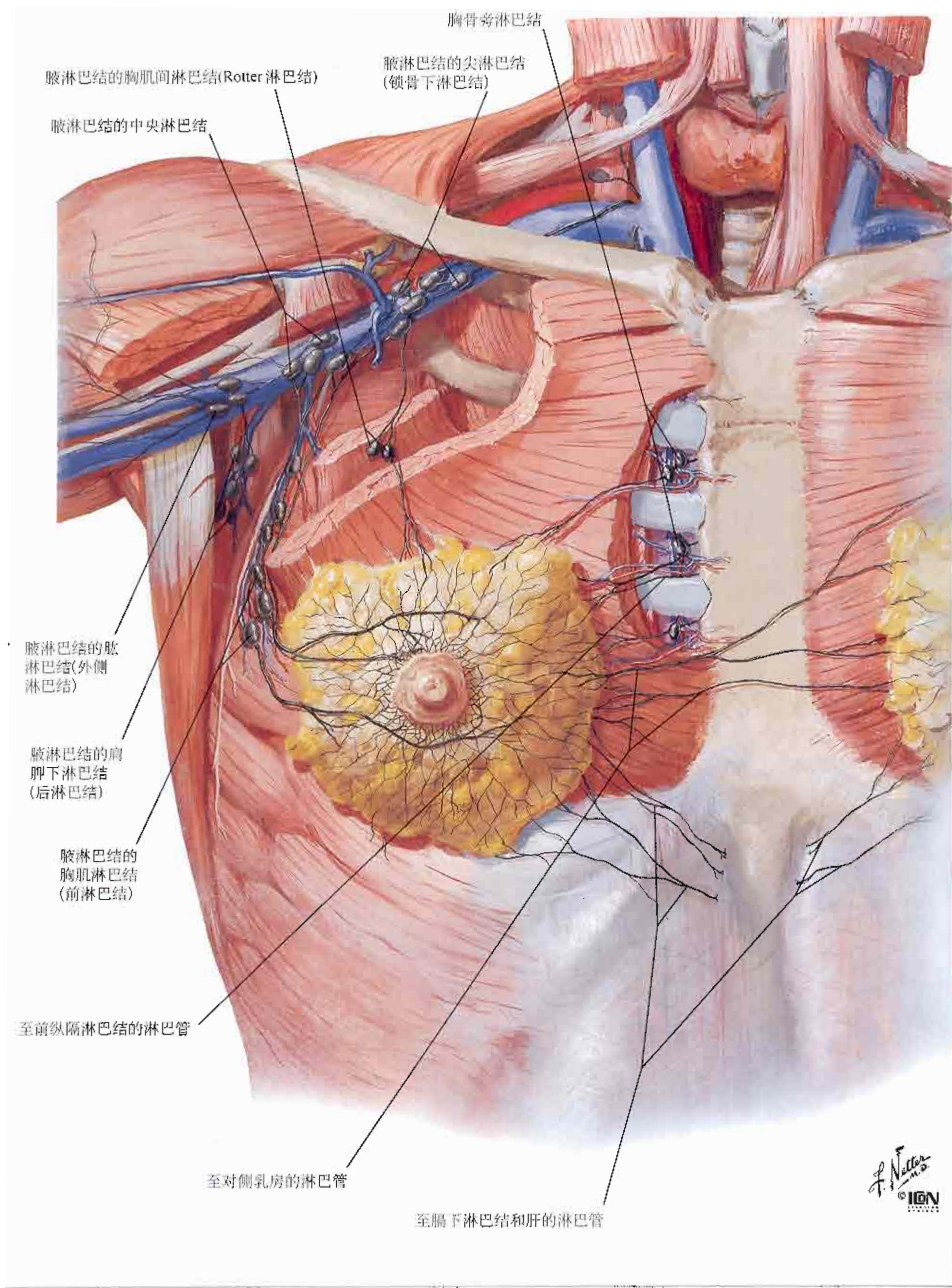
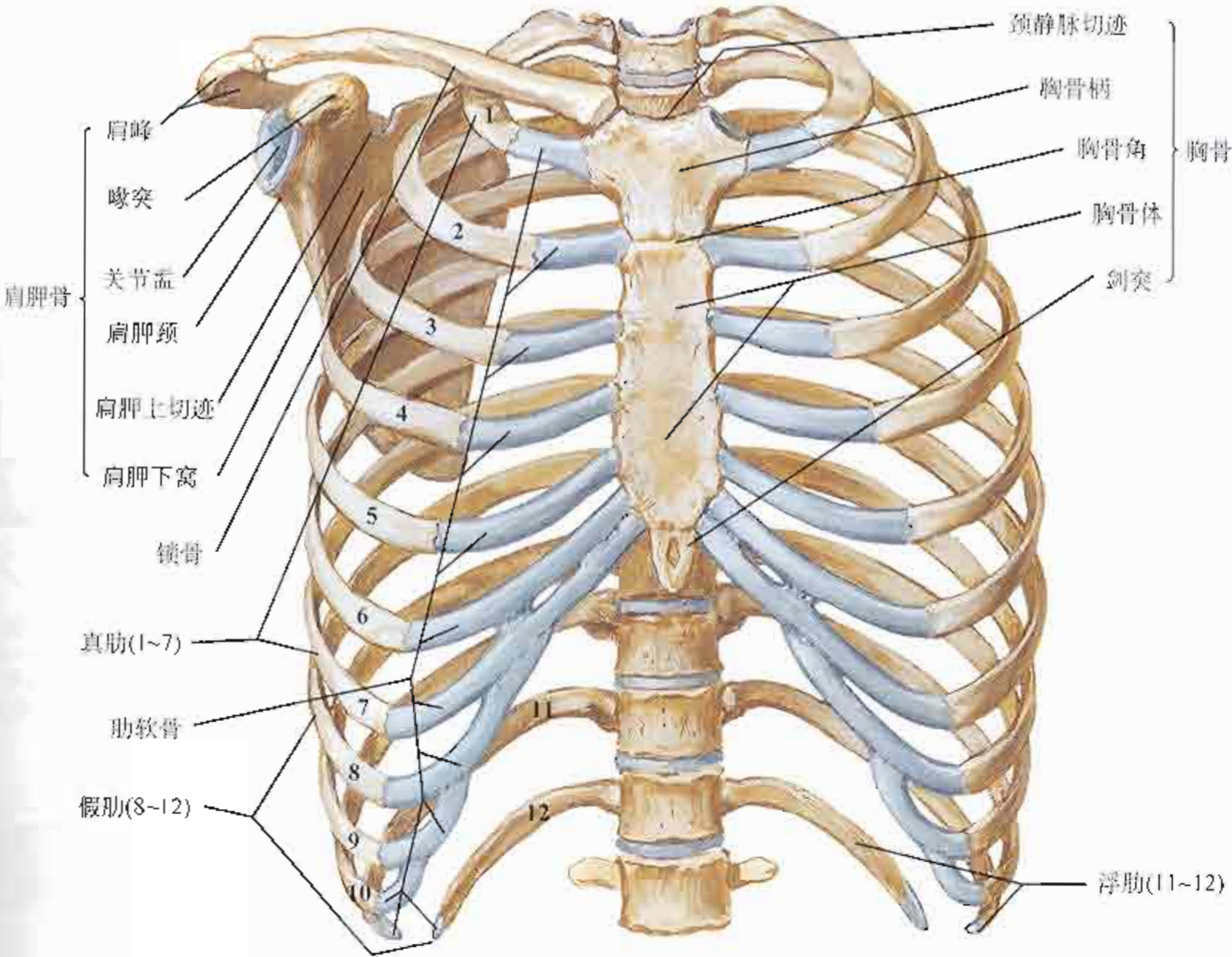


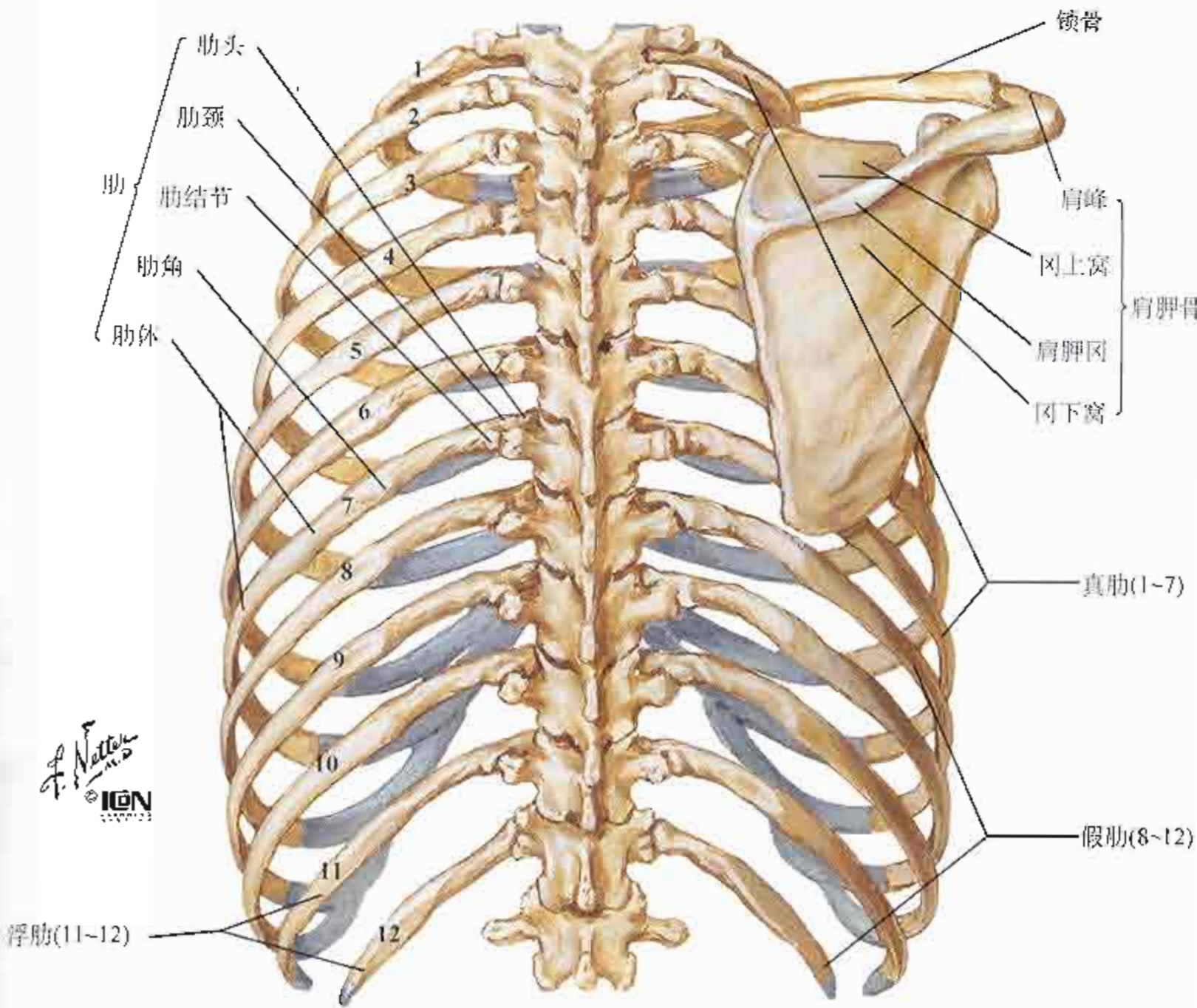
图177

参见图240

前面观



后面观



肋和胸肋连结

左侧第1肋：上面观

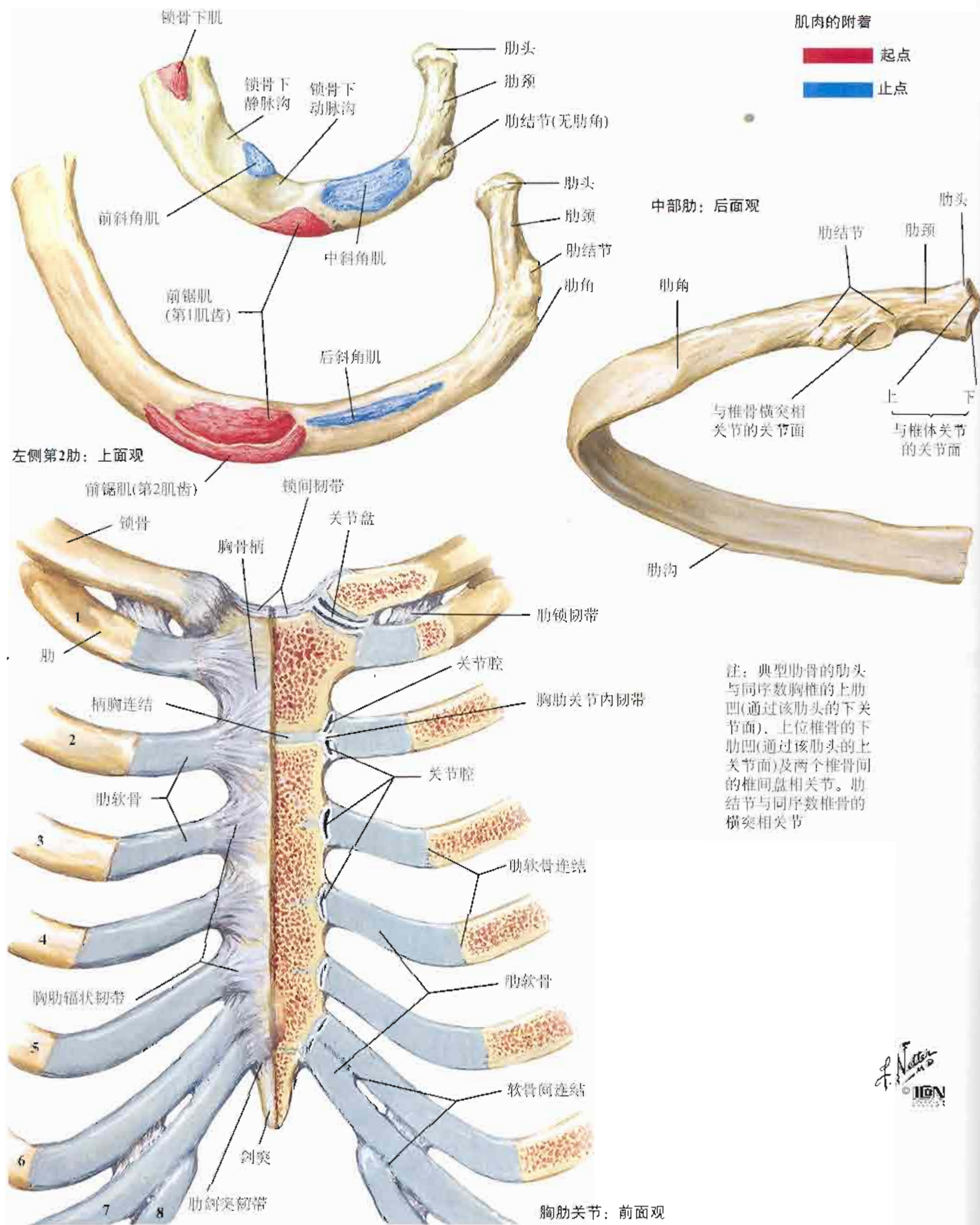
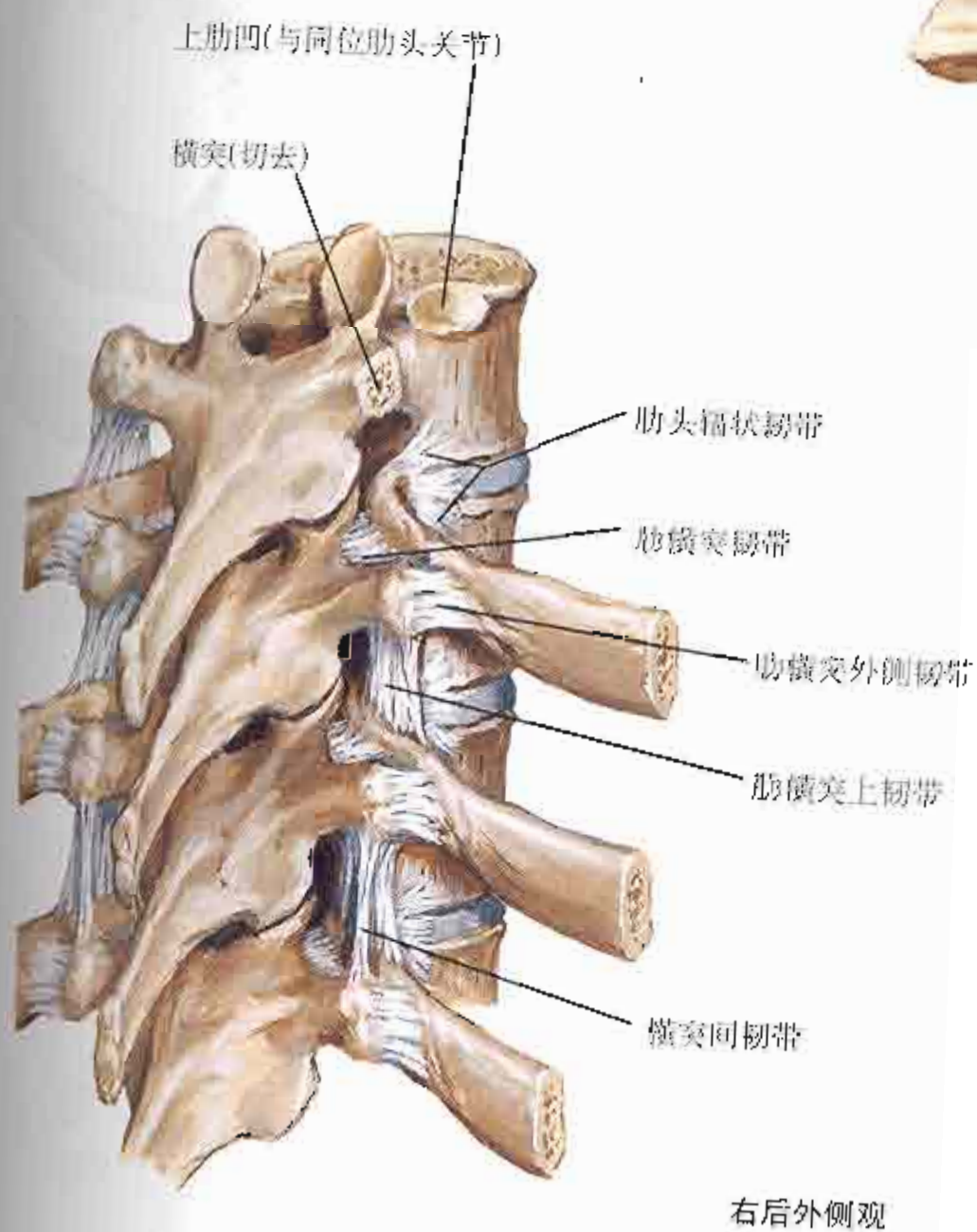
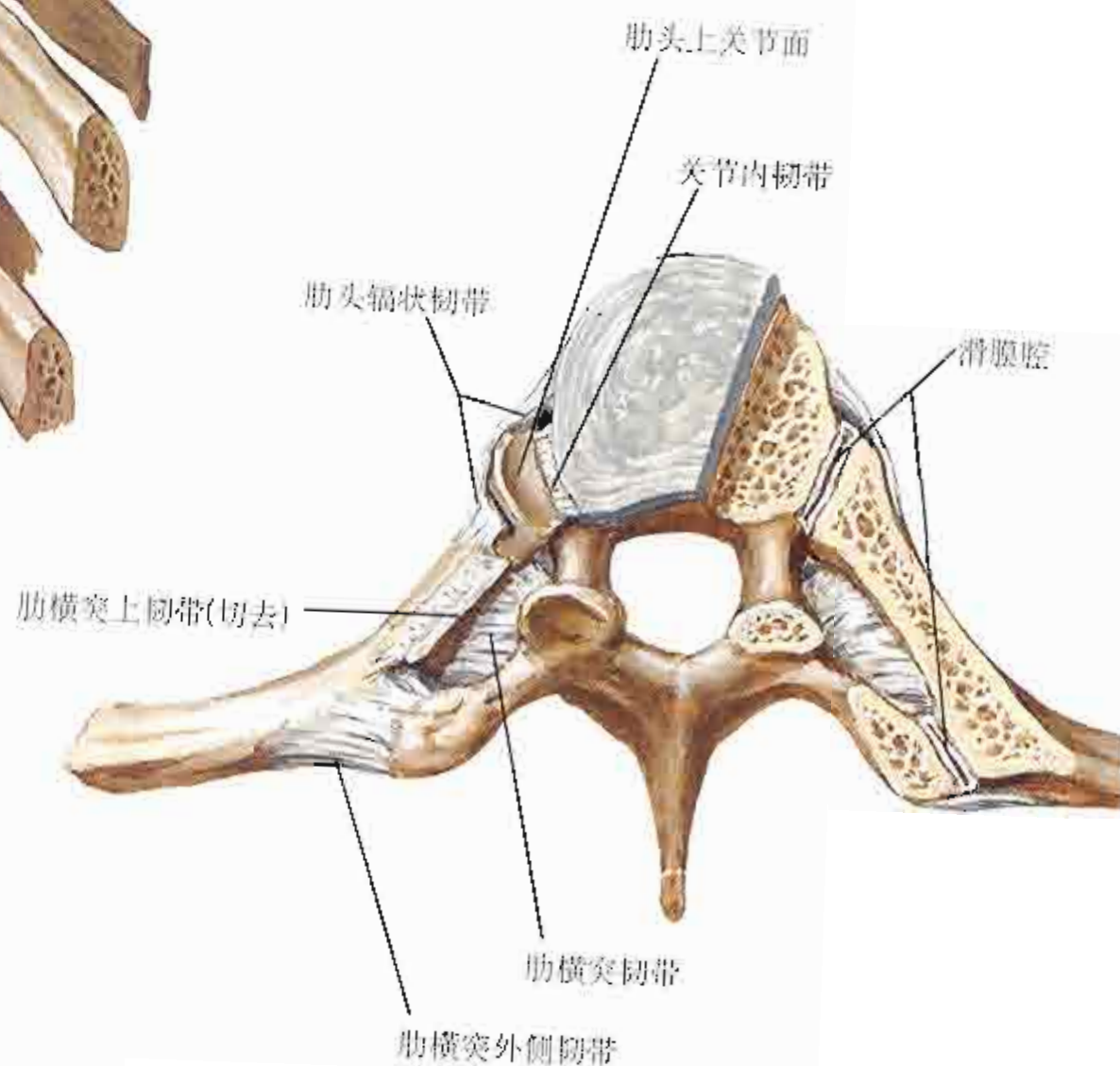
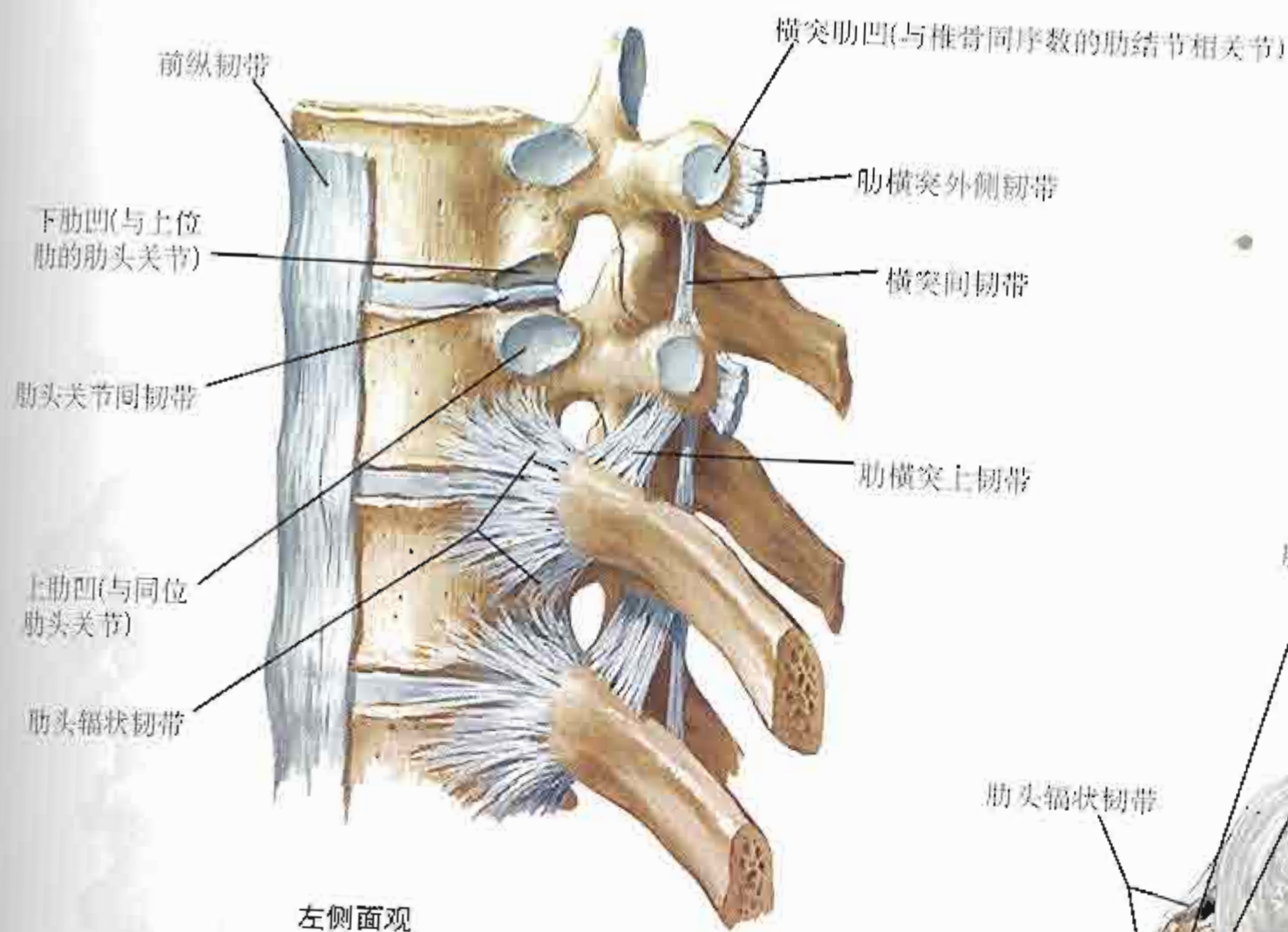


图 179



F. Netter
M.D.
© IGM

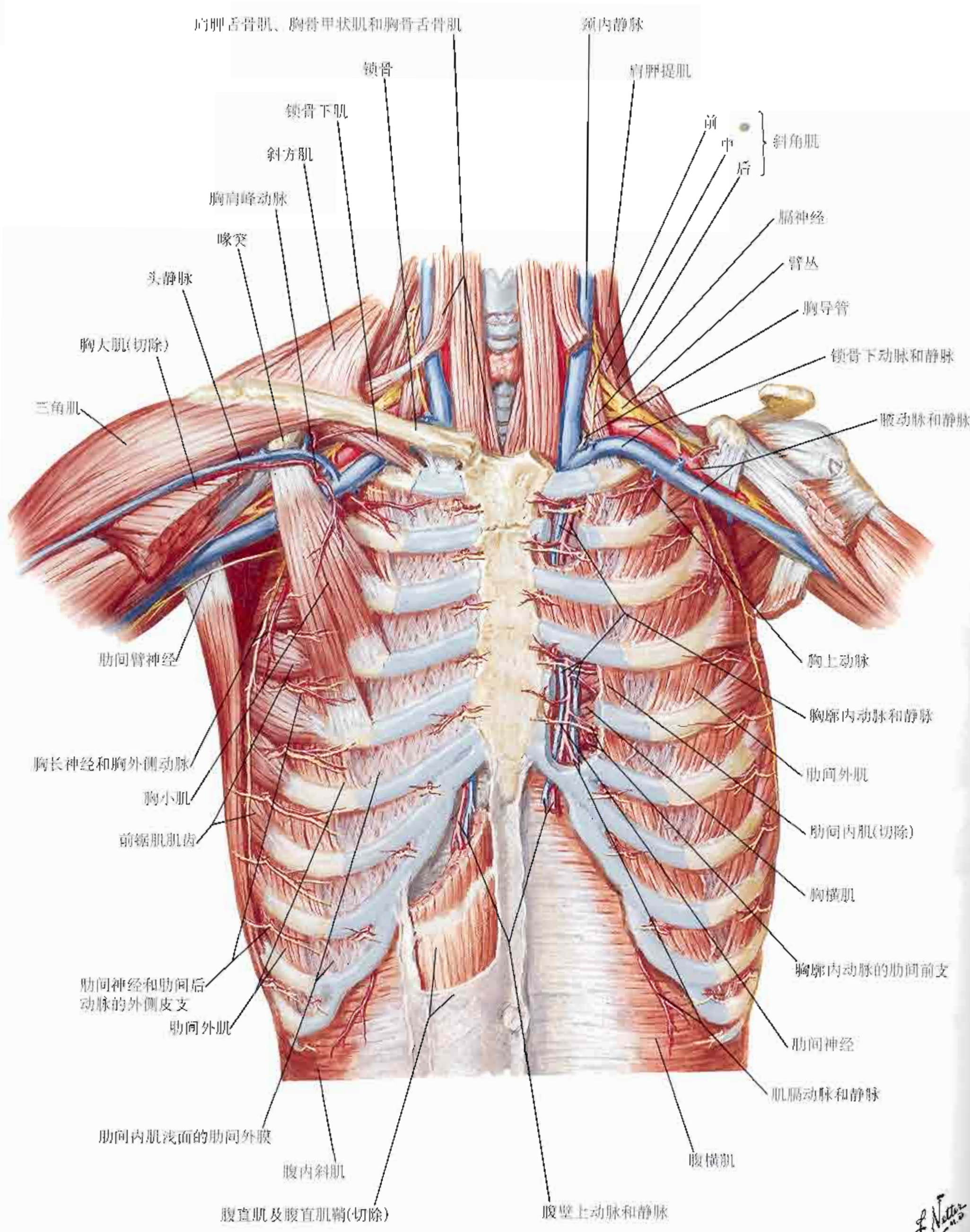


图183

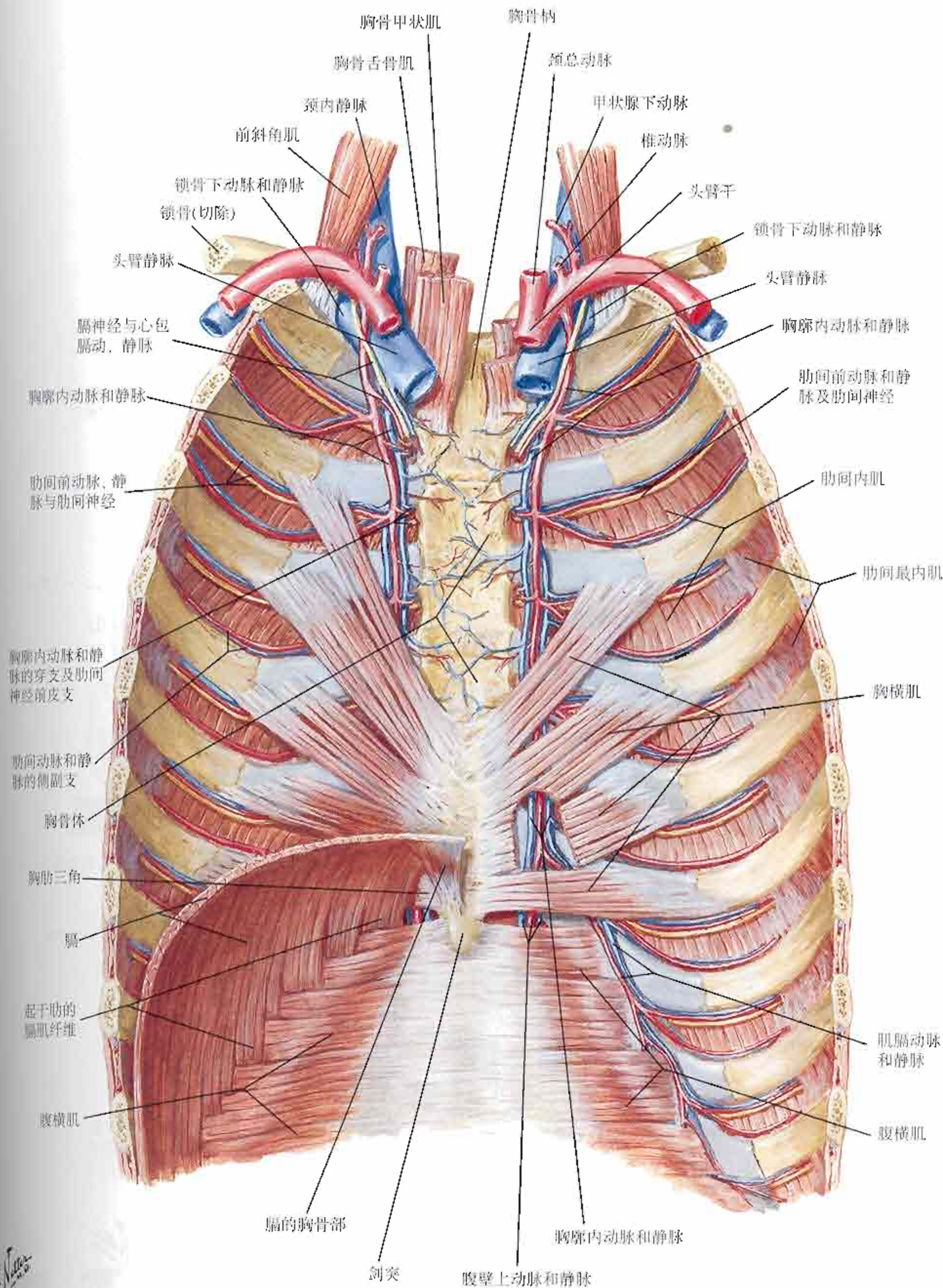


图184

参见图167~169

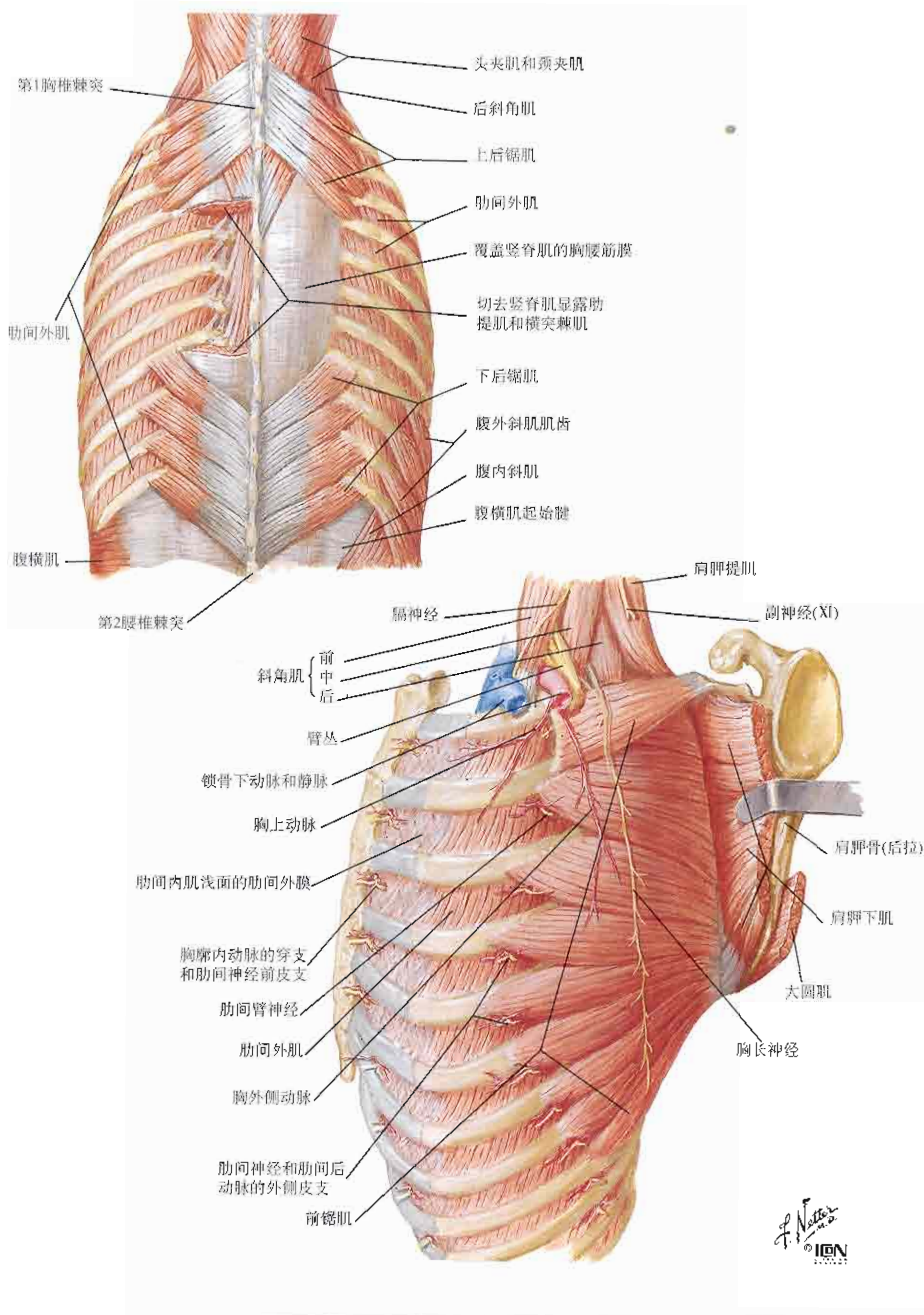


图185

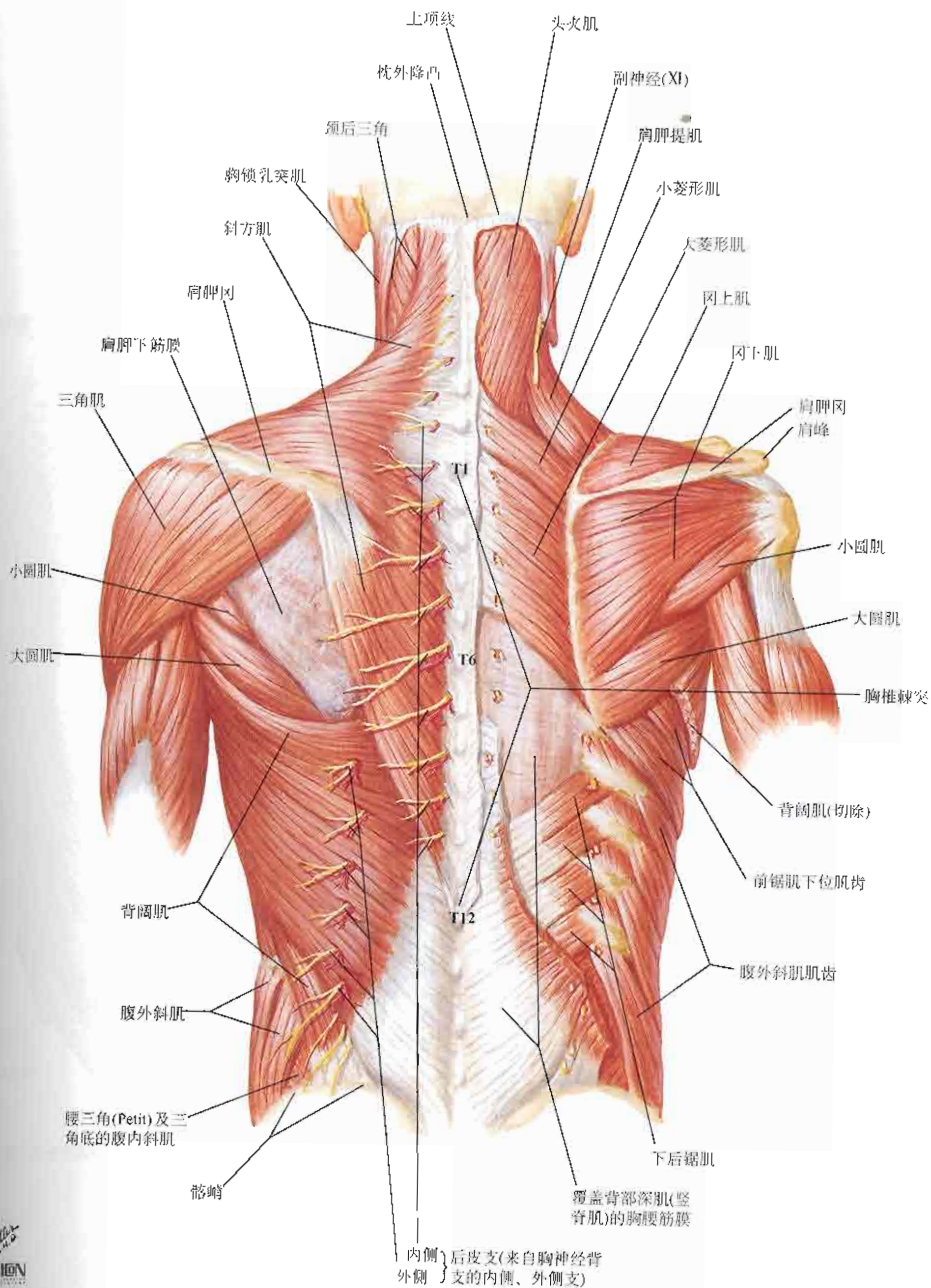


图186

参见图173、250

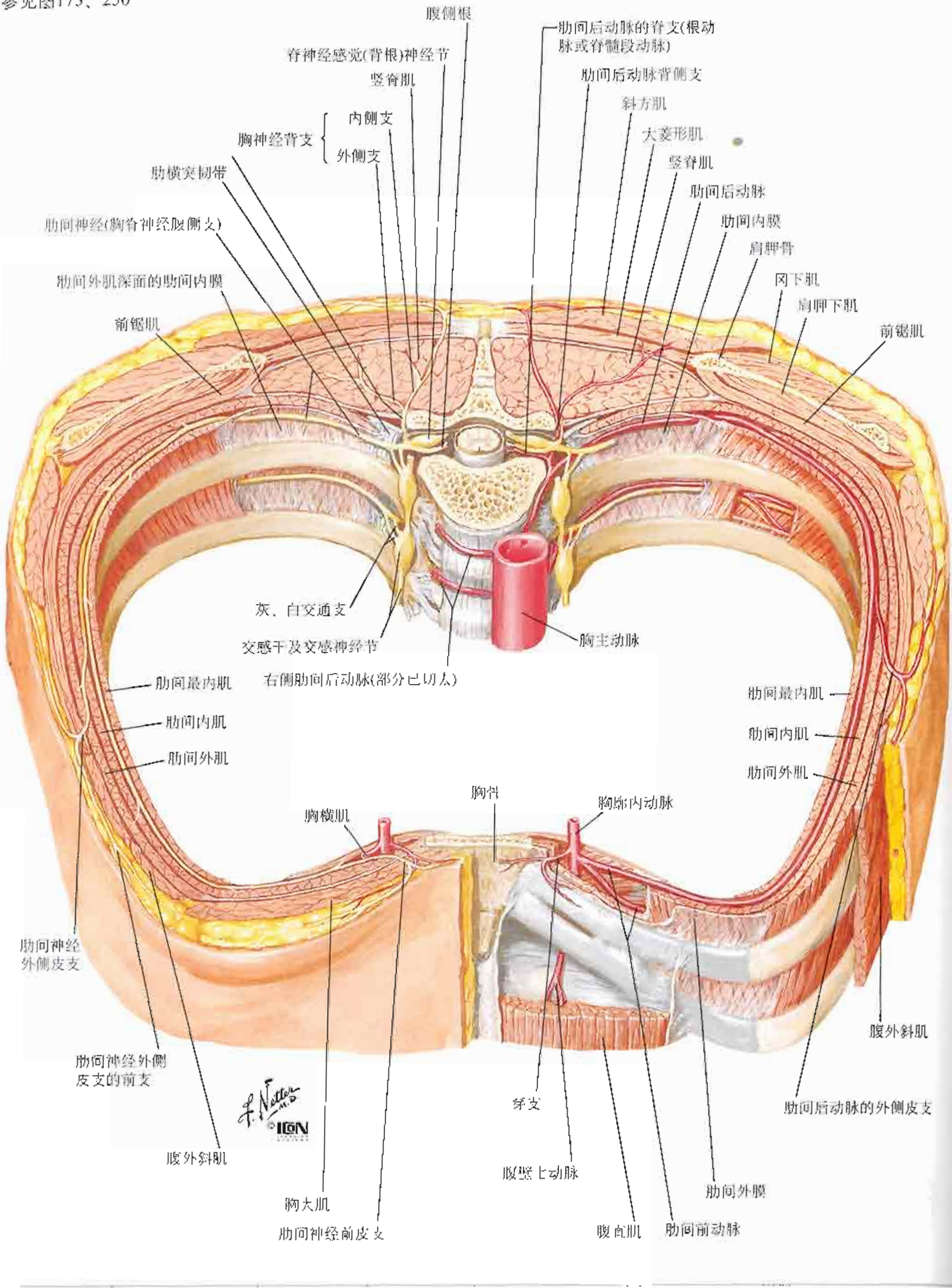


图187

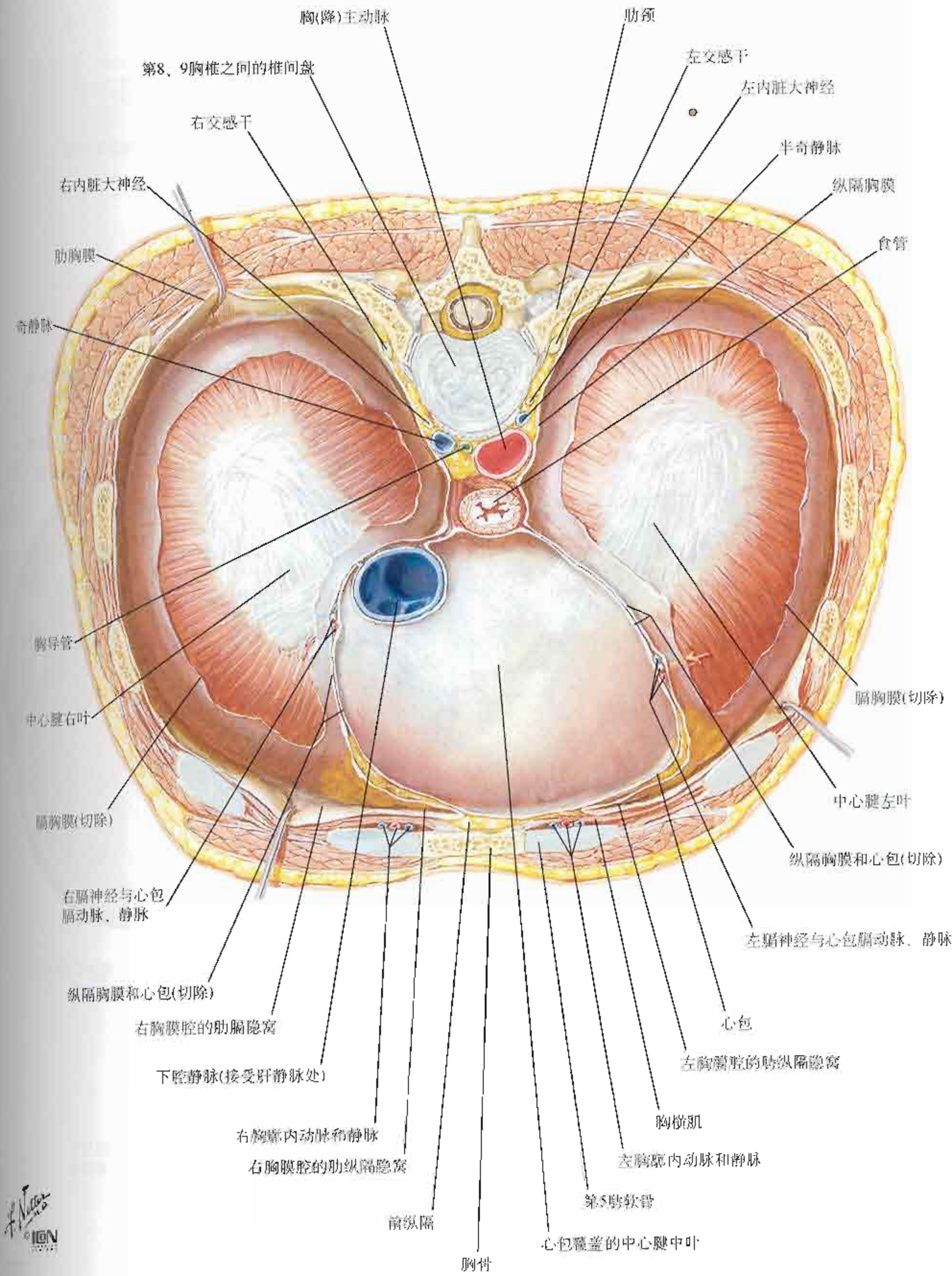


图188

膈：腹腔面

参见图245、255、262

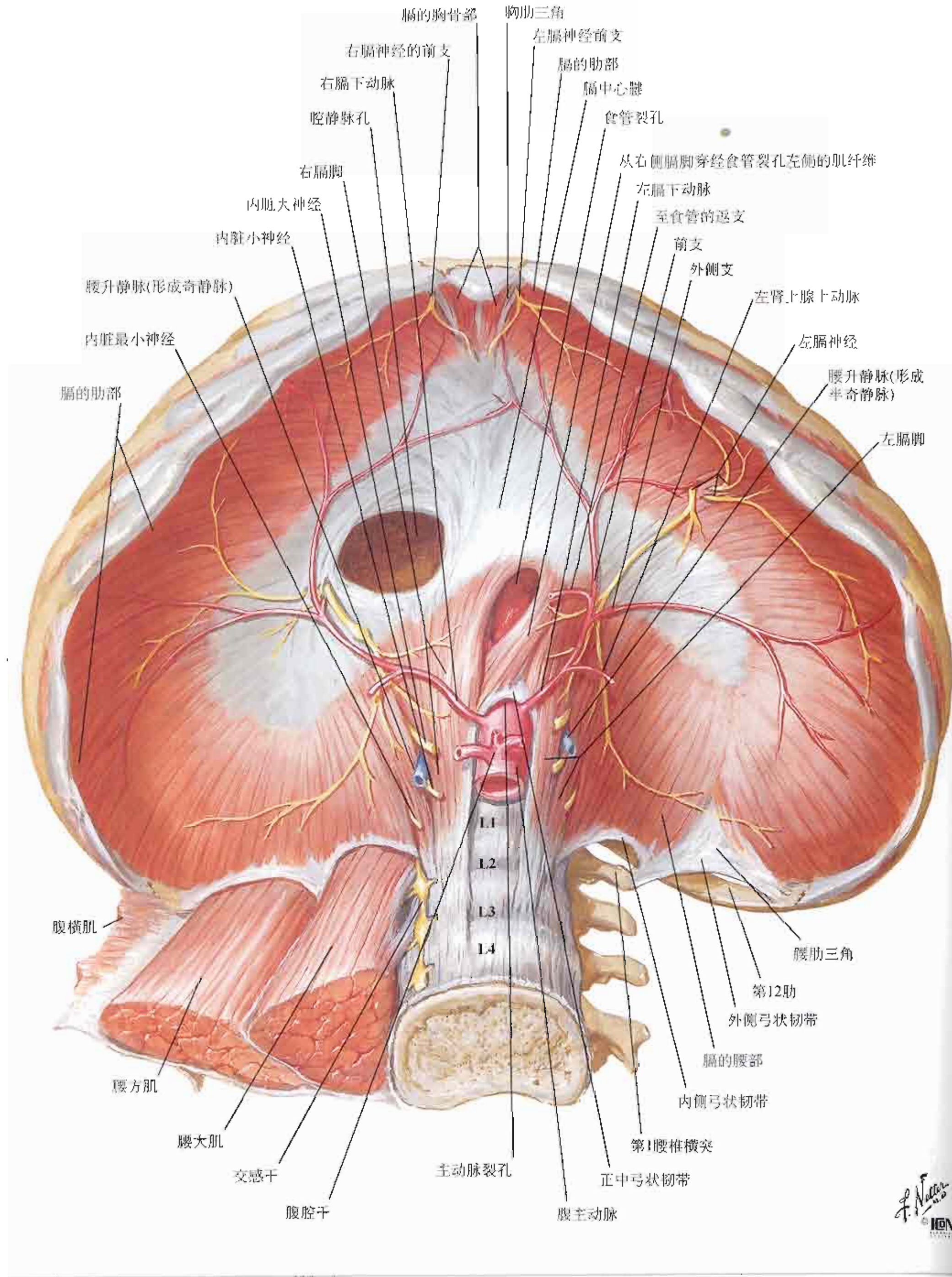
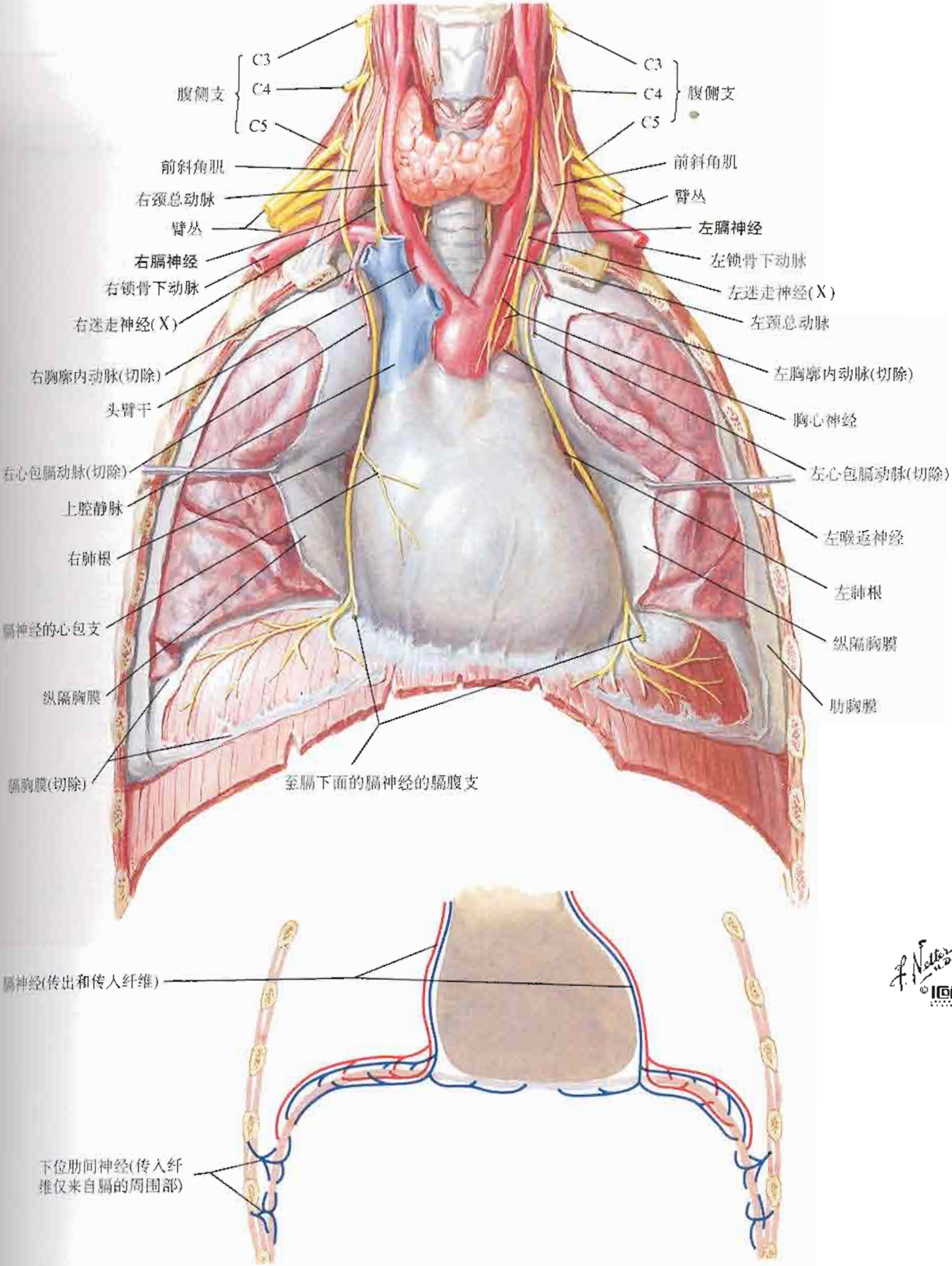


图189

胸部

参见图28、123



F. Netter M.D. ILLUSTRATIONS

图190

辅助吸气肌见图169、185

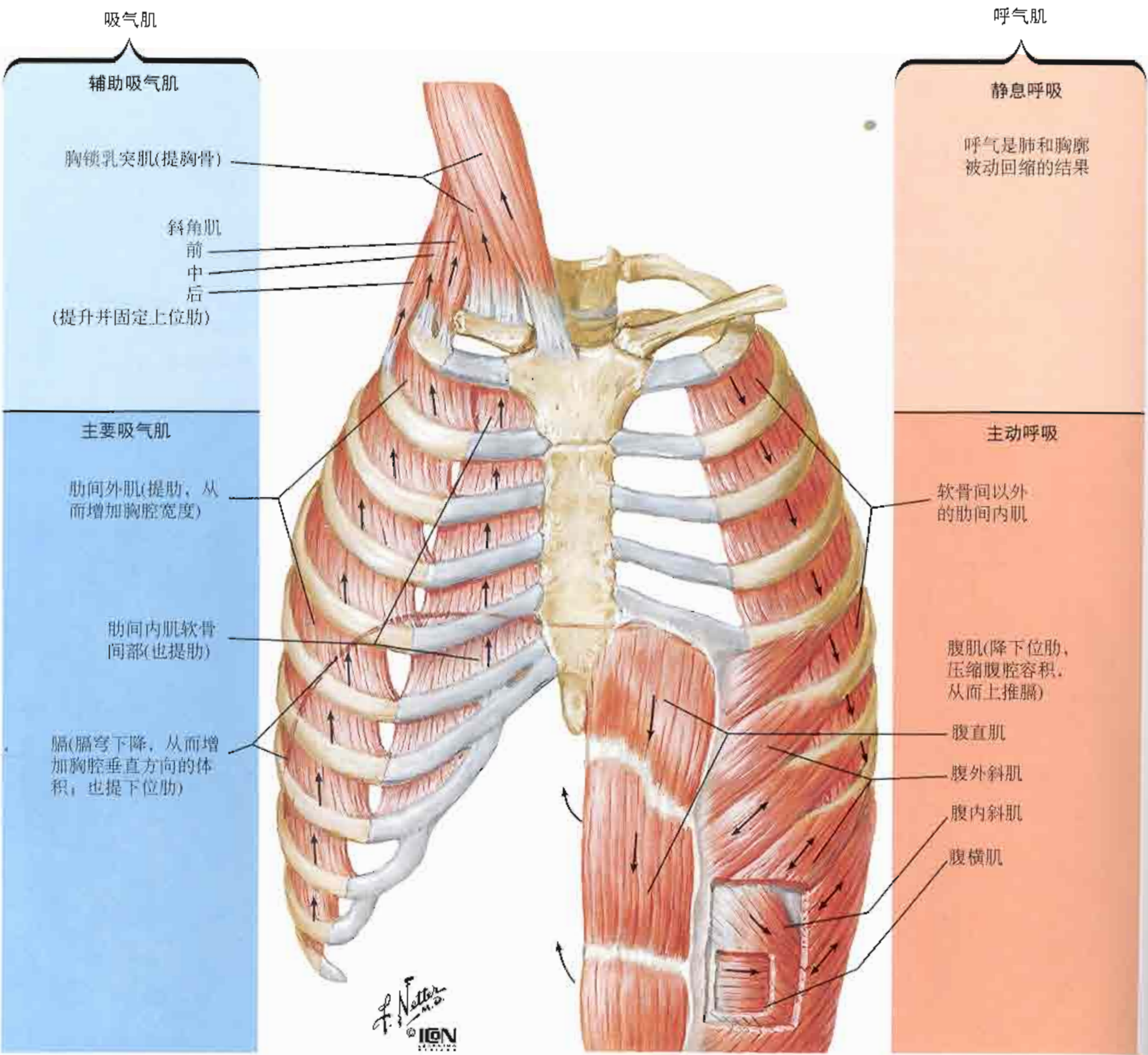
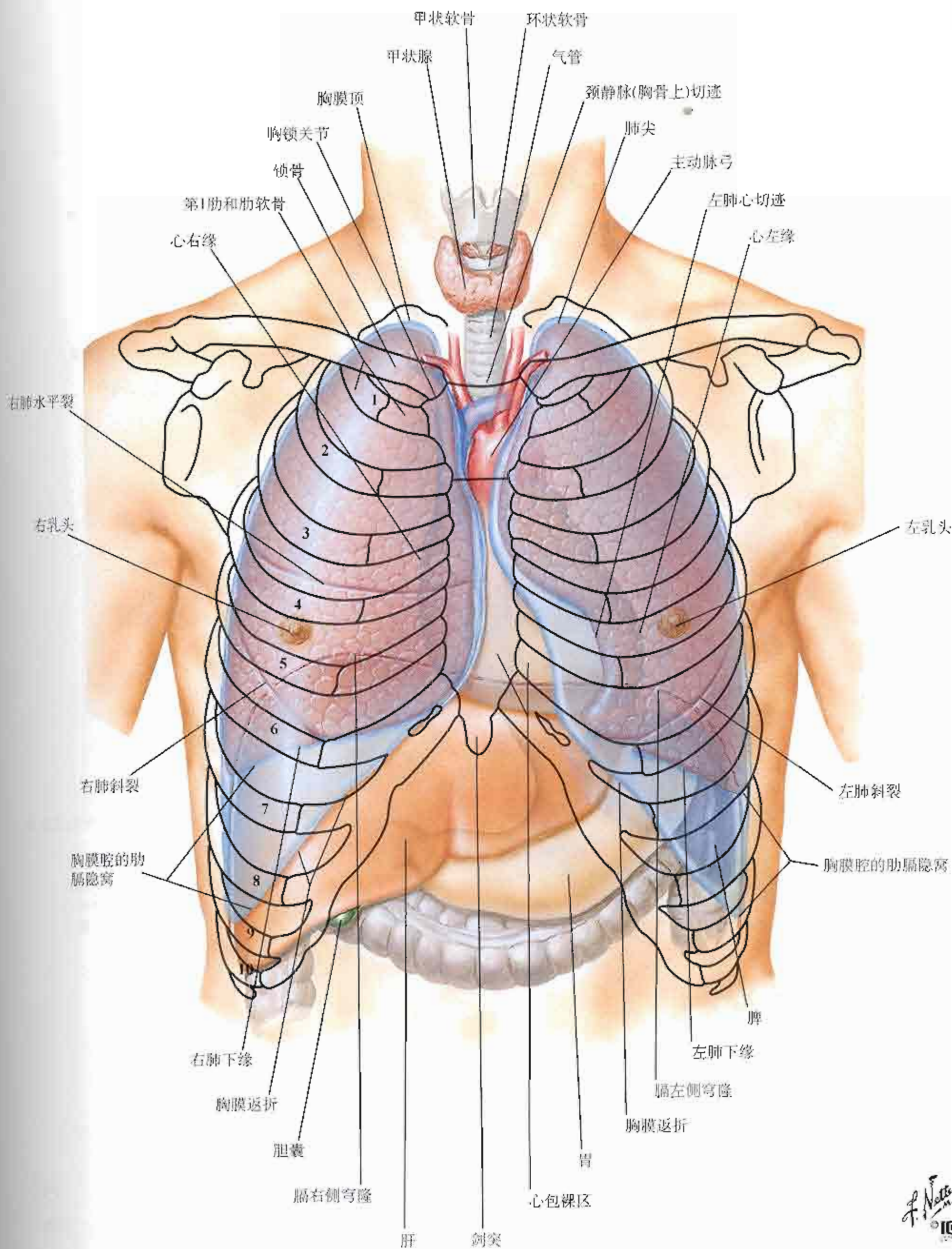


图191



F. Netter M.D.
© IGV

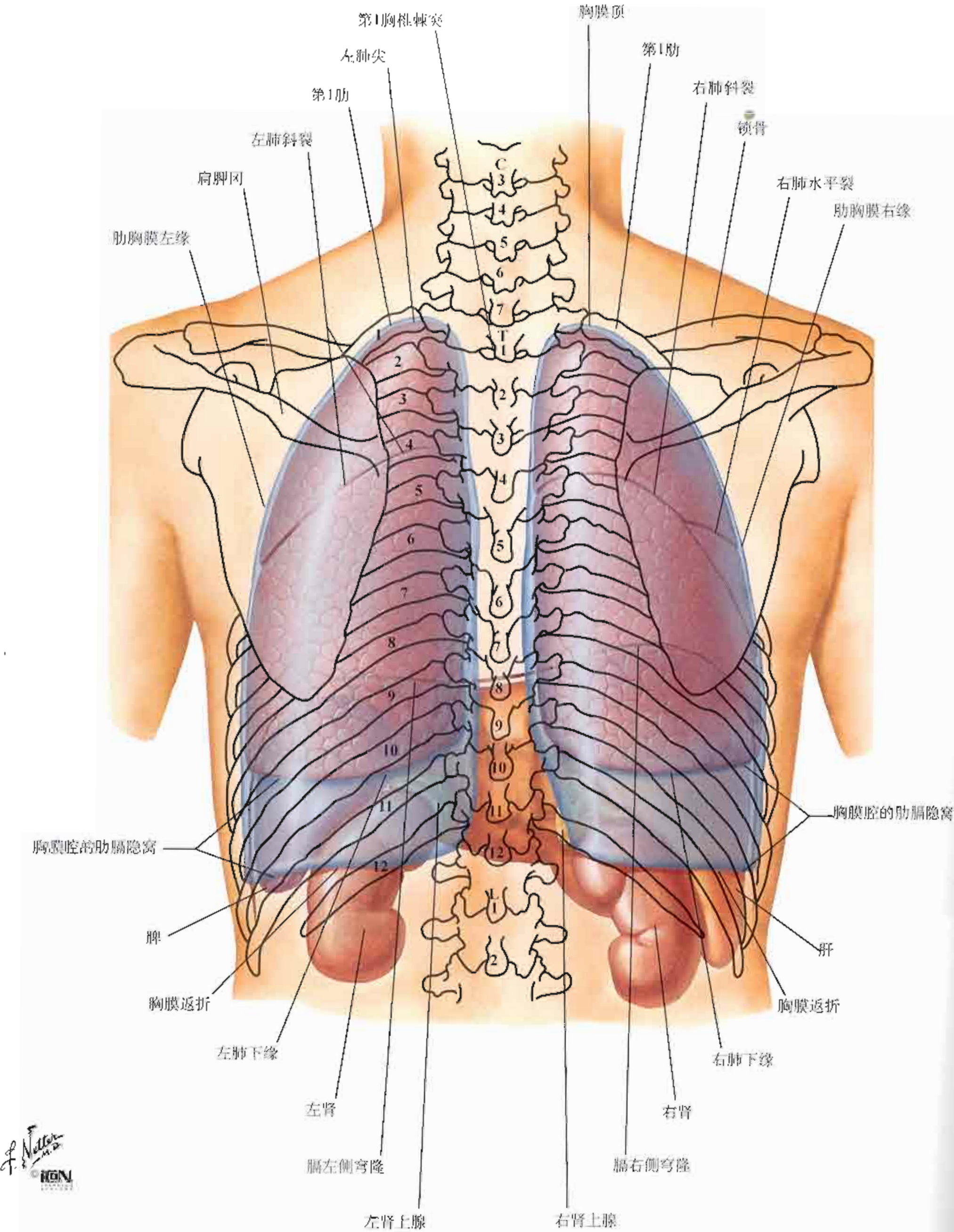


图193

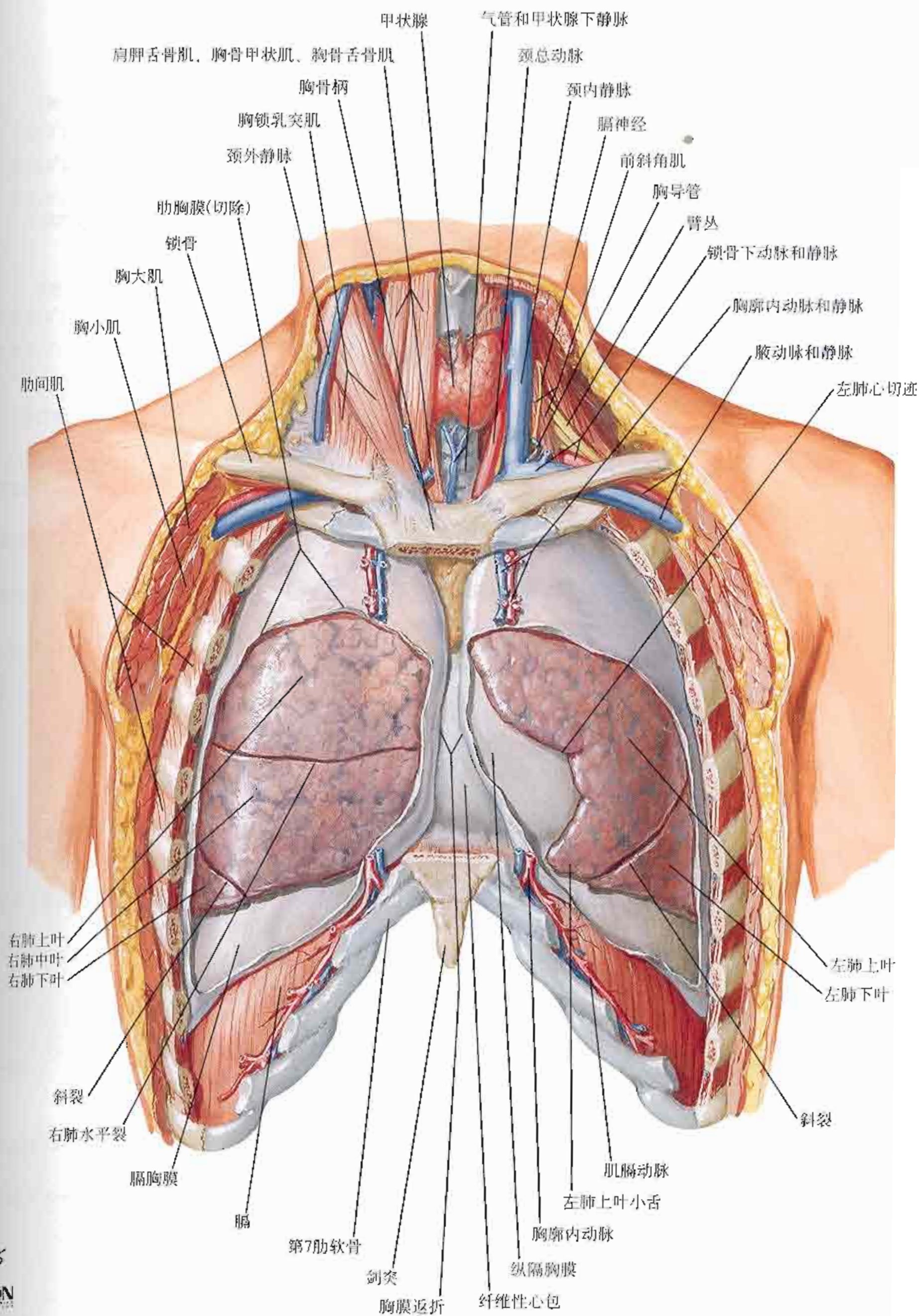


图194

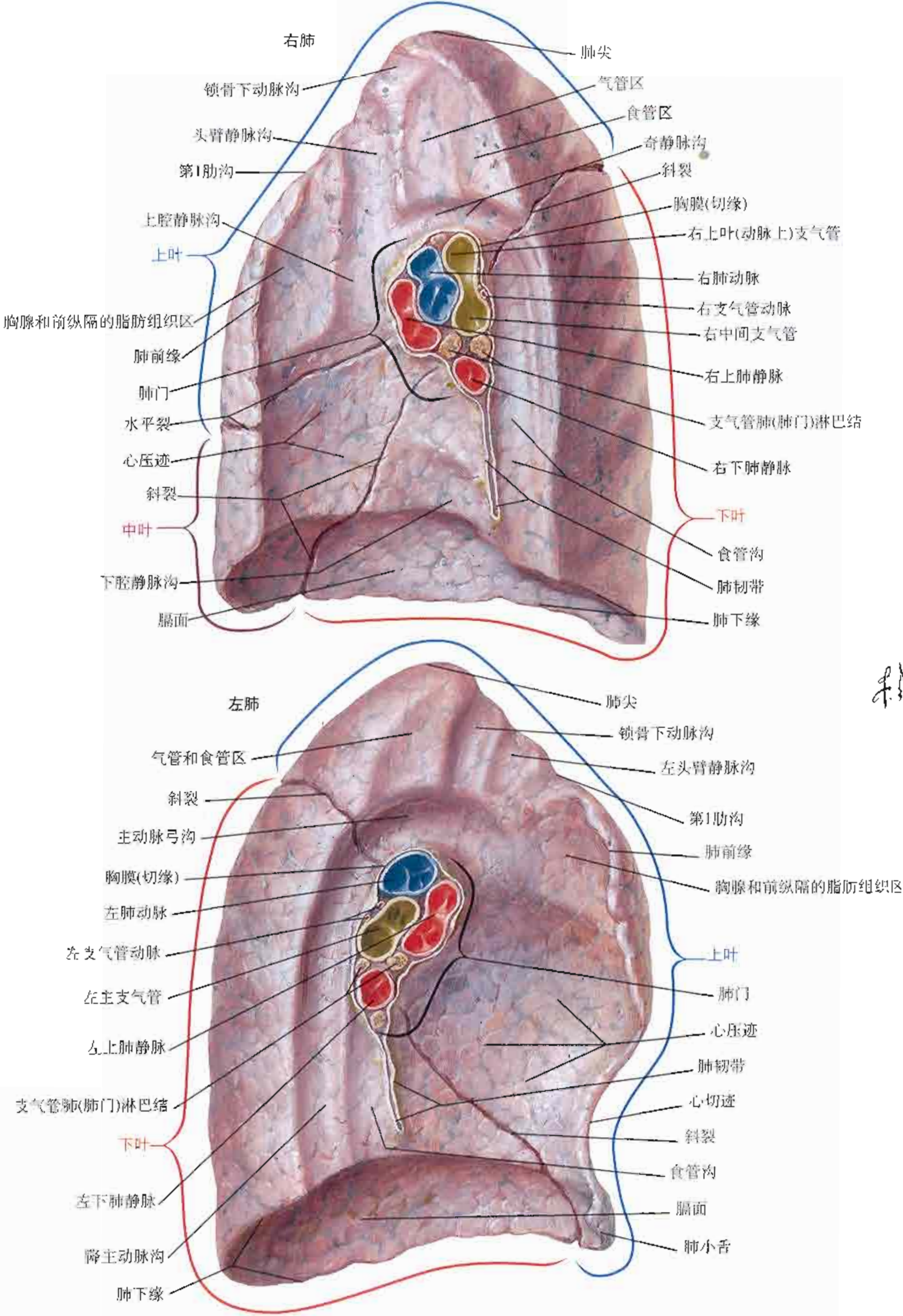
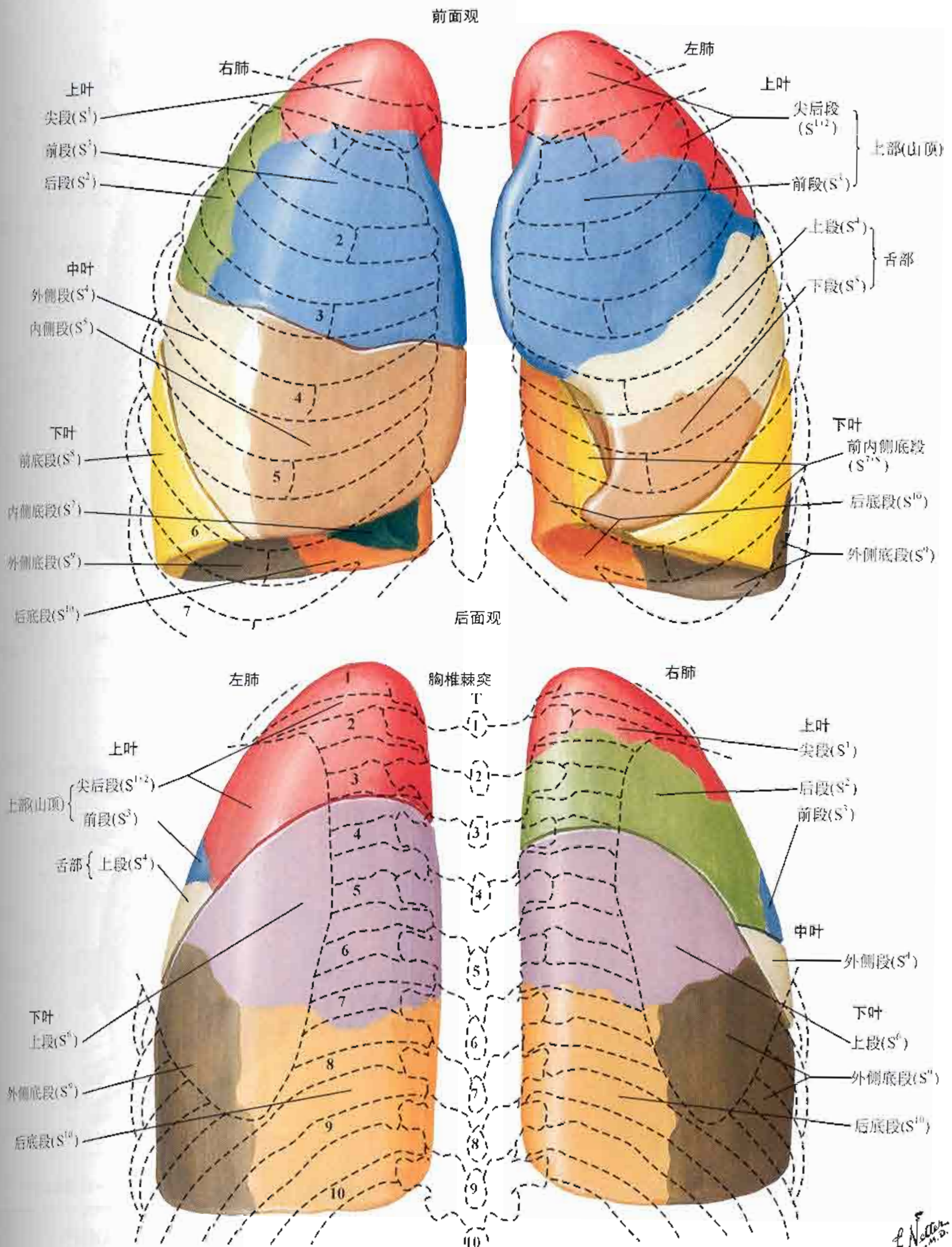


图195



F. Netter M.D.
© 1996

图196

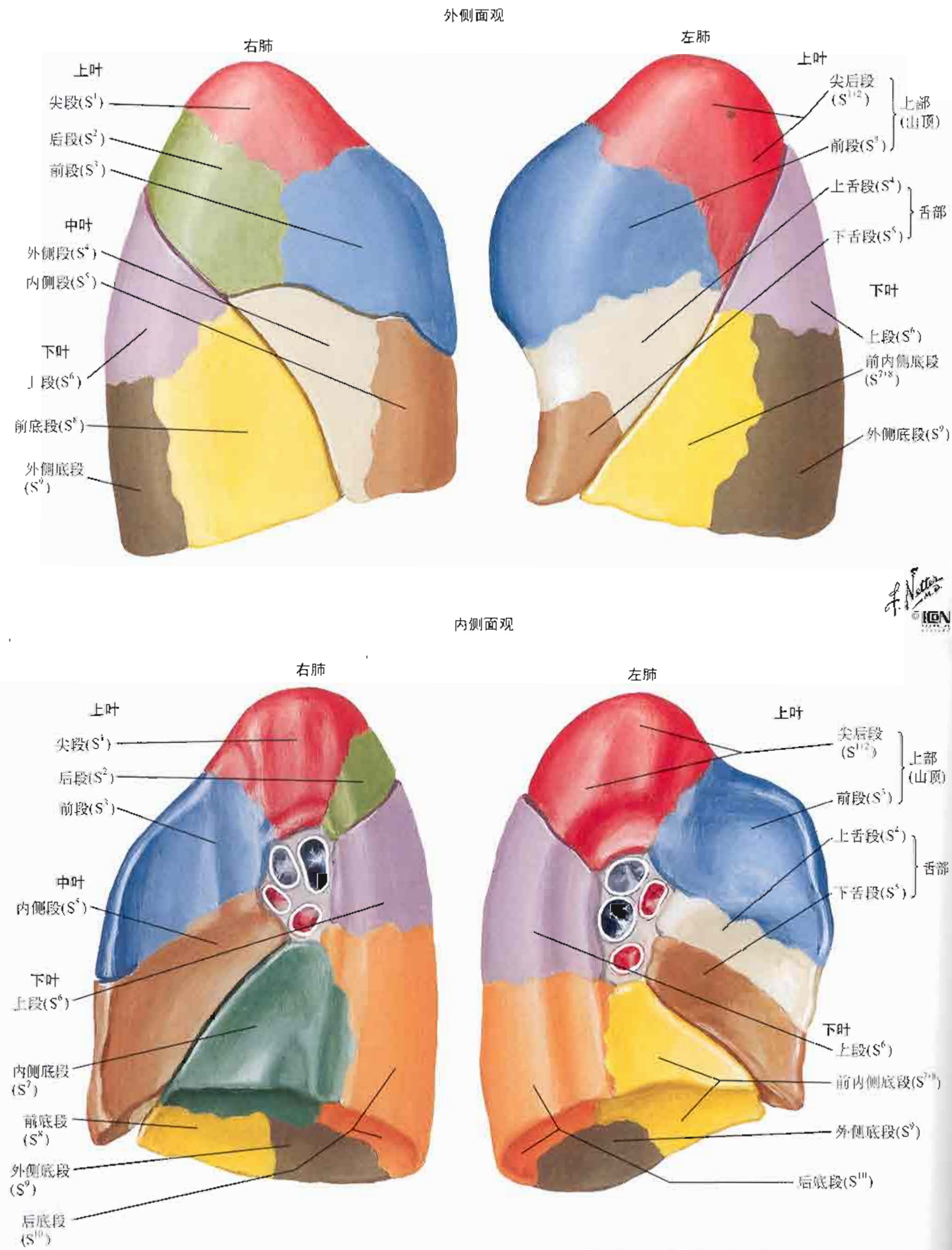


图197

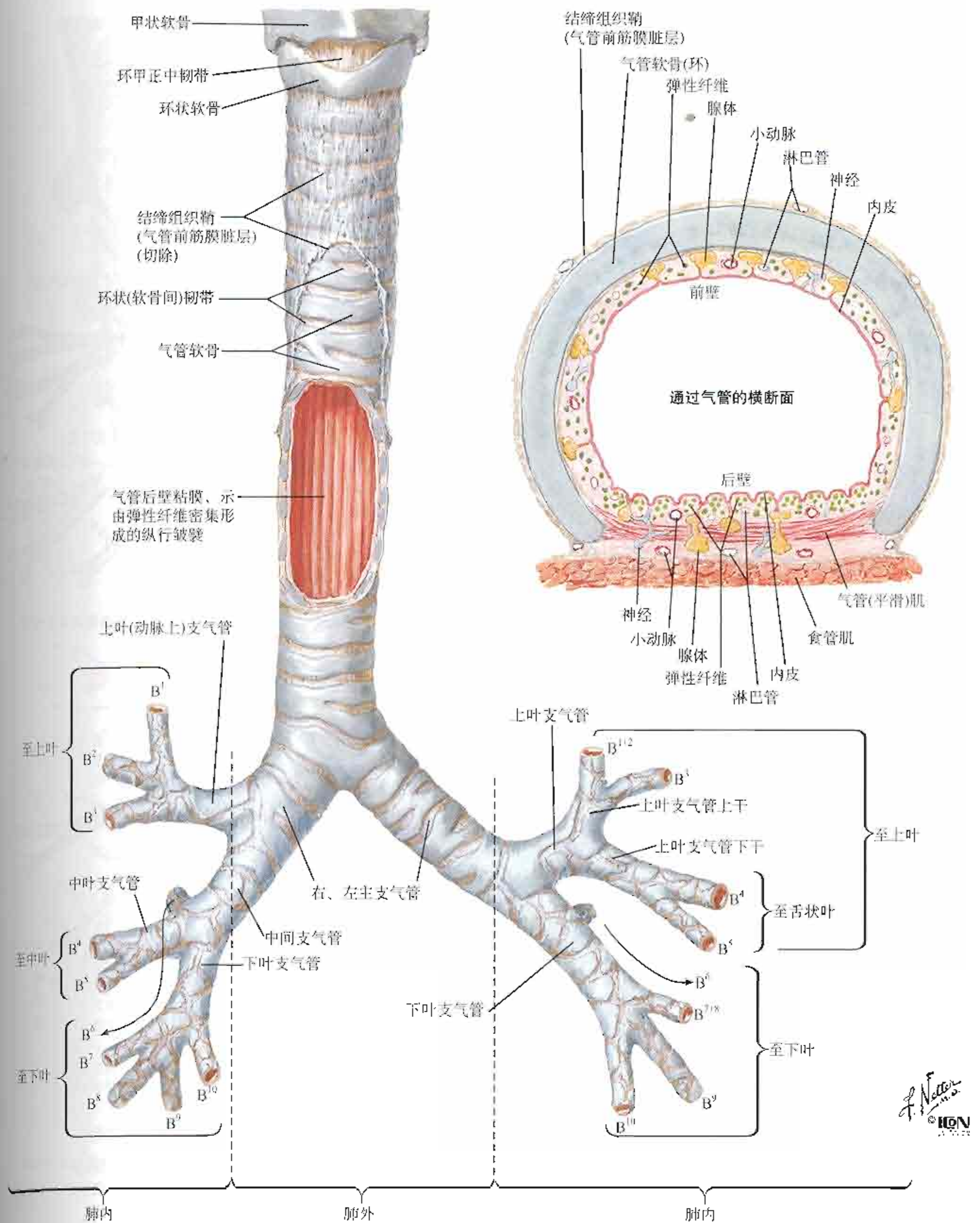
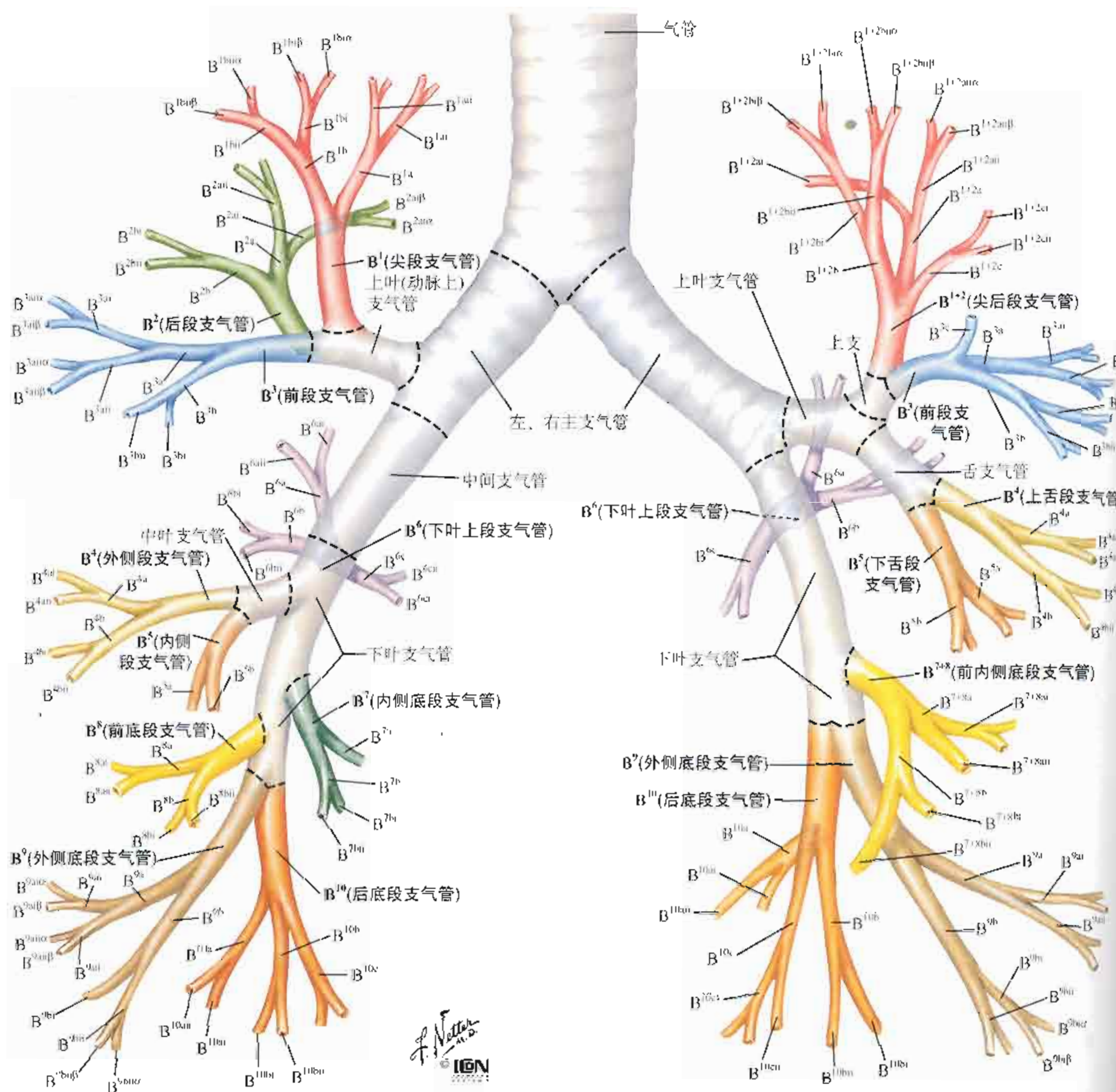


图198

支气管的命名：示意图



支气管肺段的常用名称(图196、197)是根据Jackson和Huber方法命名的,肺段支气管也按照其相应的肺段命名。Ikeda提议支气管的命名应到第5~6级分支(如此处显示)。为简化图示,此处仅对部分支气管标记到第5~6级分支。每侧肺的段支气管(B),按照相应的肺段从1排到10。

在左肺，B¹和B²，B⁷和B⁸结合在一起。段以下或第4级支气管。若存在额外分支时，用a、b或c表示。第5级支气管用罗马数字Ⅰ(横)或Ⅱ(后)表示，第6级用希腊字母α或β表示。一些版本使用其他数字替代段支气管

此处显示将支气管标准模式的变异，是在外周气体通路中特别常见的变异

图 199

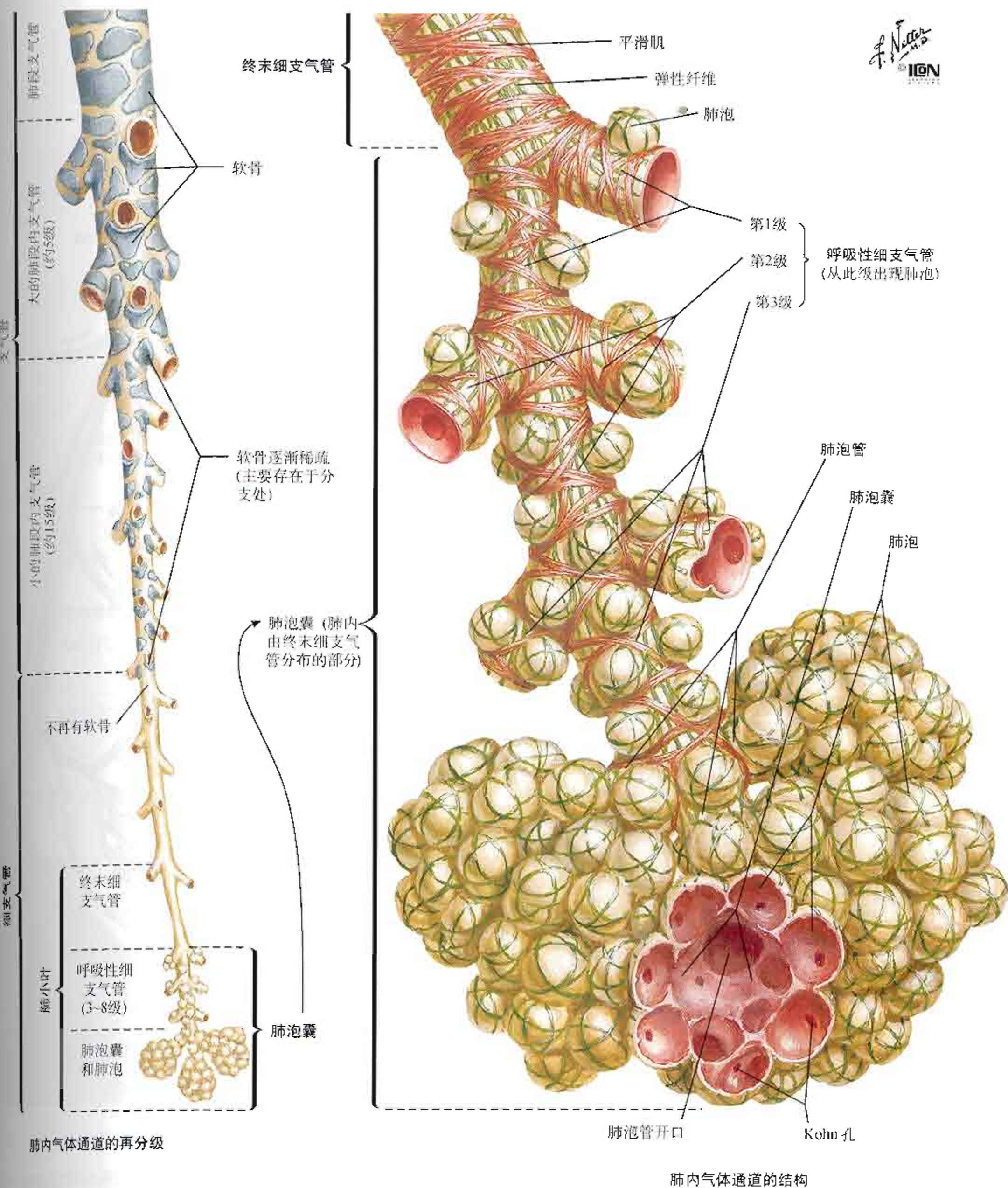
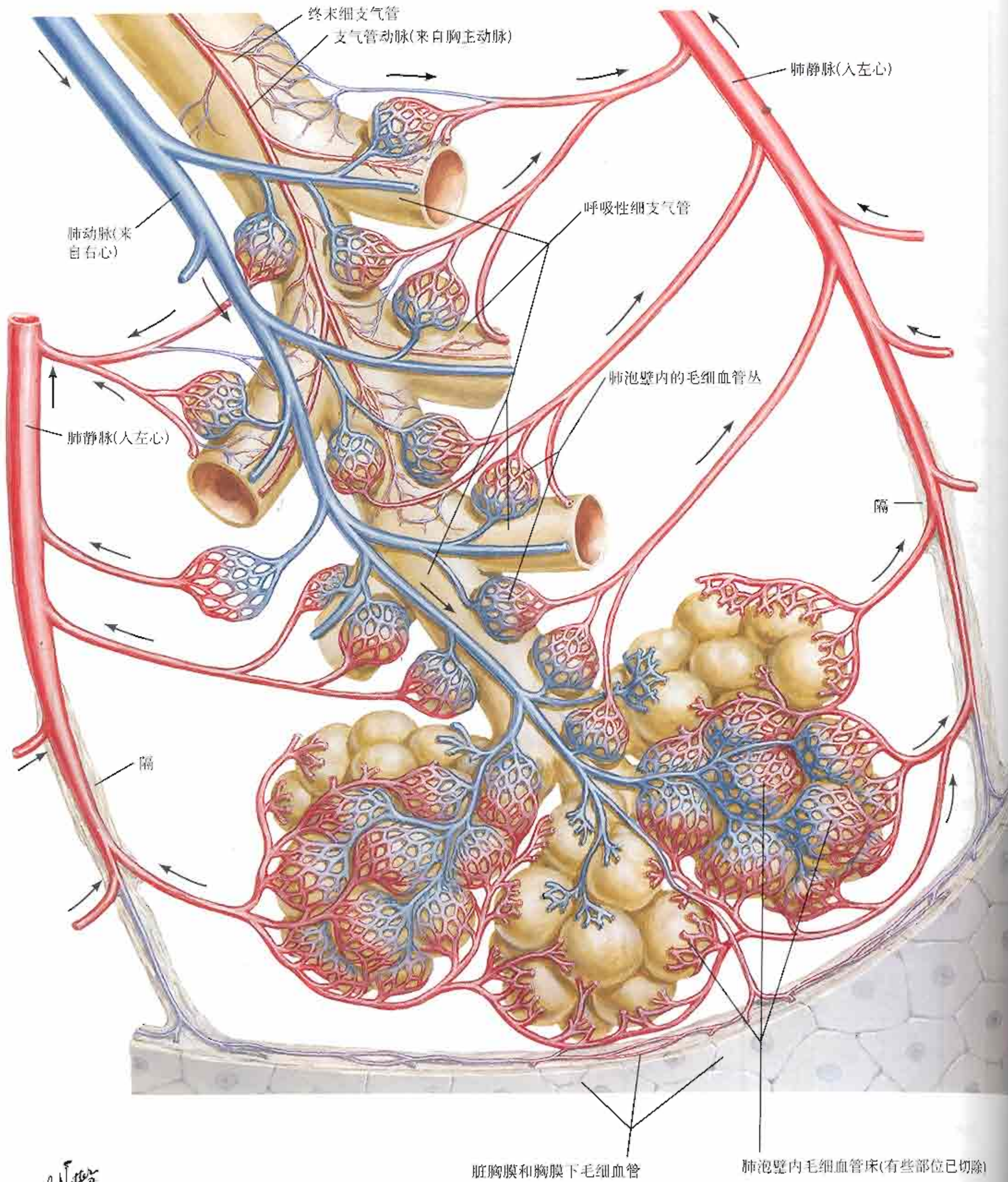
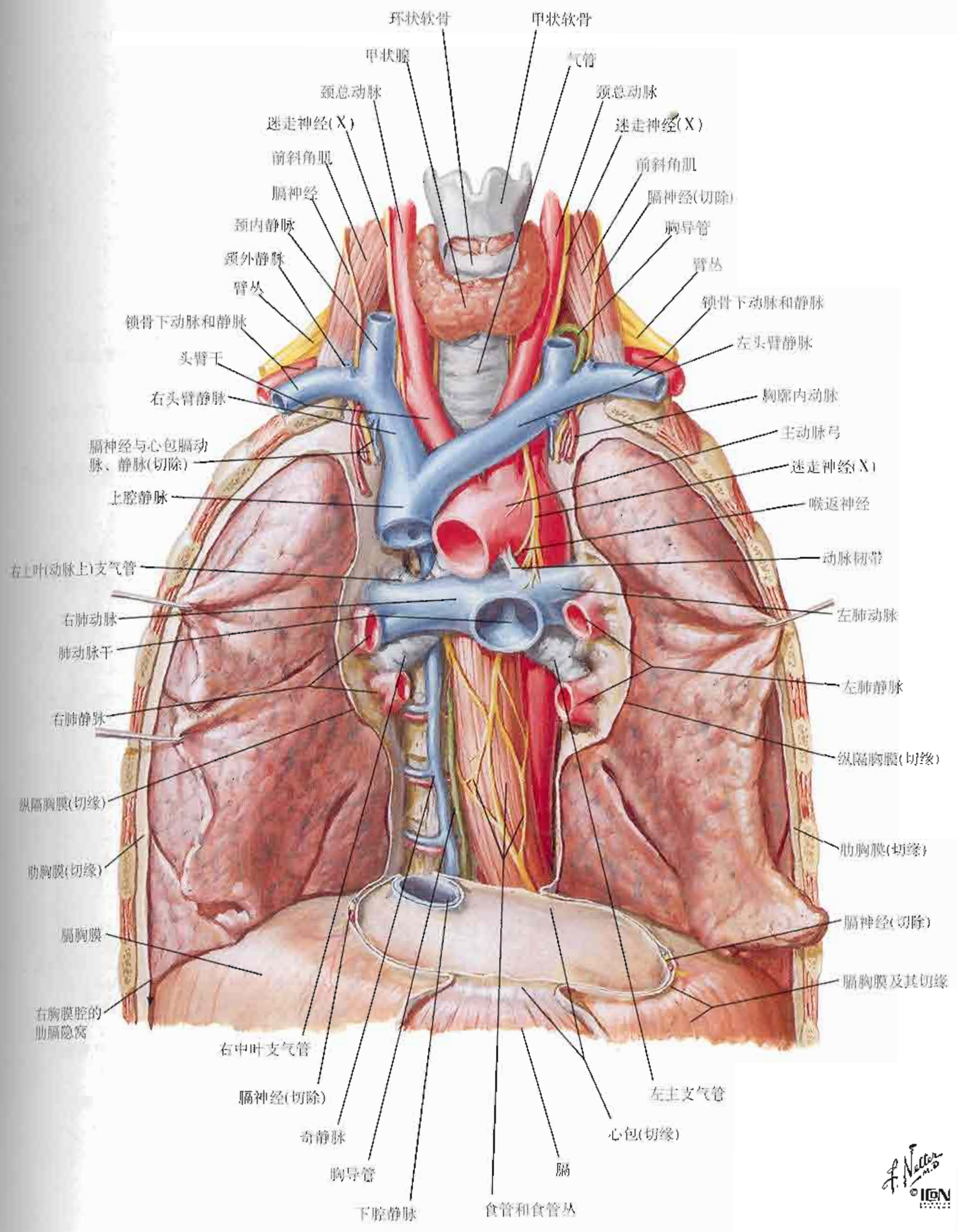


图200



F. Netter M.D.
© 1996

图201



F. Netter M.D.
© ION

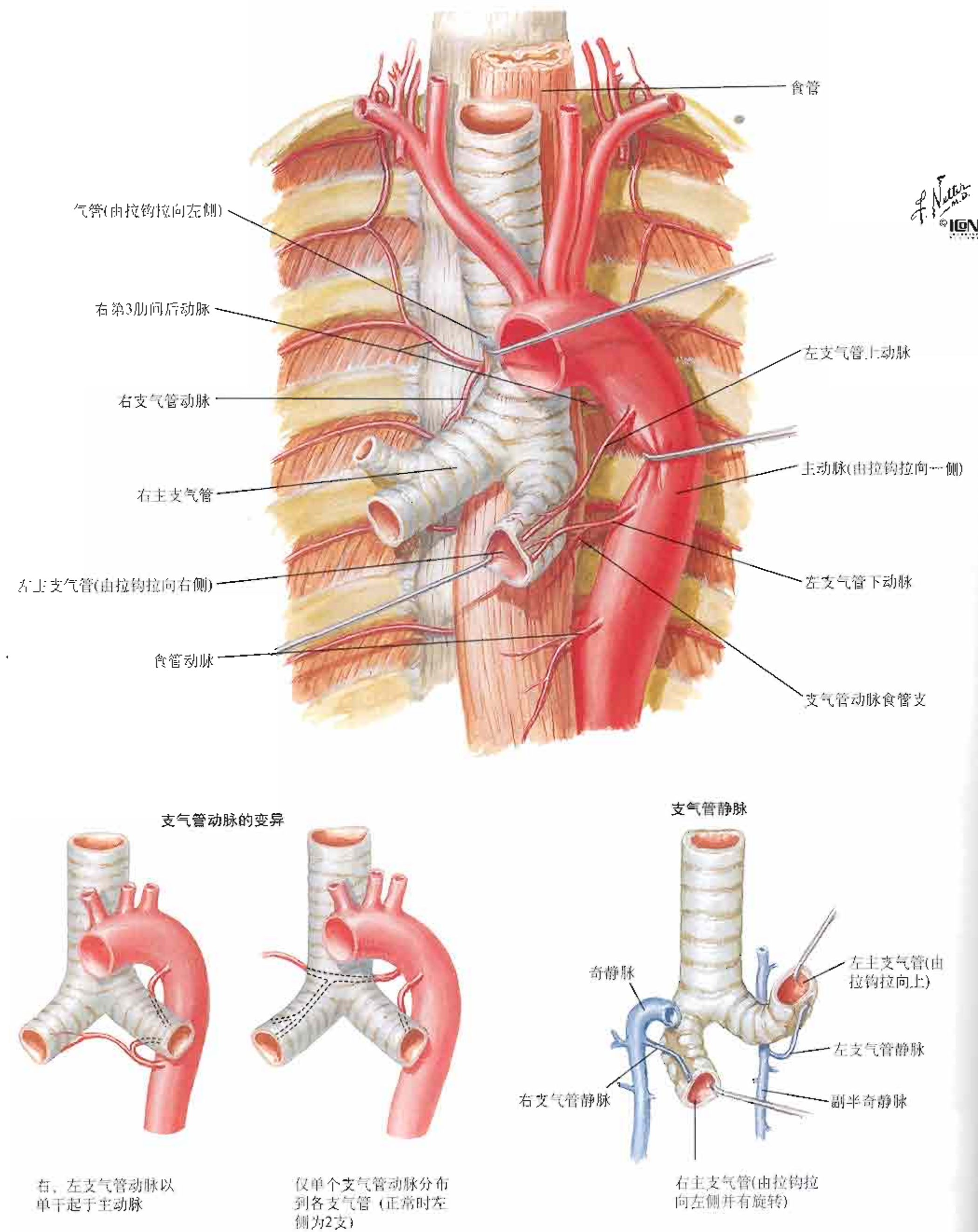
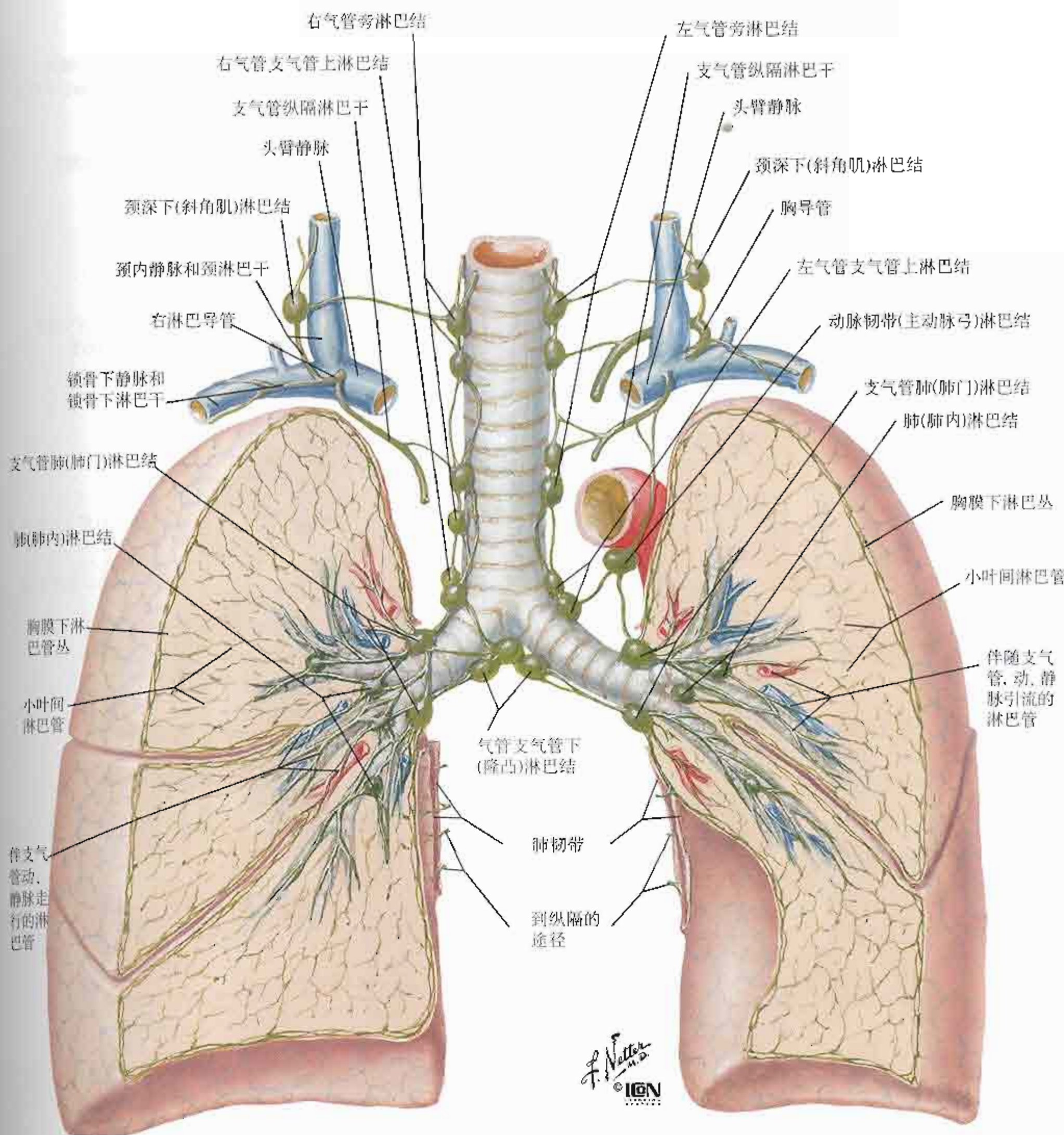


图203

参见图 68、177、235



淋巴引流途径

右肺：各叶的淋巴注入肺和支气管肺(门)淋巴结，然后汇入气管支气管下(隆凸)淋巴结。右气管支气管上淋巴结和右气管旁淋巴结，经支气管纵隔干和(或)颈深下(斜角肌)淋巴结注入头臂静脉

左肺：上叶引流到肺和支气管肺(肺门)淋巴结，气管支气管下(隆凸)淋巴结，左气管支气管上淋巴结、左气管旁淋巴结和(或)动脉韧带(主动脉弓)淋巴结，然后通过左支气管纵隔干和胸导管汇入左头臂静脉。下叶也引流到肺和支气管肺(肺门)淋巴结和气管支气管下(隆凸)淋巴结，然后大部分到右气管支气管上淋巴结，此后沿着与右肺相同的淋巴途径引流

参见图 124、125、159、308

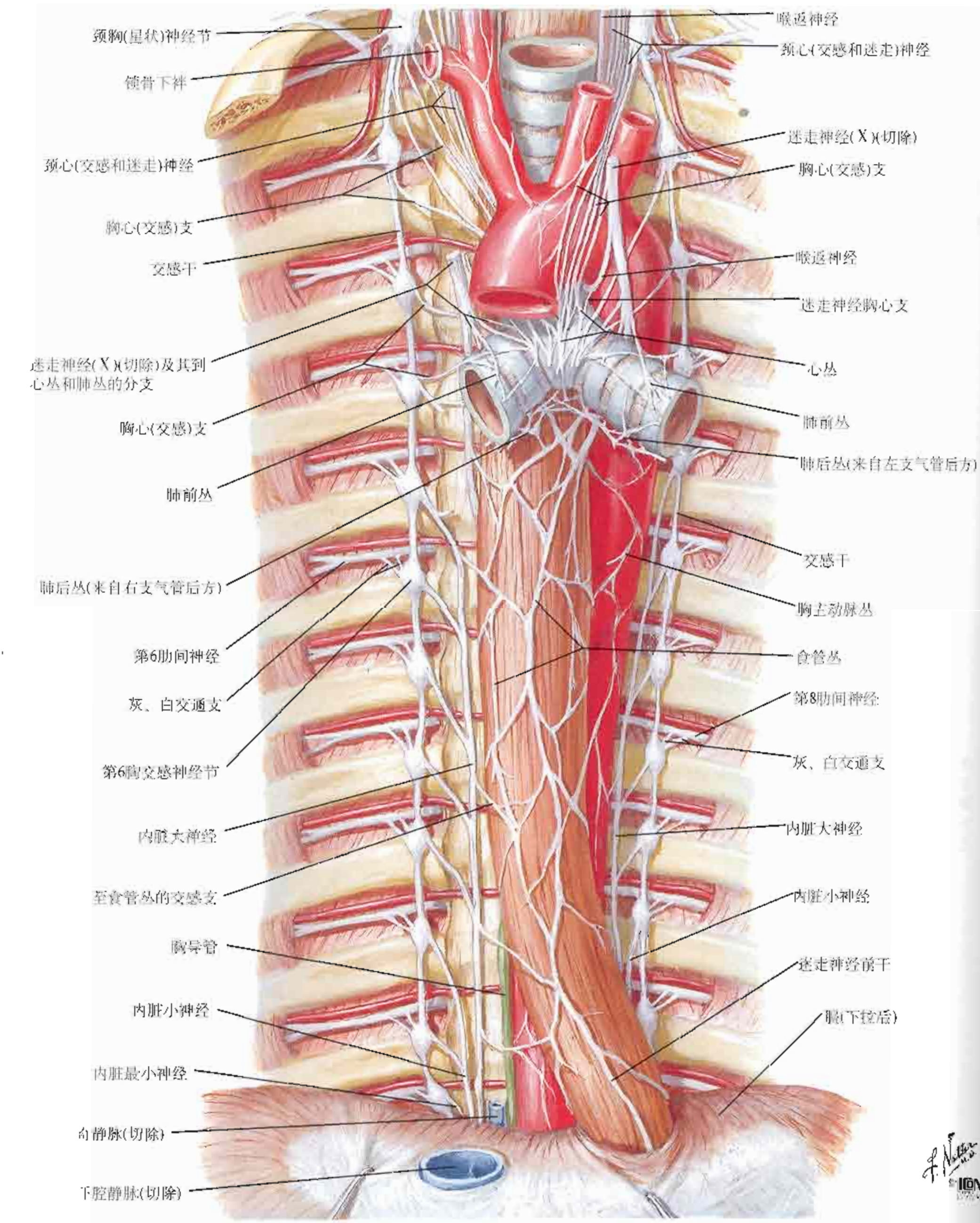


图205

参见图 160

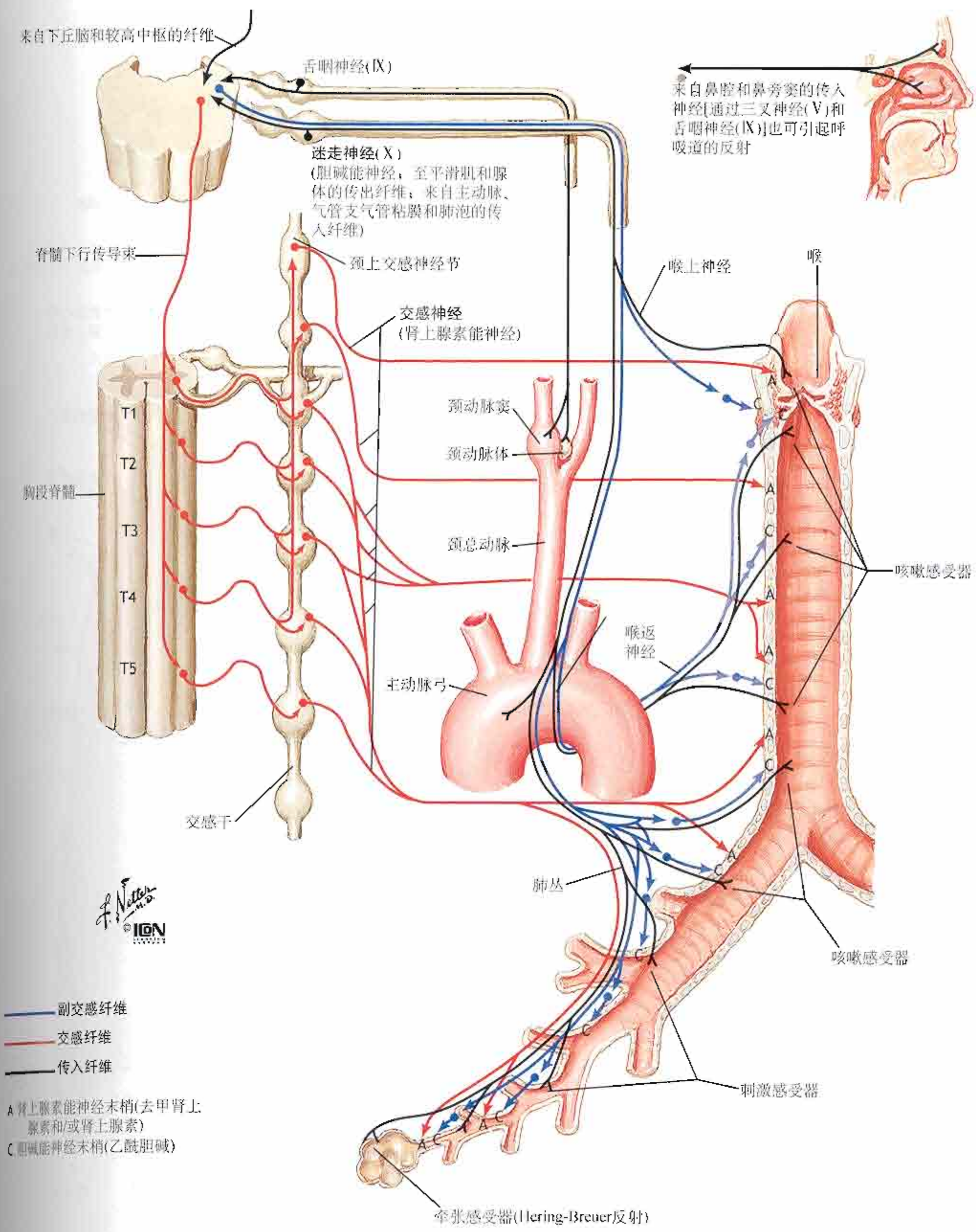
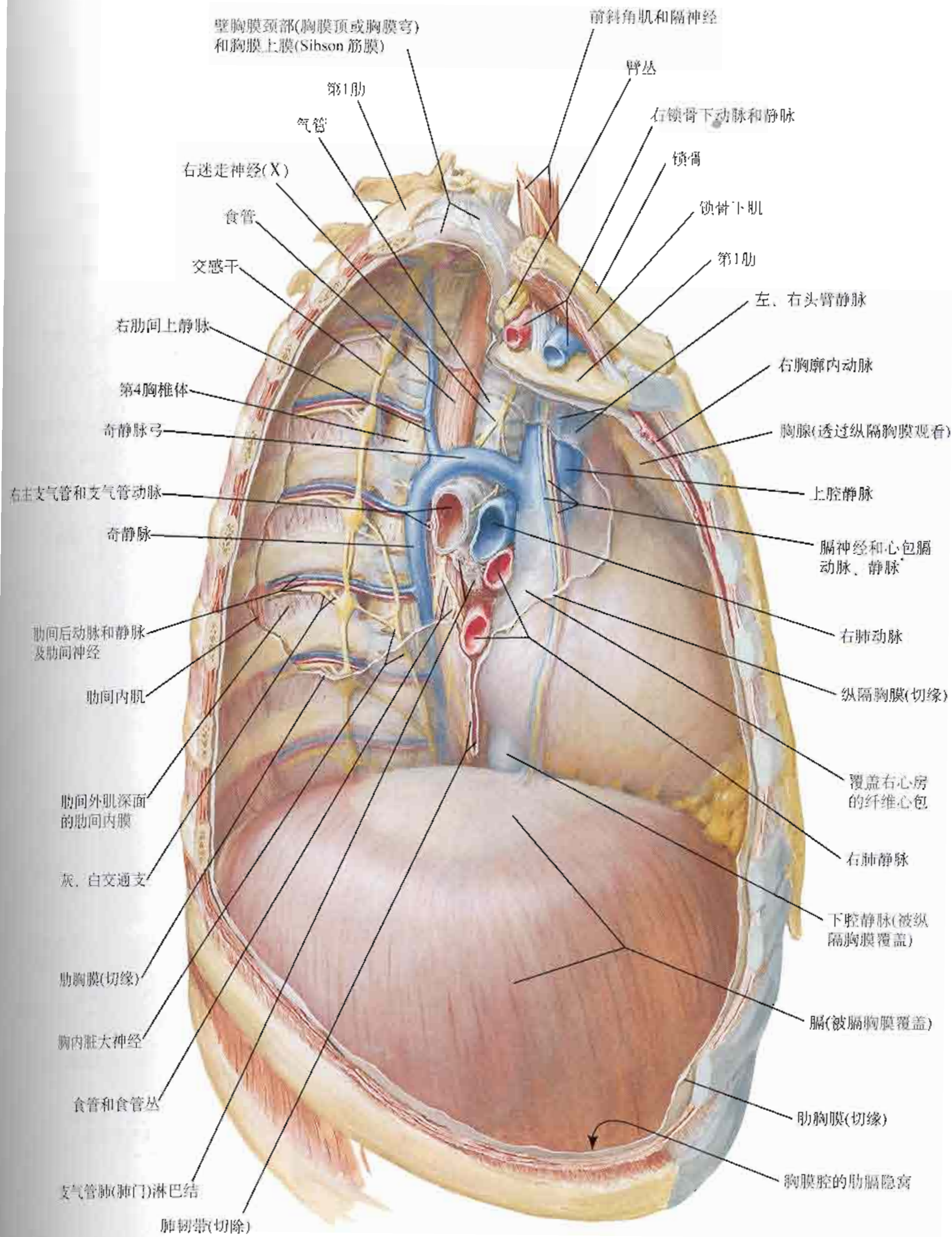


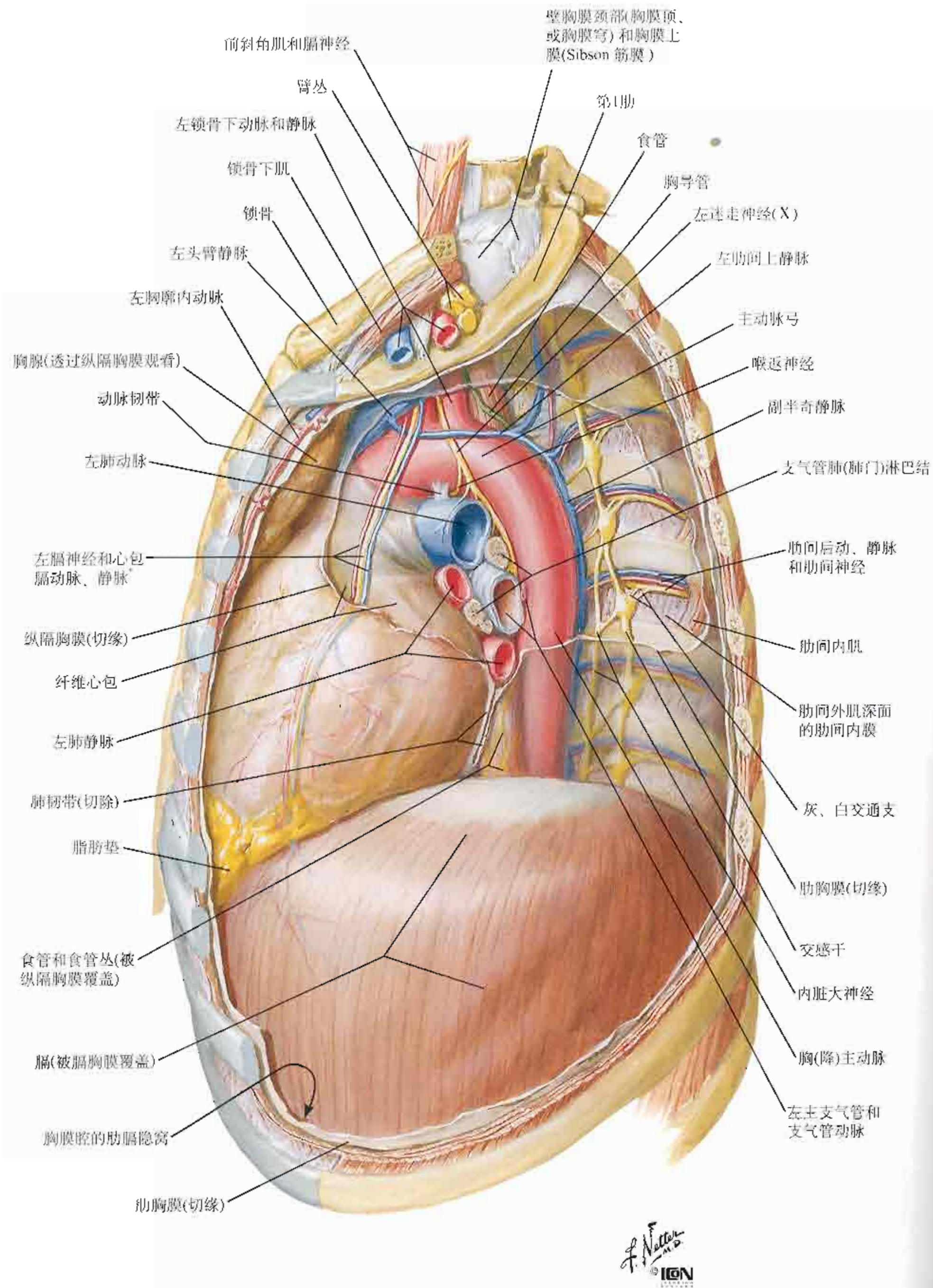
图206

肺



F. Netter M.D.
© IGV

*神经和血管通常独立走行



神经和血管通常独立走行

F. Netter M.D.
© IGV

图227

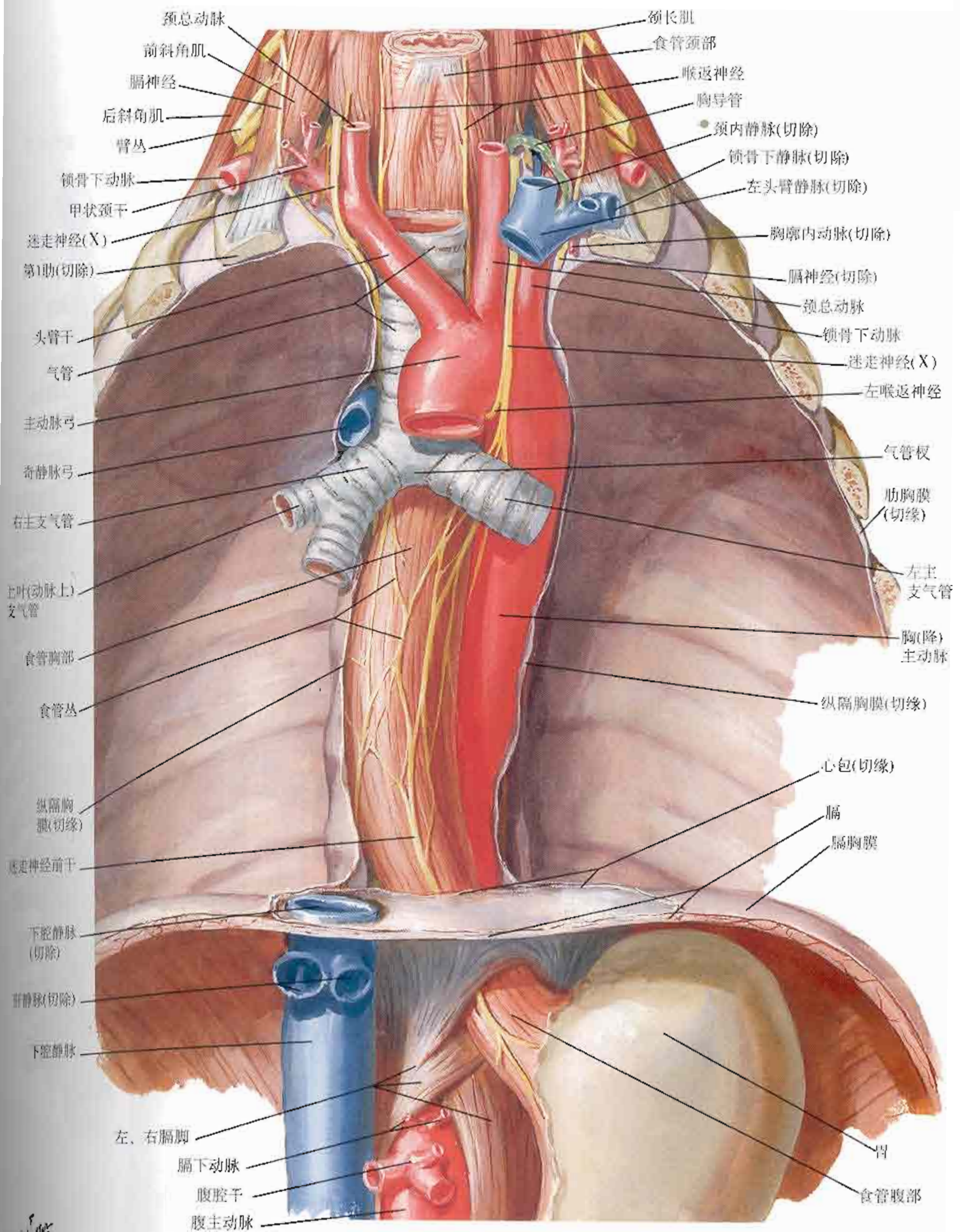


图228

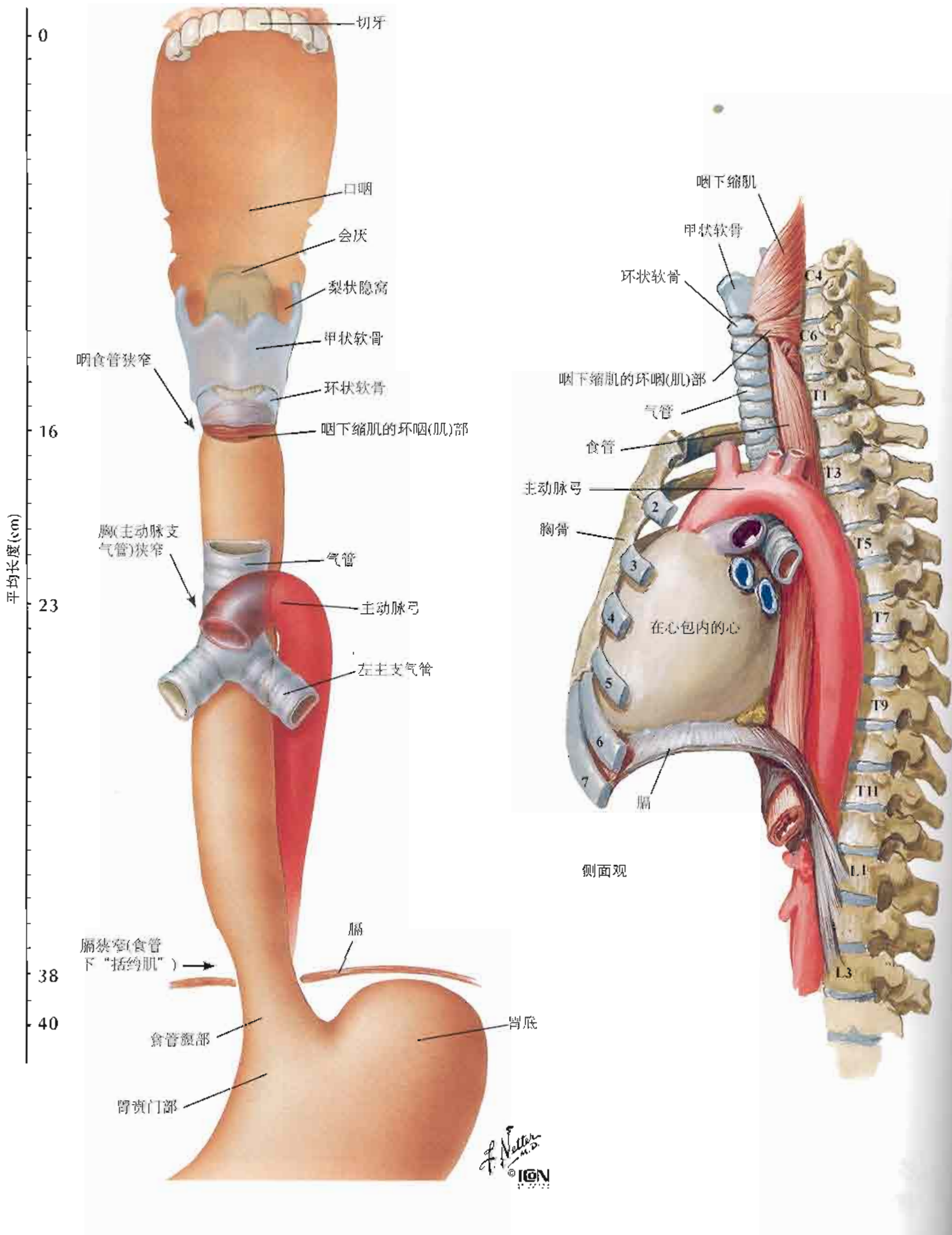


图229



运动科学网站



运动科学网站



运动科学网站



运动科学网站



运动科学网站



运动科学网站



运动科学网站



运动科学网站



运动科学网站



运动科学网站



运动科学网站



运动科学网站



运动科学网站



运动科学网站

参见图 63

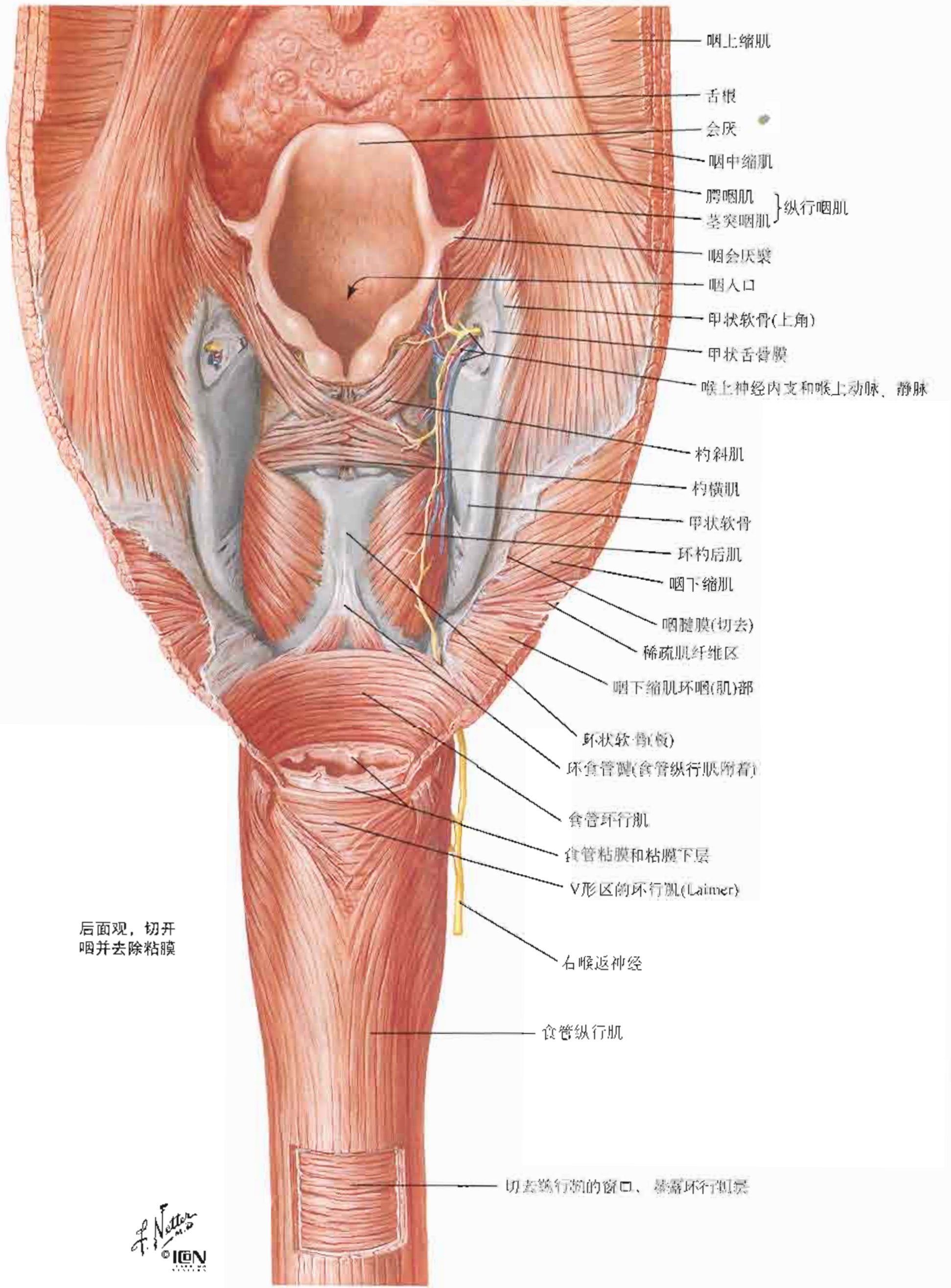
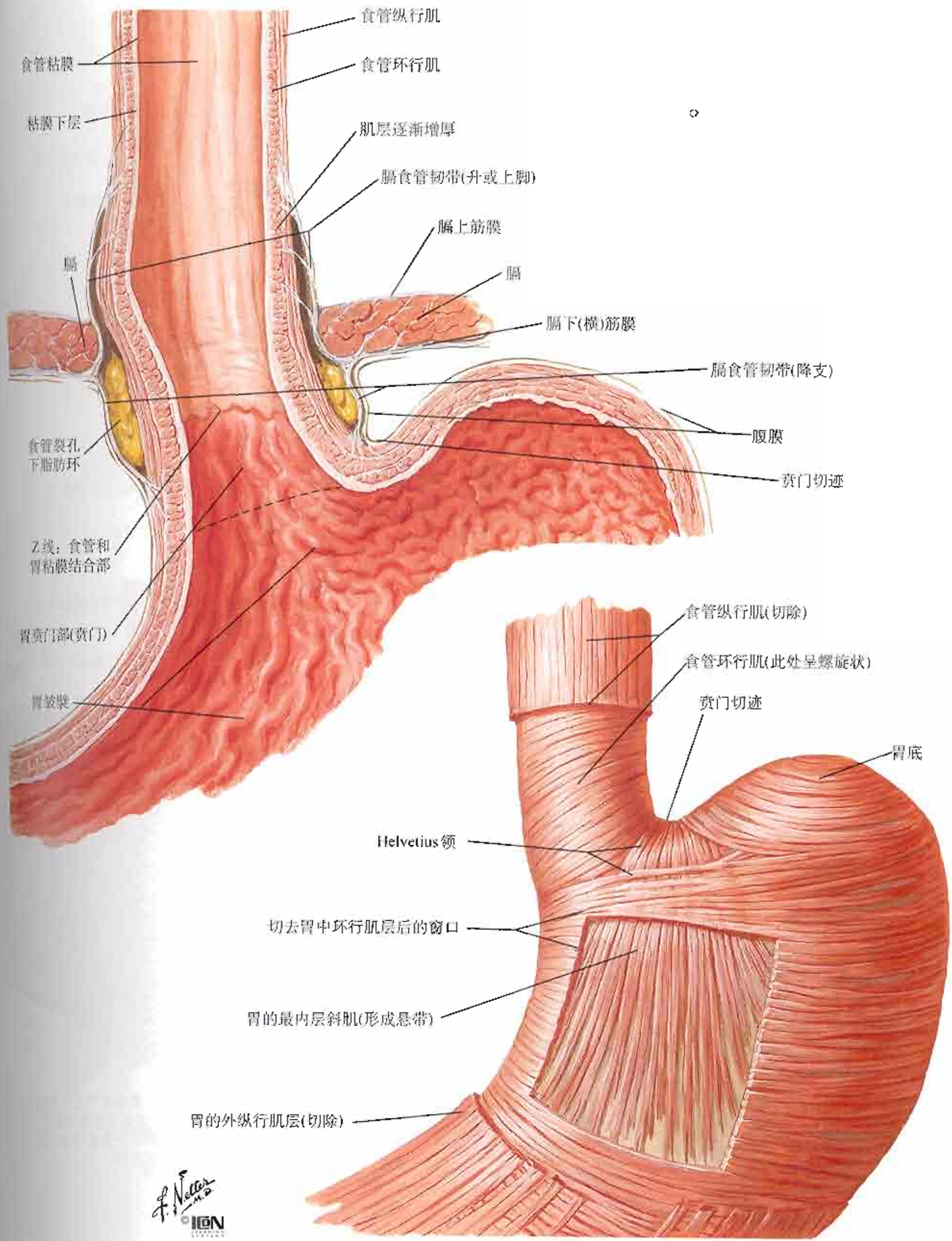


图231



F. Netter M.D.
© IGM

食管的动脉

参见图 290、291

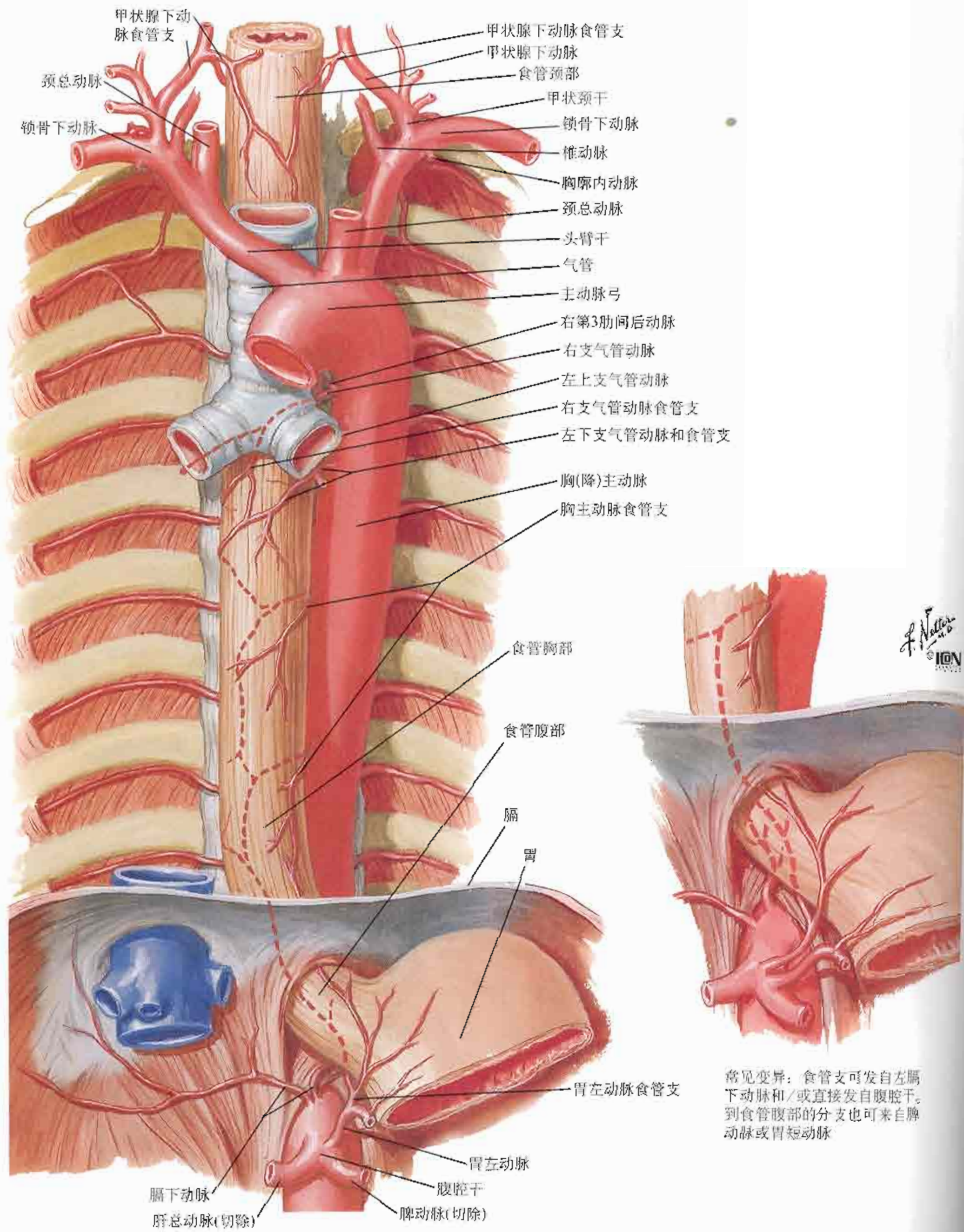
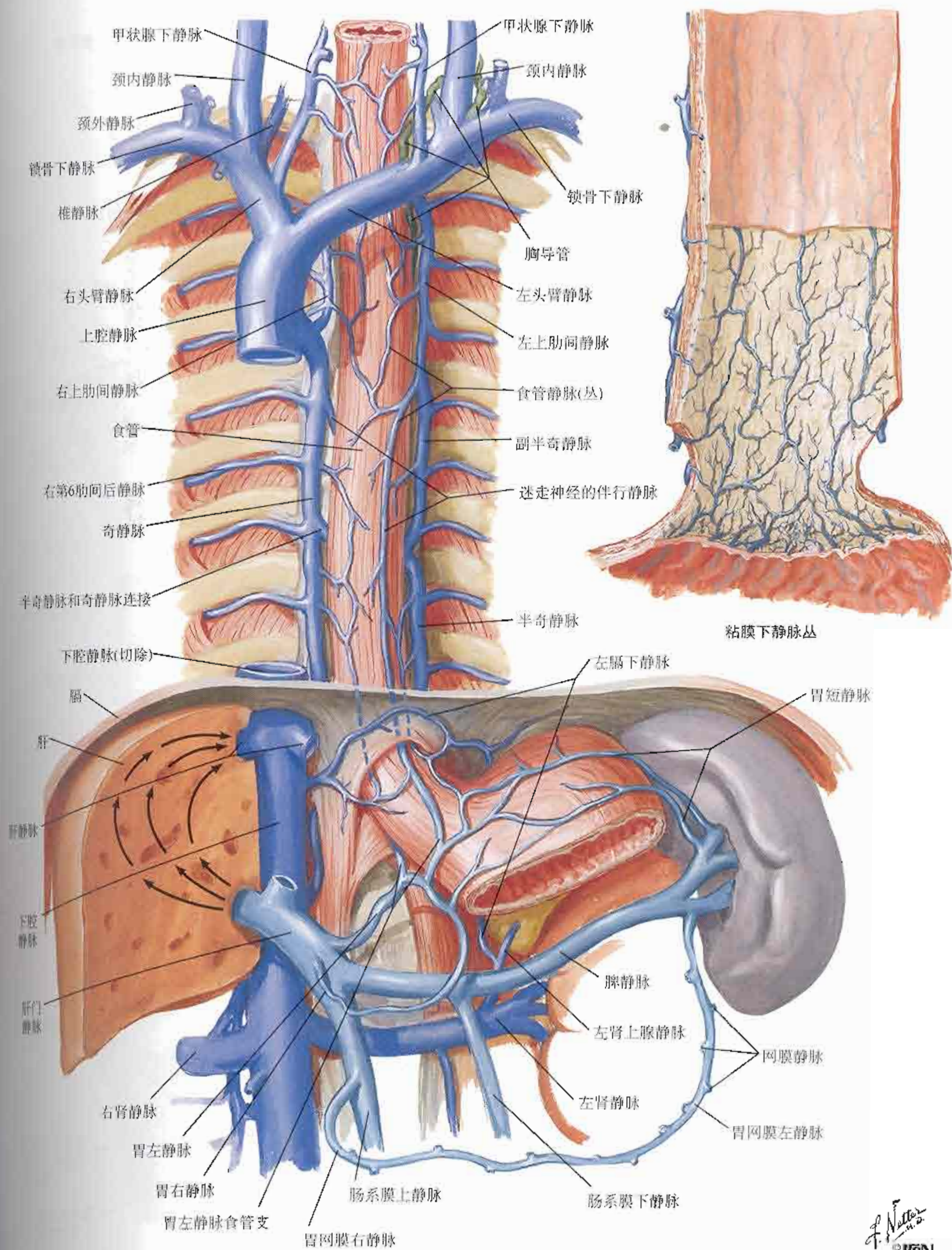


图233



F. Netter M.D. © IGCN

参见图 204、258

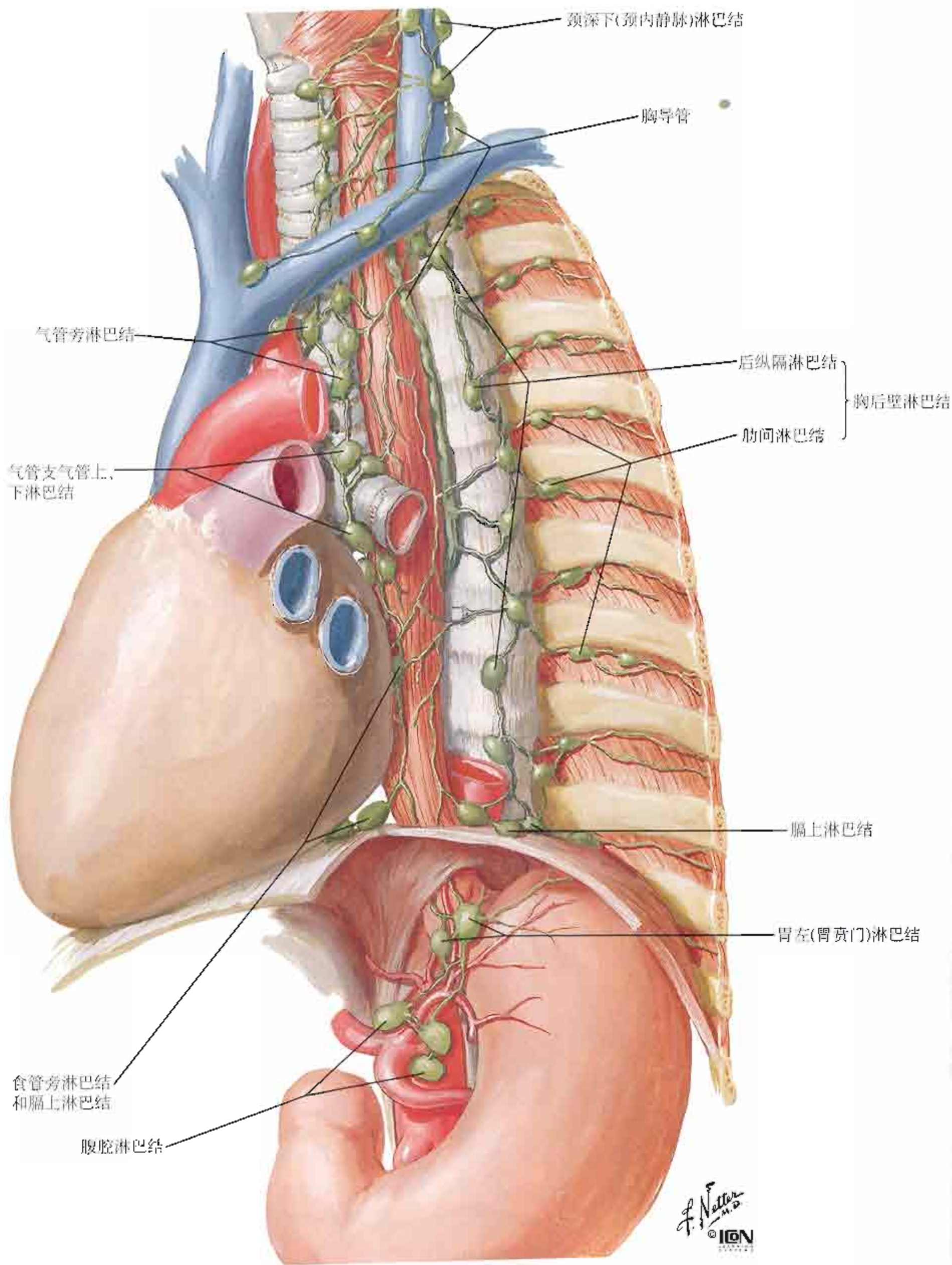
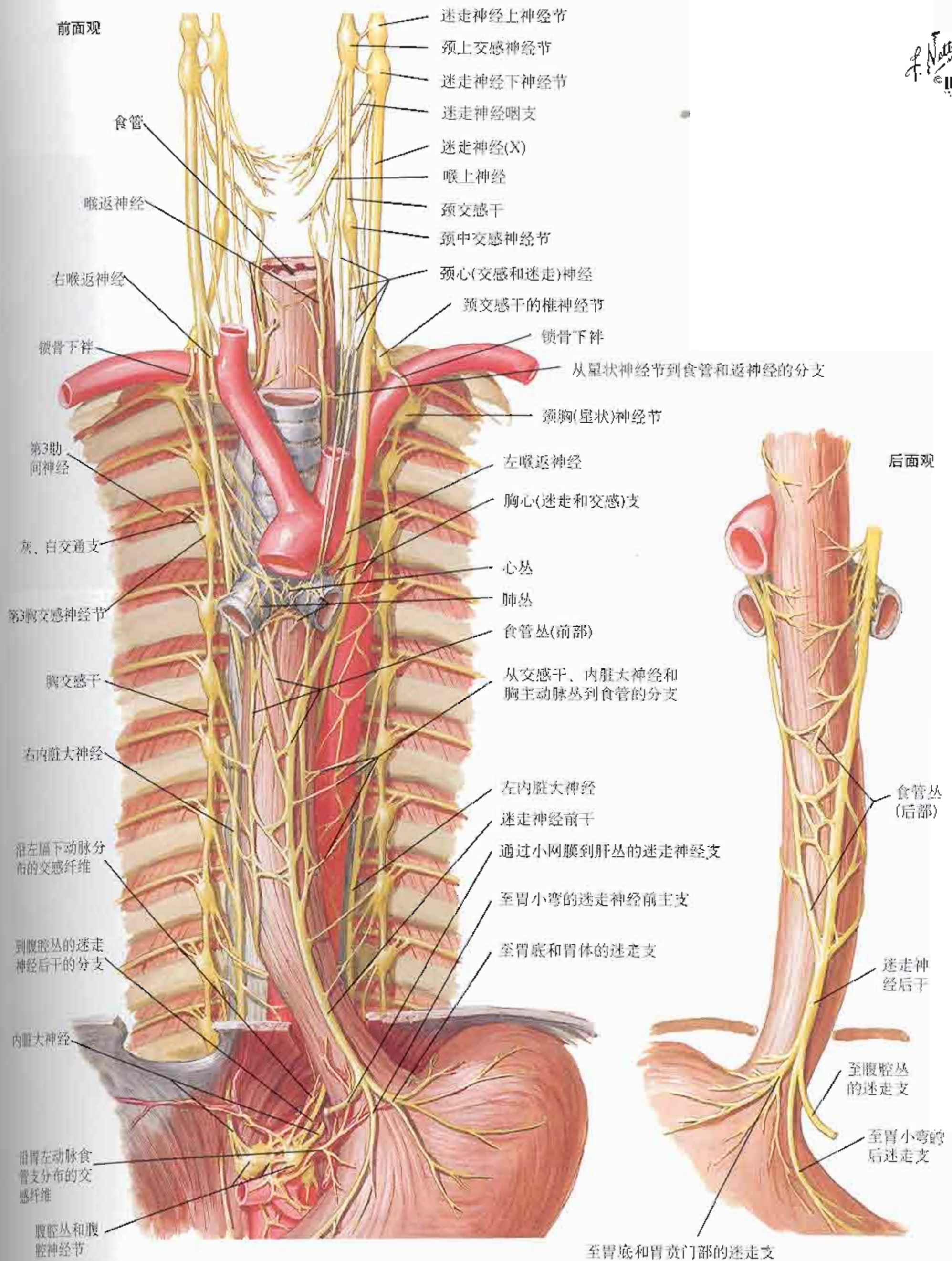


图235



纵隔：横断面

参见图 533

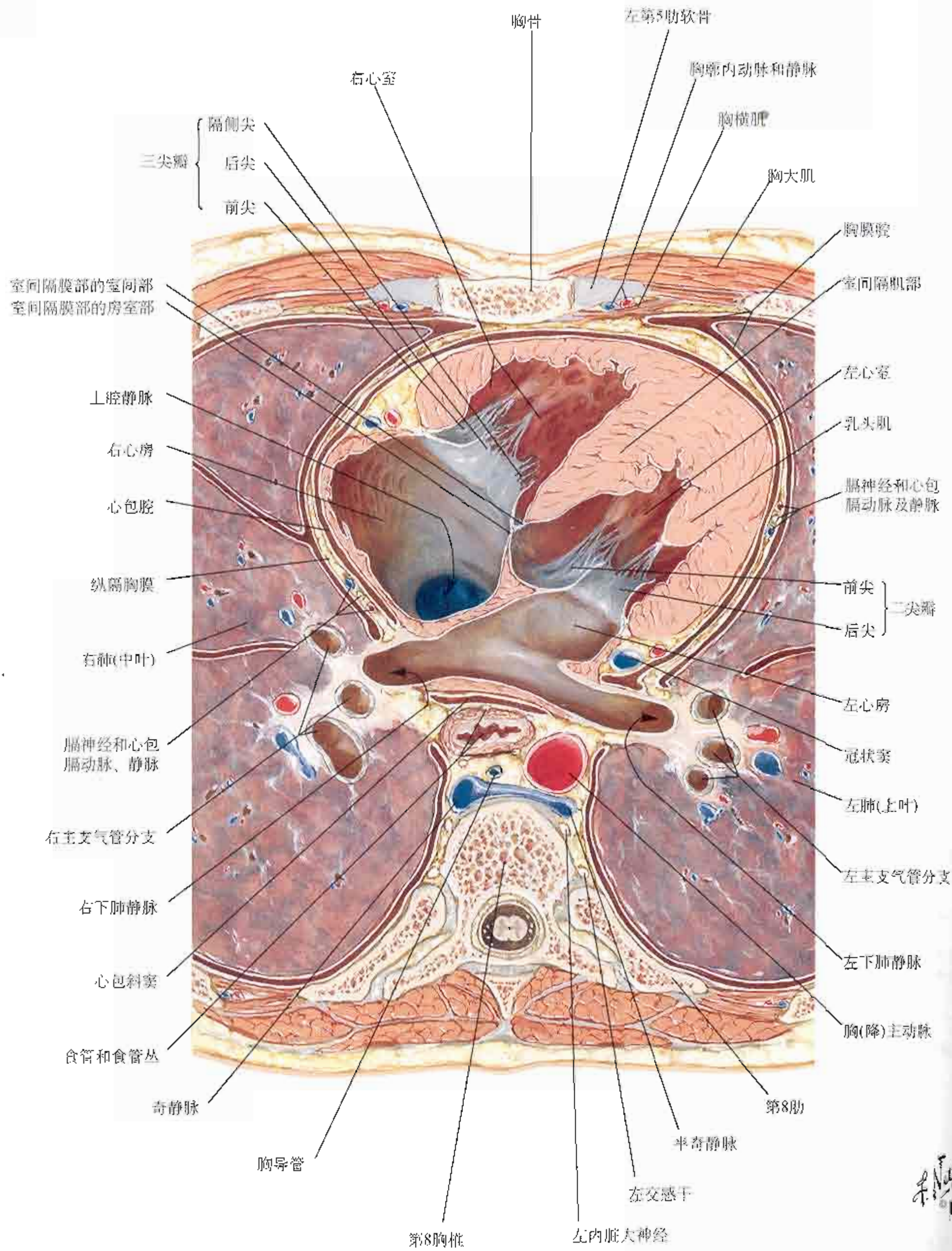
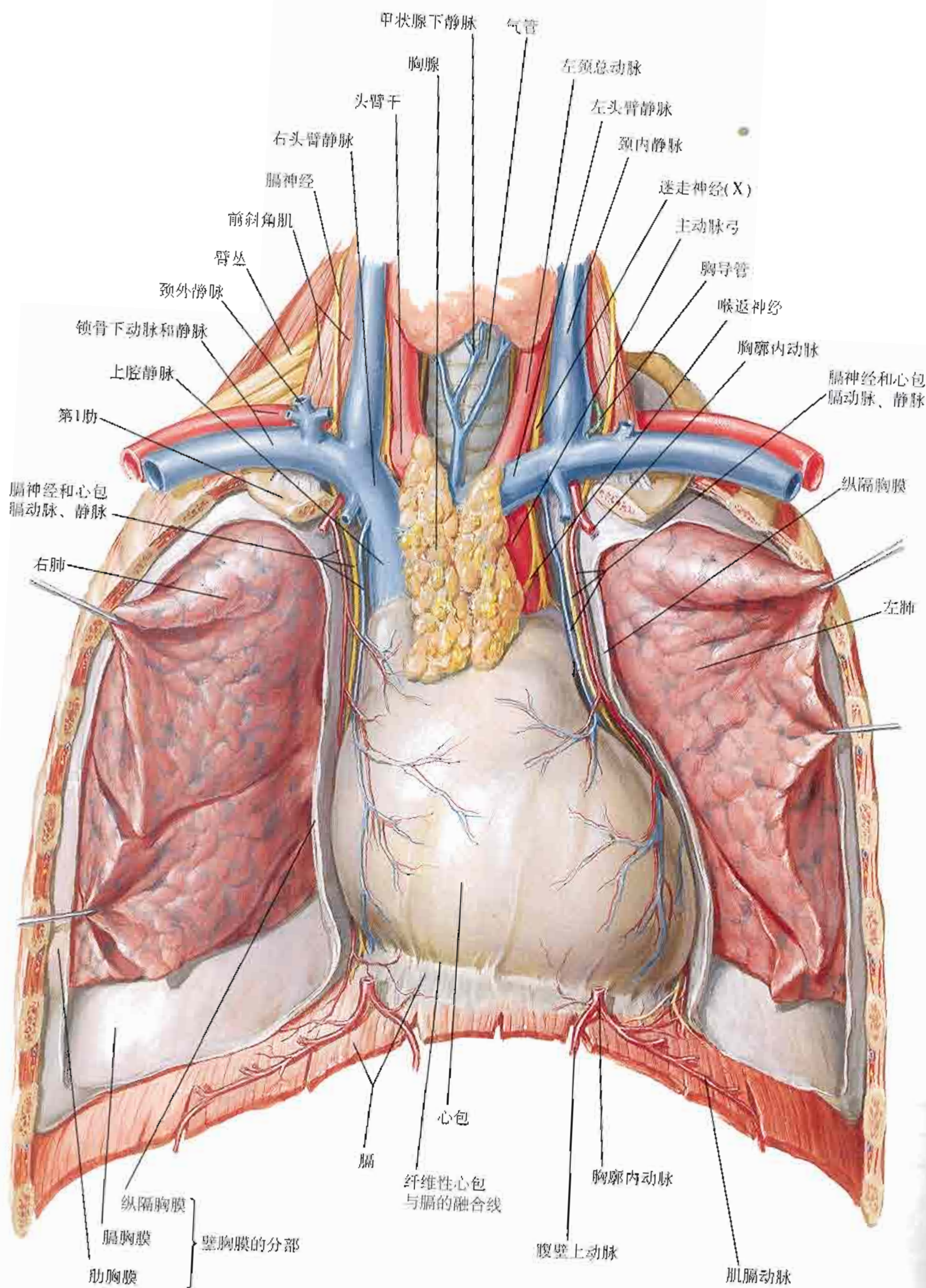


图237



F. Netter M.D.
© IEN

图207

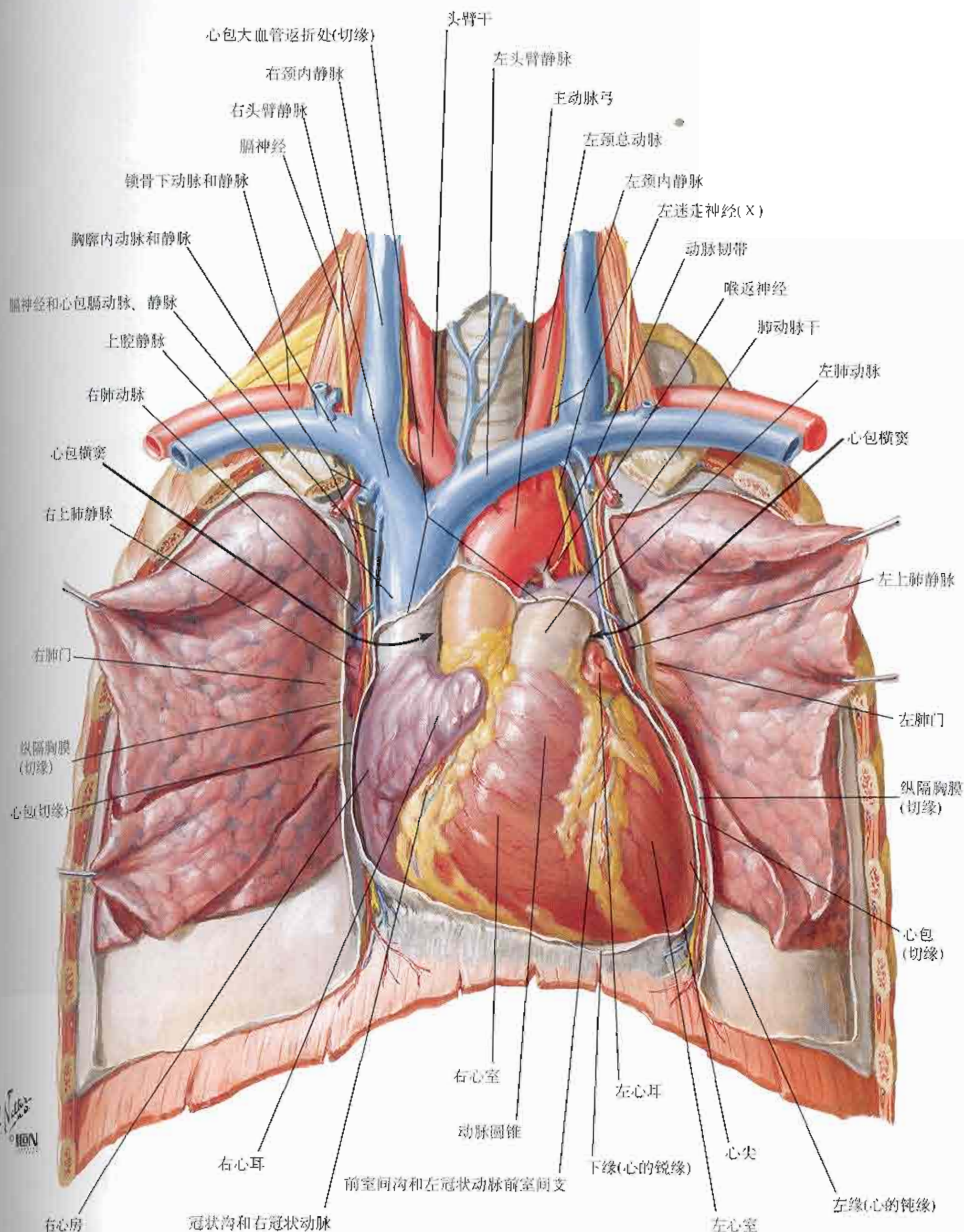
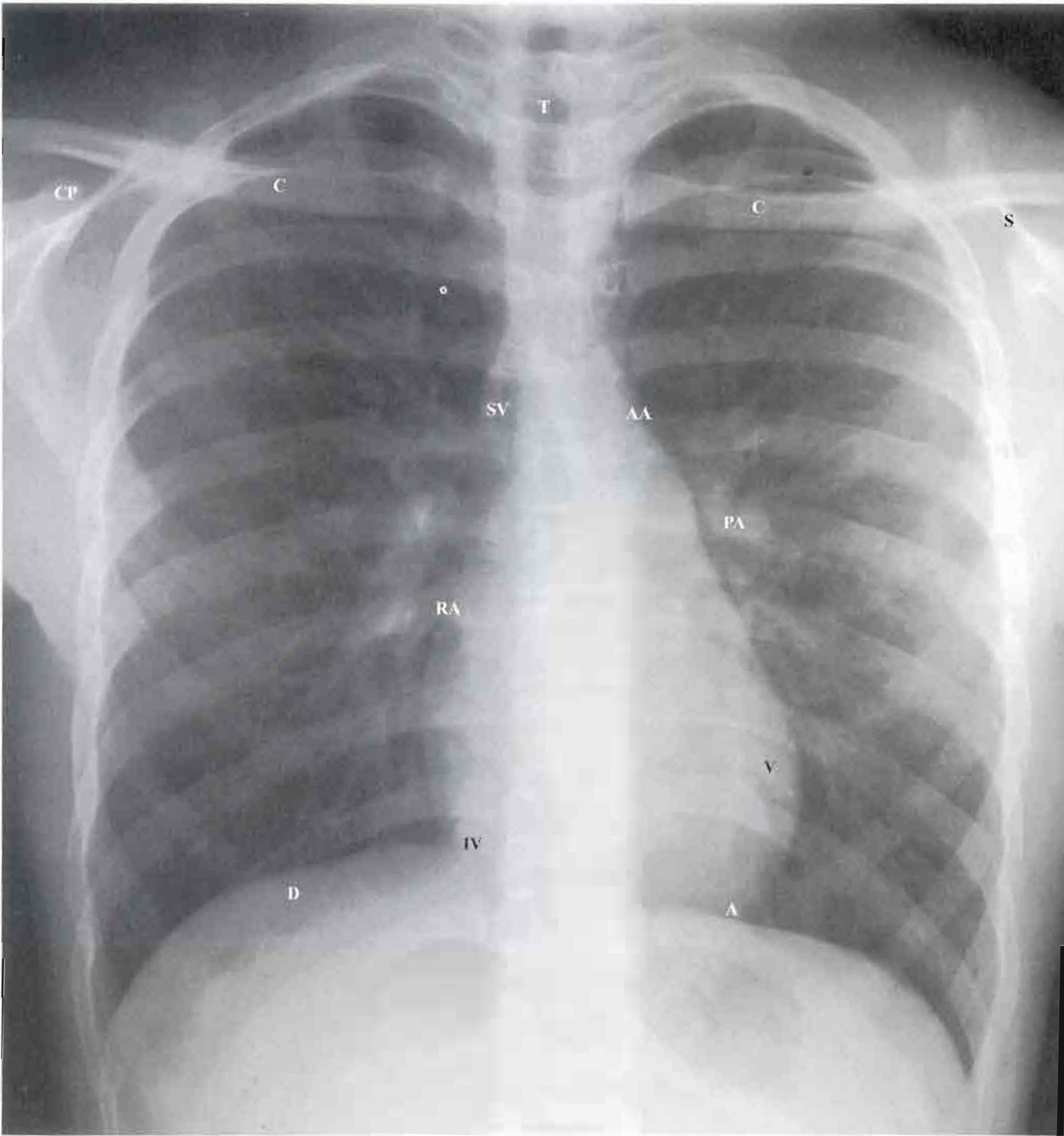
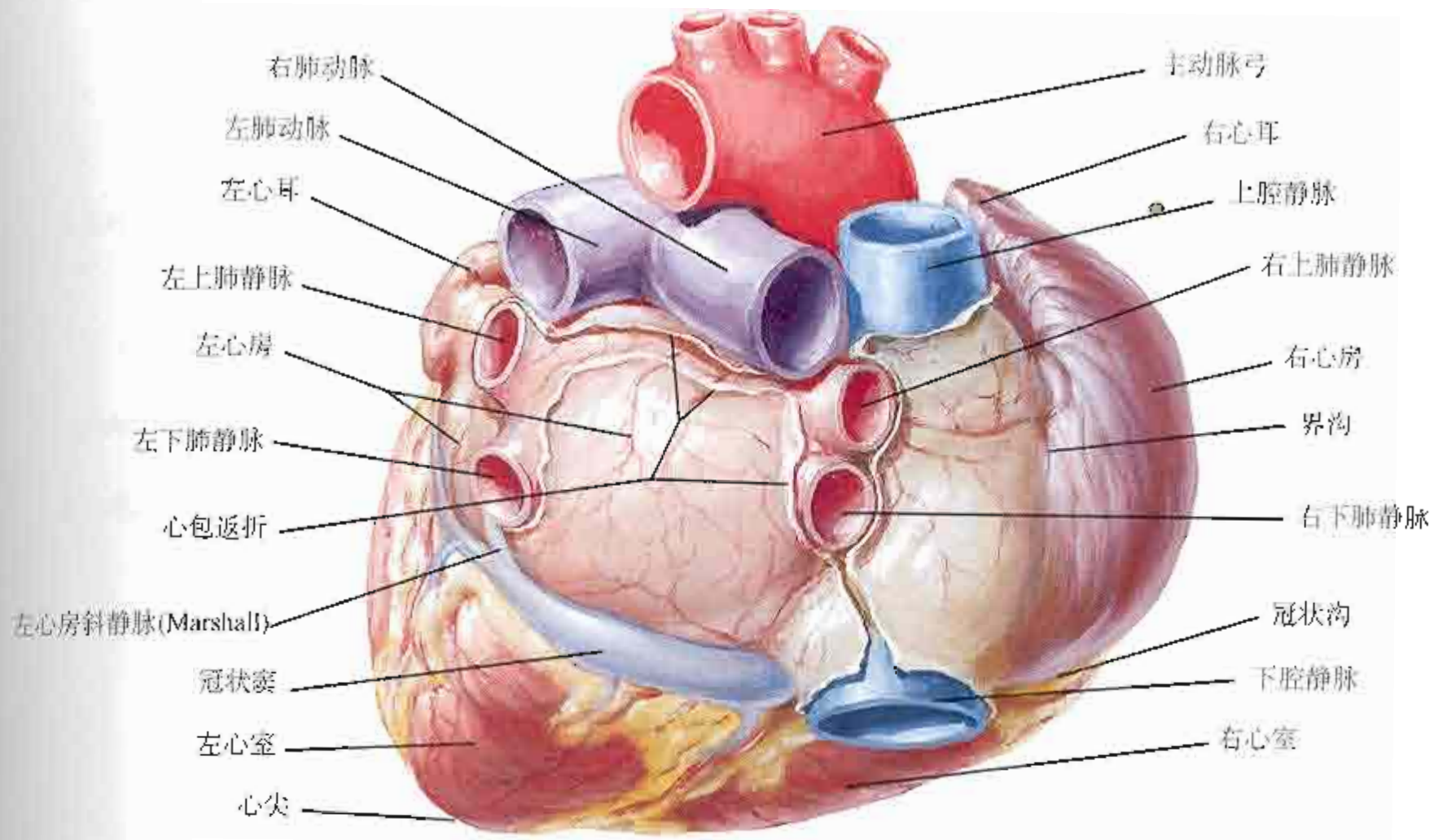


图208

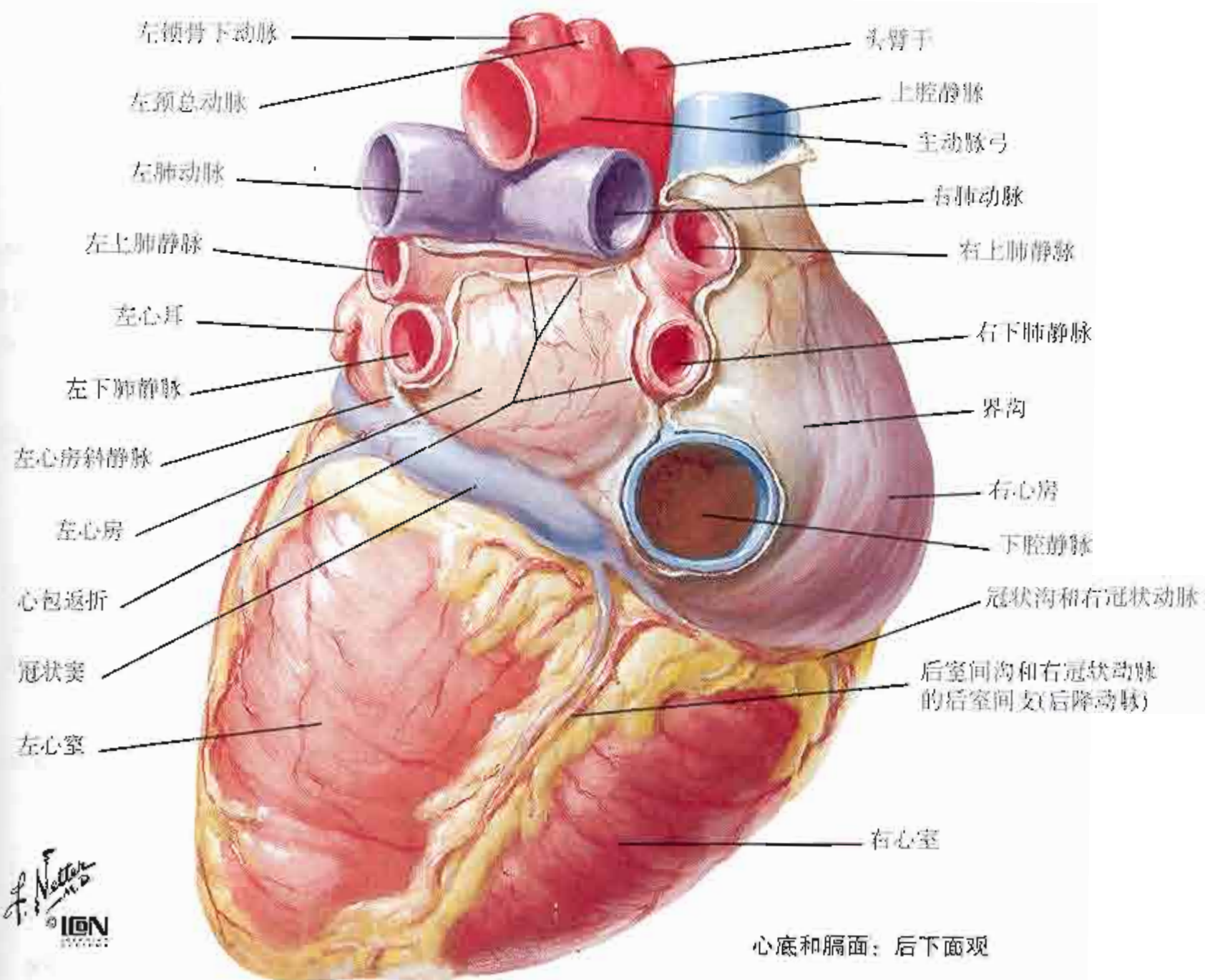


- A 心尖
- AA 主动脉弓
- C 锁骨
- CP 肩胛骨喙突
- D 膈穹隆(右)
- IV 下腔静脉
- PA 肺动脉(左)
- RA 右心房
- S 肩胛冈
- SV 上腔静脉
- T 气管
- V 左心室

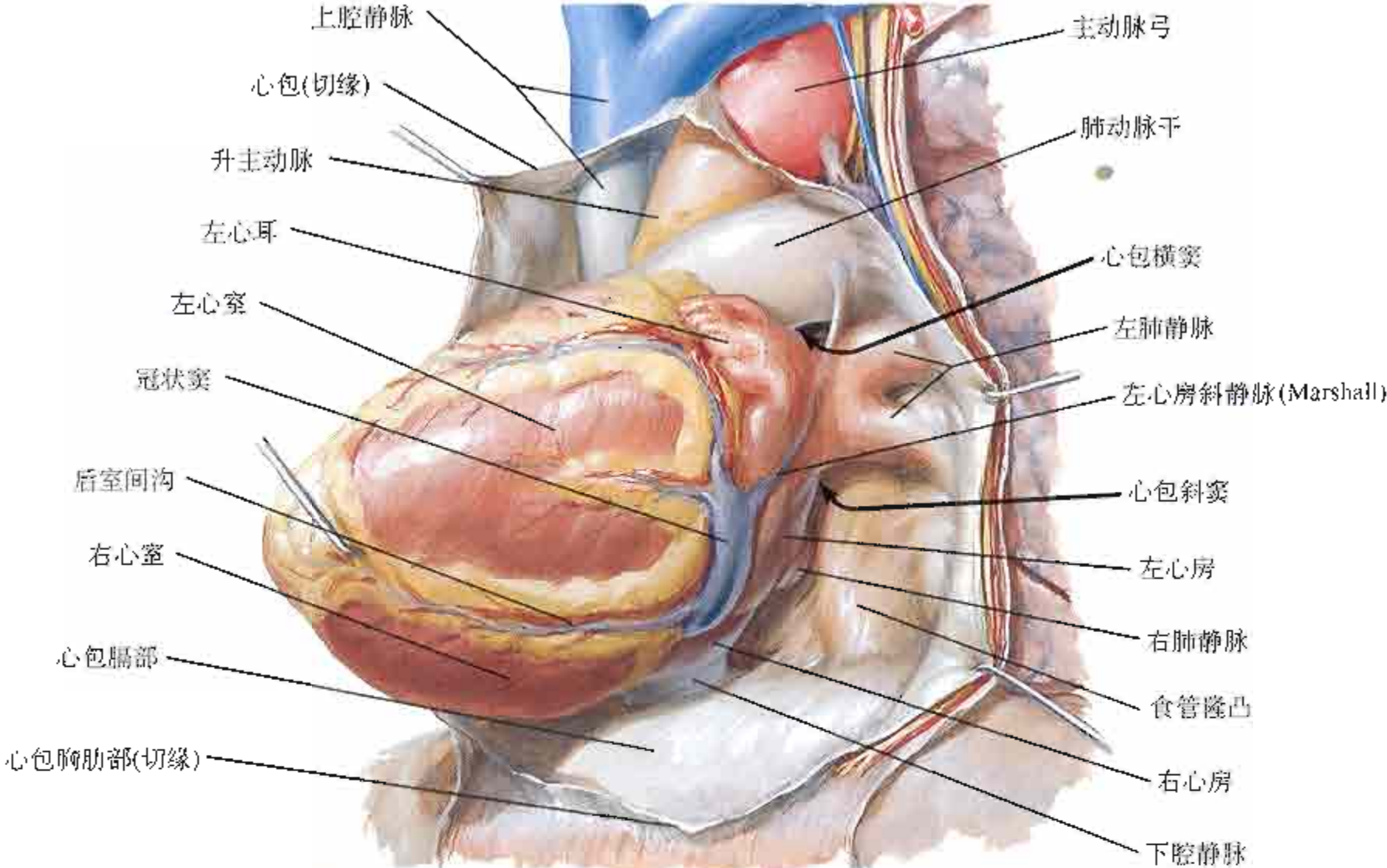
图209



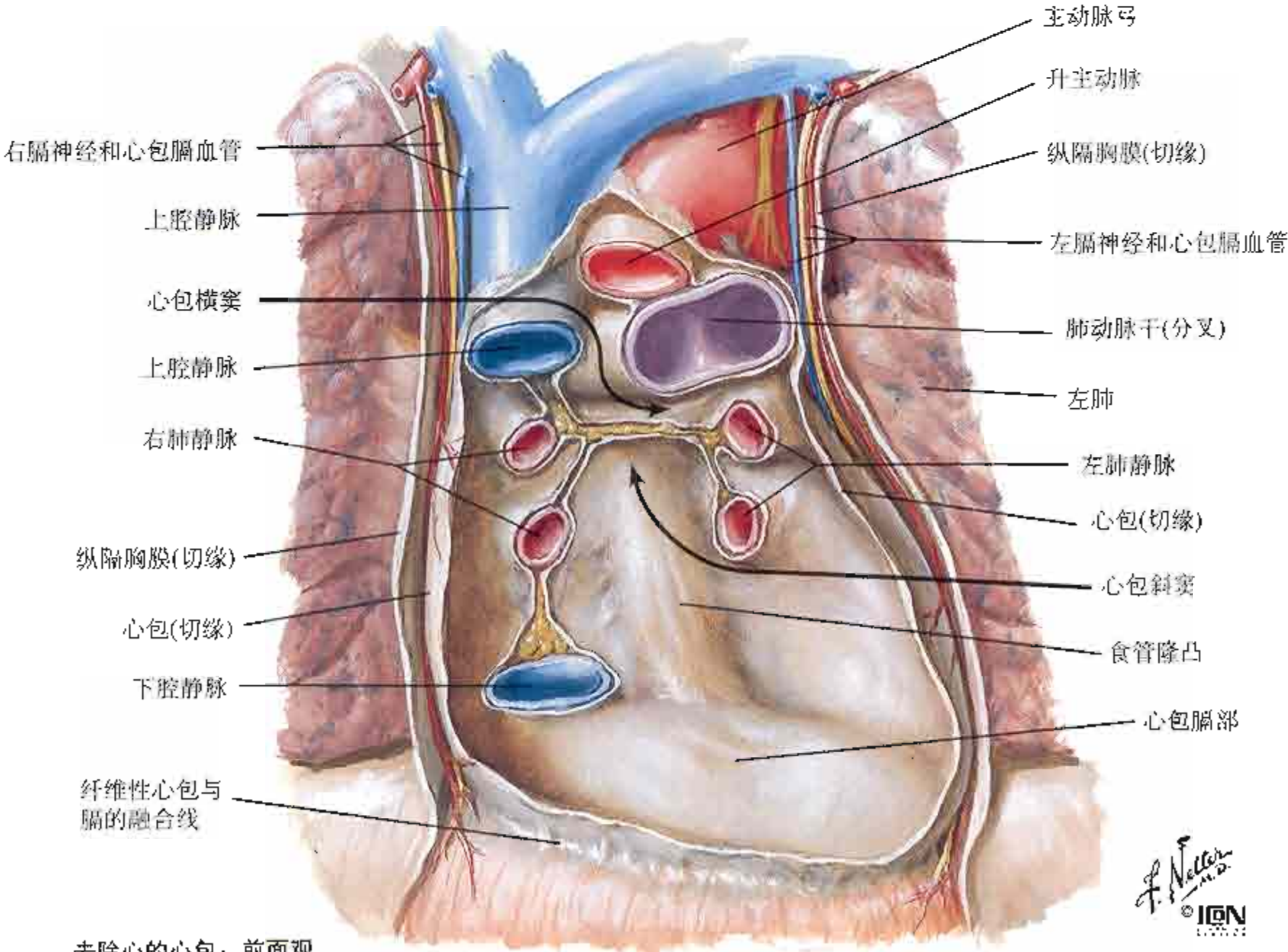
心底：后面观



心底和膈面：后下面观



心从切开的心包拉出：左侧面观



去除心的心包：前面观

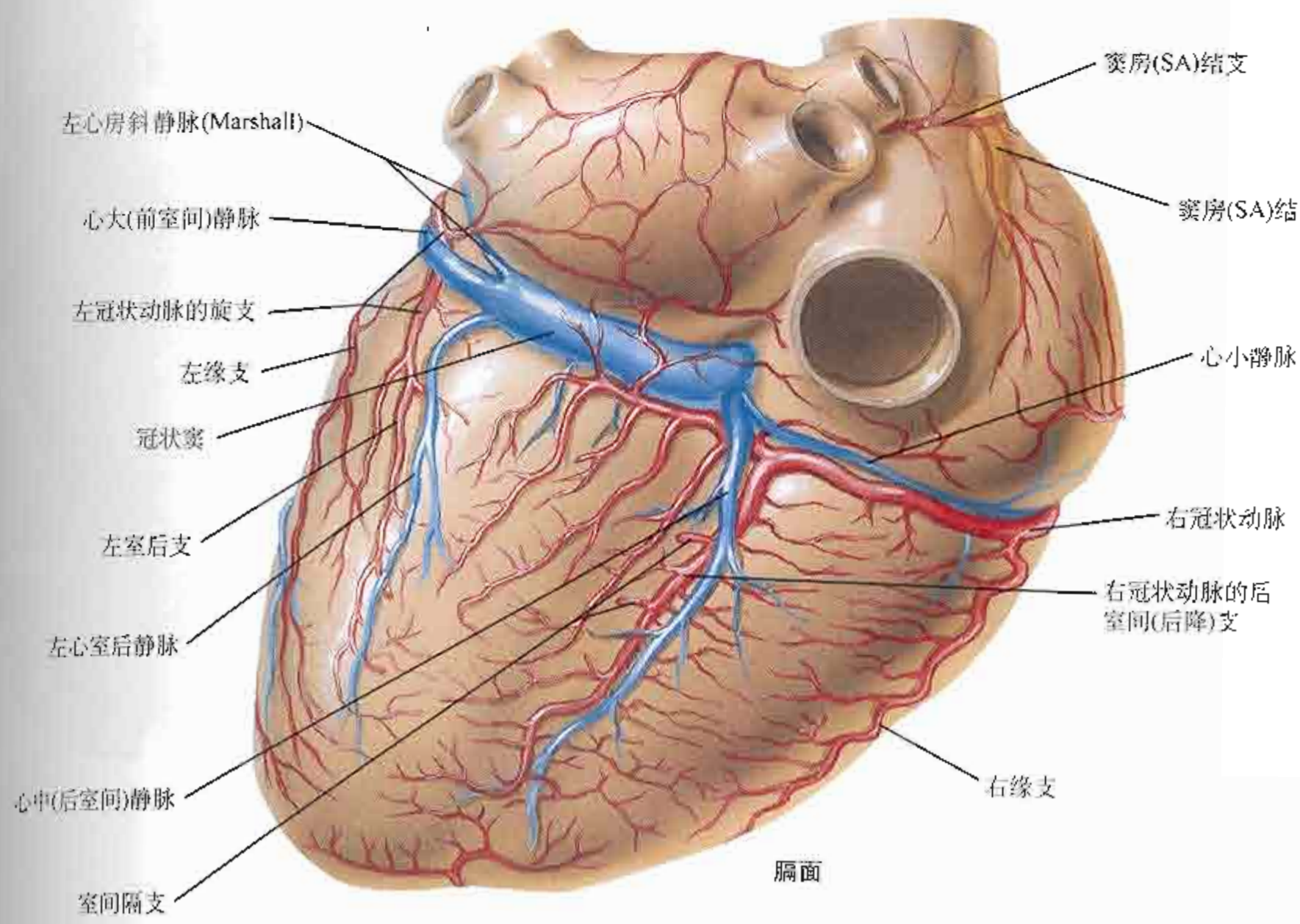
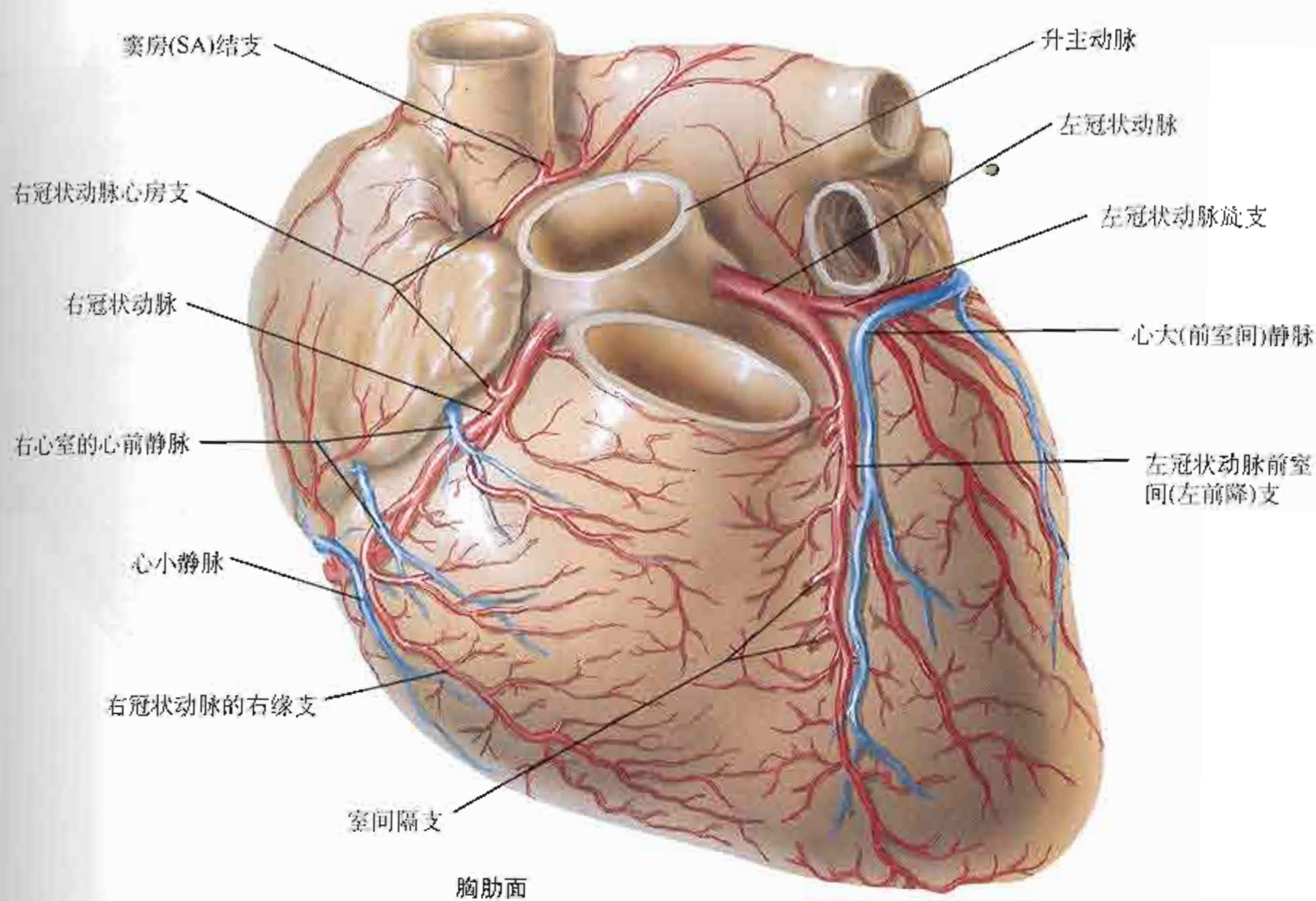
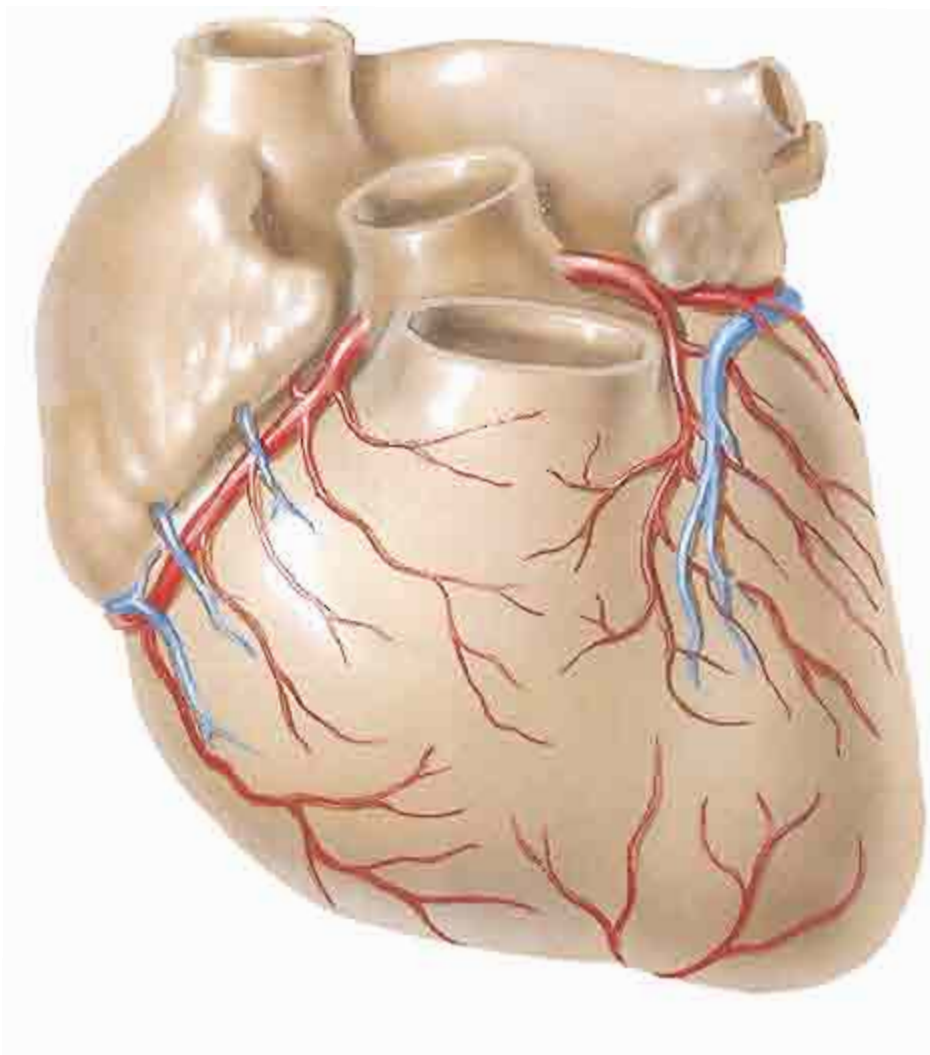
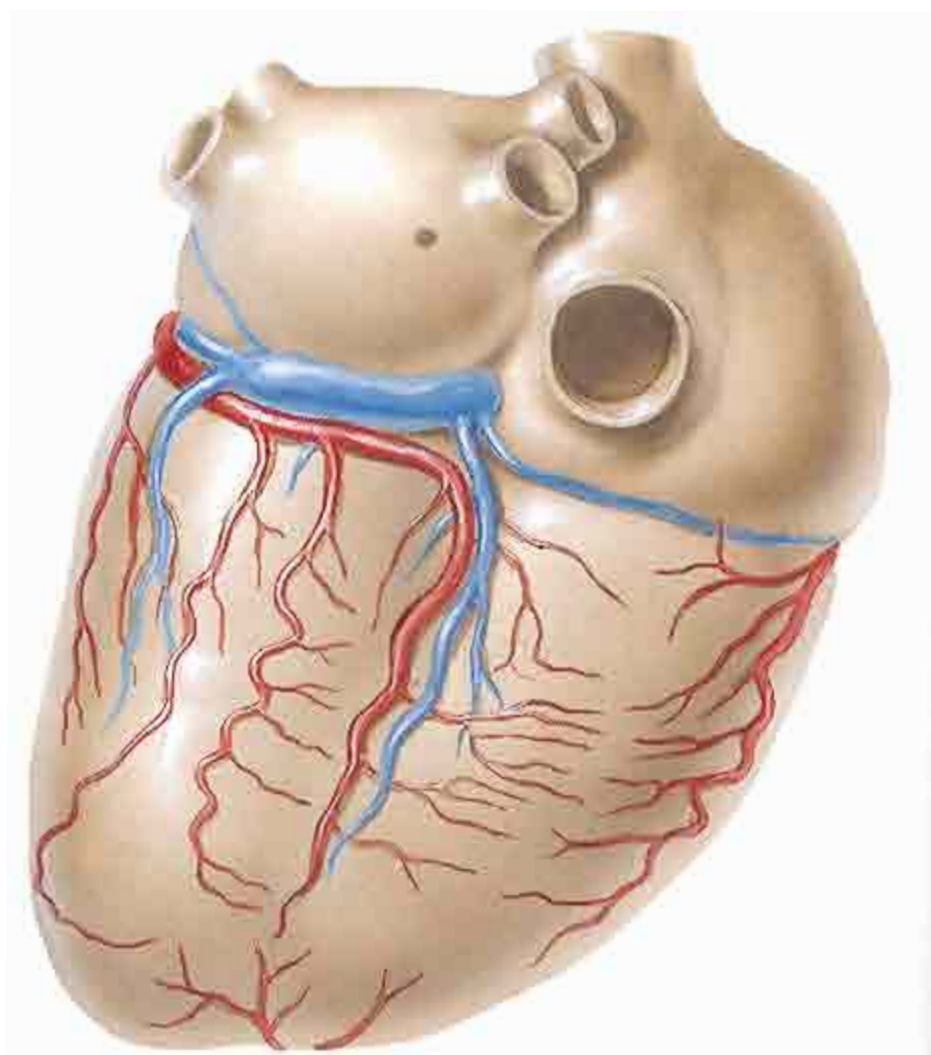


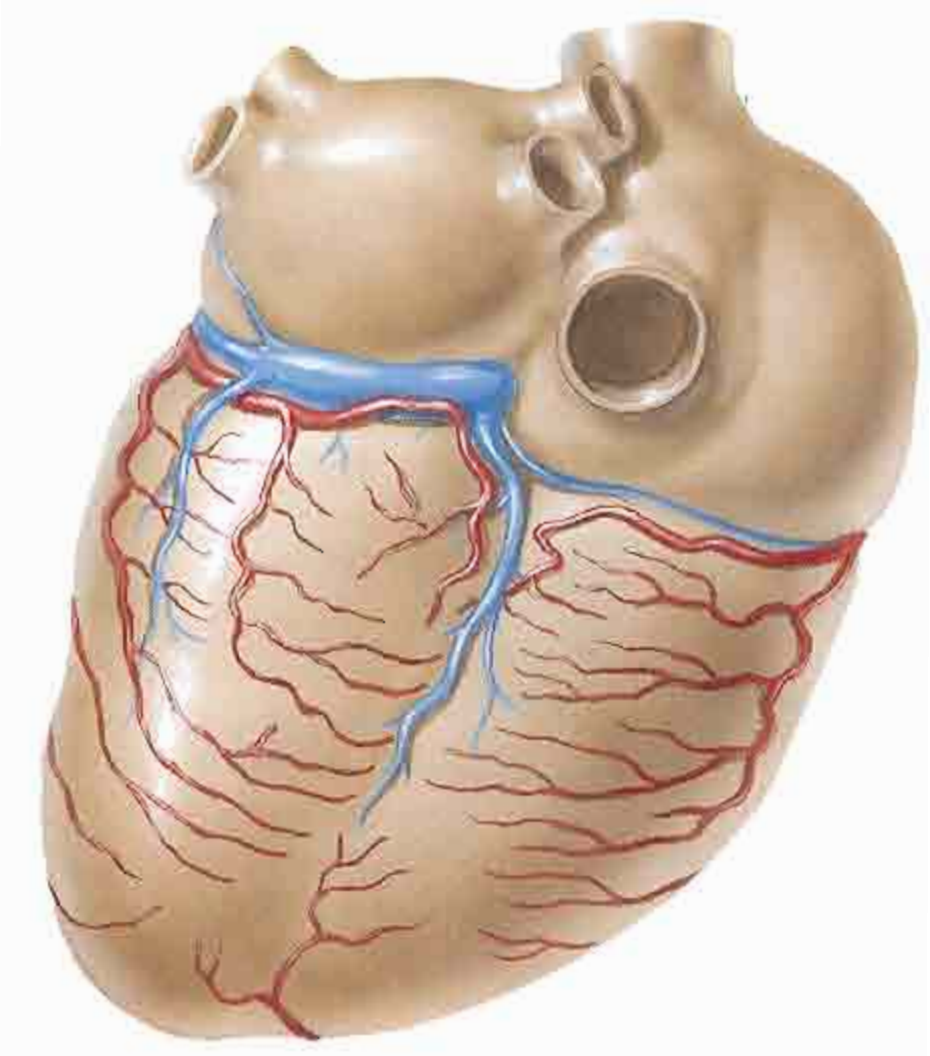
图212



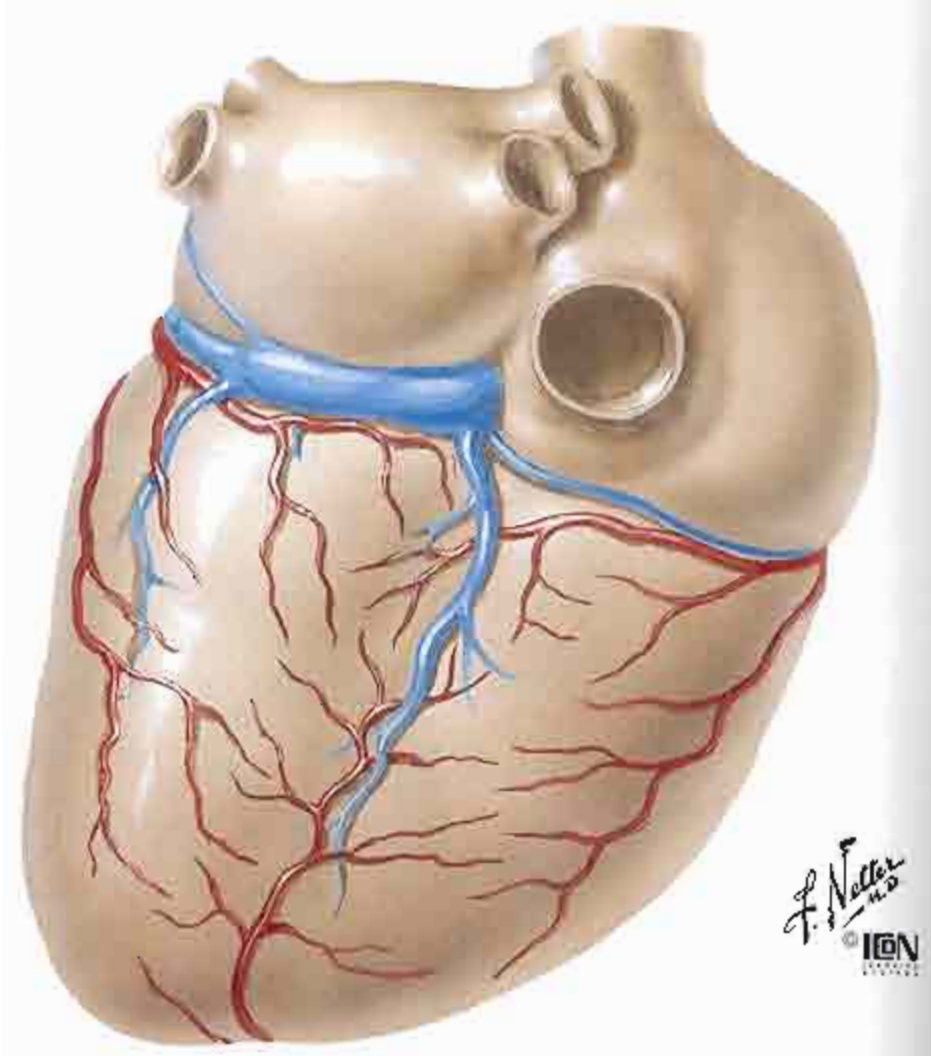
左冠状动脉的前室间(左前降)支很短。前面(胸肋面)的心尖部由迂行于心尖周围的右冠状动脉的后室间(后降)支供应



后室间(后降)支来自左冠状动脉旋支，而不是来自右冠状动脉的旋支

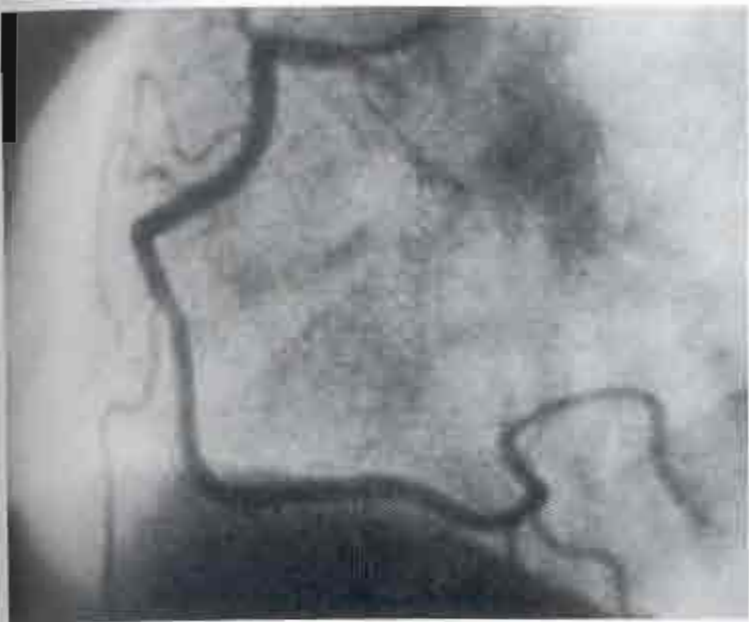


后室间(后降)支缺如。其供应区主要来自左冠状动脉旋支和来自右冠状动脉的小支供应

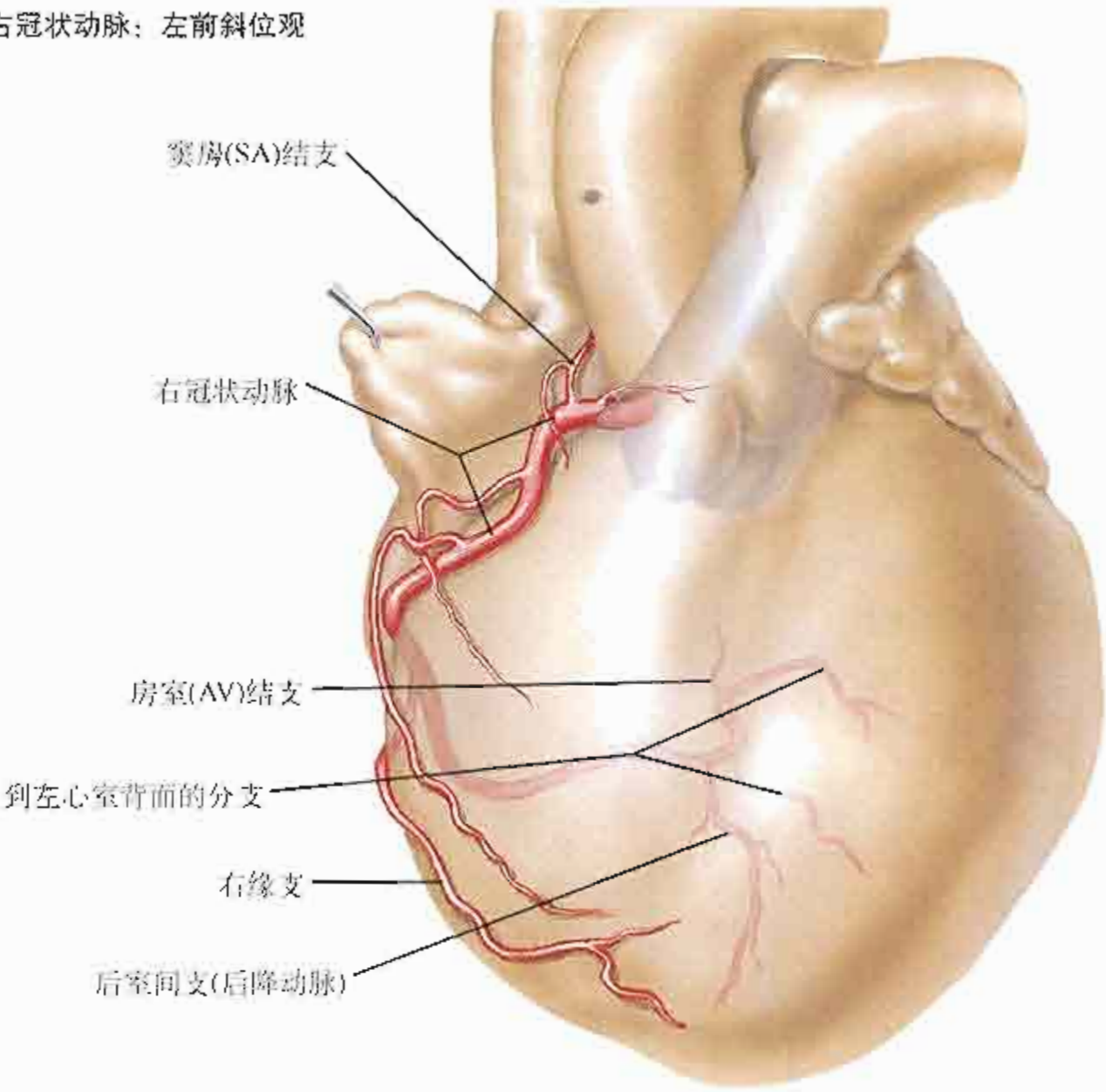


后室间(后降)支缺如。其供应区主要由迂行于心尖周围、延长了的前室间(左前降)支供应

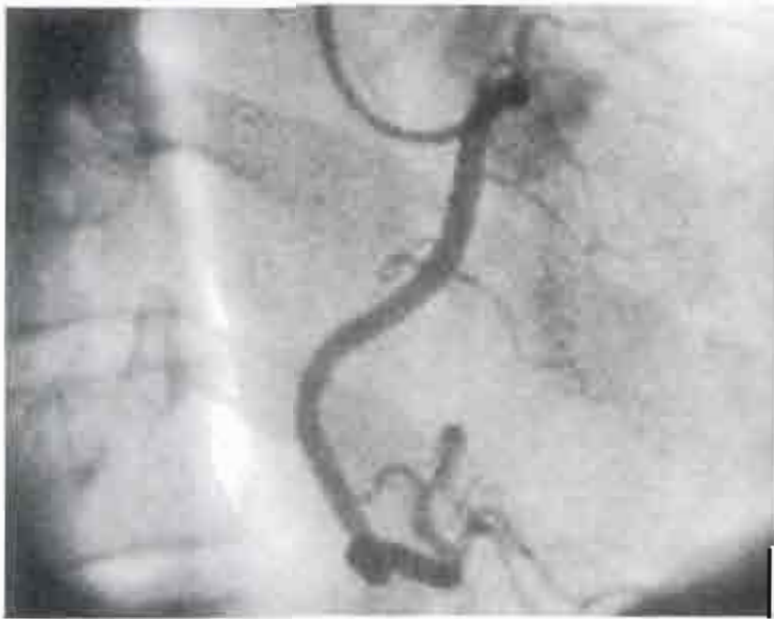
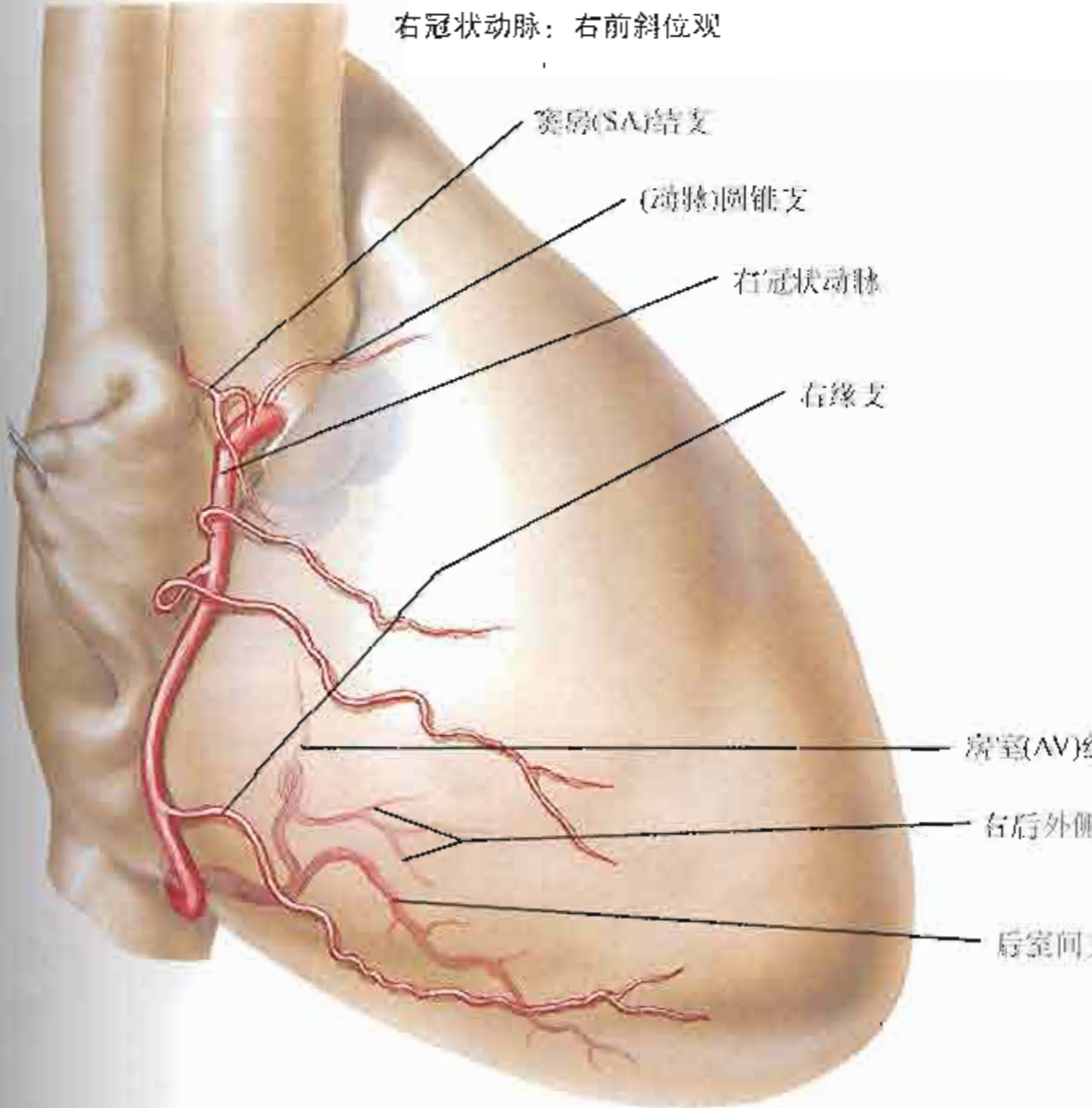
右冠状动脉：左前斜位观



动脉造影照片



右冠状动脉：右前斜位观



动脉造影照片

F. Netter
M.D.
© ION
ILLUSTRATIONS

图214

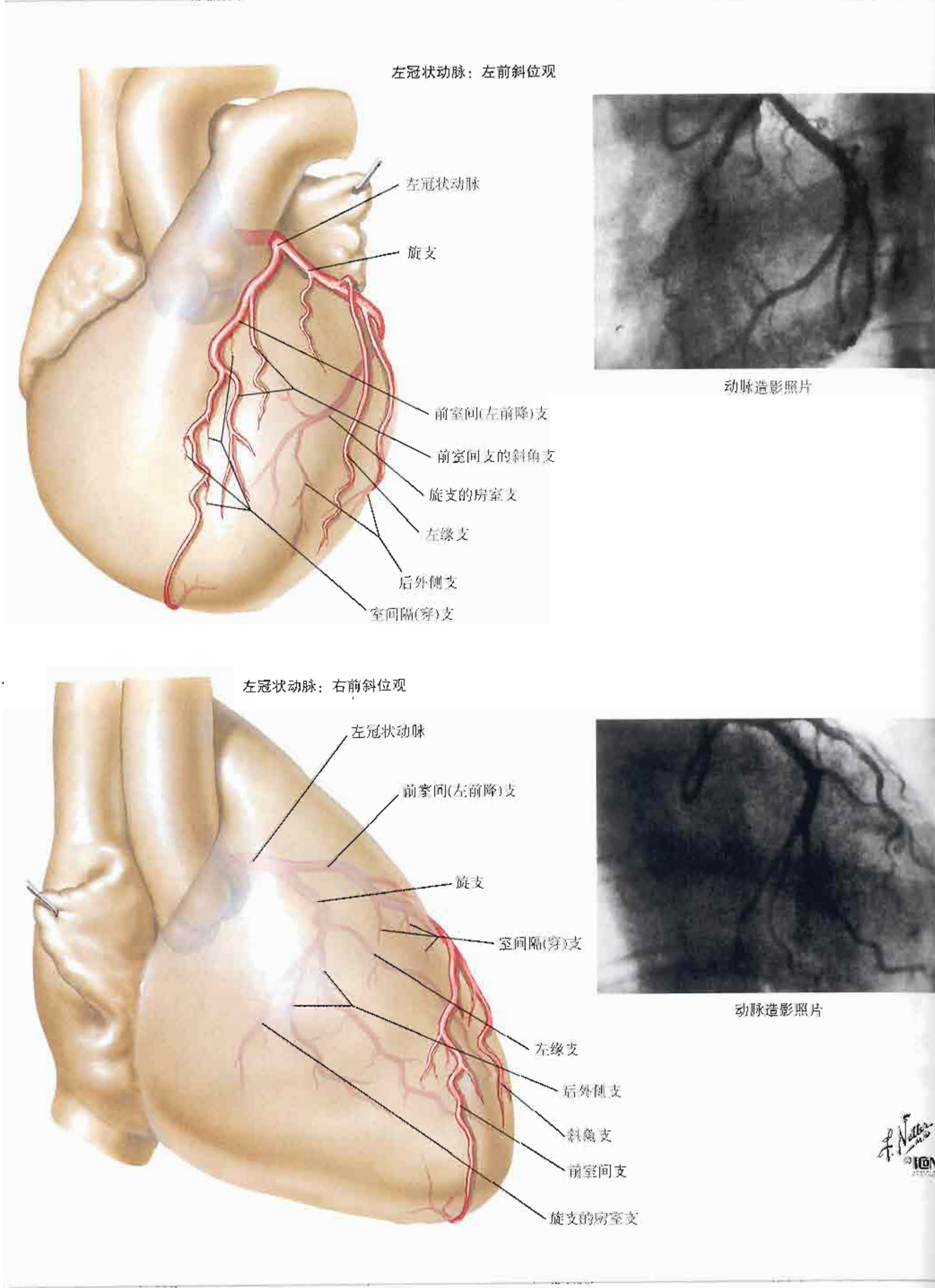
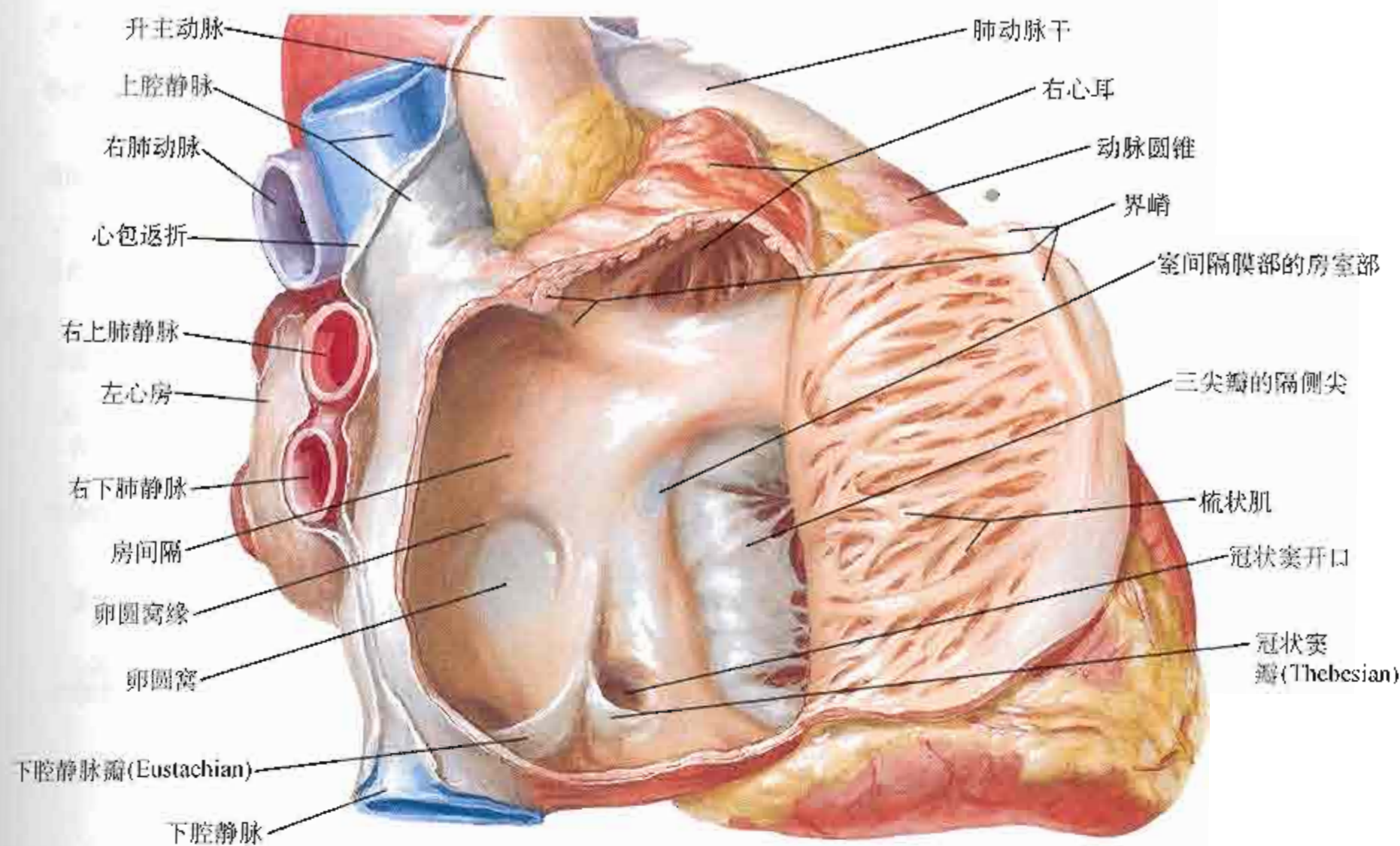
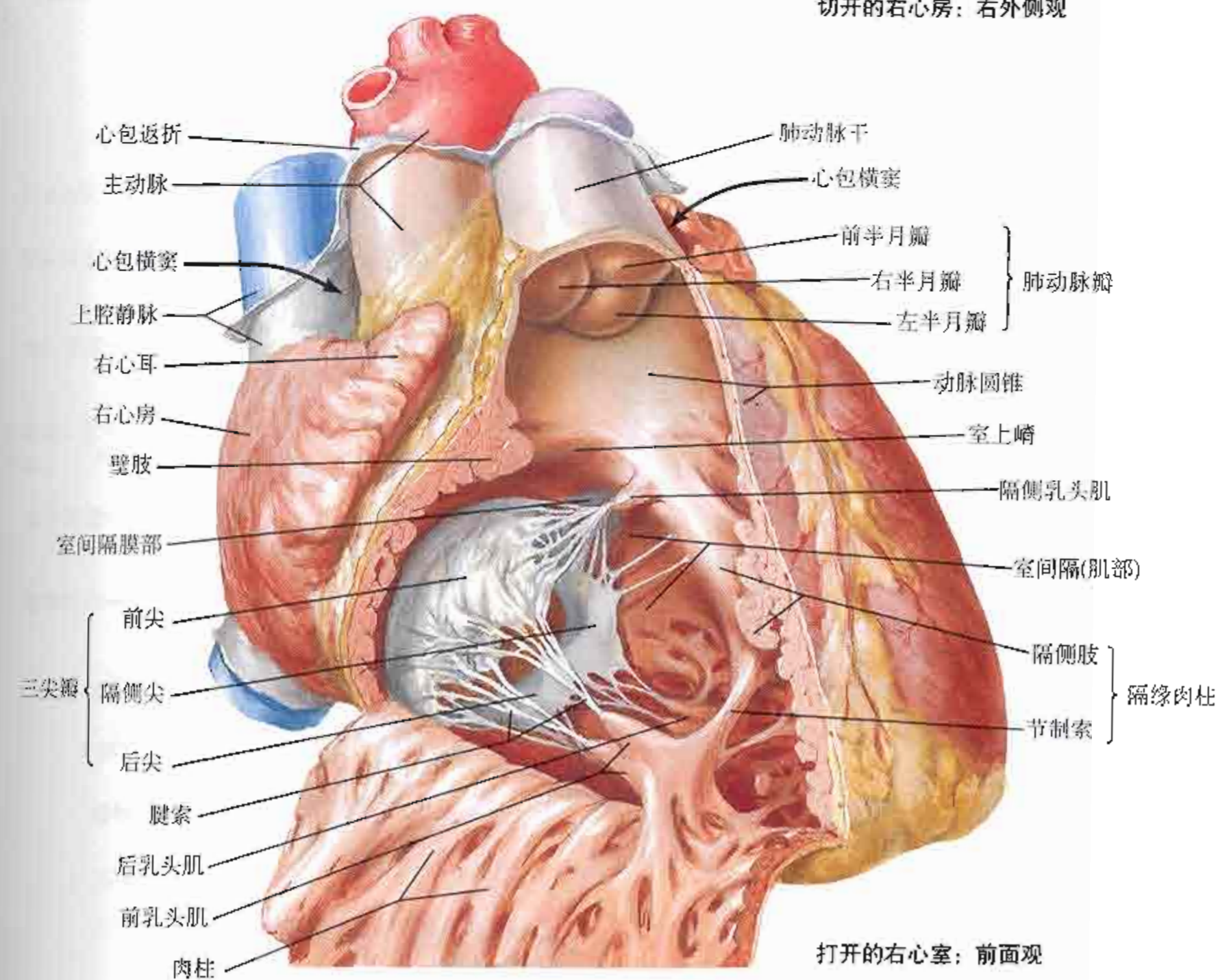


图215



切开的右心房：右外侧观



打开的右心室：前面观

F. Netter M.D. IGM

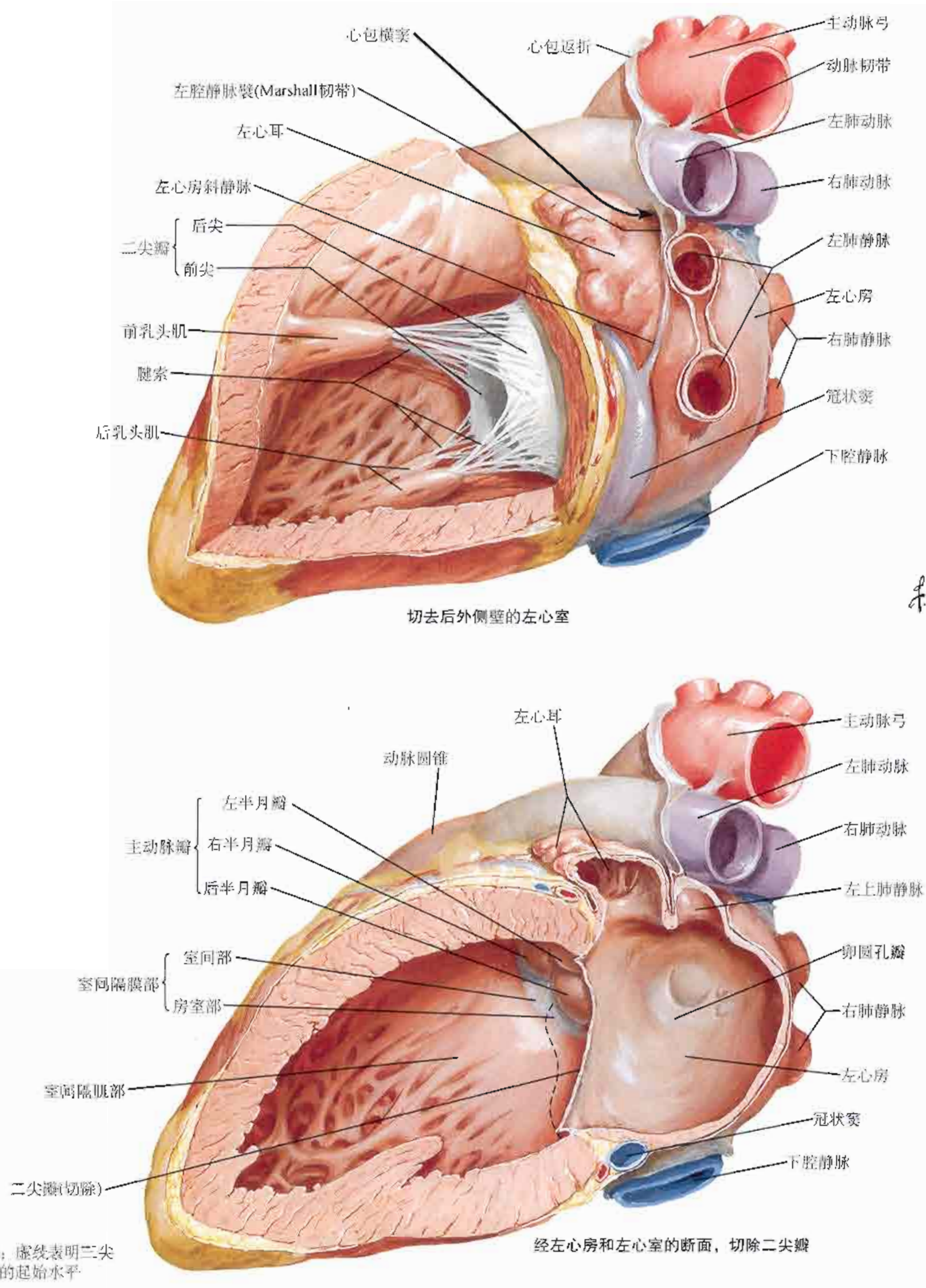
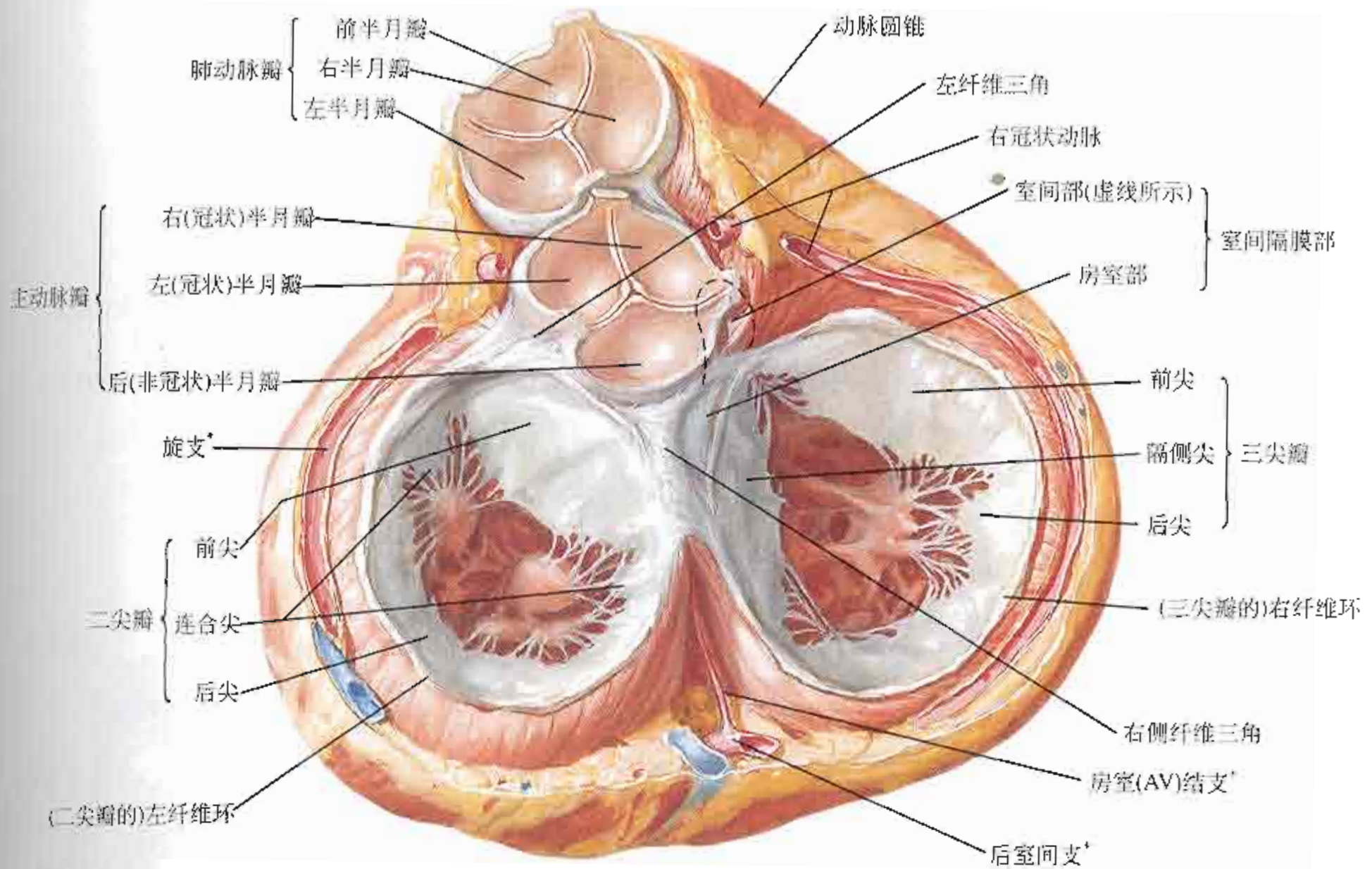
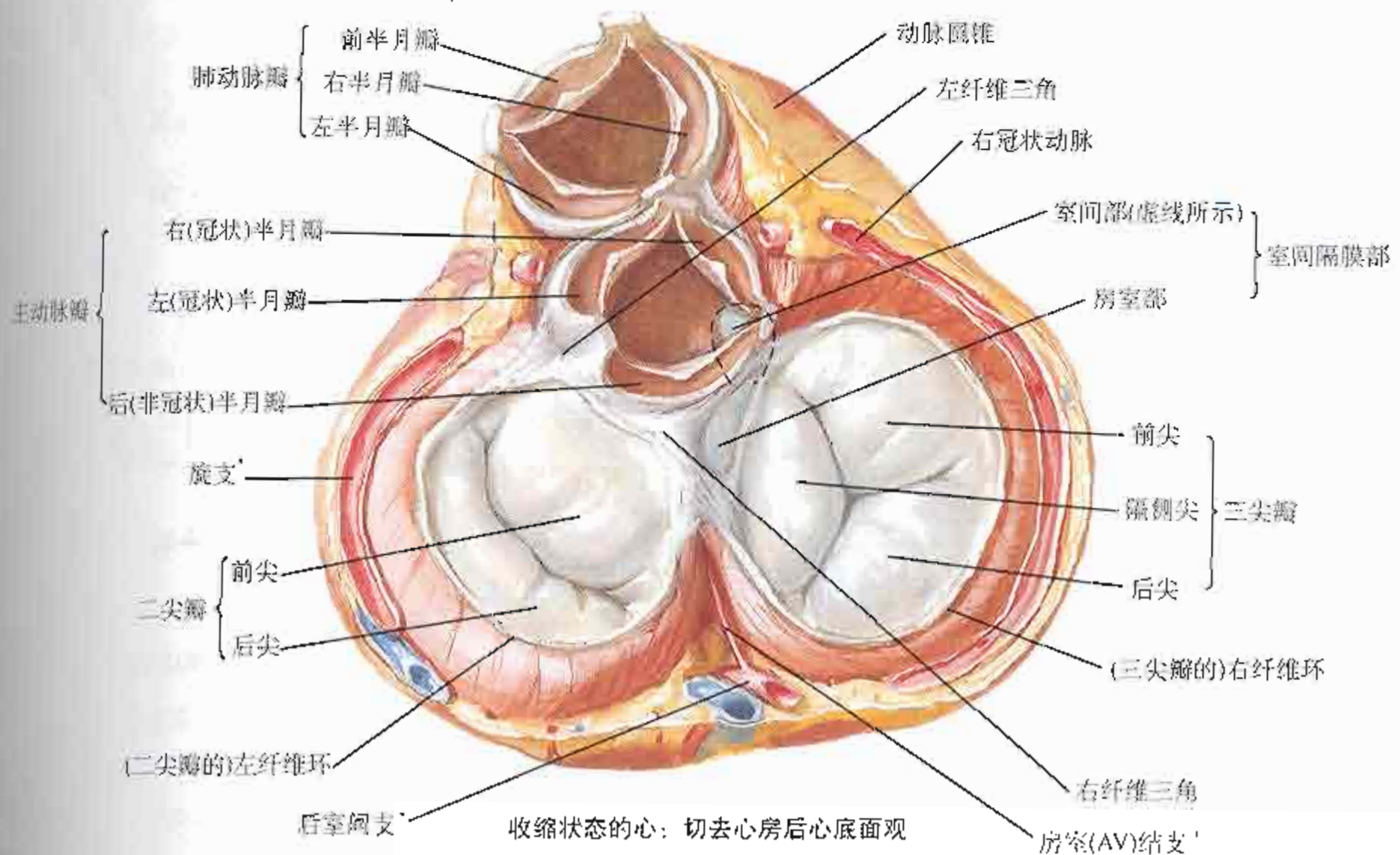


图217



舒张状态的心：切去心房后心底面观

F. Netter M.D. ILLUSTRATIONS



收缩状态的心：切去心房后心底面观

左冠状动脉的分支
右冠状动脉的分支

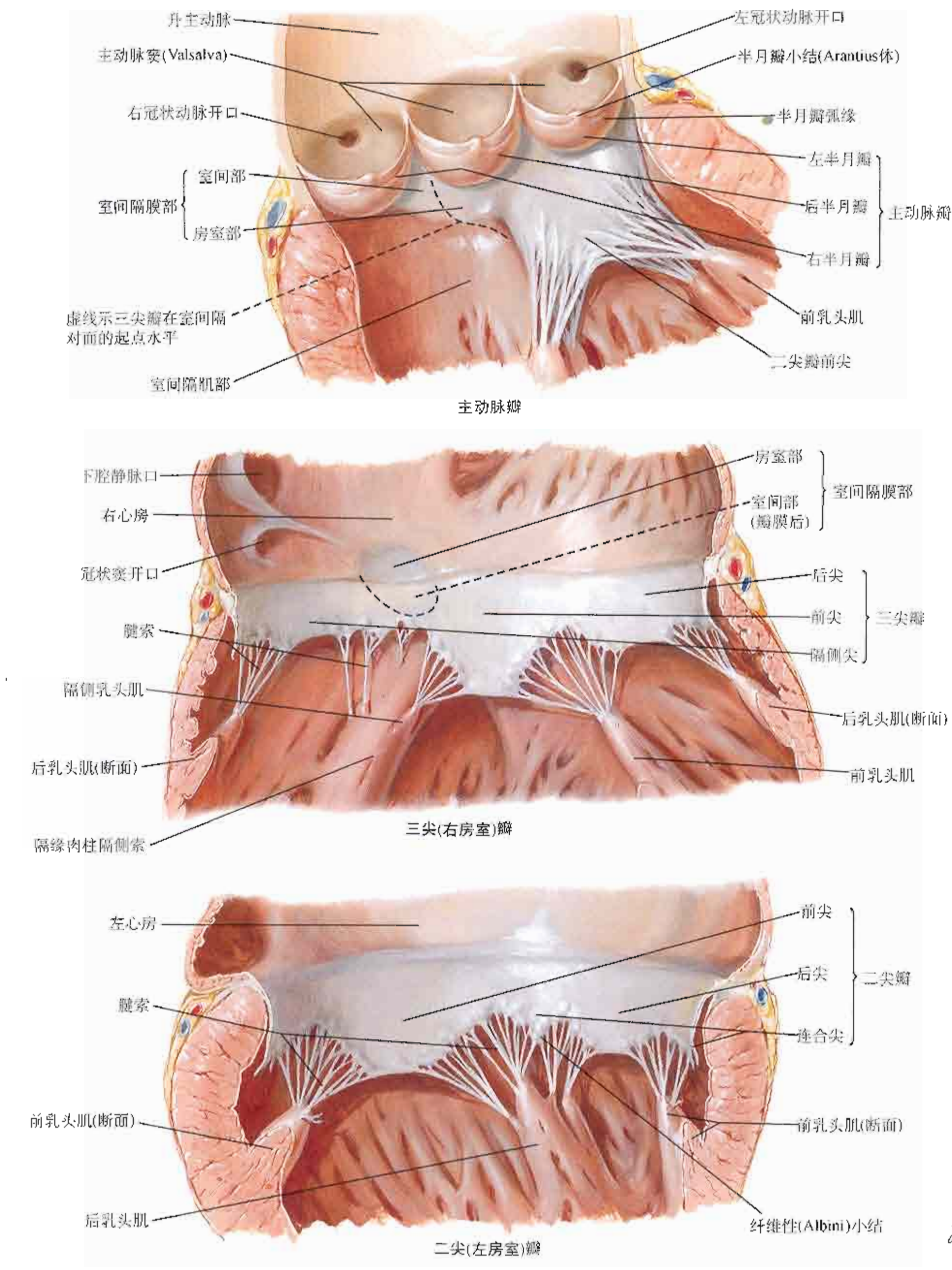
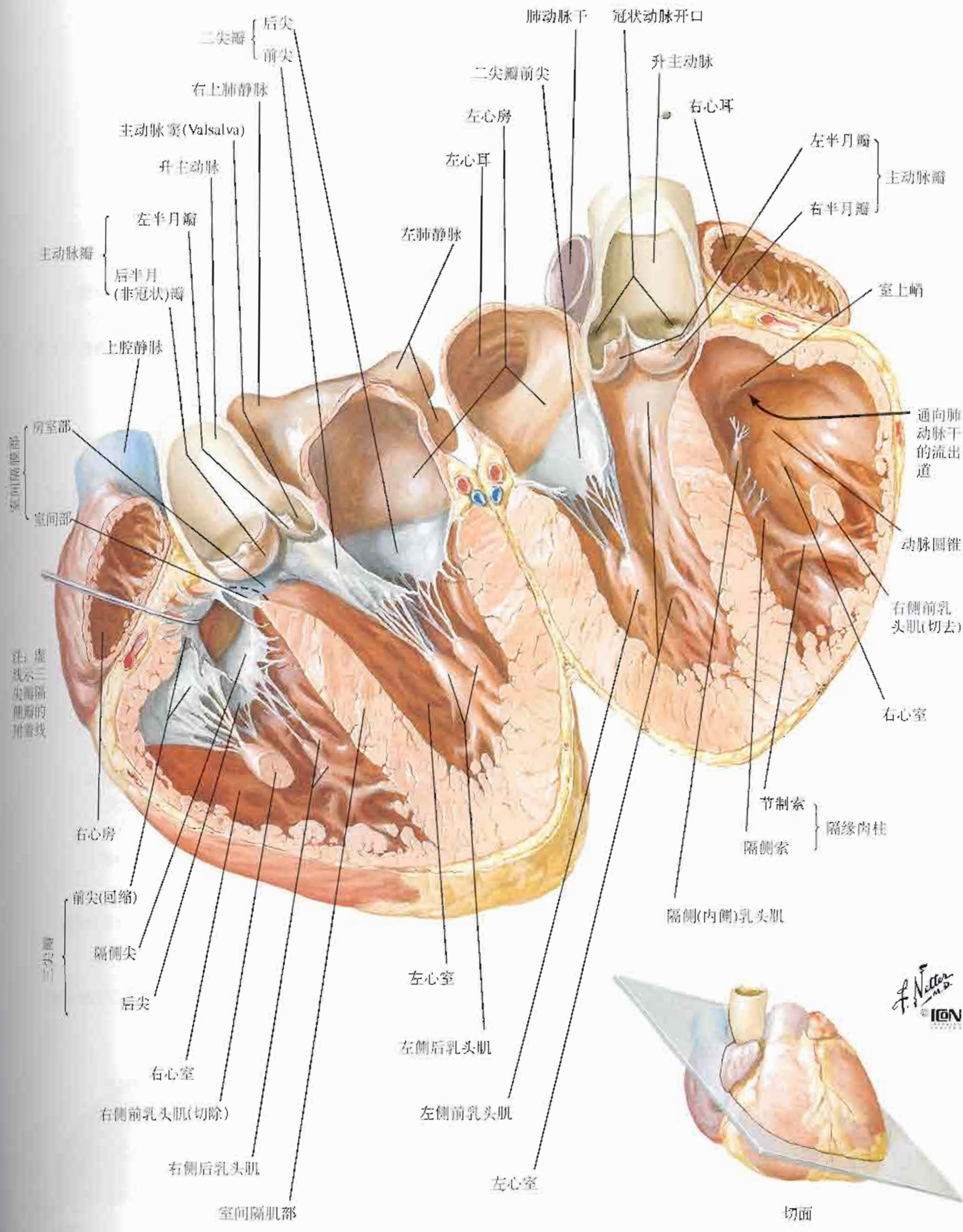
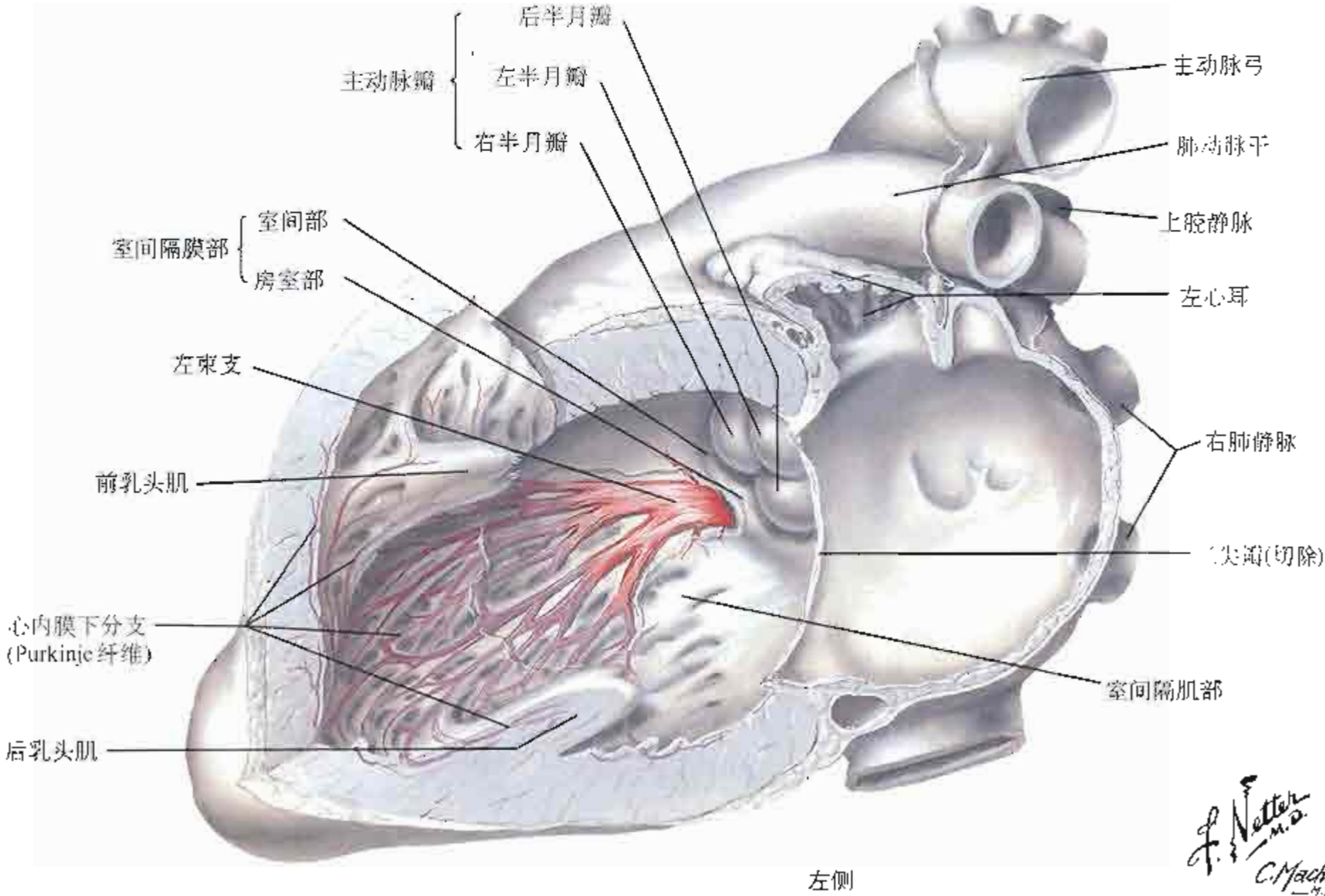
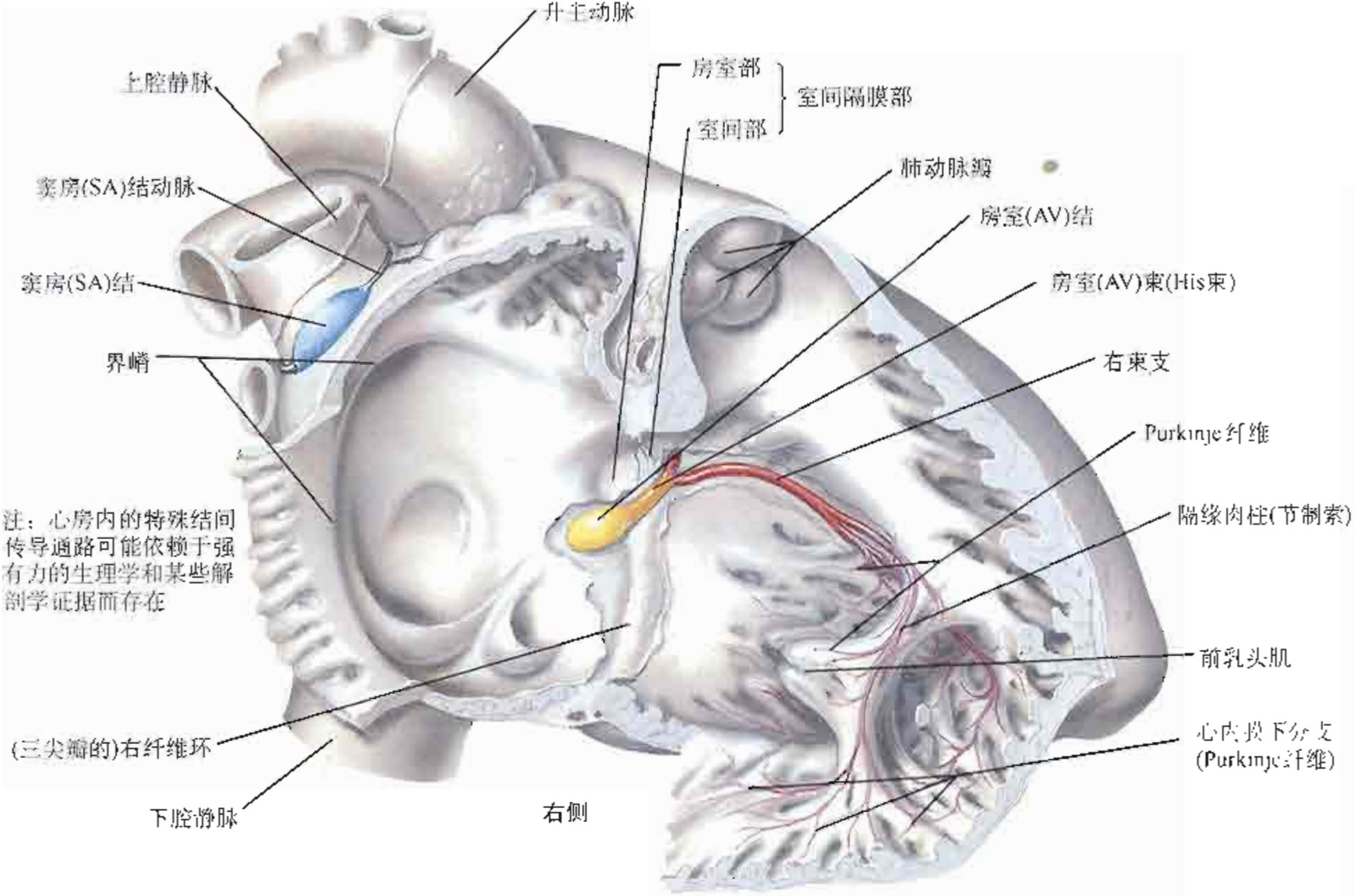


图219



F. Netter M.D. ION



F. Netter M.D.
C. Machado
© IGCN

图221

参见图 124、159、205

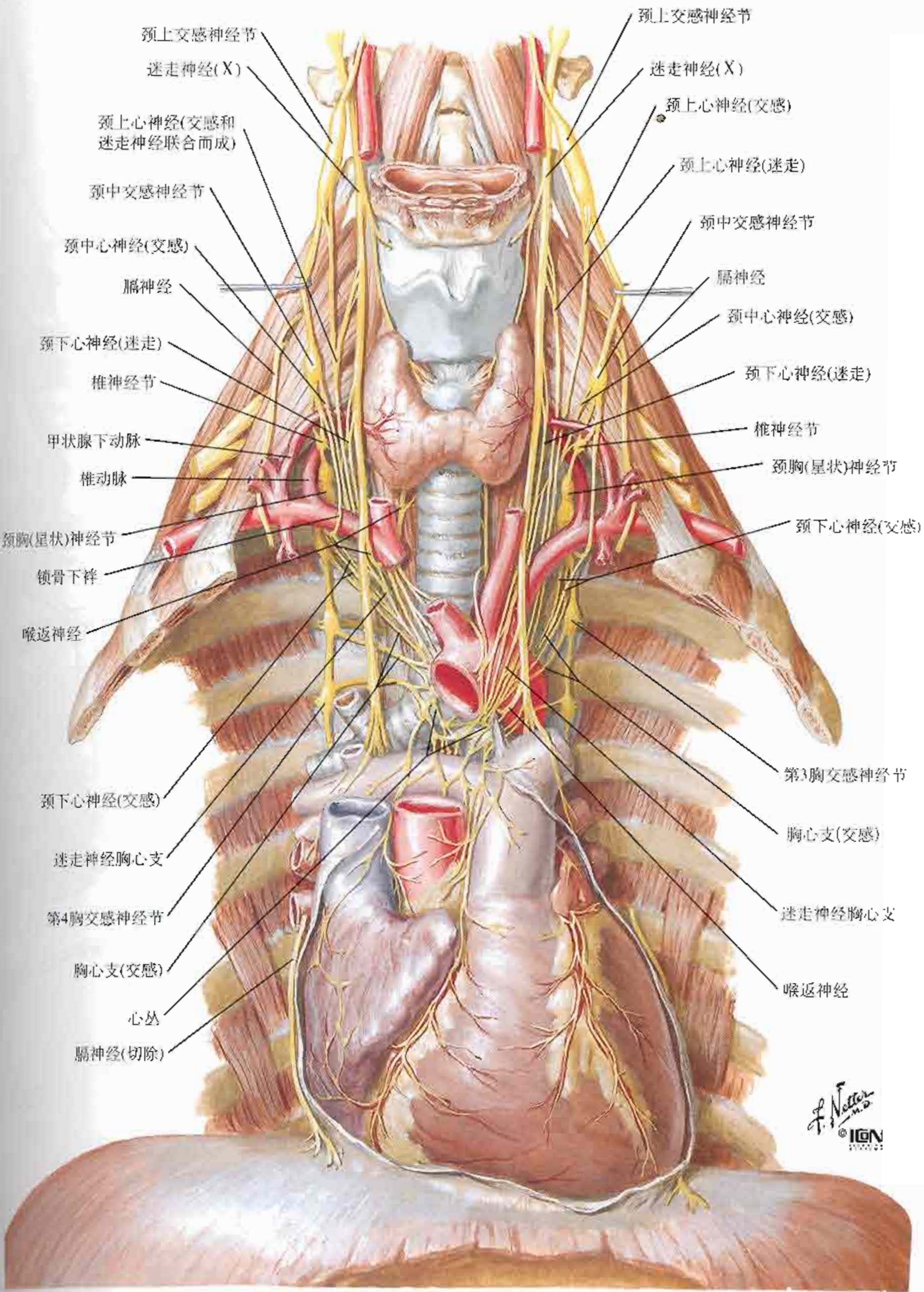


图222

参见图 120、160

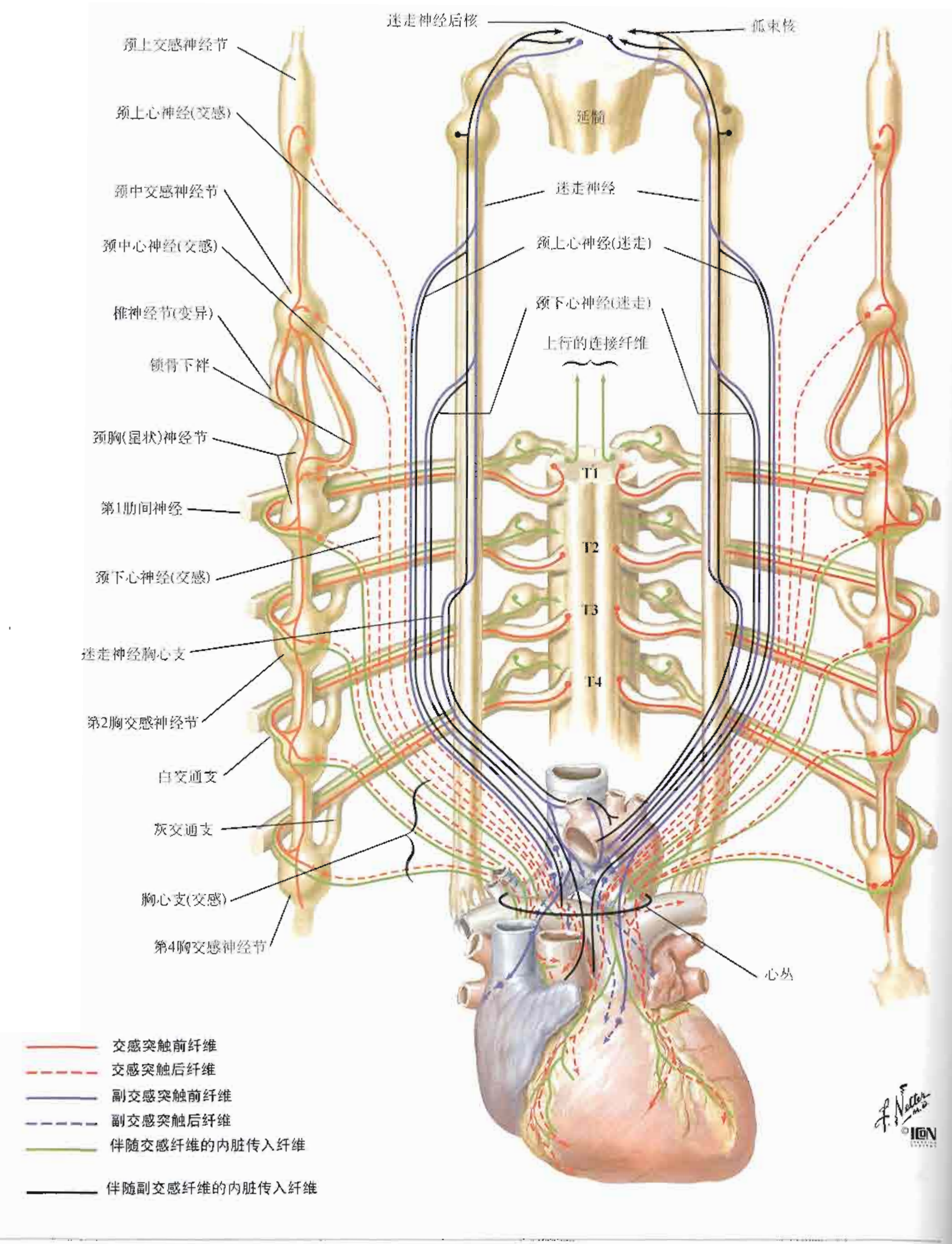


图223

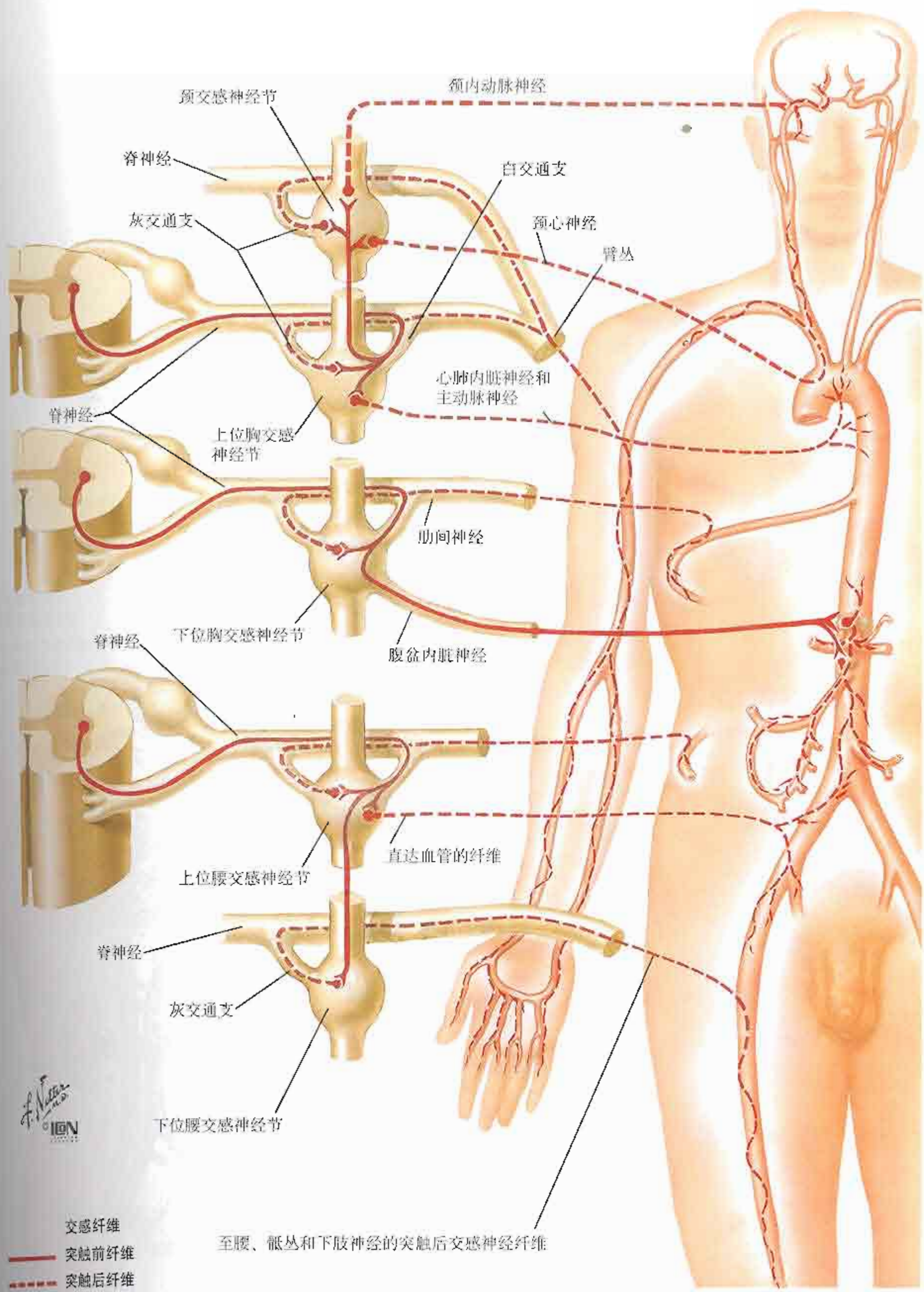


图224

脐血管闭塞后的情况见图 245

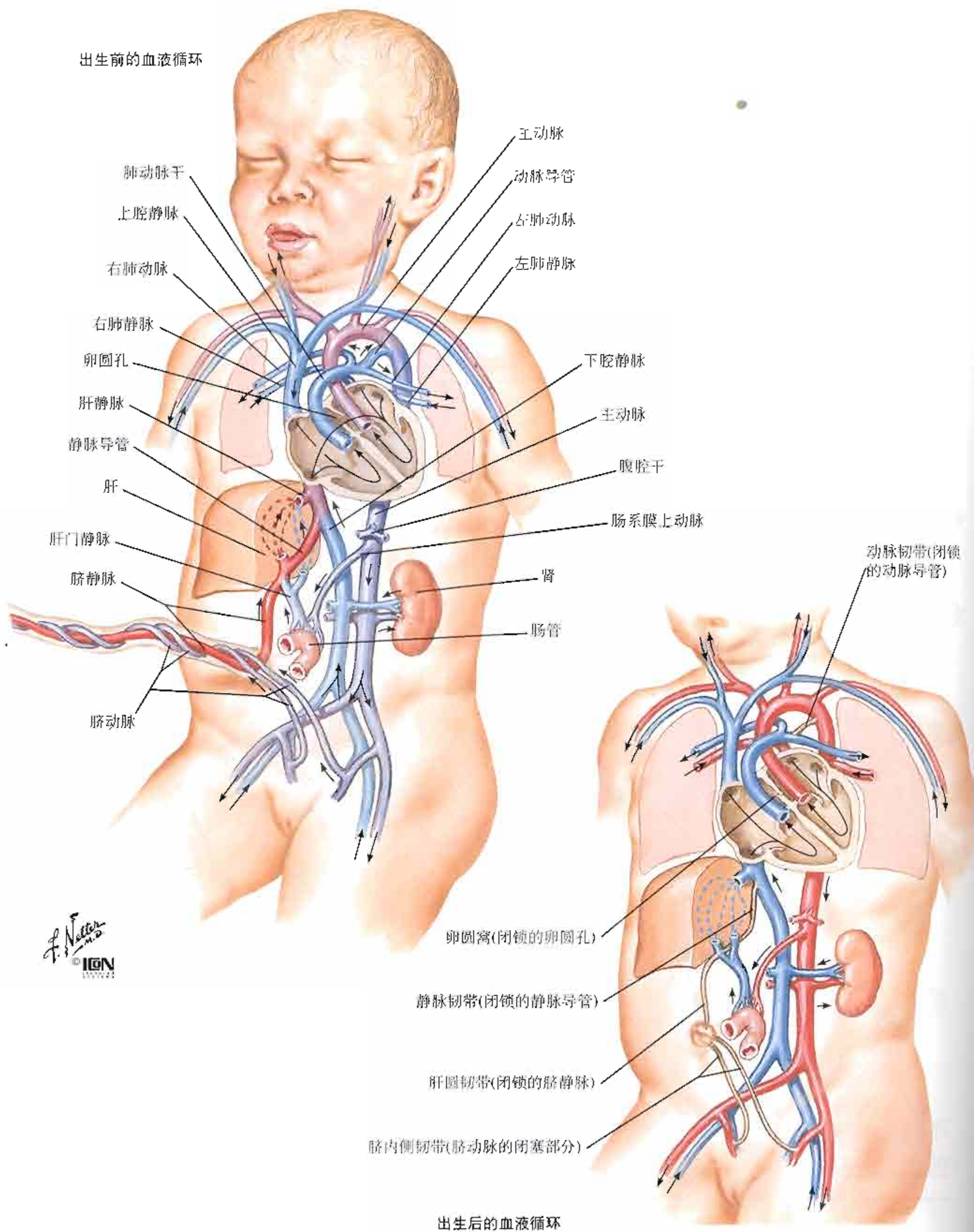
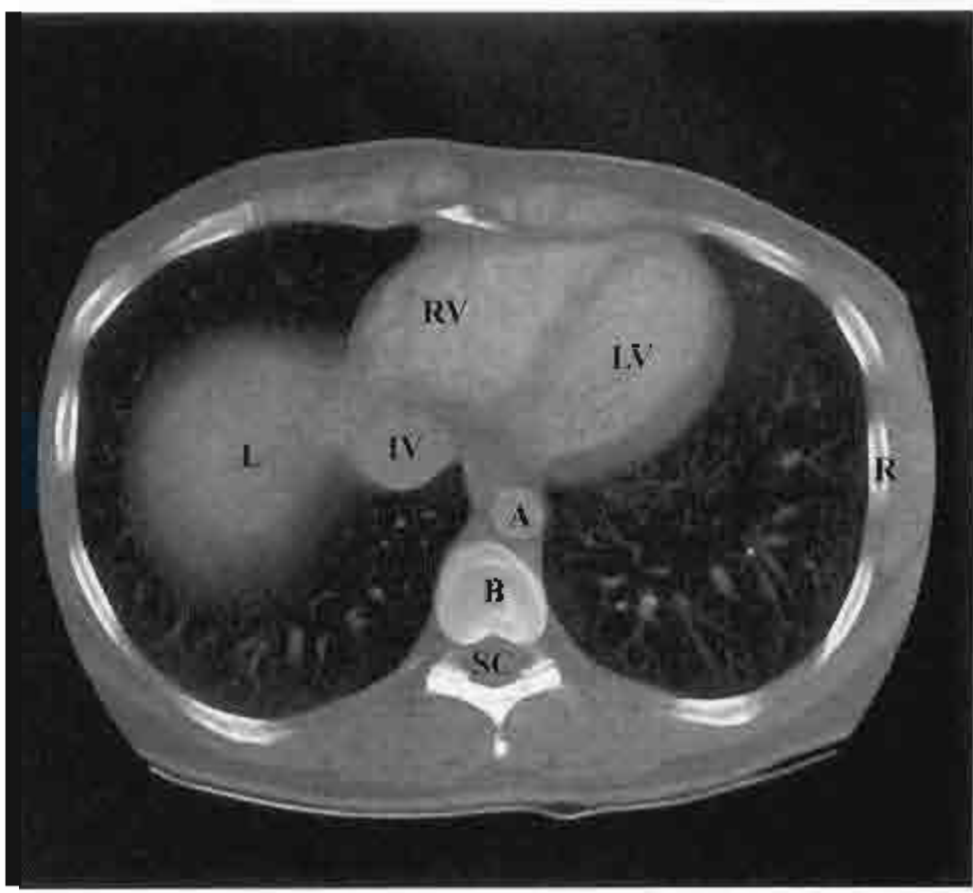
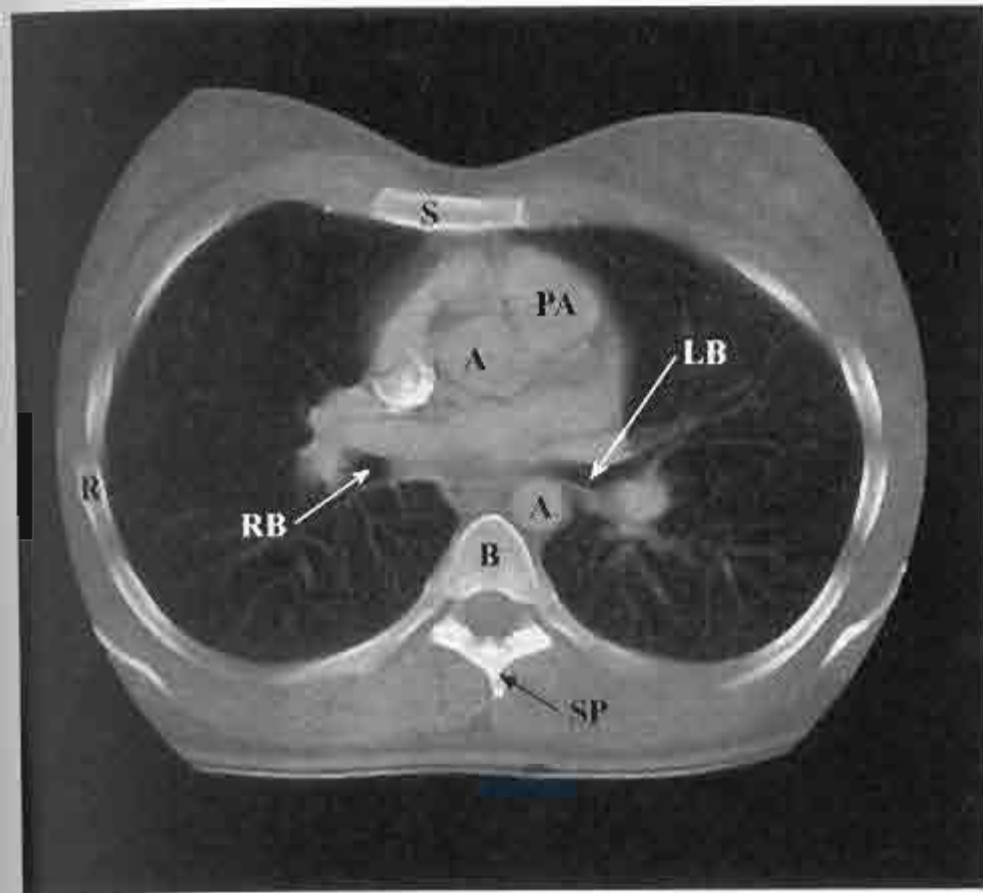
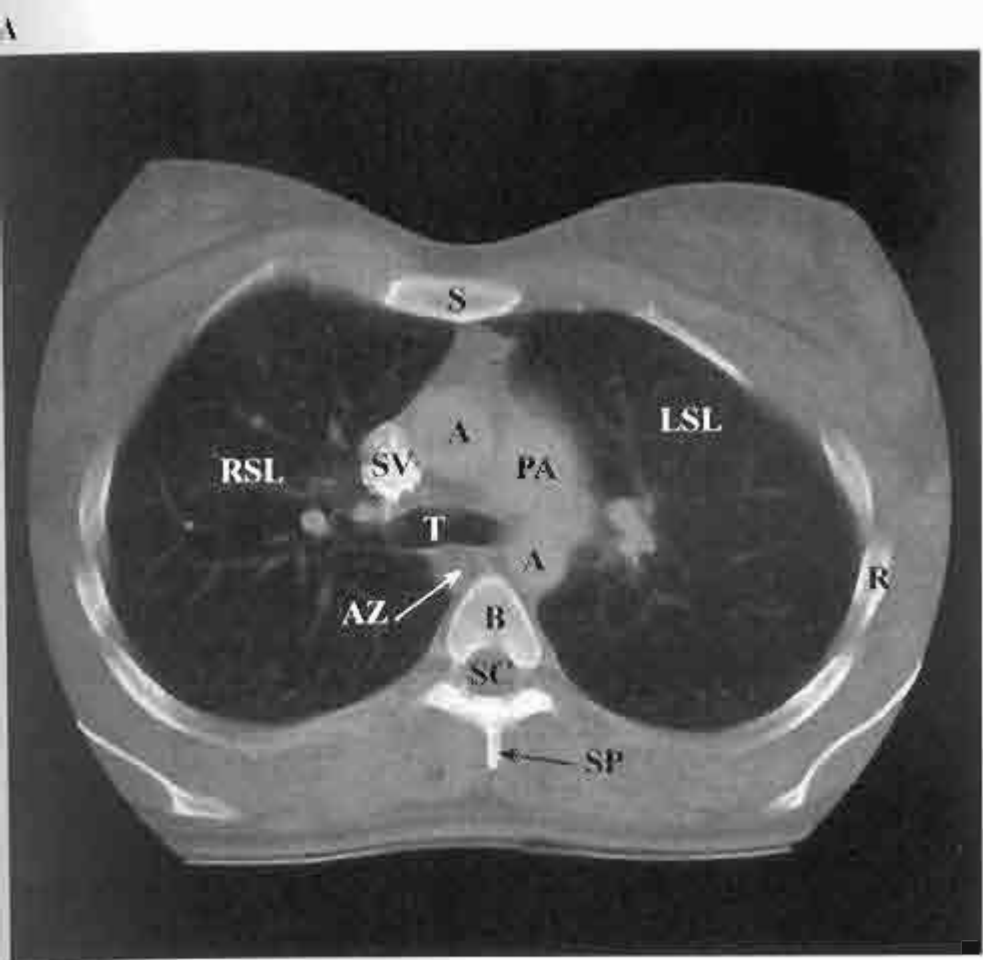
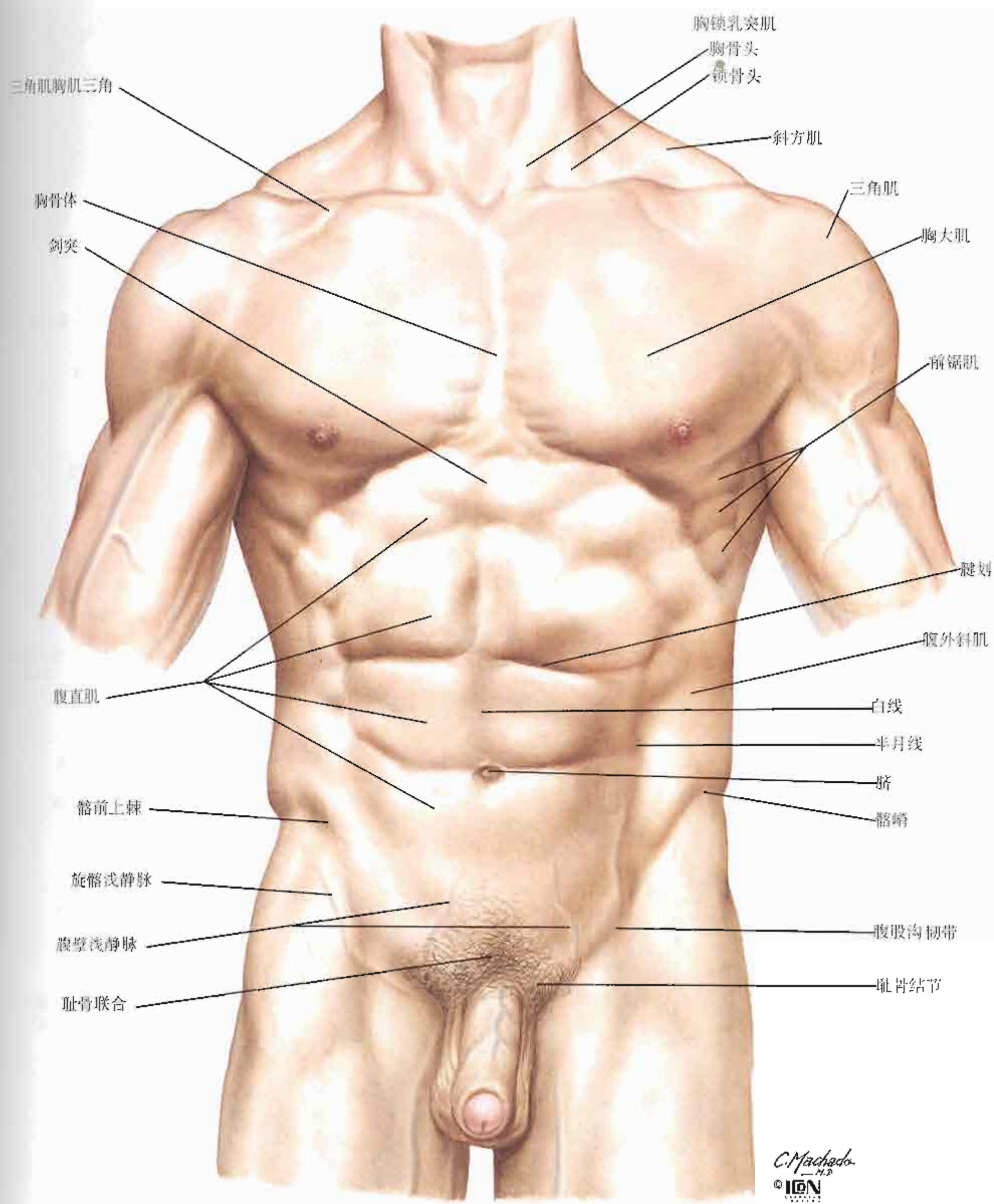


图225

从上(A)到下(C)连续胸部轴位CT影像



- A 主动脉
- AZ 奇静脉
- B 椎体
- IV 下腔静脉
- L 肝
- LB 左支气管
- LSL 左肺上叶
- LV 左心室
- PA 肺动脉
- R 肋
- RB 右支气管
- RL 右肺上叶
- RV 右心室
- S 胸骨
- SC 脊髓
- SP 椎骨棘突
- SV 上腔静脉
- T 气管(杈)



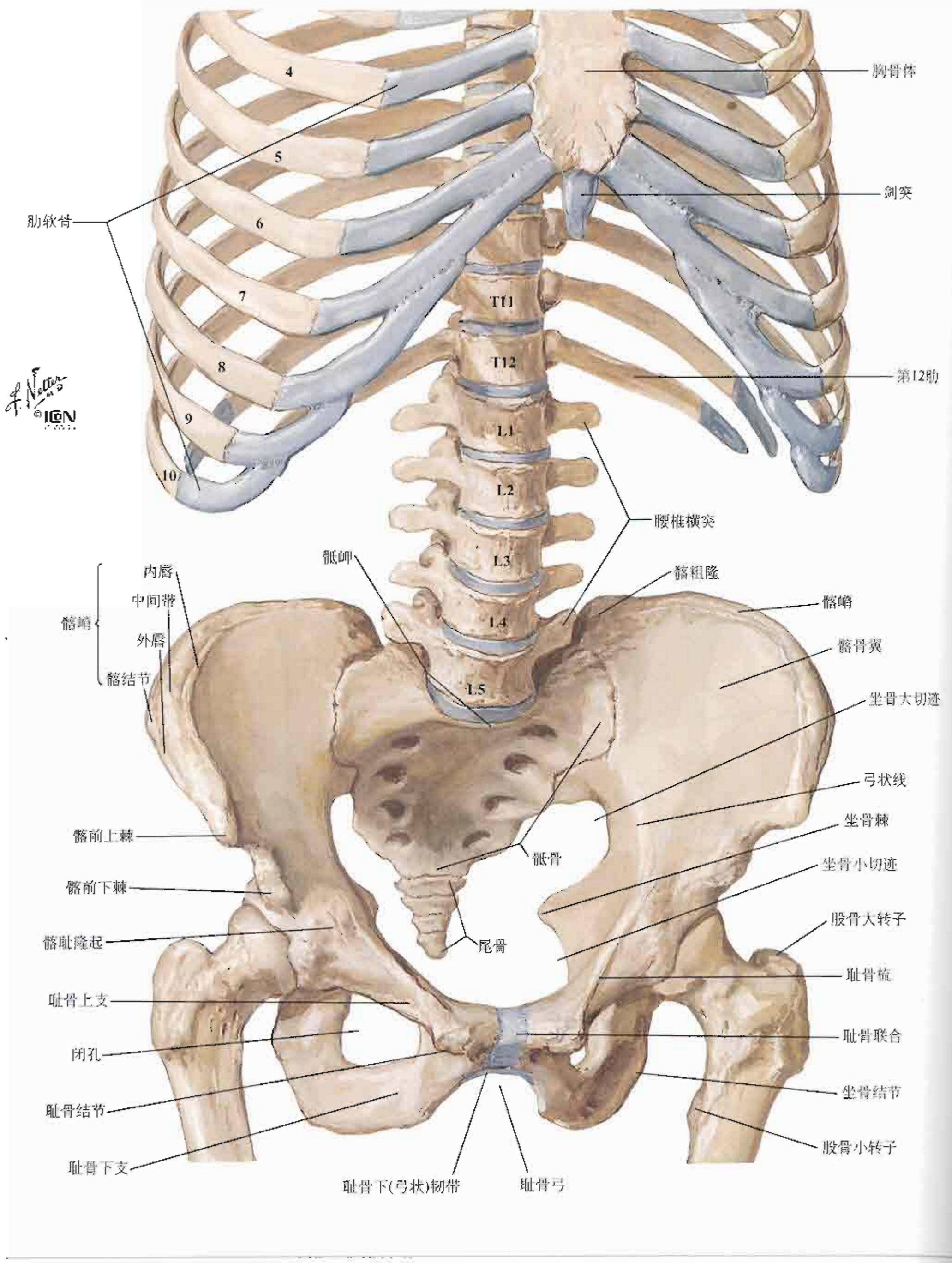


图240

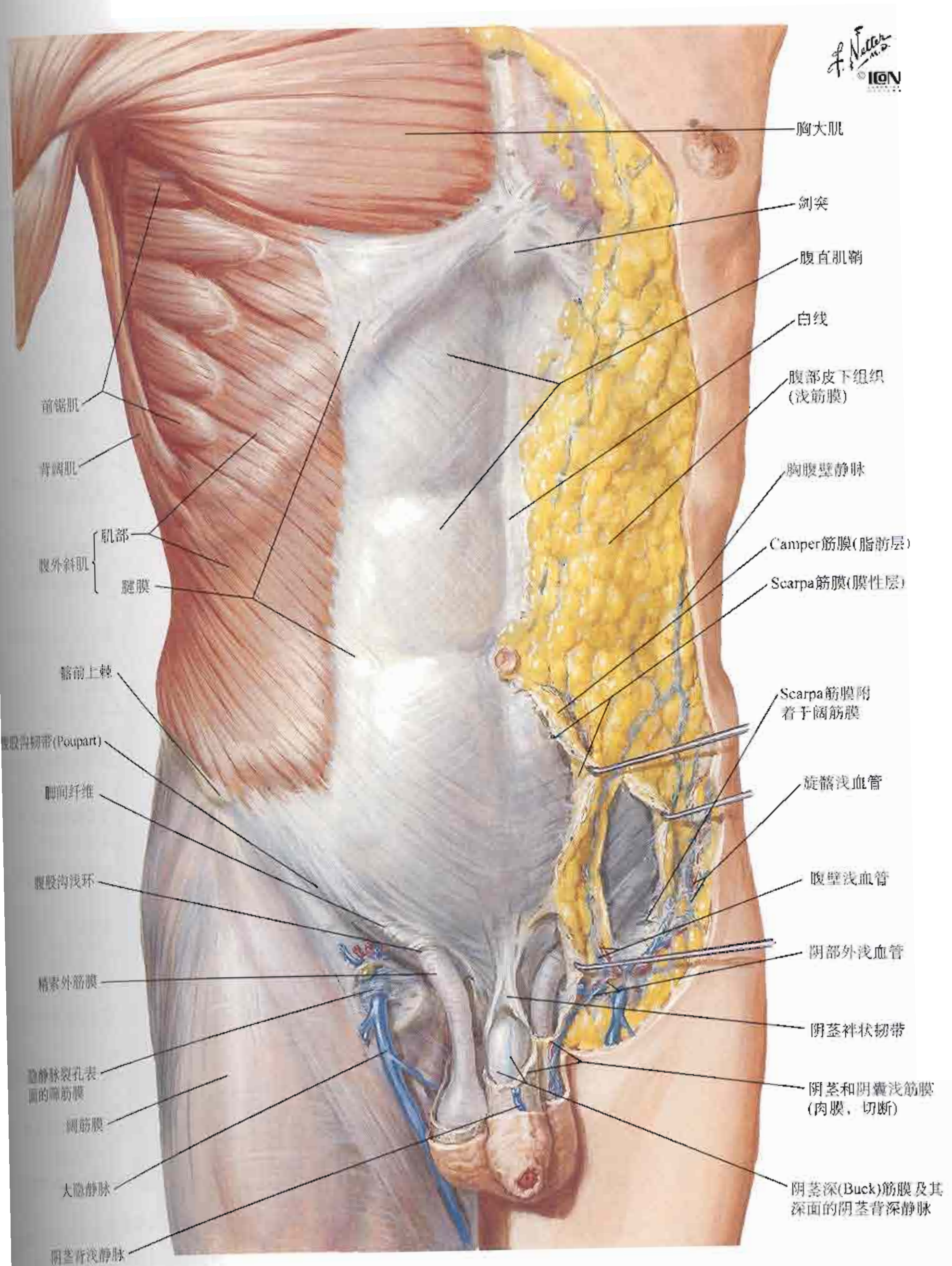


图241

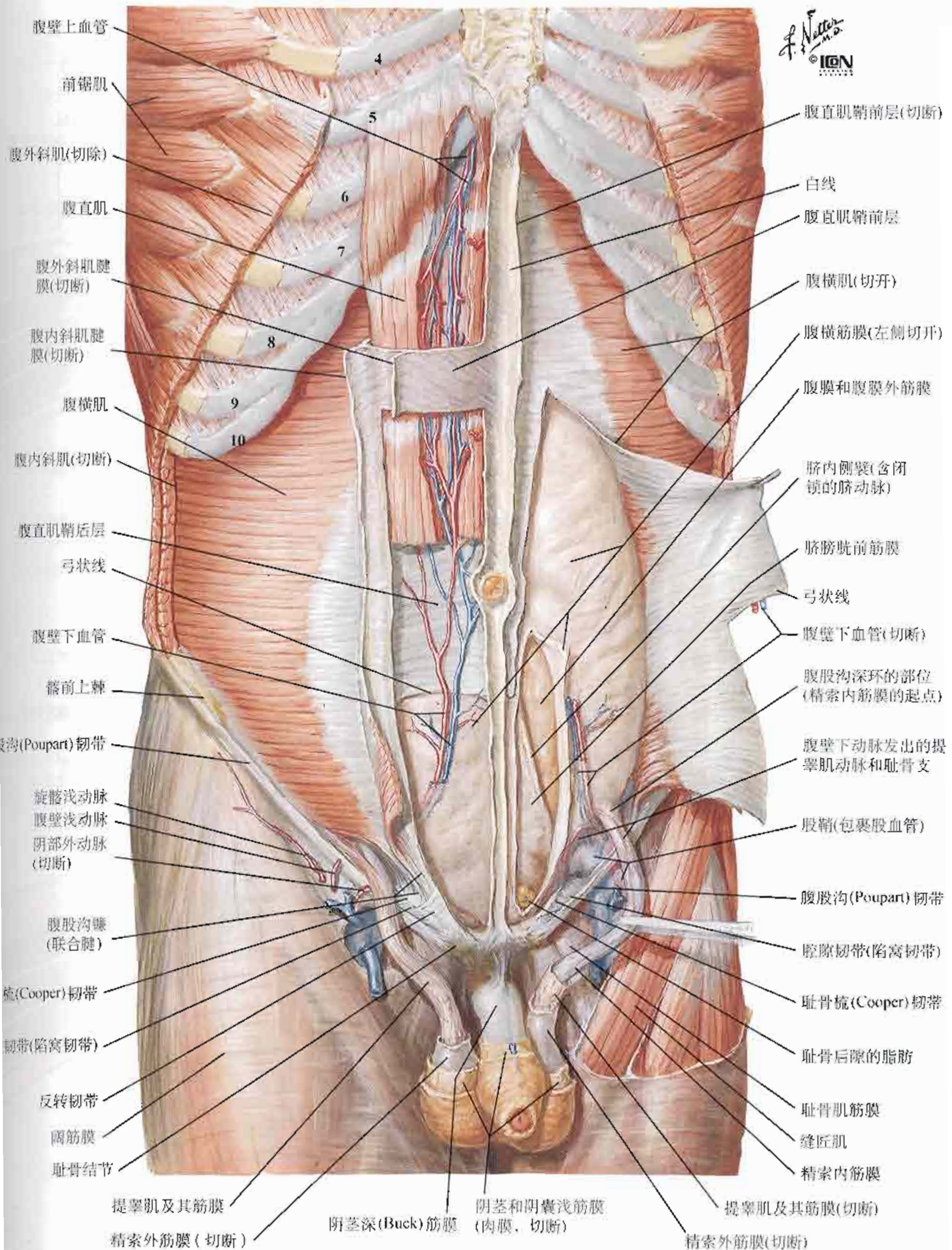
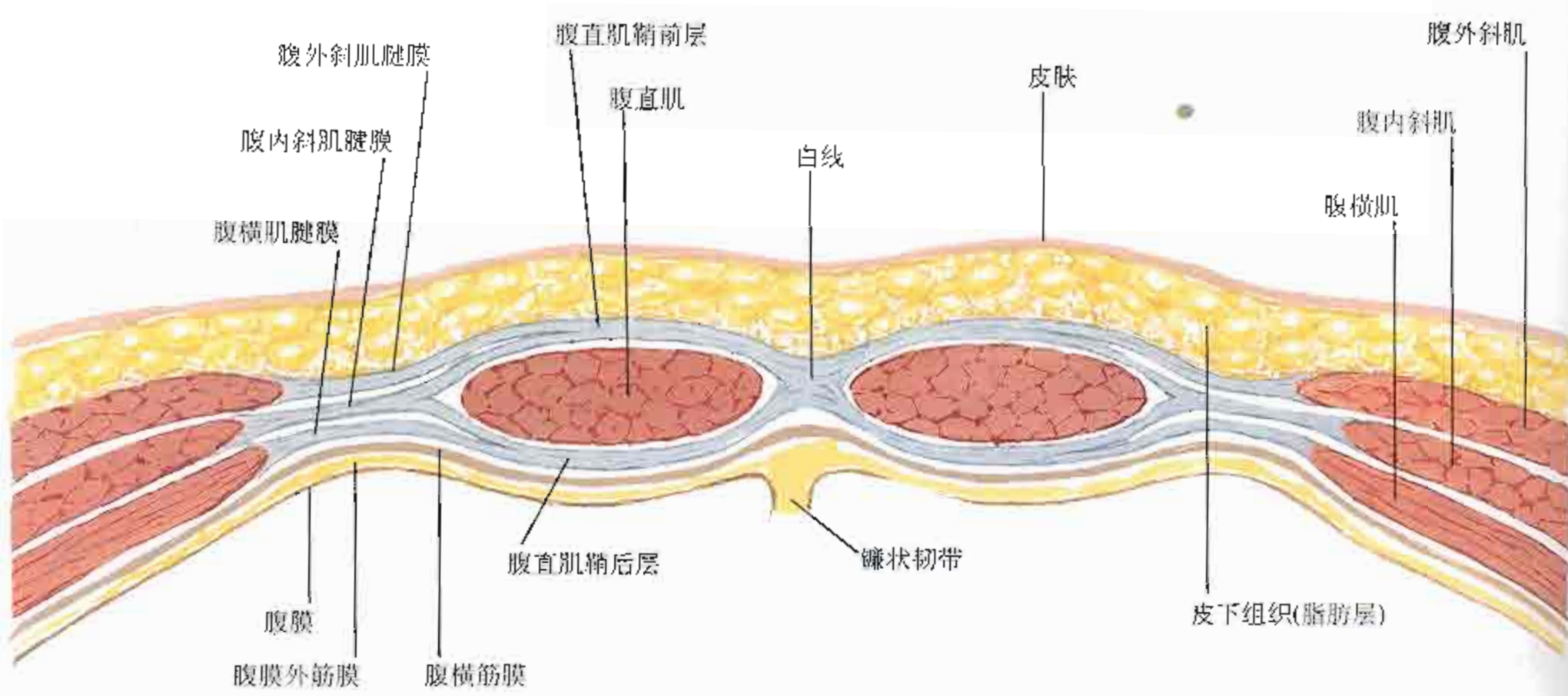


图243

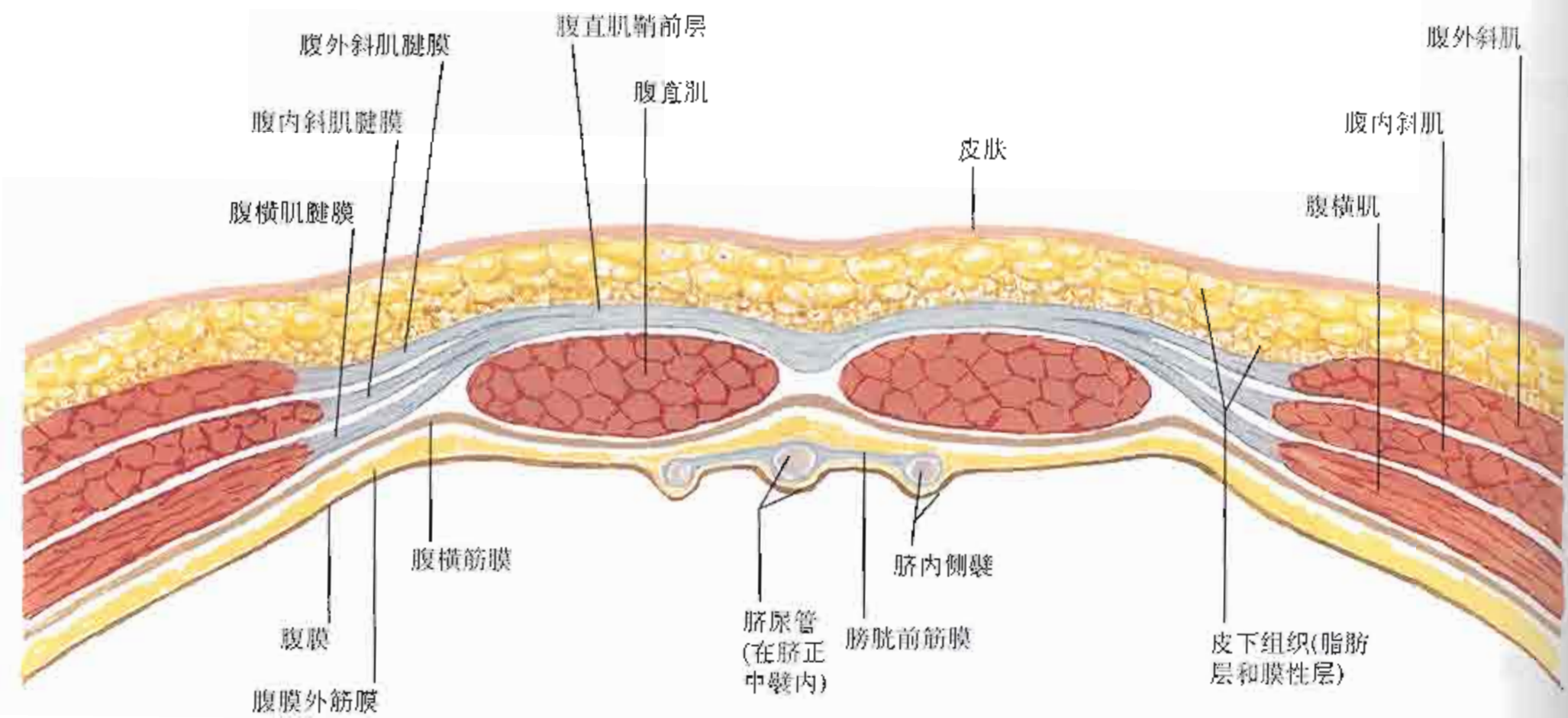
腹直肌鞘：横断面

弓状线以上的切面



腹内斜肌腱膜裂开，构成腹直肌鞘的前层和后层。腹外斜肌腱膜参与构成腹直肌鞘的前层；腹横肌腱膜参与构成腹直肌鞘的后层。腹直肌鞘的前、后层在中线交织，形成白线

弓状线以下的切面

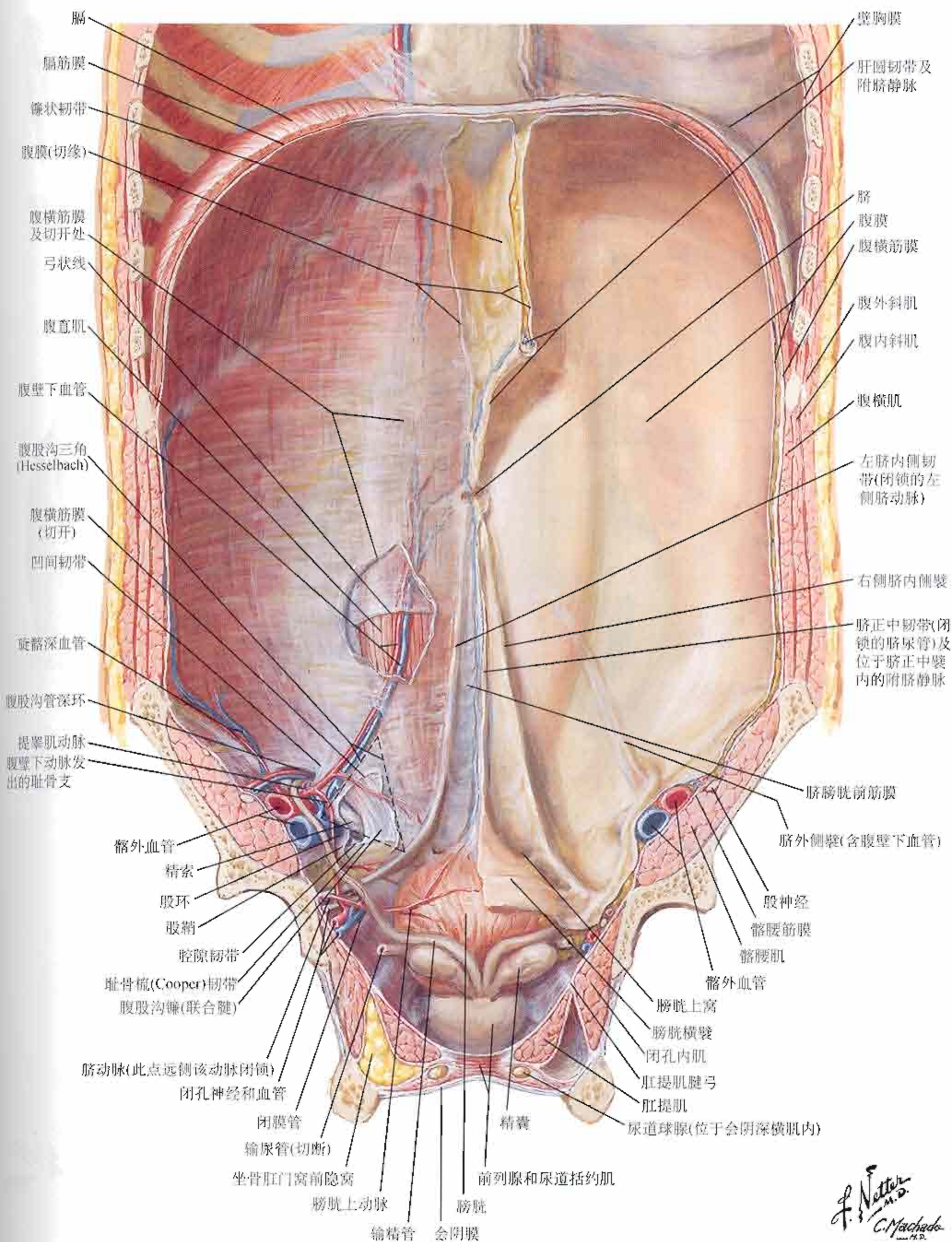


腹内斜肌腱膜在此平面没有裂开，而是全部位于腹直肌鞘前面，与腹外斜肌和腹横肌的腱膜融合在一起。所以，在弓状线以下腹直肌鞘后层消失，腹直肌与腹横筋膜相贴

图244

腹部

关于脐的血管参见图 225



L. Natter
M.D.
C. Machado
M.D.
ION
ION
ION

图245

参见图 167、170、172、173、250

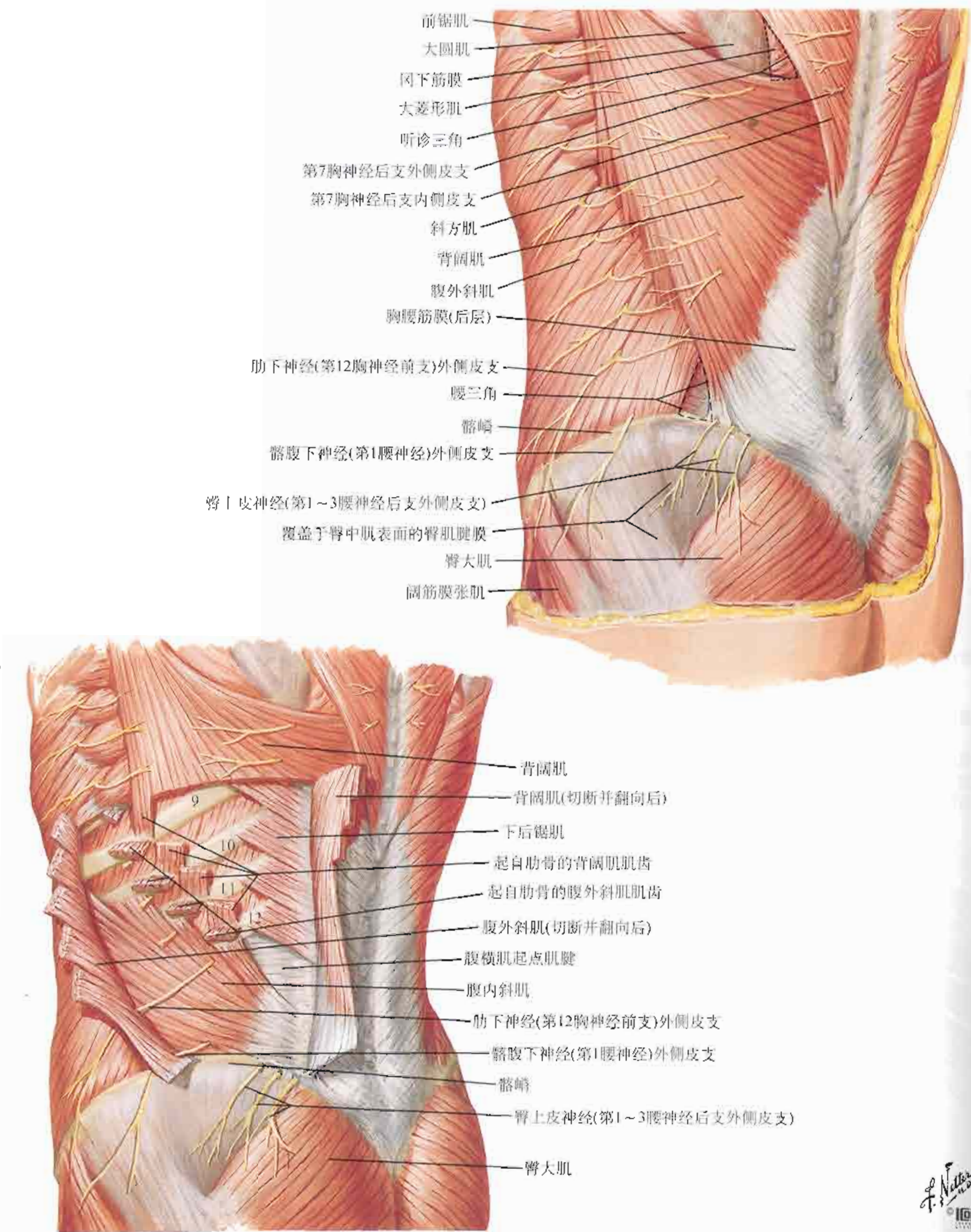
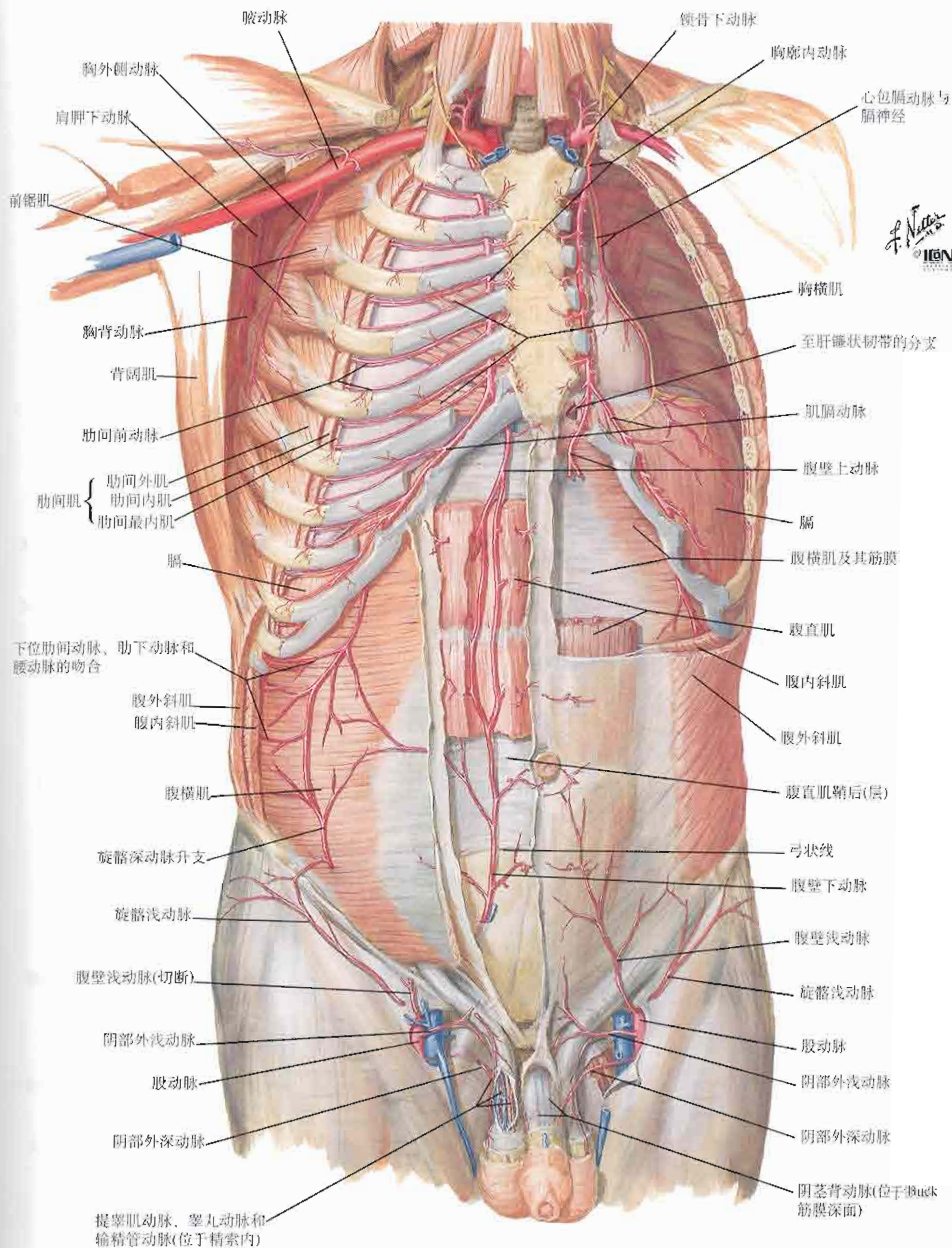


图246



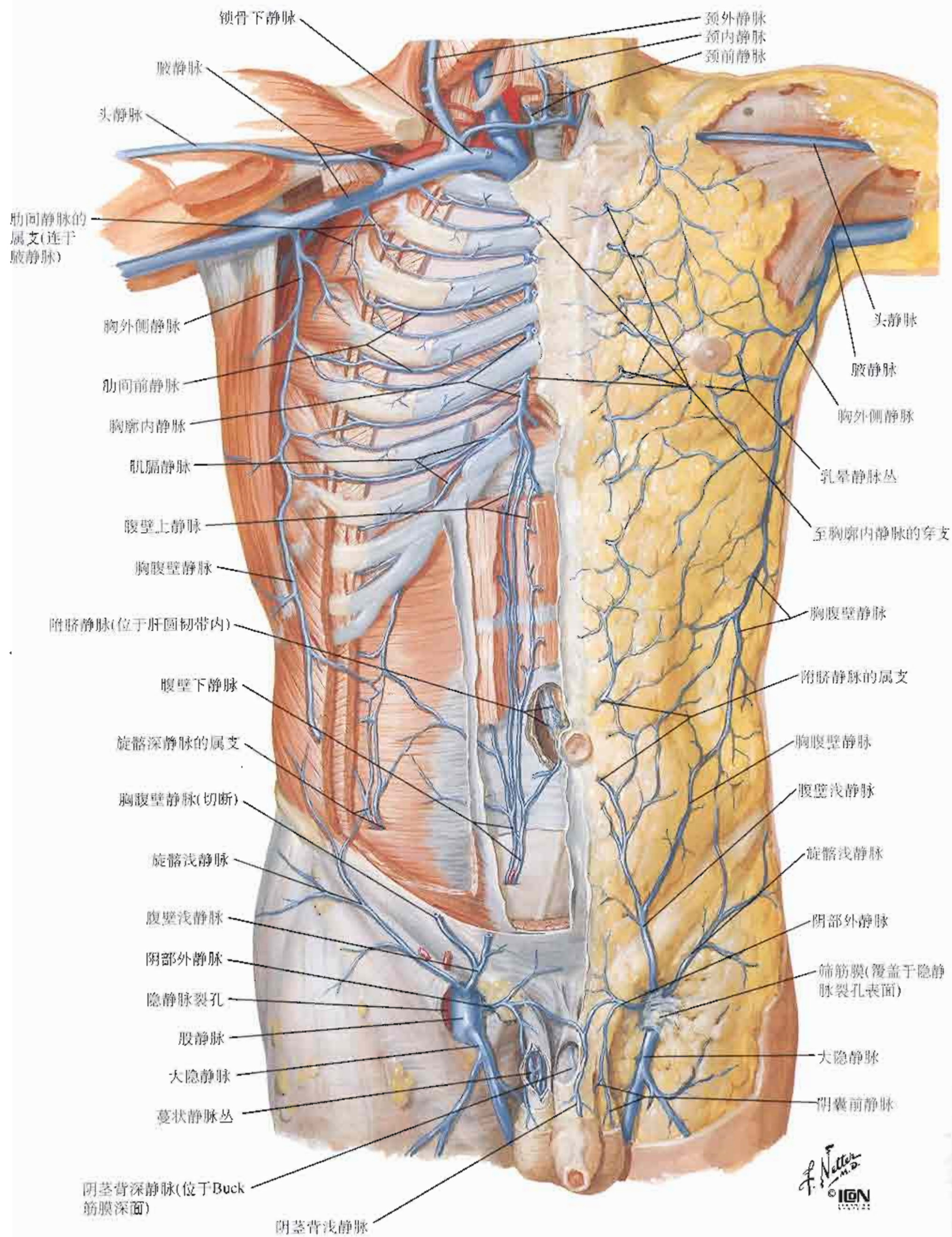
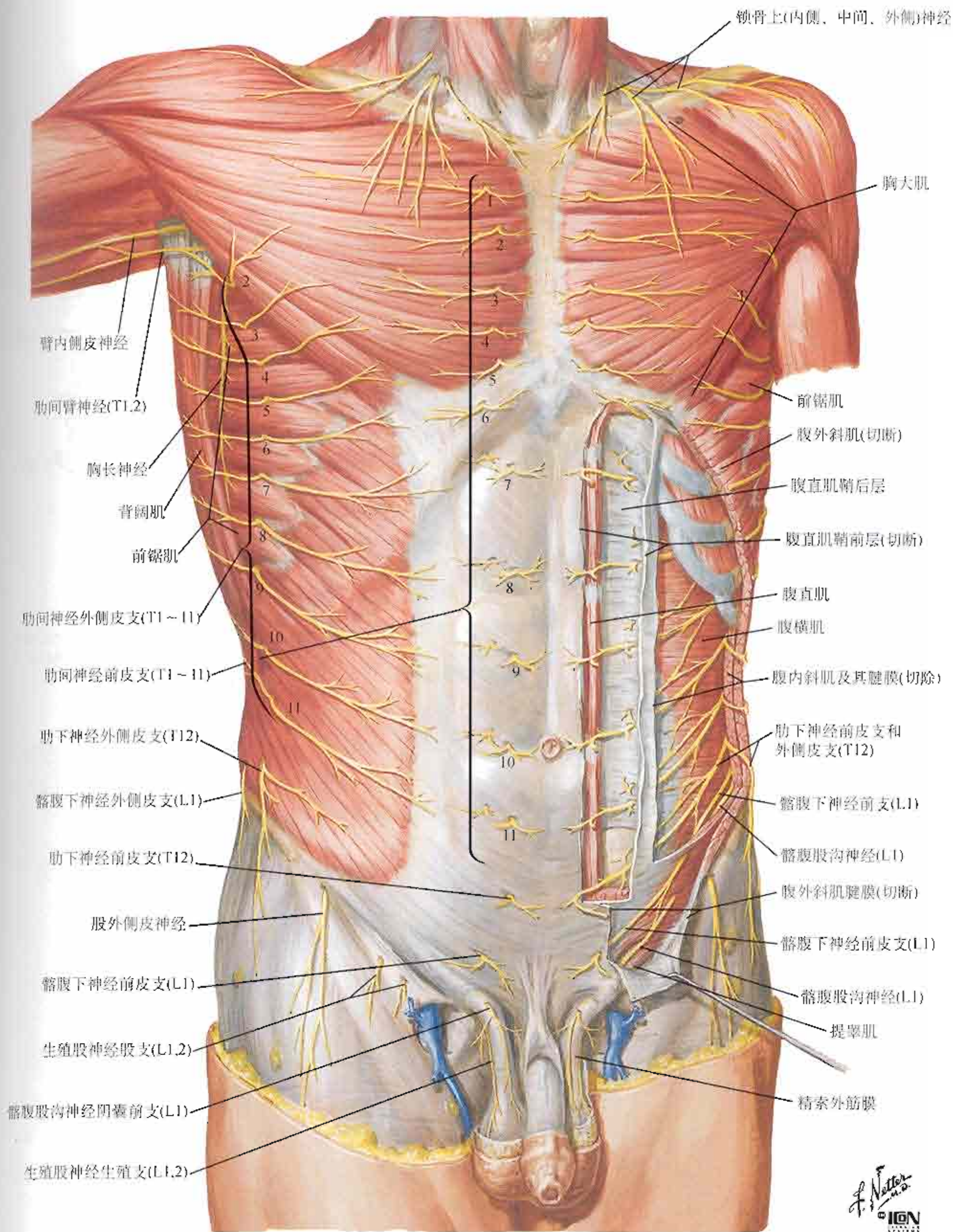


图248



F. Netter
M.D.
© 1996

图249

胸腹壁的神经

参见图 173、187

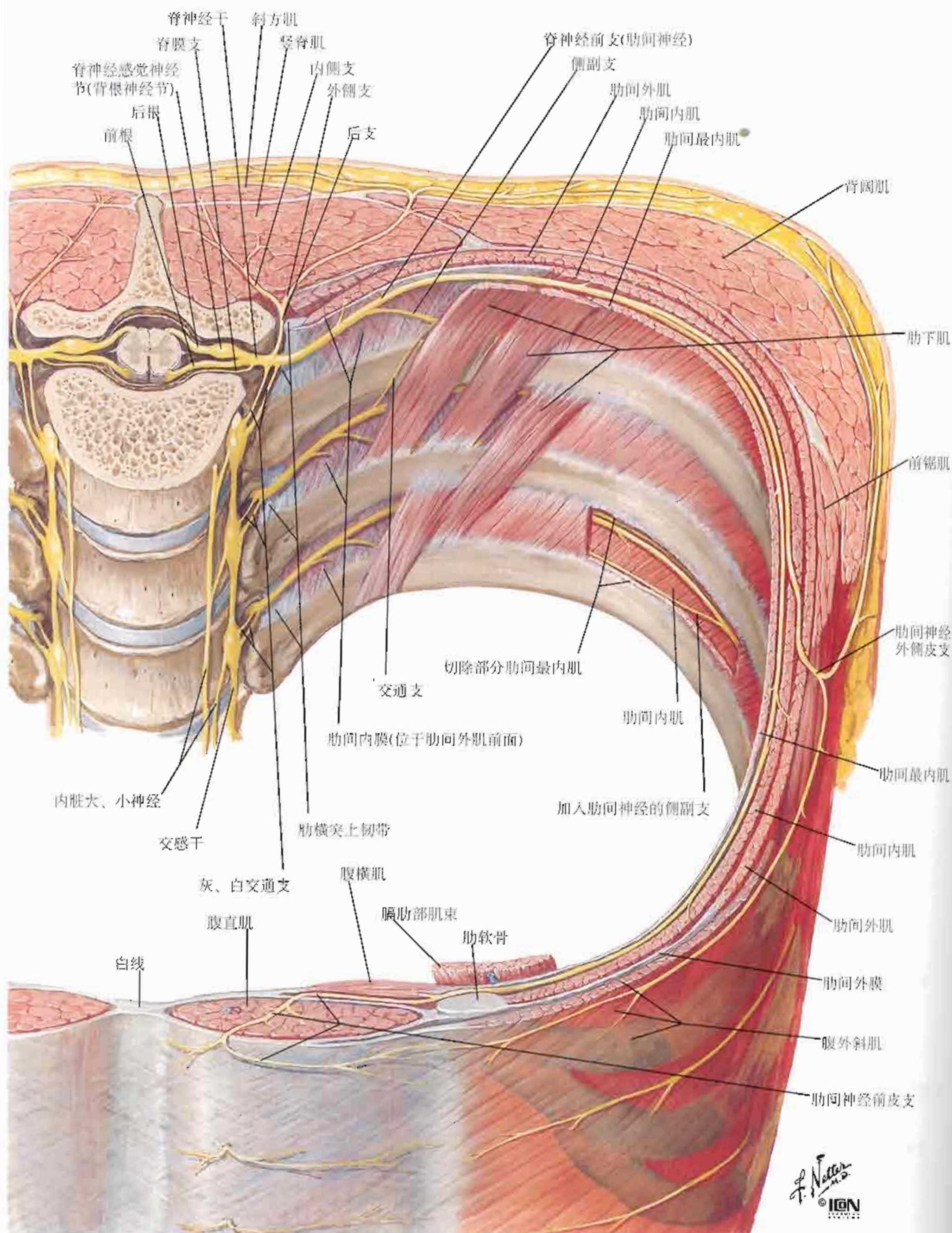
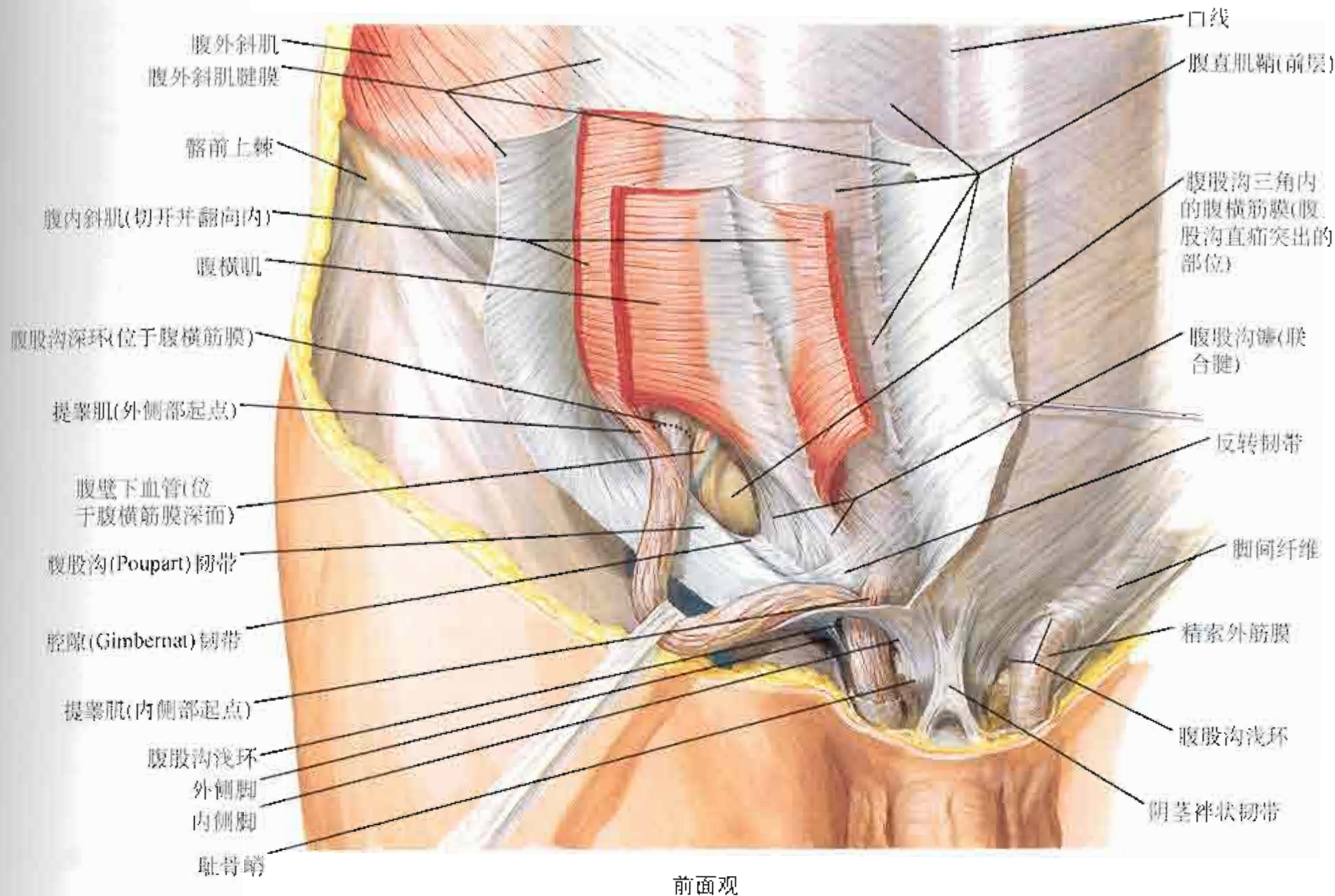
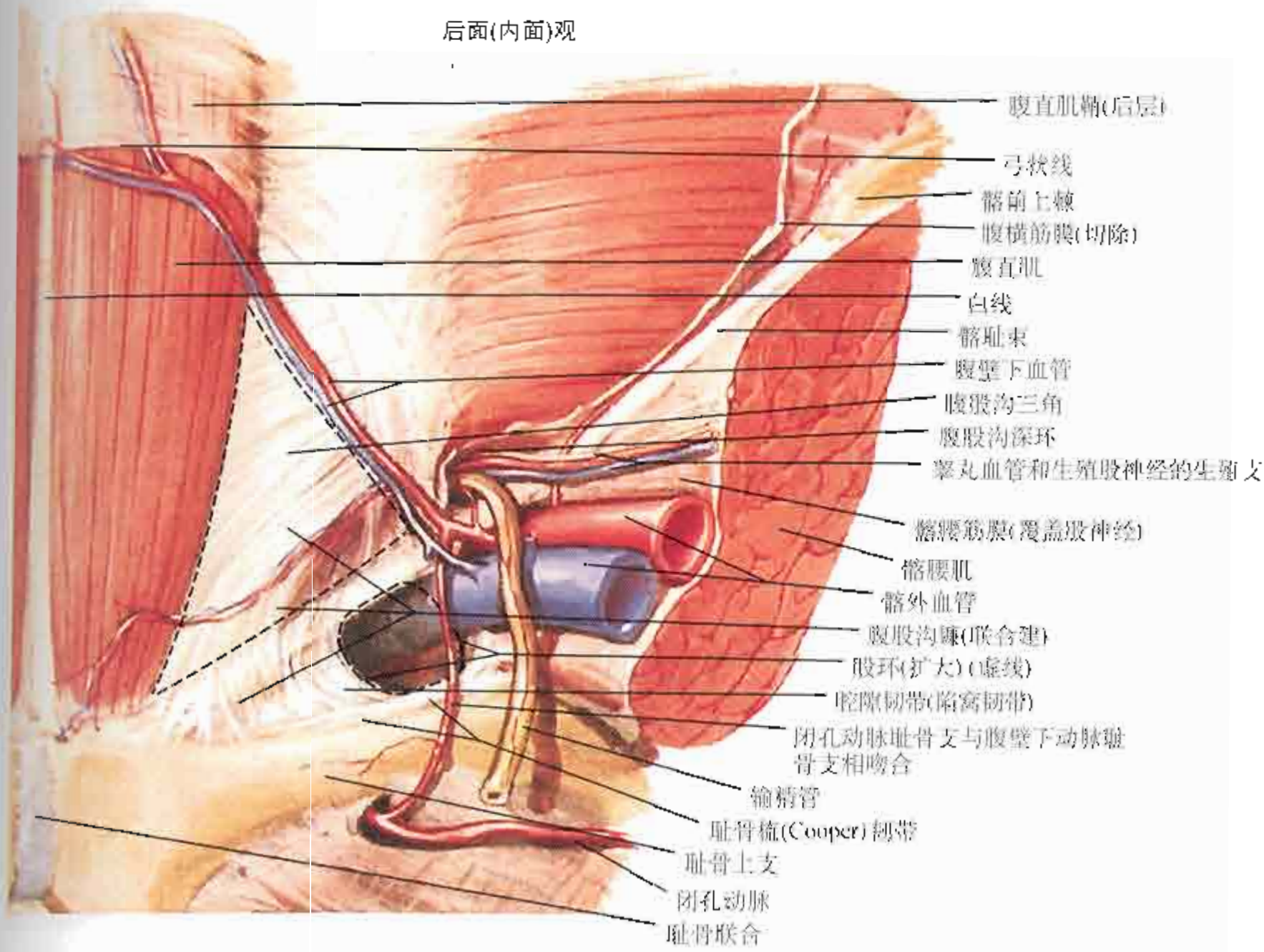


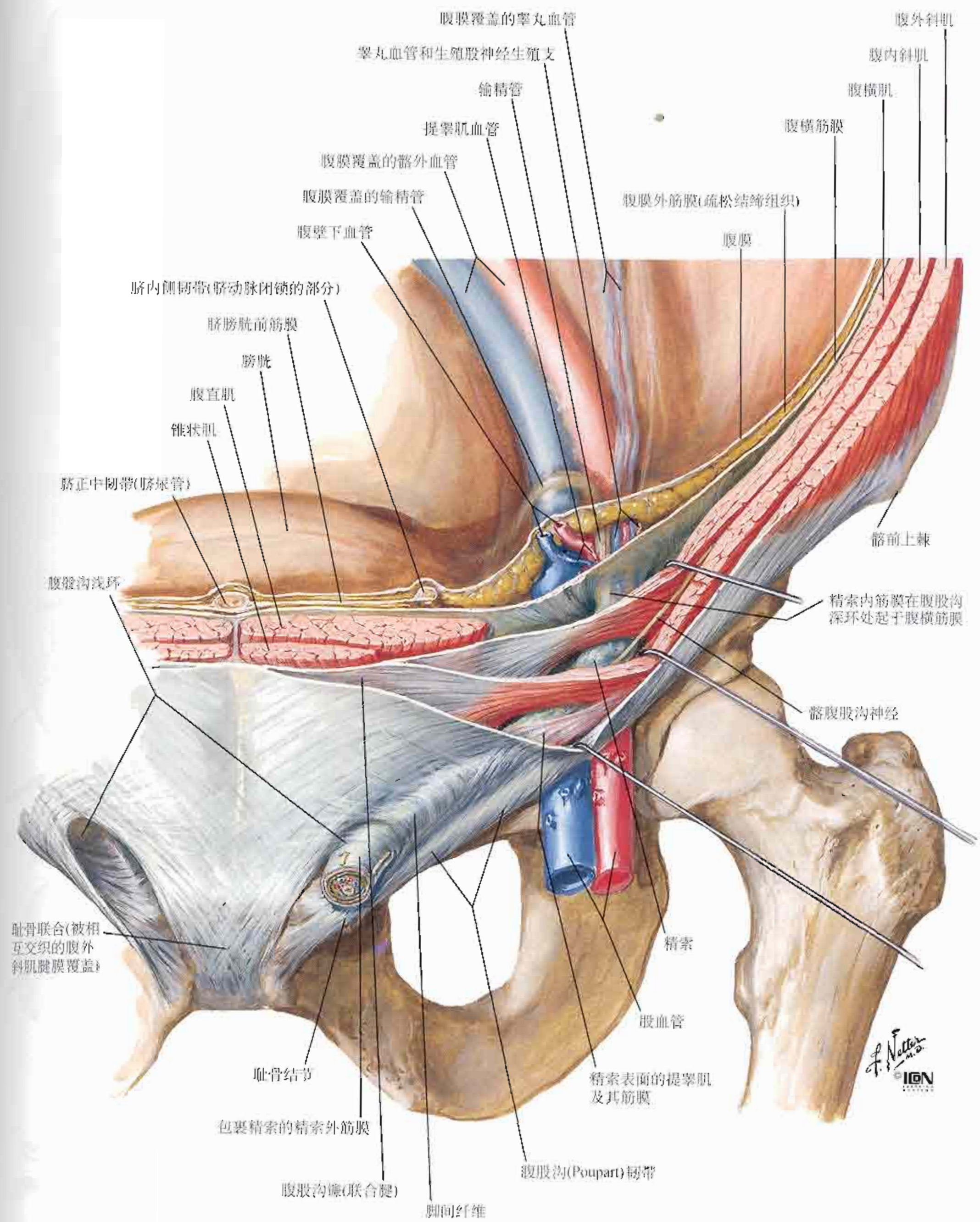
图250



后面(内面)观



F. Netter M.D.
ION



腹股沟斜疝

与图253对照

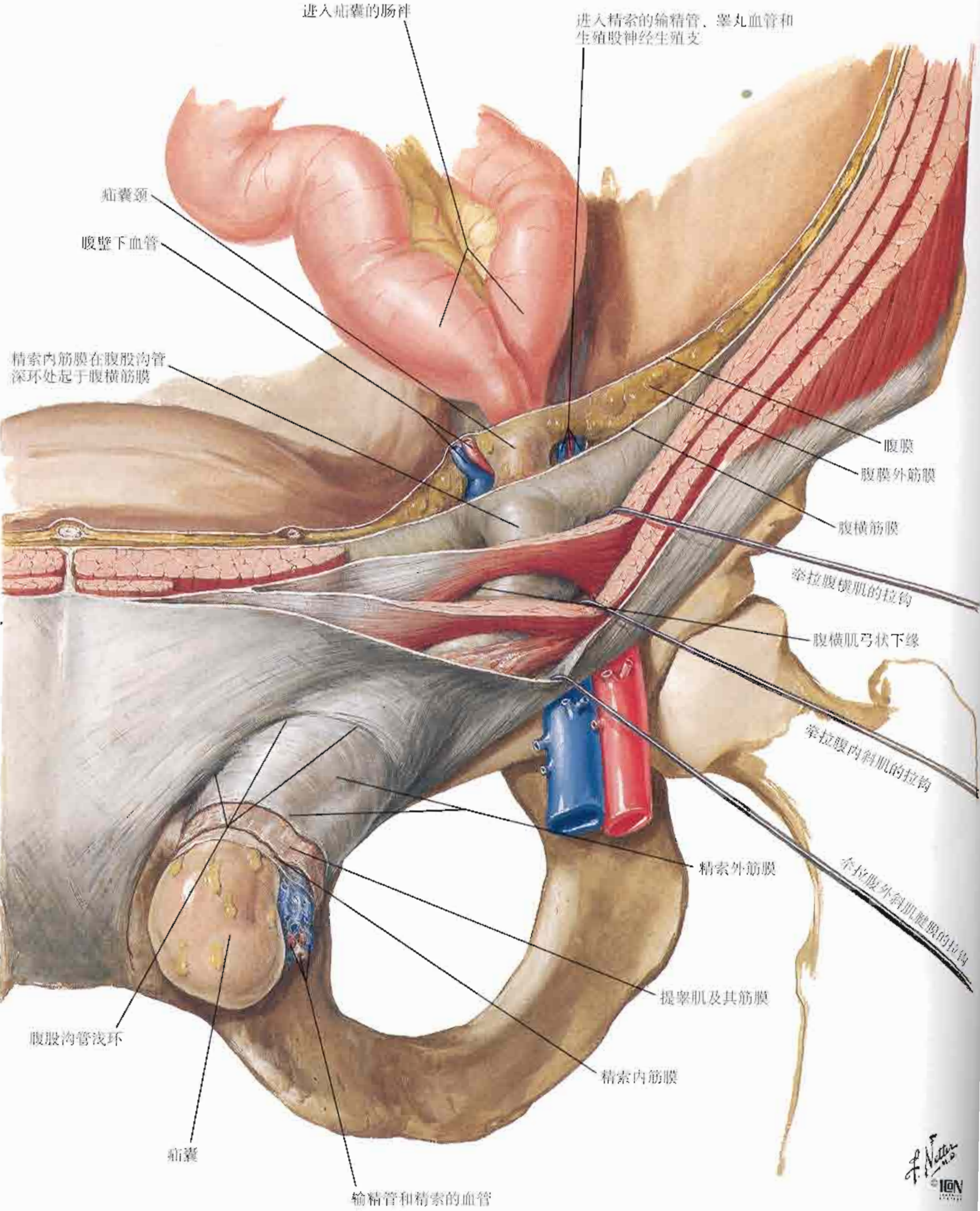
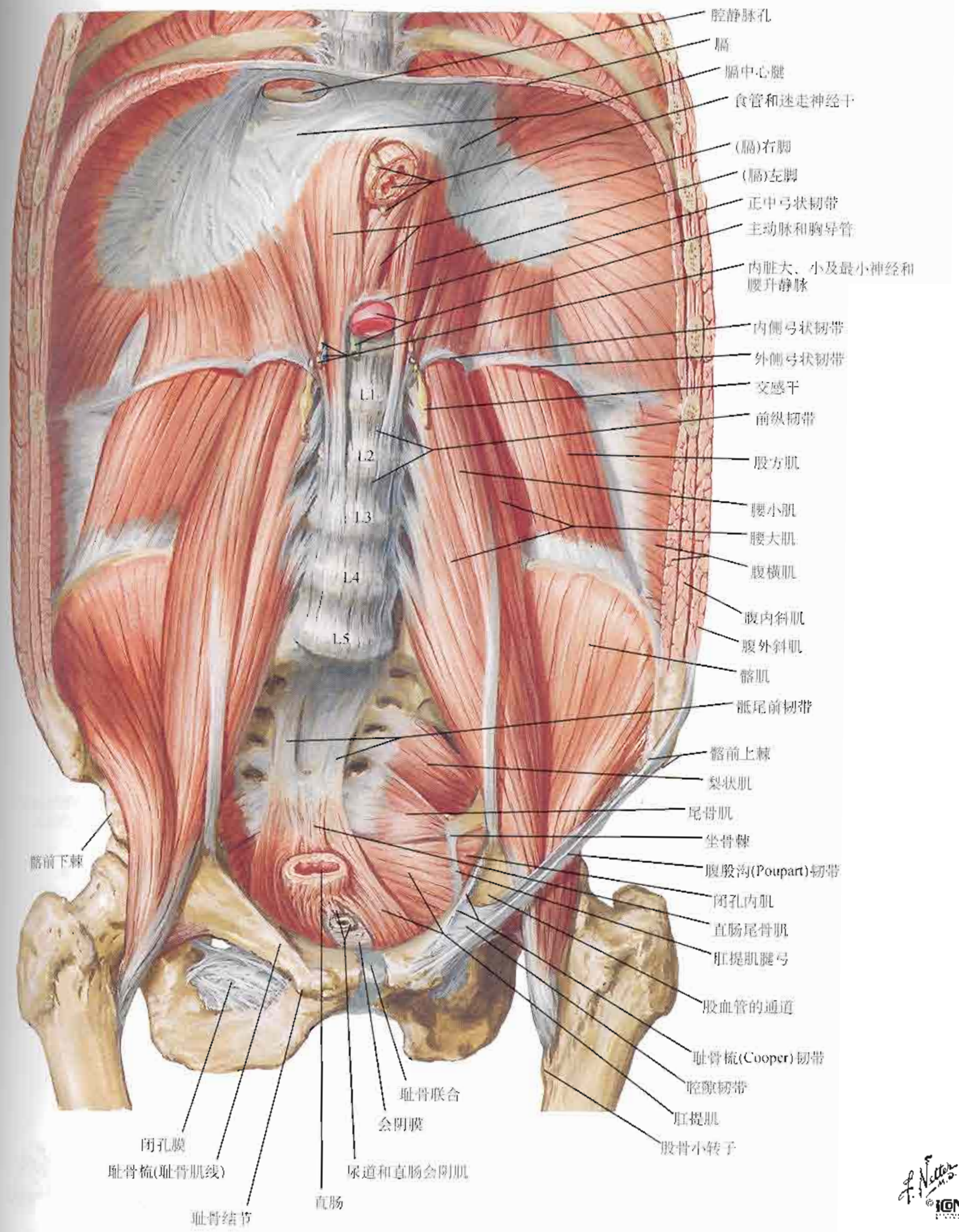


图254

腹部

膈参见图189



F. Netter M.D. IGM

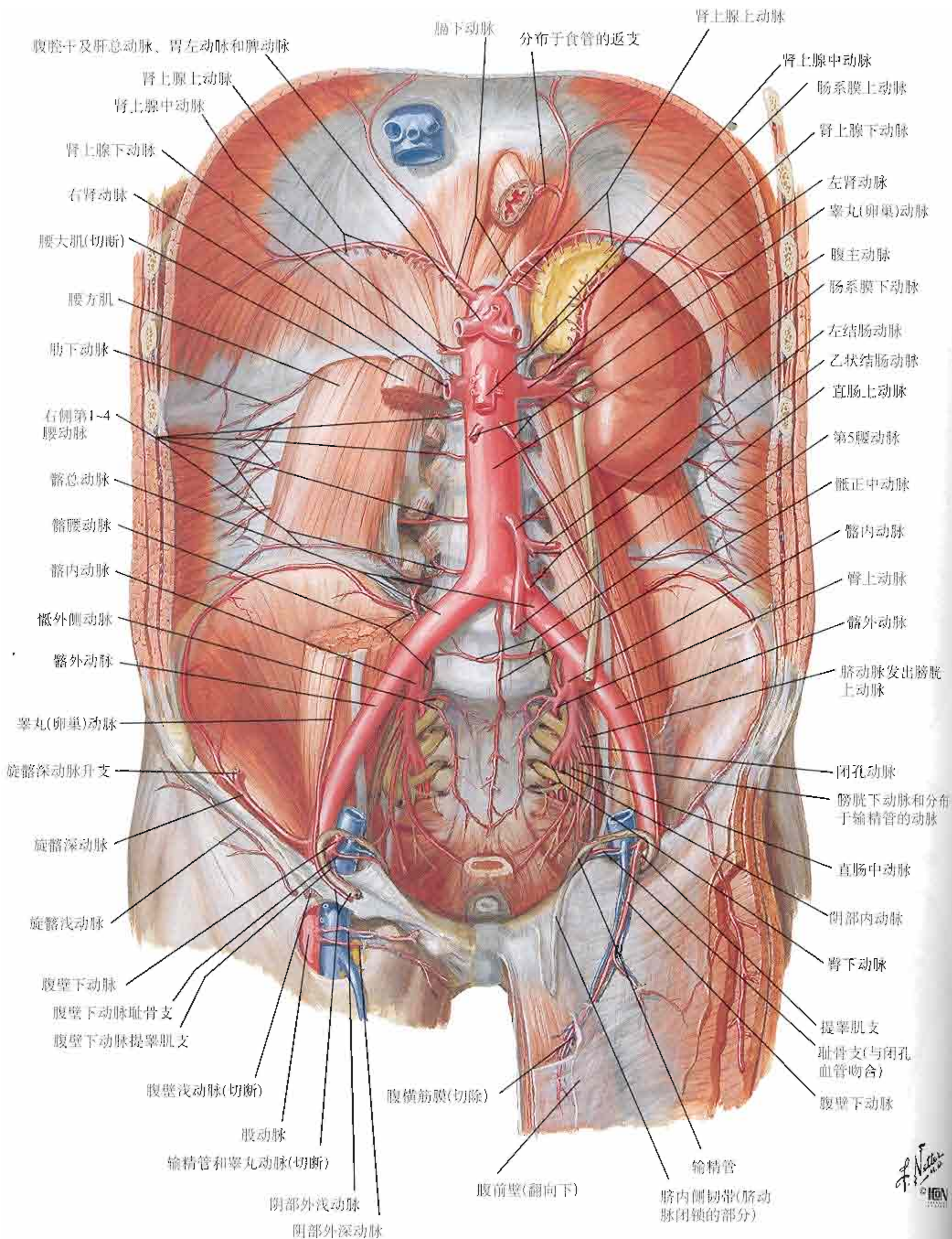


图256

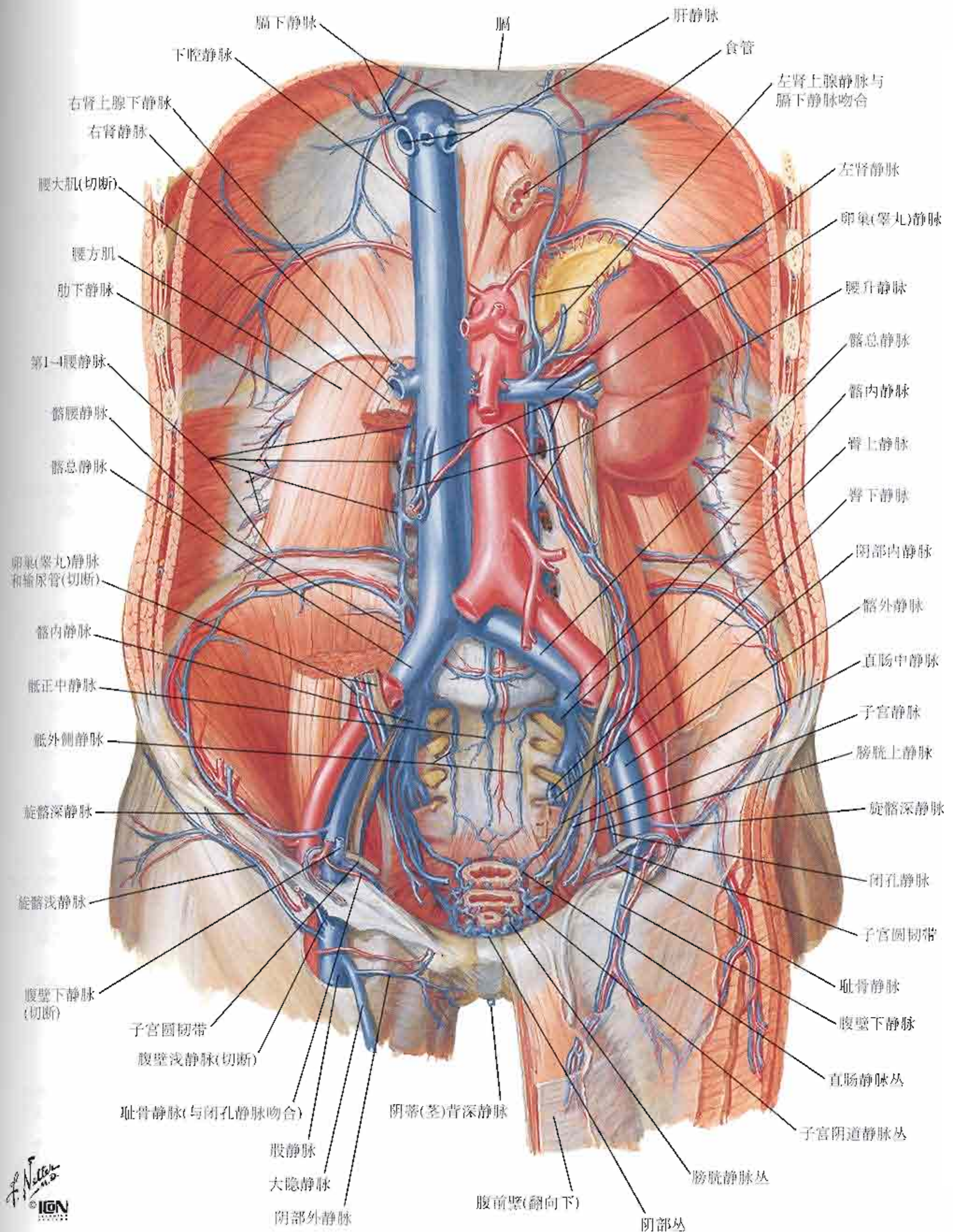


图257

参见图387

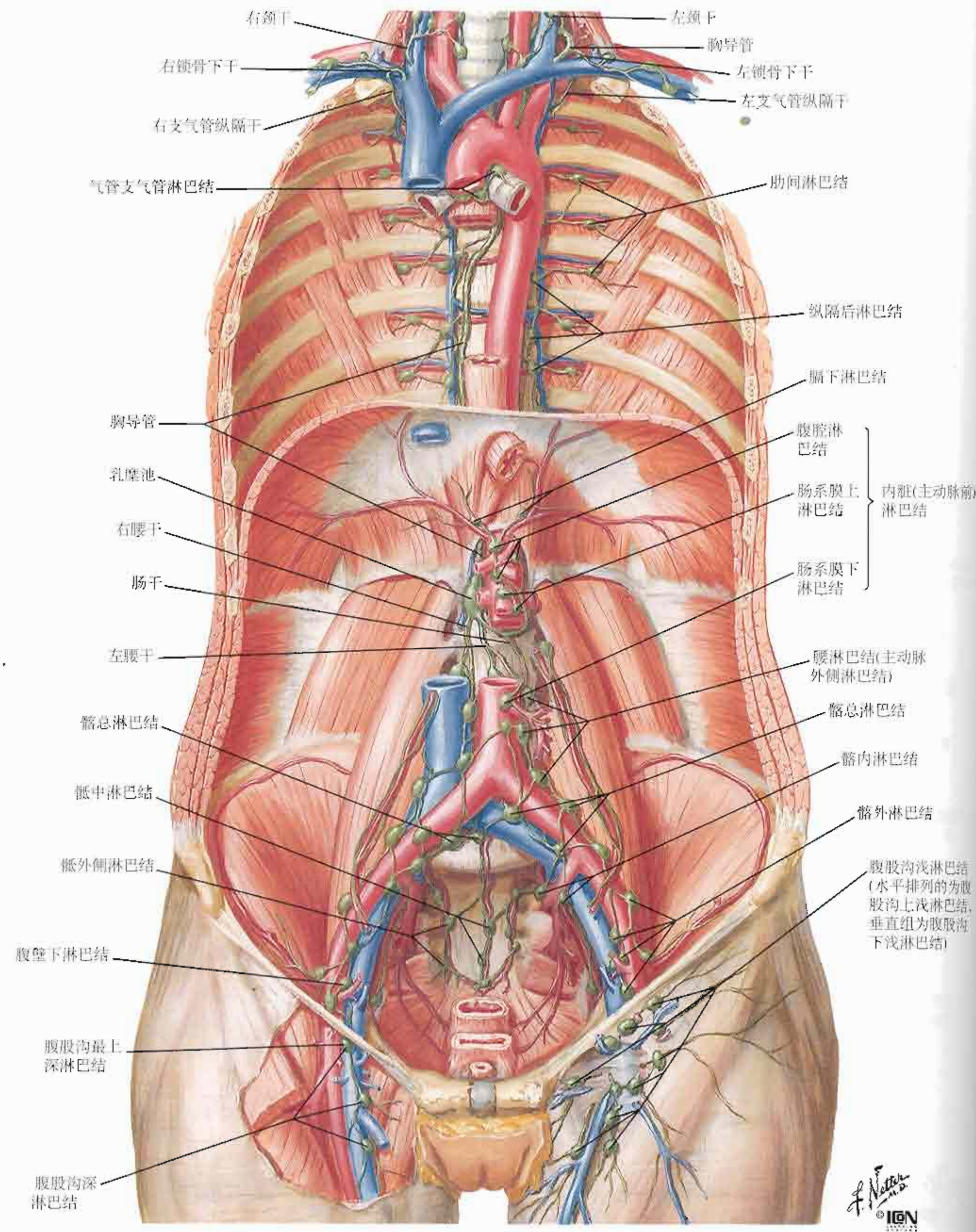
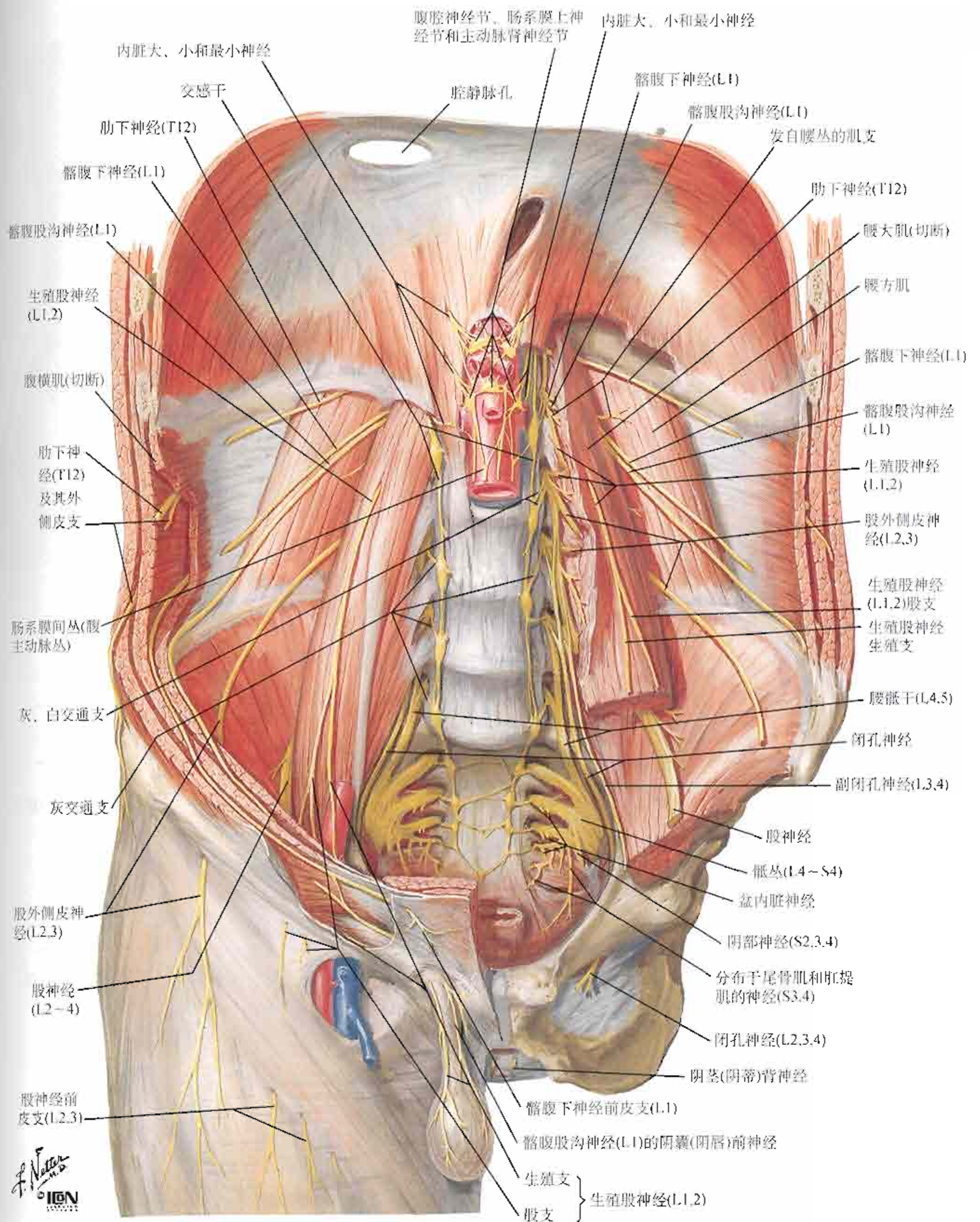


图258



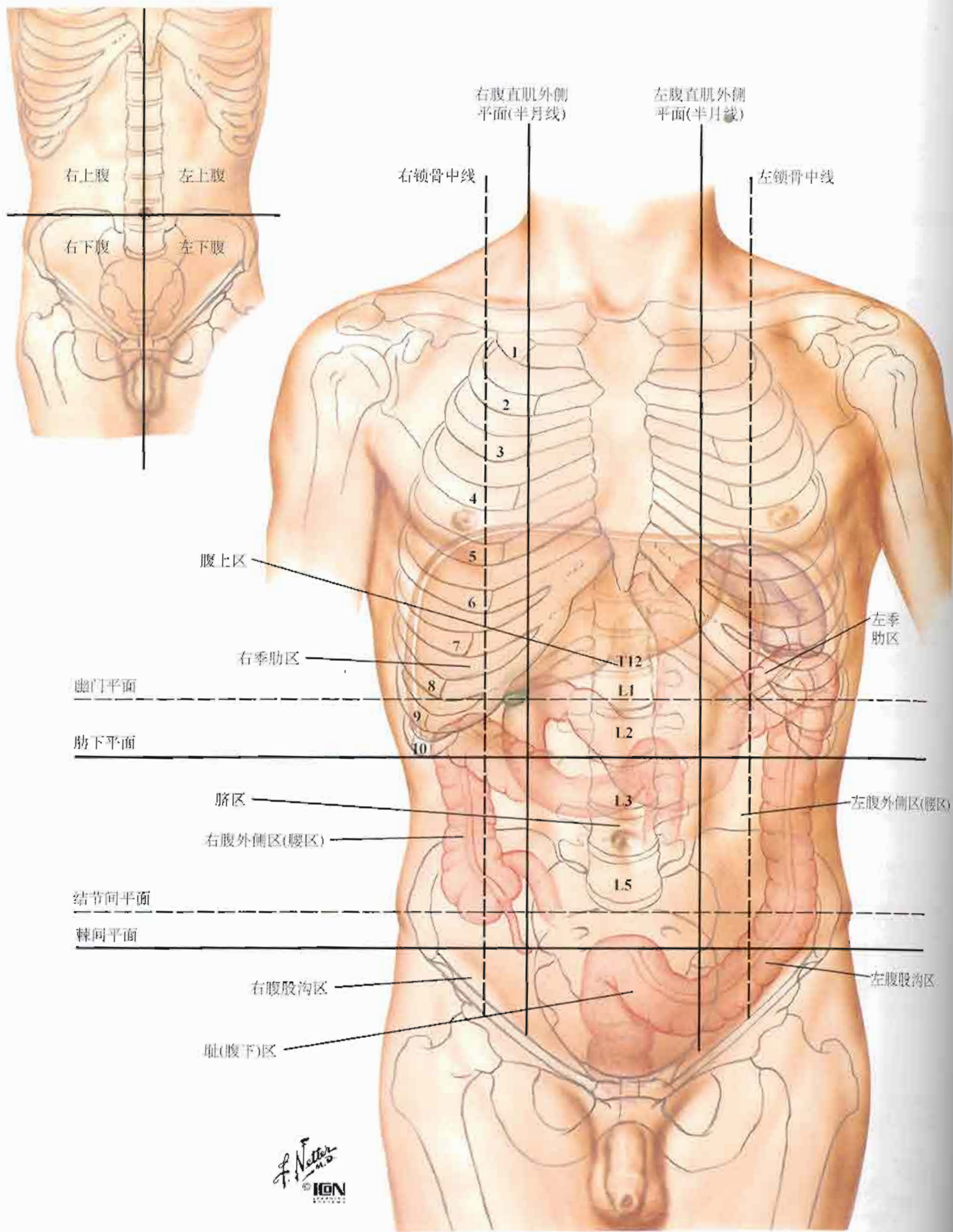
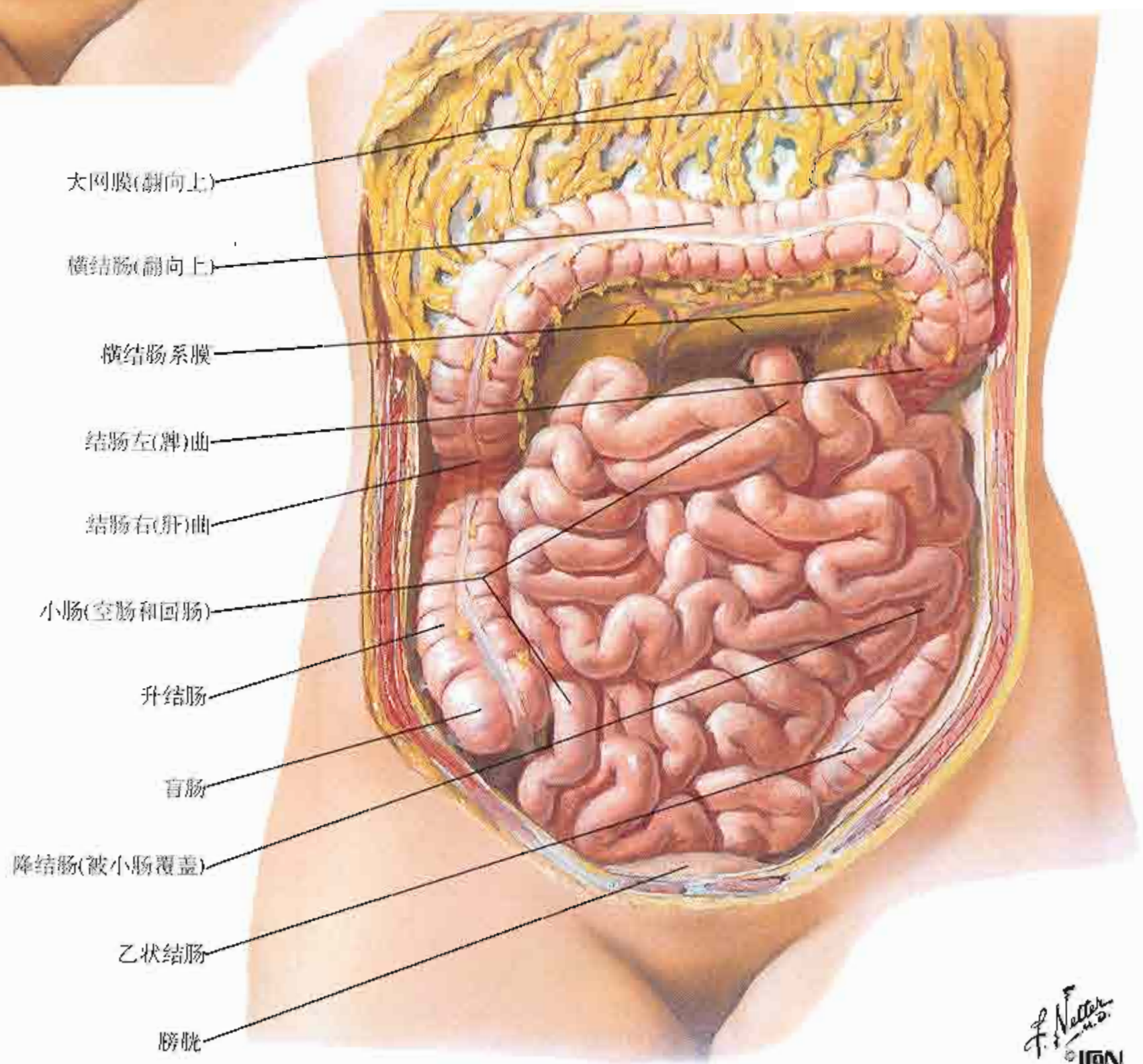
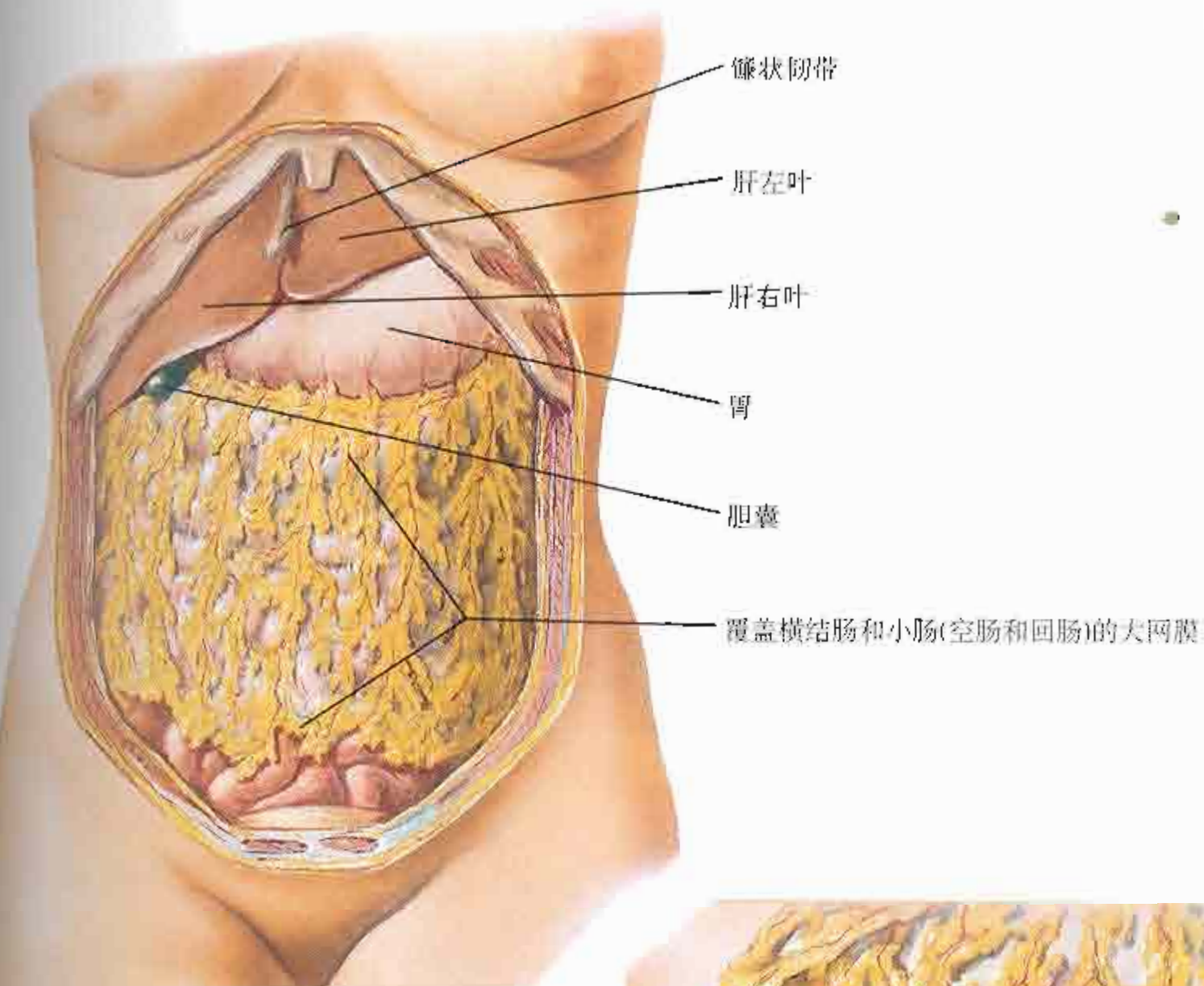


图260



F. Netter M.D.
© IGV

图261

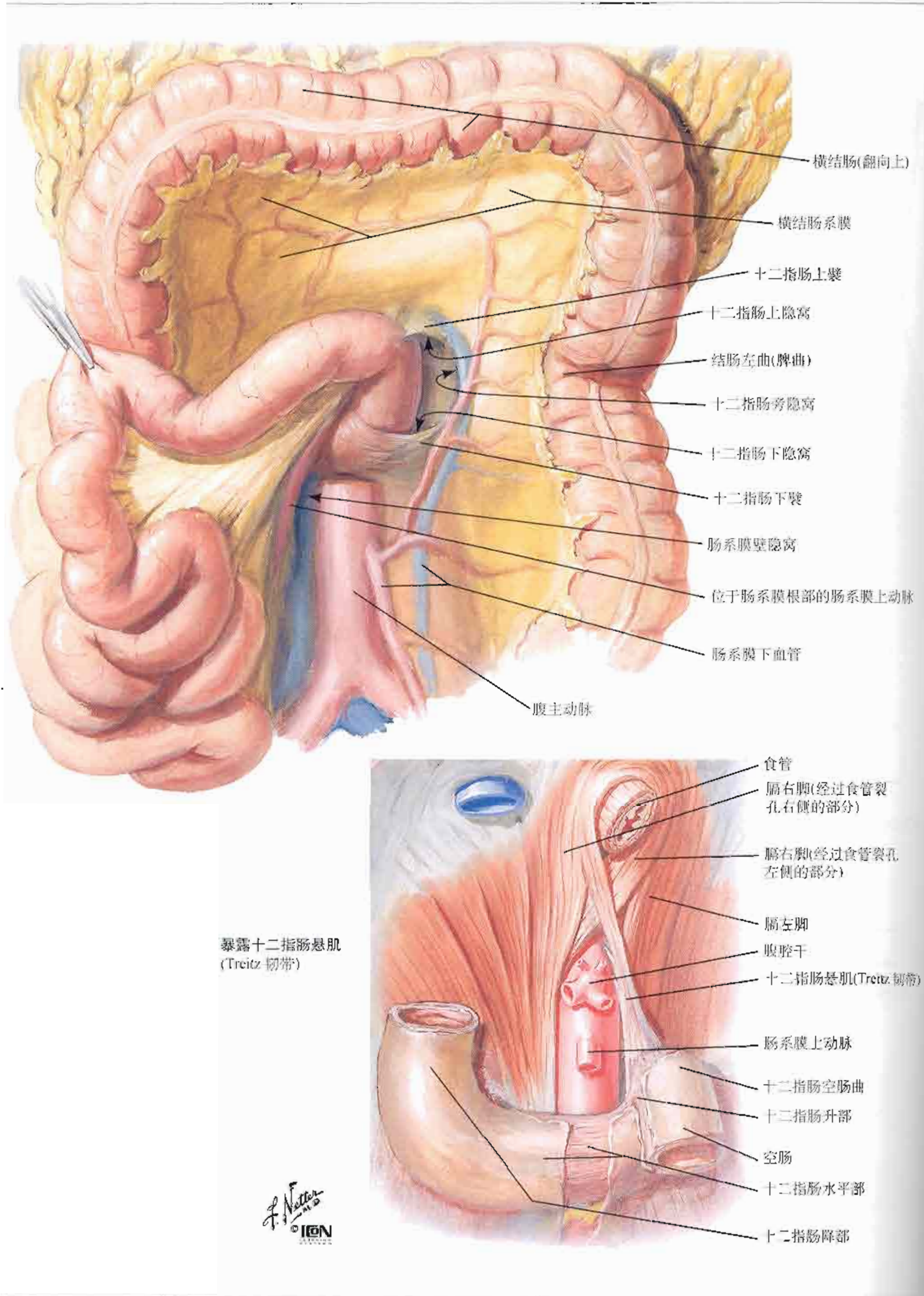


图262



运动科学网站



运动科学网站



运动科学网站



运动科学网站



运动科学网站



运动科学网站



运动科学网站



运动科学网站



运动科学网站



运动科学网站



运动科学网站



运动科学网站



运动科学网站



运动科学网站

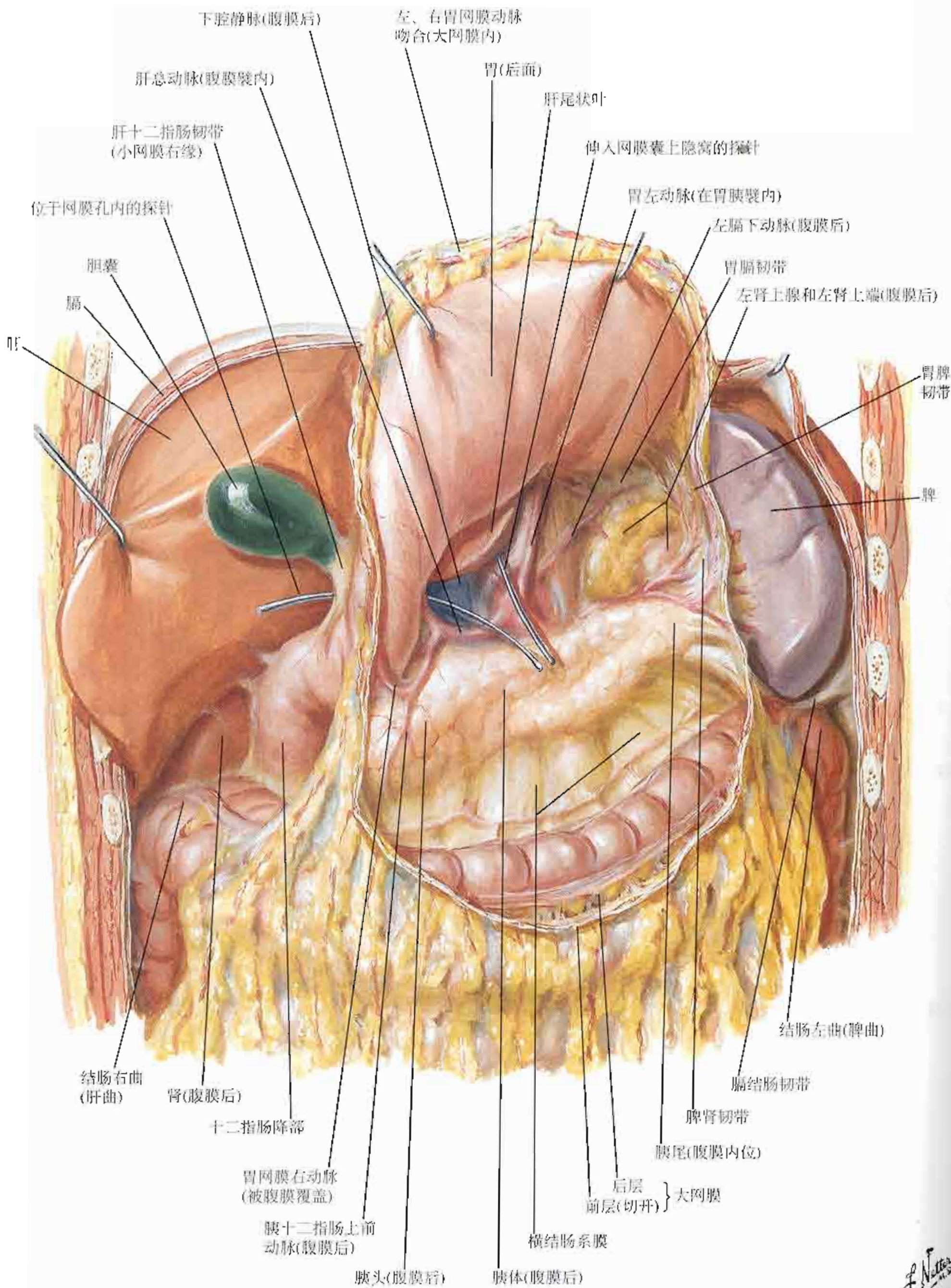


图264



运动科学网站



运动科学网站



运动科学网站



运动科学网站



运动科学网站



运动科学网站



运动科学网站



运动科学网站



运动科学网站



运动科学网站



运动科学网站



运动科学网站



运动科学网站



运动科学网站

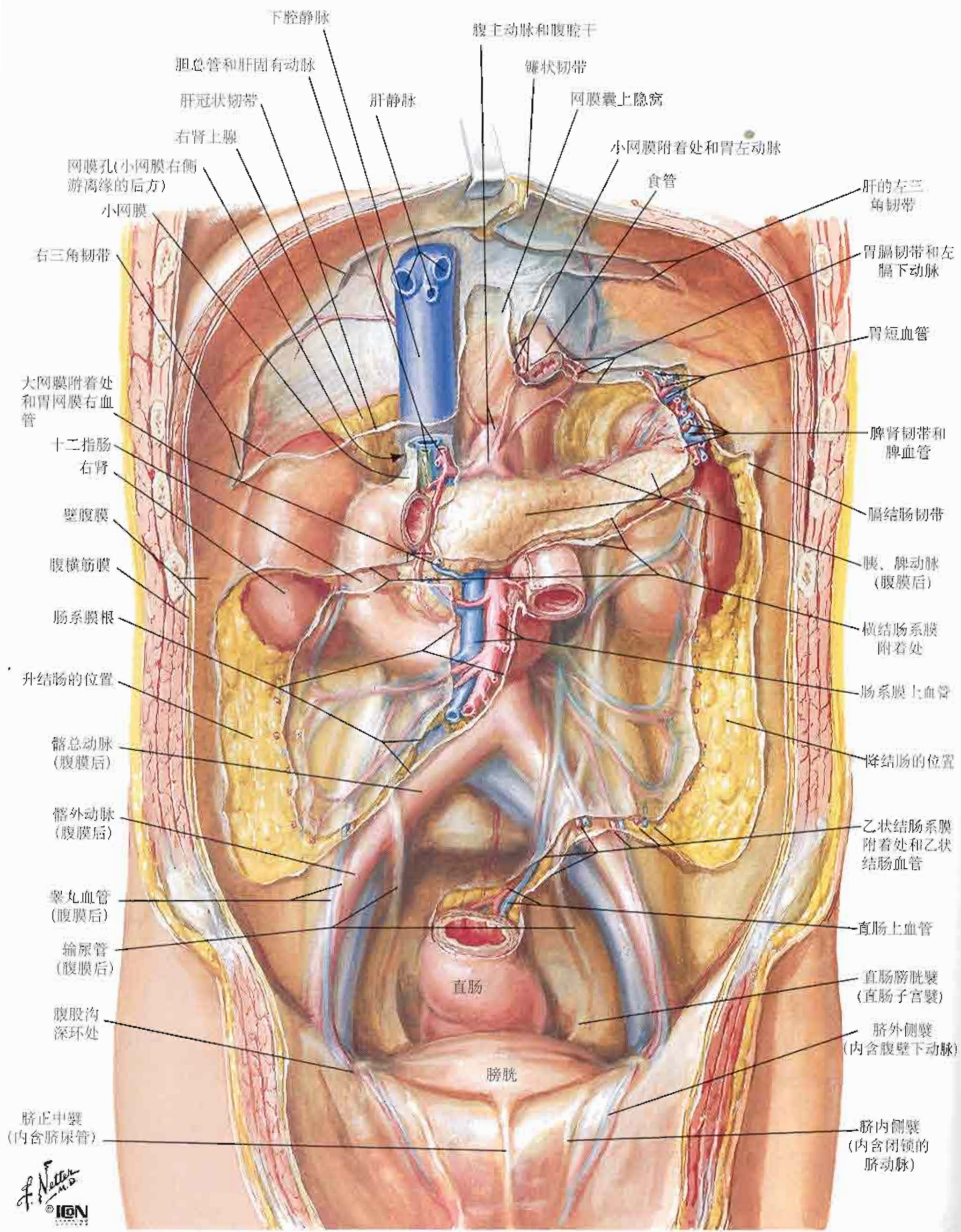
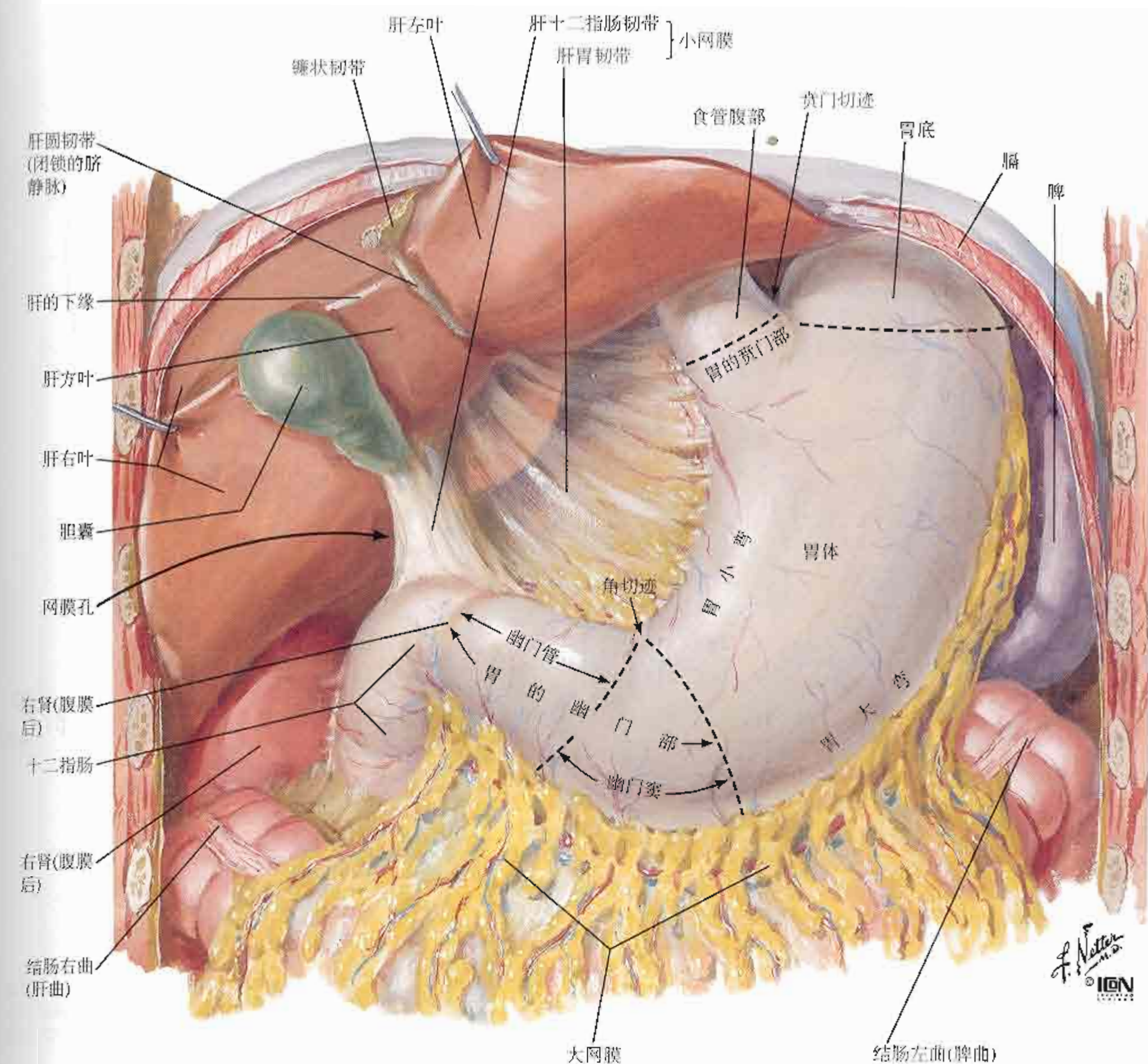
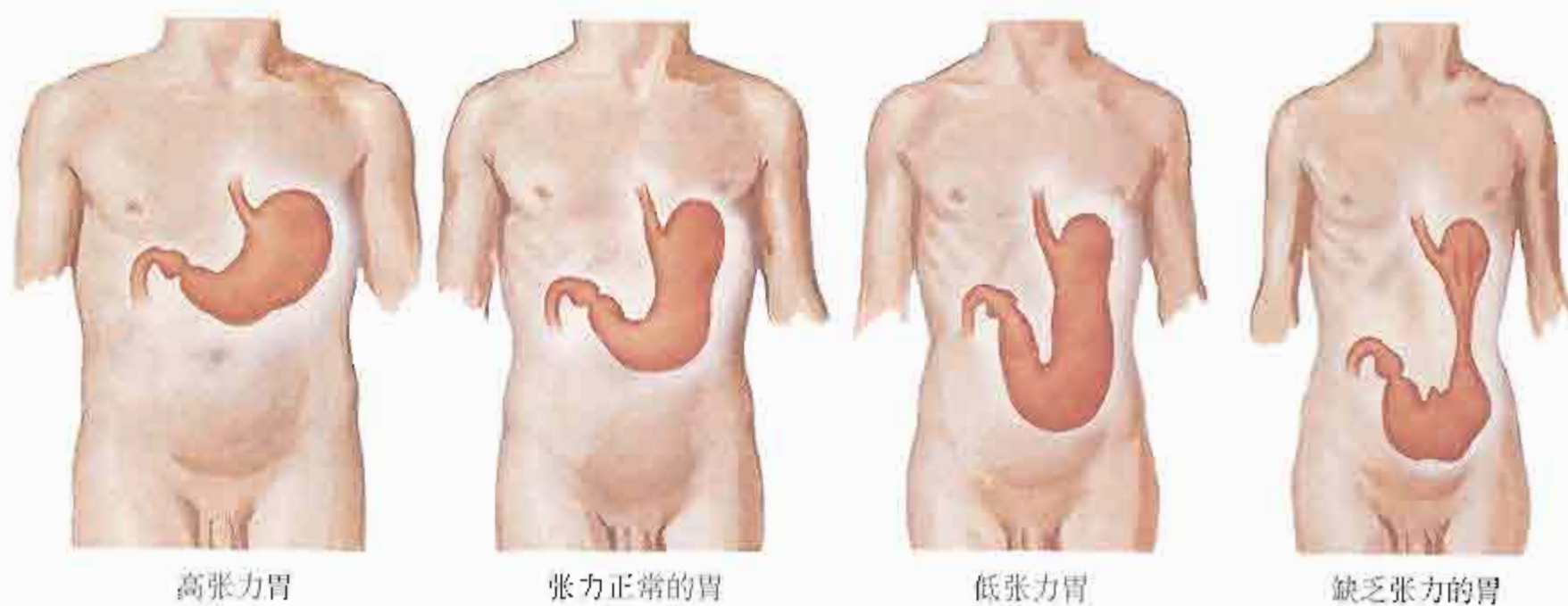

图266



胃的位置和形态随体型变化



参见图232

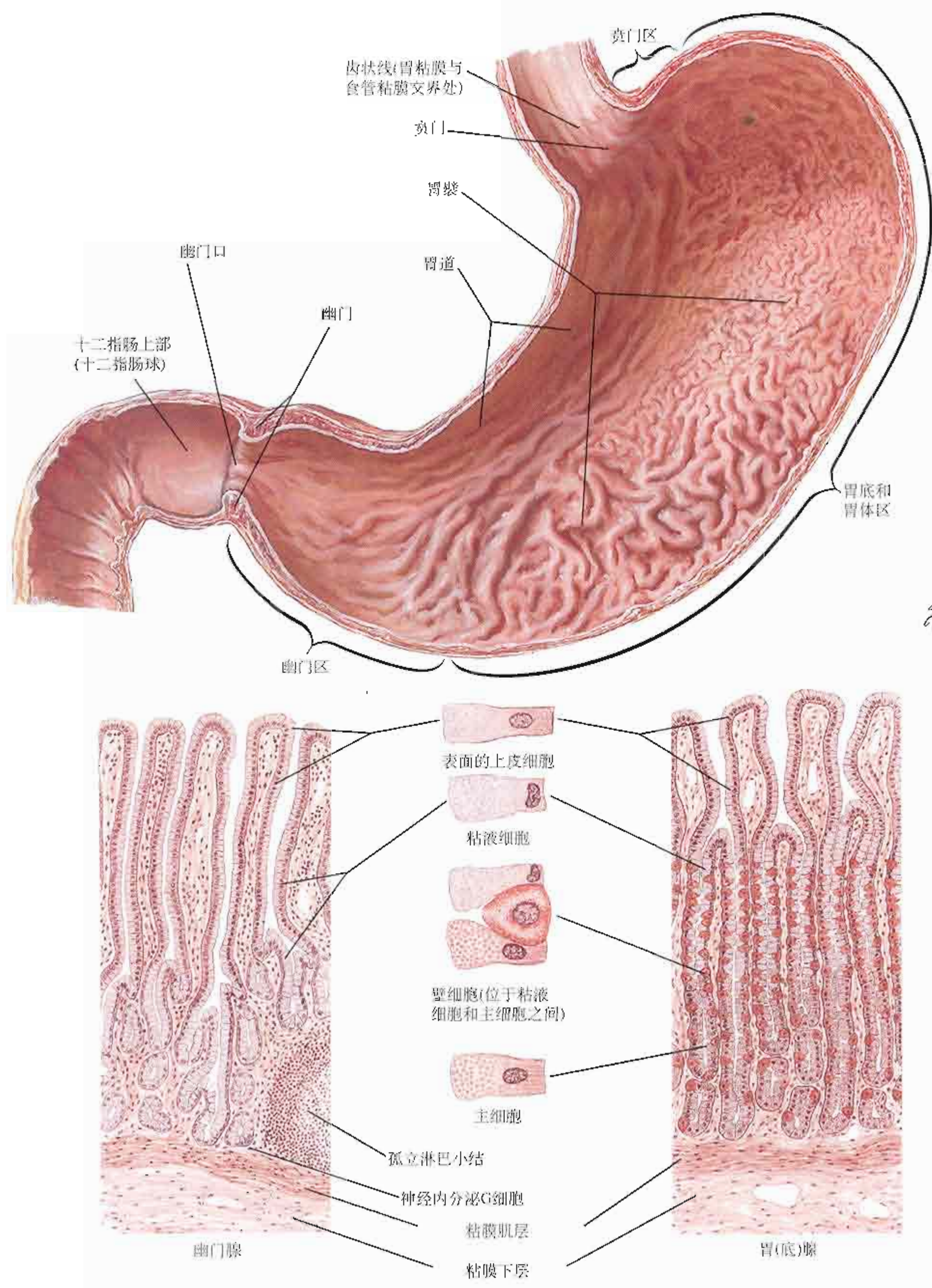
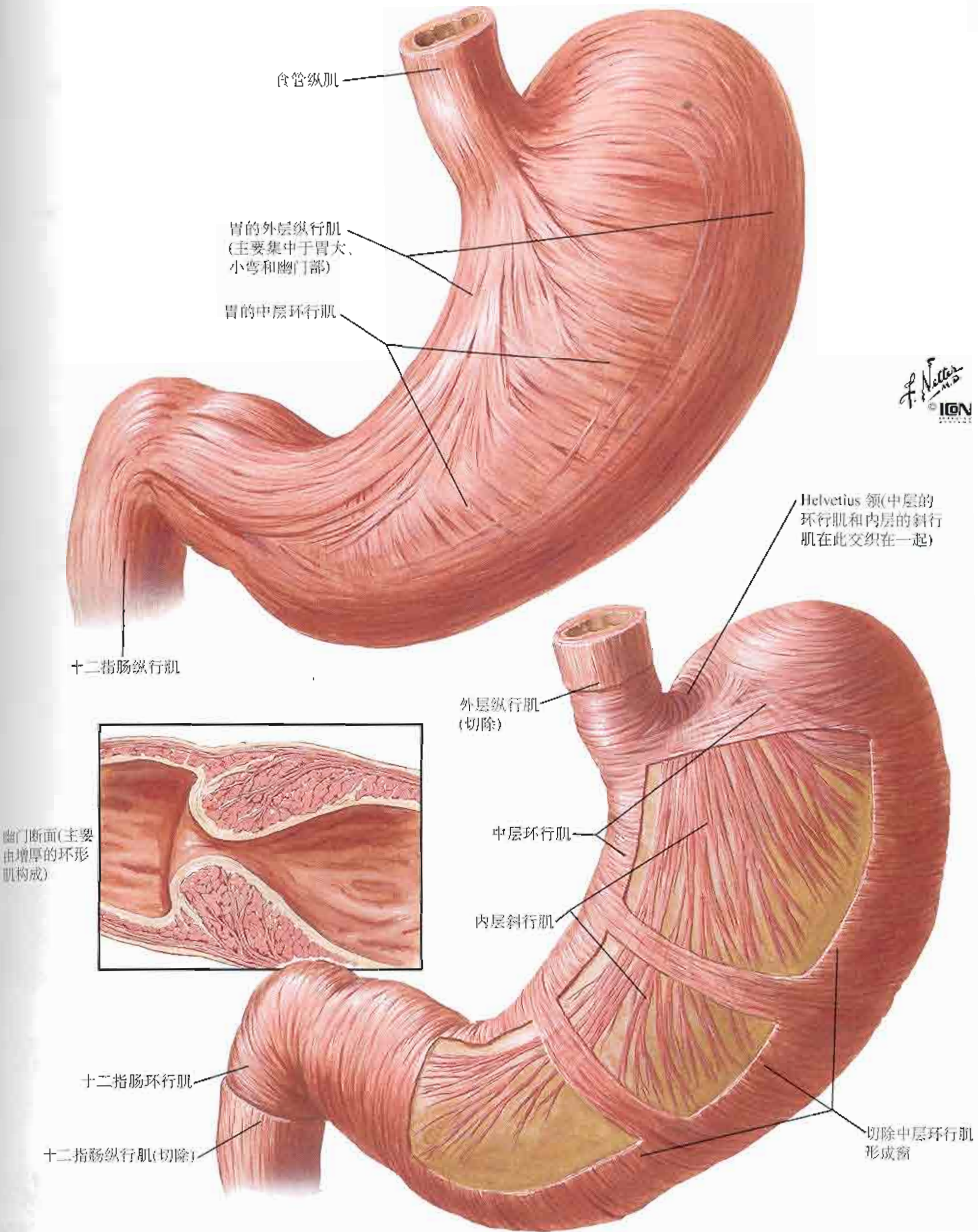


图268



十二指肠 (原位)

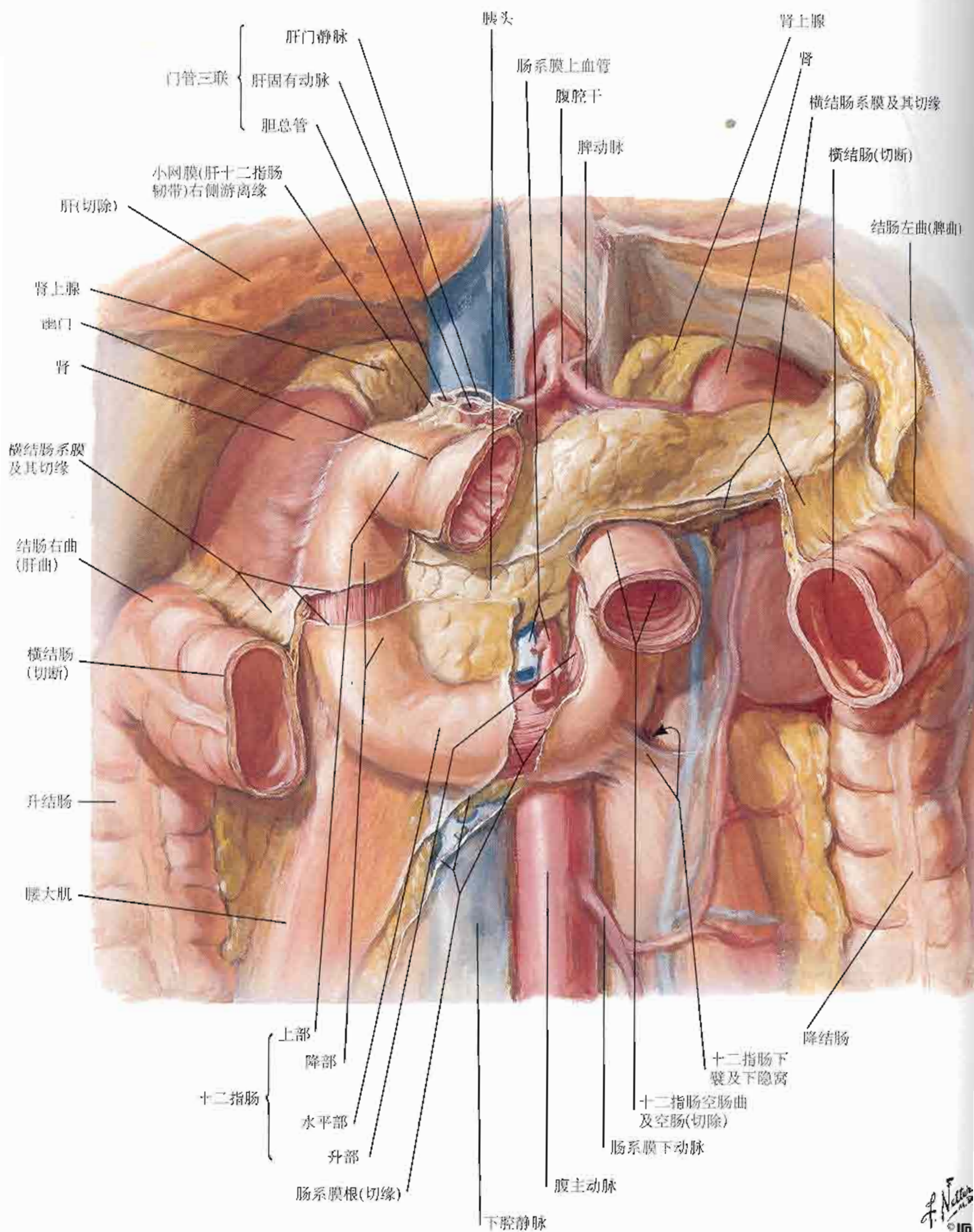
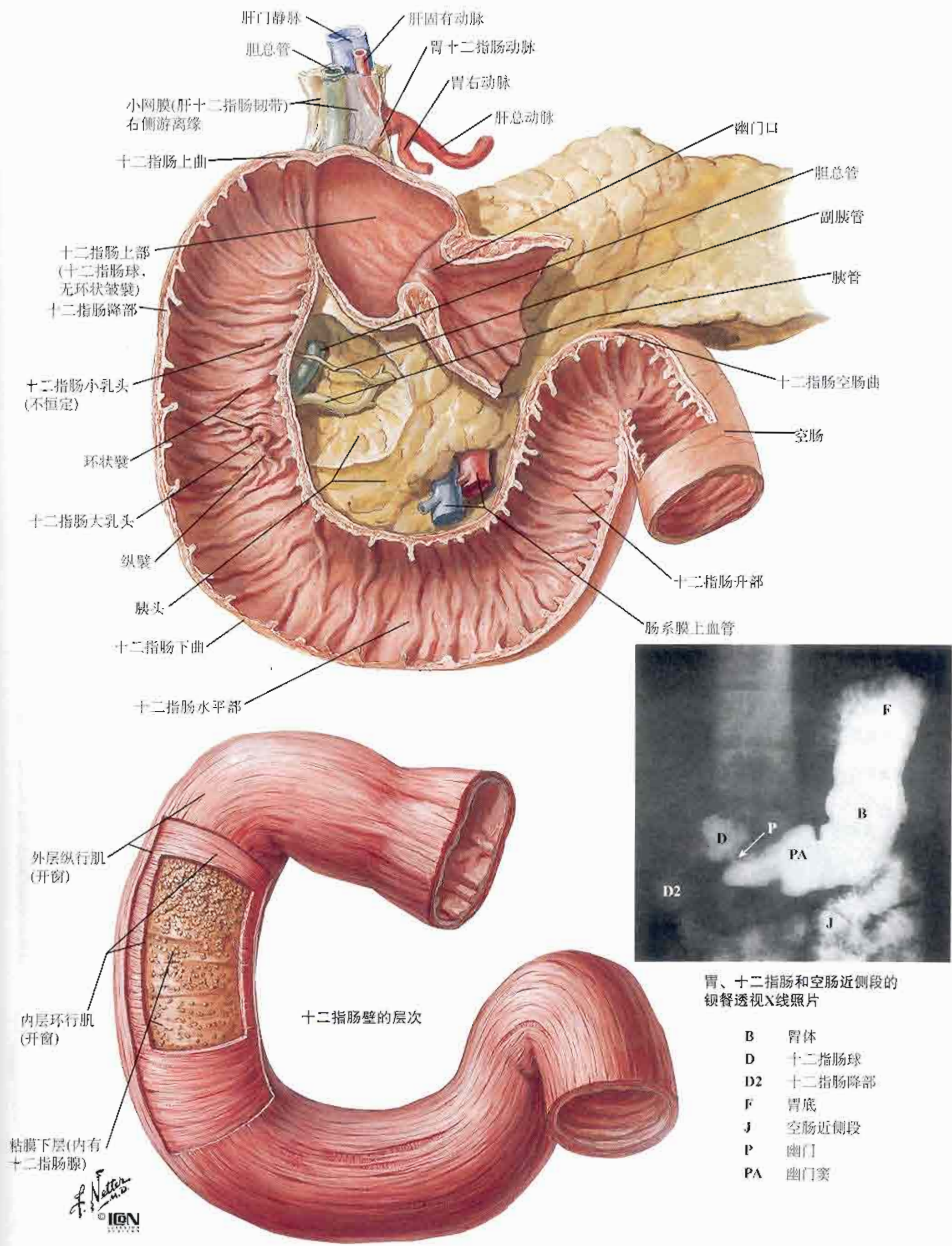


图270



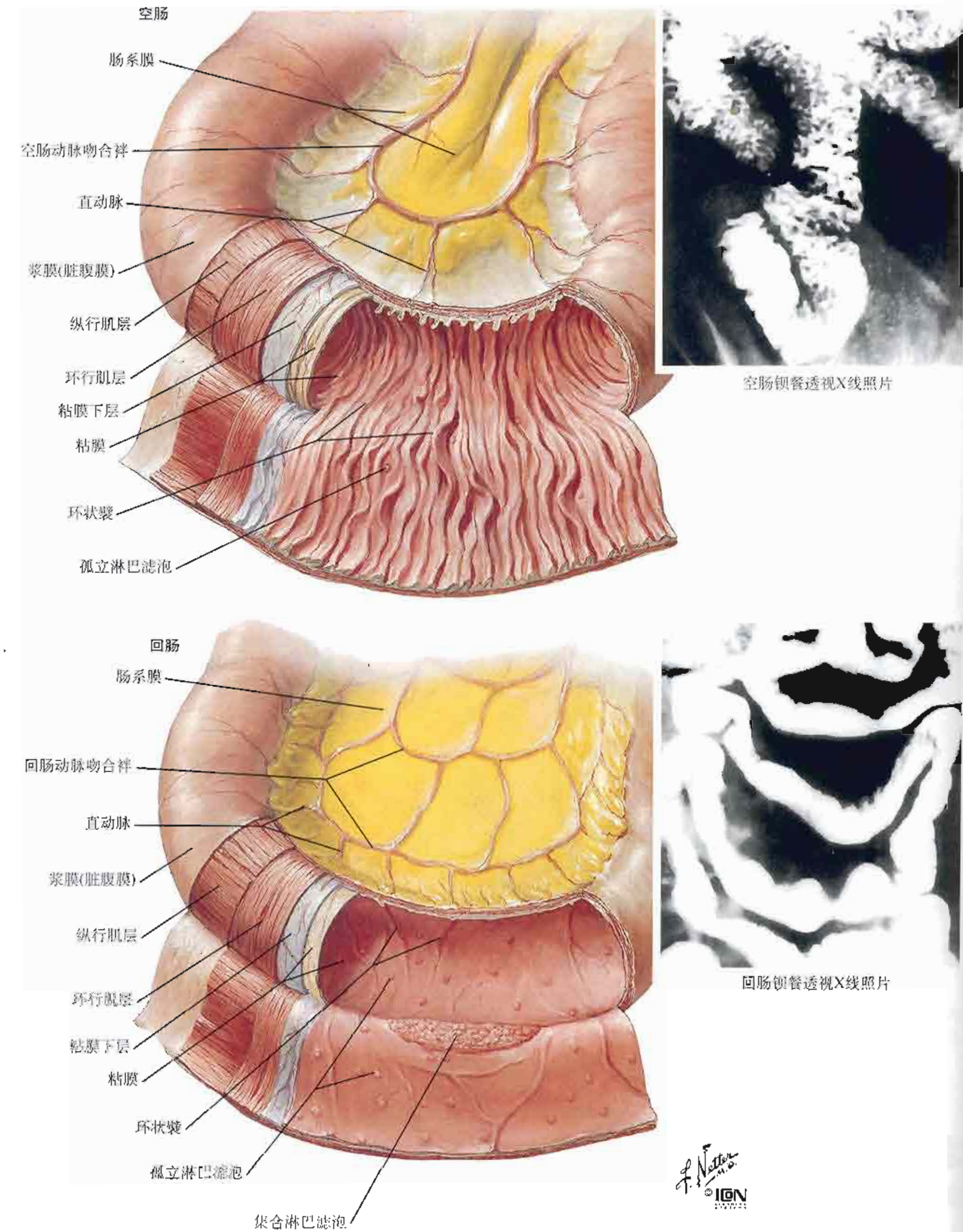
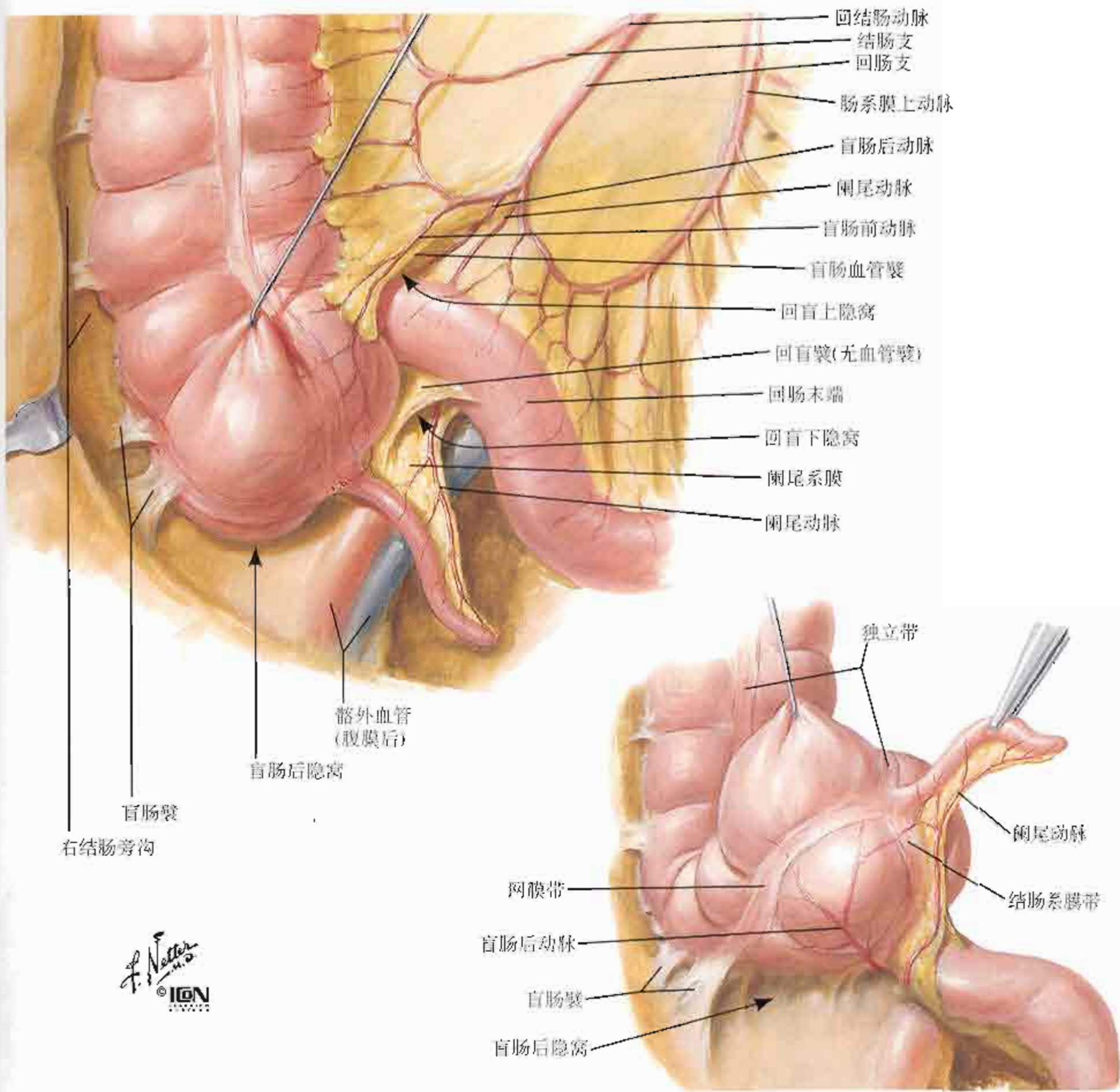
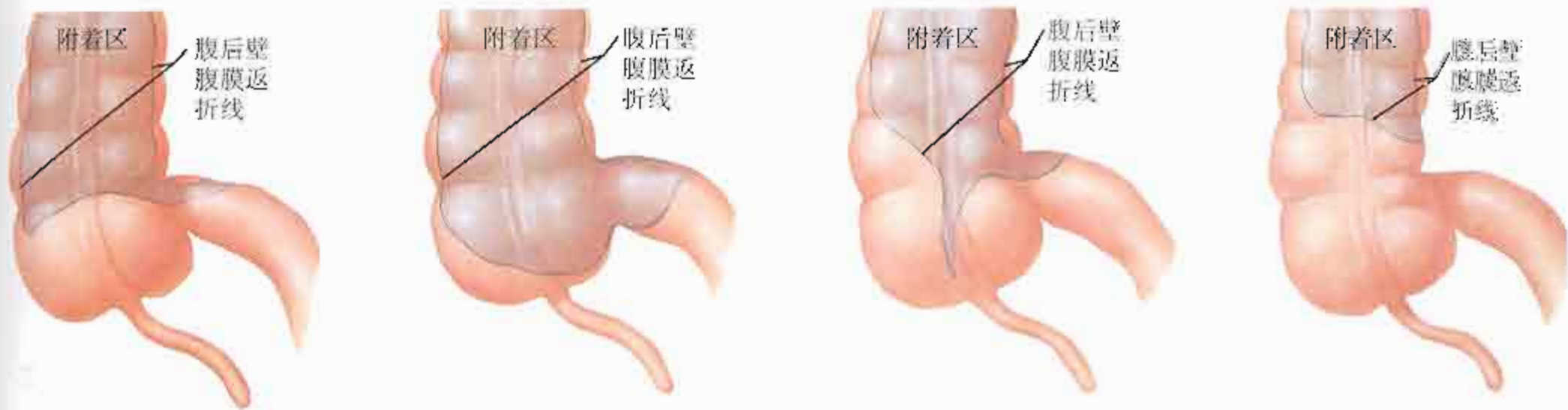
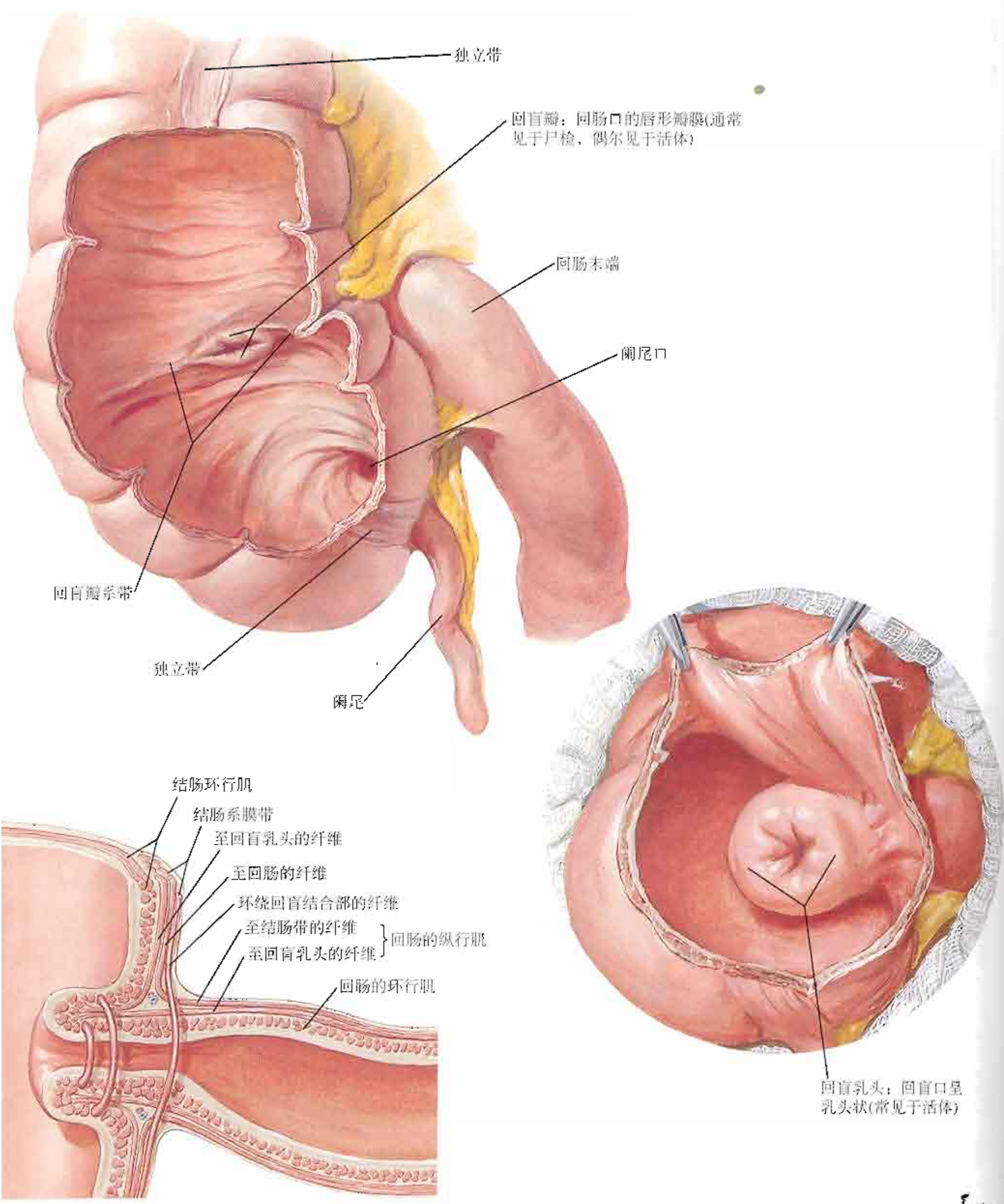


图272

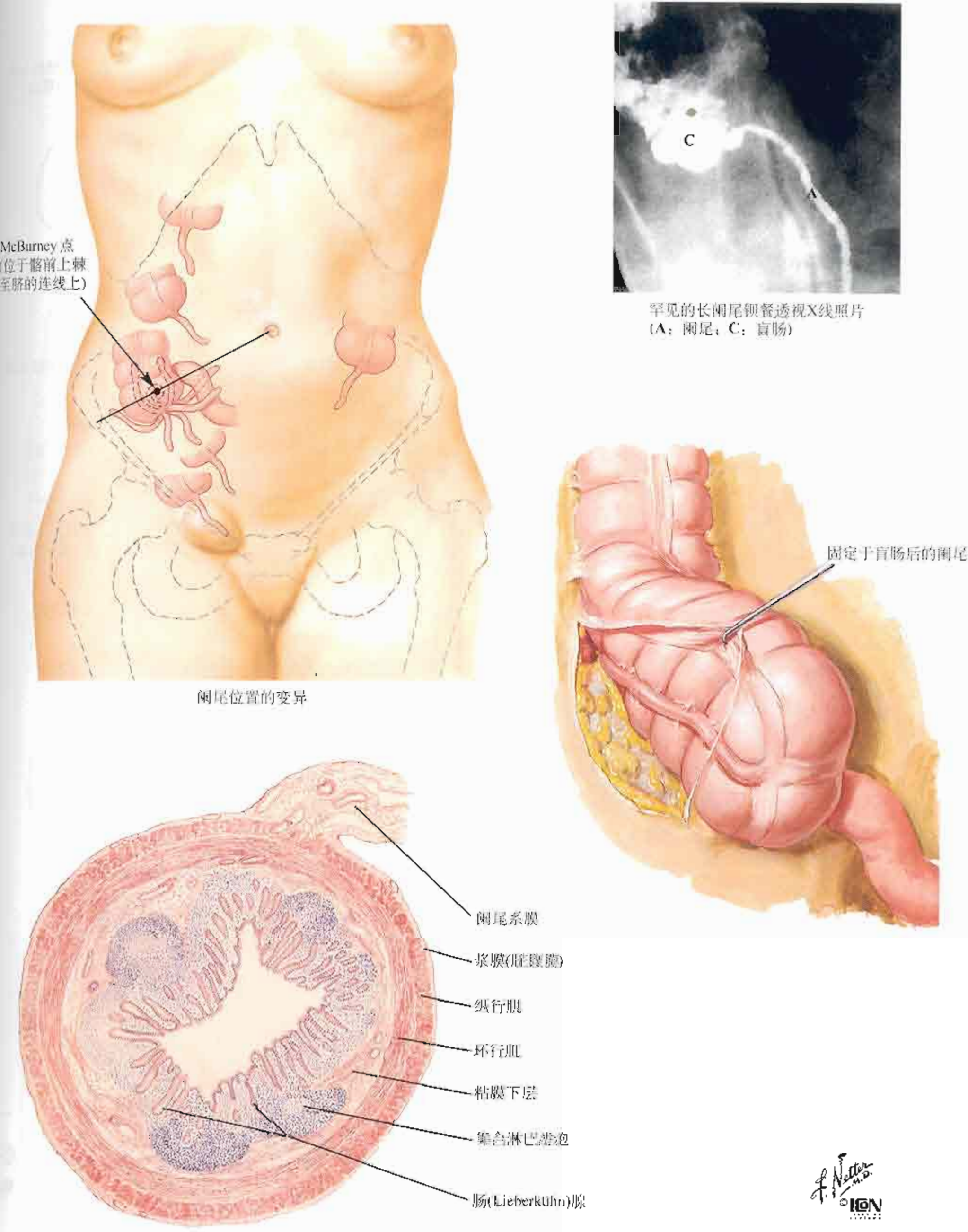


腹后壁腹膜附着于盲肠的某些变异





回盲口肌纤维示意图



大肠的粘膜和肌层

直肠和肛管参见图372~377

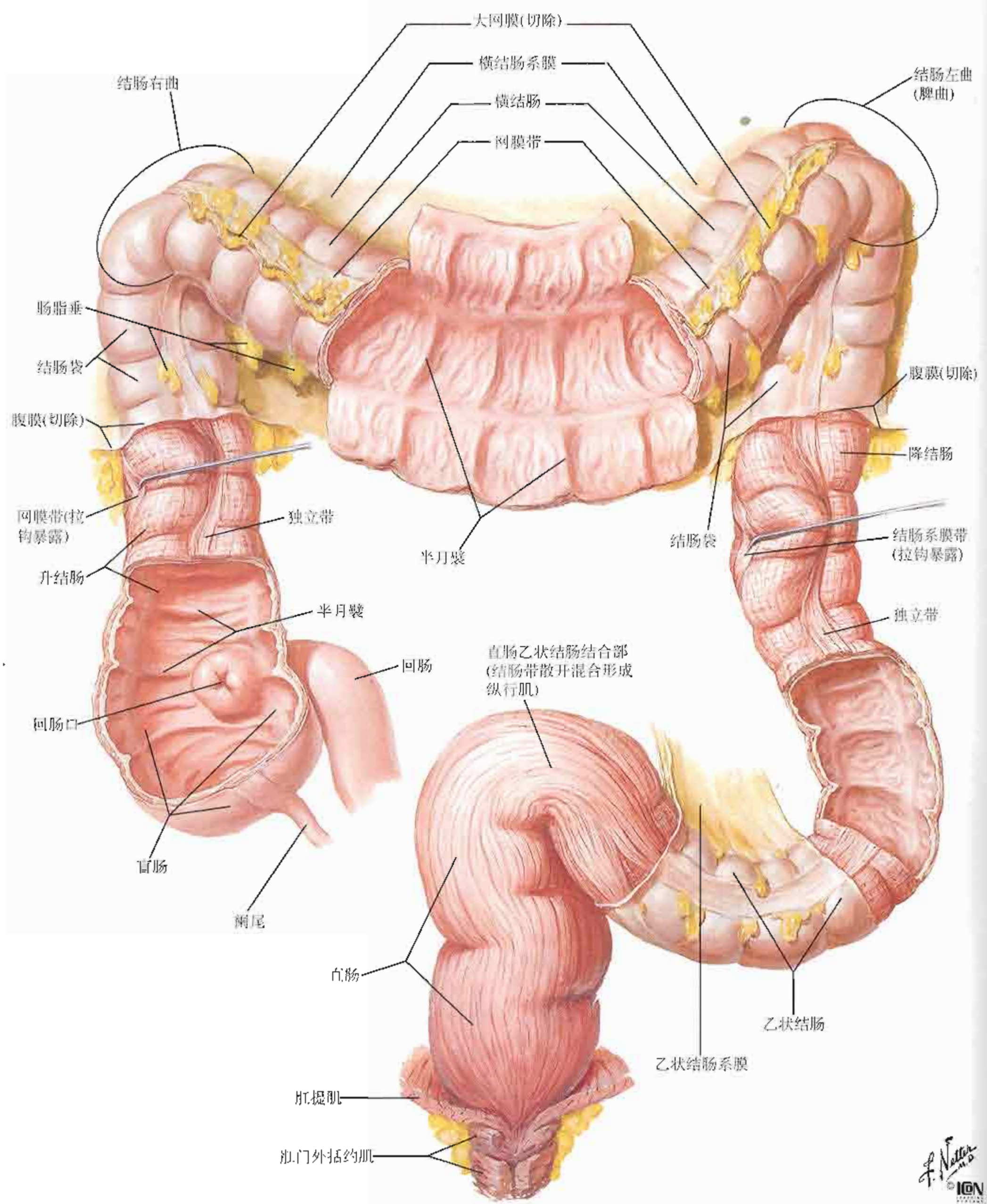
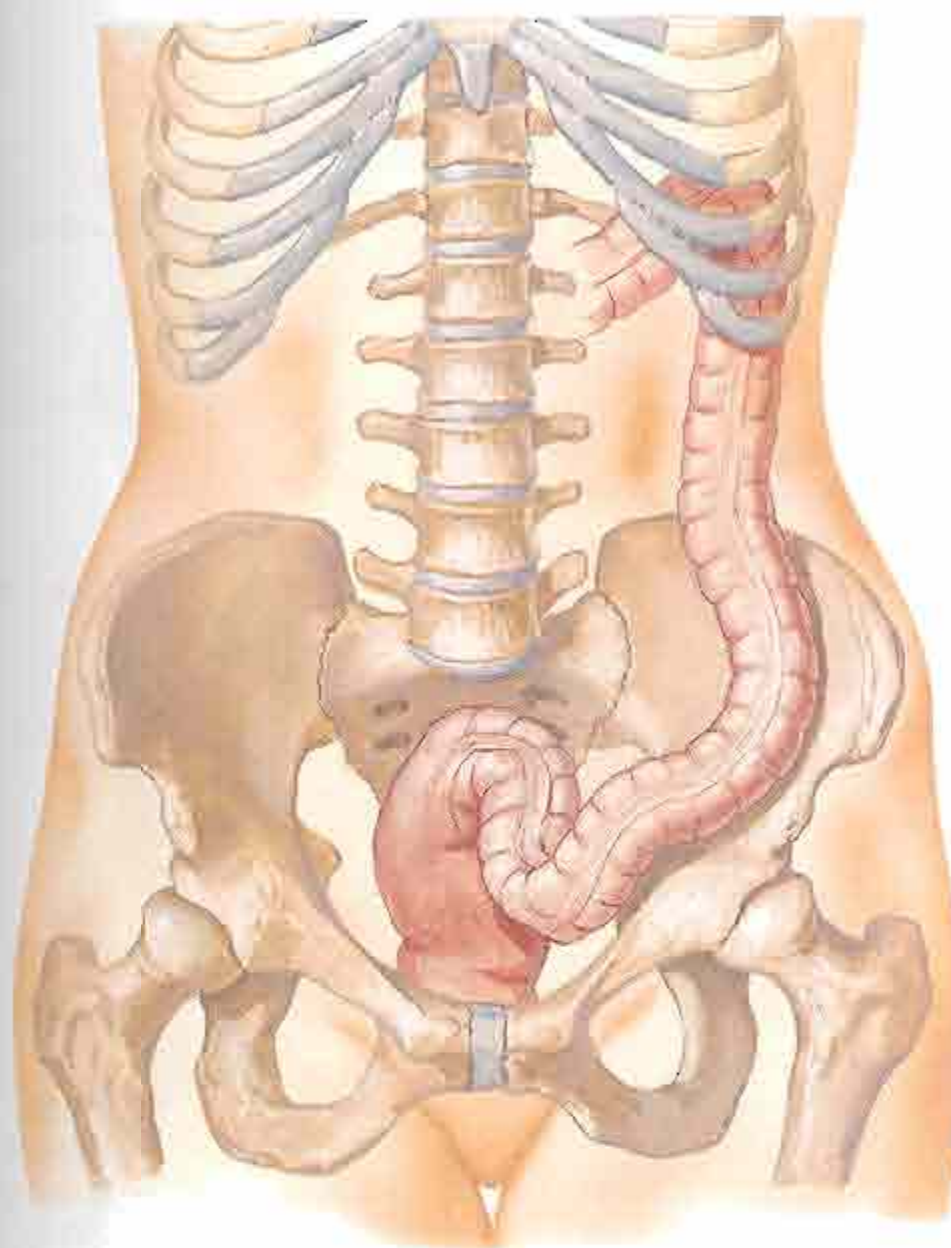


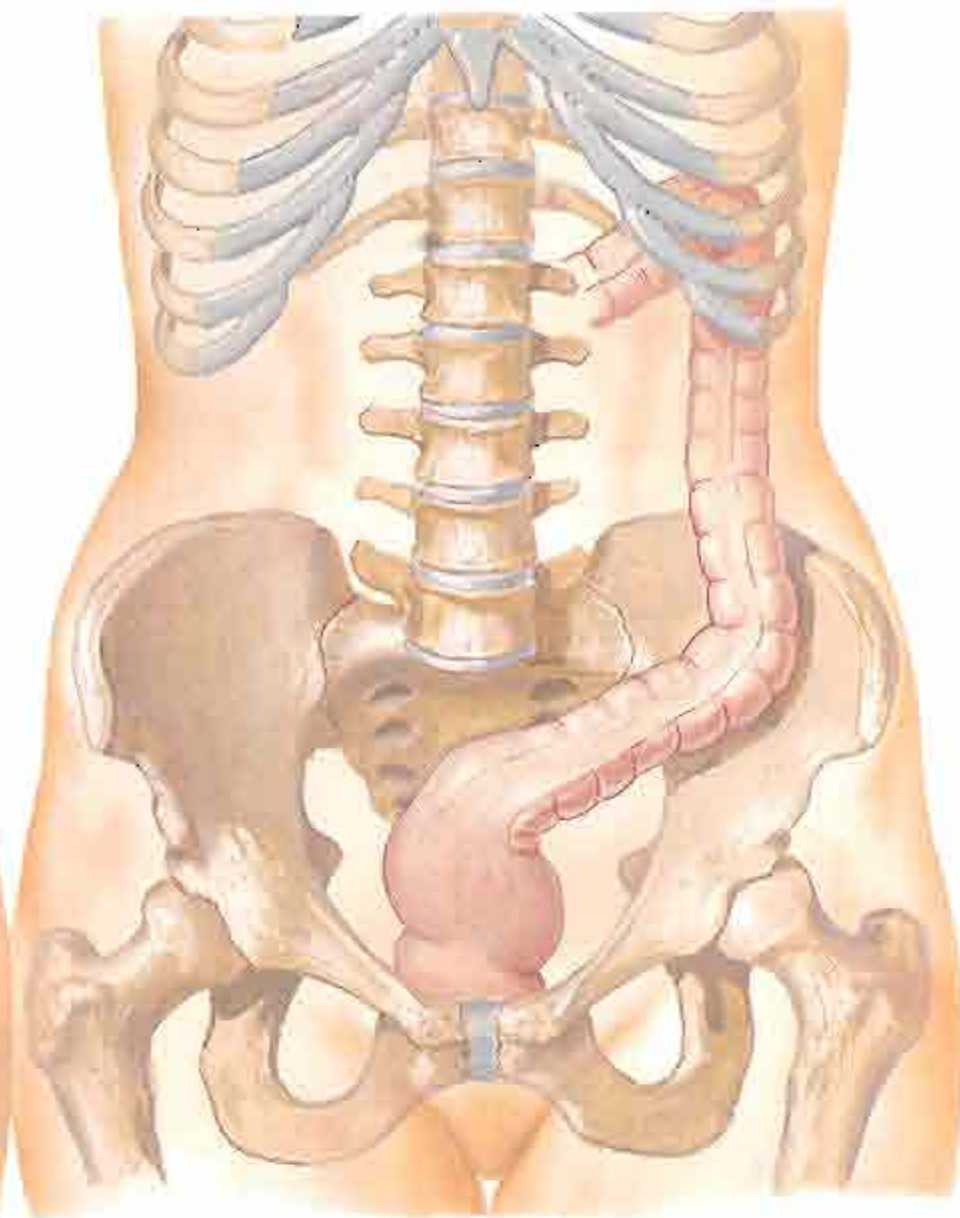
图276

腹部

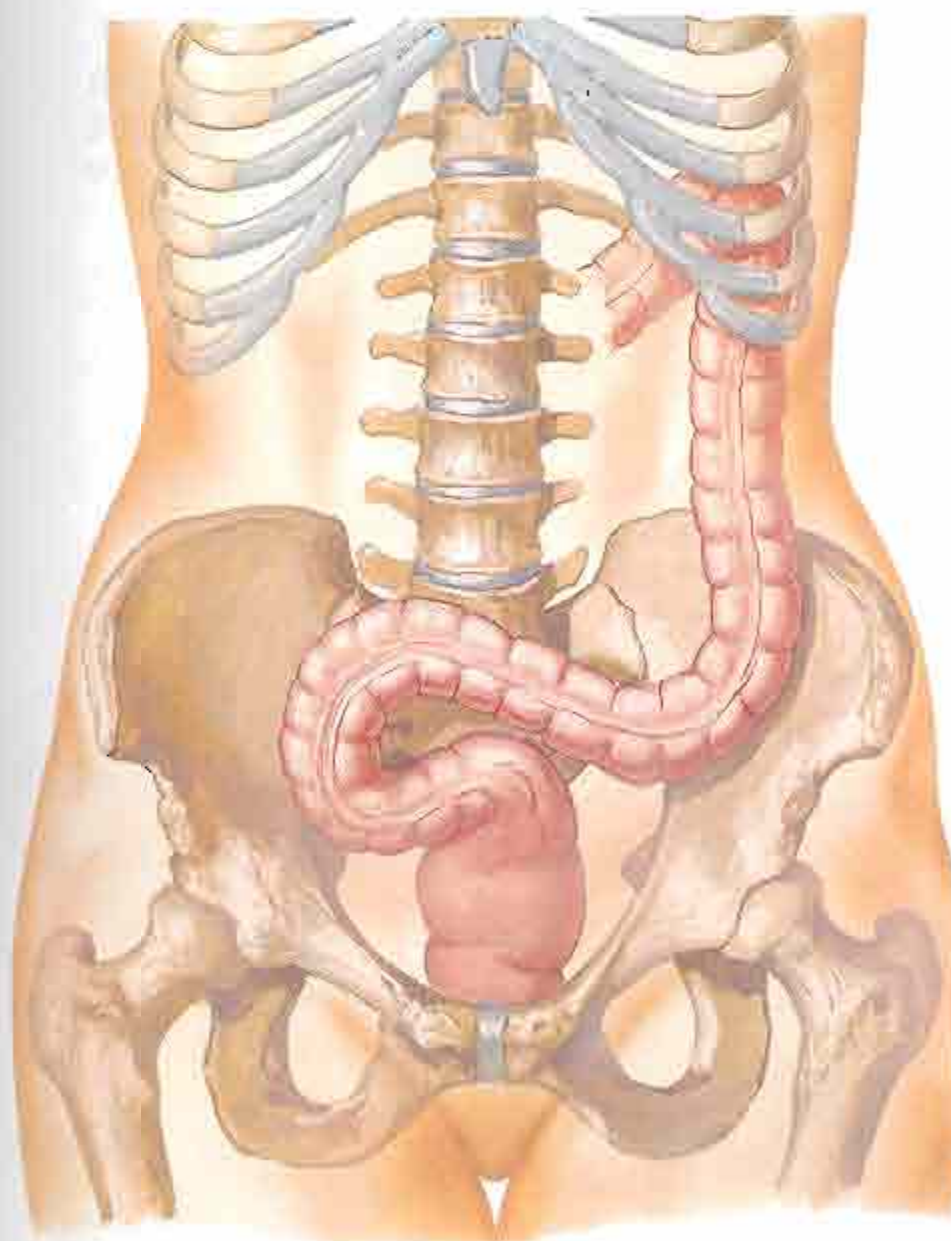
关于直肠参见图347、348、372~375



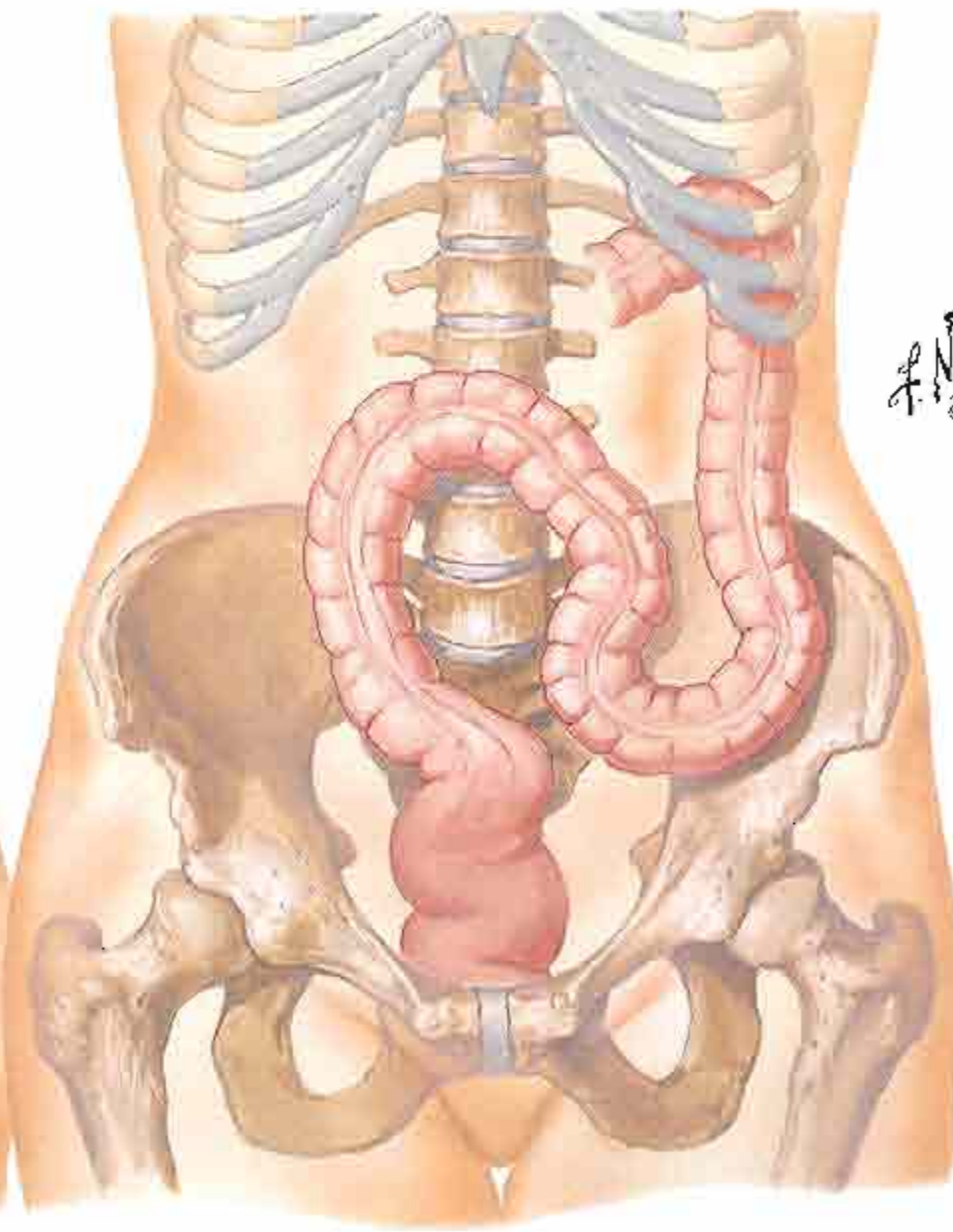
典型的位置



短、直、斜行进入盆腔



形成肠袢至盆腔右侧



上升至腹部

F. Netter M.D.
© IGCN

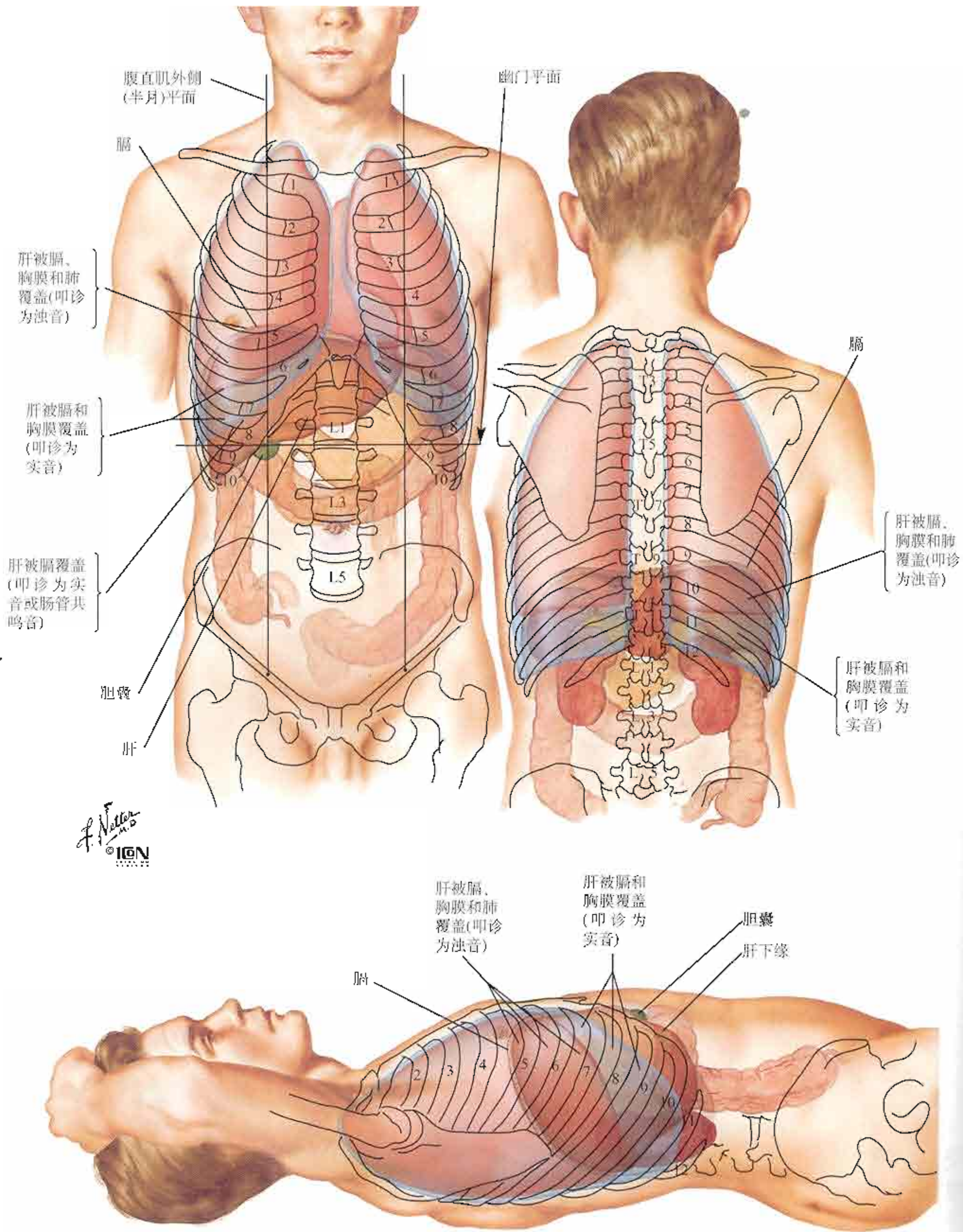
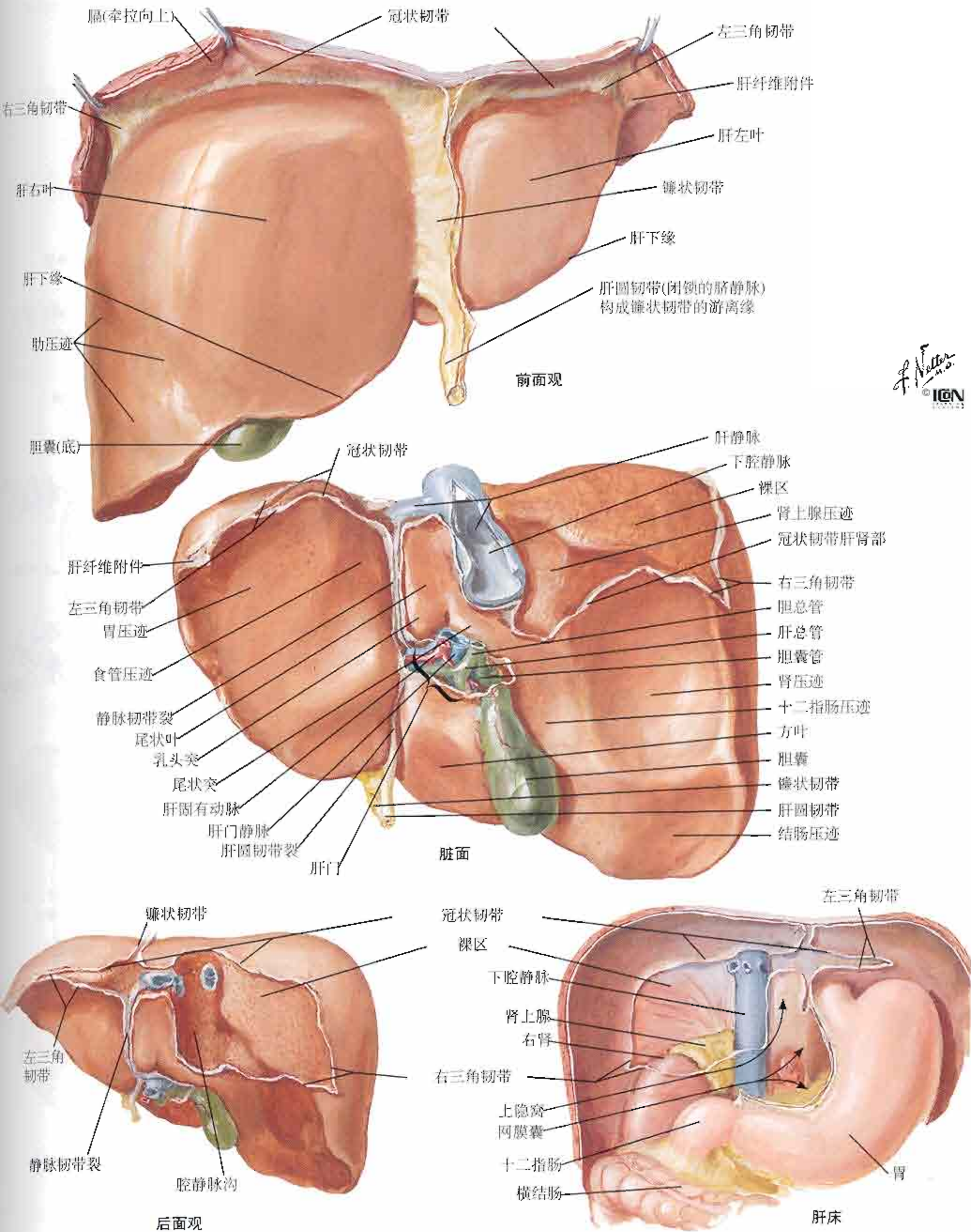


图278



F. Netter M.D.
© IGCN

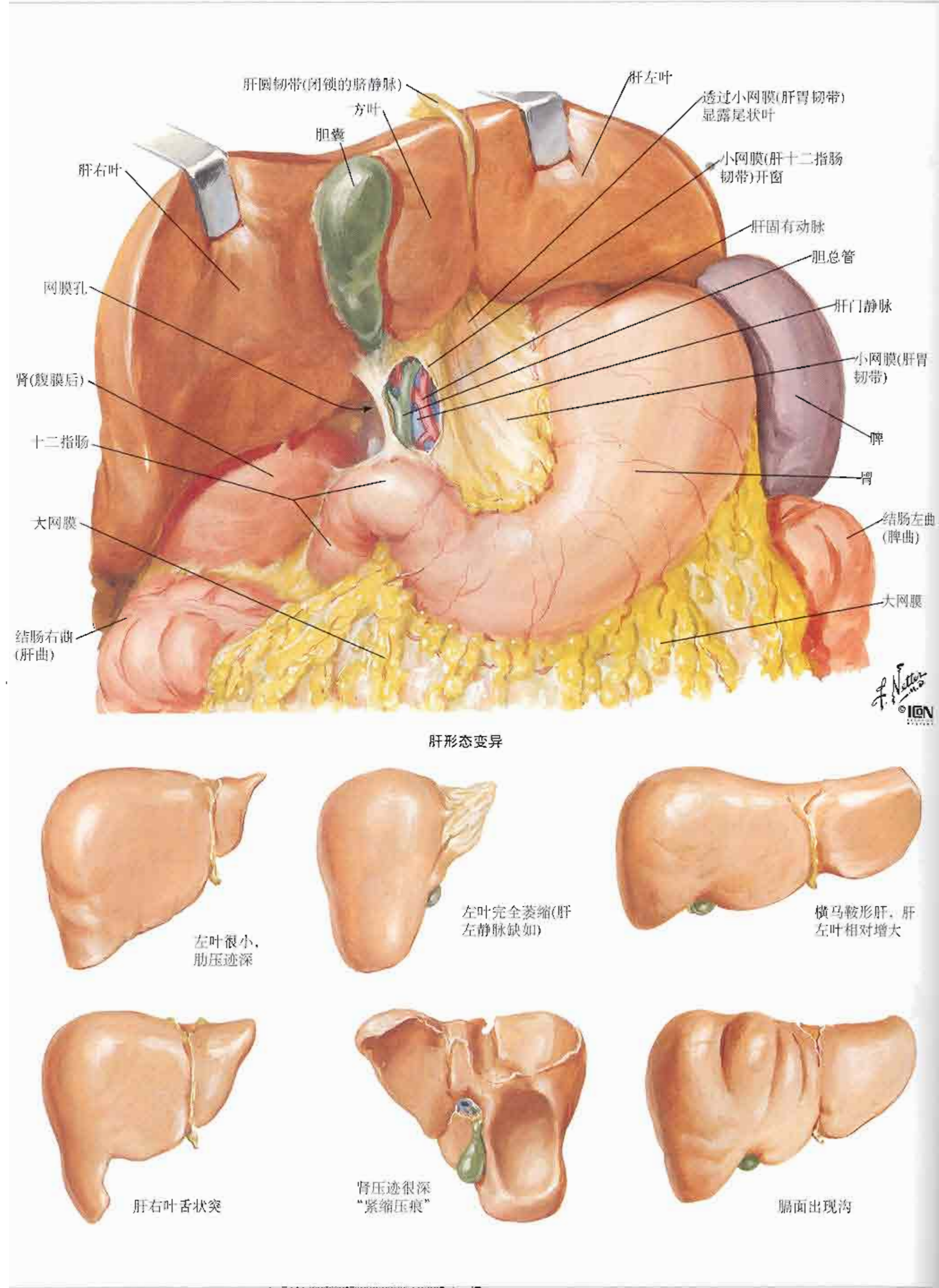
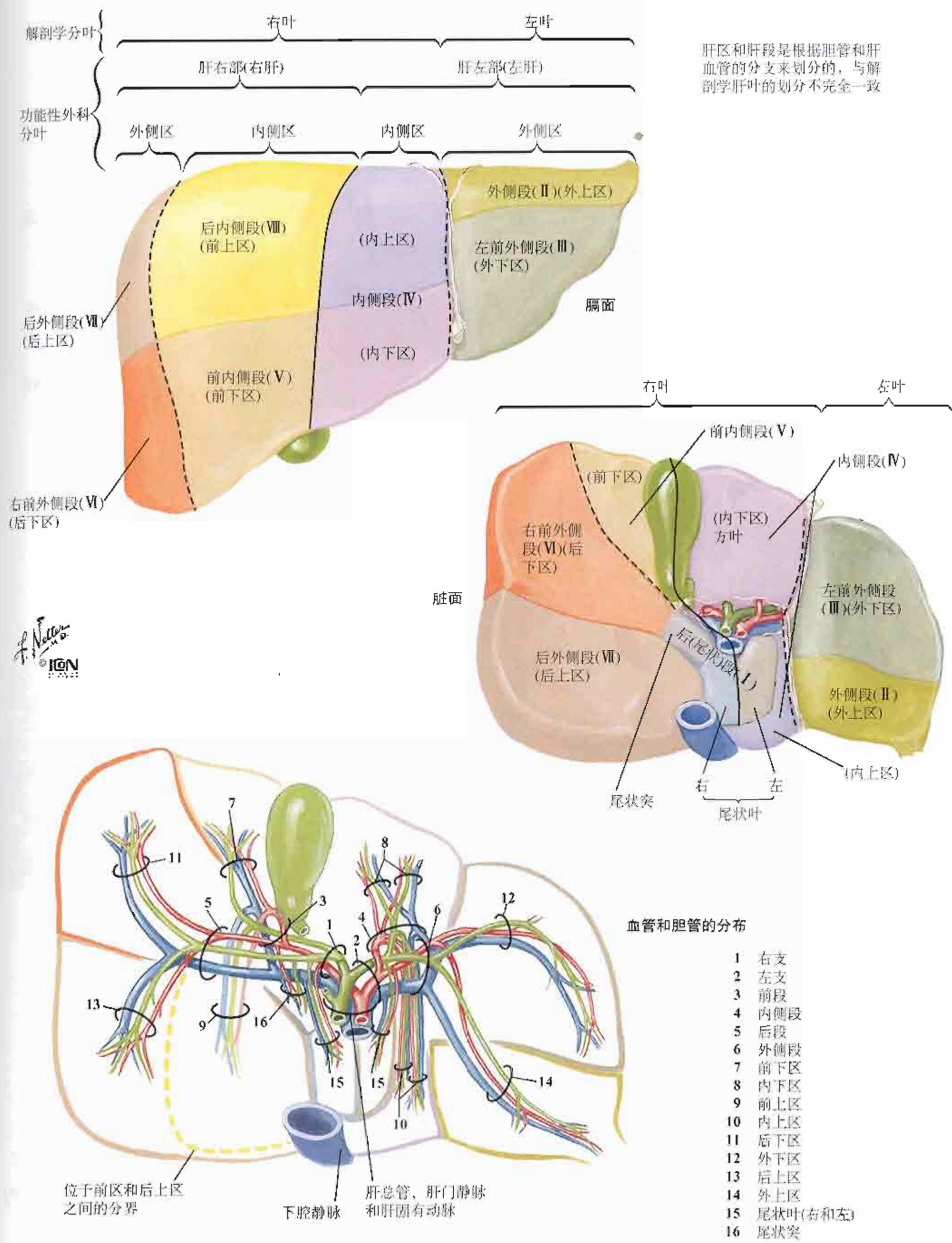
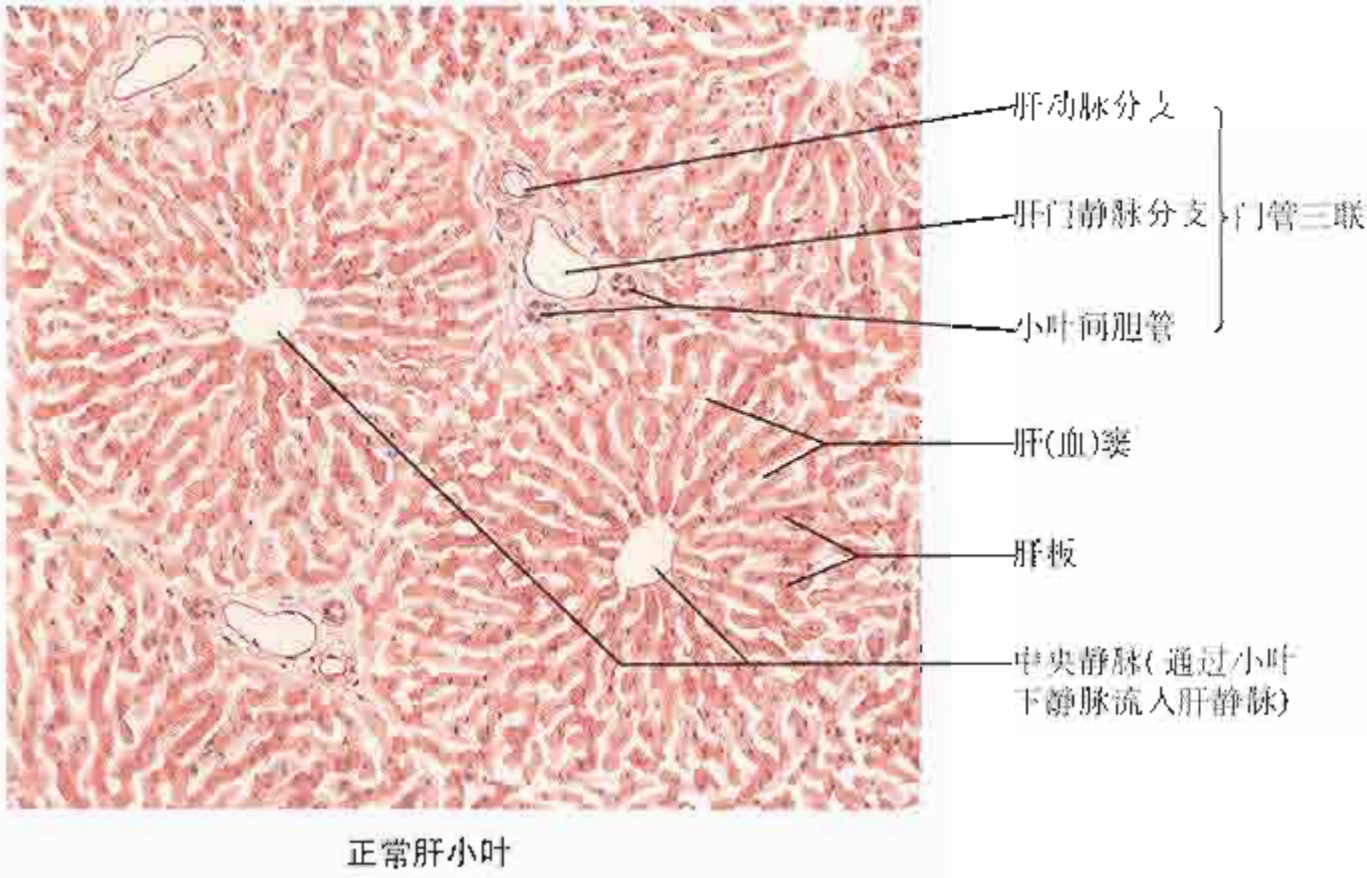
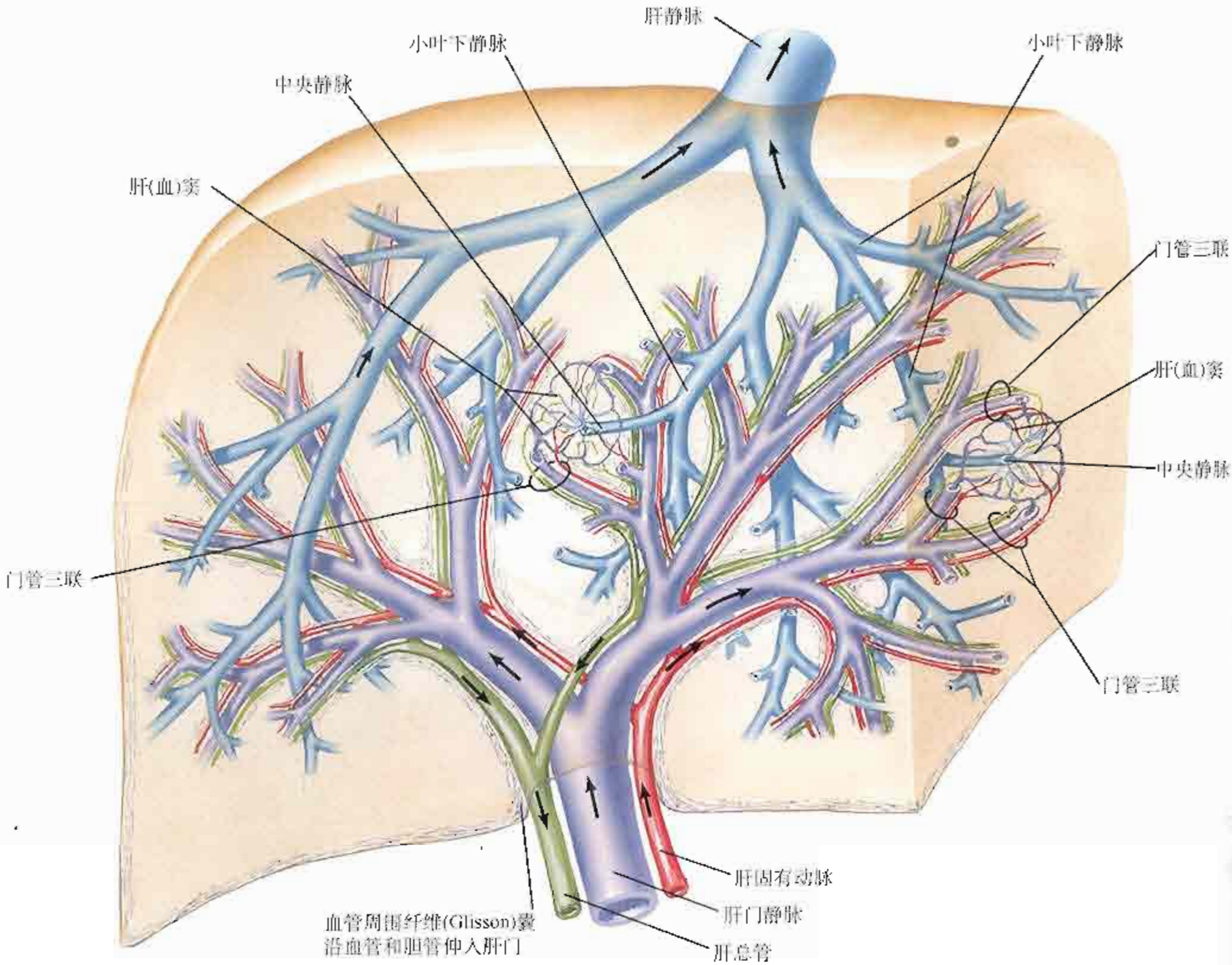


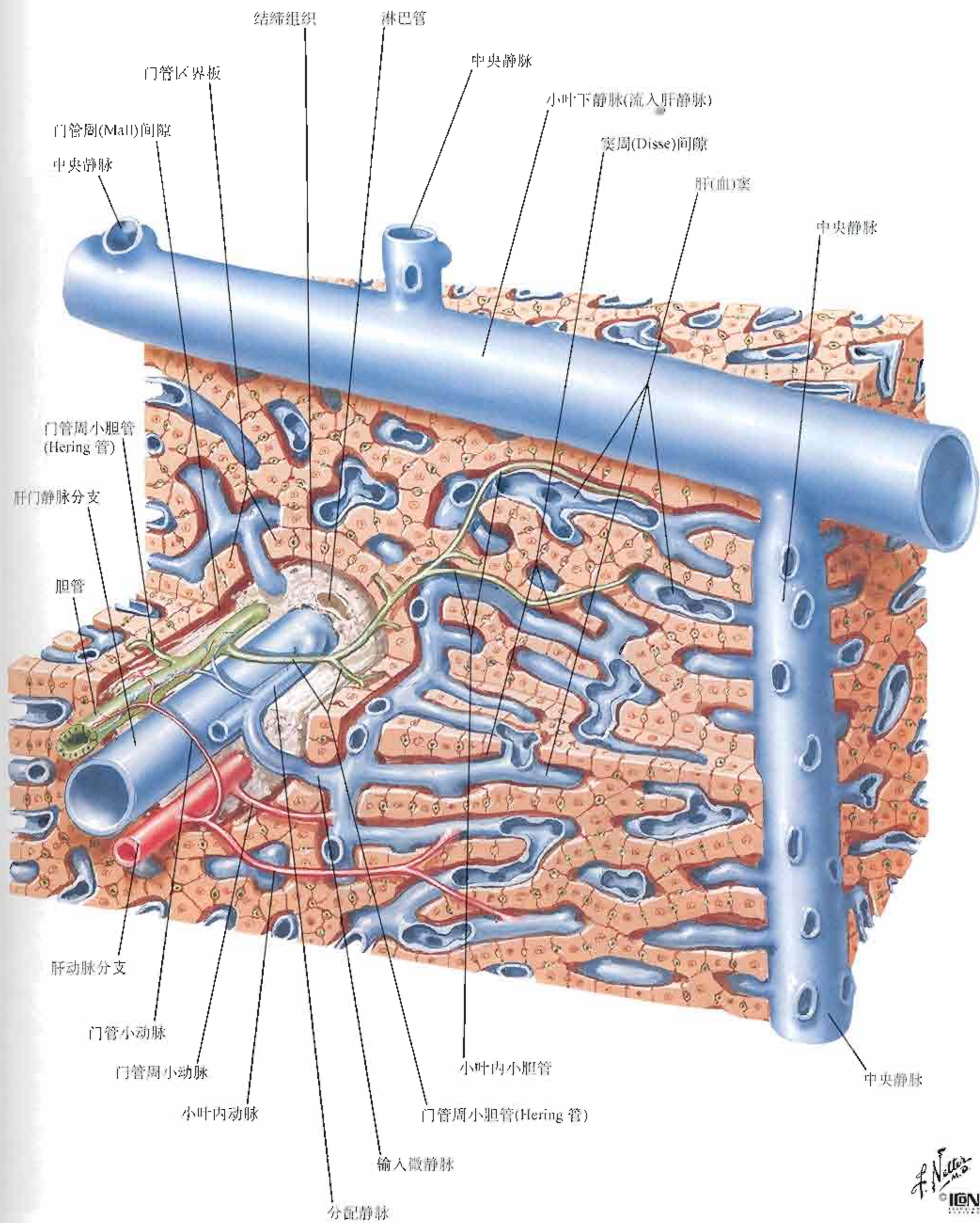
图280

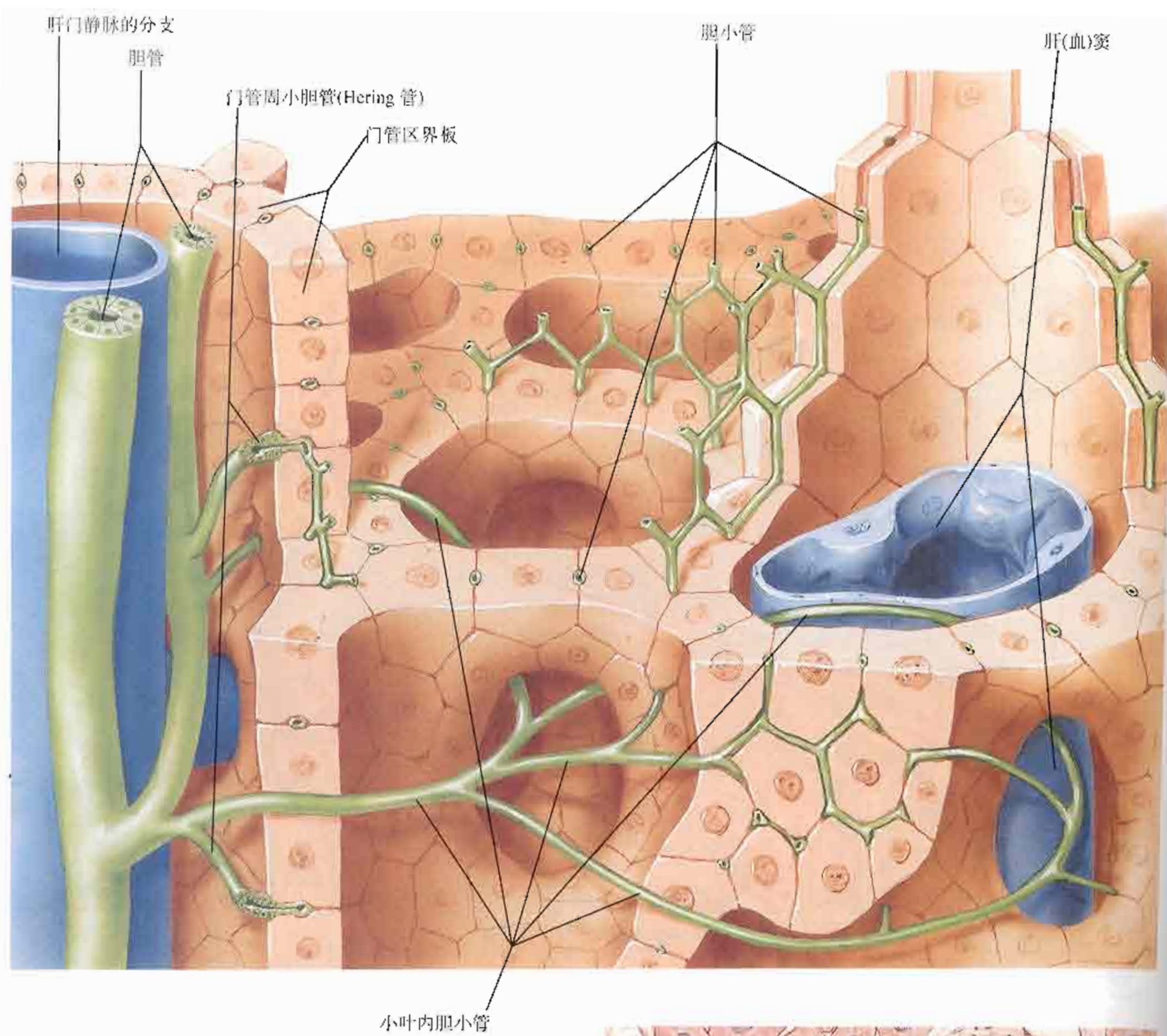




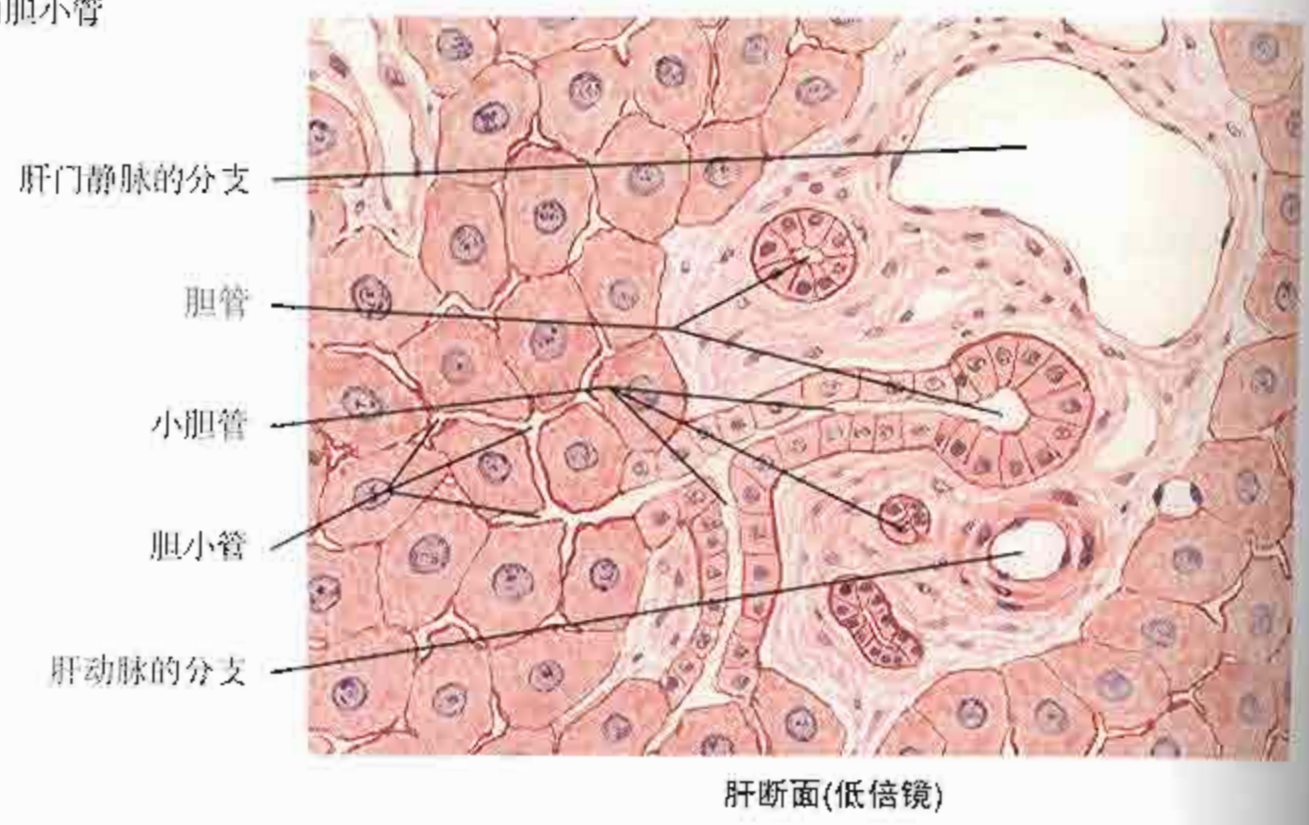
F. Netter M.D.
© ION

图282

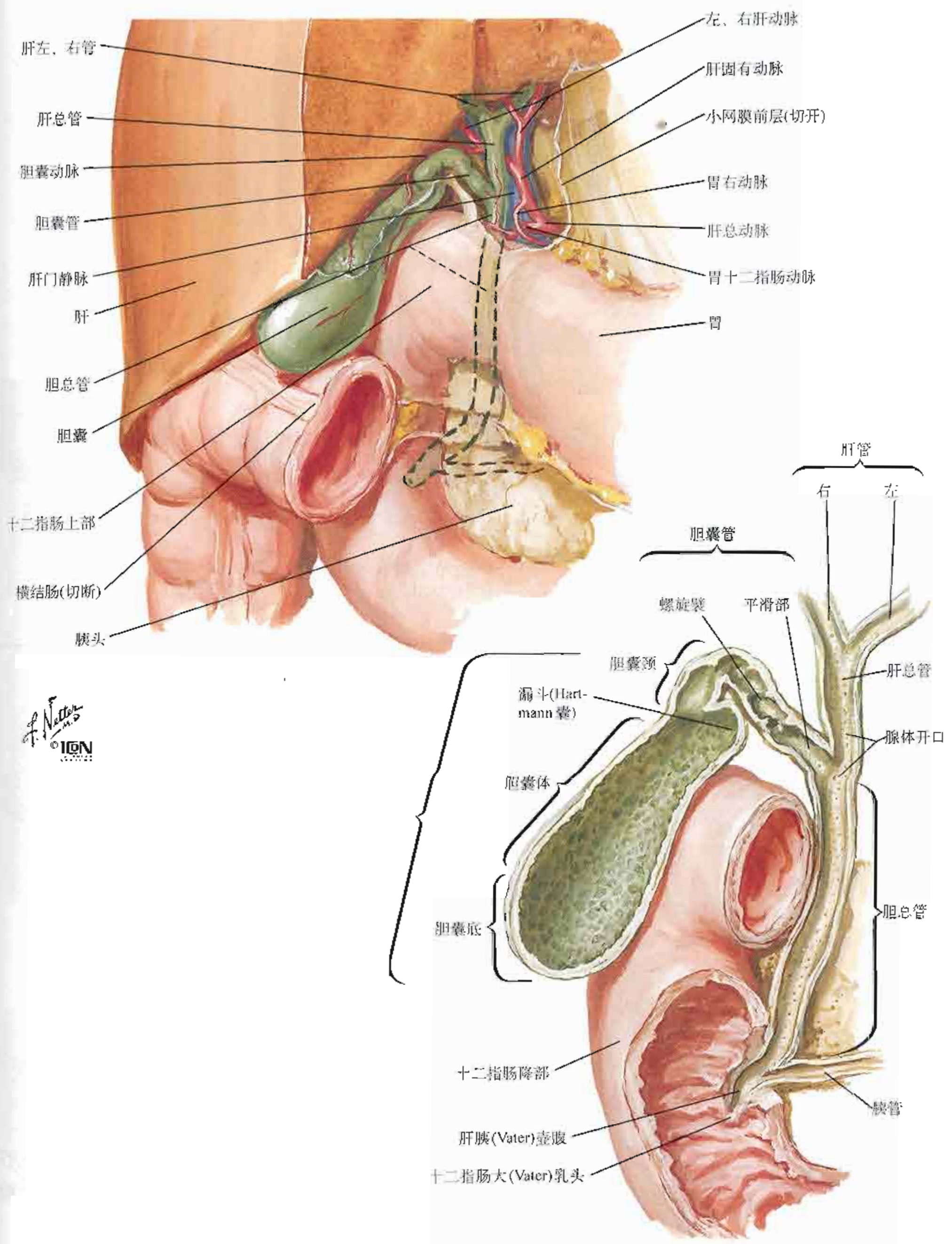




注：在上面的示意图中，胆小管作为一种具有管壁的结构出现。然而，在右侧的组织切片中，胆小管的边界实际上是相邻的肝实质细胞膜的表面



肝断面(低倍镜)



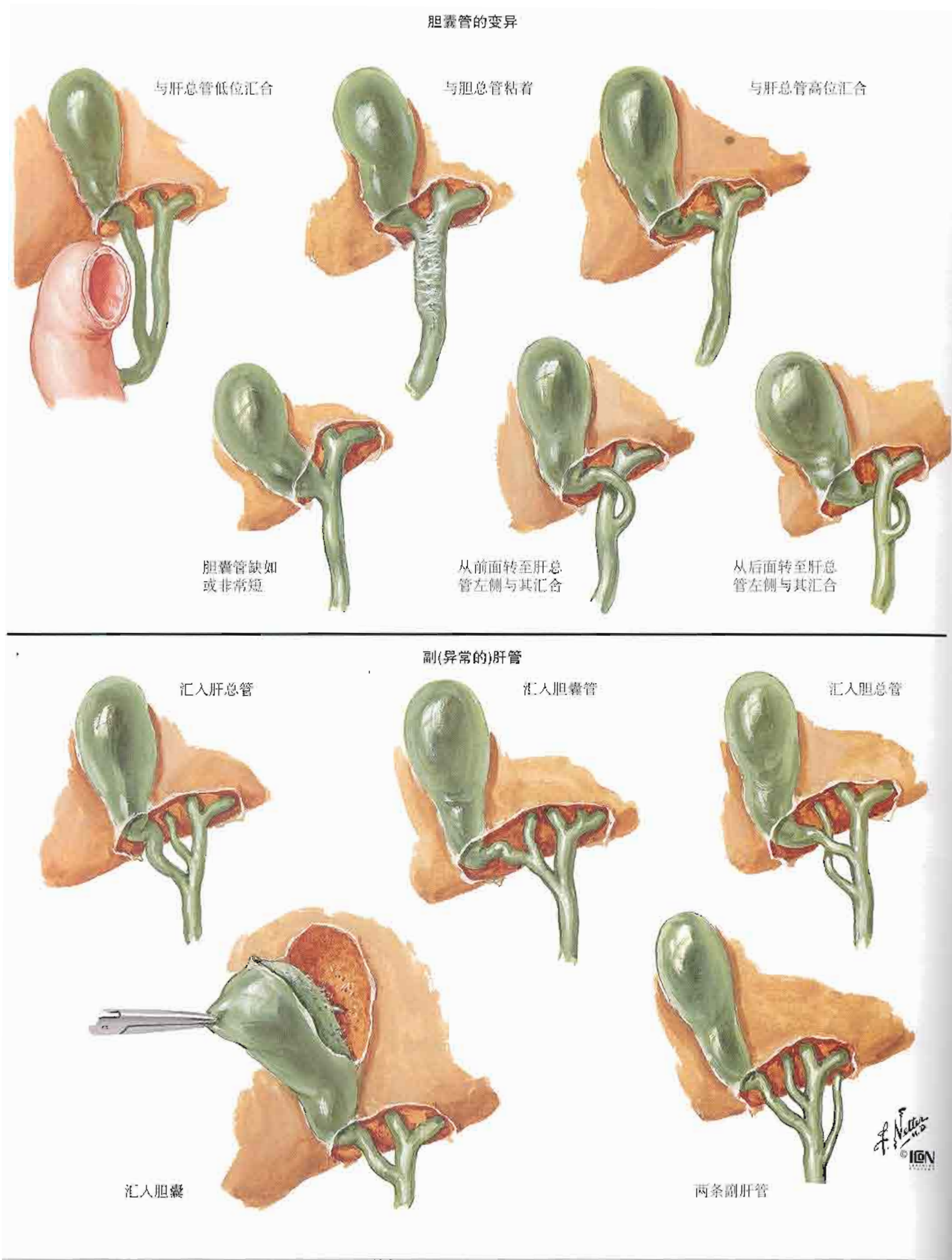
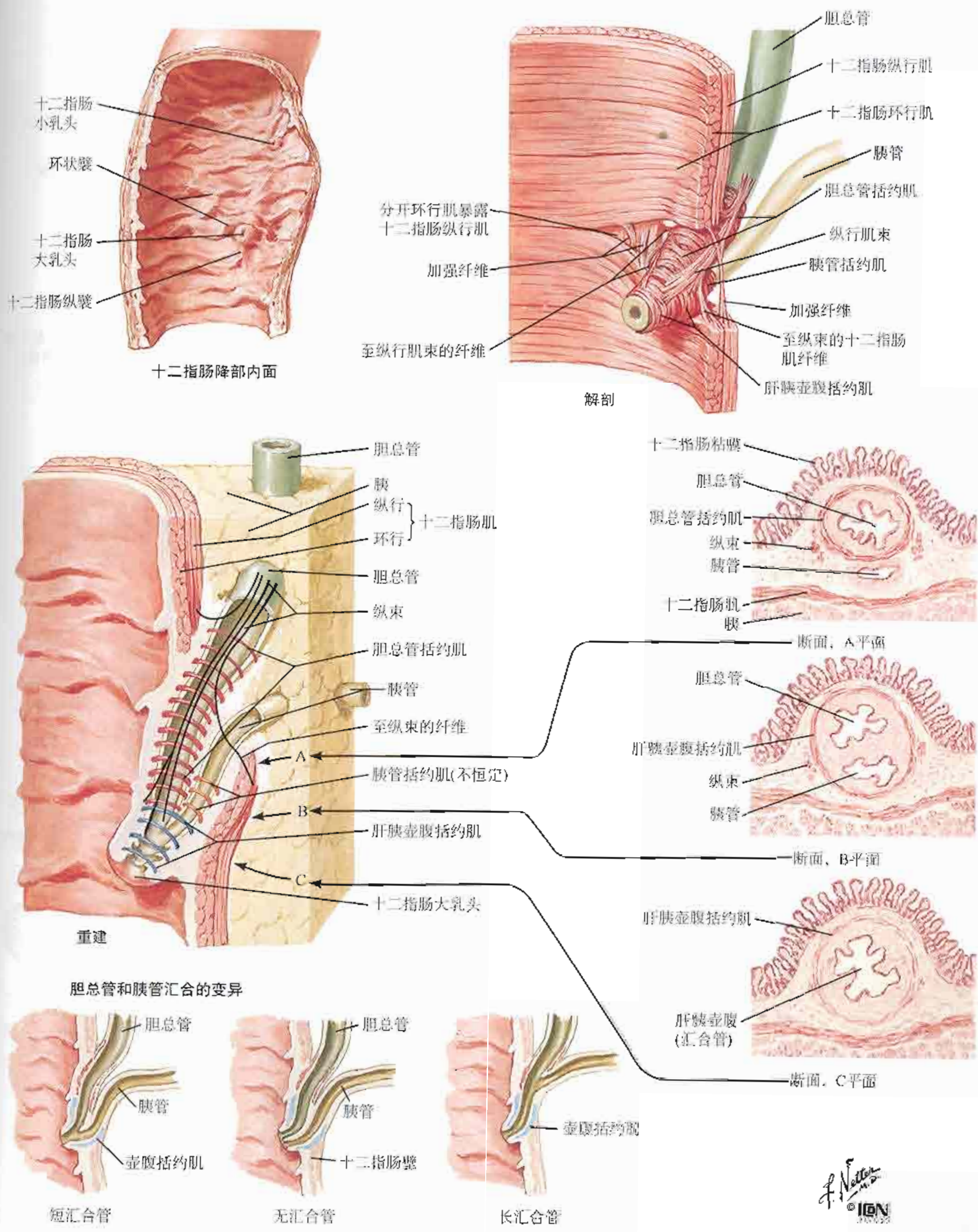


图286



胰 (原位)

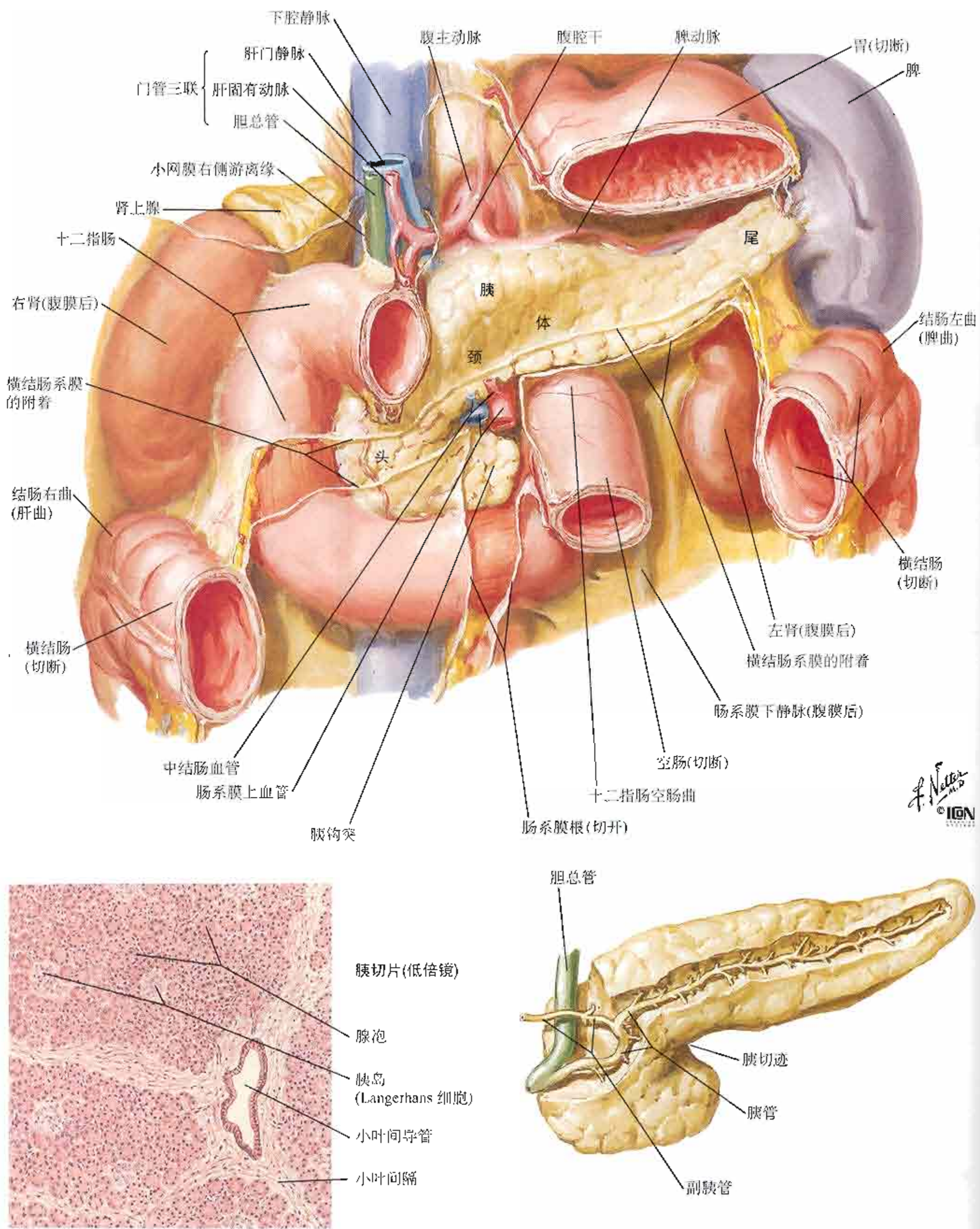
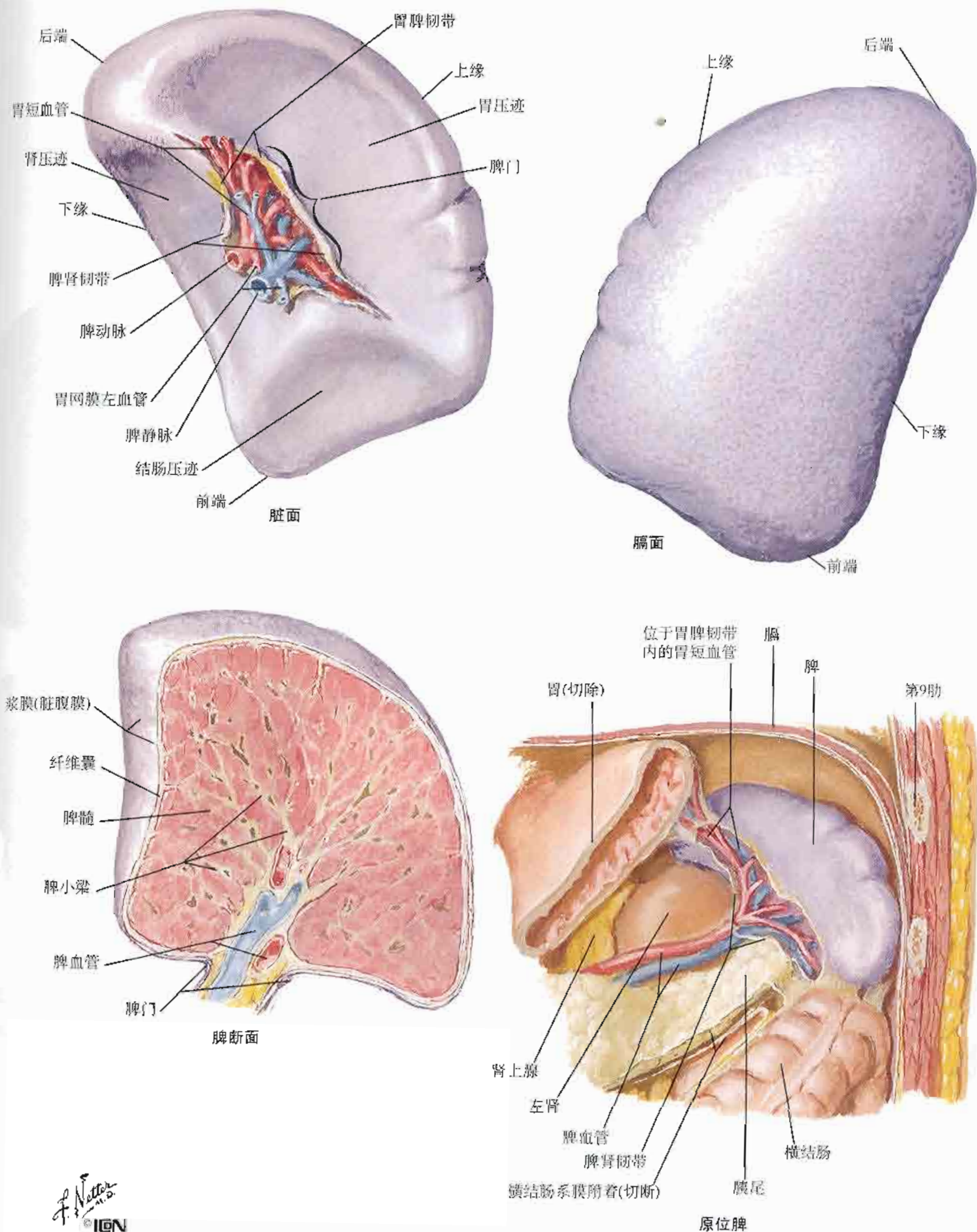


图288



胃、肝和脾的动脉

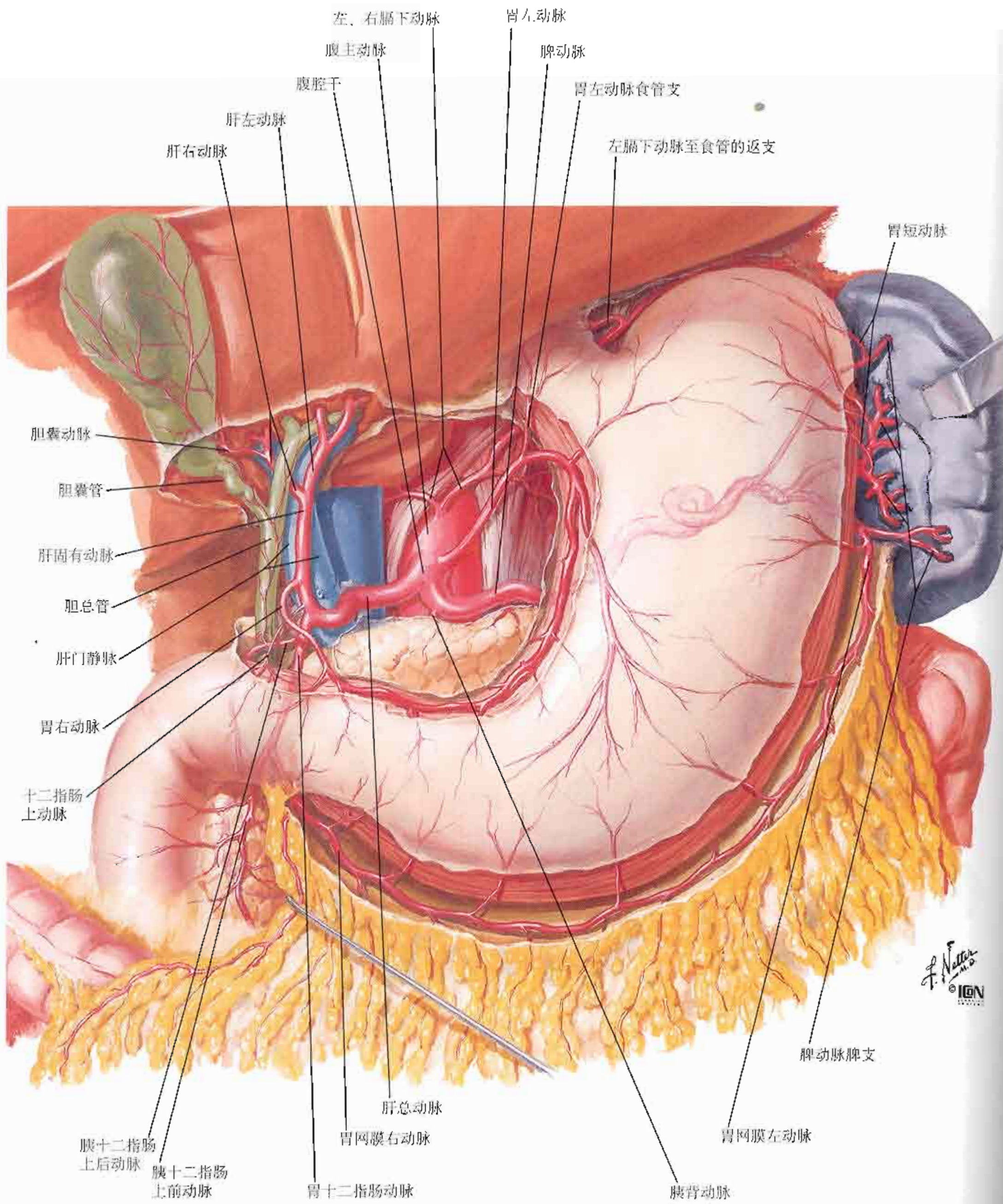
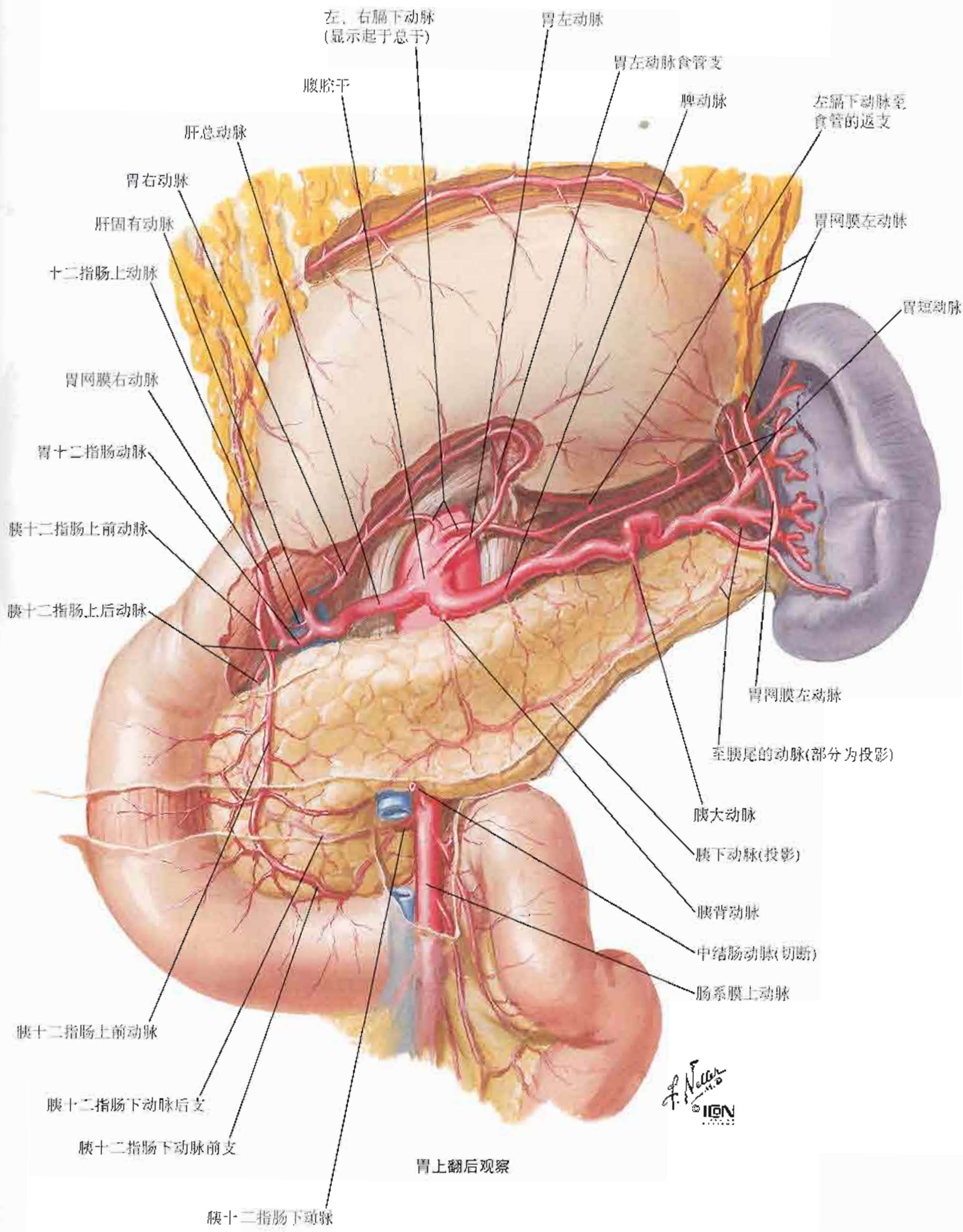


图290



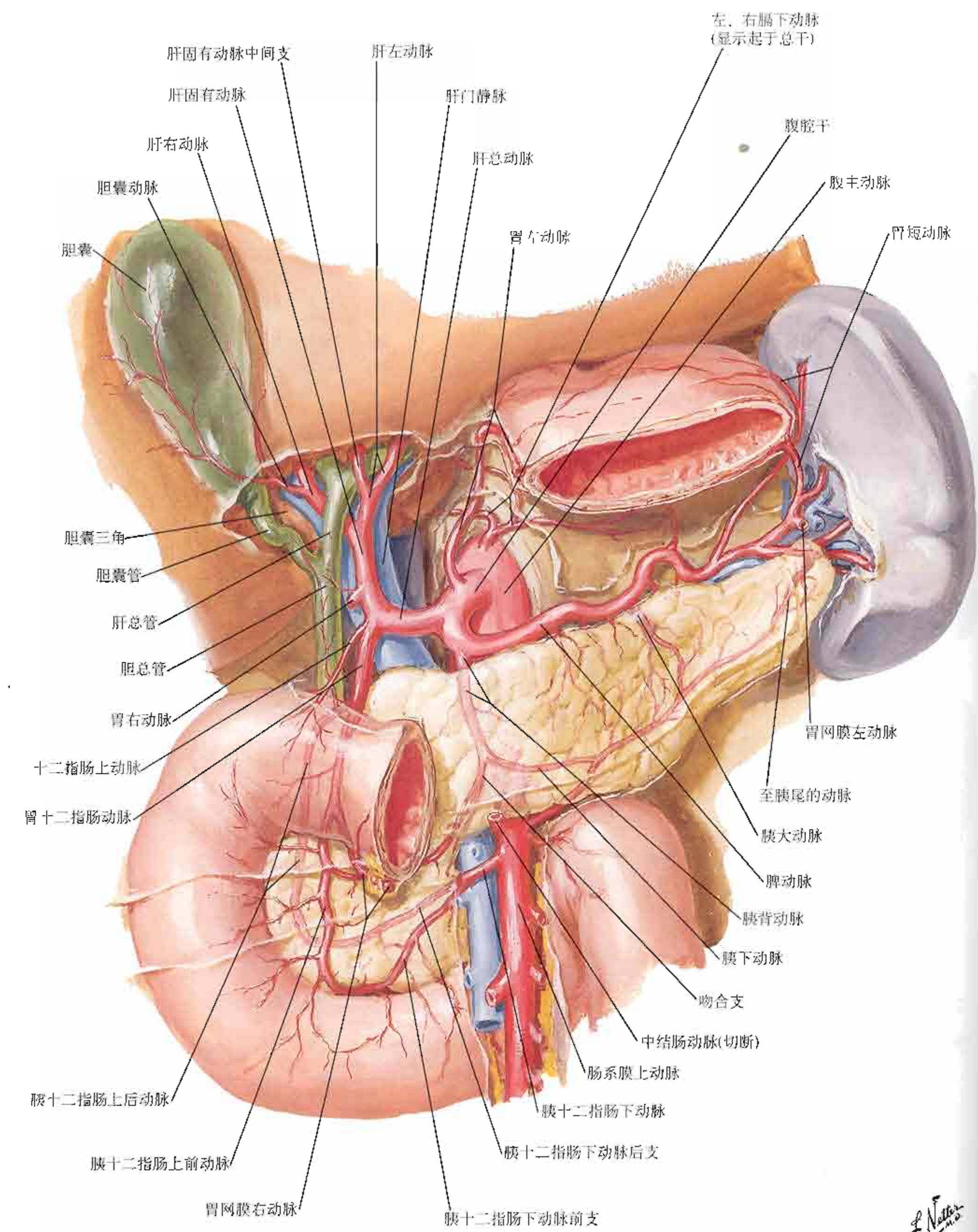
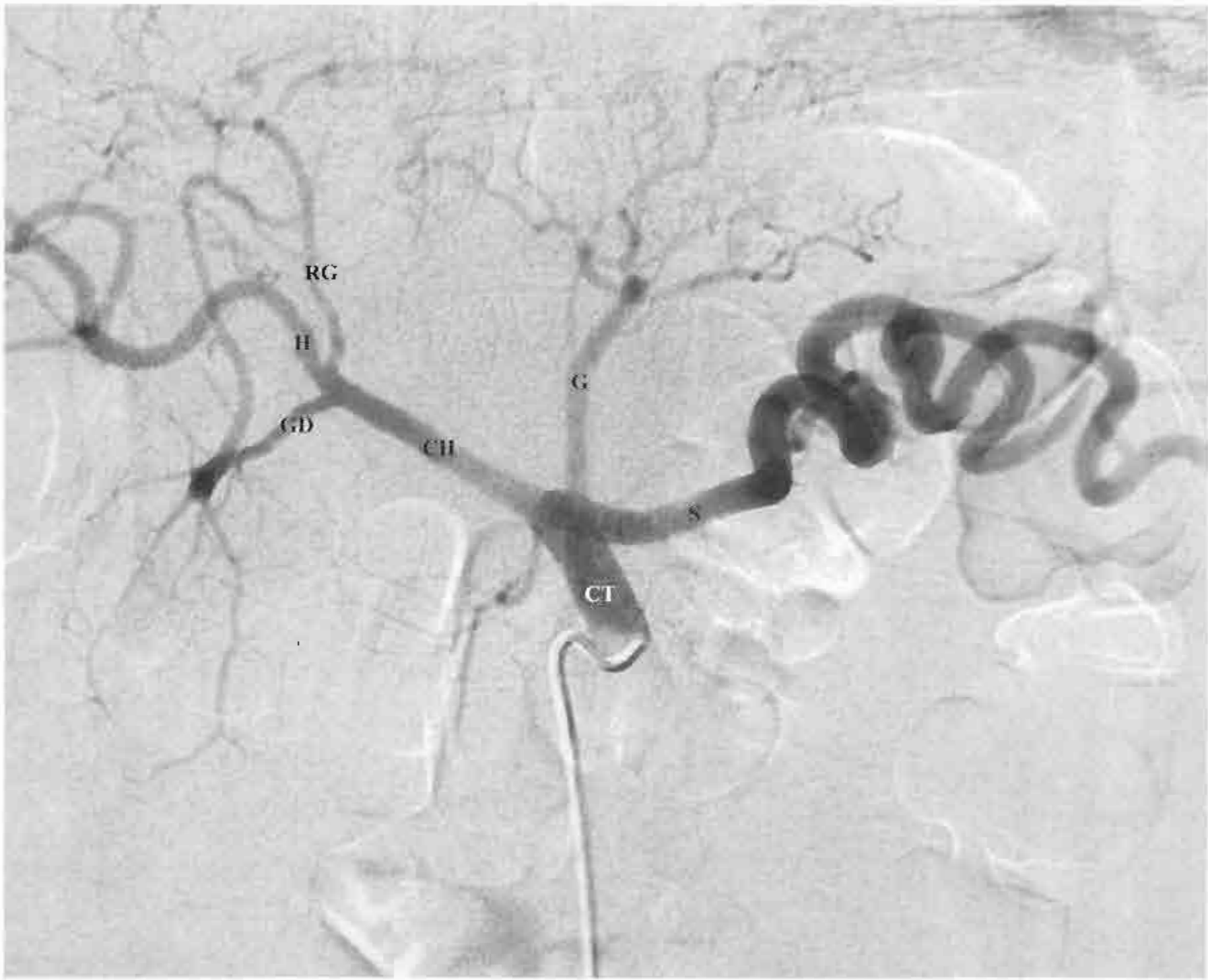


图292



- CH 肝总动脉
- CT 腹腔干
- G 胃左动脉
- GD 胃十二指肠动脉
- H 肝固有动脉
- RG 胃右动脉
- S 脾动脉



运动科学网站



运动科学网站



运动科学网站



运动科学网站



运动科学网站

大肠的动脉

直肠的动脉参见图378

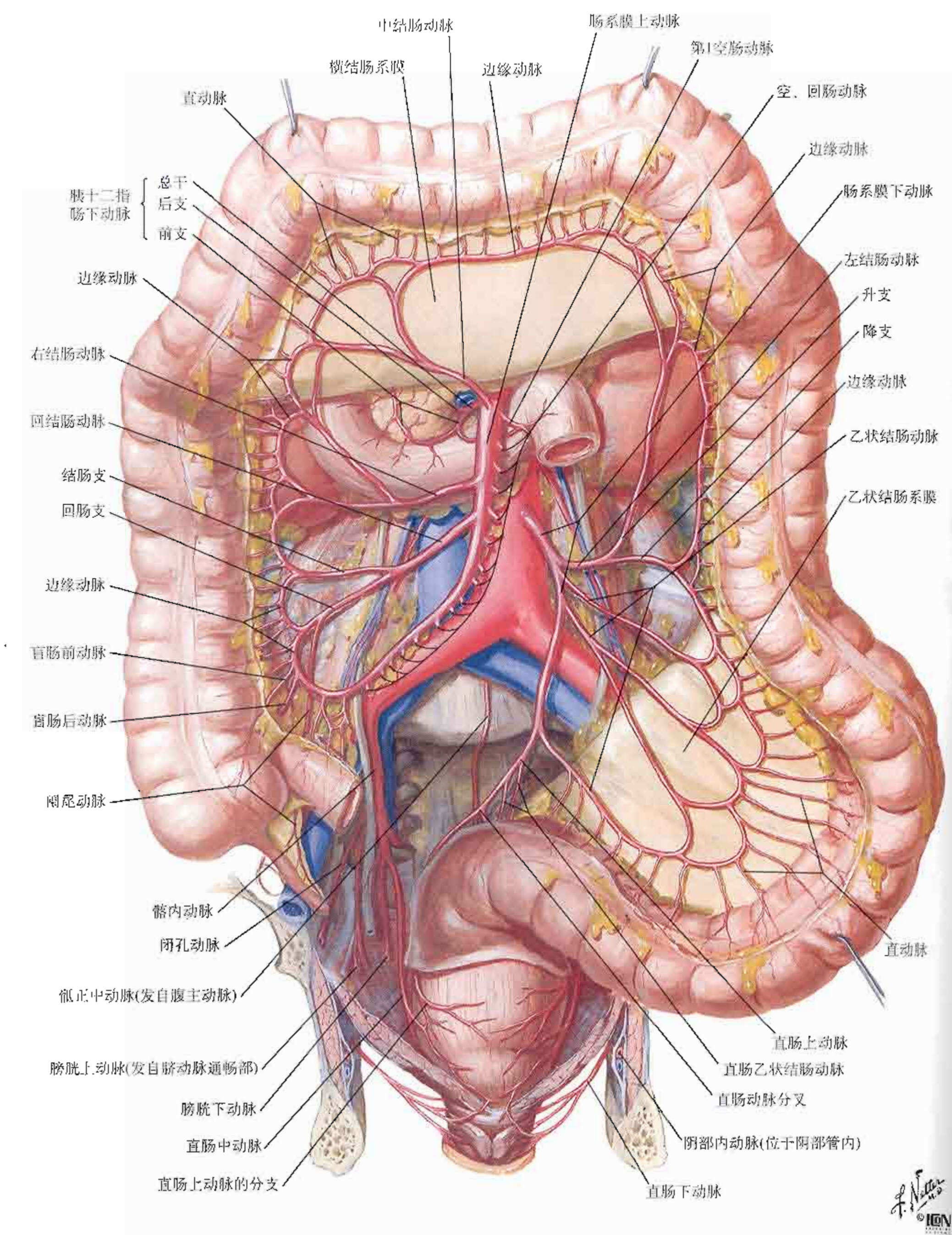
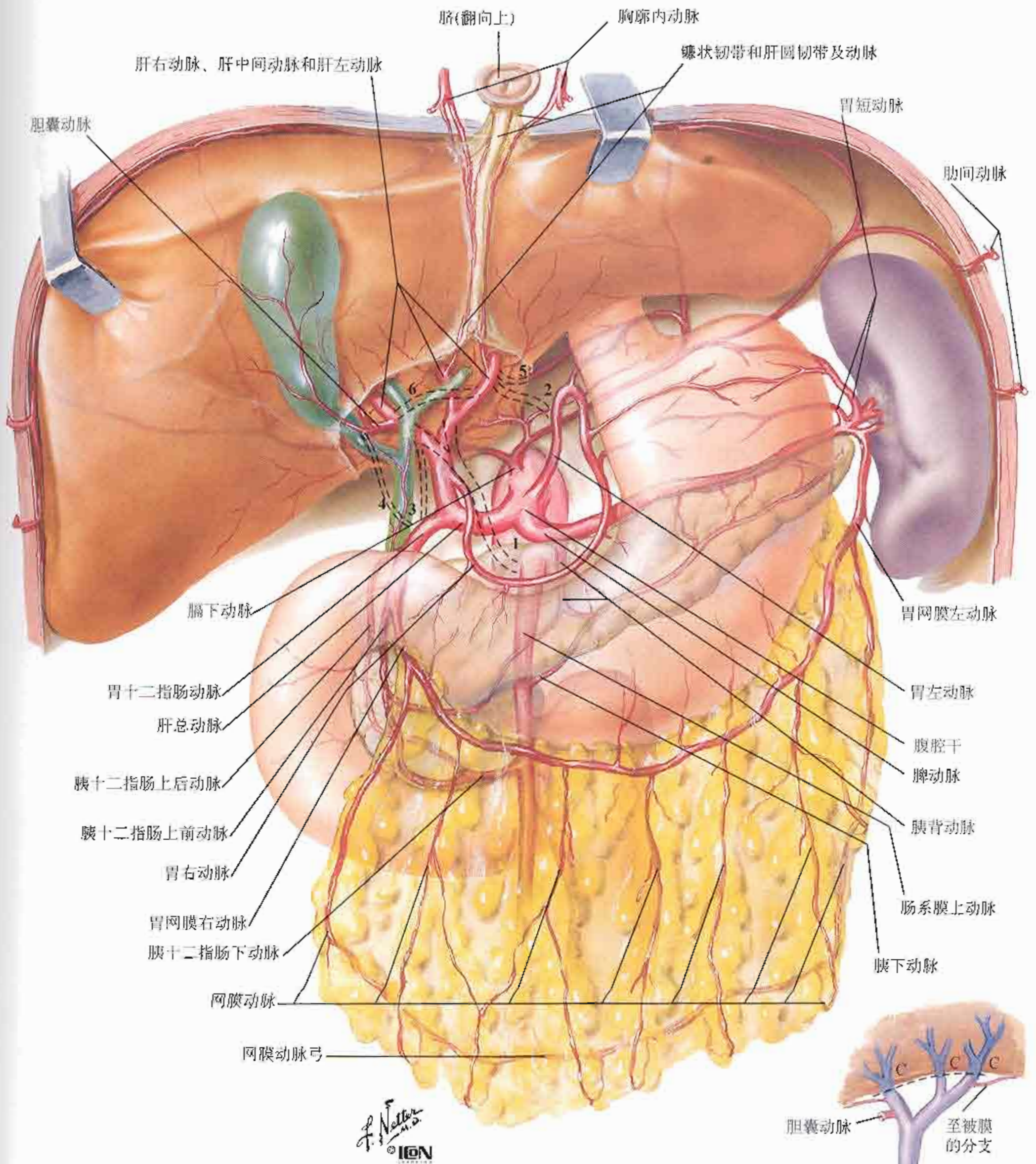


图296

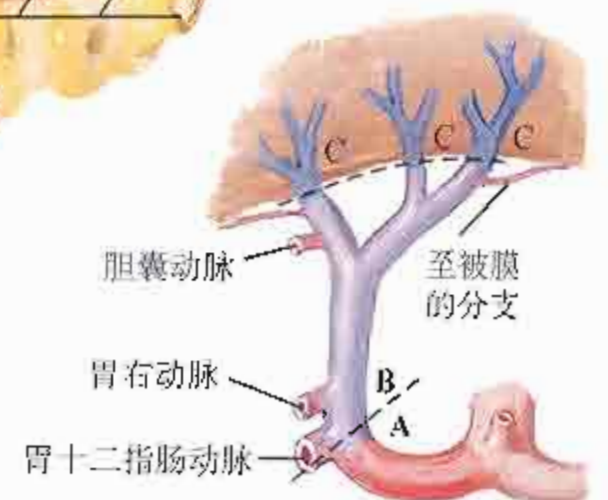


副动脉或替代动脉

1. 肝右动脉或肝总动脉
2. 肝左动脉
3. 肝右动脉
4. 胆囊动脉

相关动脉的吻合

5. 膈下动脉/胃左动脉 ↔ 肝左动脉
6. 肝右动脉 ↔ 肝左动脉



肝动脉堵塞后的影响

- A. 相对安全区
- B. 可能受影响区
- C. 必然梗塞区

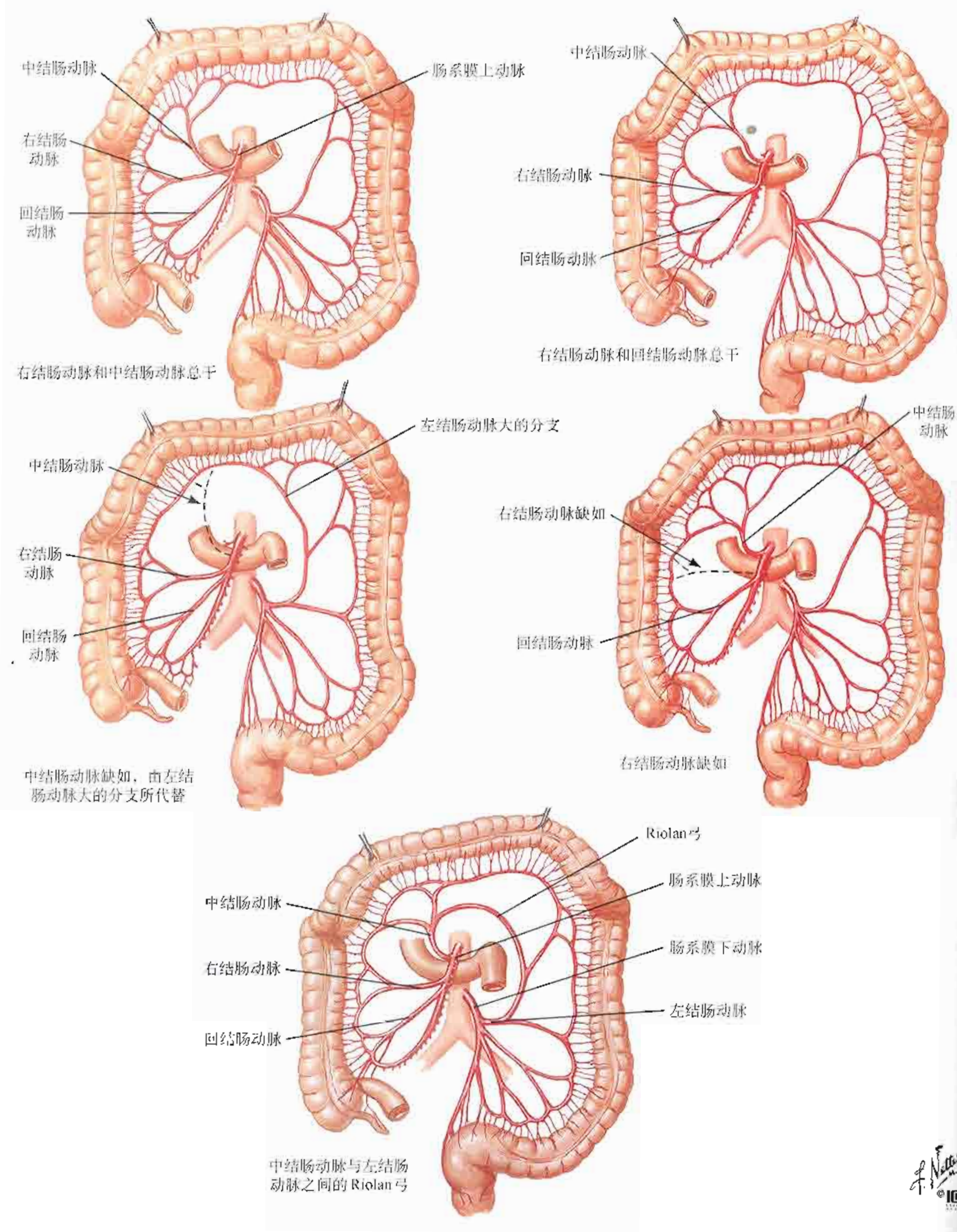
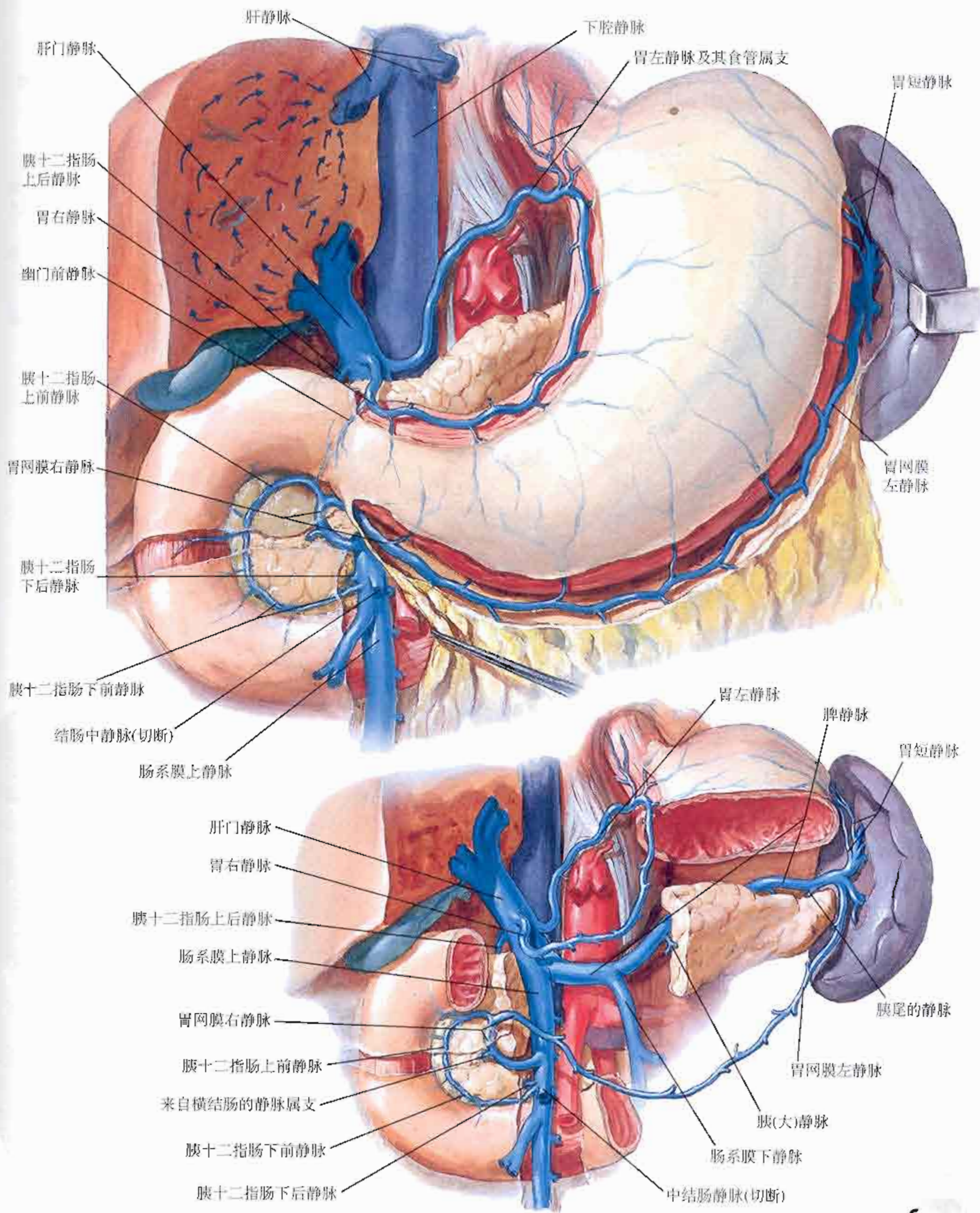


图298



F. Netter M.D.
© IGCN

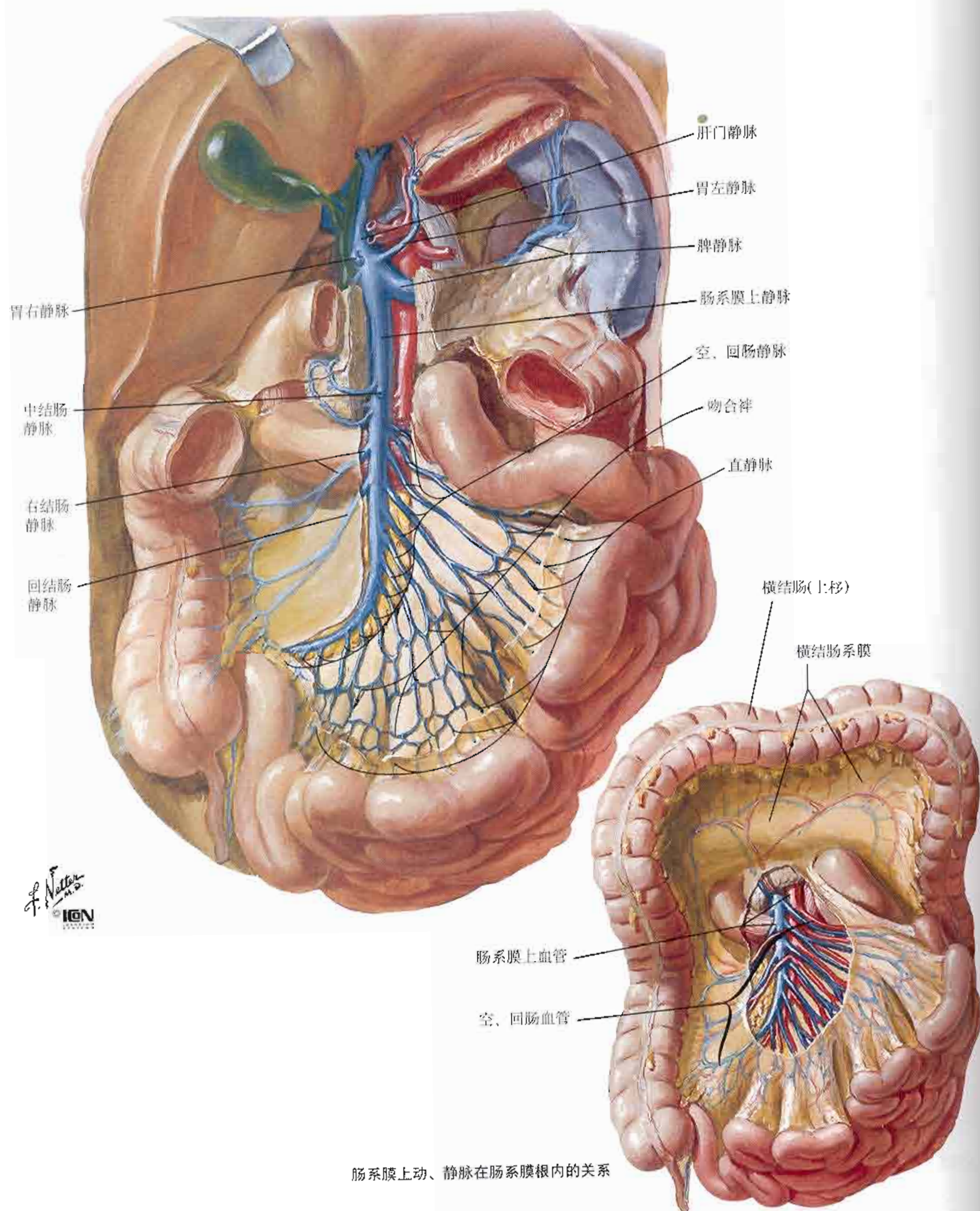
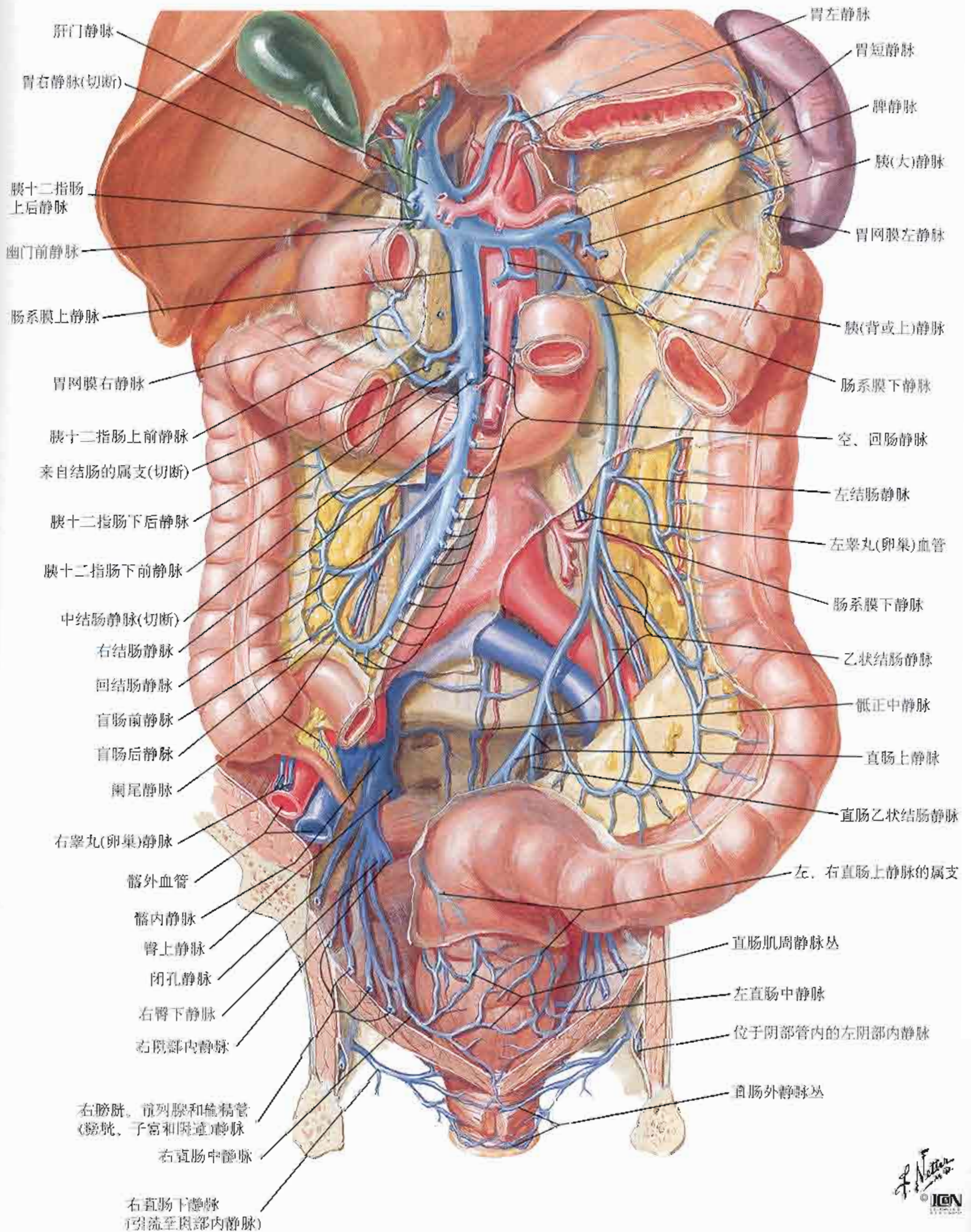
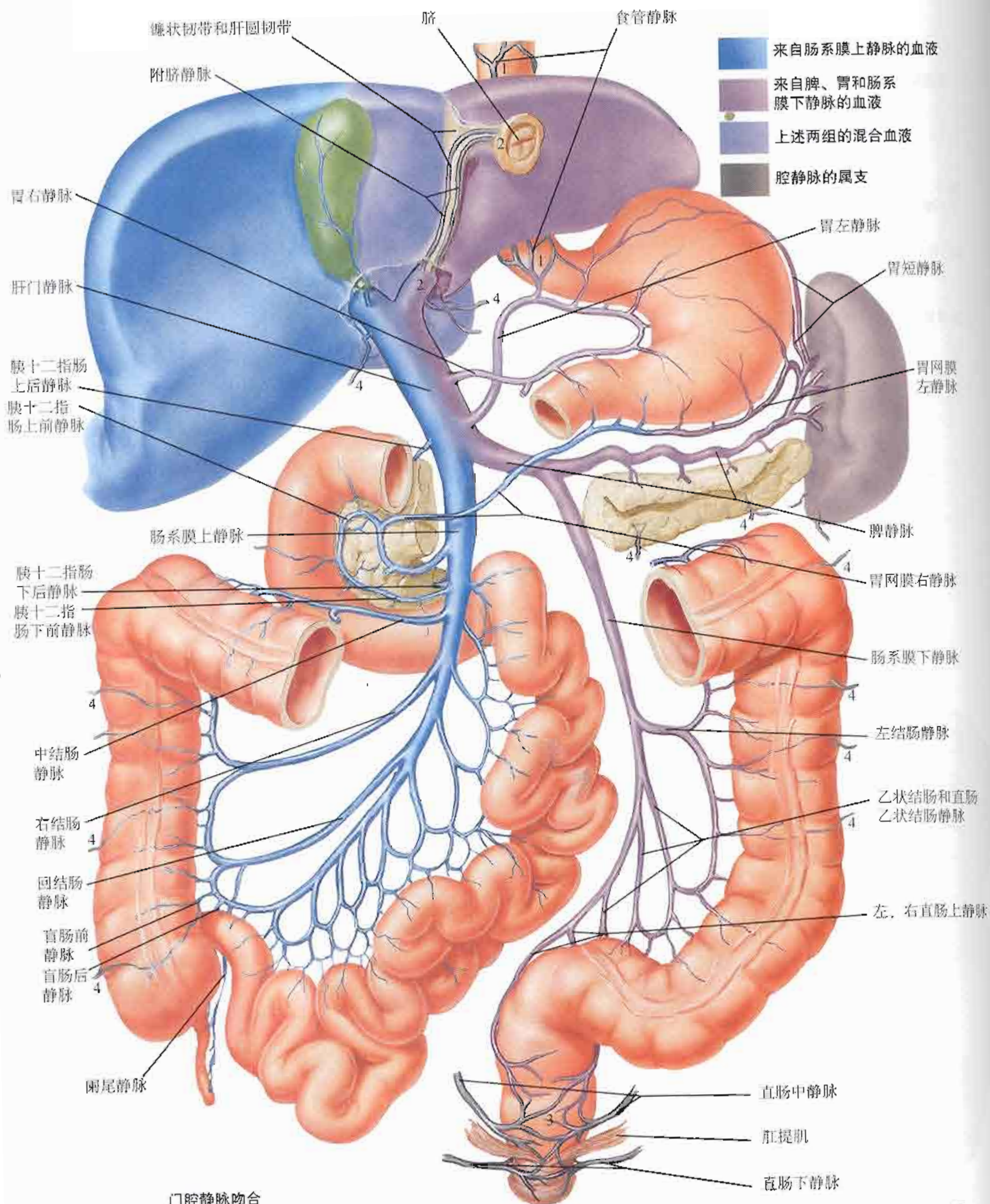


图300

直肠的静脉参见图379



肝门静脉的属支：门腔静脉吻合



- 门腔静脉吻合
- 1 食管静脉丛
 - 2 脐周静脉网
 - 3 直肠静脉丛
 - 4 腹膜后小静脉

图302

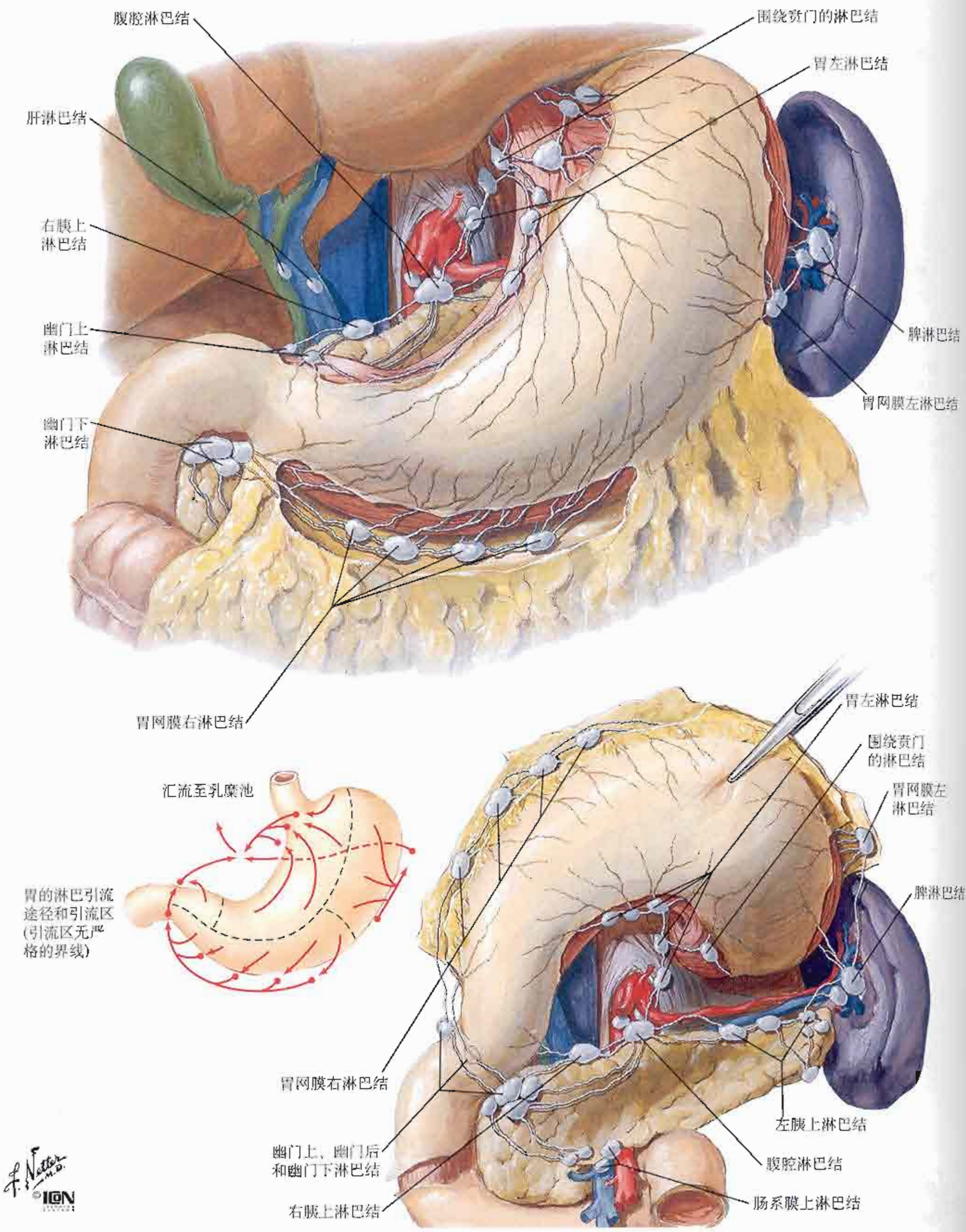
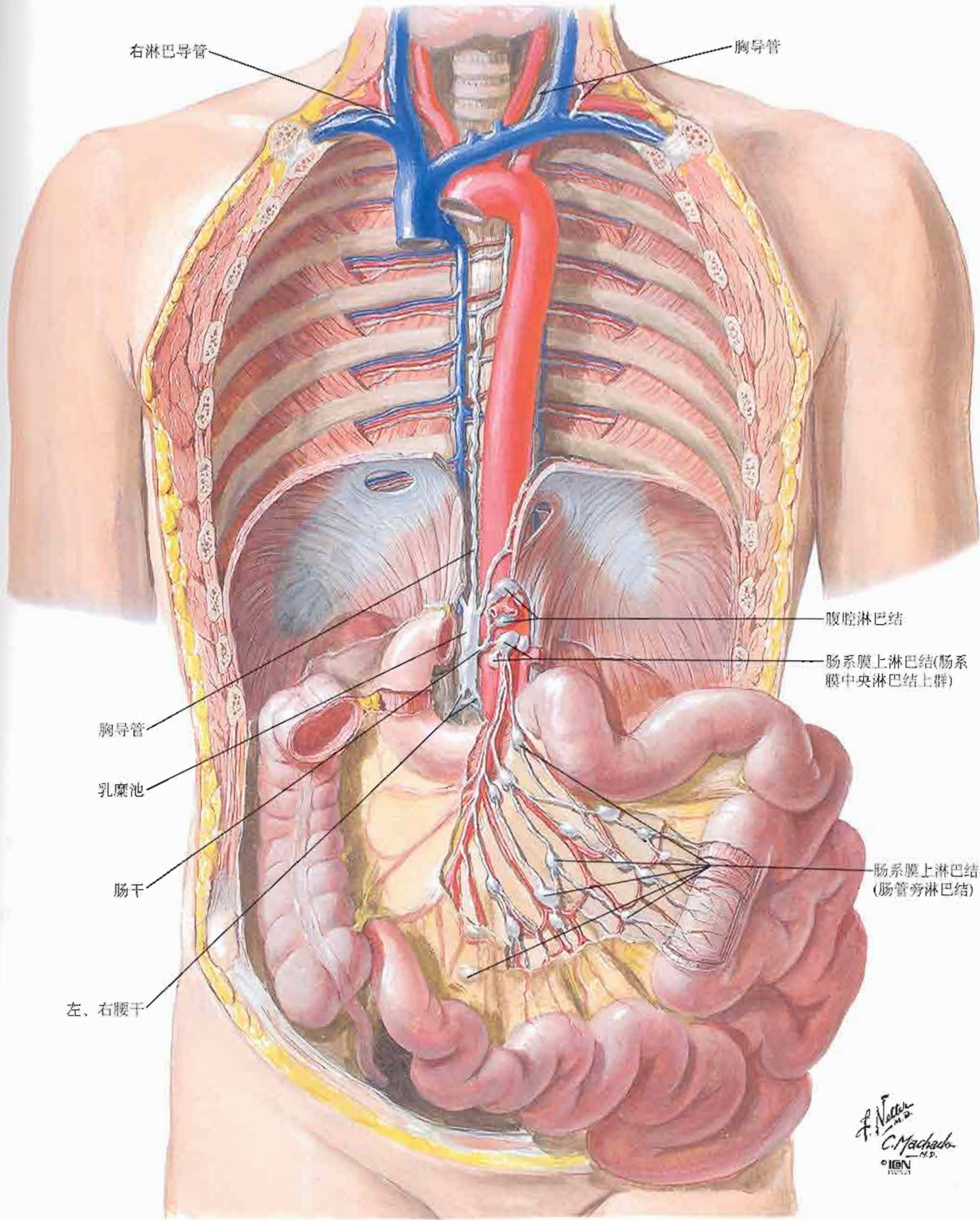


图304



内脏的血管

图305

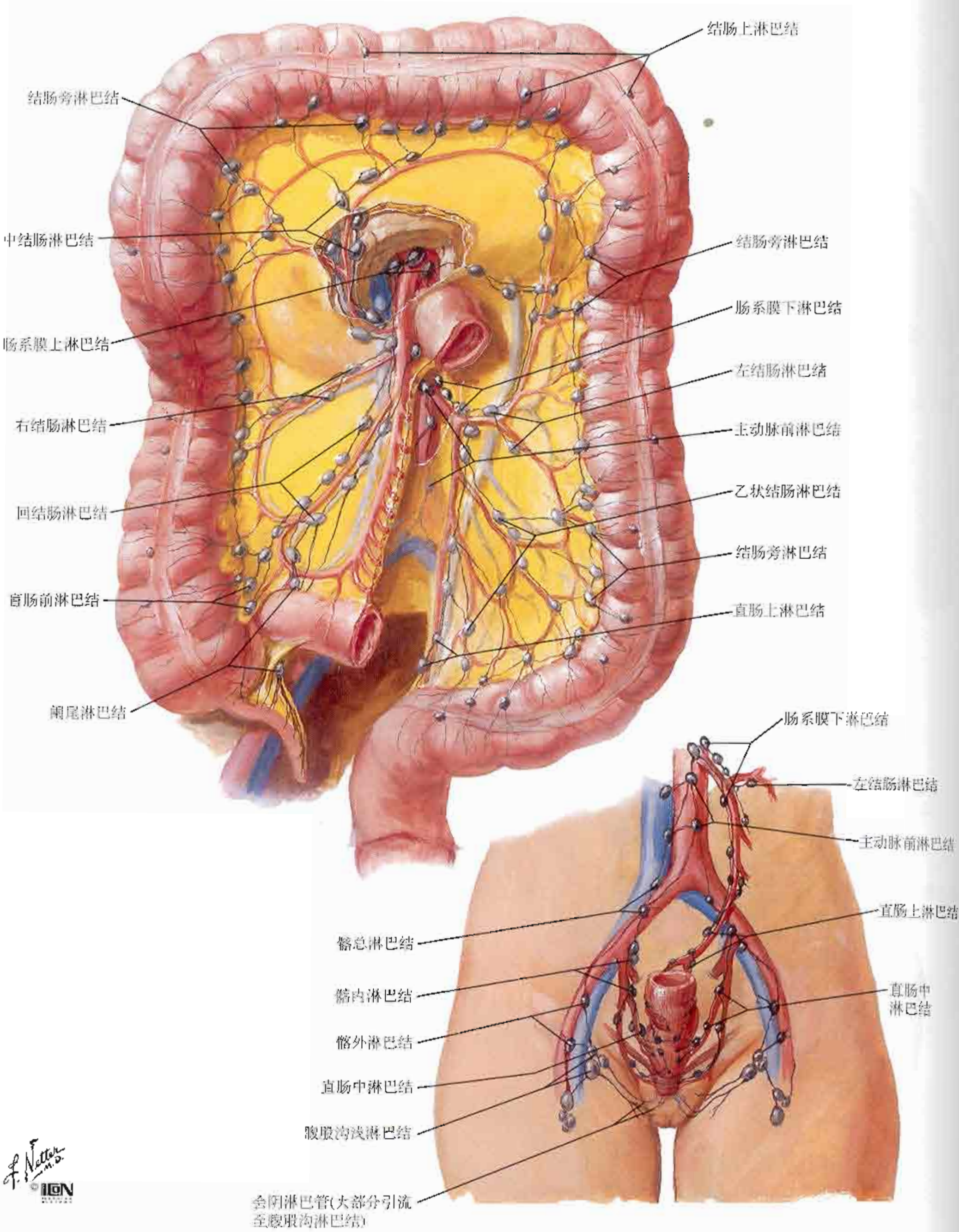
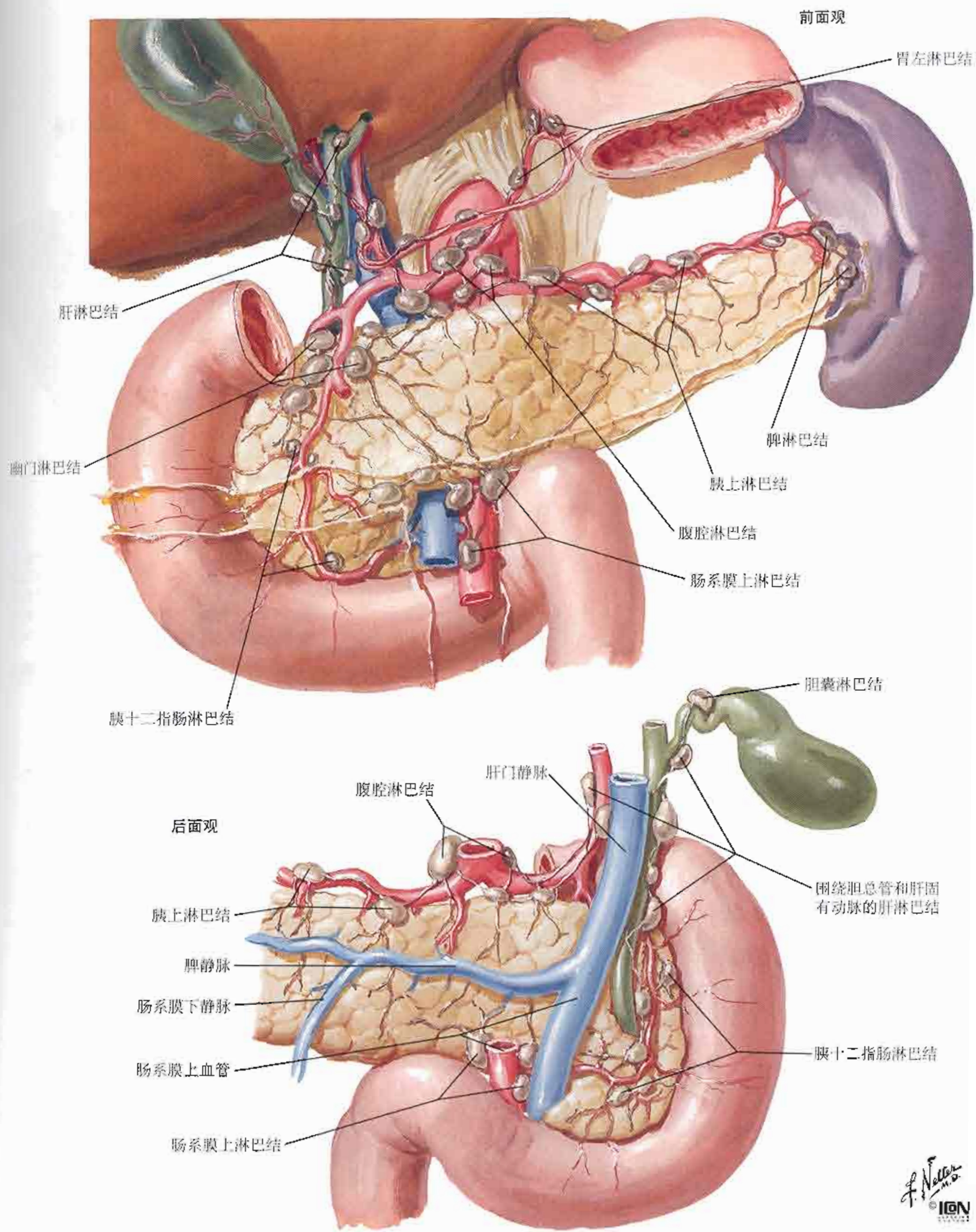


图306





运动科学网站



运动科学网站



运动科学网站

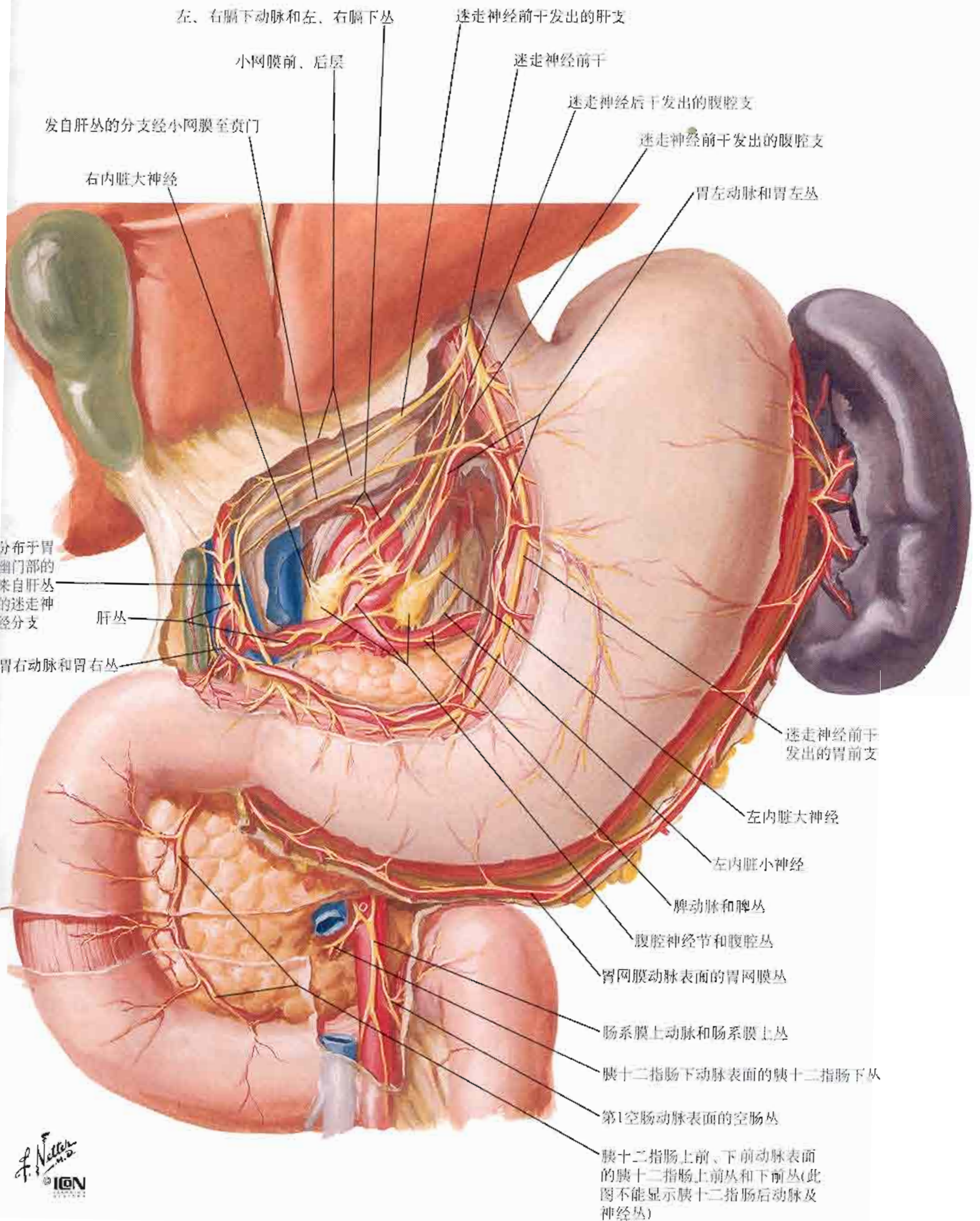


运动科学网站



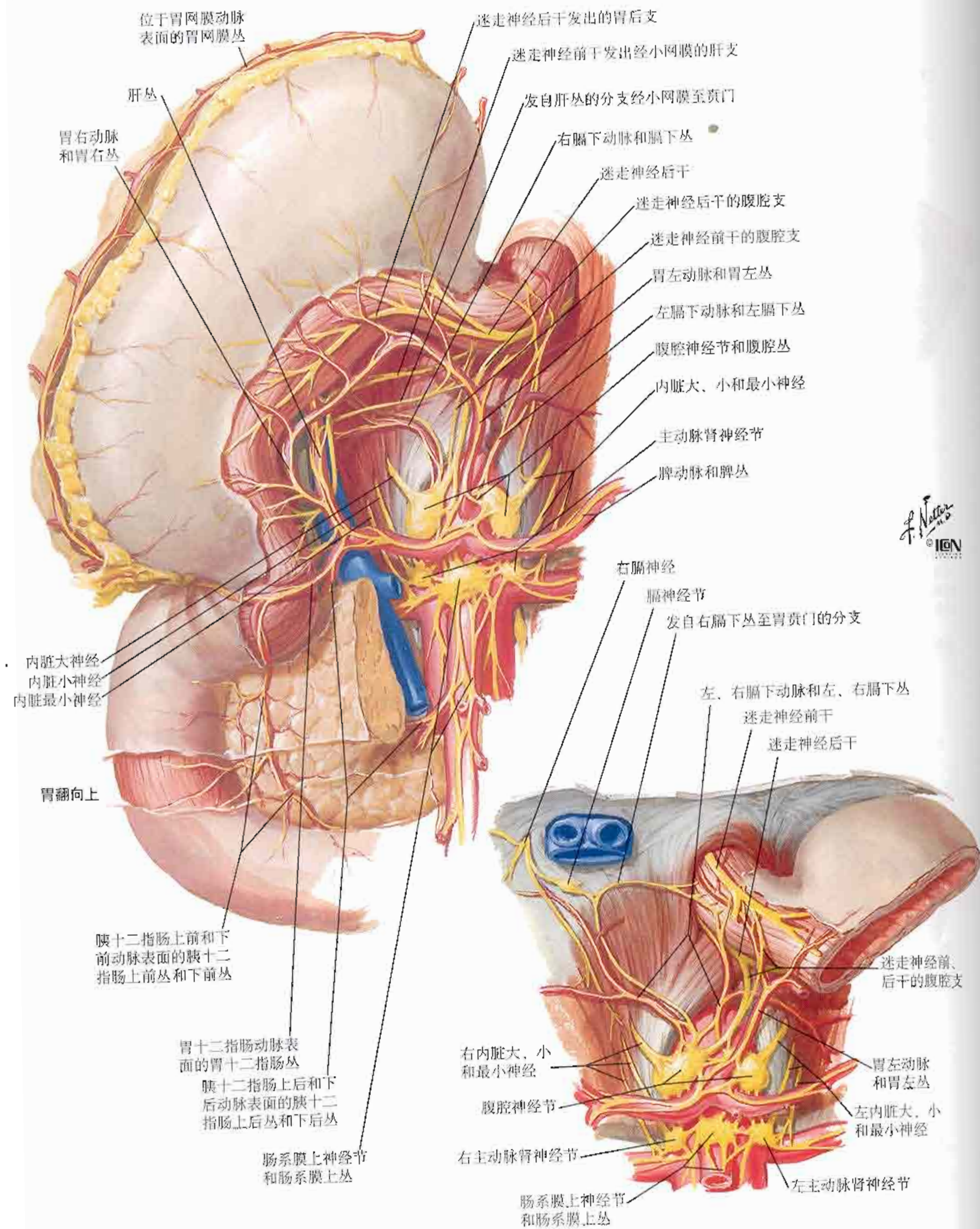
运动科学网站

www.vo2maxcn.com



胃和十二指肠的神经 (续)

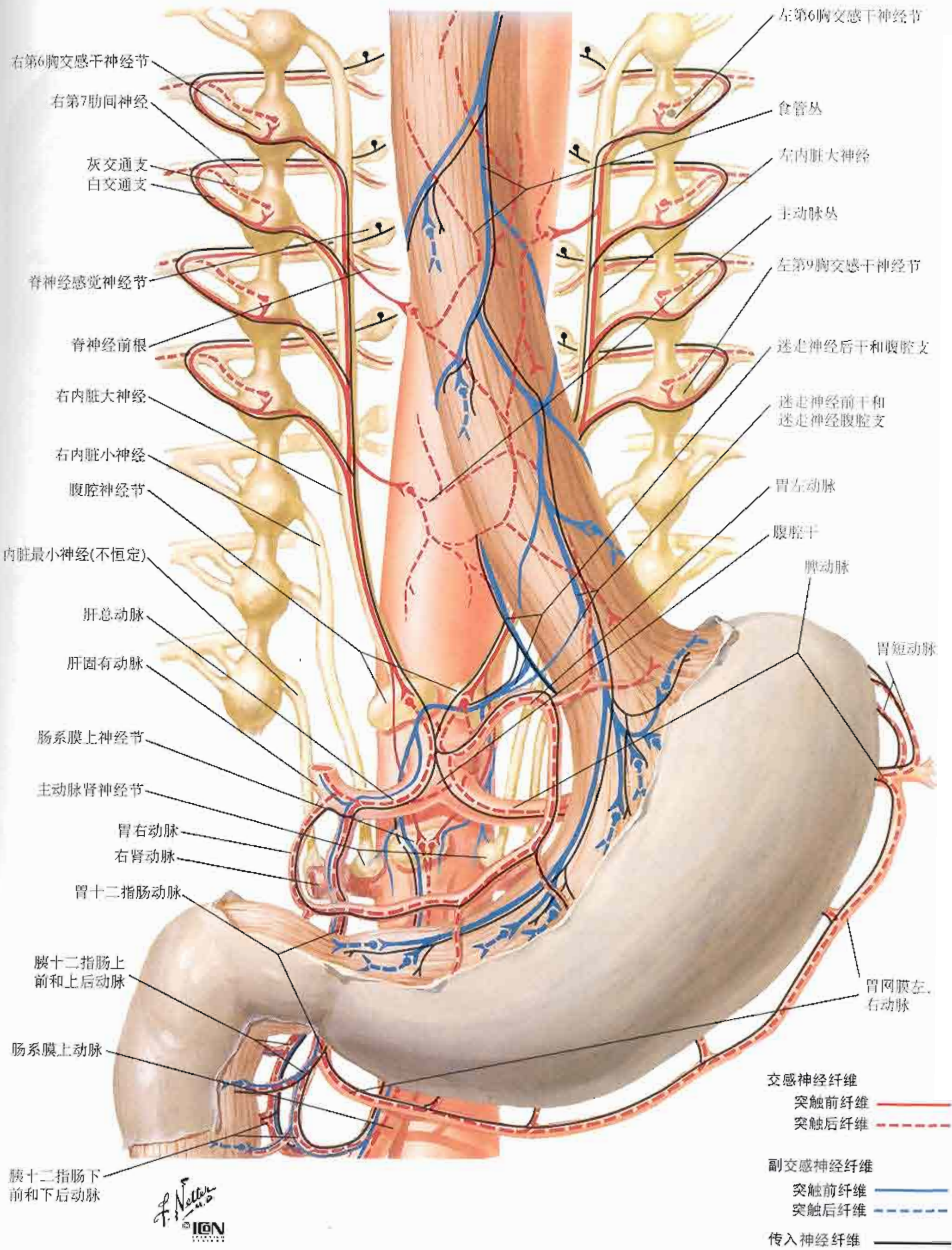
参见图159



F. Netter M.D.
© IGCN

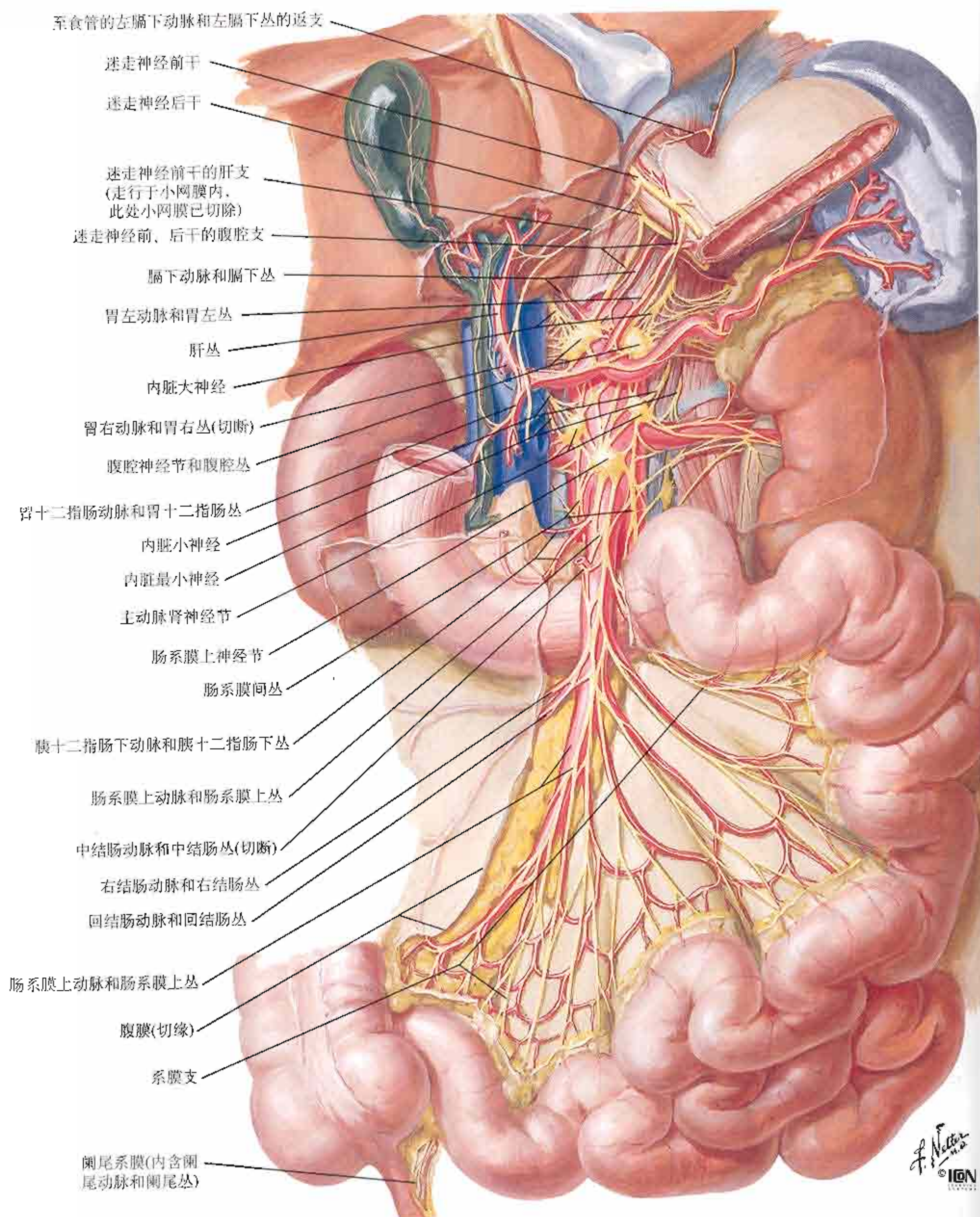
图310

腹部



小肠的神经

参见图159

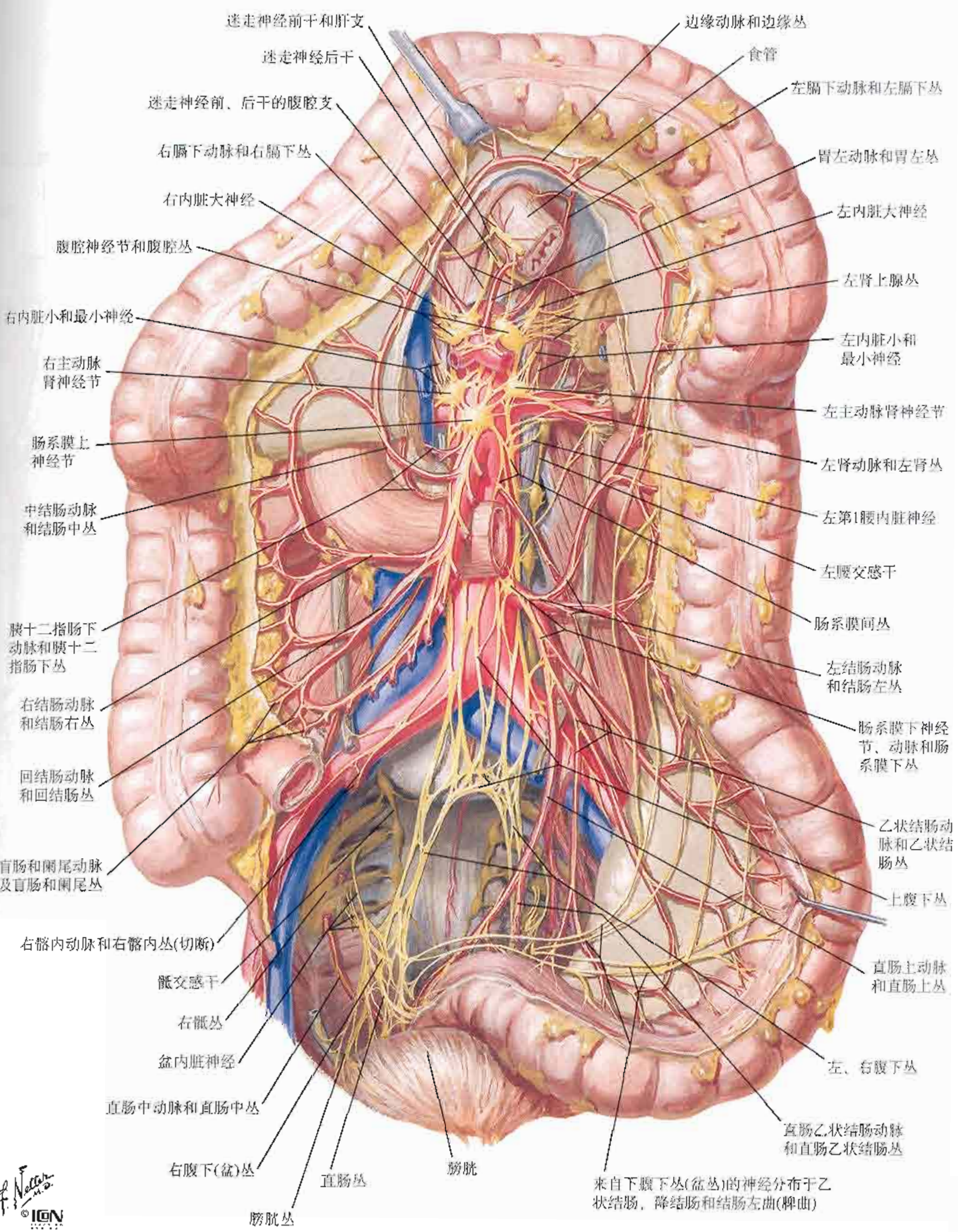


F. Netter M.D.
© IGM

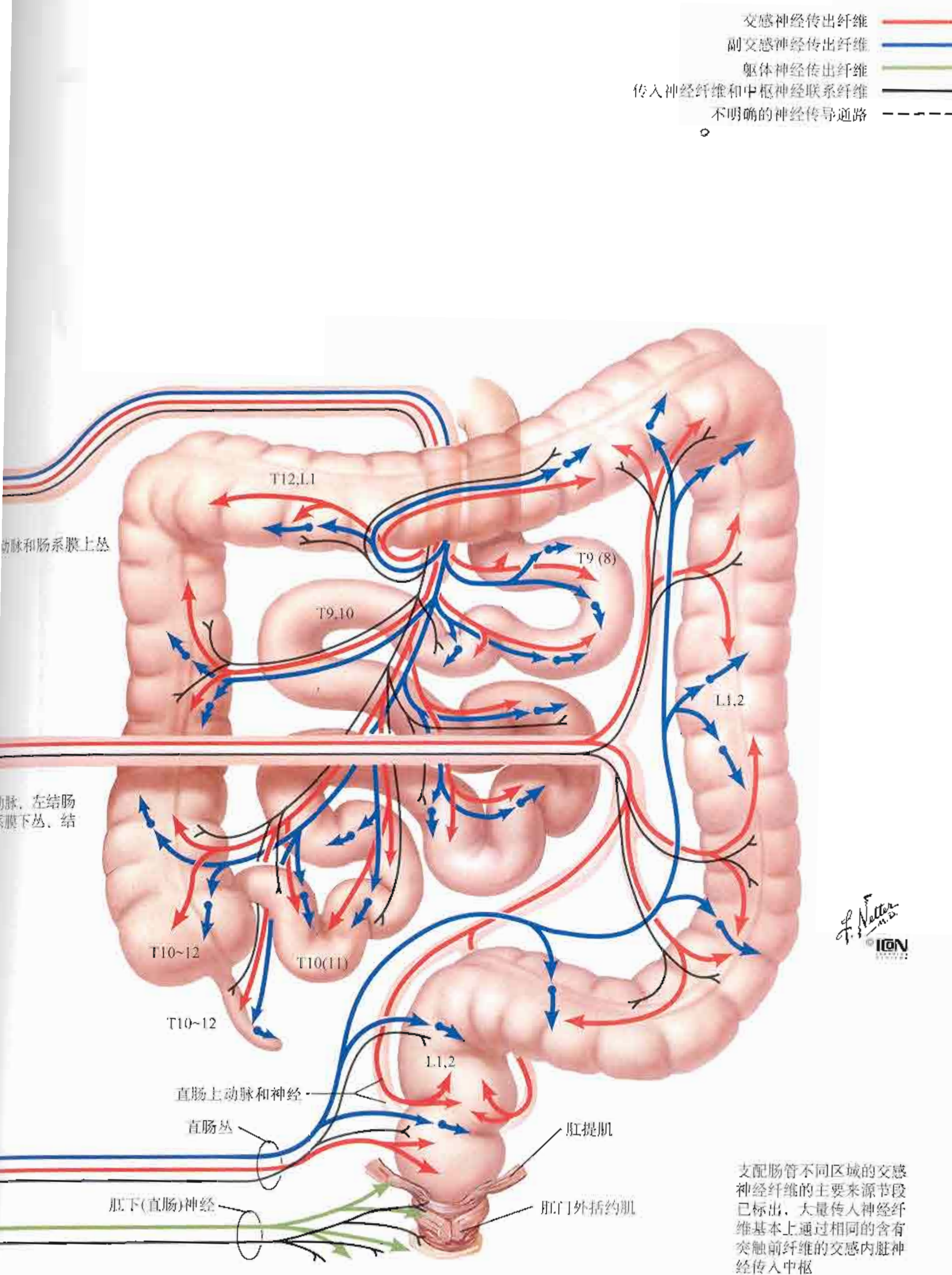
图312

腹部

直肠的神经参见图159、390~393



参见图160





运动科学网站



运动科学网站



运动科学网站

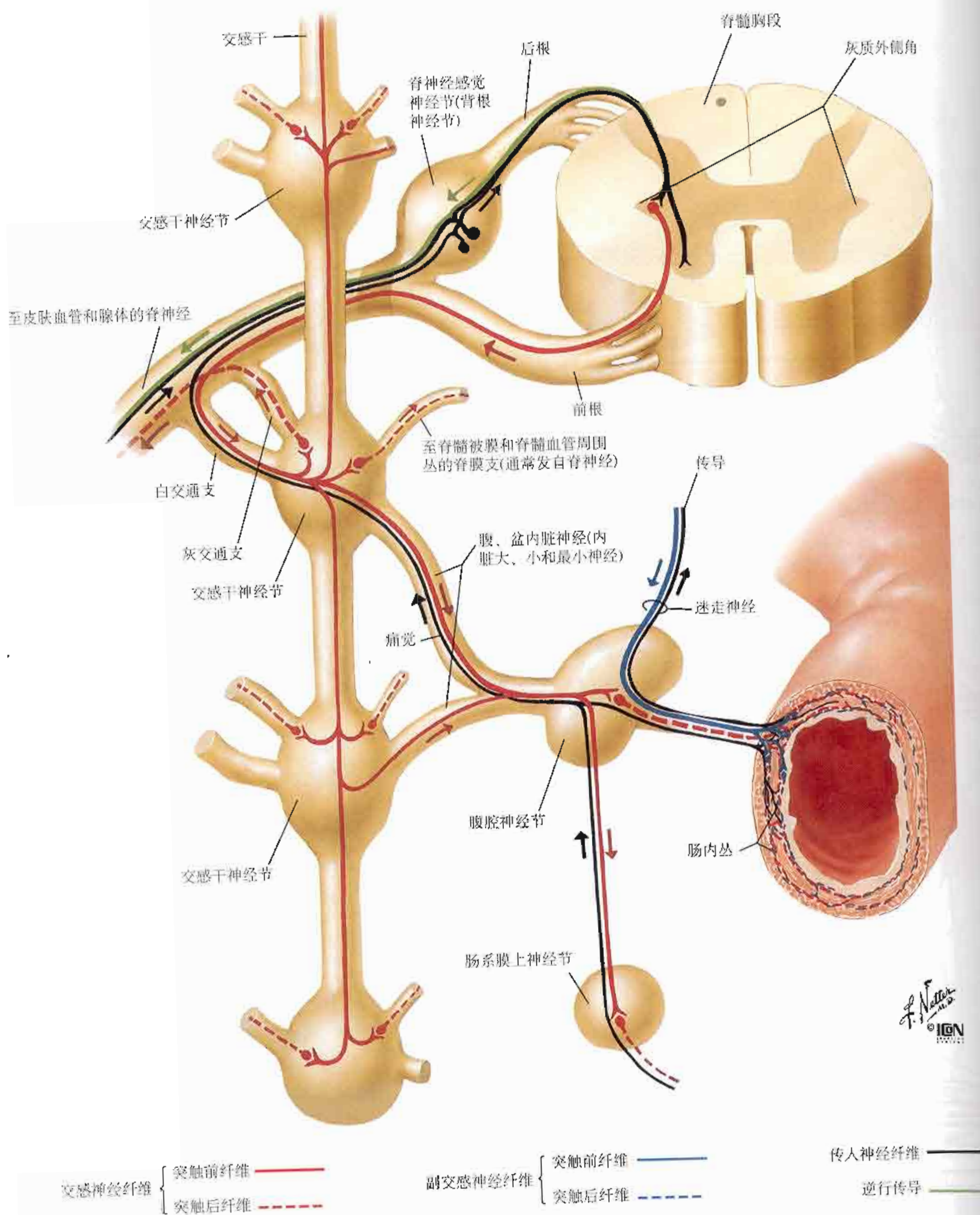


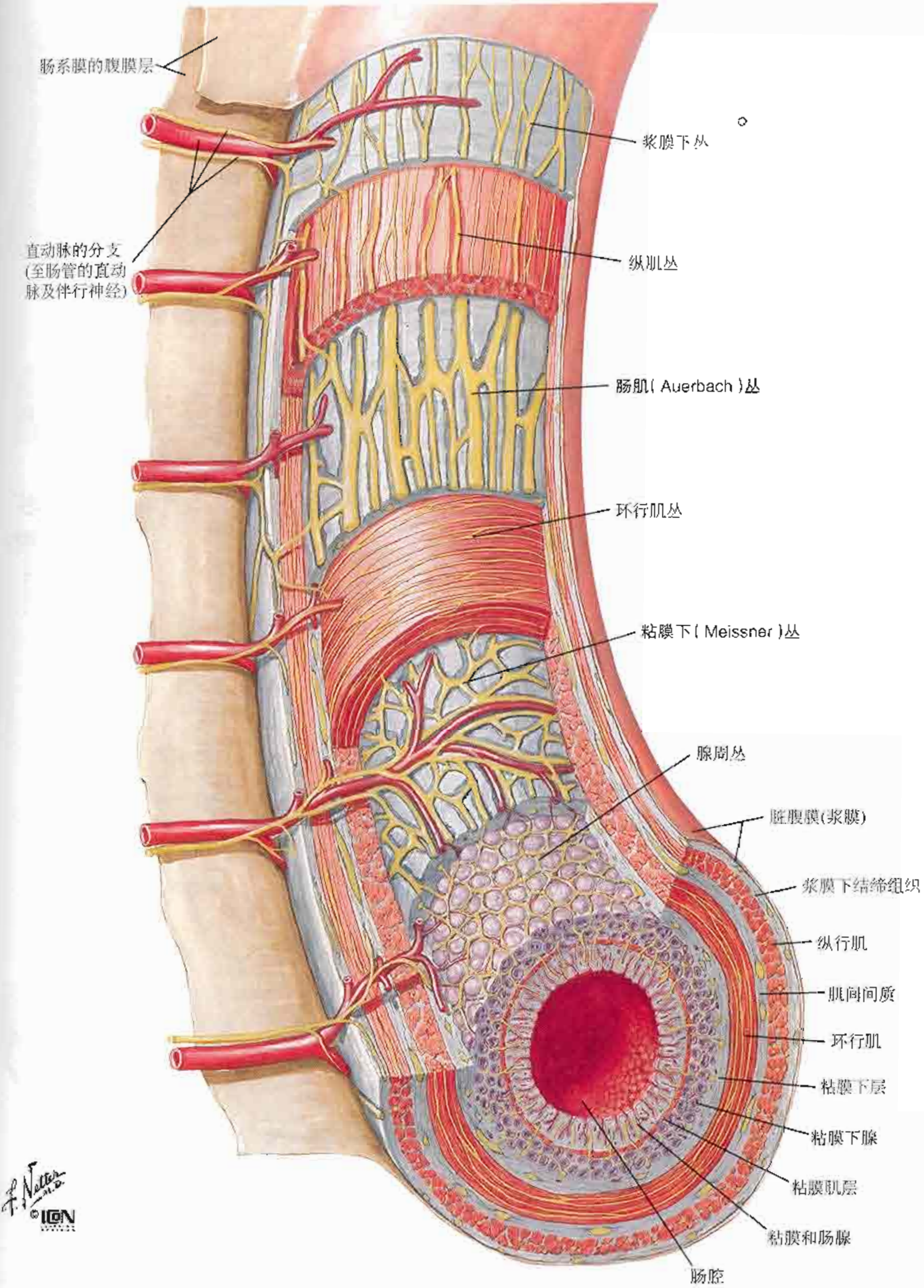
运动科学网站



运动科学网站

www.vo2maxcn.com

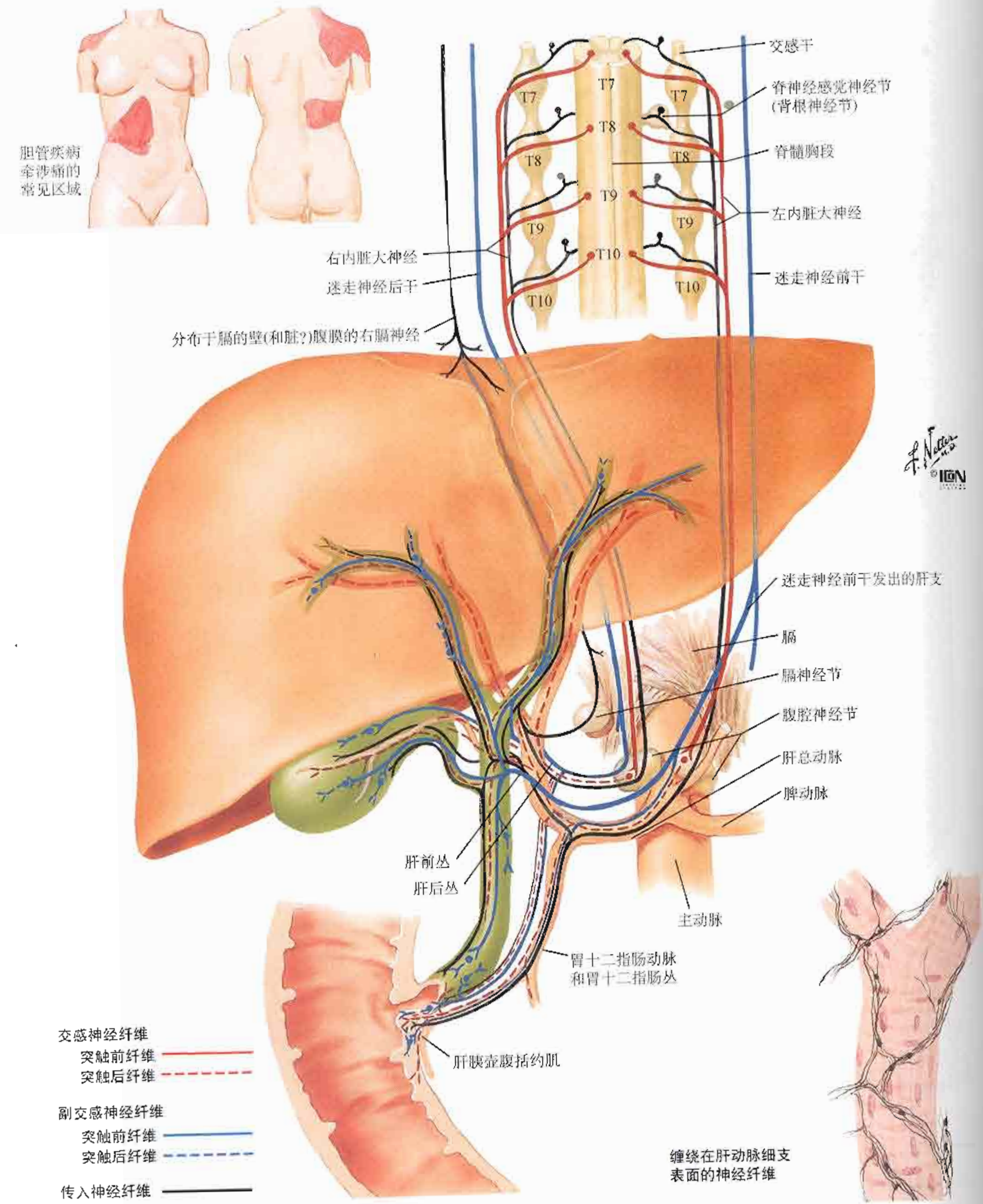




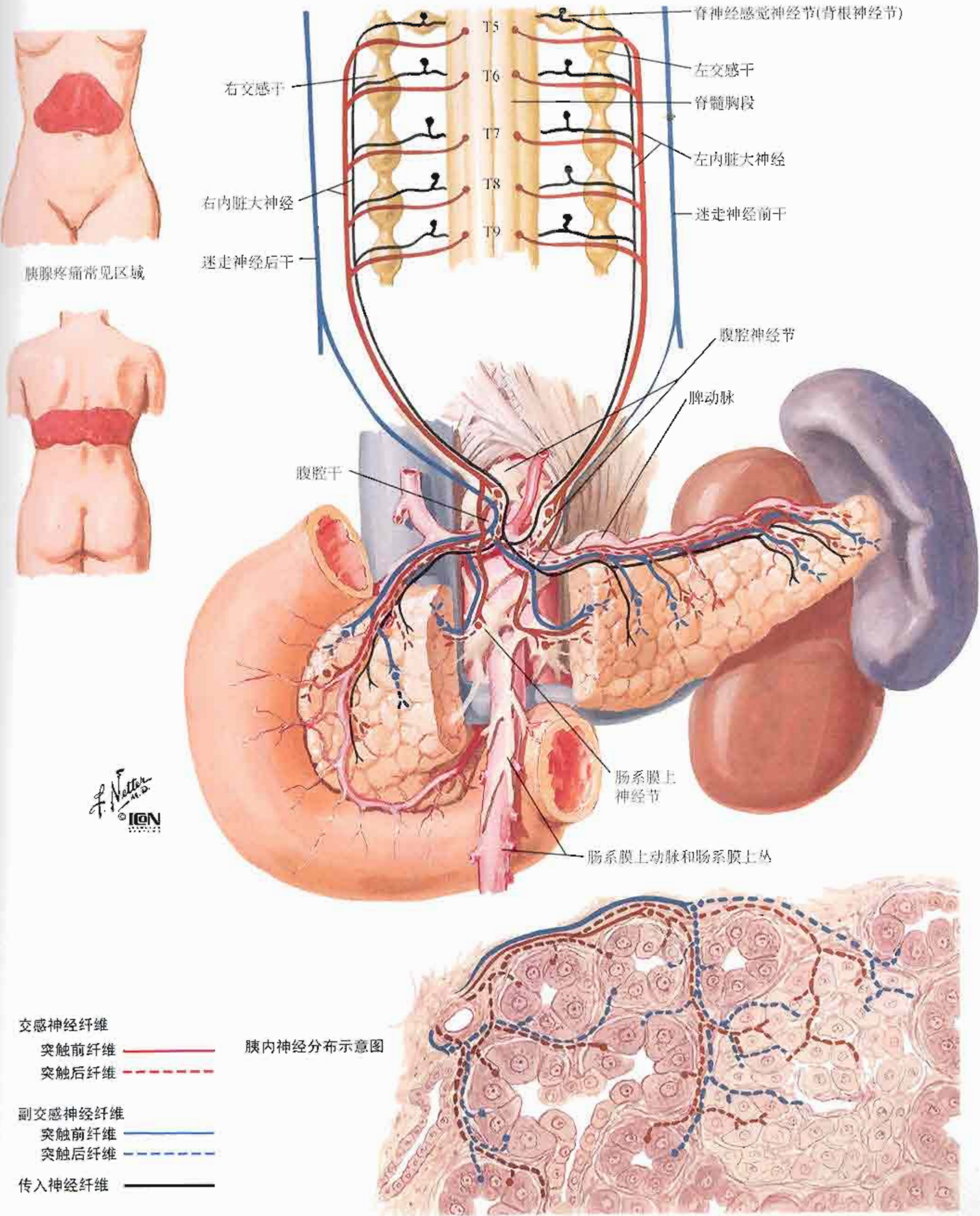
注：肠壁显示比实际的厚

肝、胆管的神经分布：示意图

参见图160



参见图160



肾(原位): 前面观

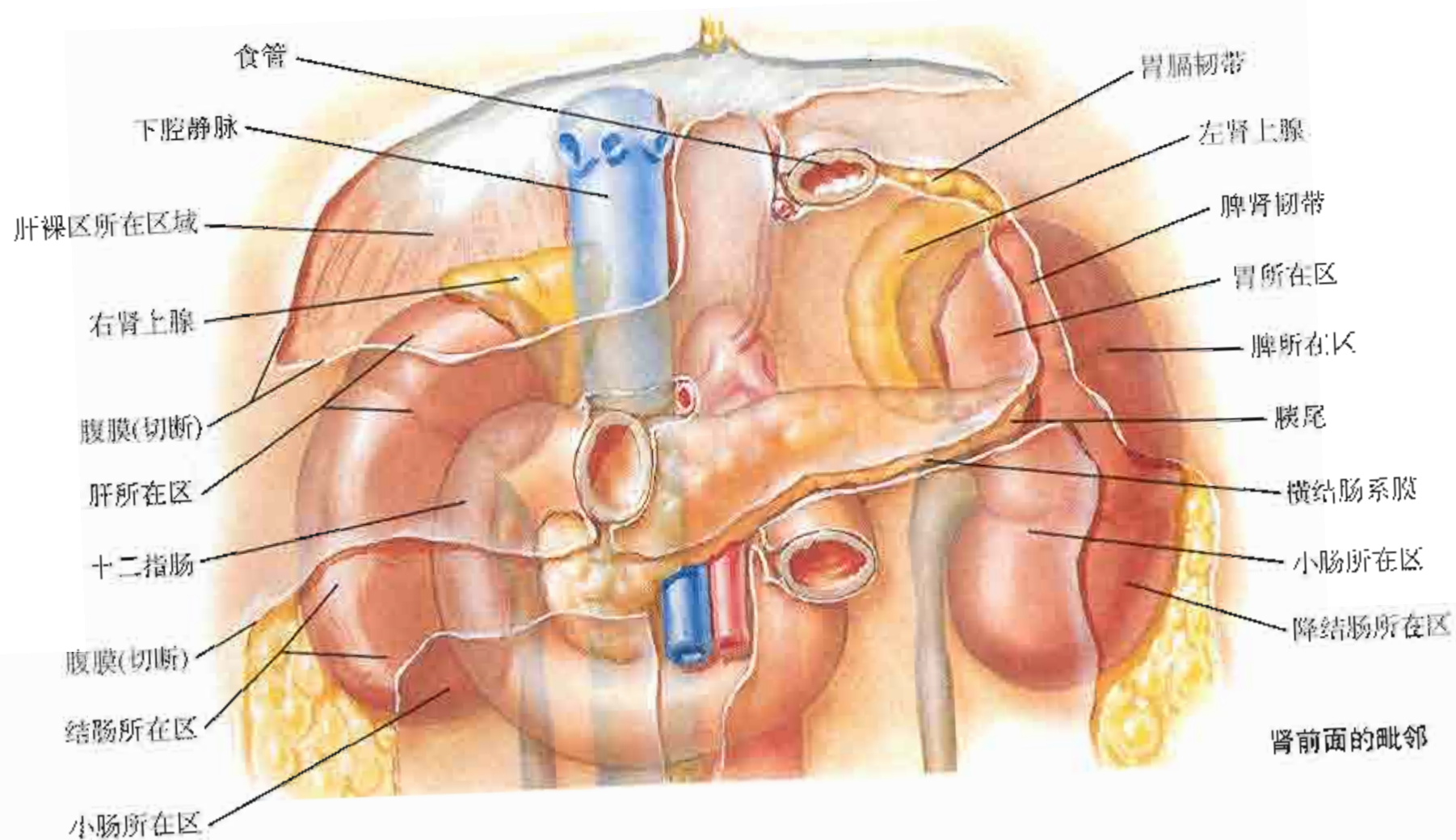
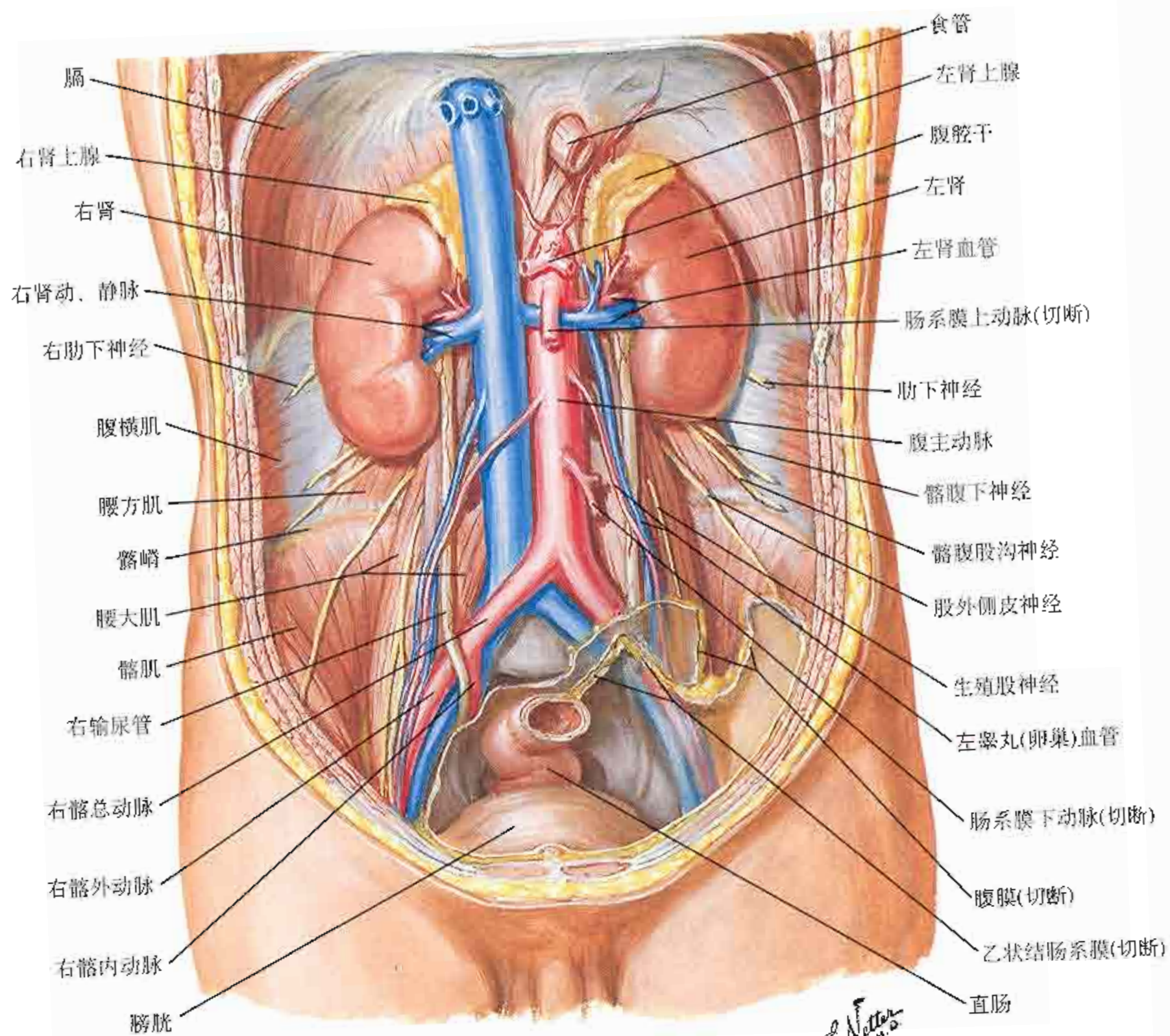
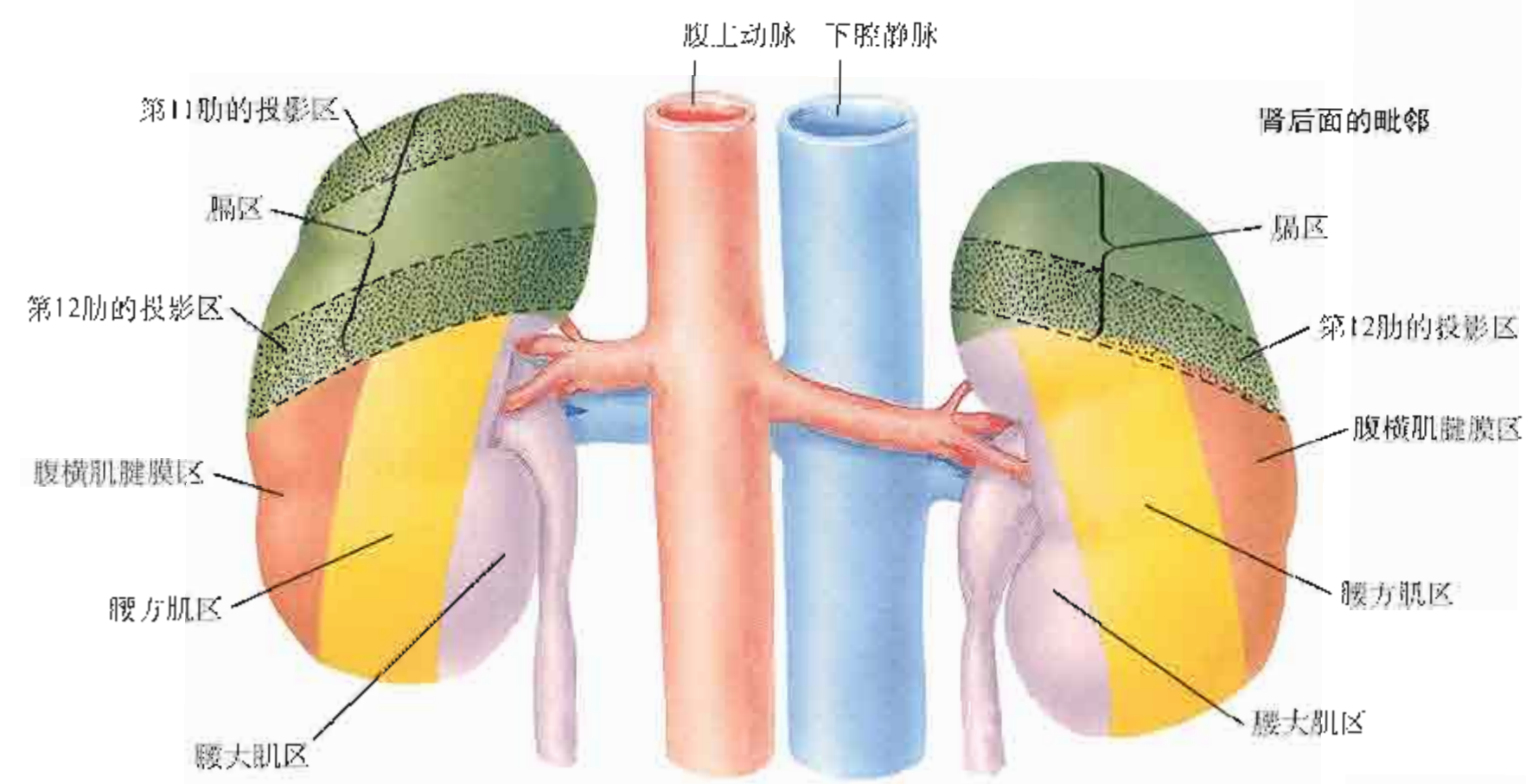
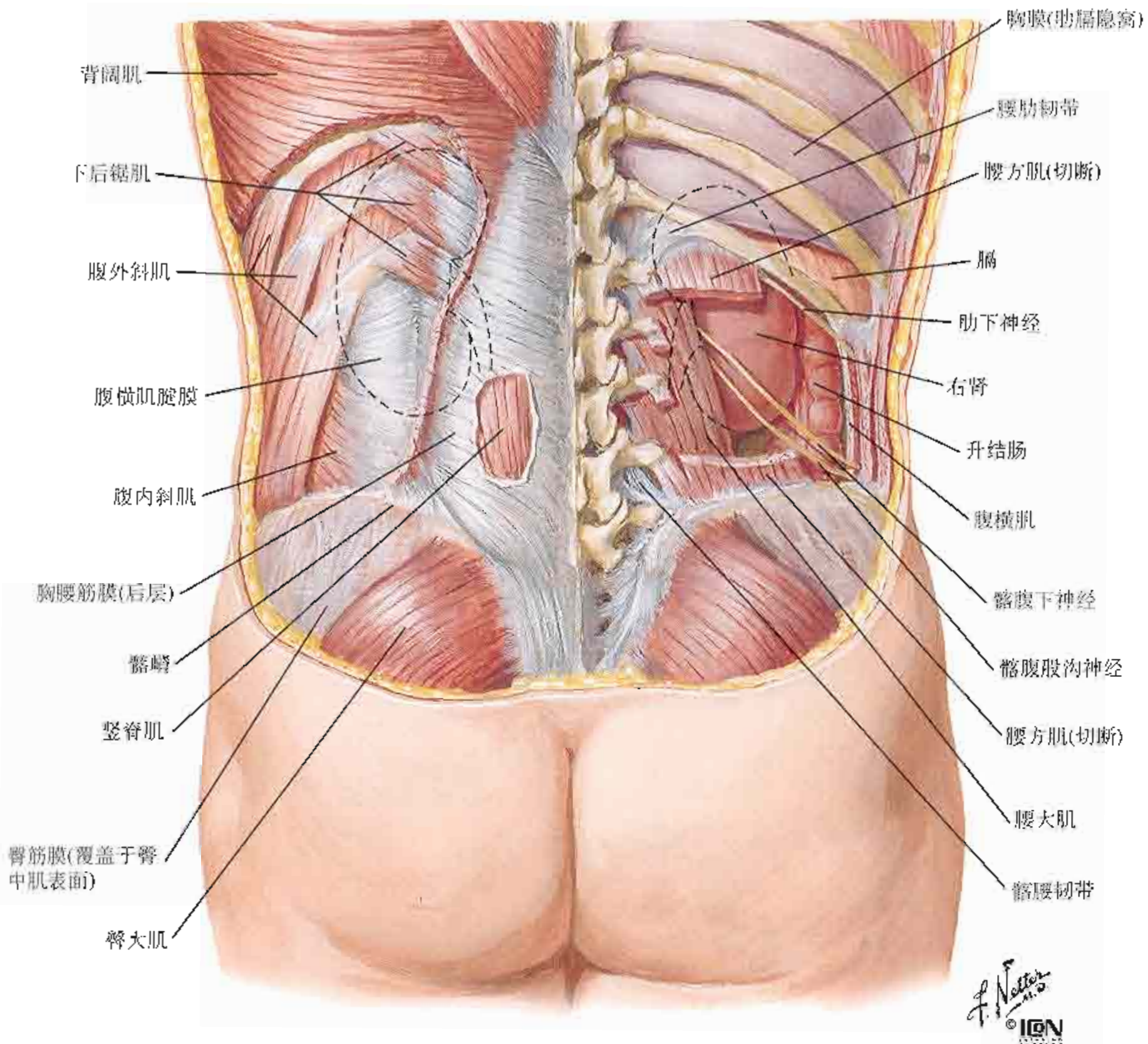
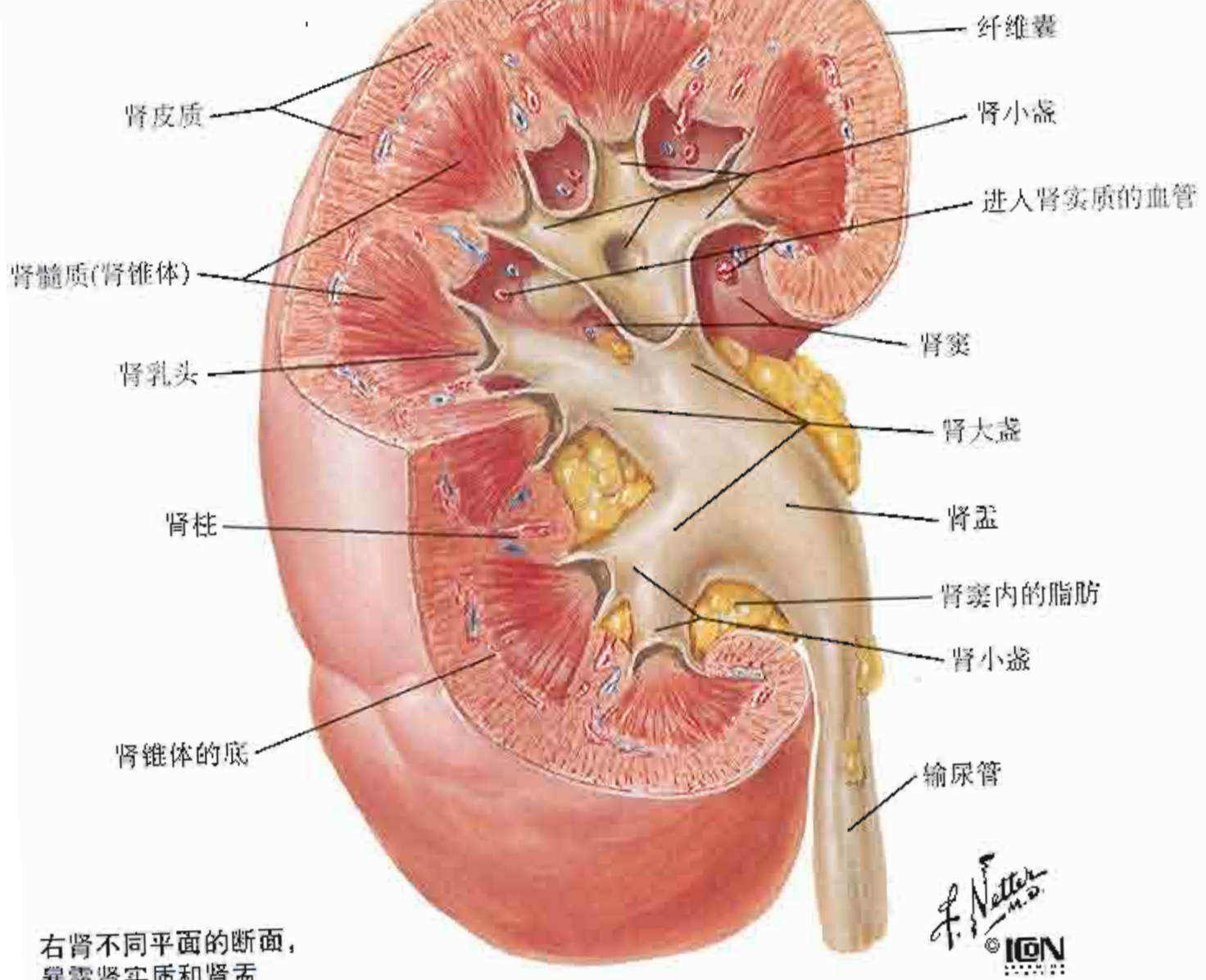
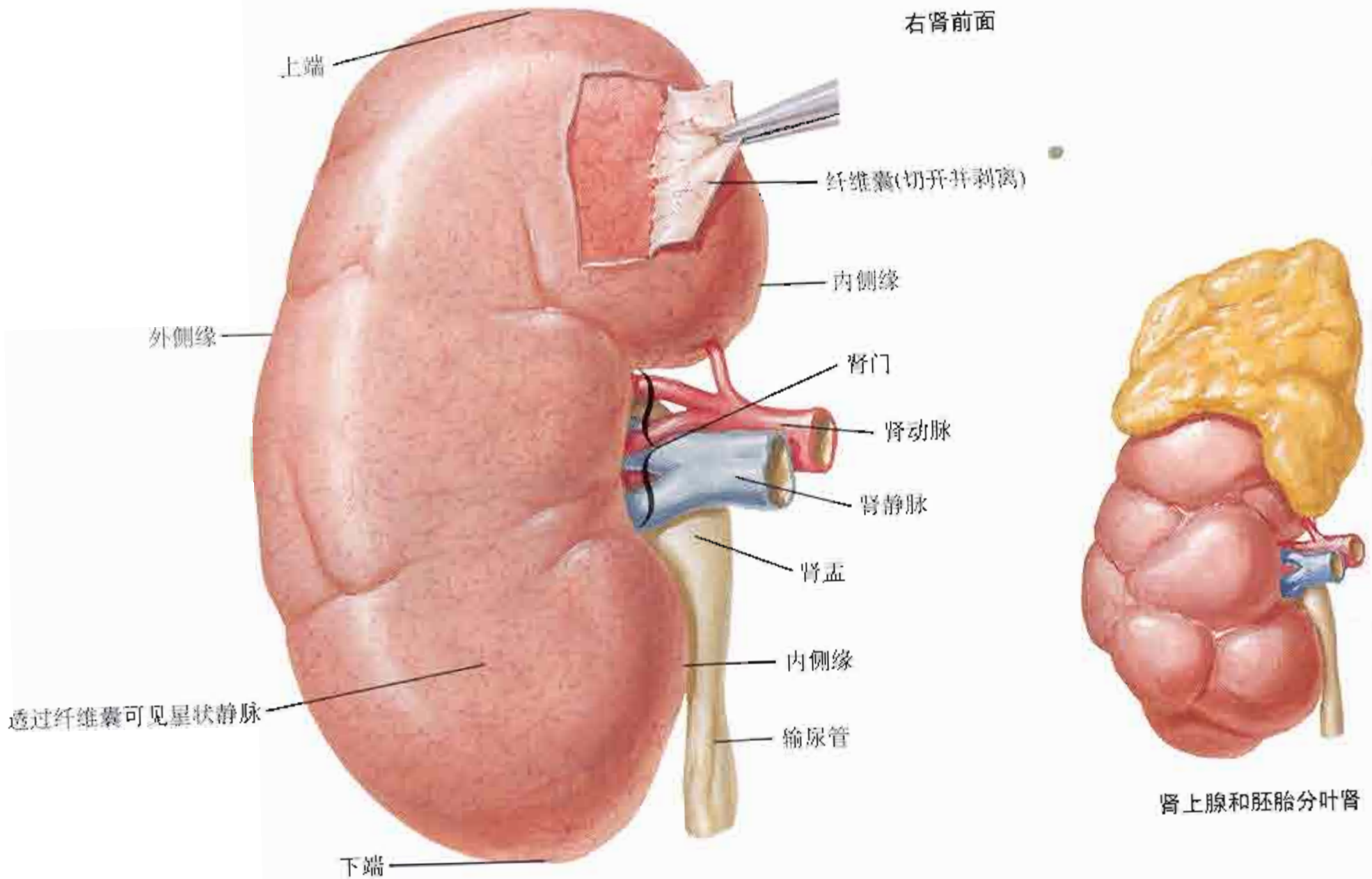


图319



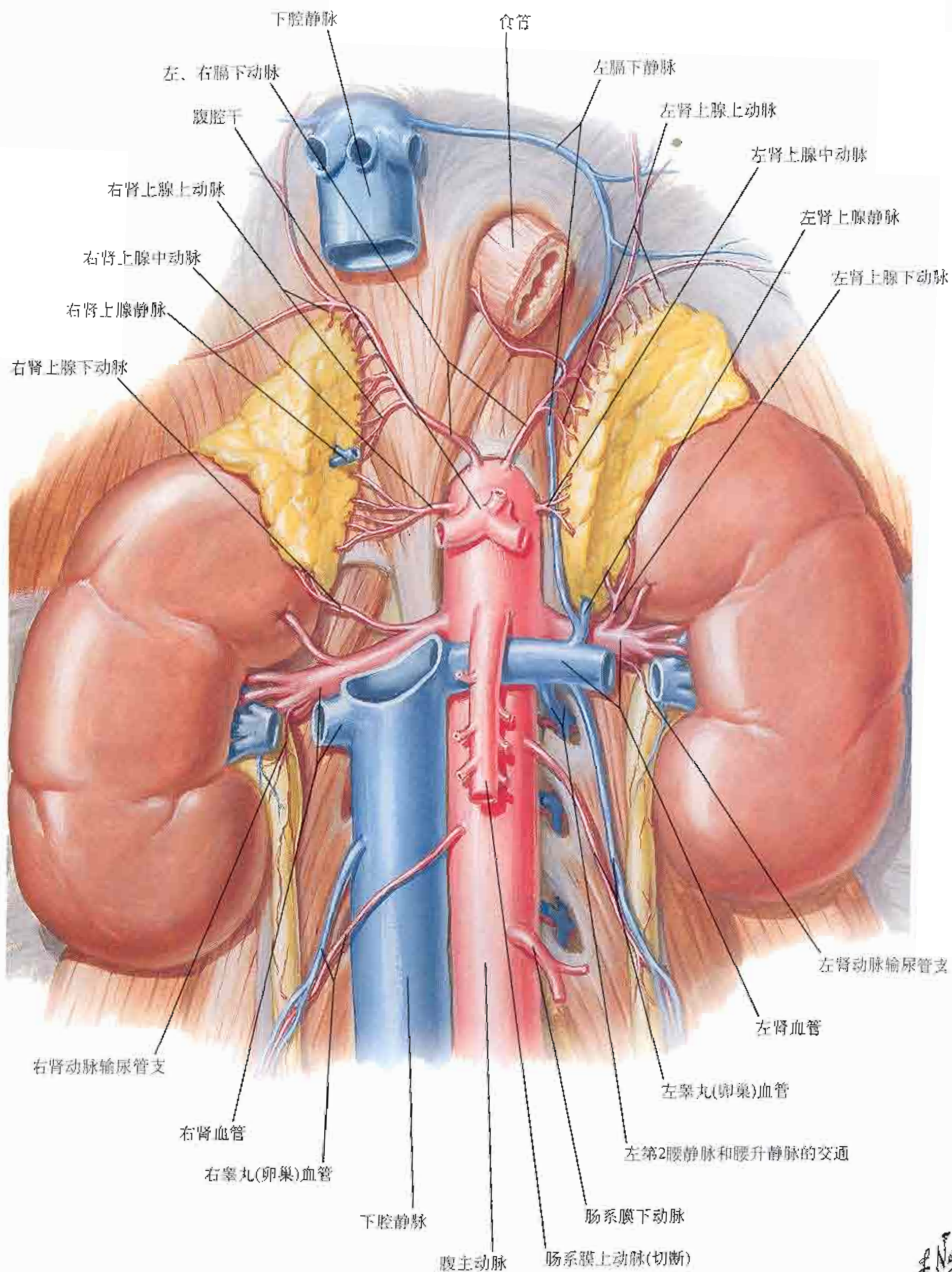
右肾前面



右肾不同平面的断面，
暴露肾实质和肾盂

F. Netter M.D.
© ION

图321



IGN

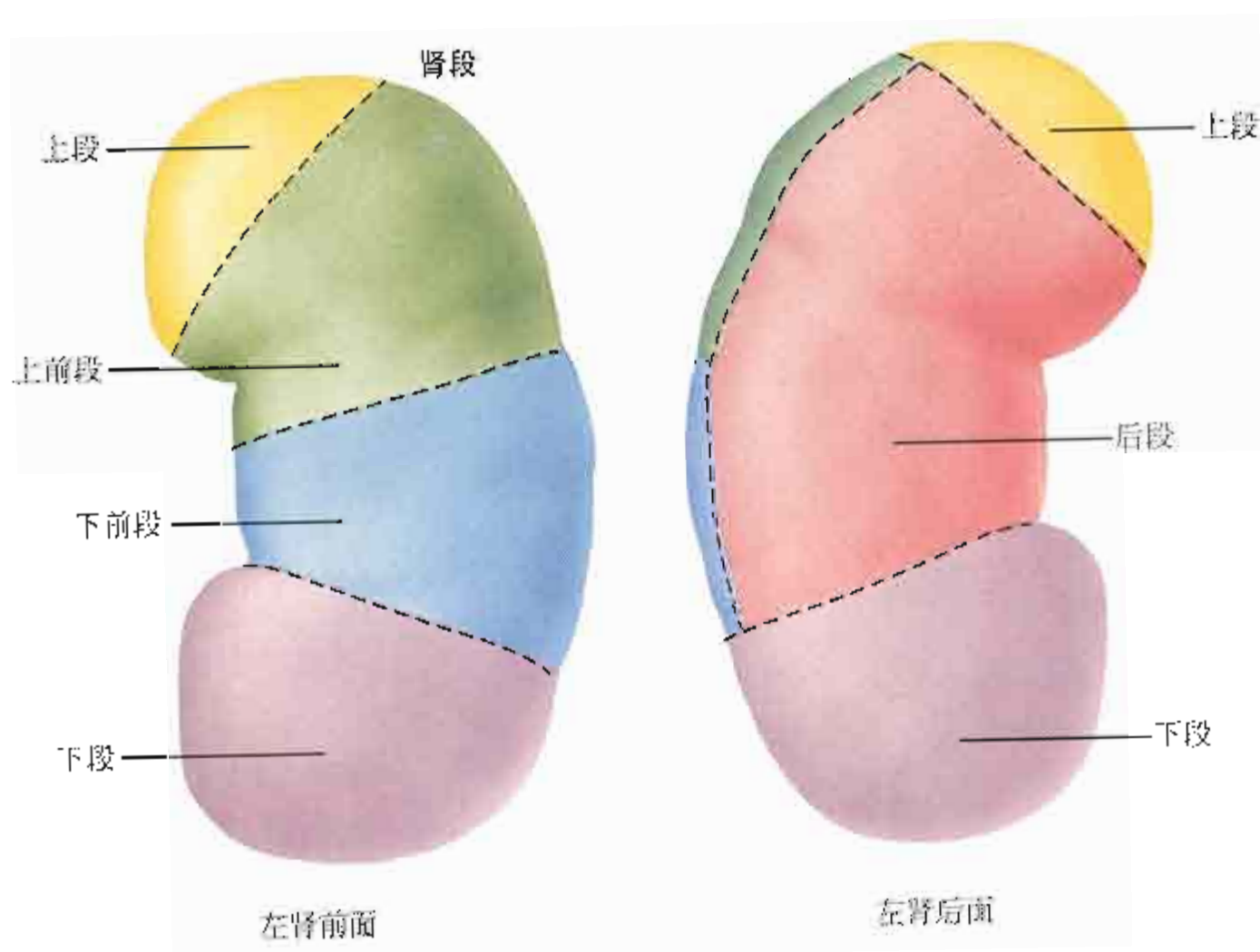
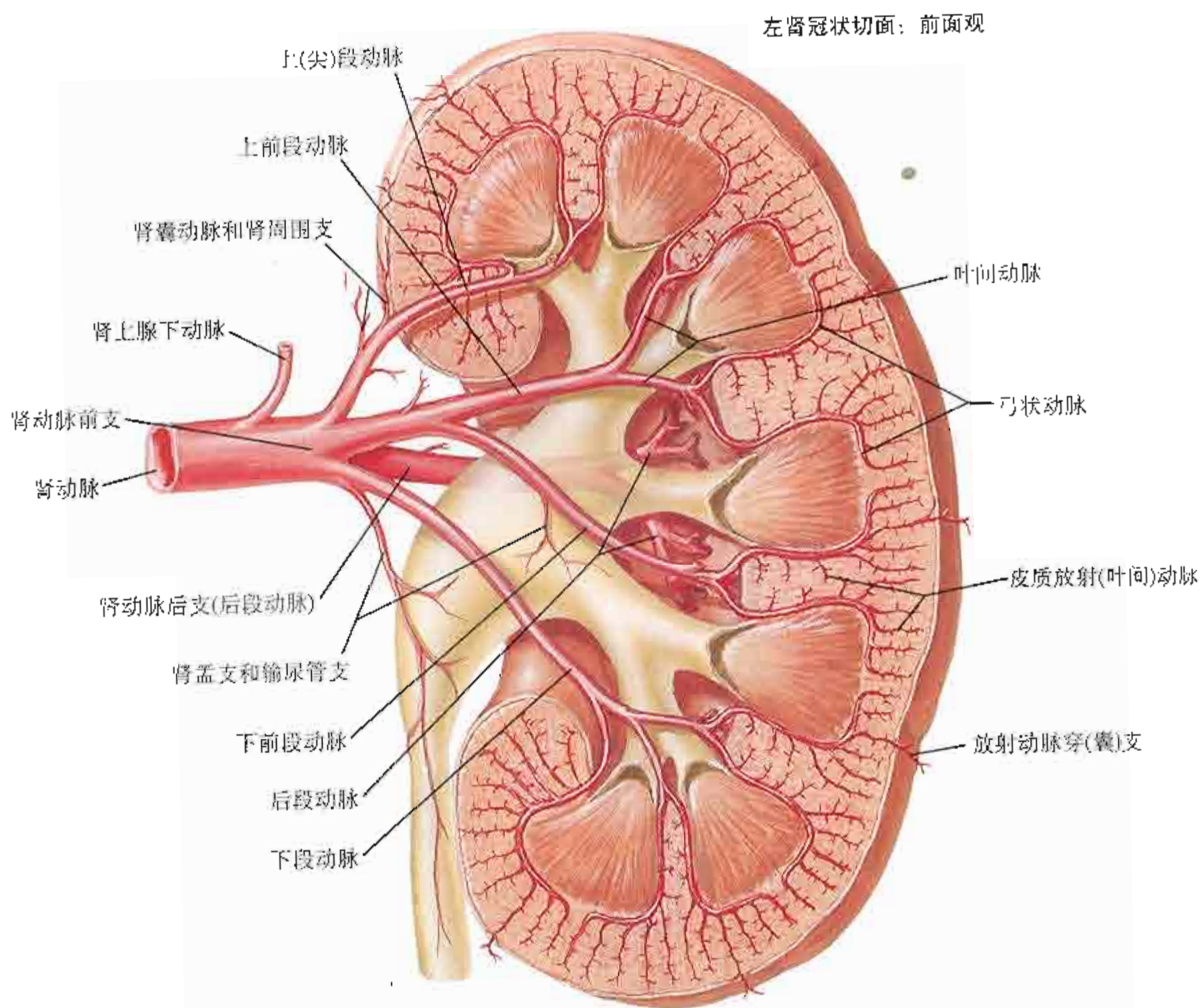
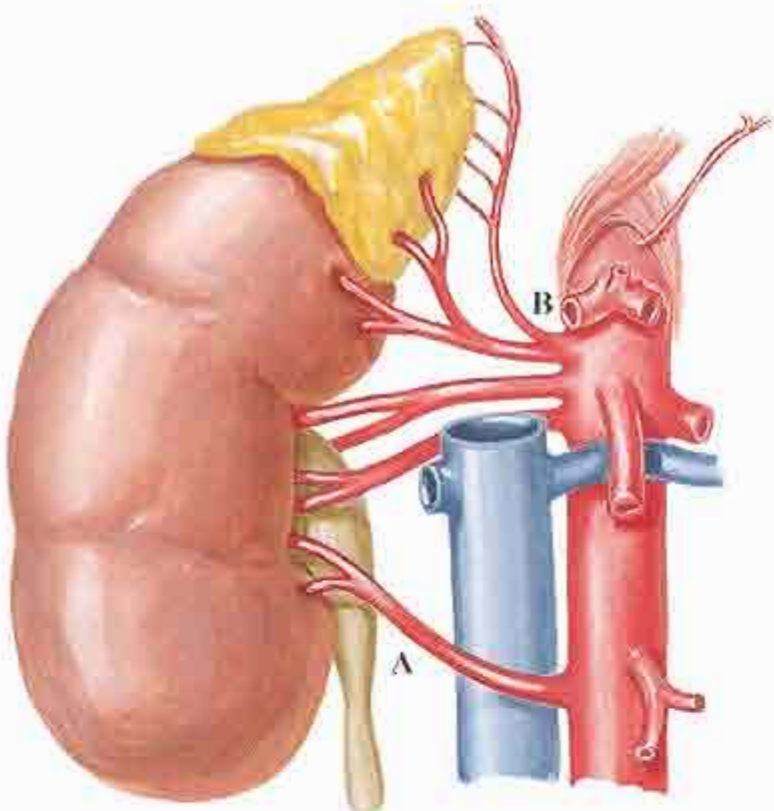
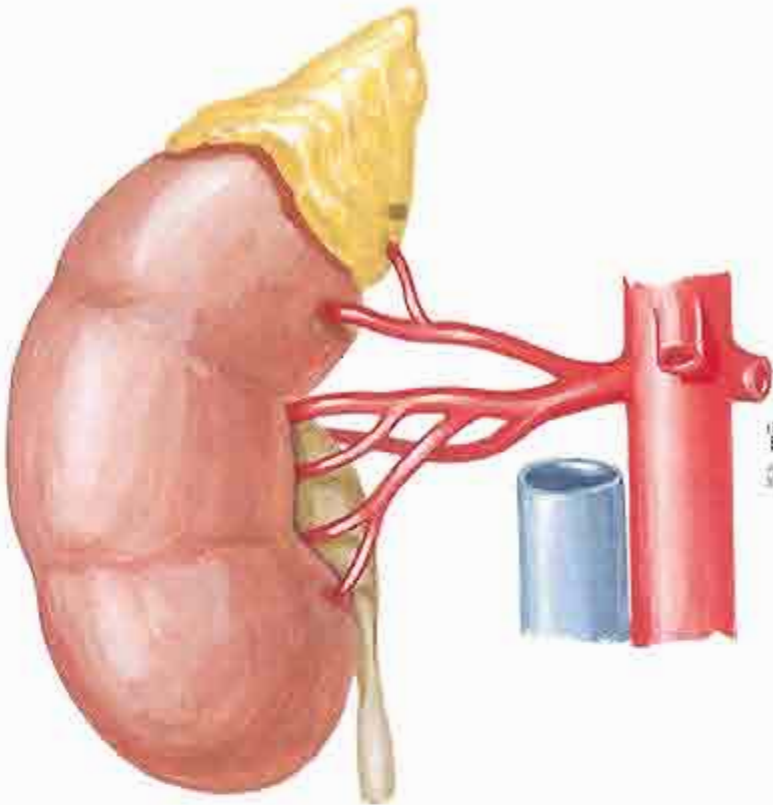


图323

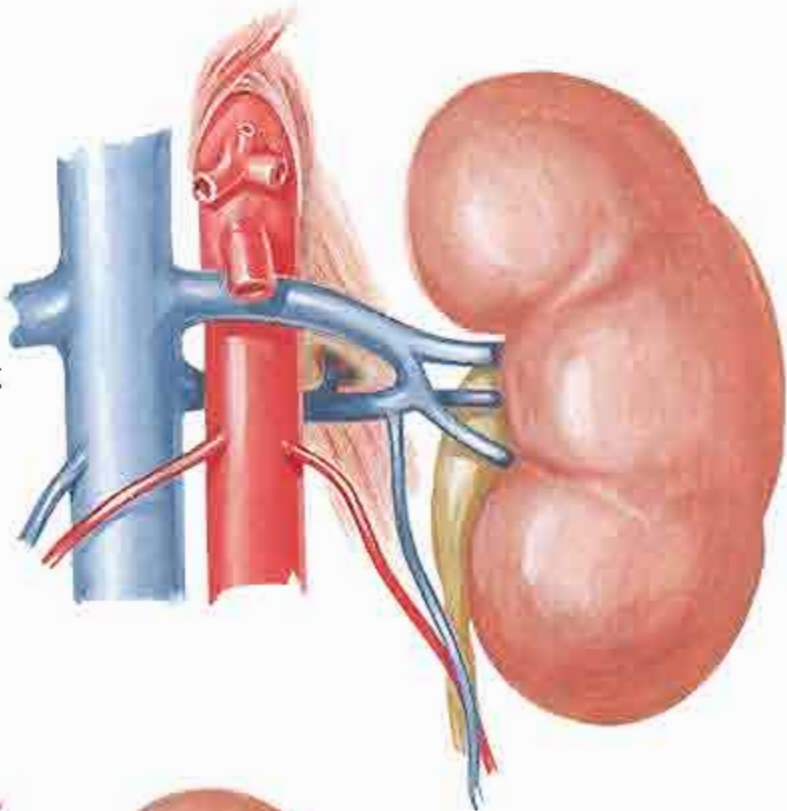


A 低位右肾副动脉行经下腔静脉前方而不是后方

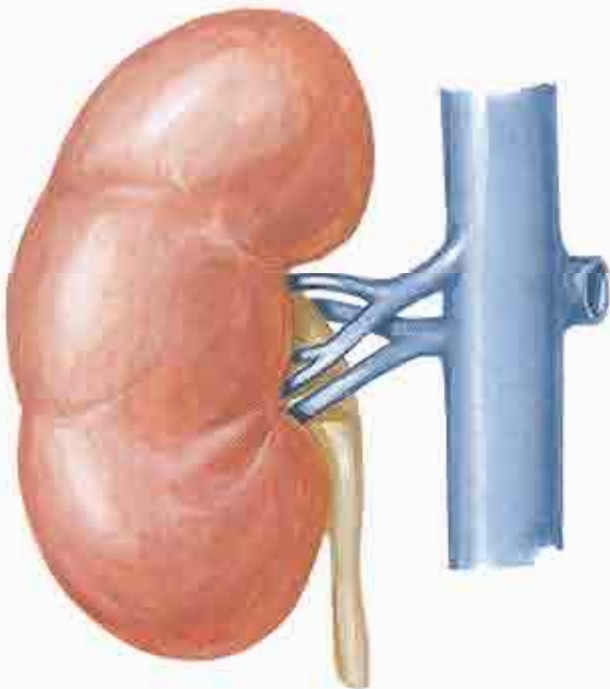
B 膈下动脉与肾上腺上动脉可起自肾动脉(肾上腺中动脉缺如)



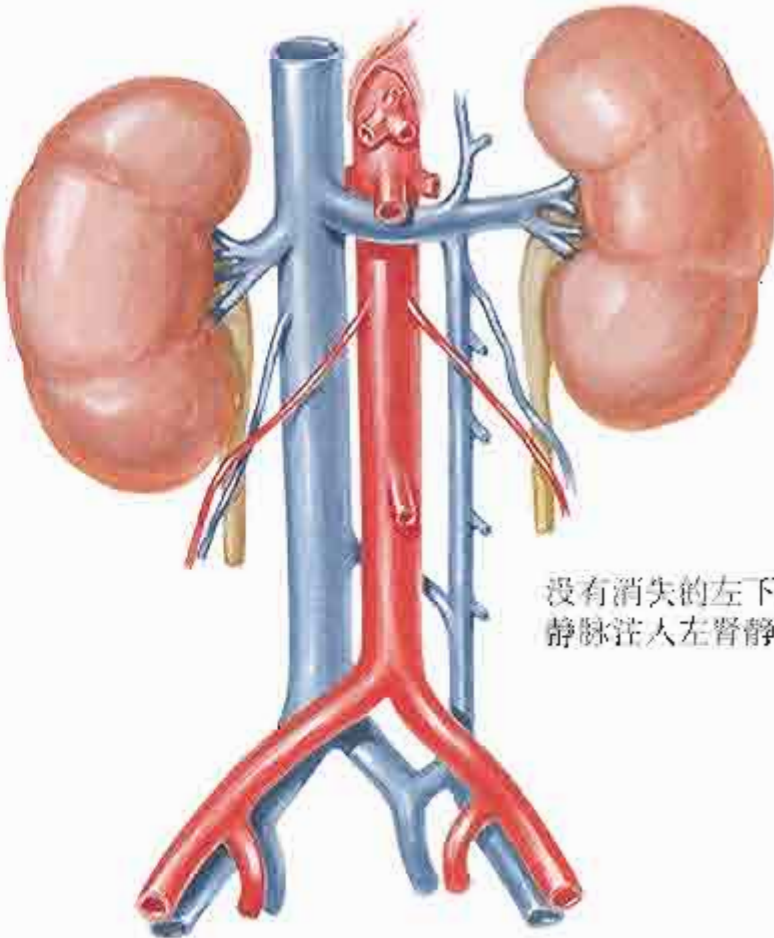
肾动脉近侧端分支



双左肾静脉形成环状围绕腹主动脉



多支肾静脉



没有消失的左下腔静脉注入左肾静脉

F. Netter M.D.
© IGV

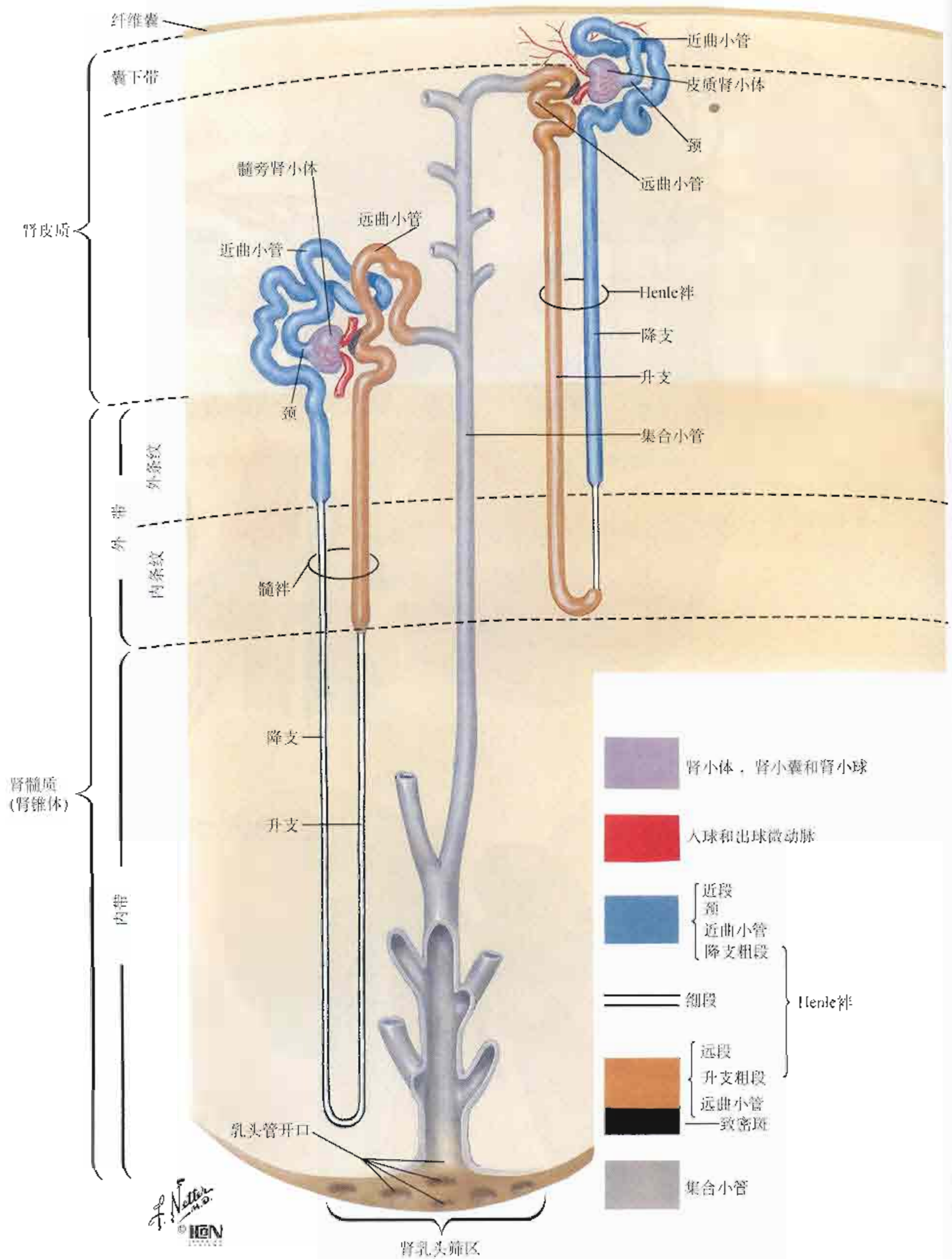
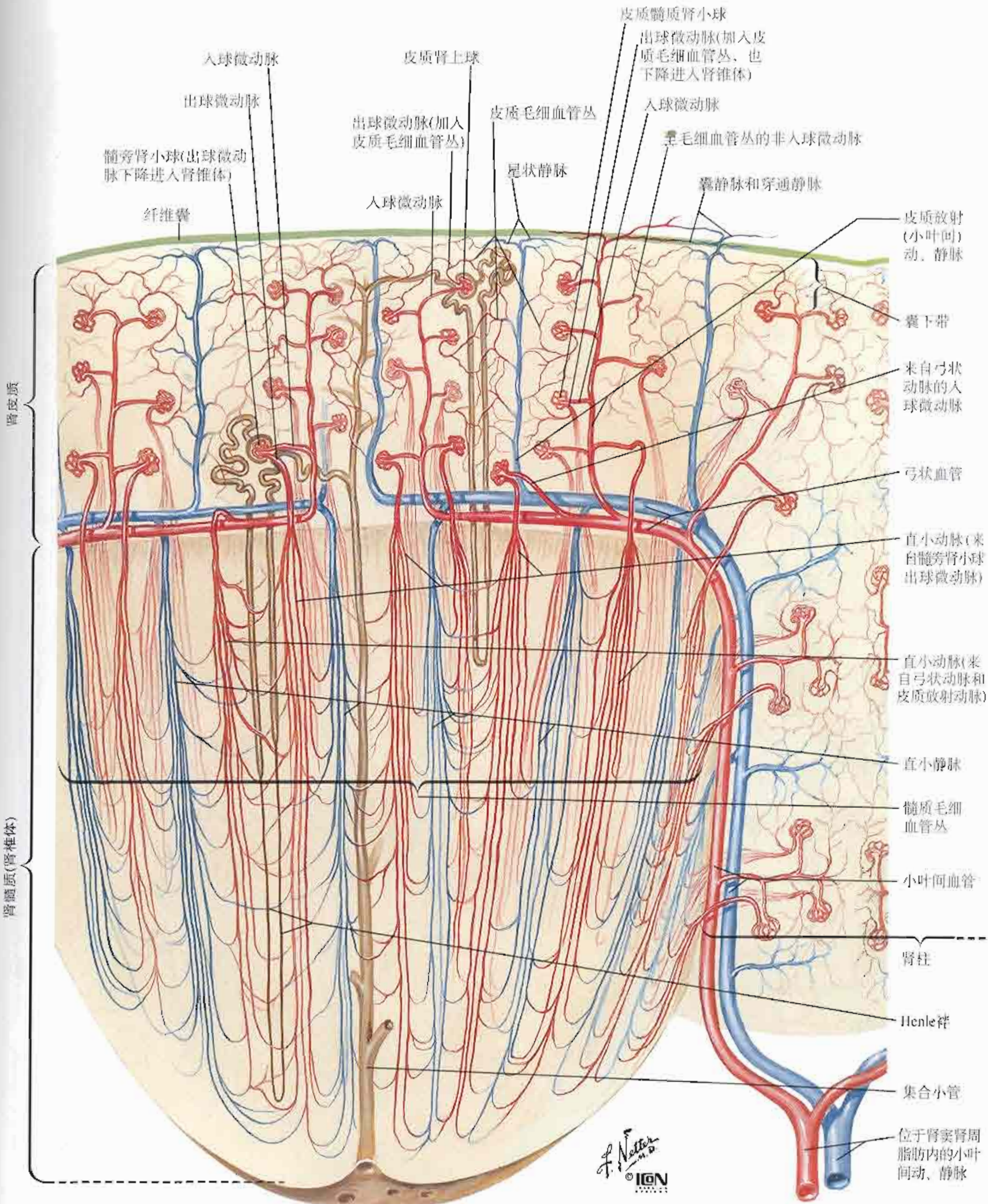


图325



输尿管

参见图 349、350、354

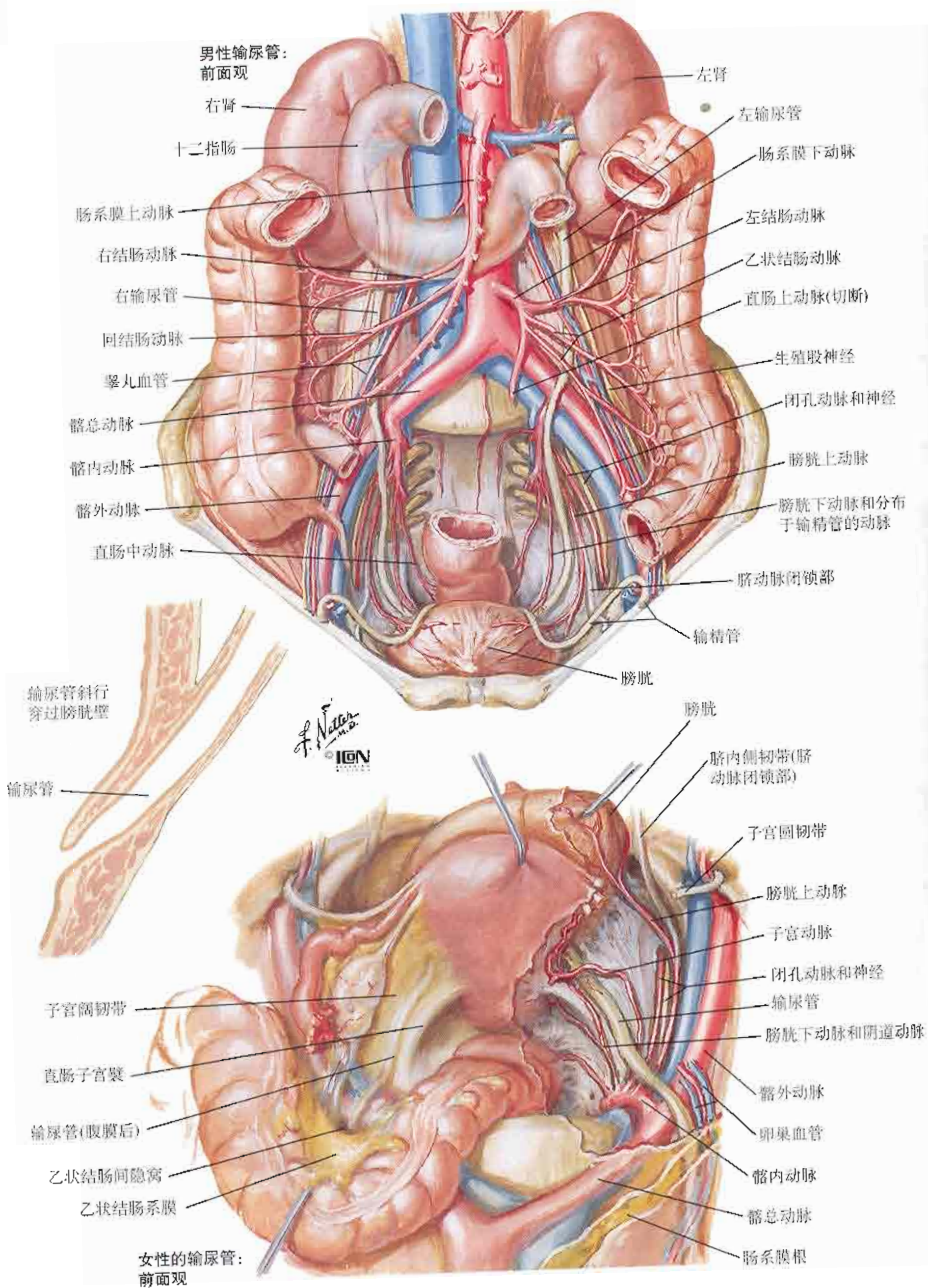
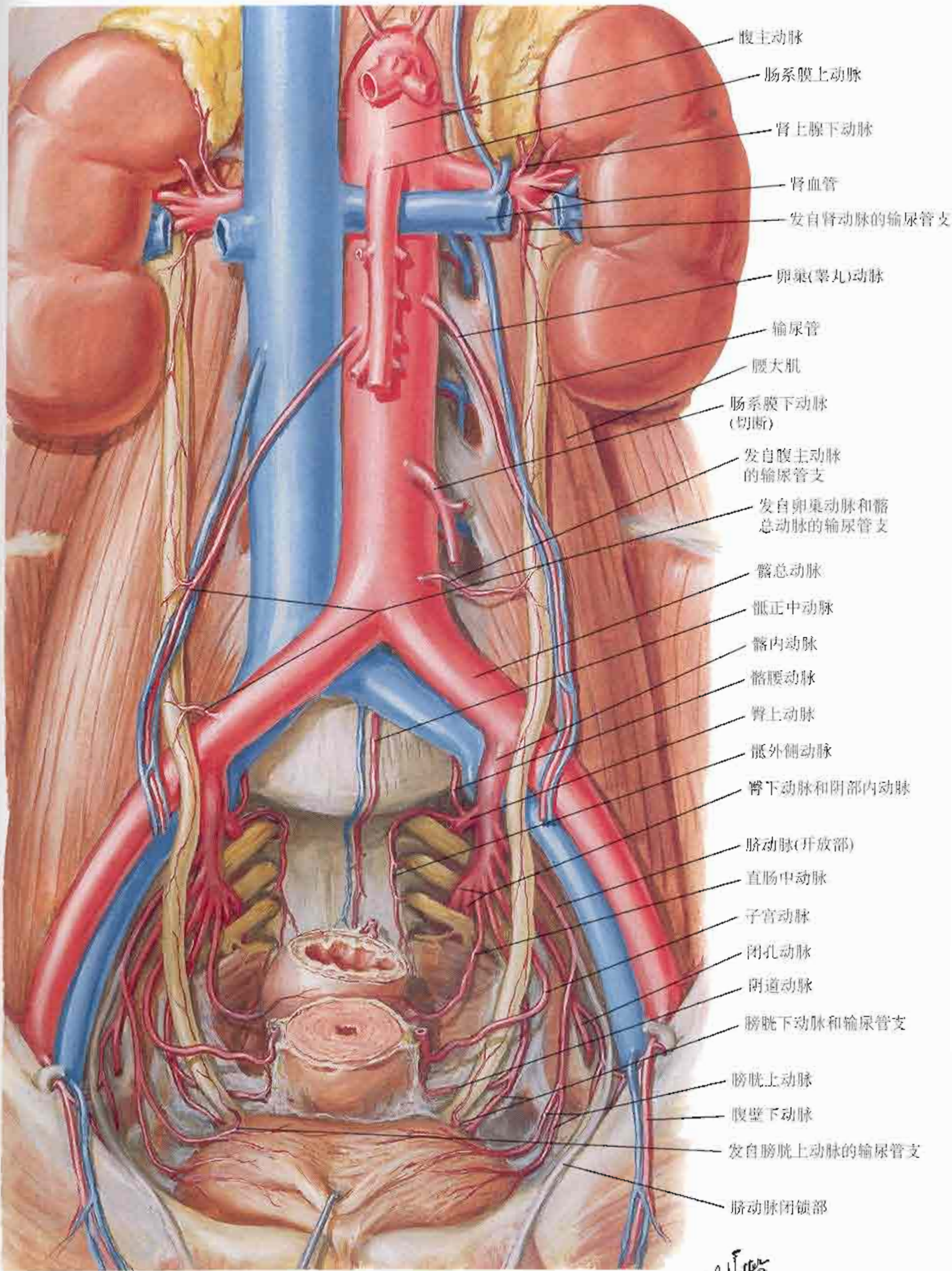


图327



F. Netter
M.D.
ION

肾与膀胱的淋巴管和淋巴结

参见图 386、388

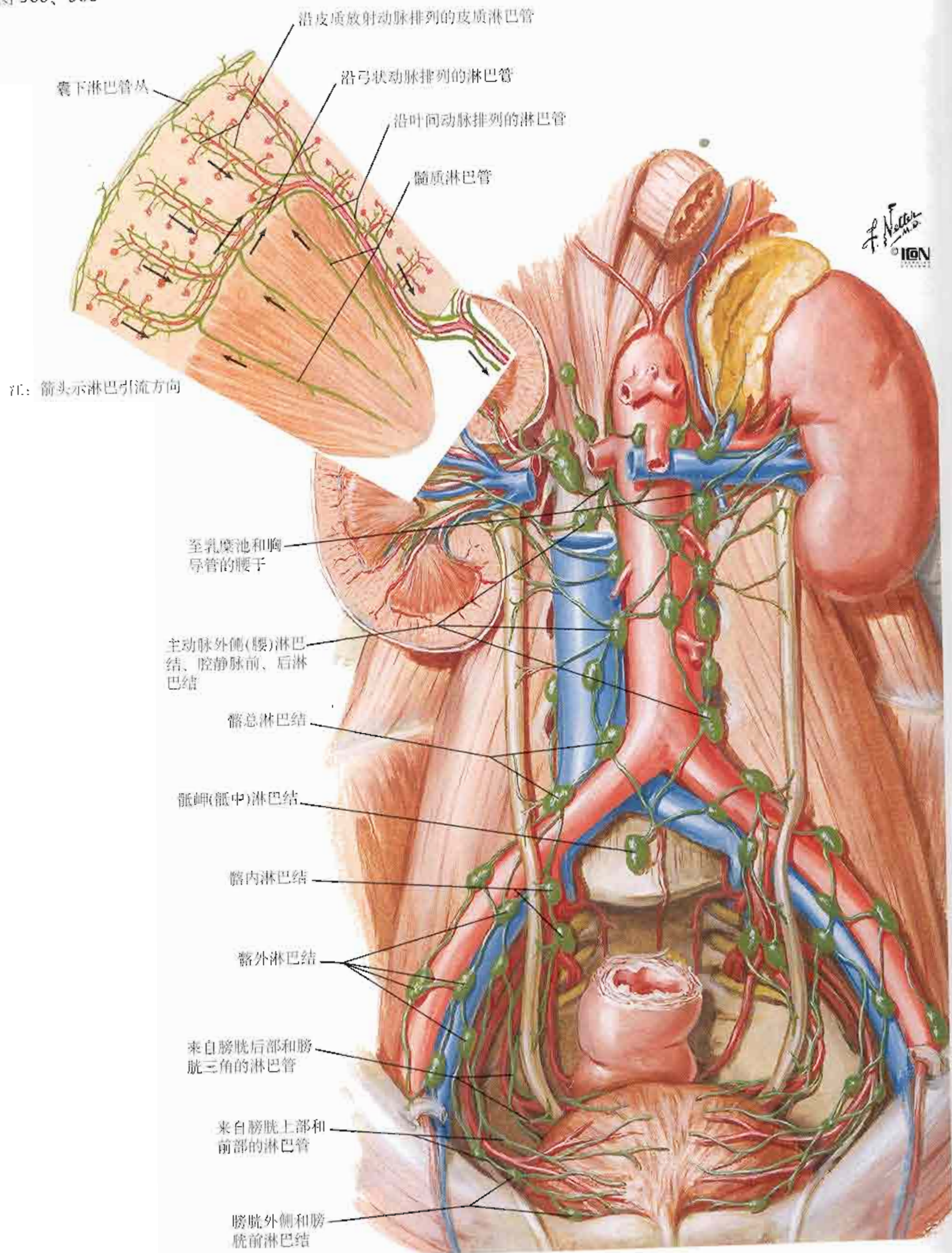
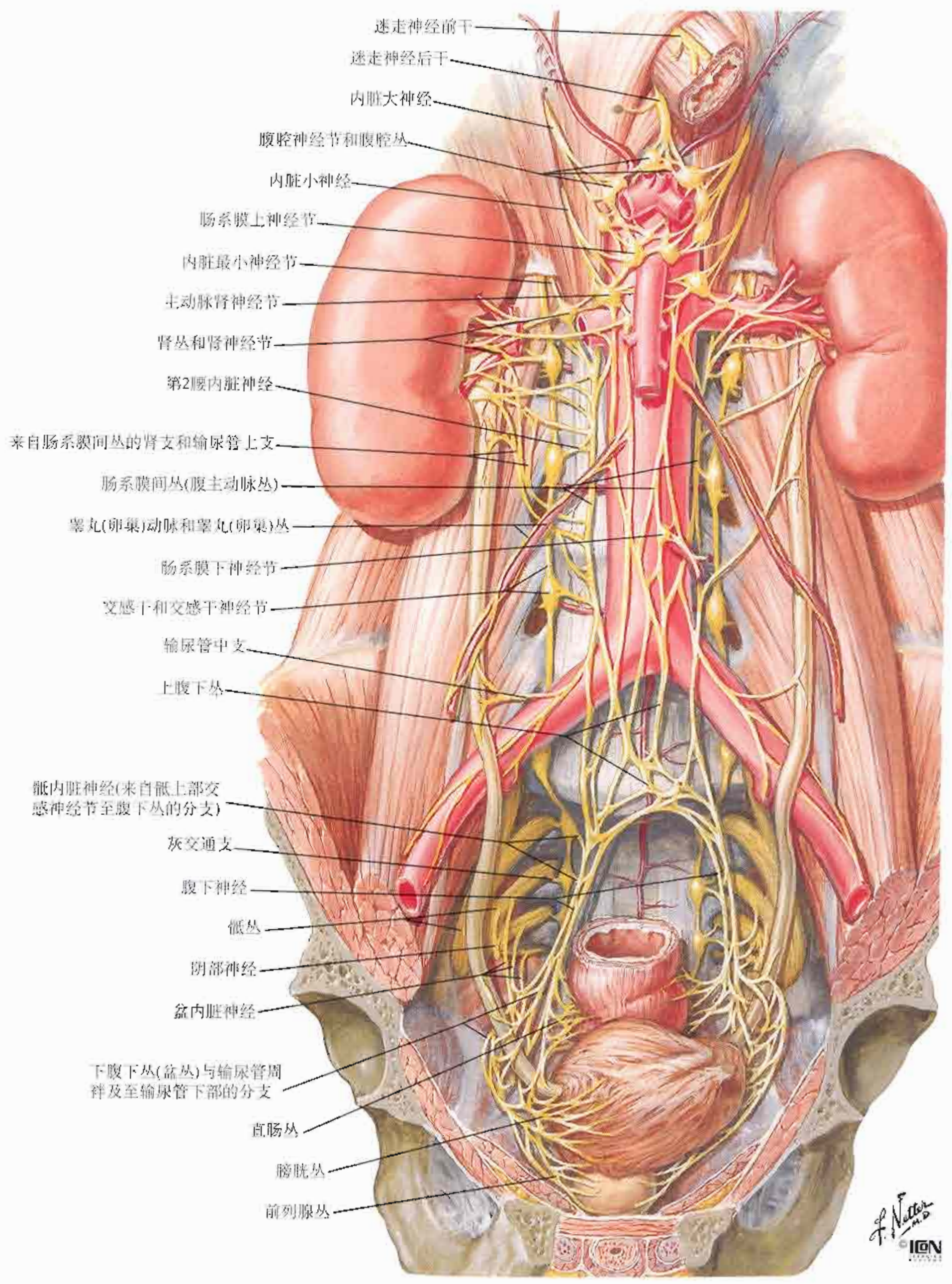


图329

腹部



肾和肾上腺

图330

肾和输尿管上部的神经分布：示意图

参见图 160、397

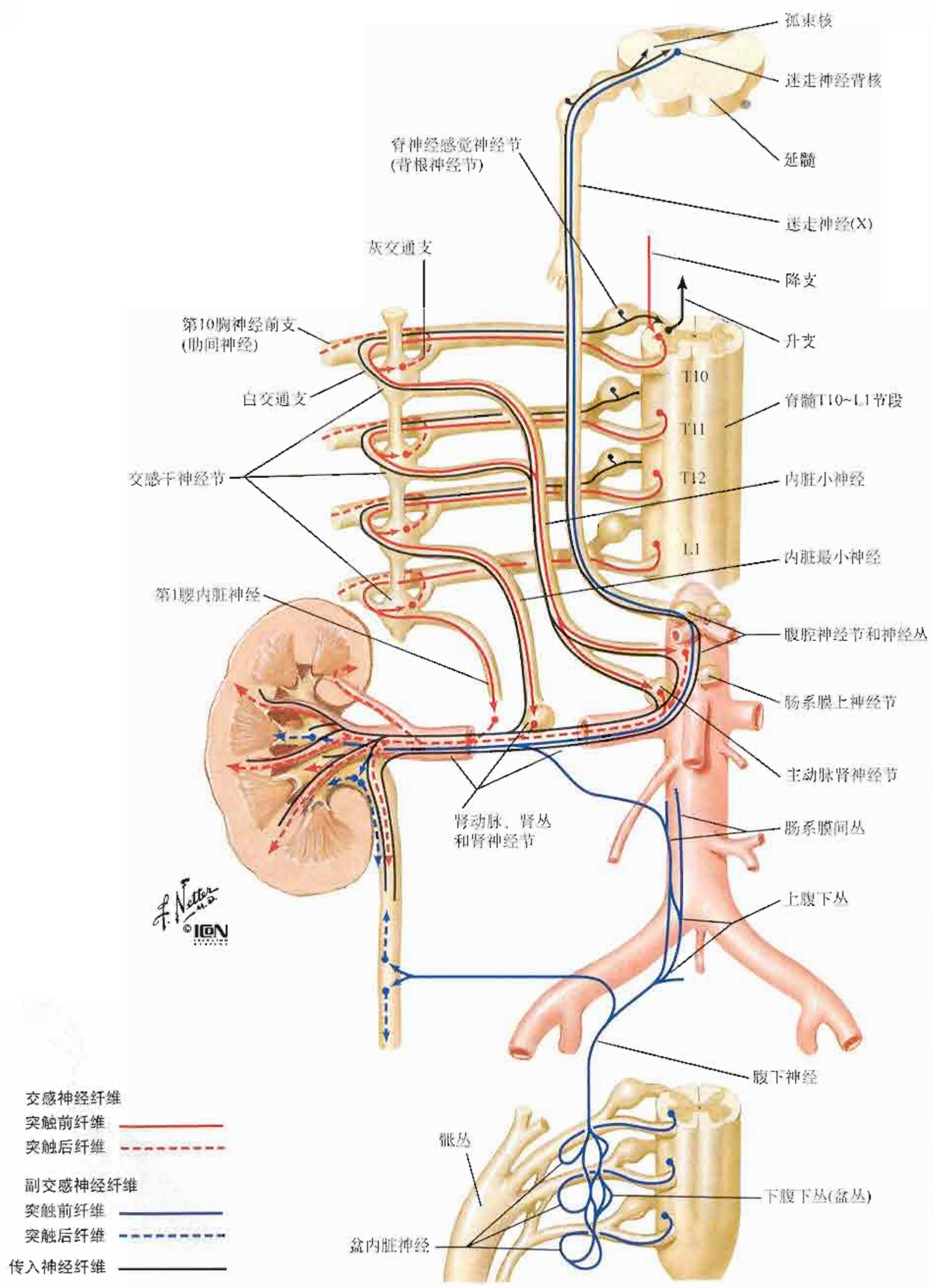
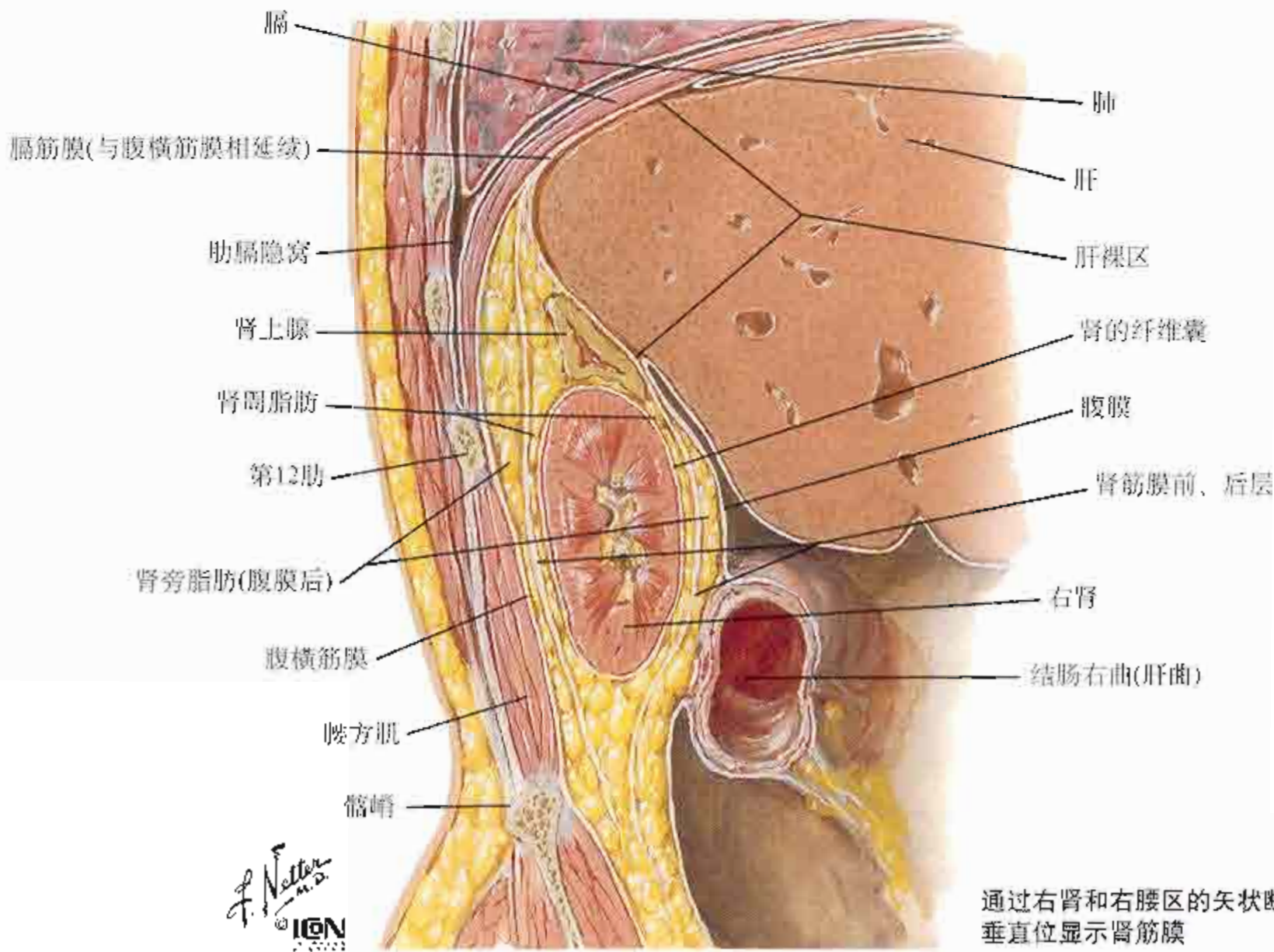
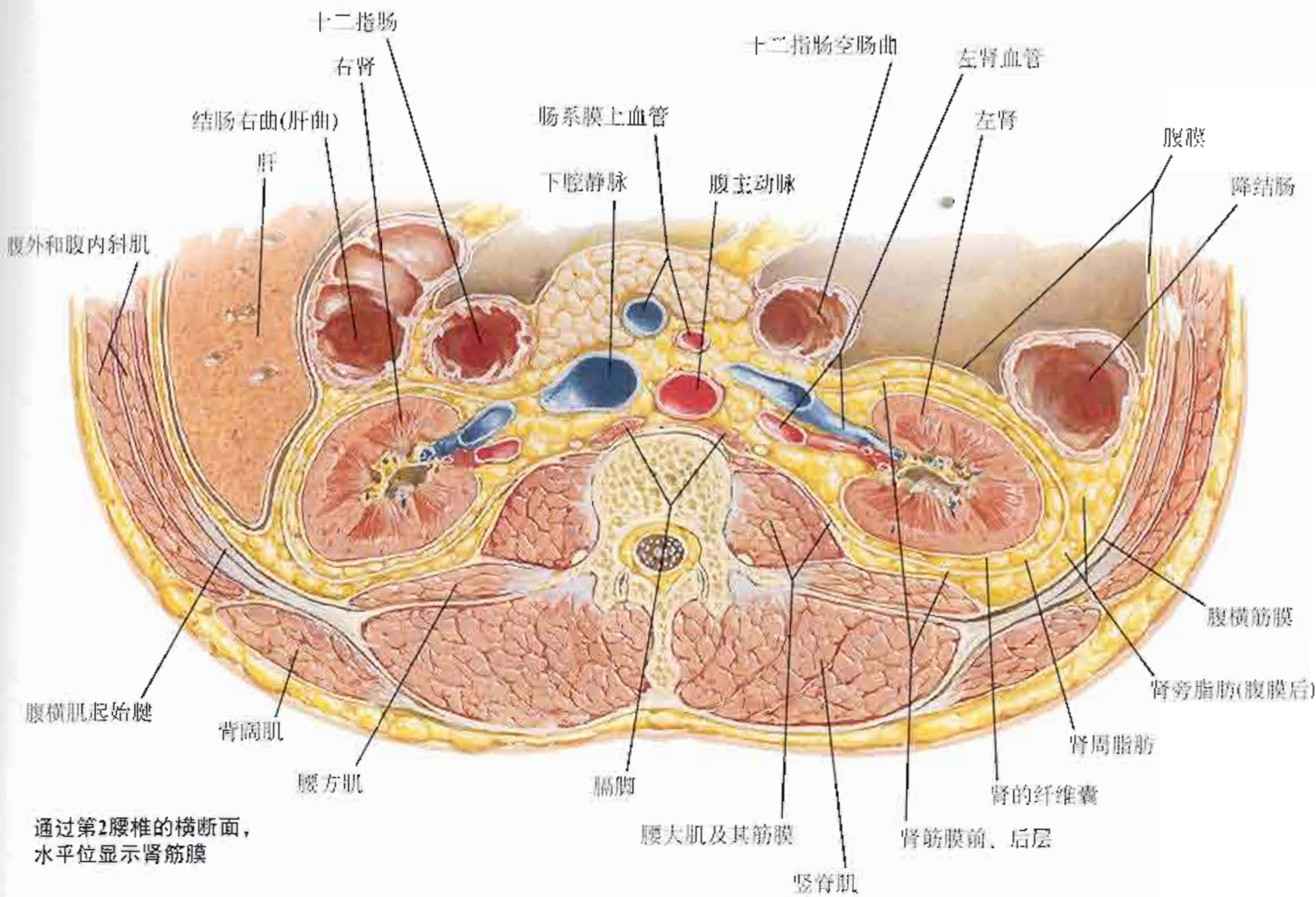


图331

腹部



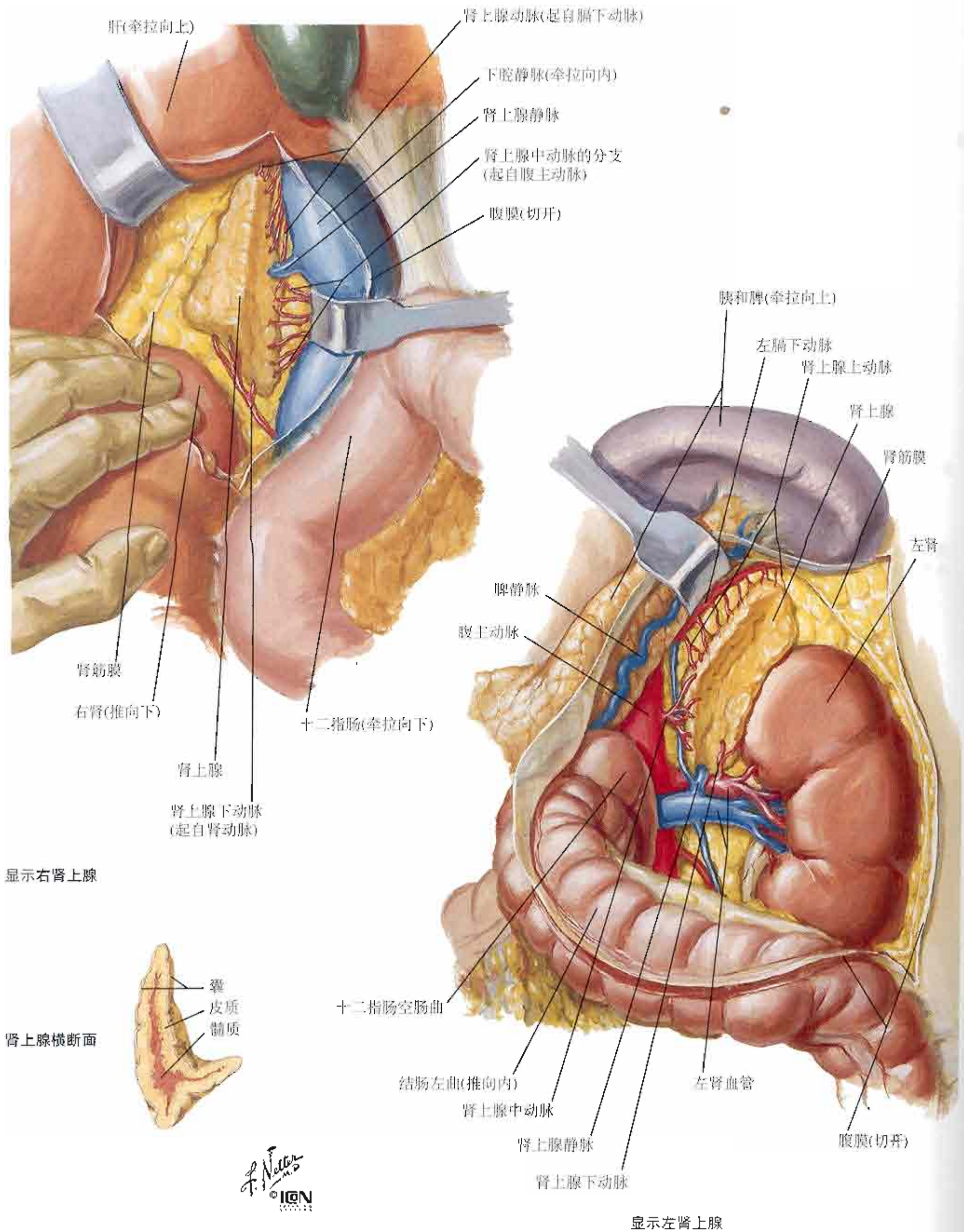
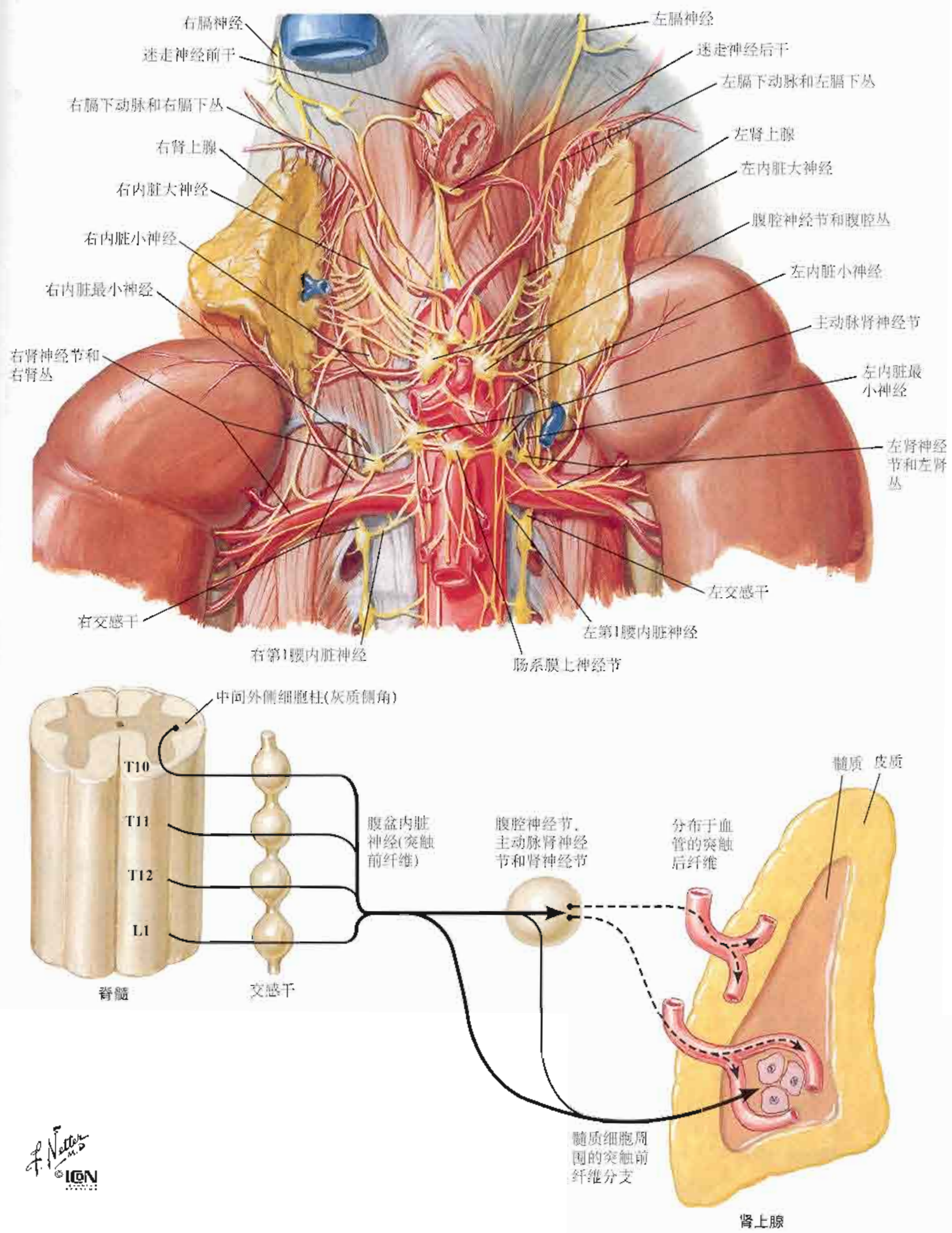


图333

参见图 159、160



腹壁和内脏：正中矢状切面

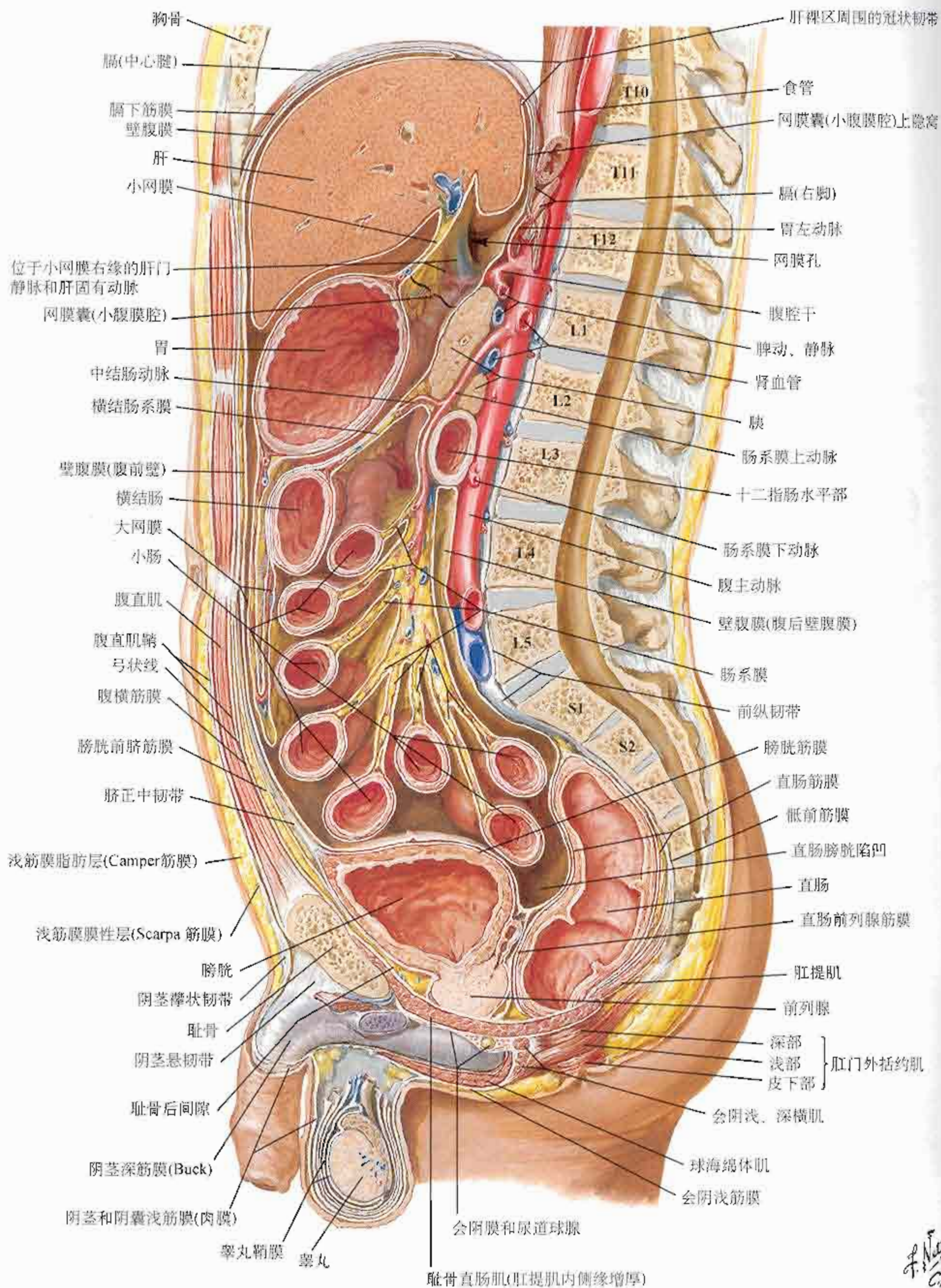
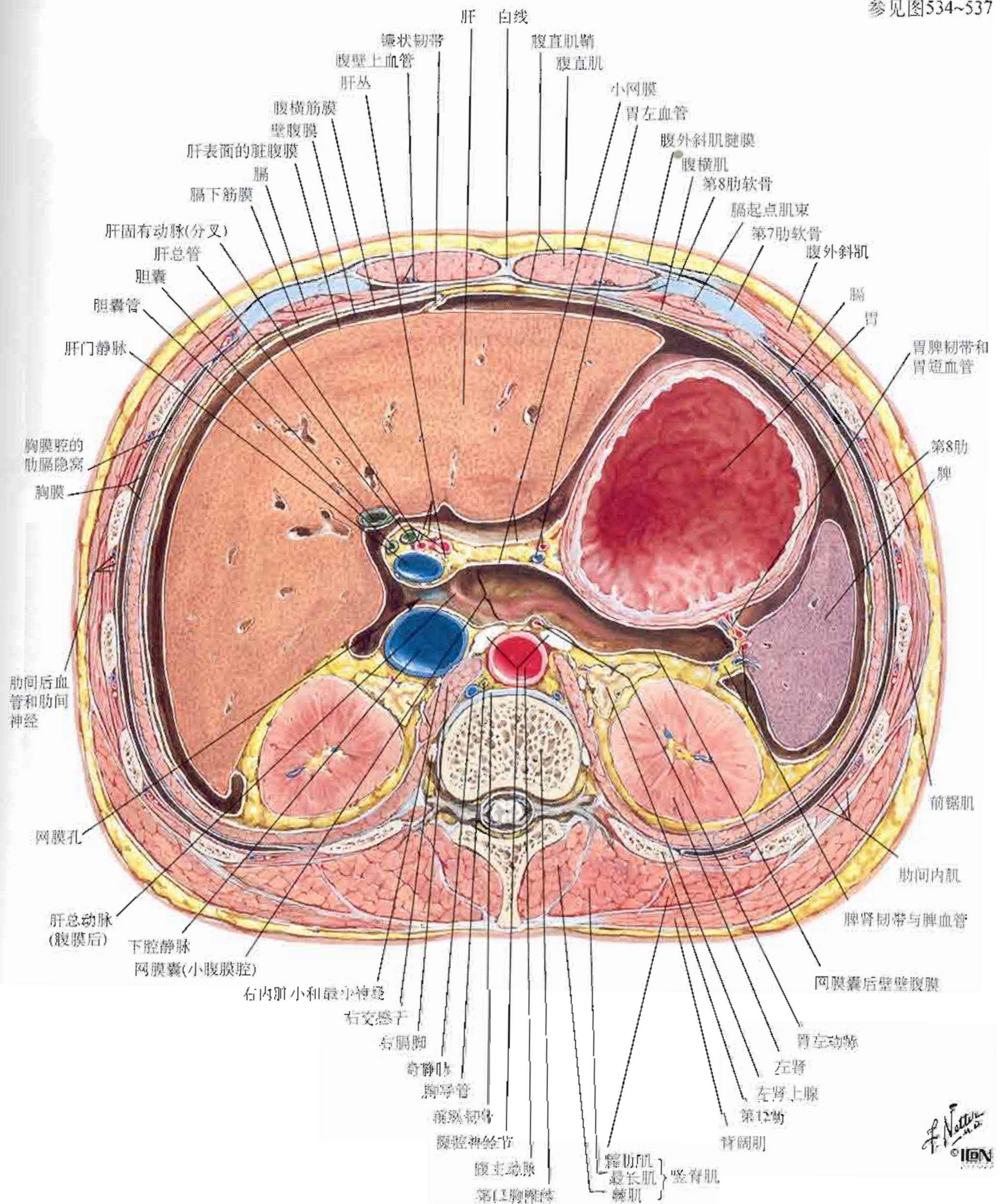


图335

腹部



F. Netter M.D. ION

经第3、4腰椎间的腹部横断面示意图

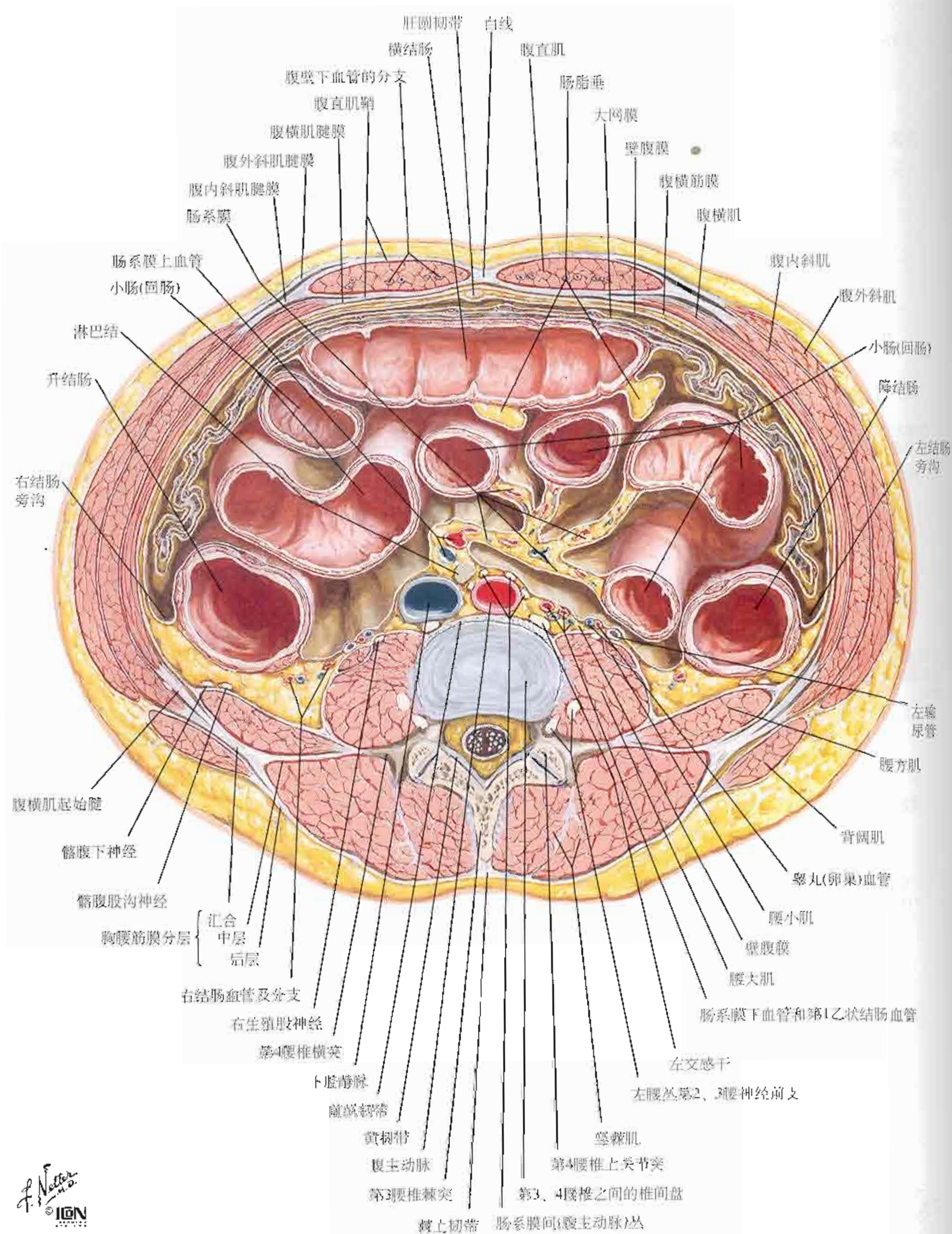
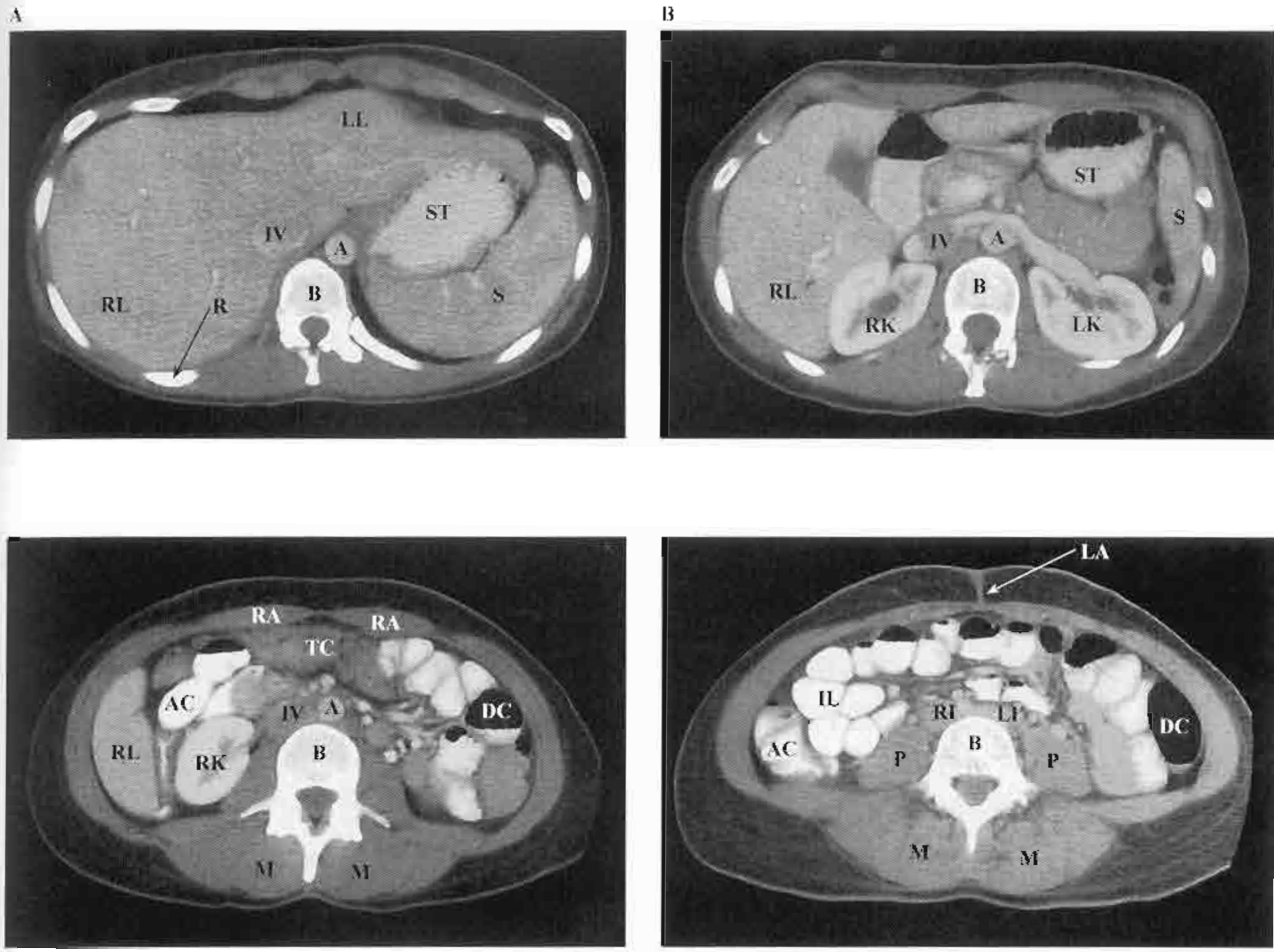


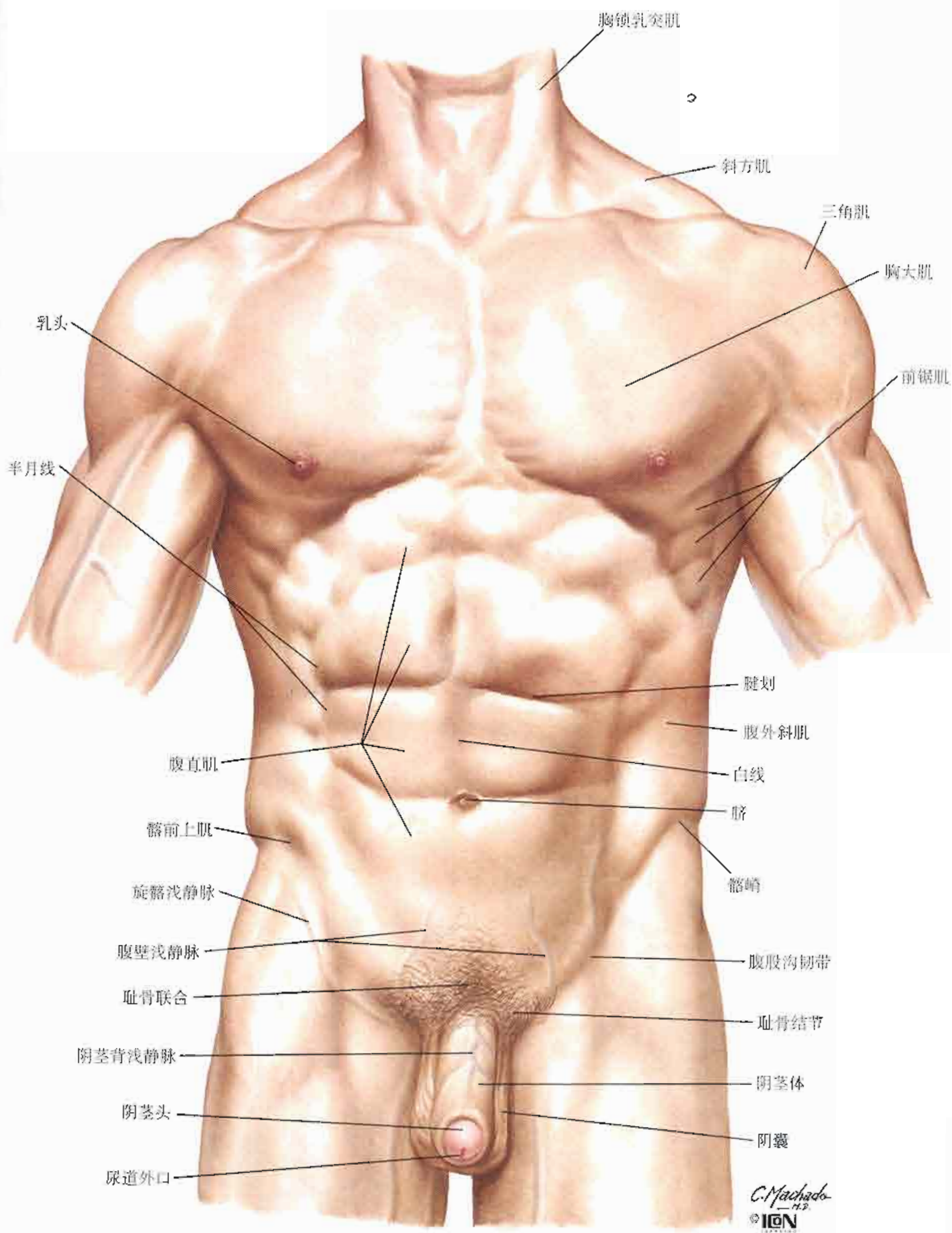
图337

从上 (A) 向下 (D) 腹部轴位 CT 连续图像



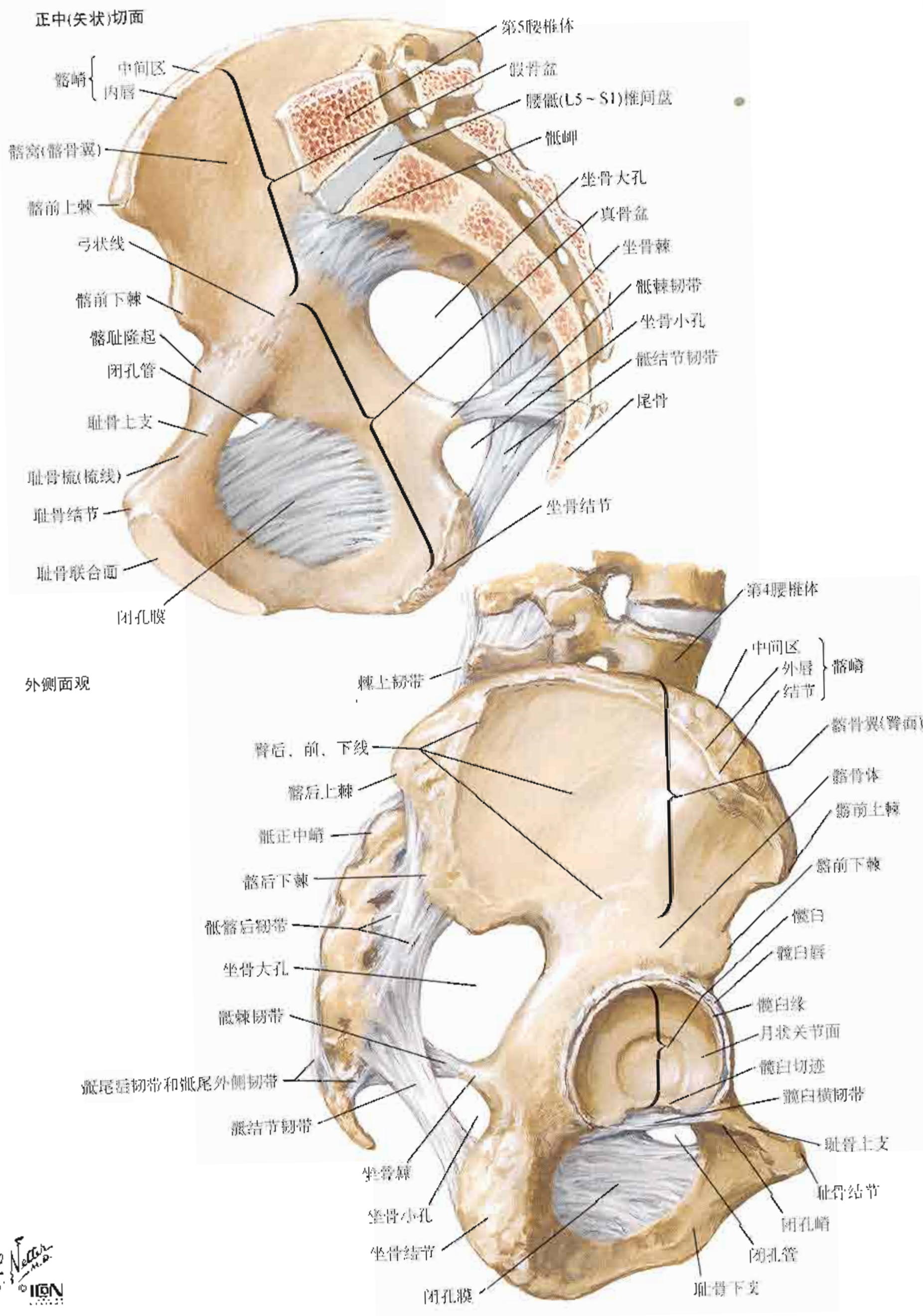
- A 腹主动脉
- AC 升结肠
- B 椎体
- DC 降结肠
- IL 空肠
- IV 下腔静脉
- LA 白线
- LI 左髂总动脉
- LK 左肾
- LL 肝左叶

- M 背部深层肌
- P 腰大肌
- R 肋
- RA 腹直肌
- RI 右髂总动脉
- RL 肝右叶
- S 脾
- ST 胃
- TC 横结肠



骨盆的骨和韧带

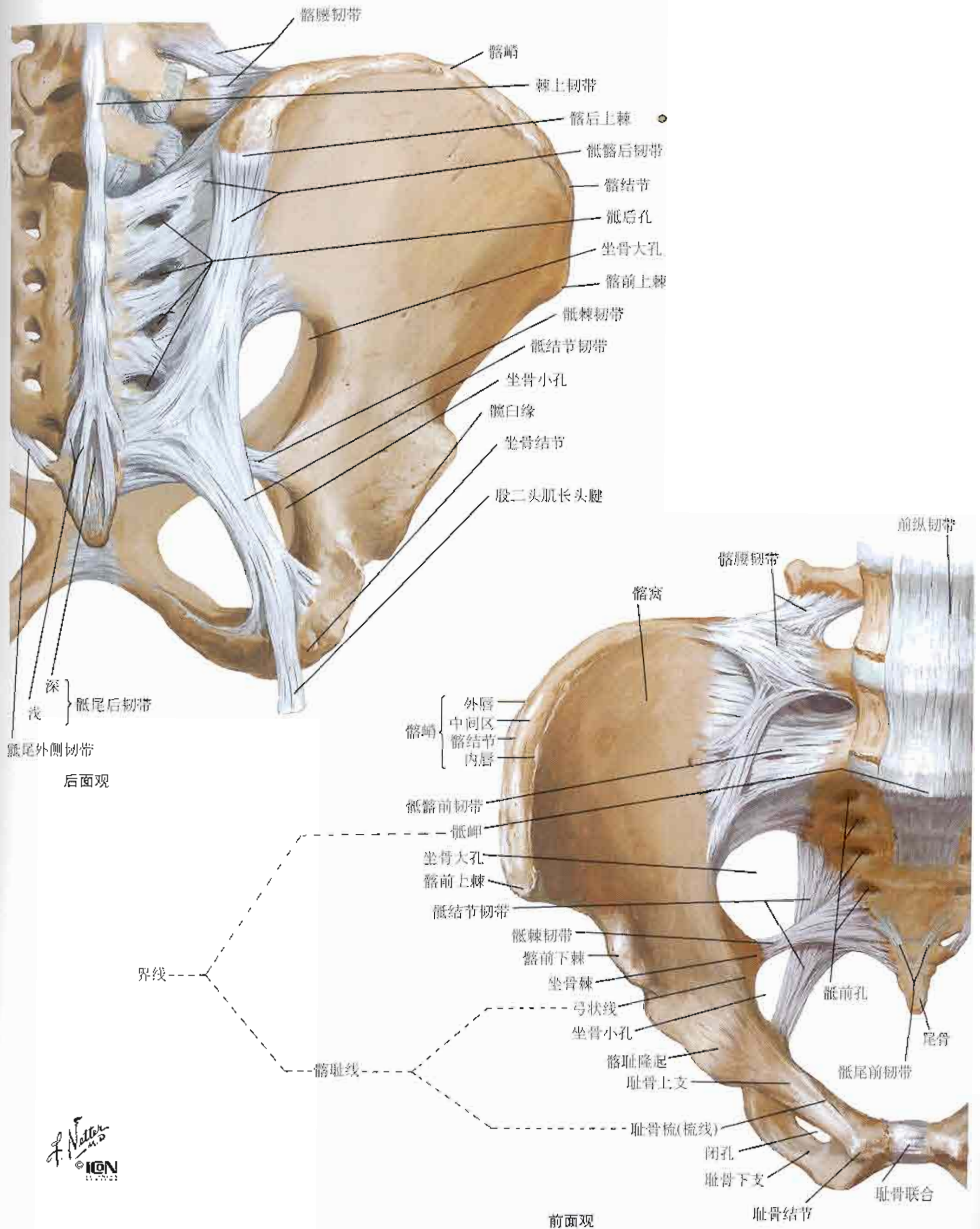
参见图468



F. Netter M.D. ILLUSTRATIONS

图340

盆和会阴



骨盆的性别差异：测量

参见图240

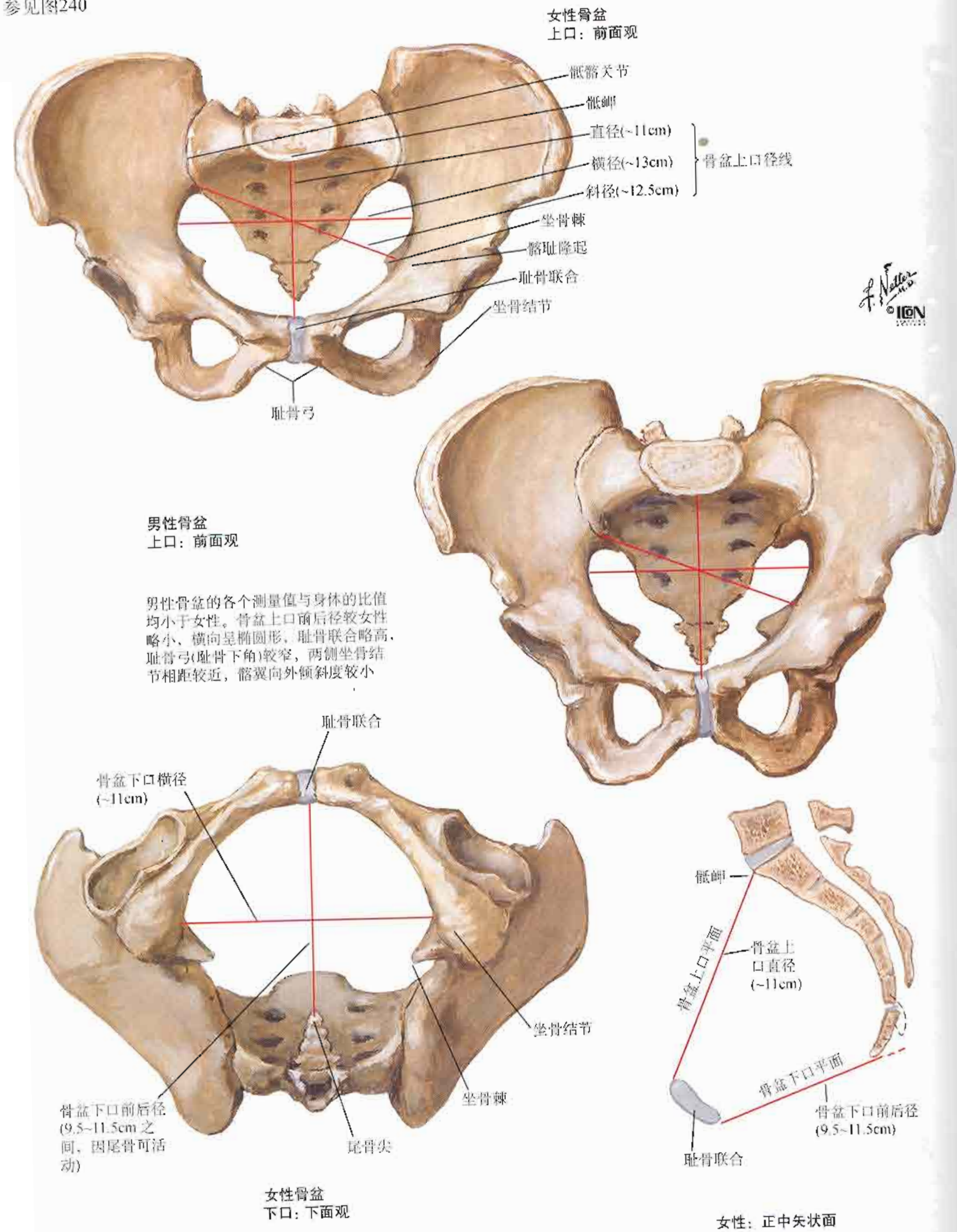


图342

参见图255、353、355、373

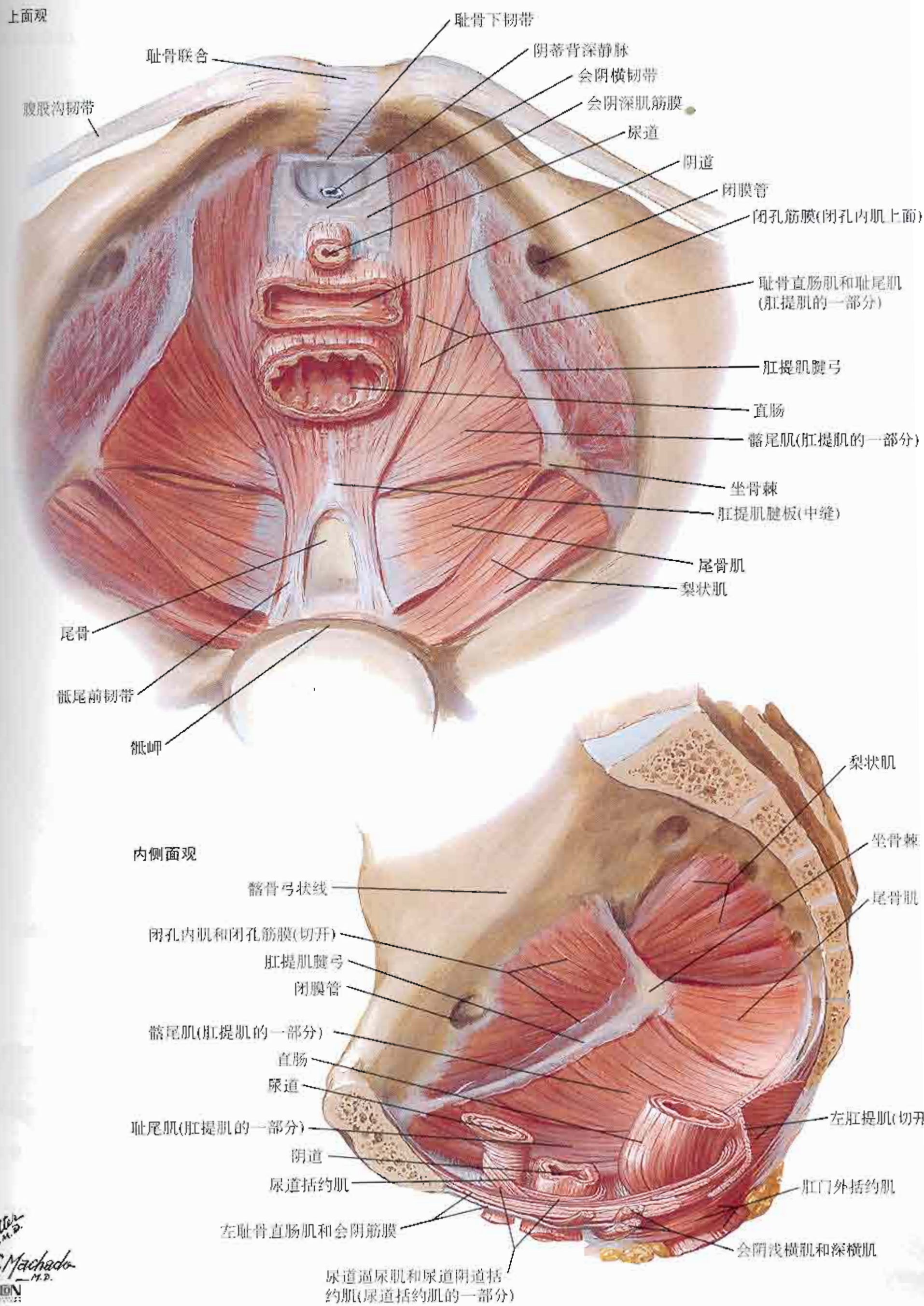
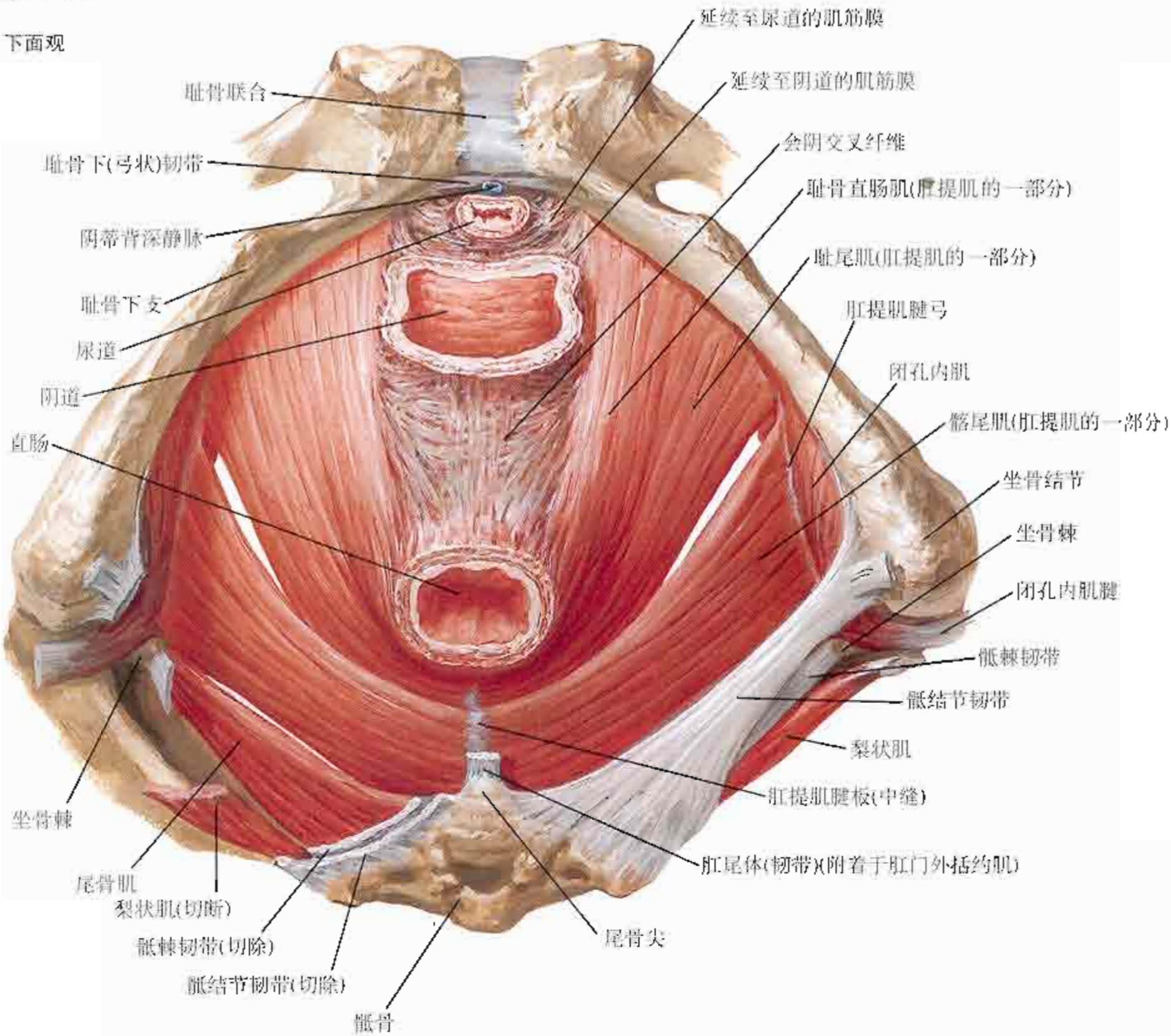


图343

及其内容

尿生殖膈见图361

下面观



外侧面观

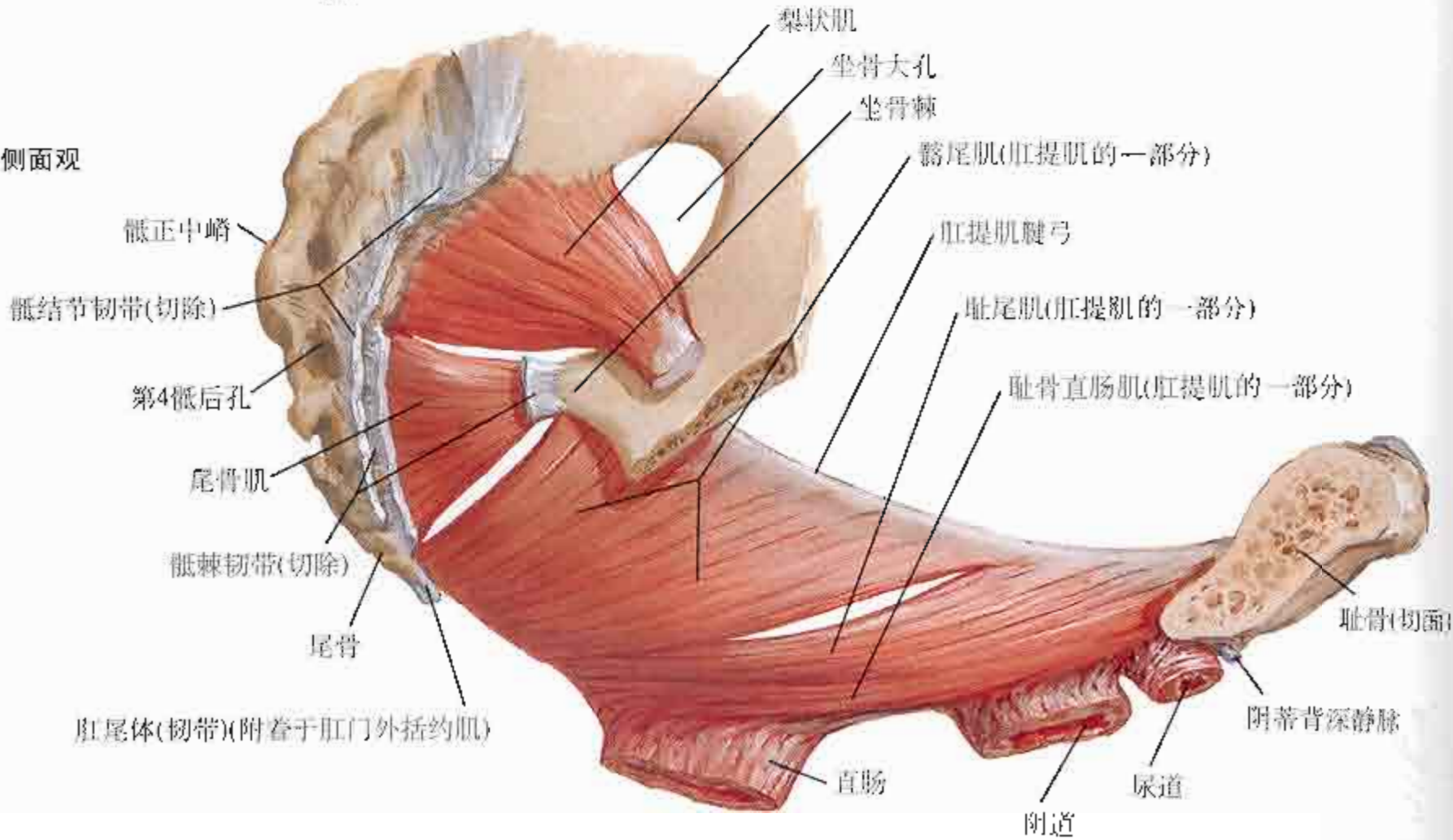
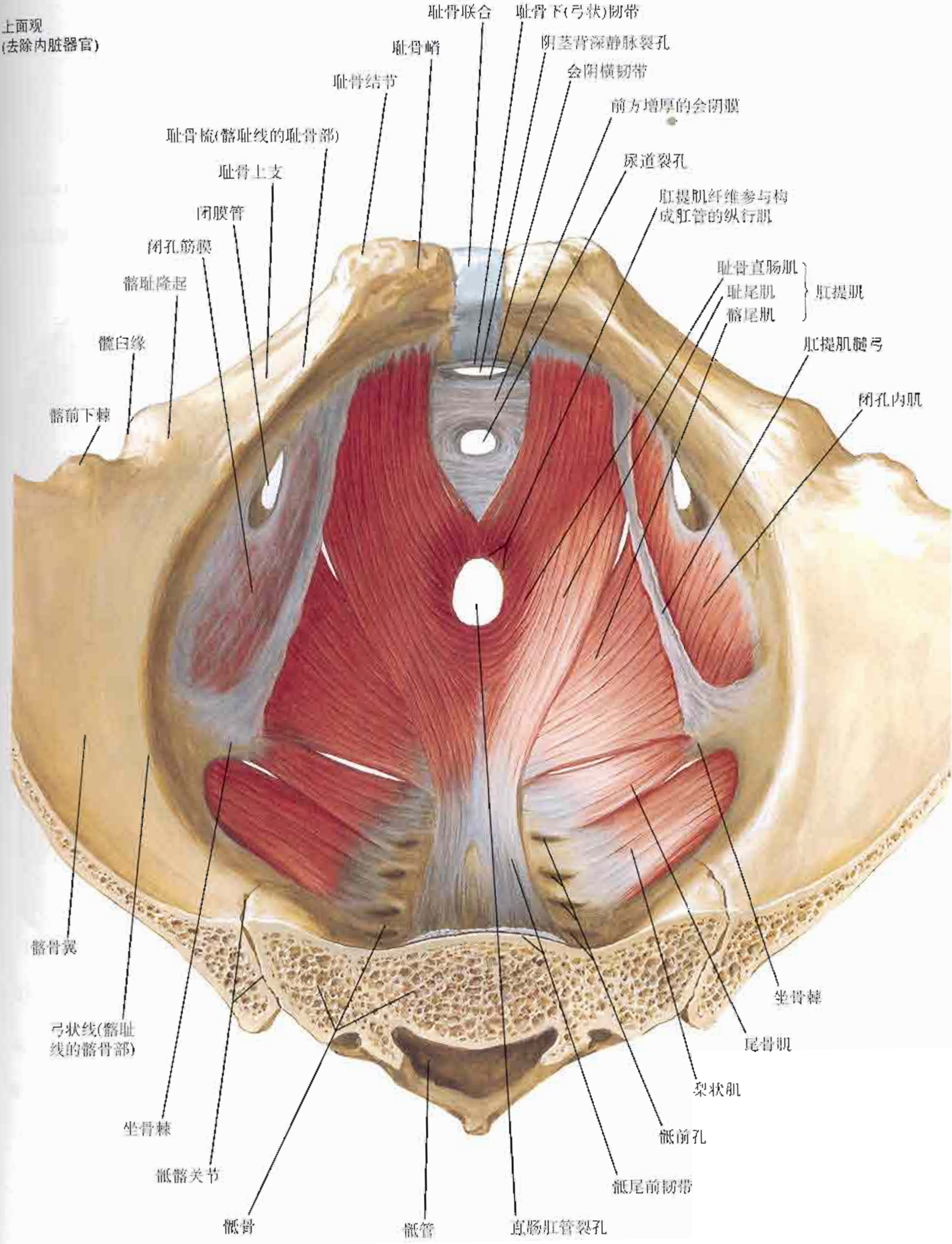


图344

参见图 255、353、373

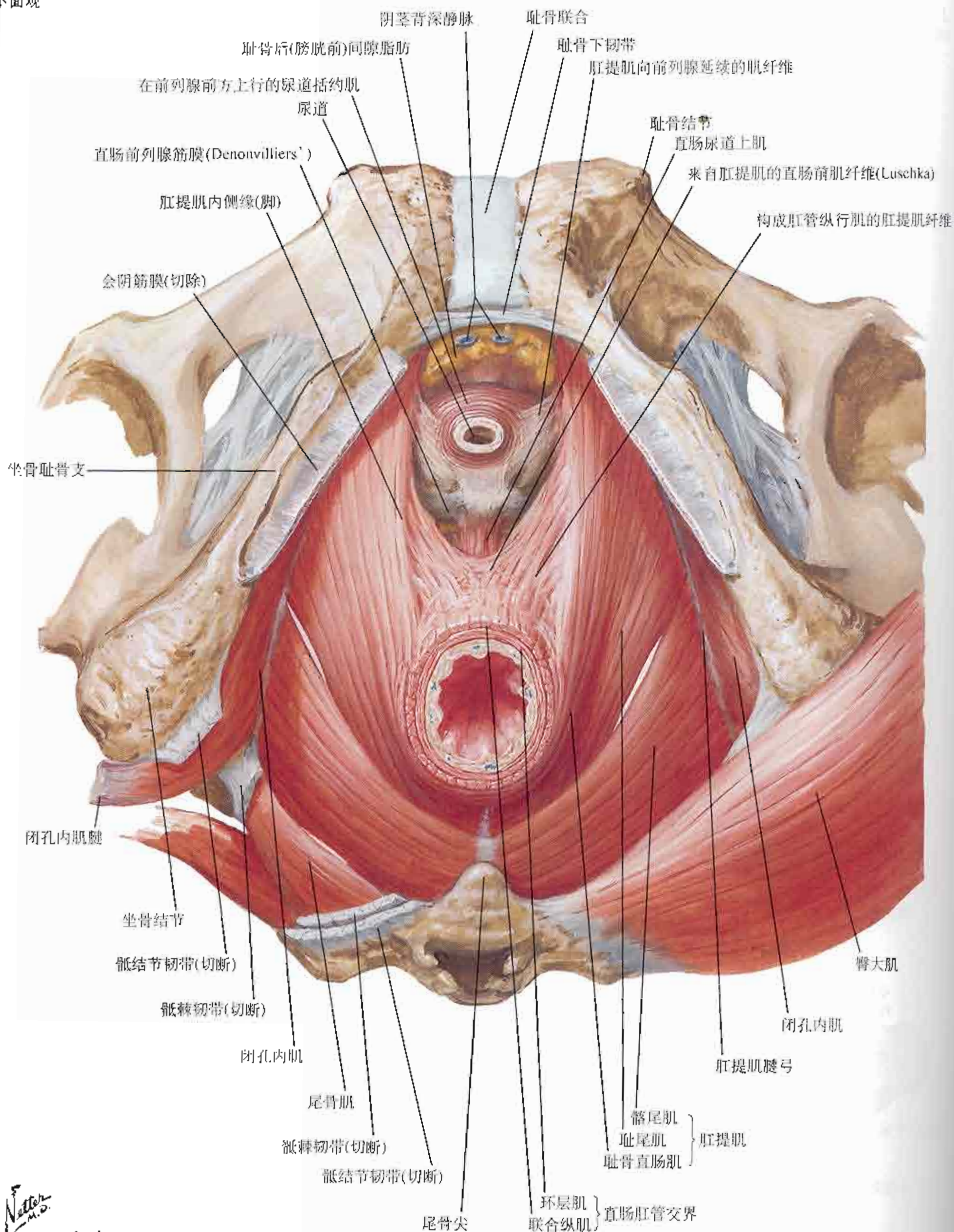


F. Netter M.D.
© 1994

盆膈：男性(续)

尿生殖膈见图366

下面观

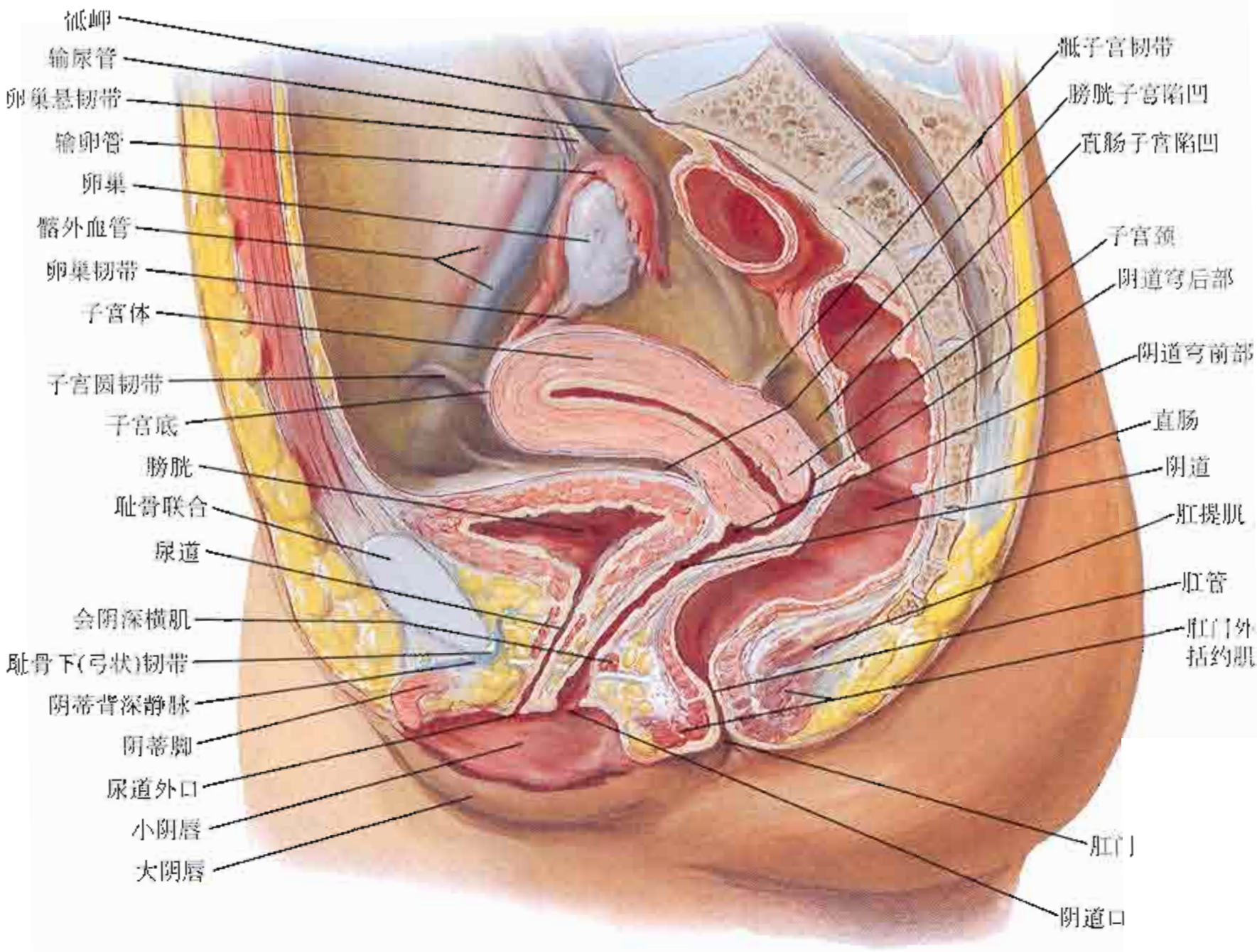


F. Natter
M.D.
C. Machado
M.D.
© IGN

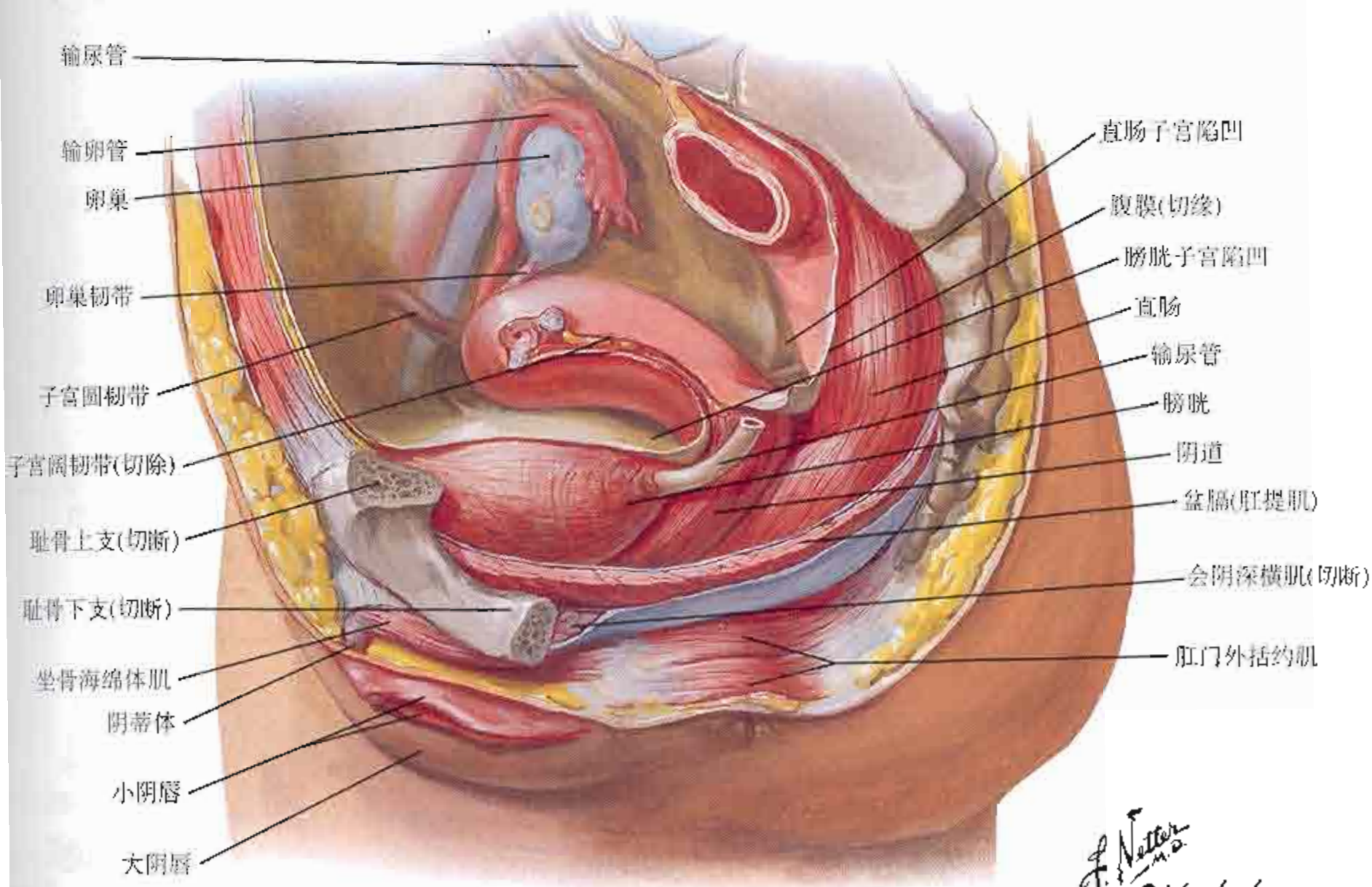
图346

盆和会阴

正中(矢状)切面



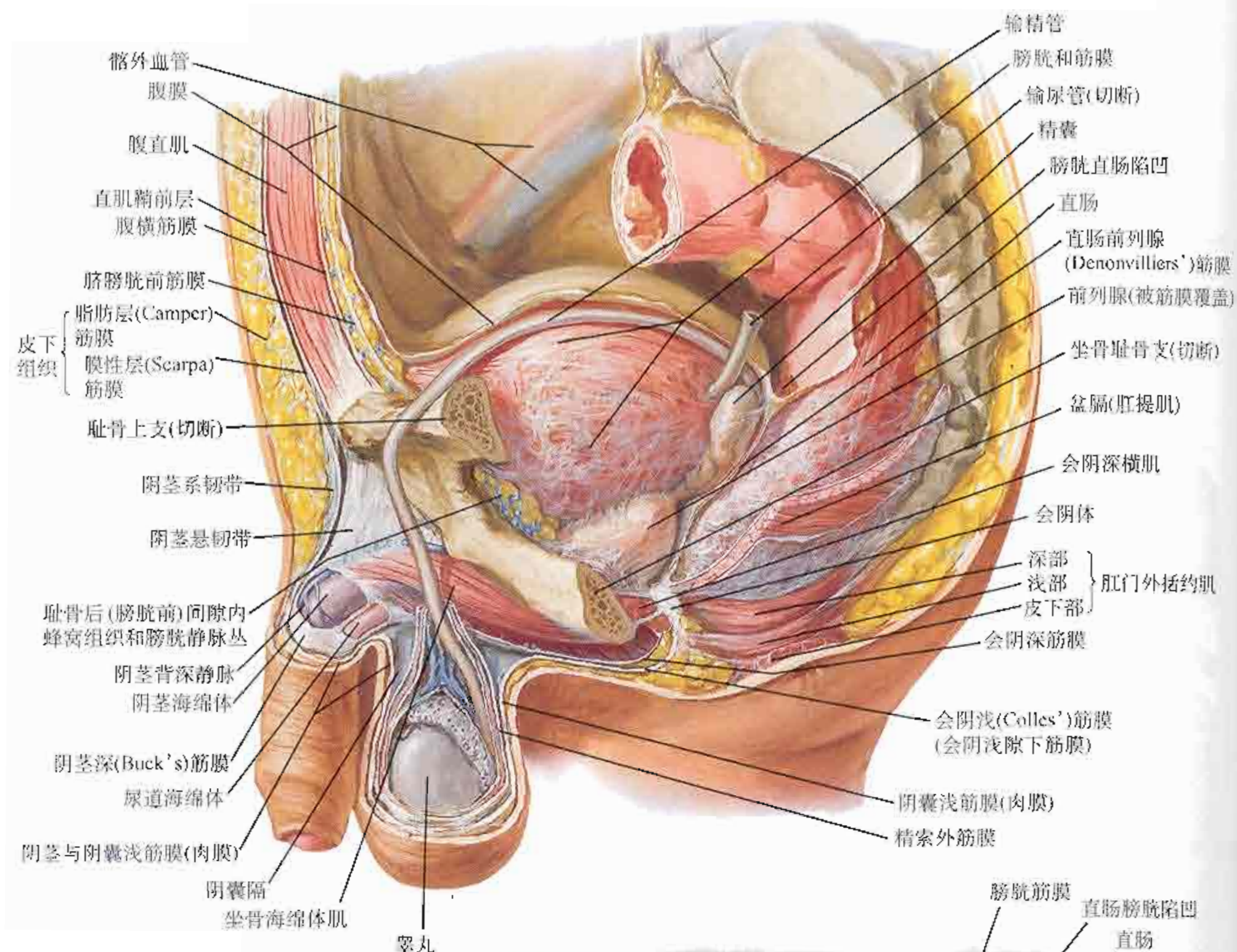
正中(矢状)切面



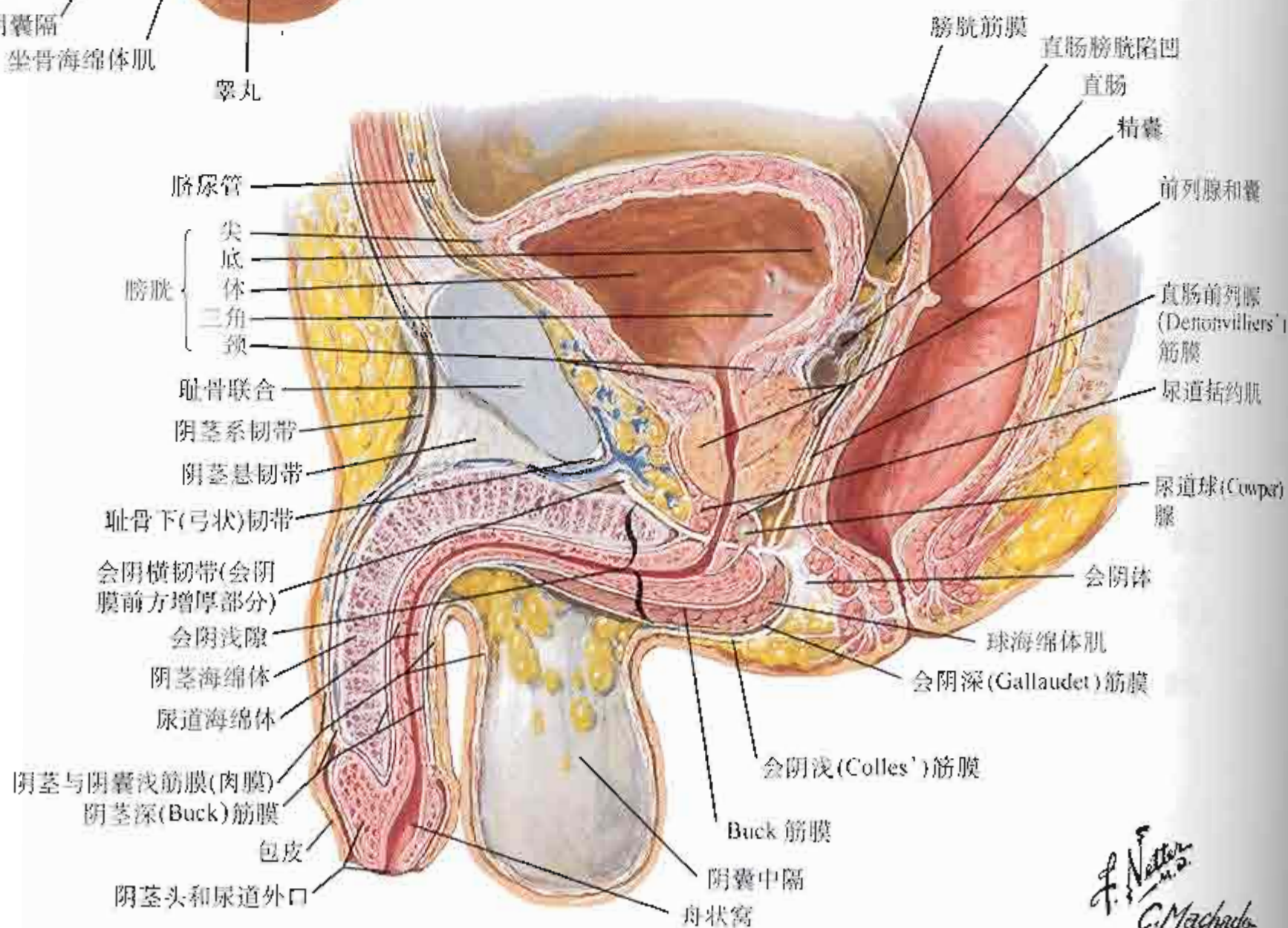
F. Netter M.D.
C. Machado M.D.
© IGM

盆腔脏器和会阴：男性

旁正中(矢状)切面



正中(矢状)切面

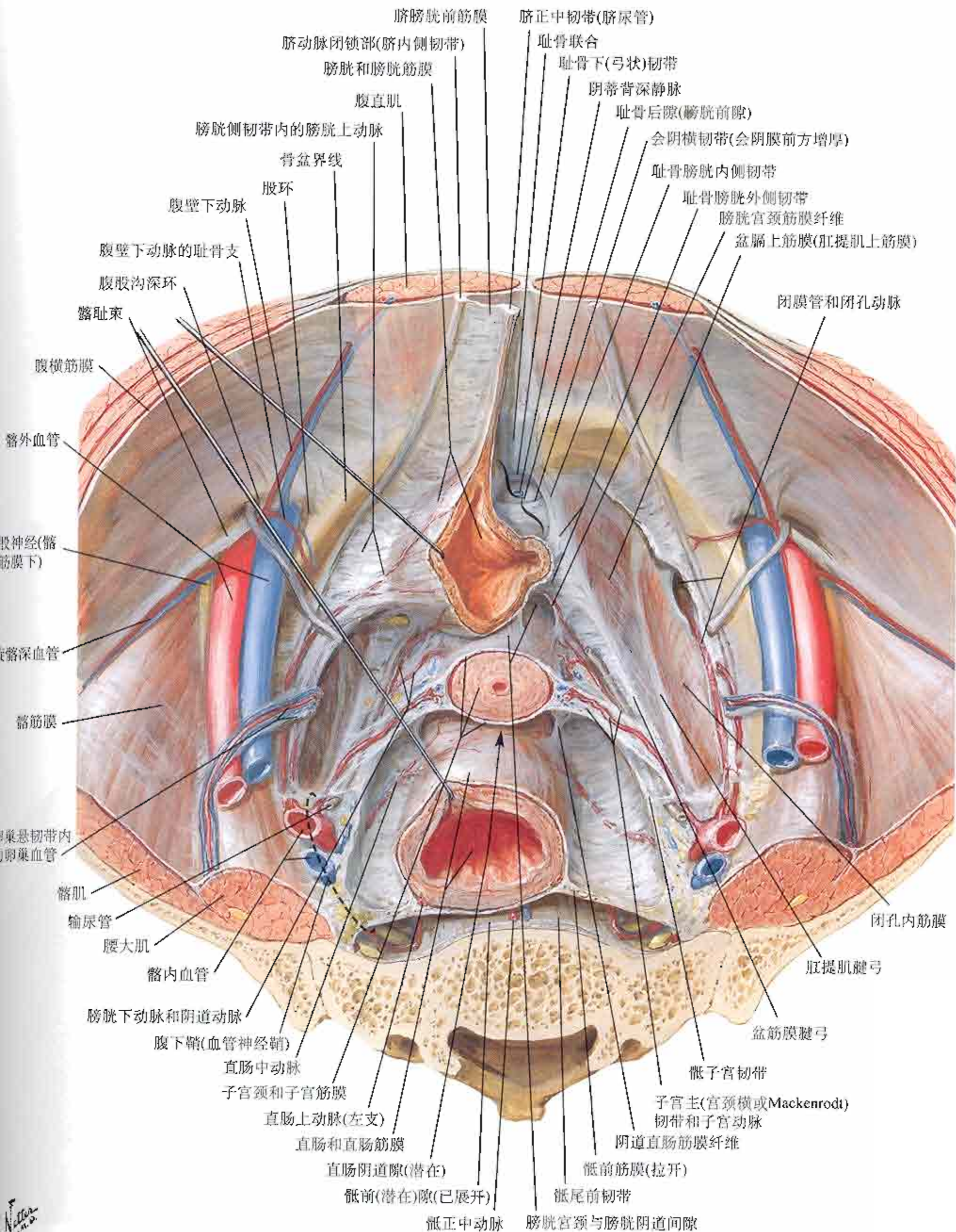


F. Netter
C. Machado
M.D.
© ION

图348

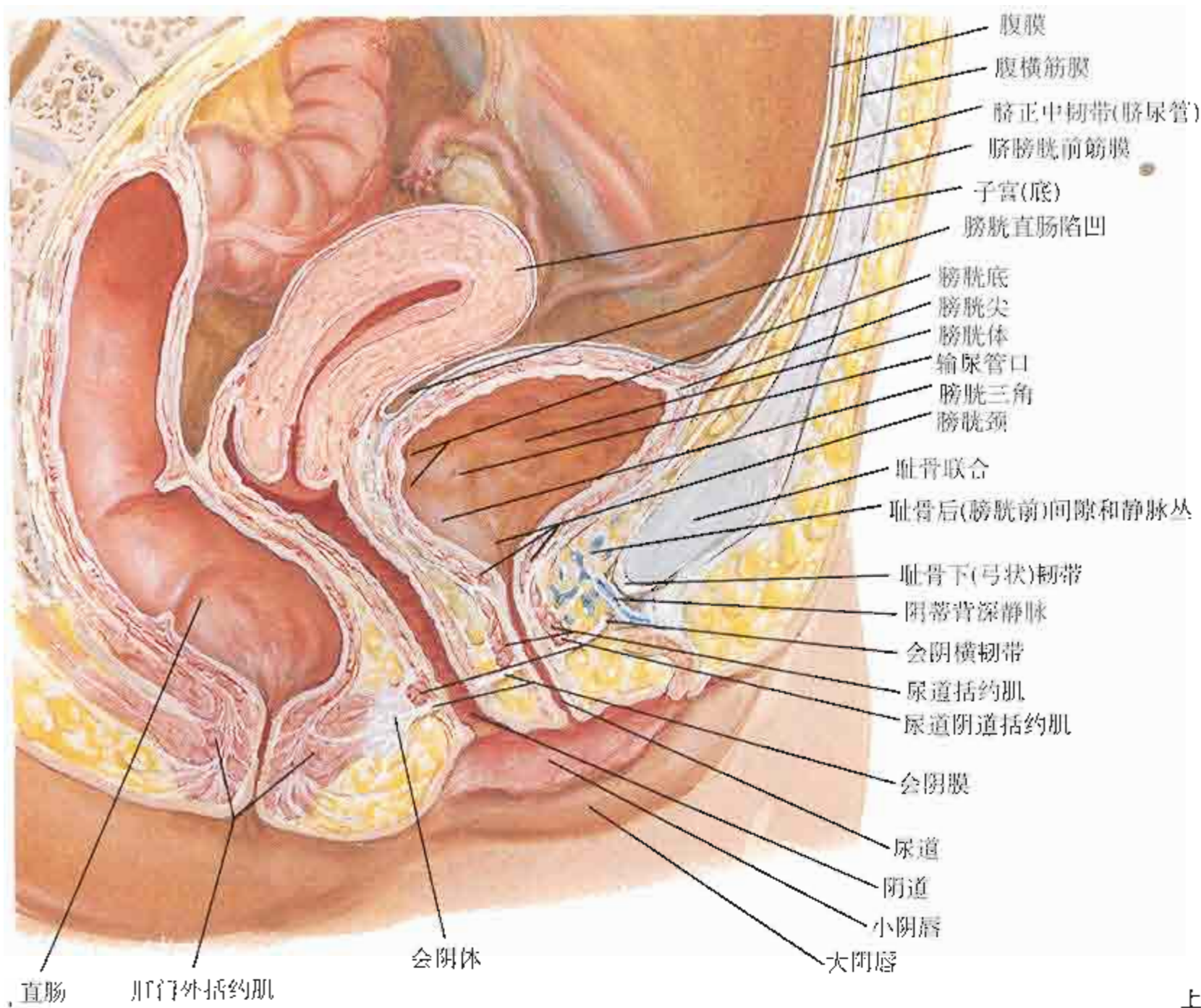
盆和会阴

性: 上面观 (已去除腹膜及疏松结缔组织)

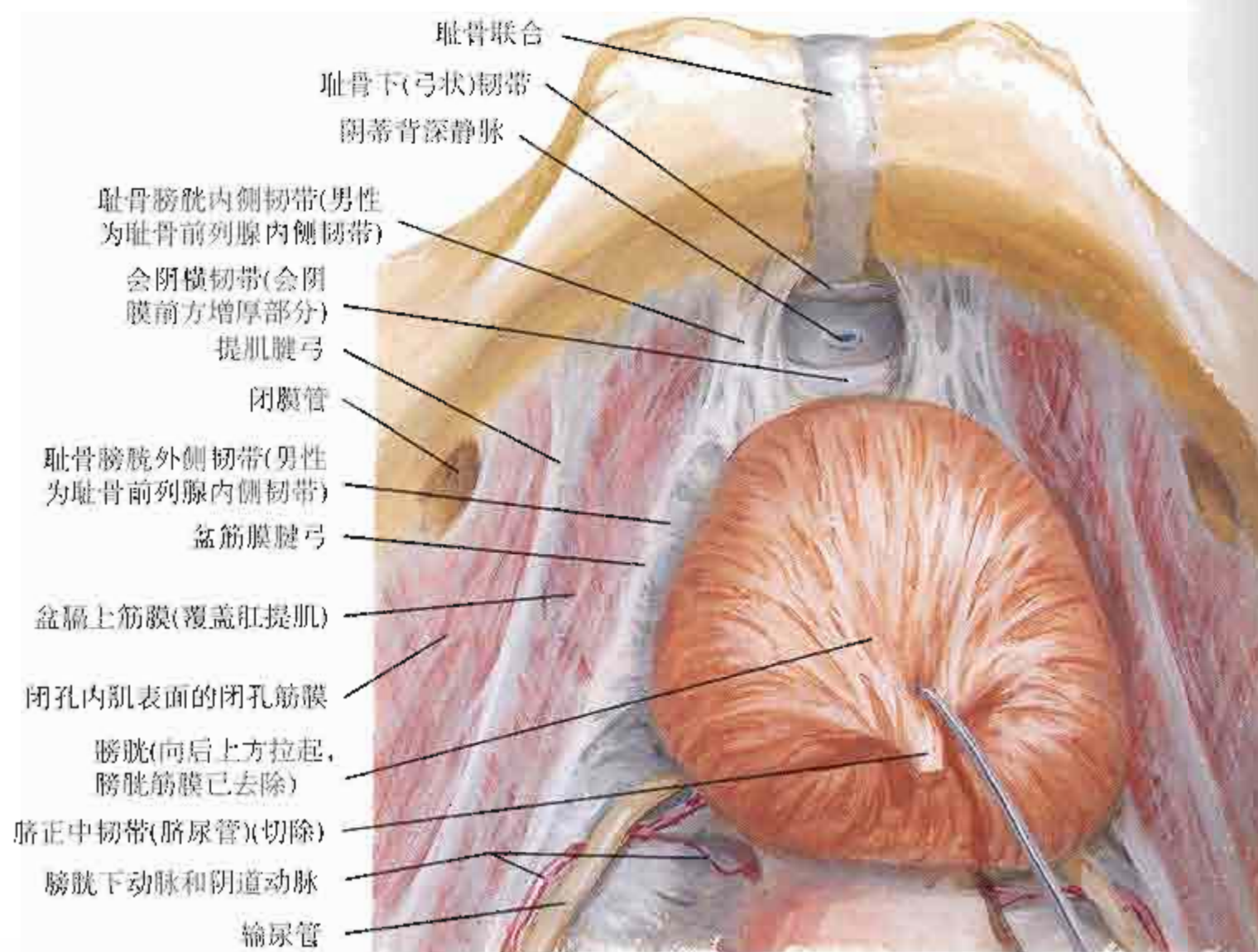


膀胱：位置和固定结构

女性：正中矢状切面

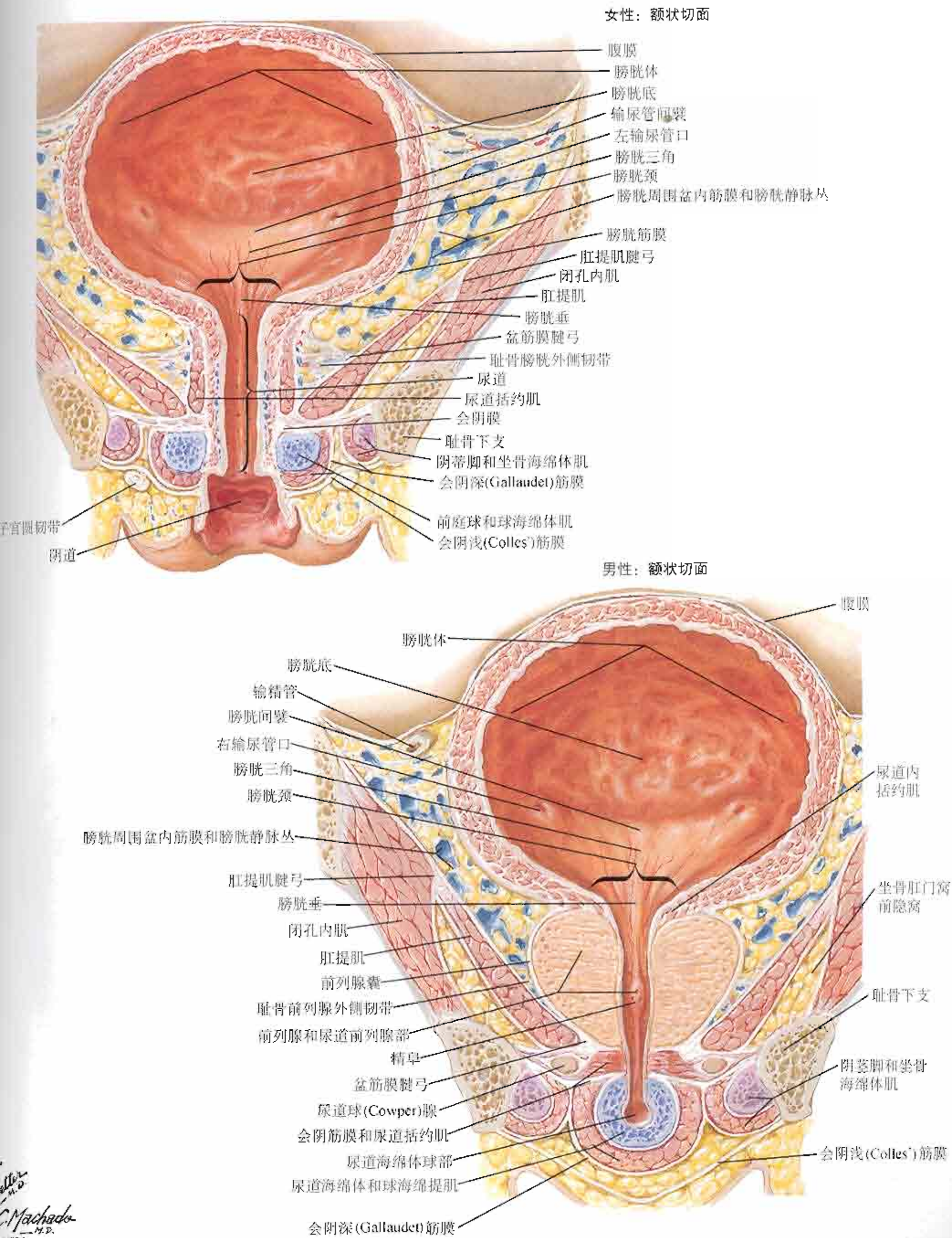


上面观：去除腹膜和膀胱筋膜



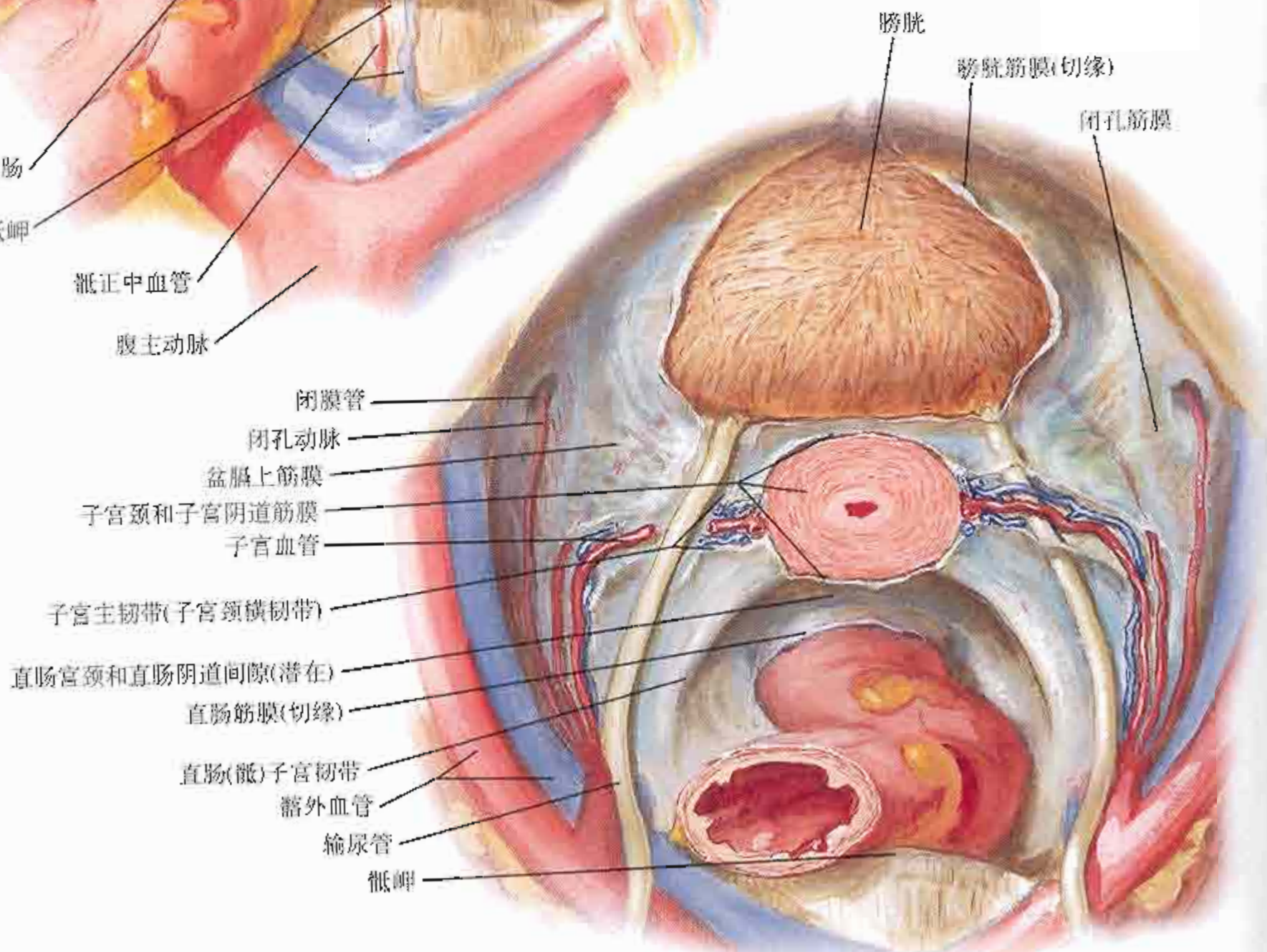
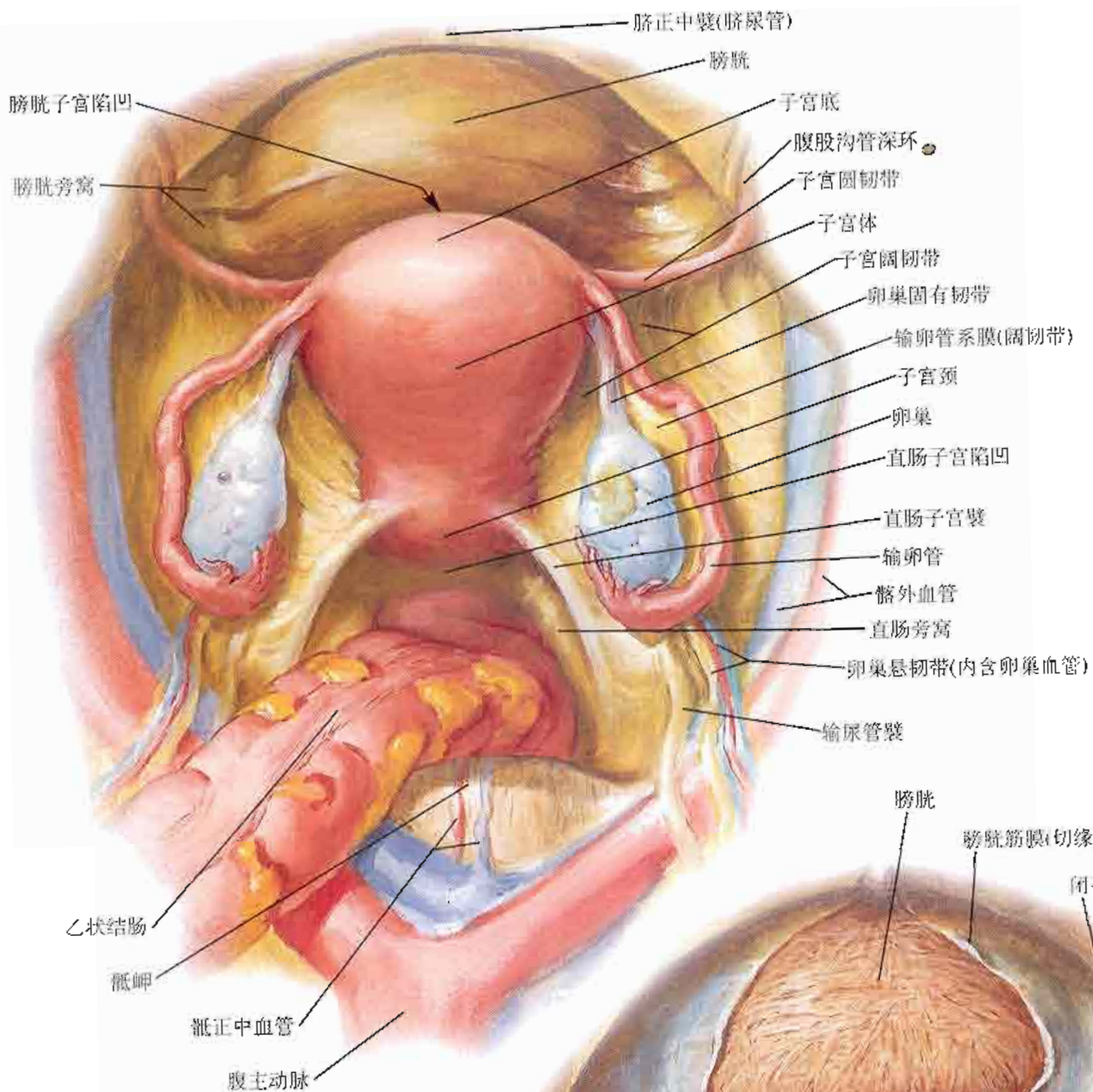
F. Netter M.D.
C. Machado M.D.
© IGCN

参见图 329、347、348、352、380、382、383、397



盆腔脏器：女性

上面观，腹膜完整

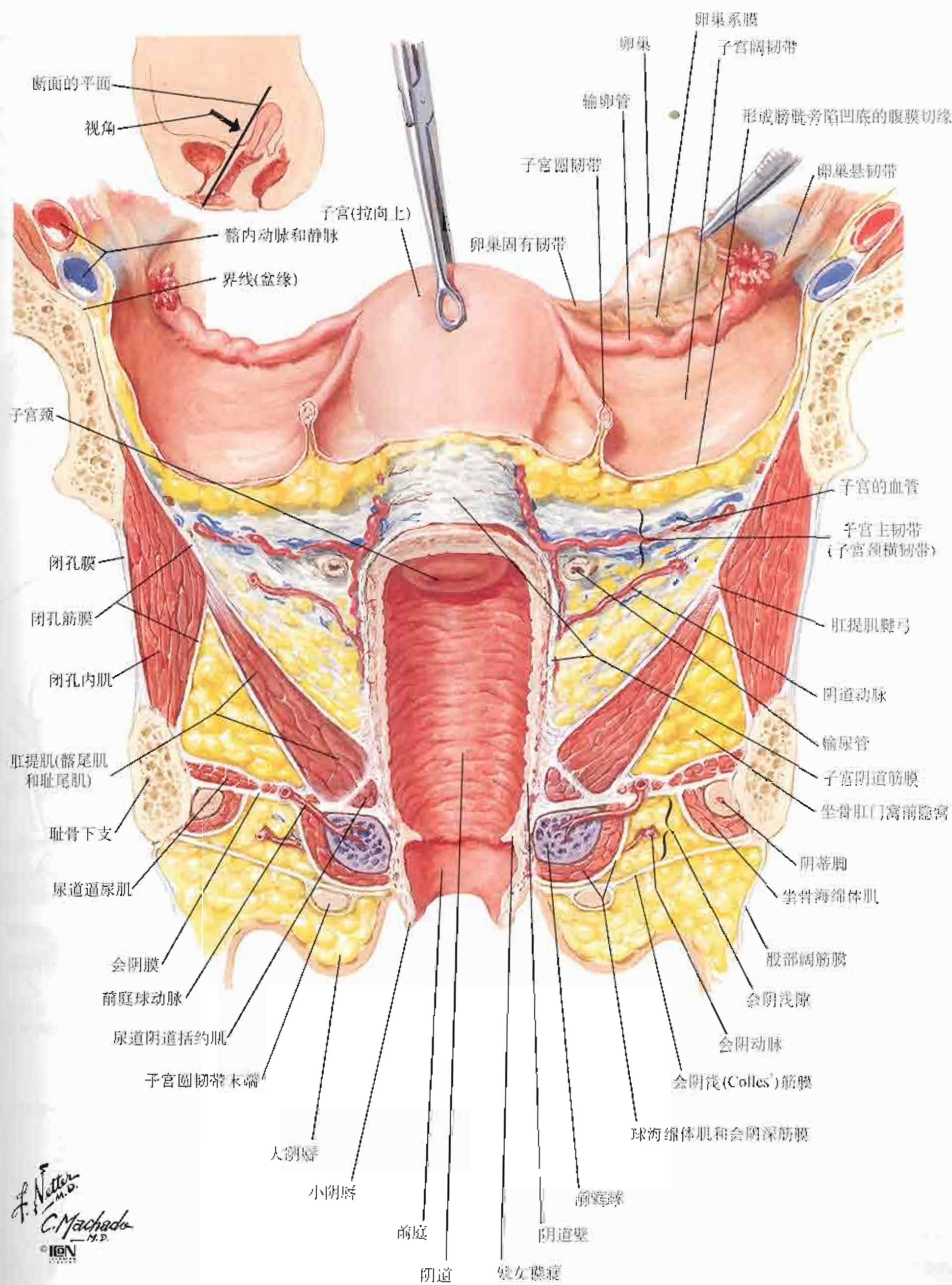


上面观，去除腹膜和子宫

F. Netter M.D. ILLUSTRATIONS

图354

参见图 380、382、384、386、392、394、395



F. Netter M.D.
C. Machado M.D.
© ION

子宫及其附件

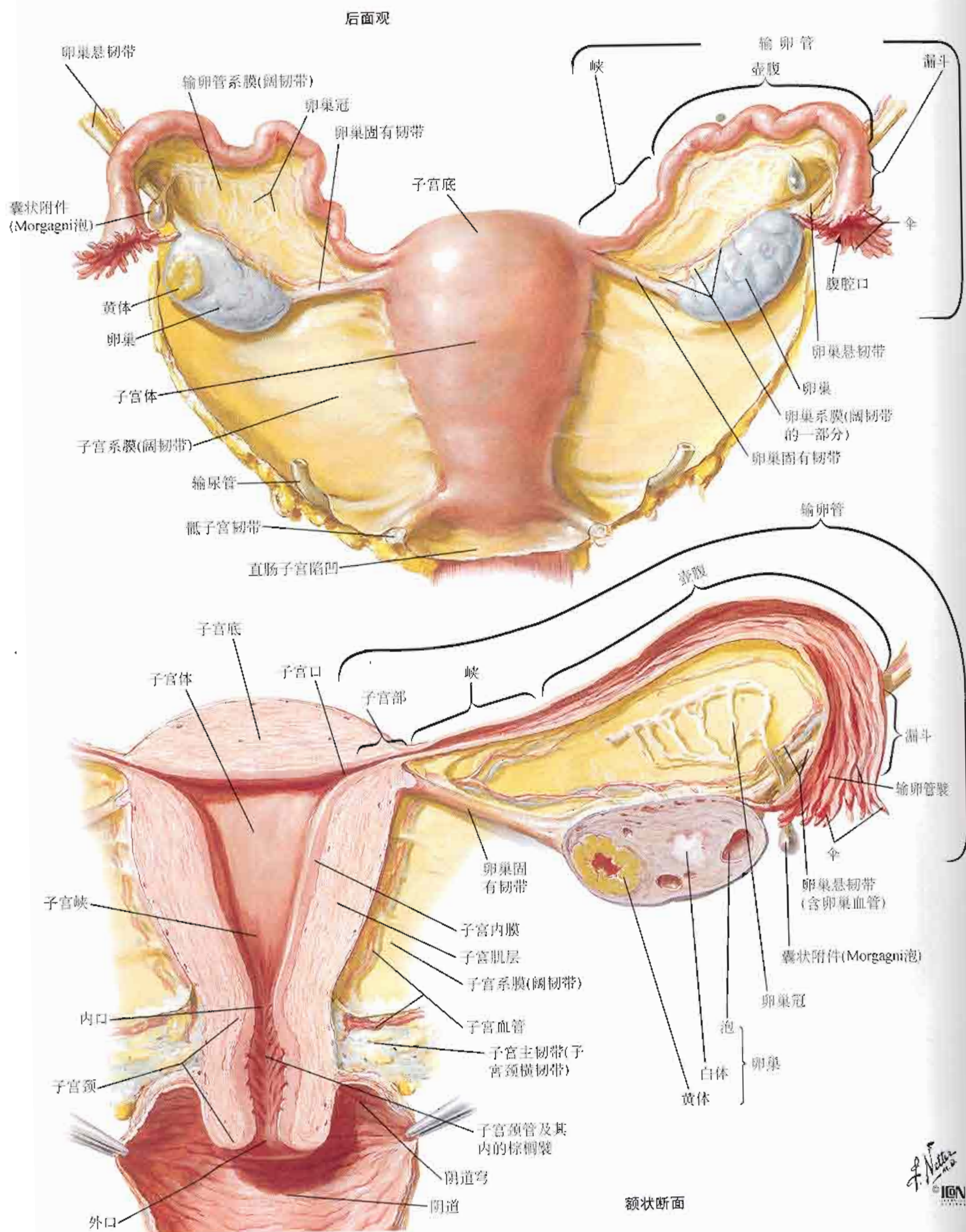
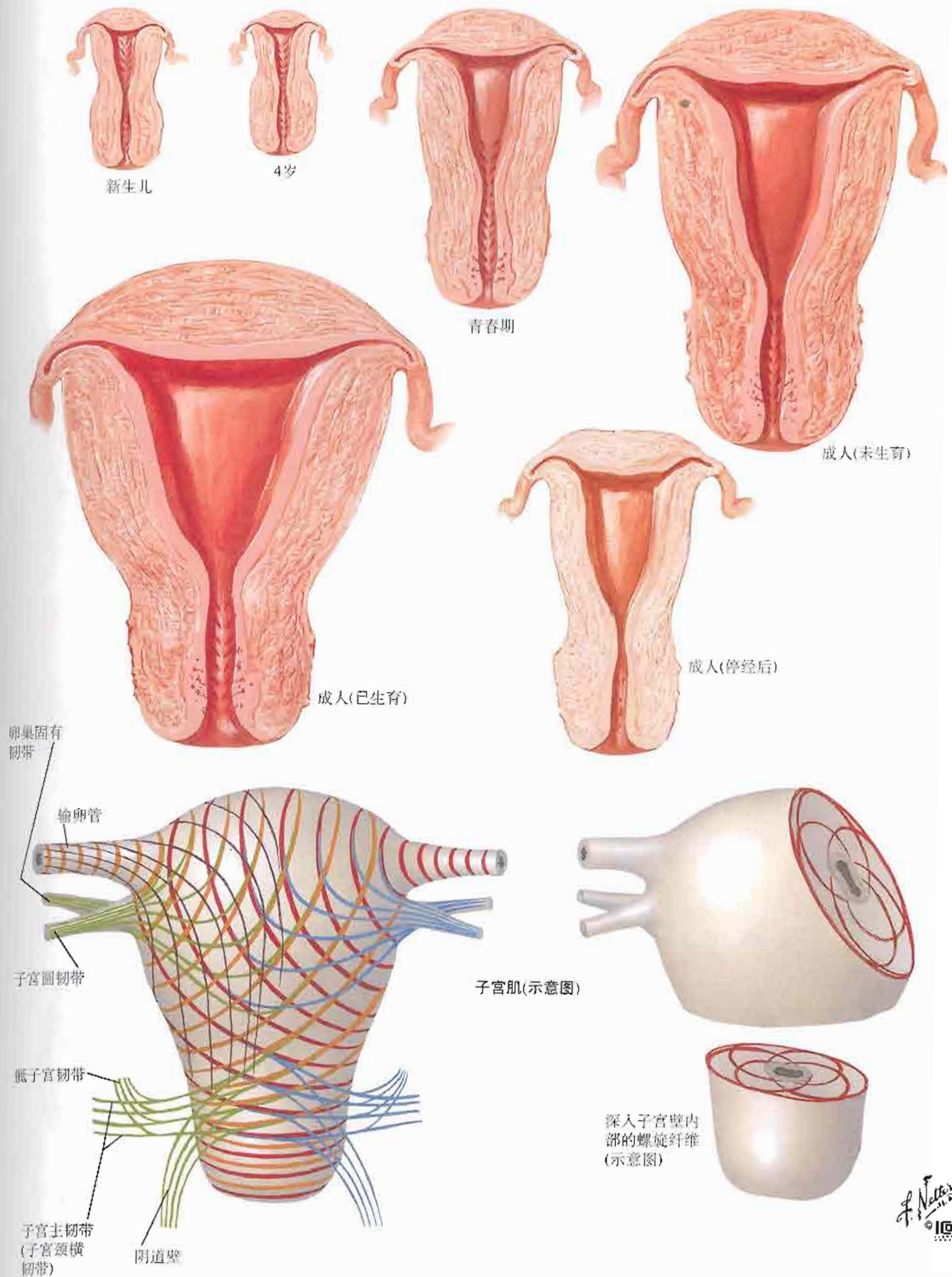


图356

盆和会阴



F. Netter M.D. ILLUSTRATIONS

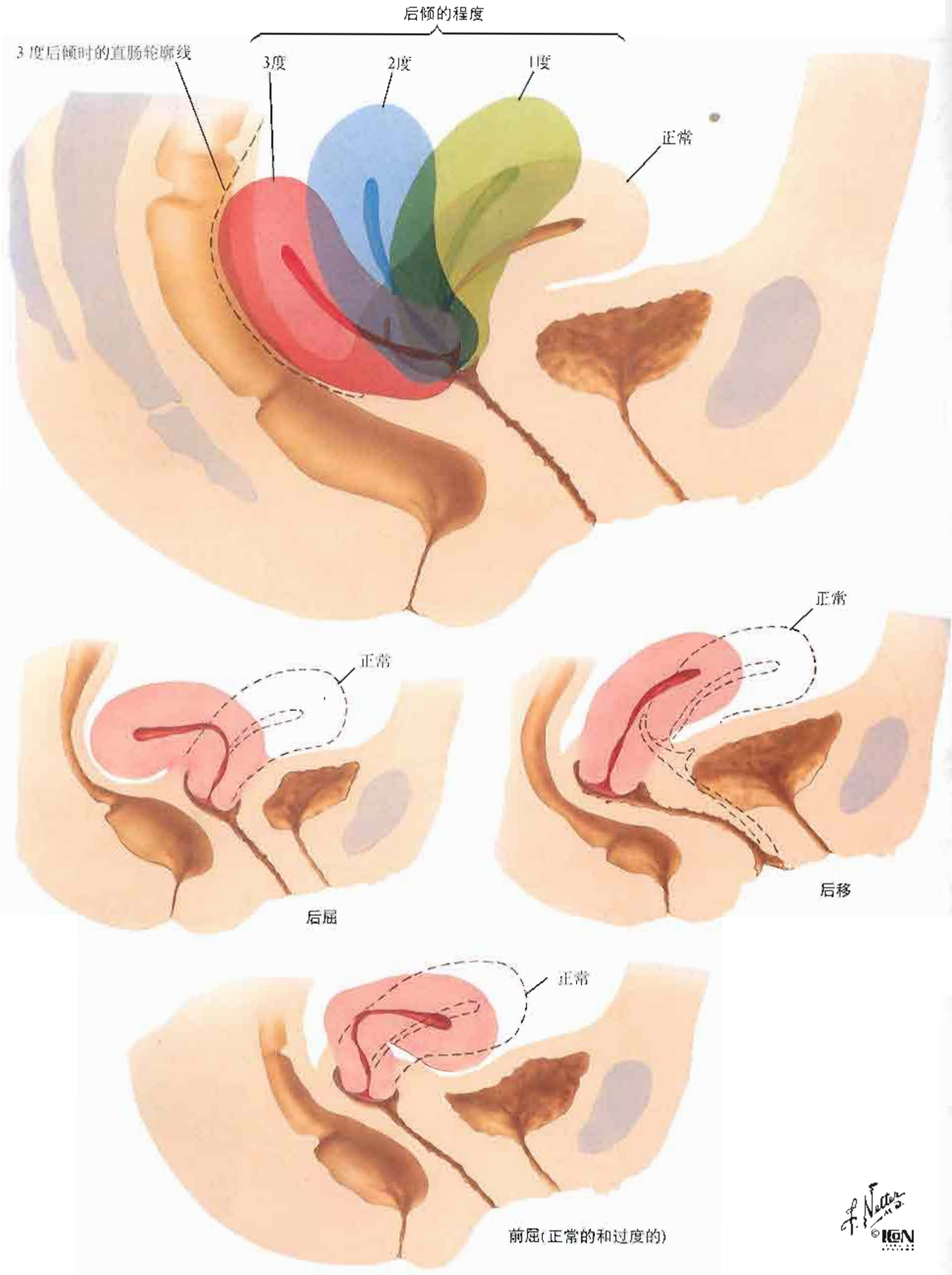
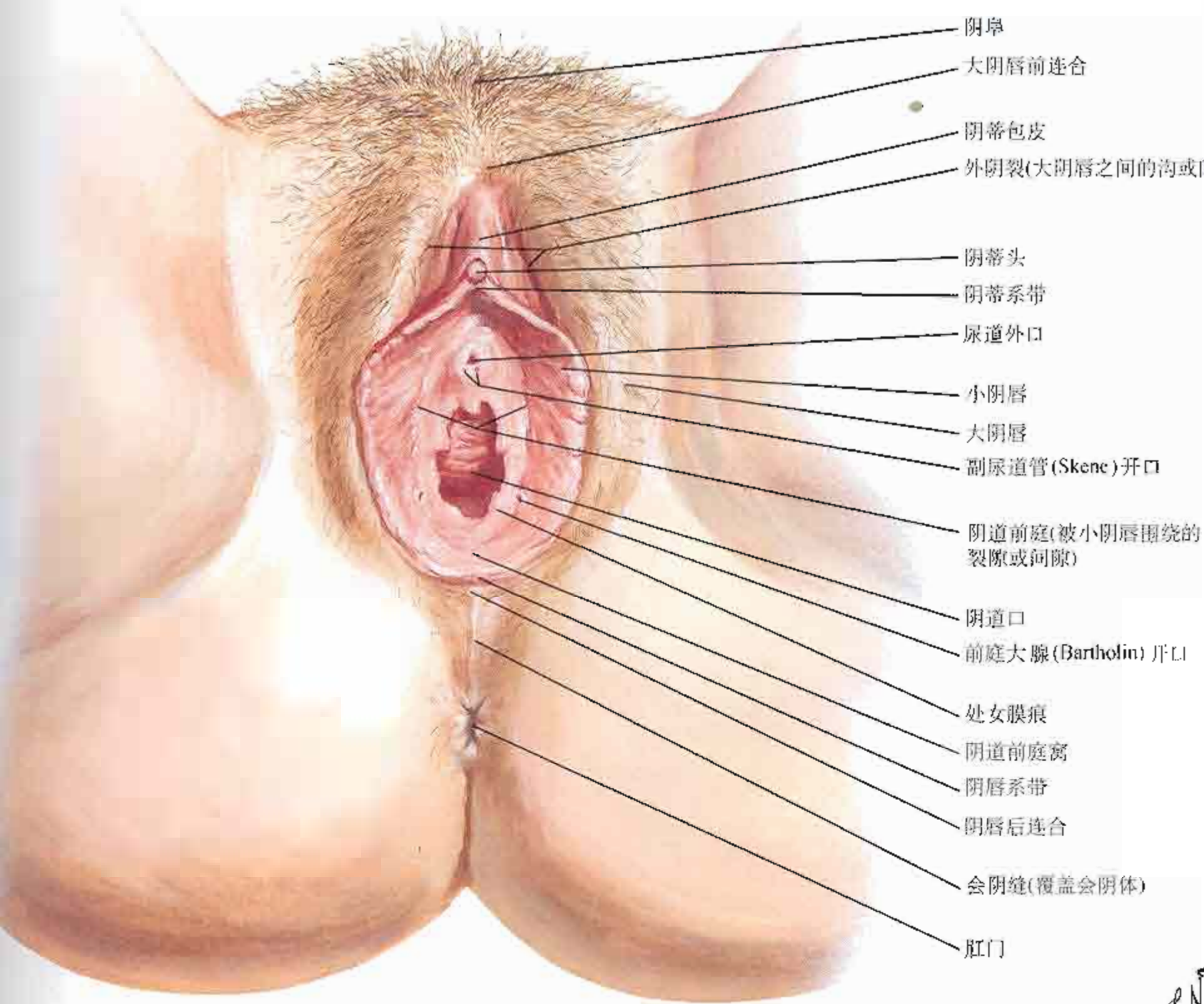
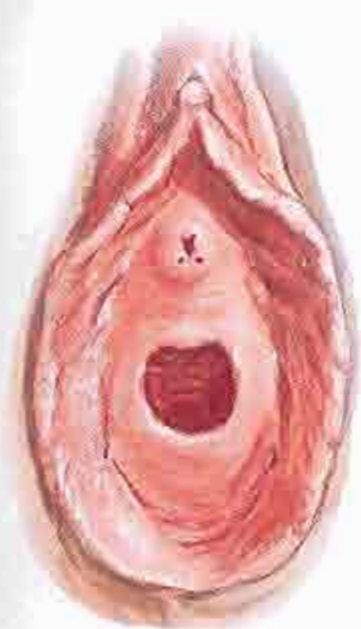


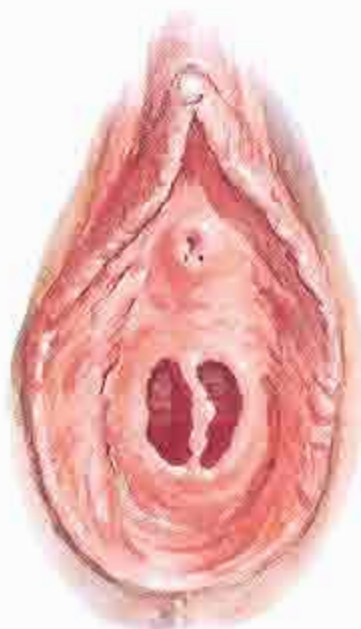
图358



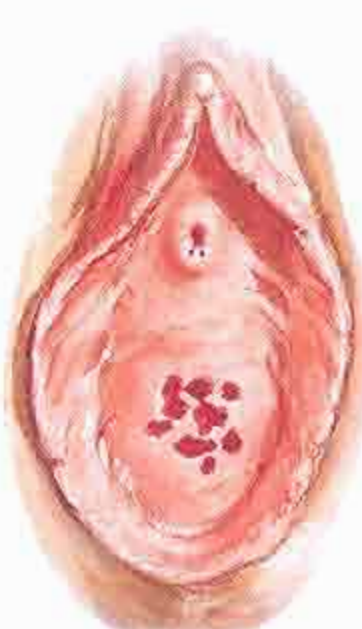
F. Netter M.D.
© ION



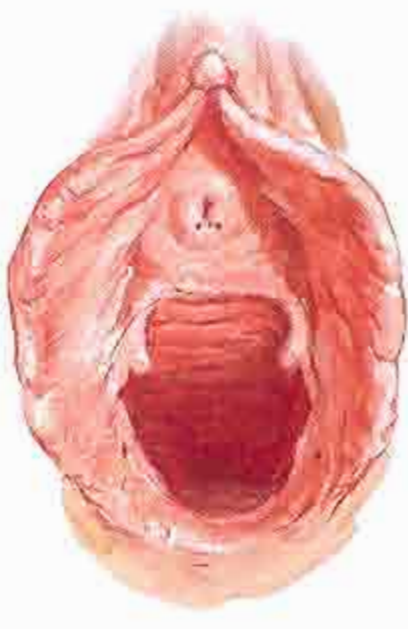
环形处女膜



中隔处女膜



筛状处女膜



生育后处女膜

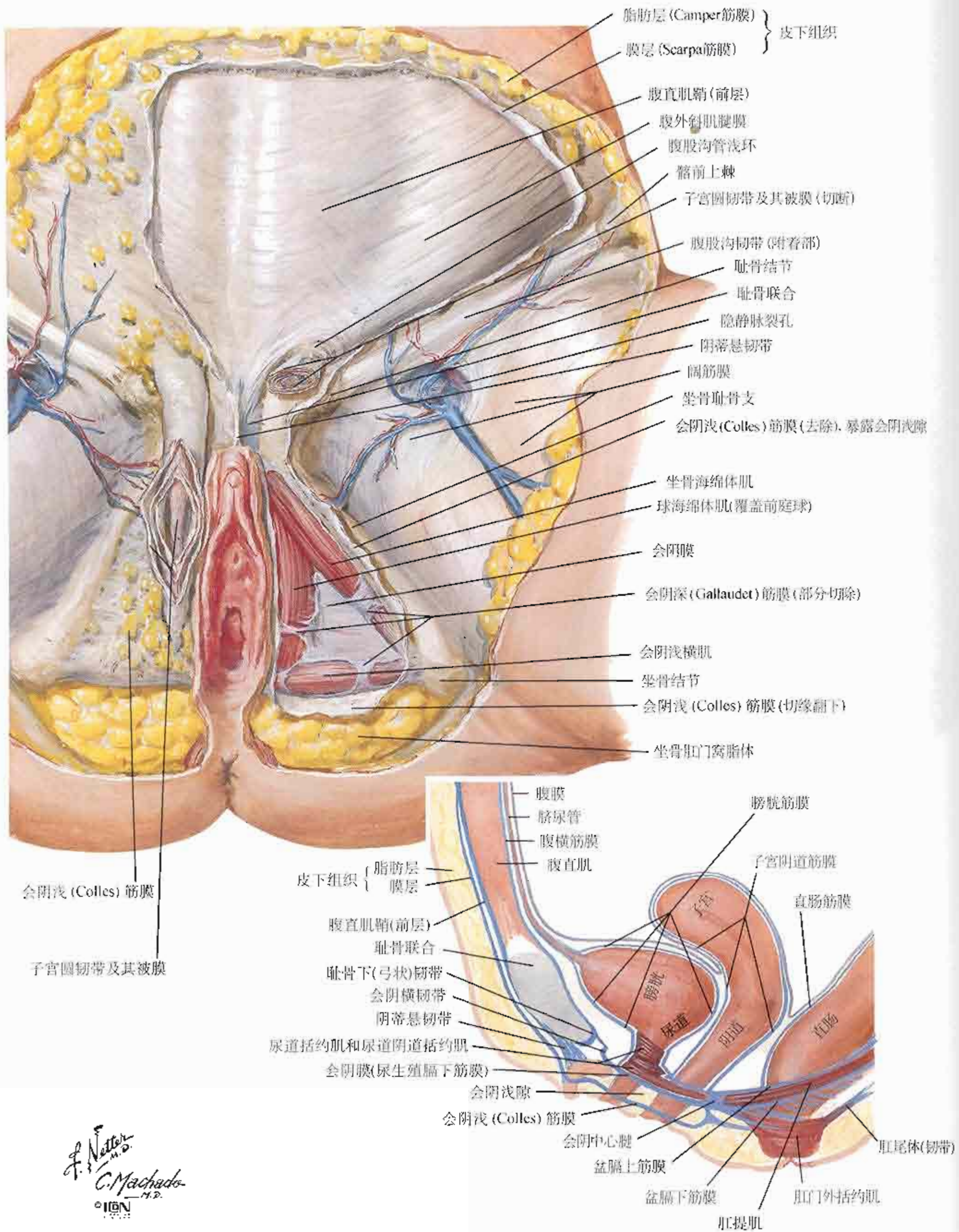
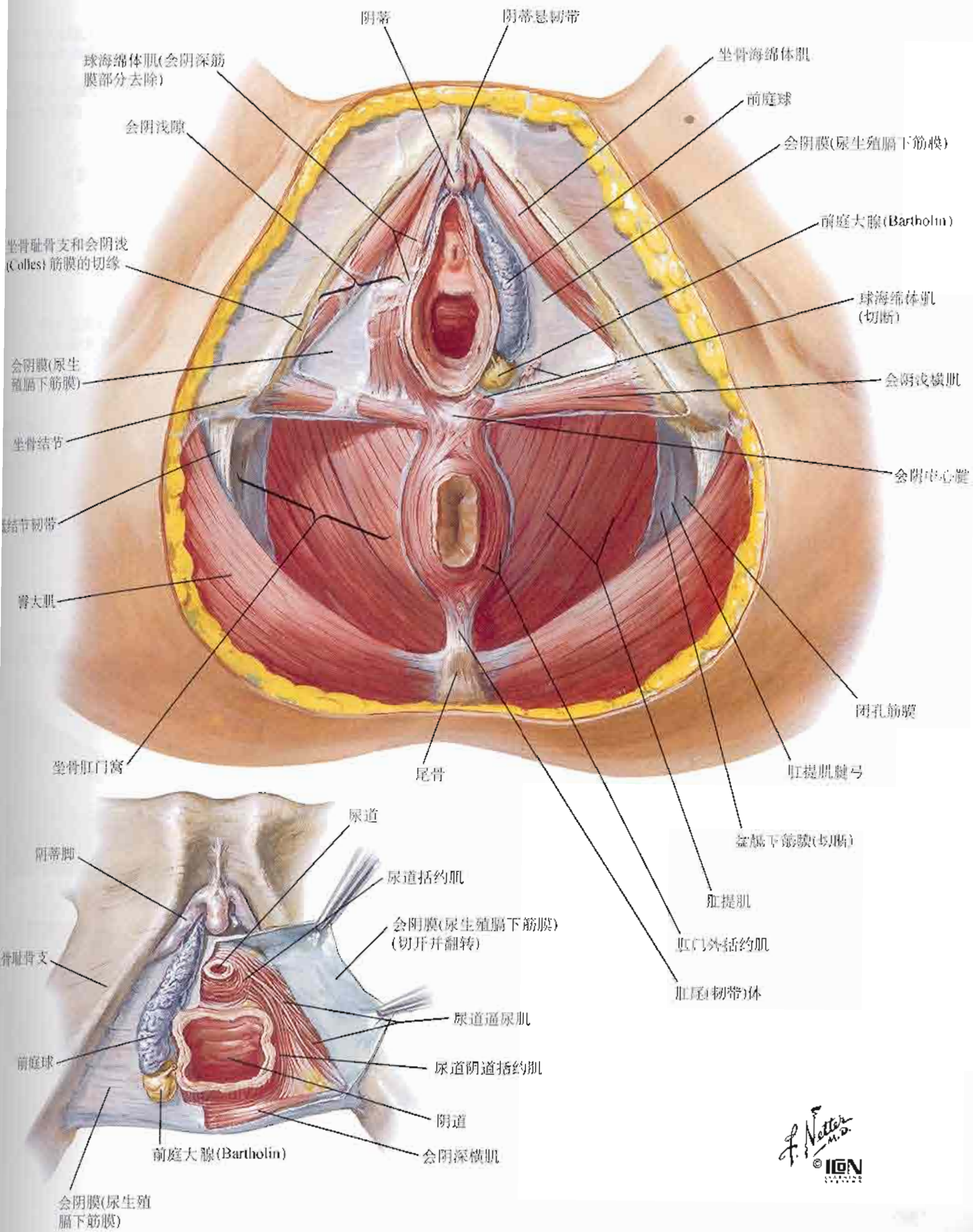


图360





运动科学网站



运动科学网站



运动科学网站

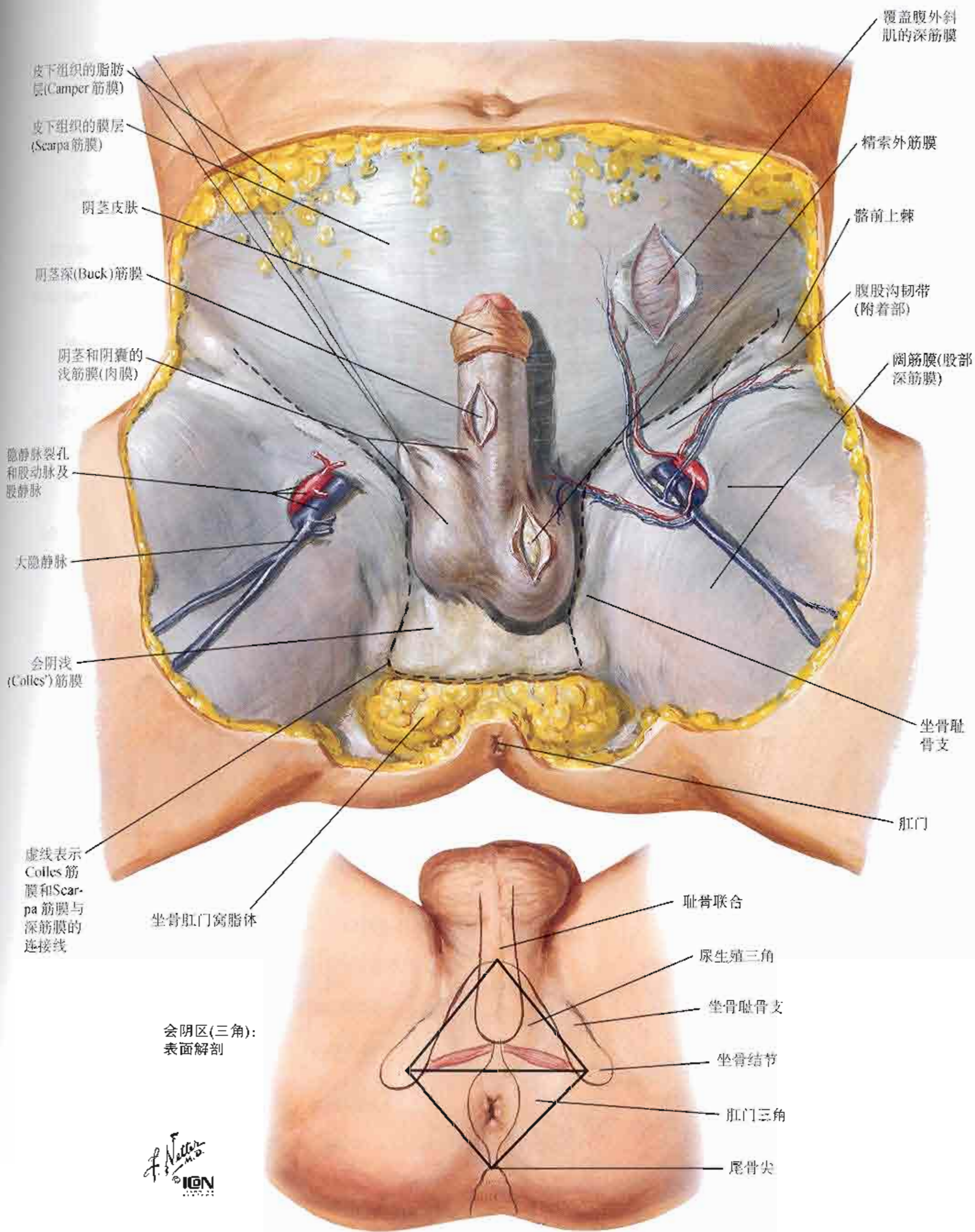


运动科学网站



运动科学网站

www.vo2maxcn.com



会阴和外生殖器(深层解剖)

参见图 383、385、388~391、396

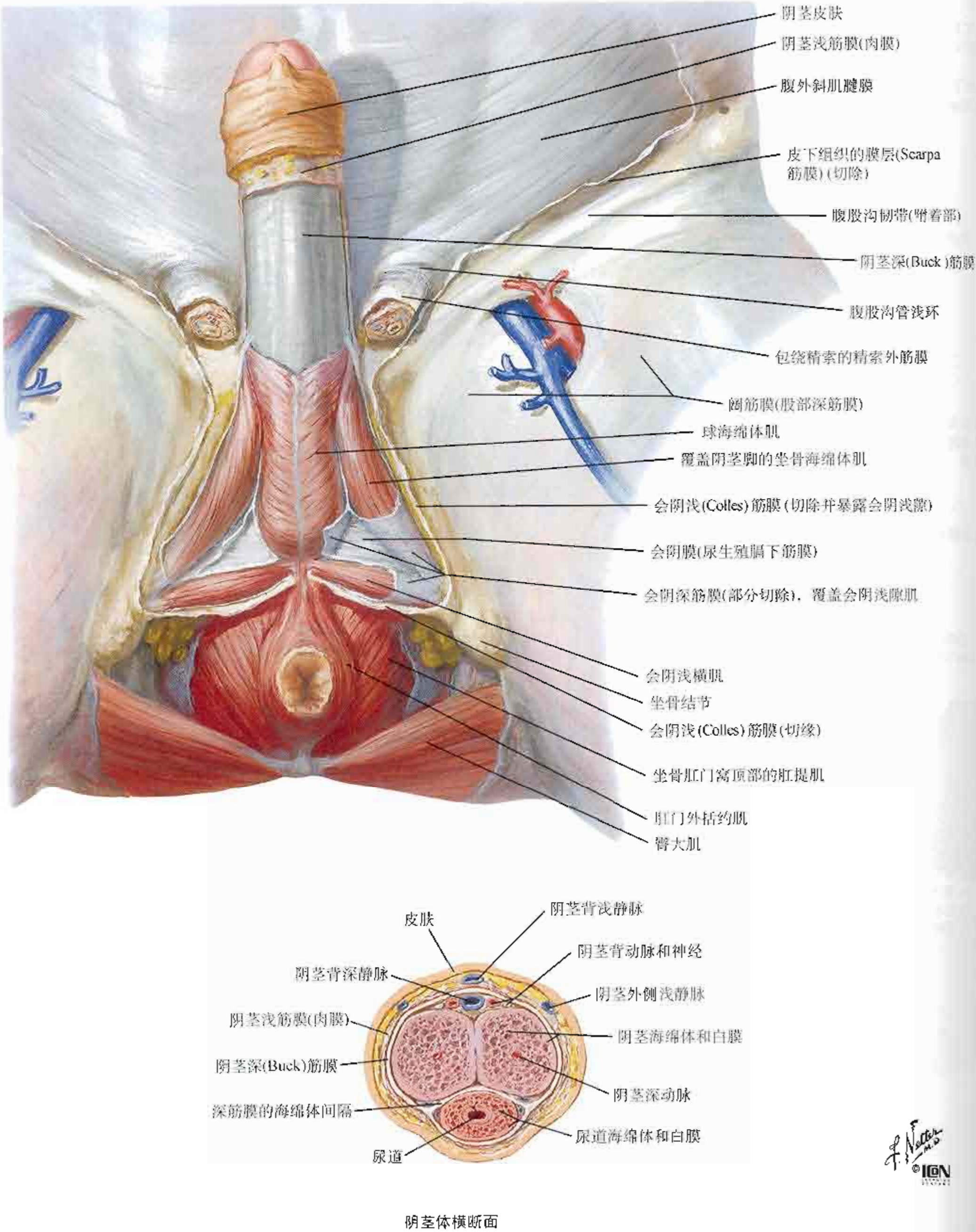


图364

盆和会阴



运动科学网站



运动科学网站



运动科学网站



运动科学网站



运动科学网站



运动科学网站



运动科学网站



运动科学网站



运动科学网站



运动科学网站



运动科学网站



运动科学网站



运动科学网站



运动科学网站

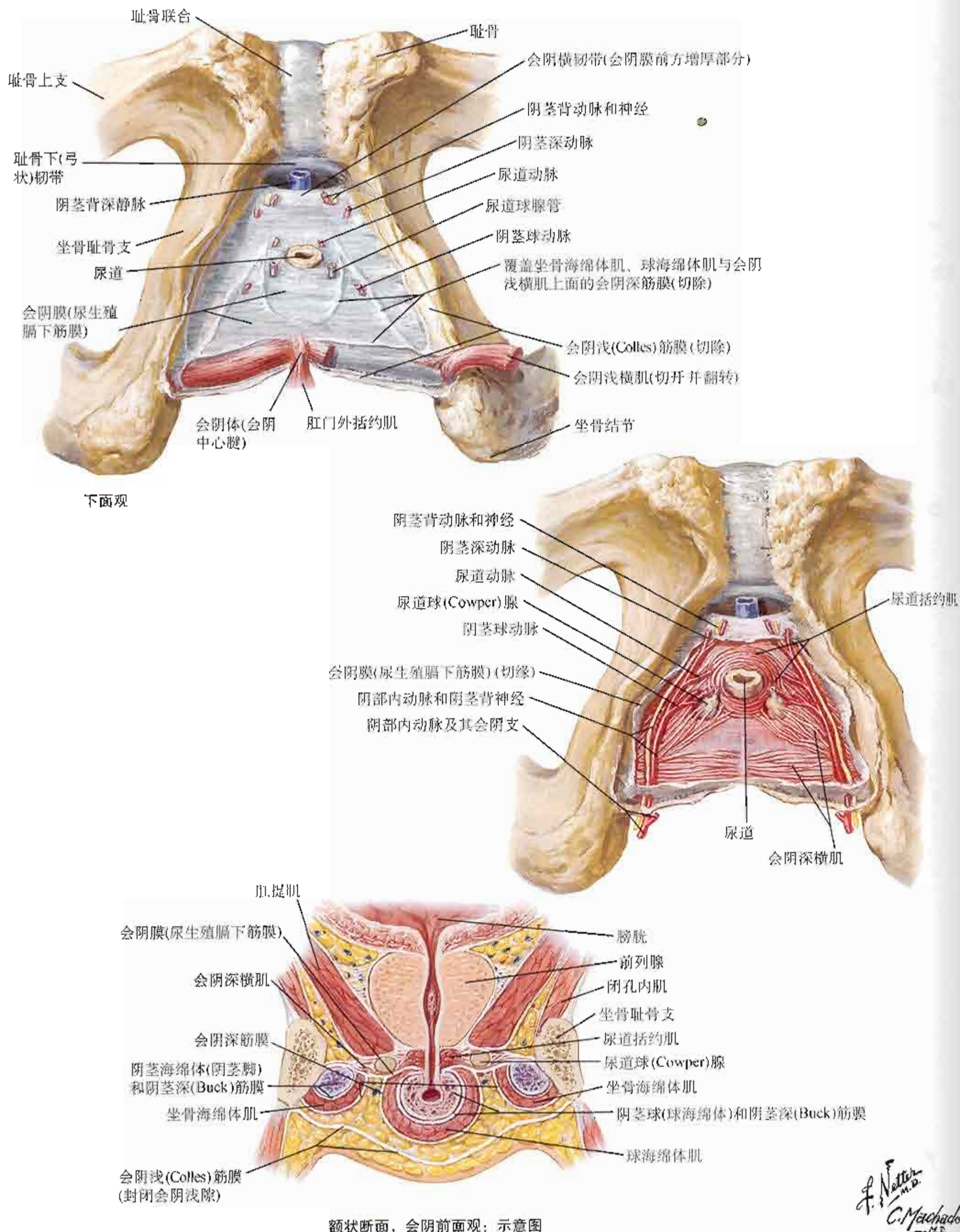
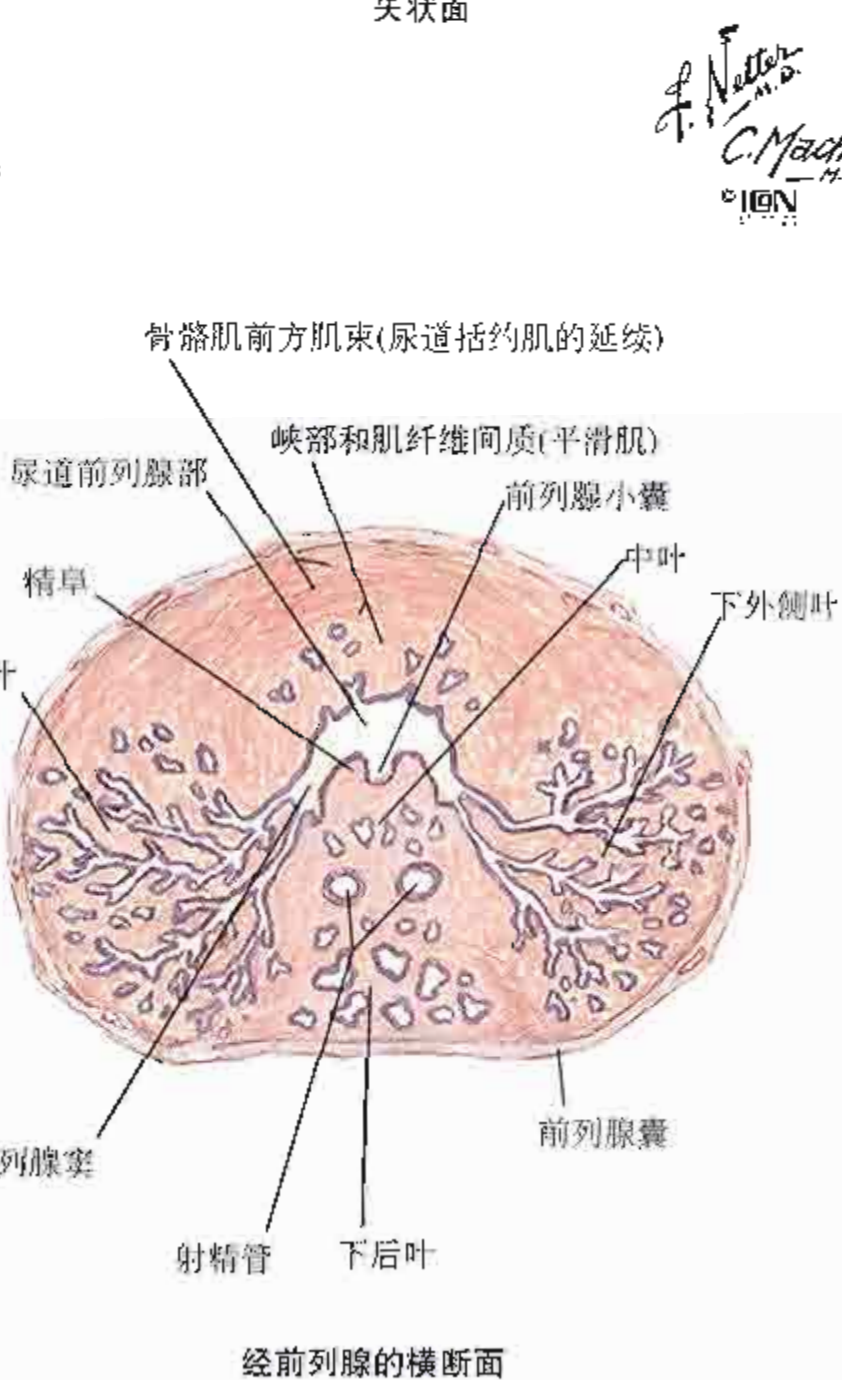
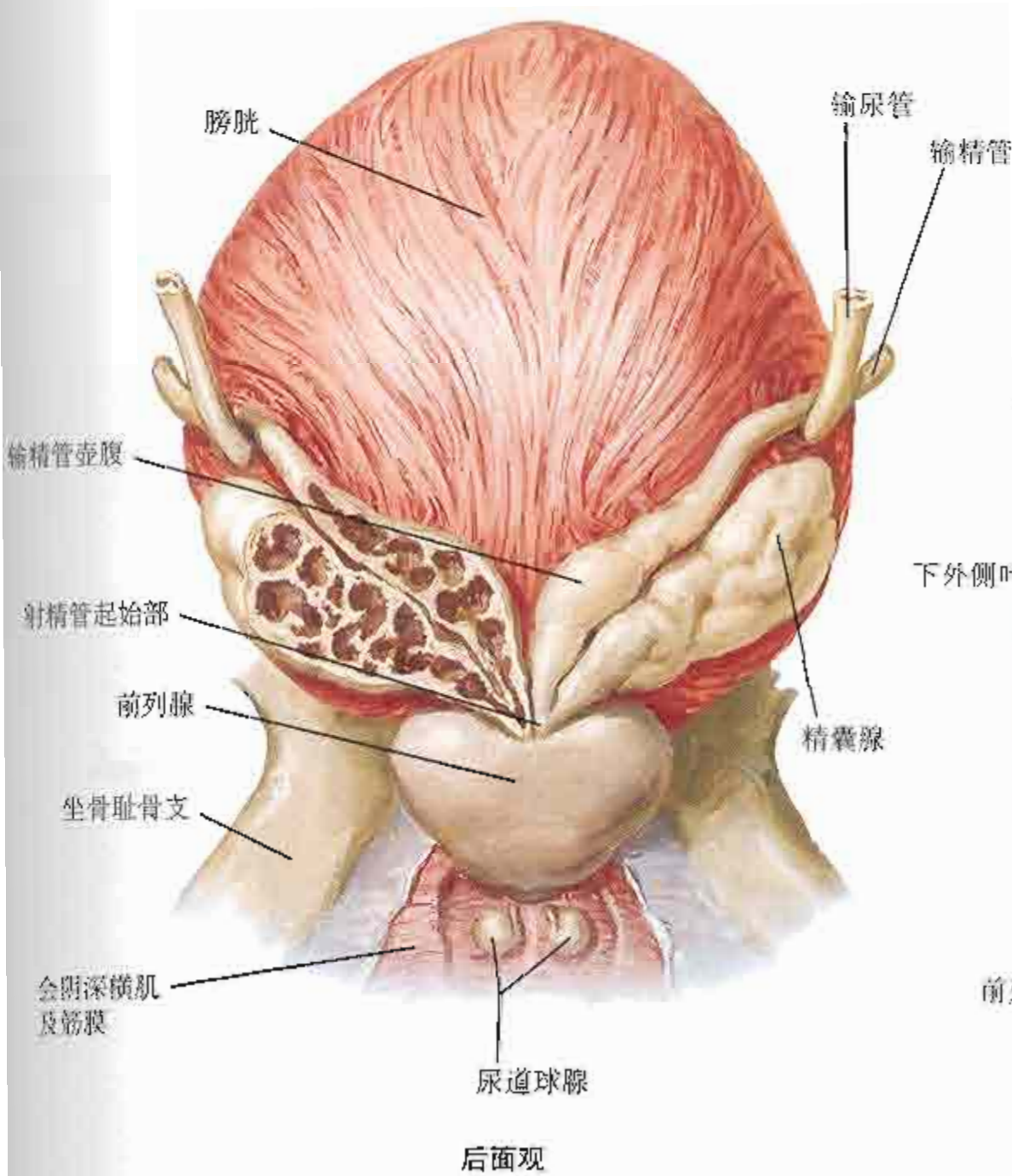
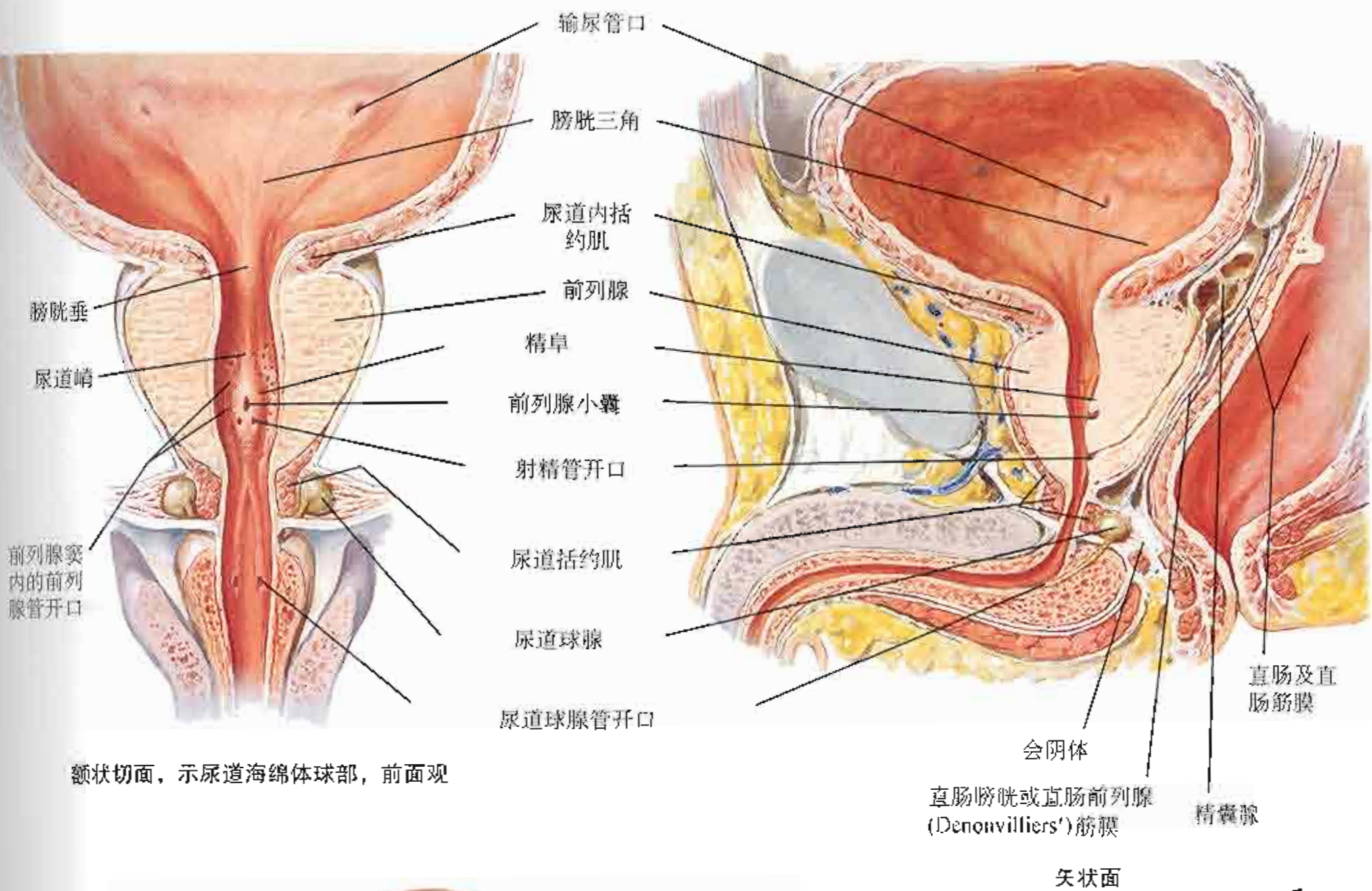


图366

参见图 348、350、353、383、390



F. Netter M.D.
C. Machado M.D.
© 1998

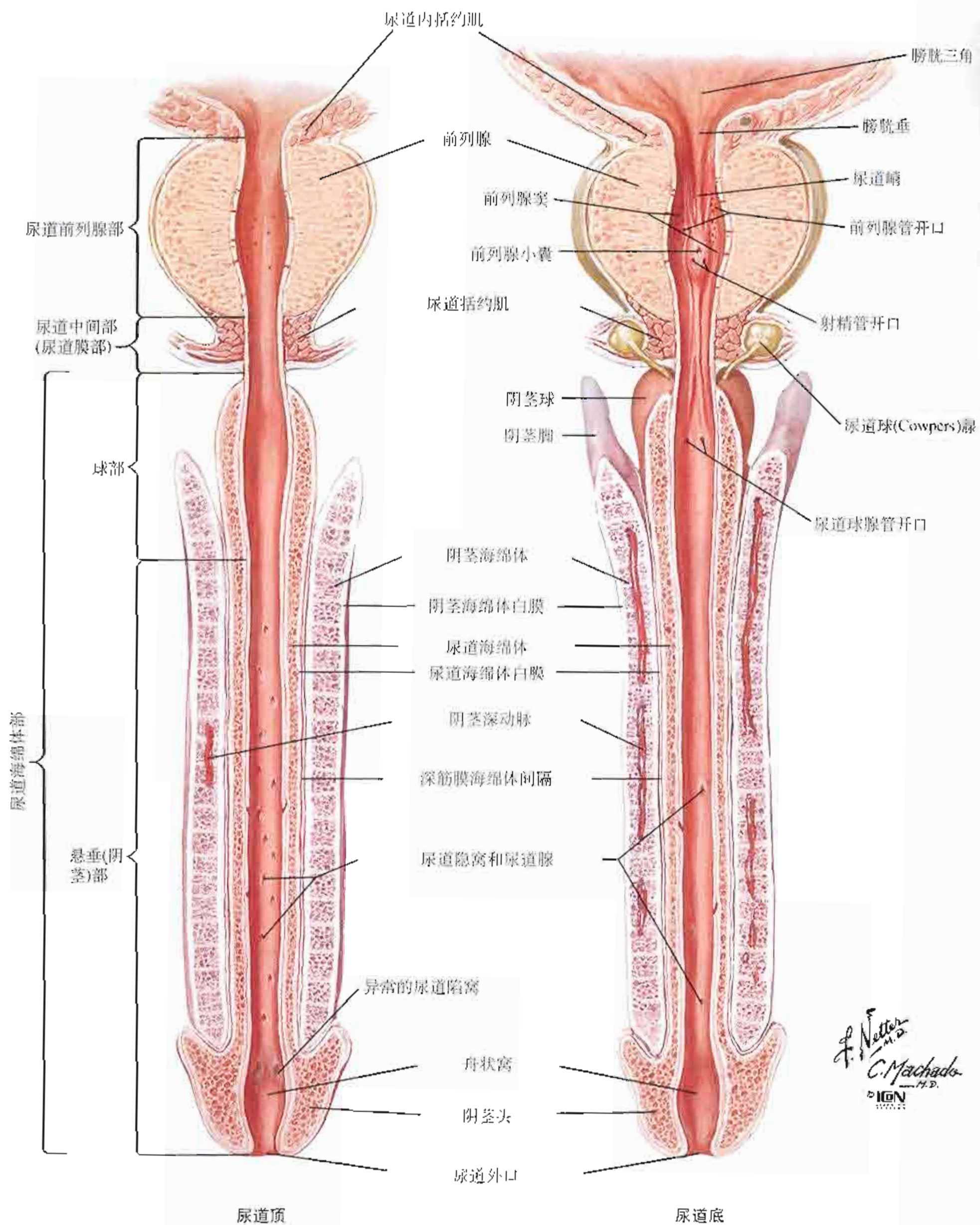
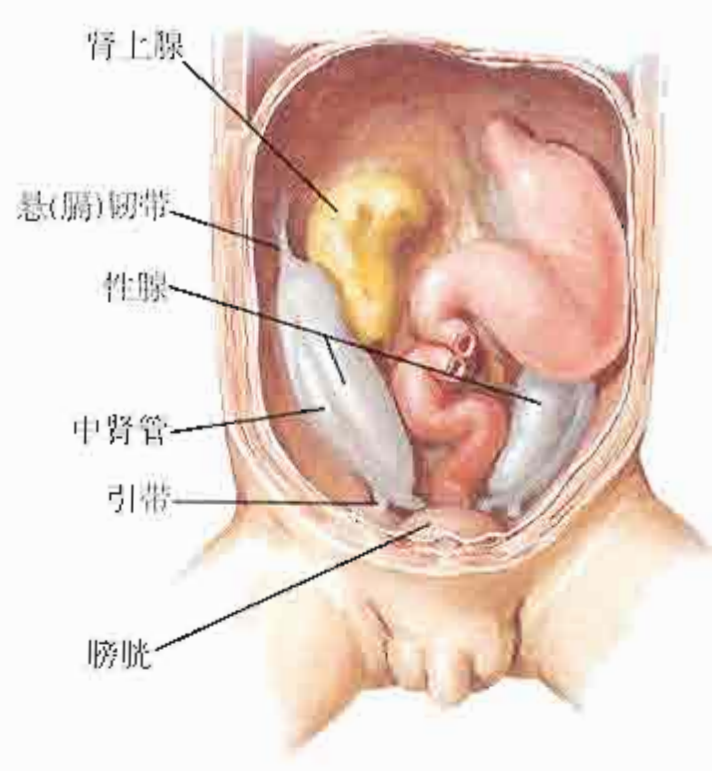
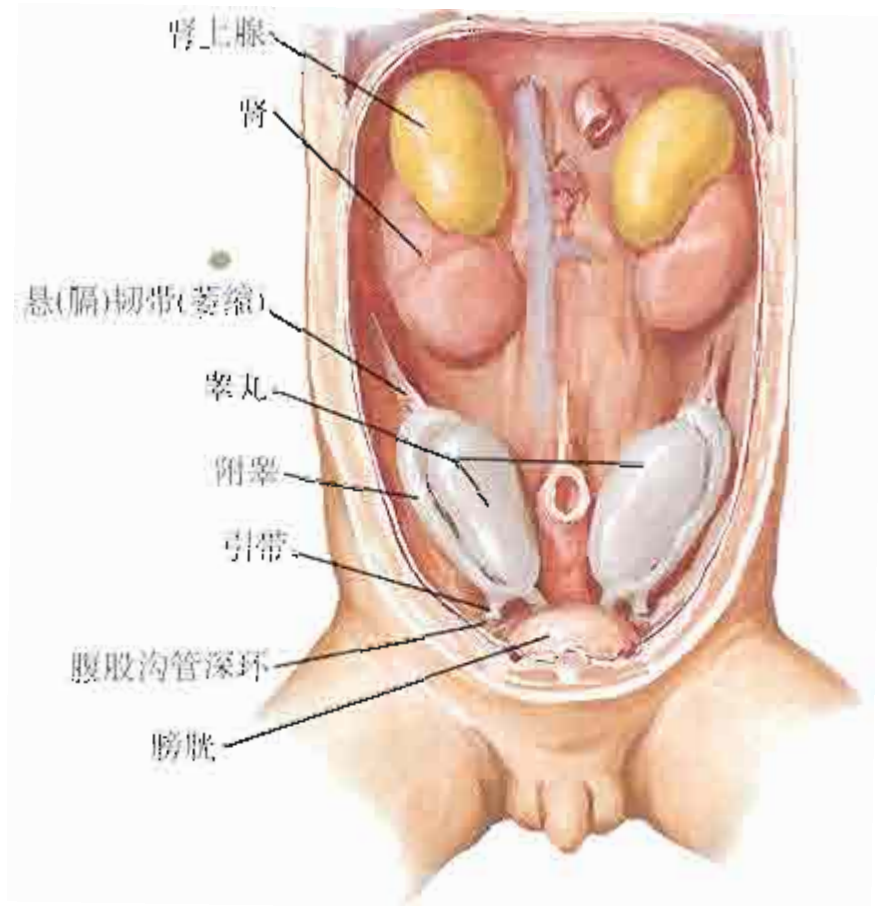


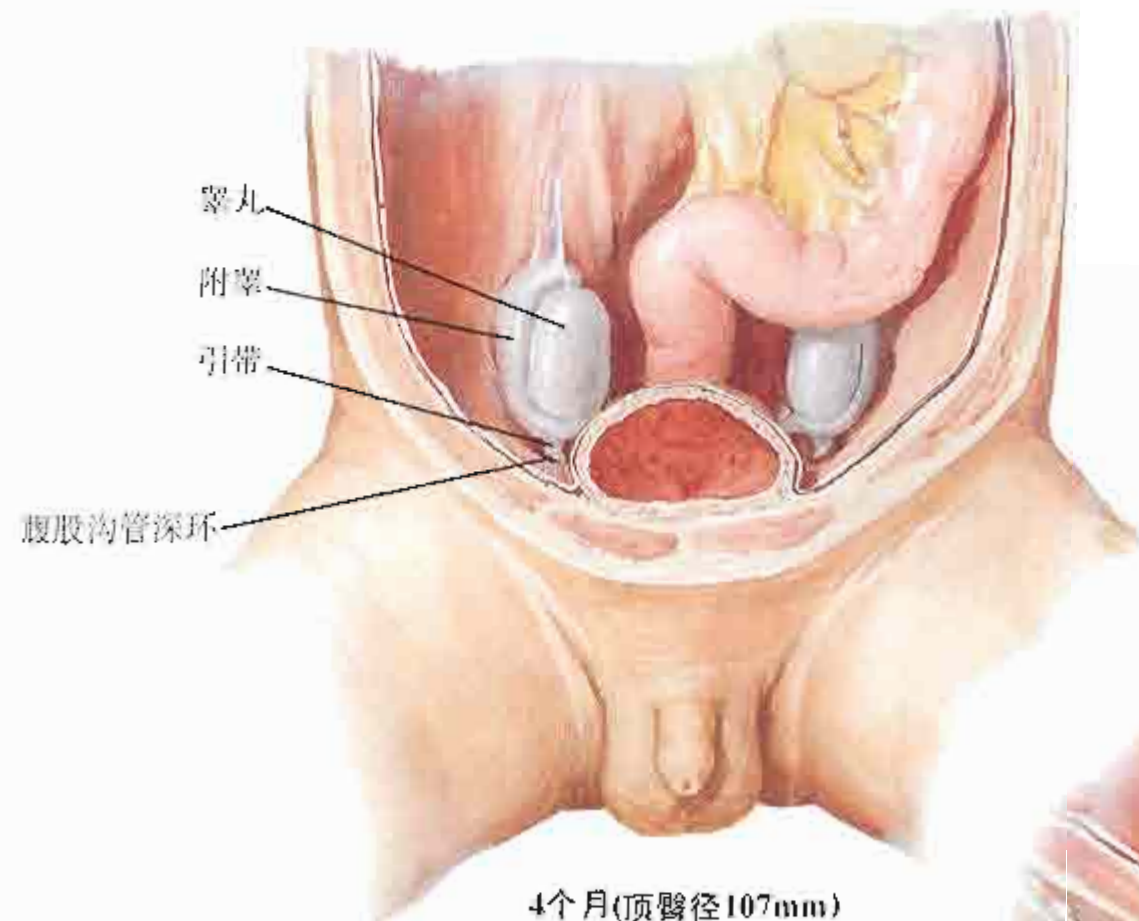
图368



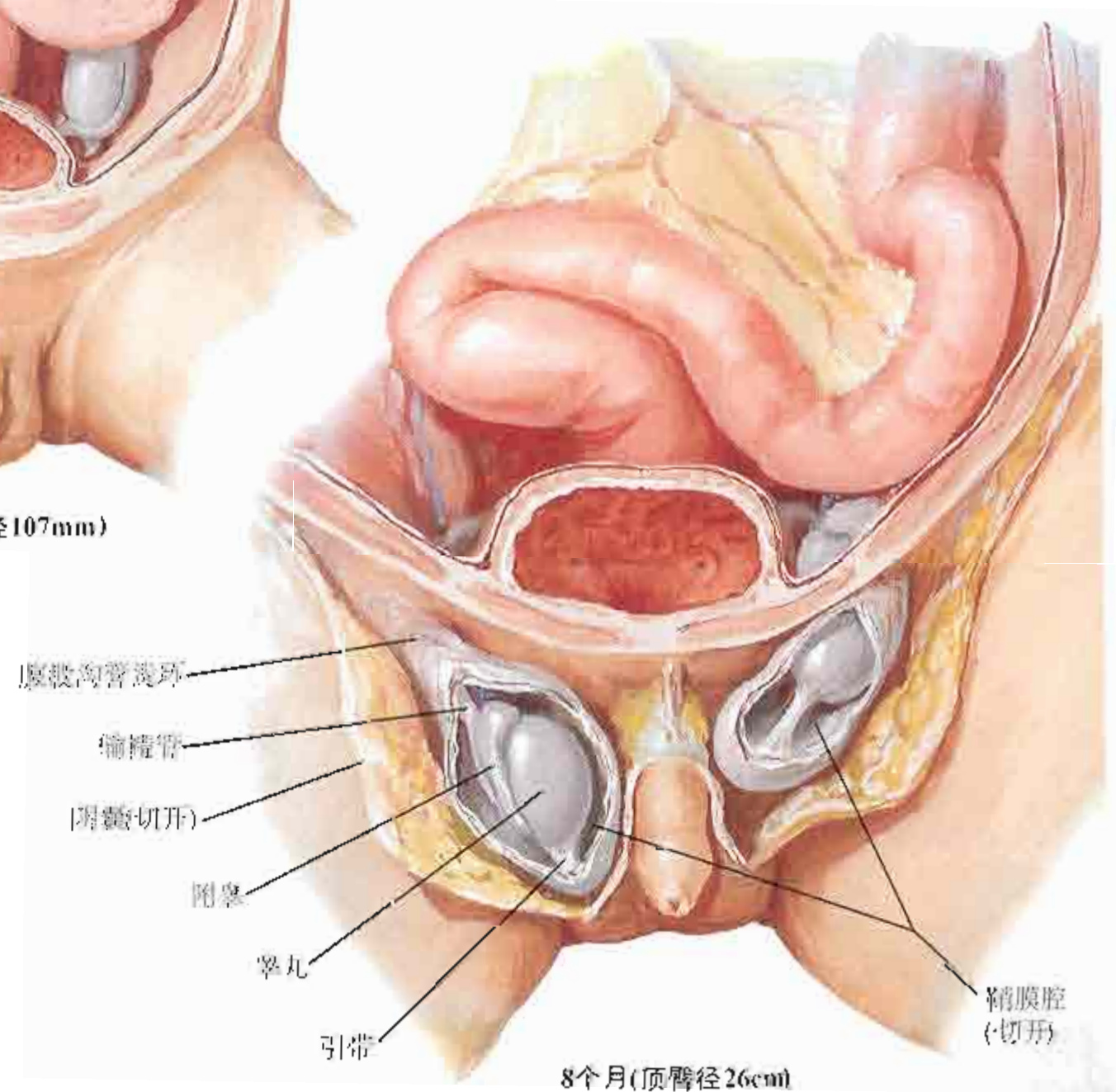
8周(顶臀径22.5mm)



11周(顶臀径43mm)

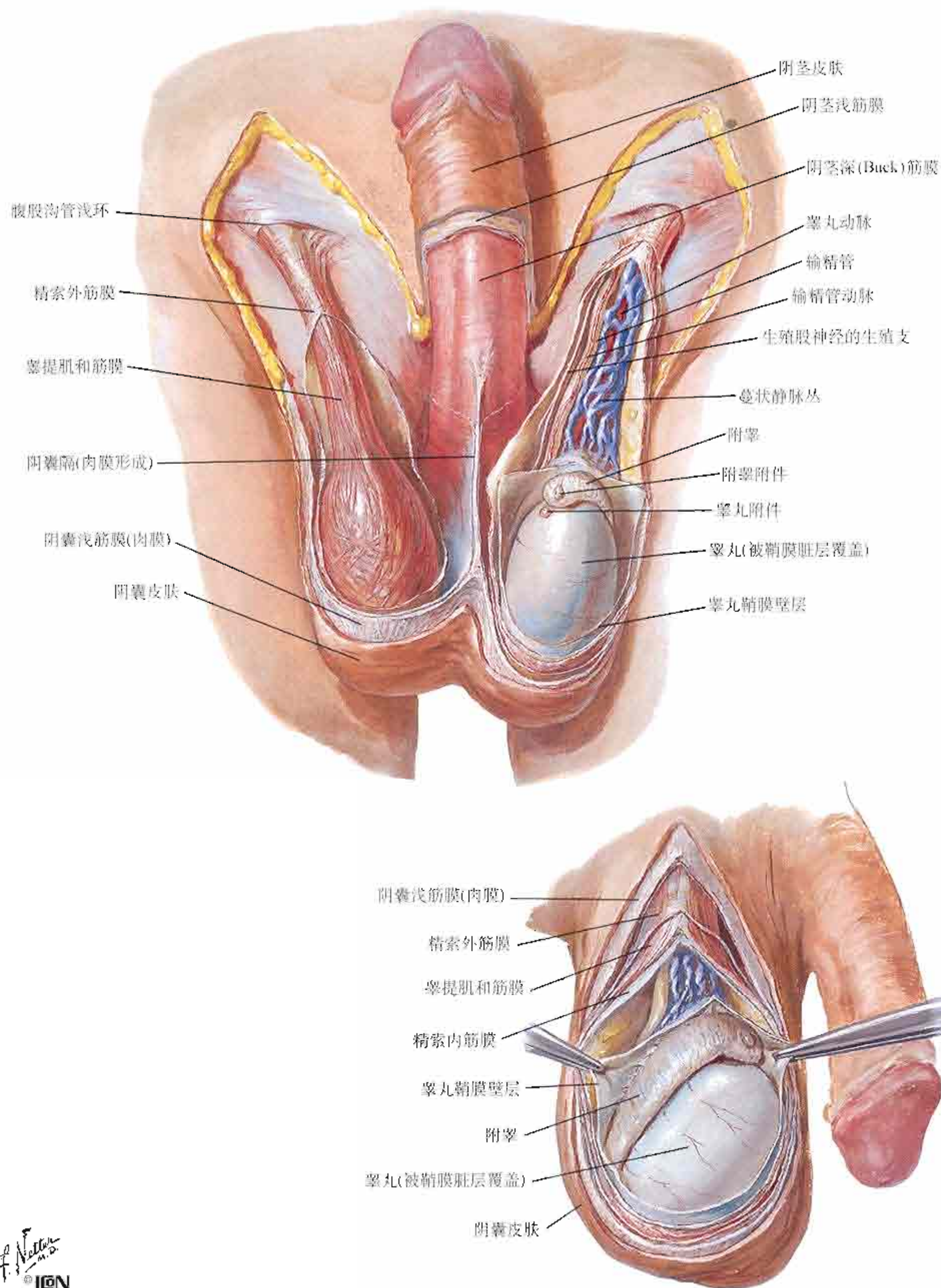


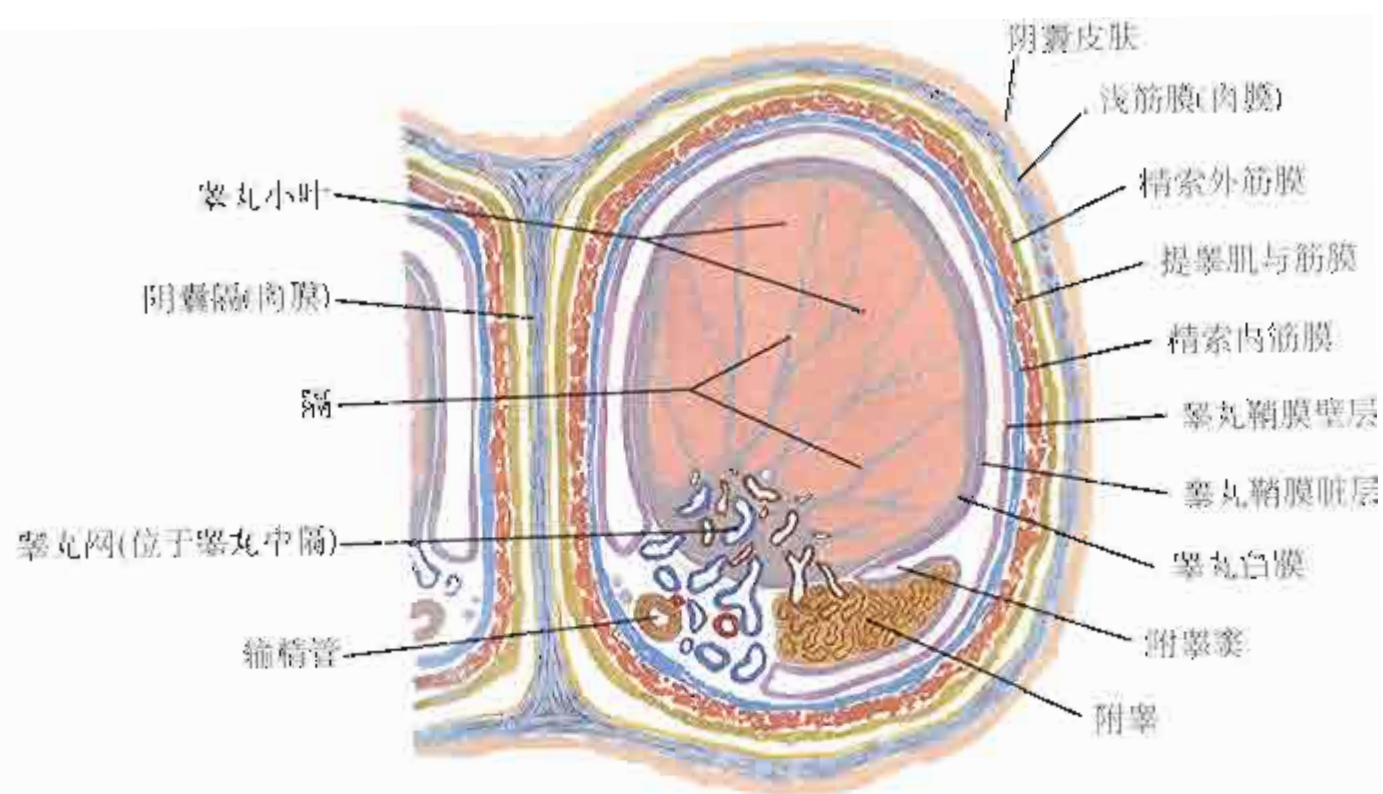
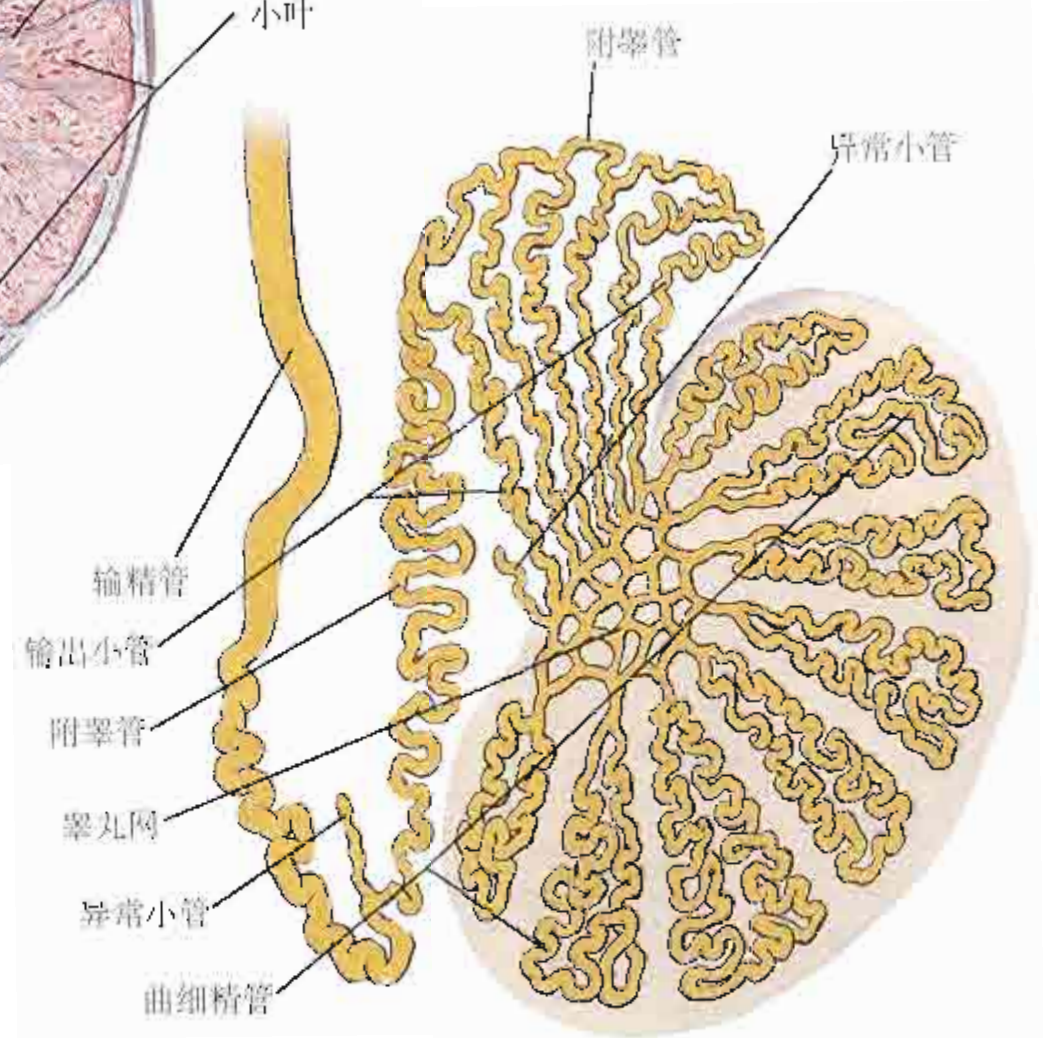
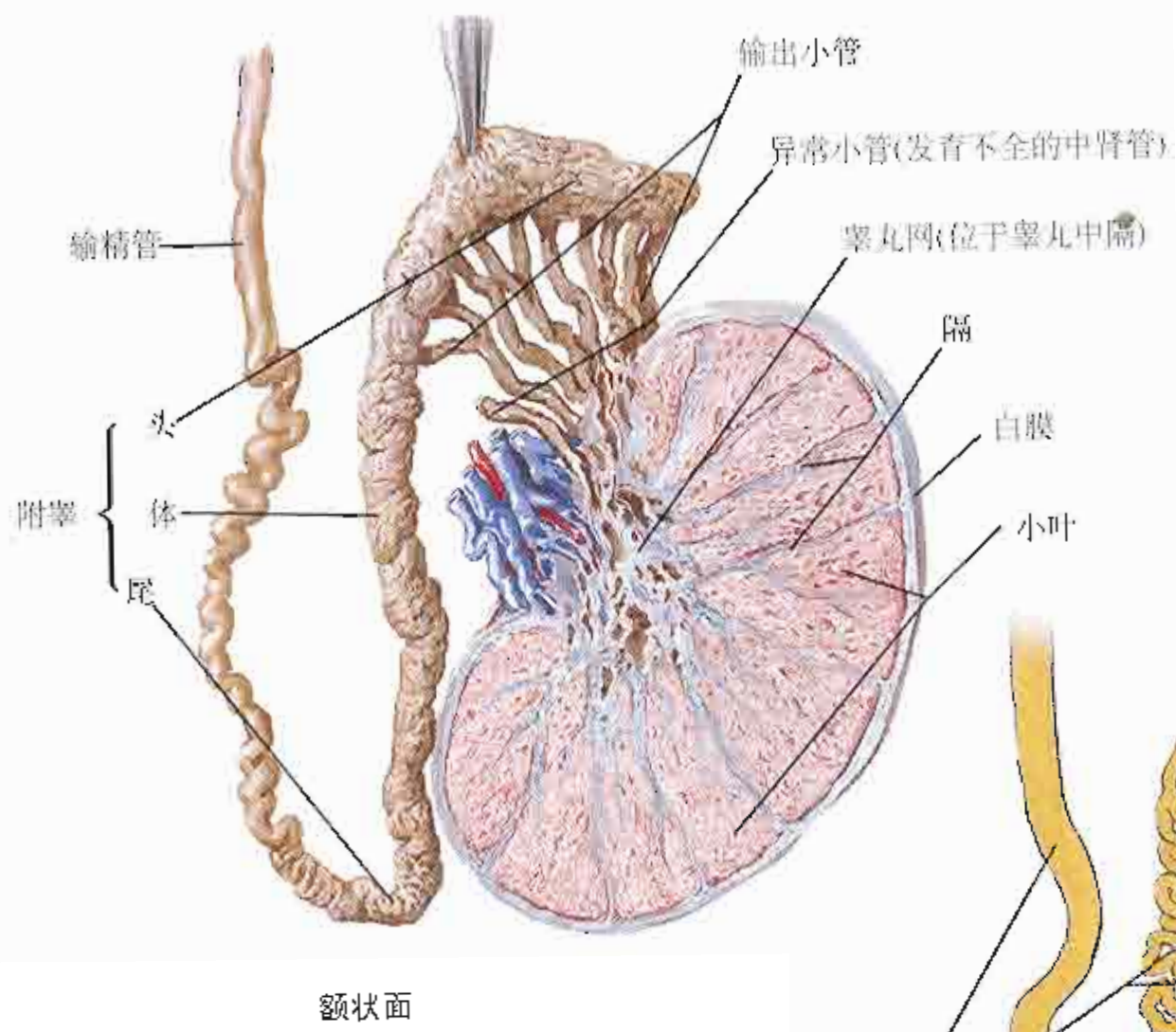
4个月(顶臀径107mm)



8个月(顶臀径26cm)

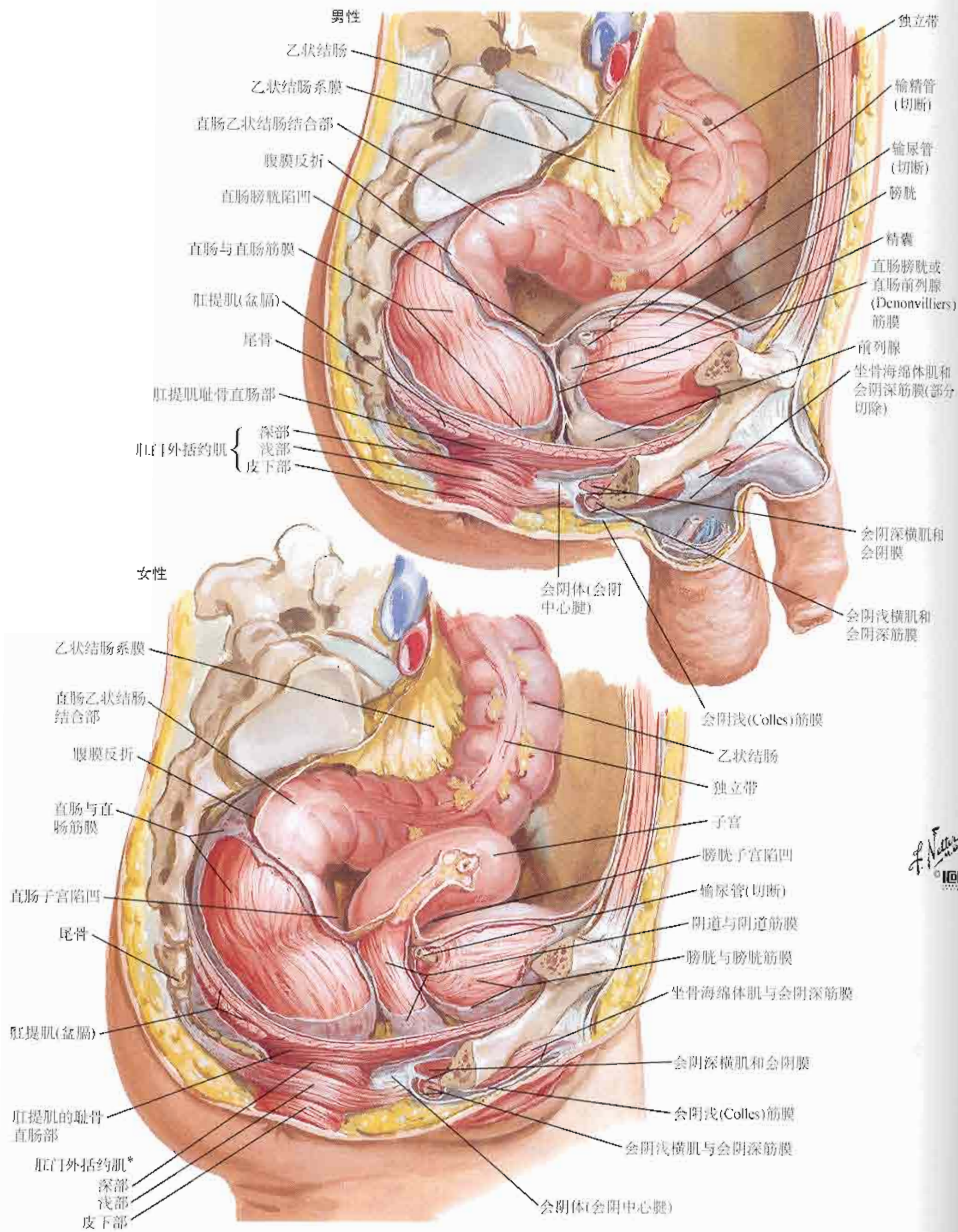
F. Netter
M.D.
© 1996
IGN





经阴囊和睾丸的横断面

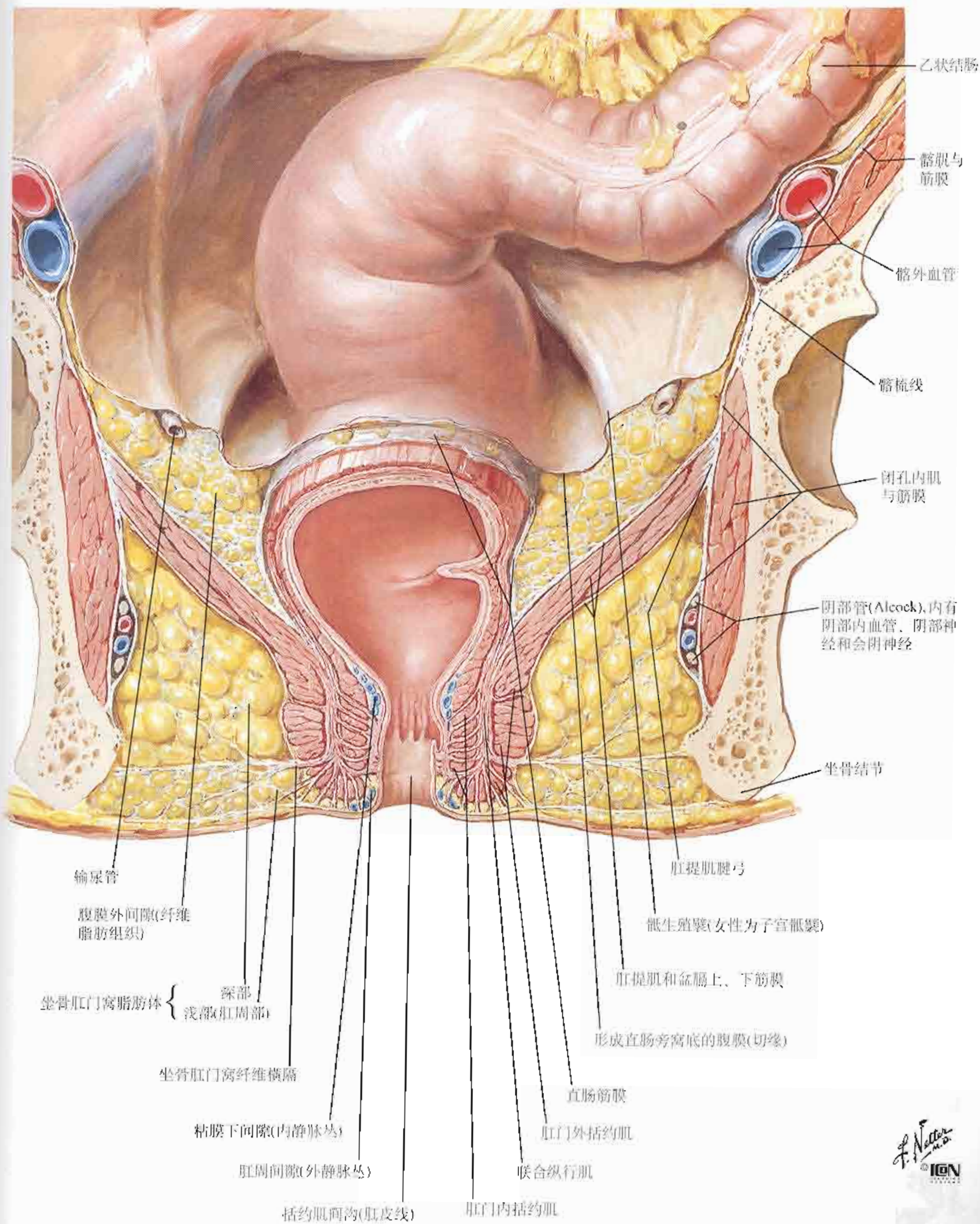
直肠(原位): 女性和男性



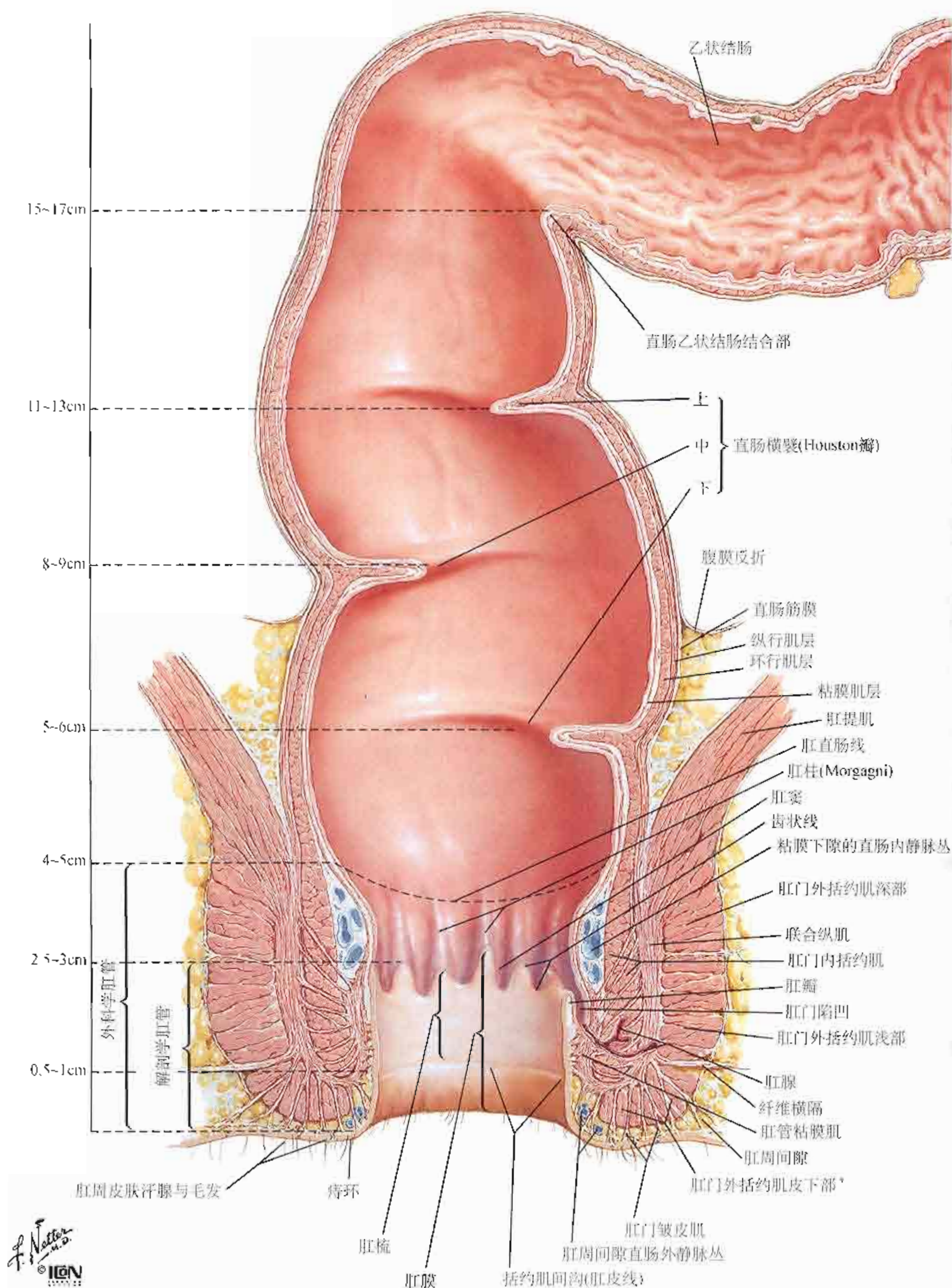
*分部可有变异

图372

盆和会阴

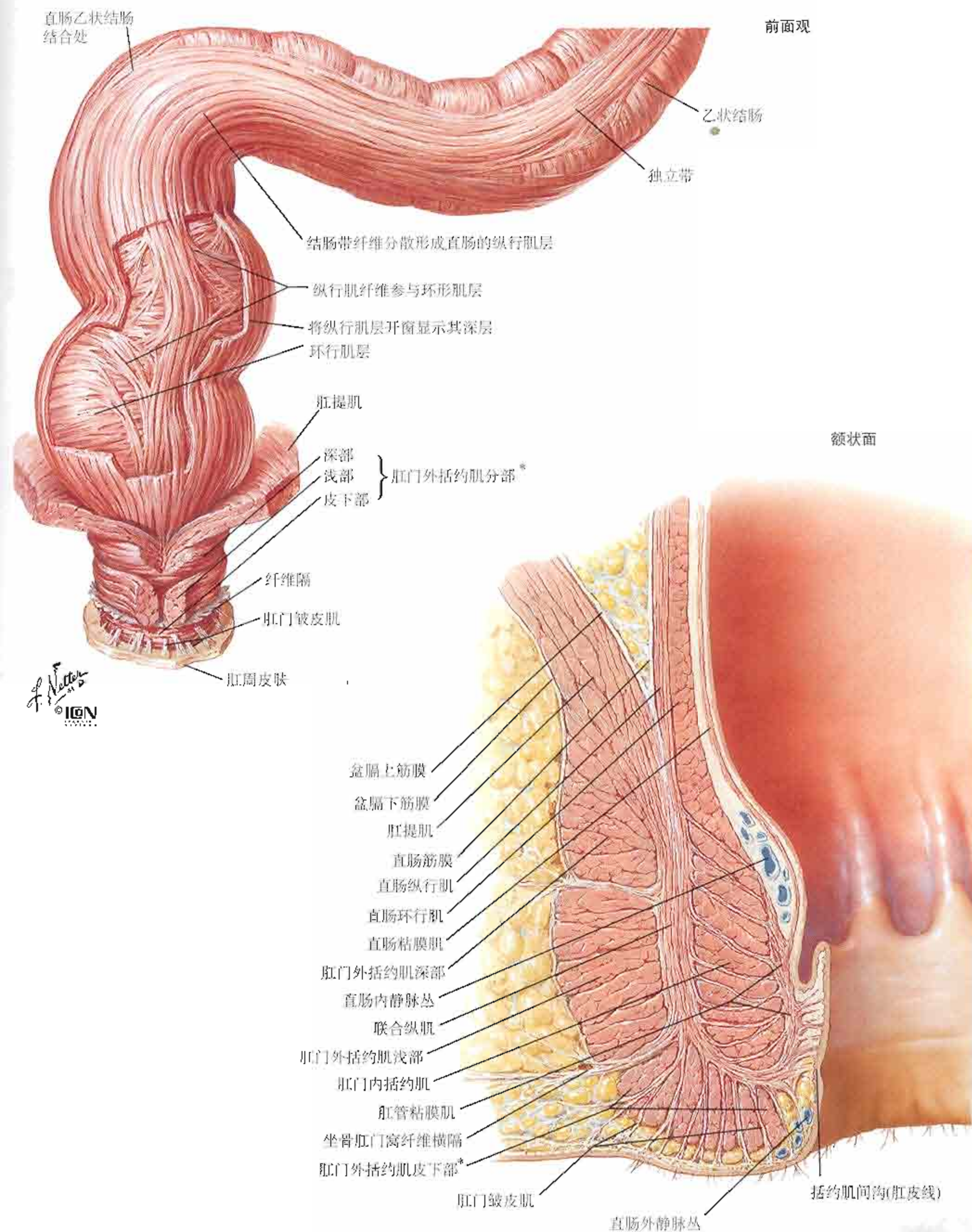


F. Netter M.D.
© IGCN



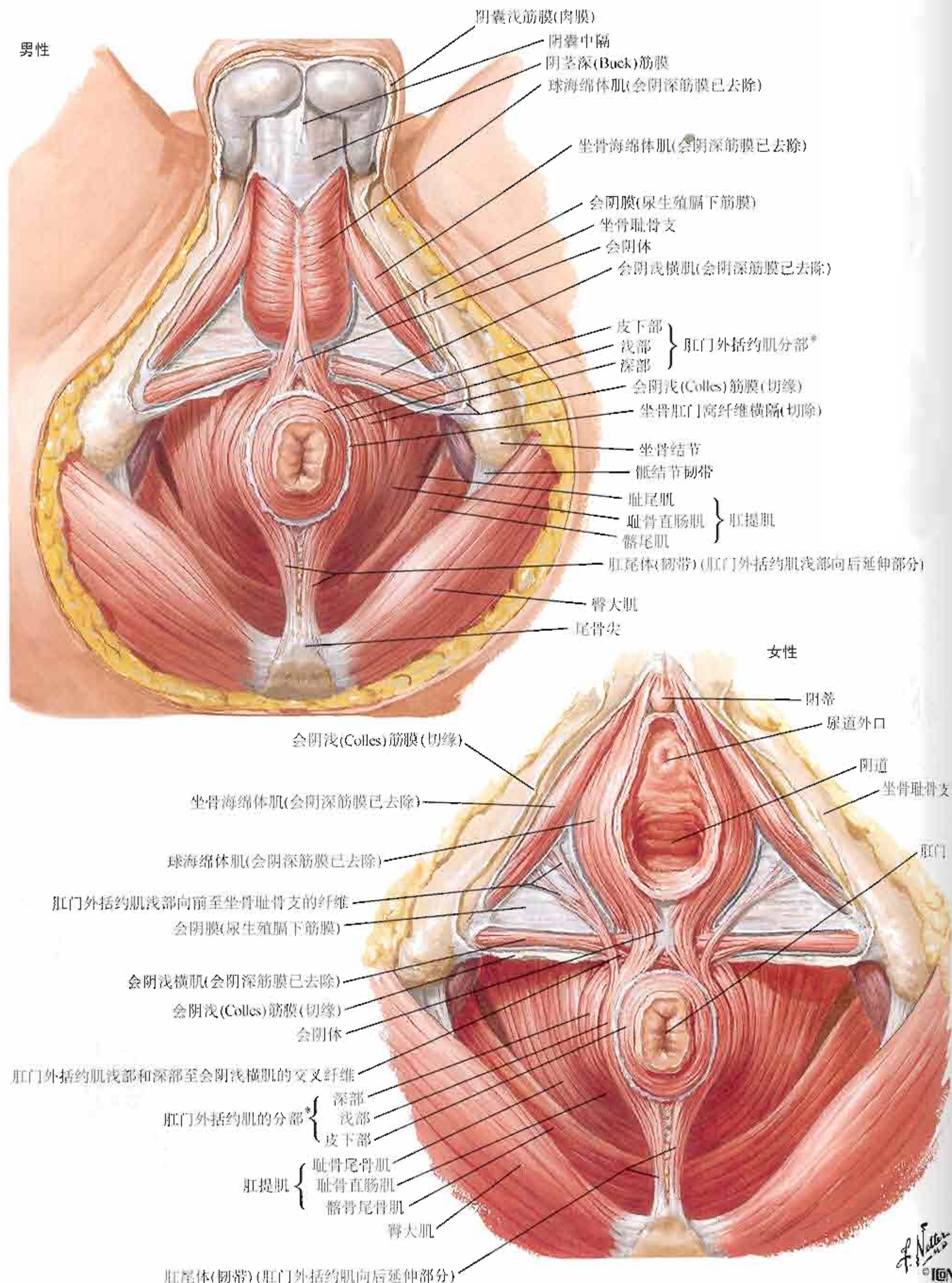
*分部可有变异

图374



*分部可有变异

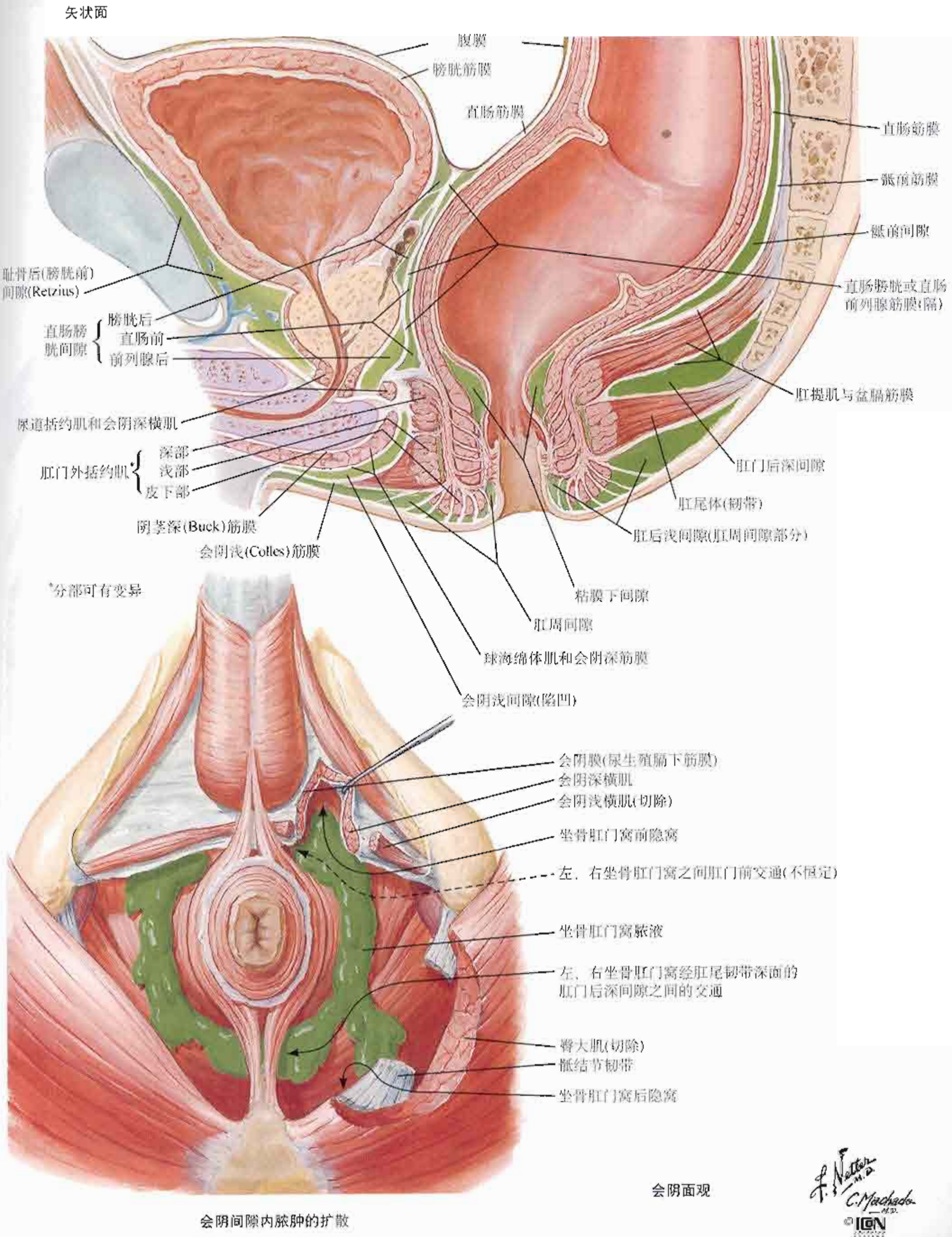
肛门外括约肌：会阴面观



*分部可有变异

图376

盆和会阴





运动科学网站



运动科学网站



运动科学网站



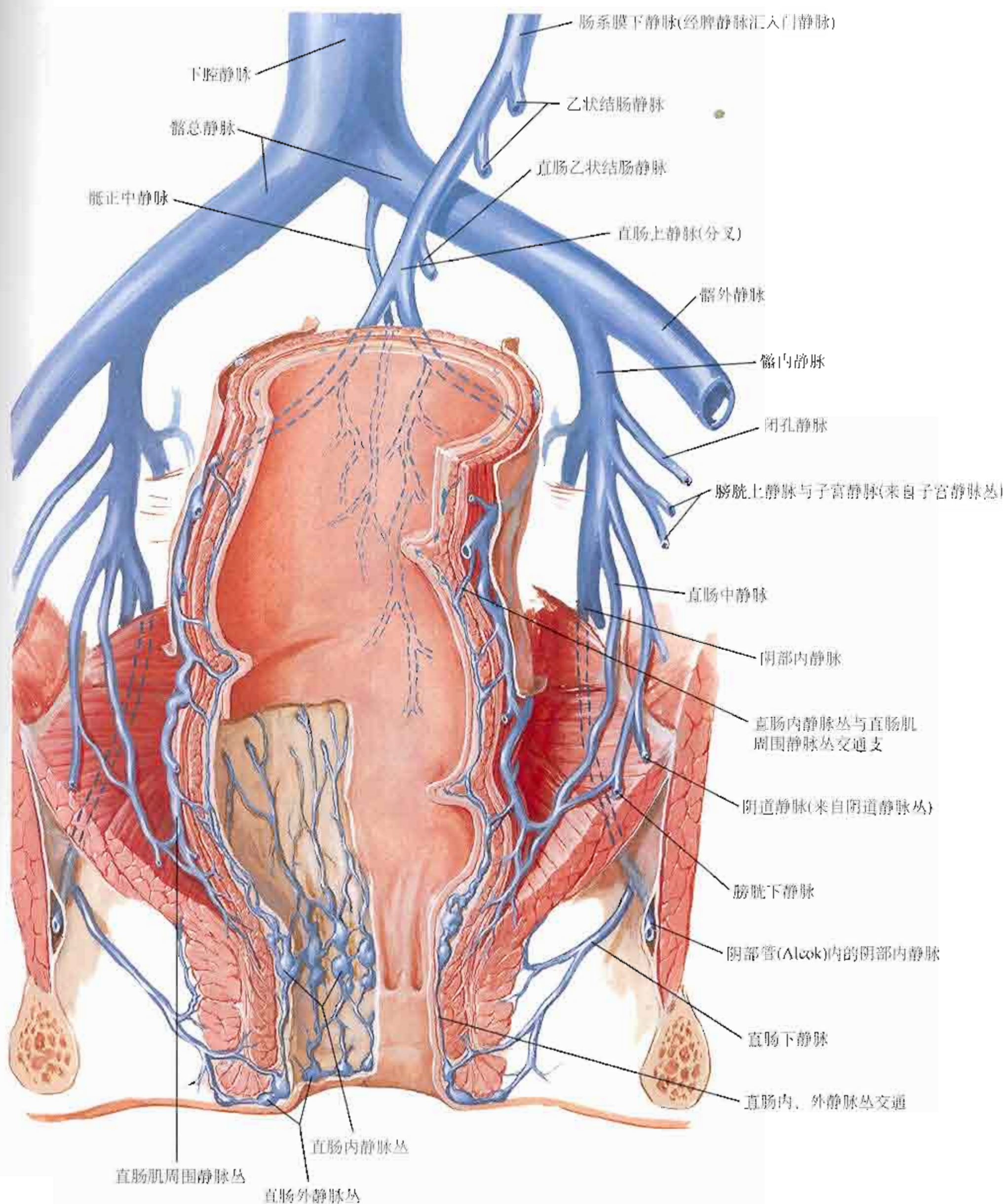
运动科学网站



运动科学网站

www.vo2maxcn.com

前面观



F. Netter M.D.
© IGM

盆腔脏器的动脉和静脉：女性

前面观

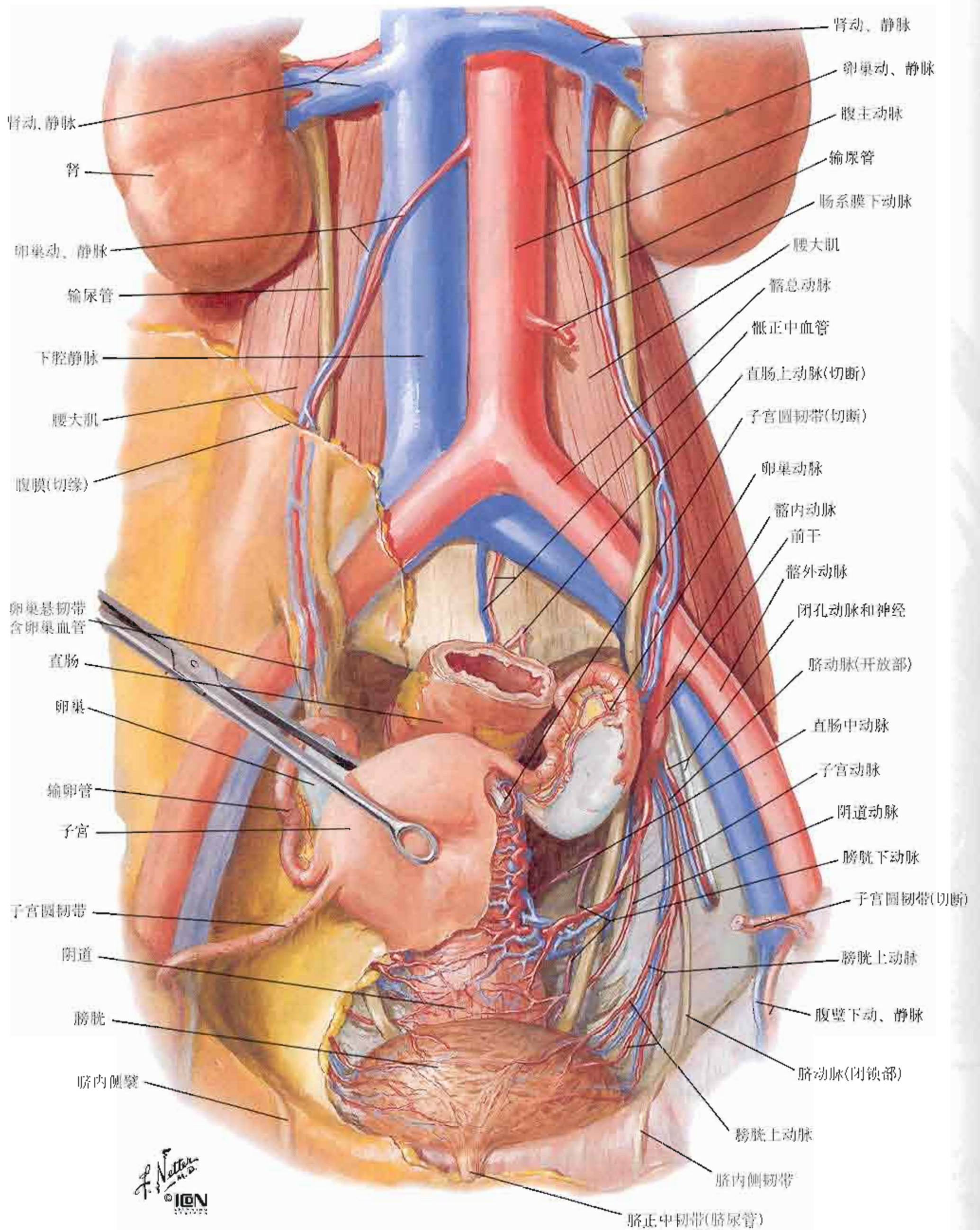
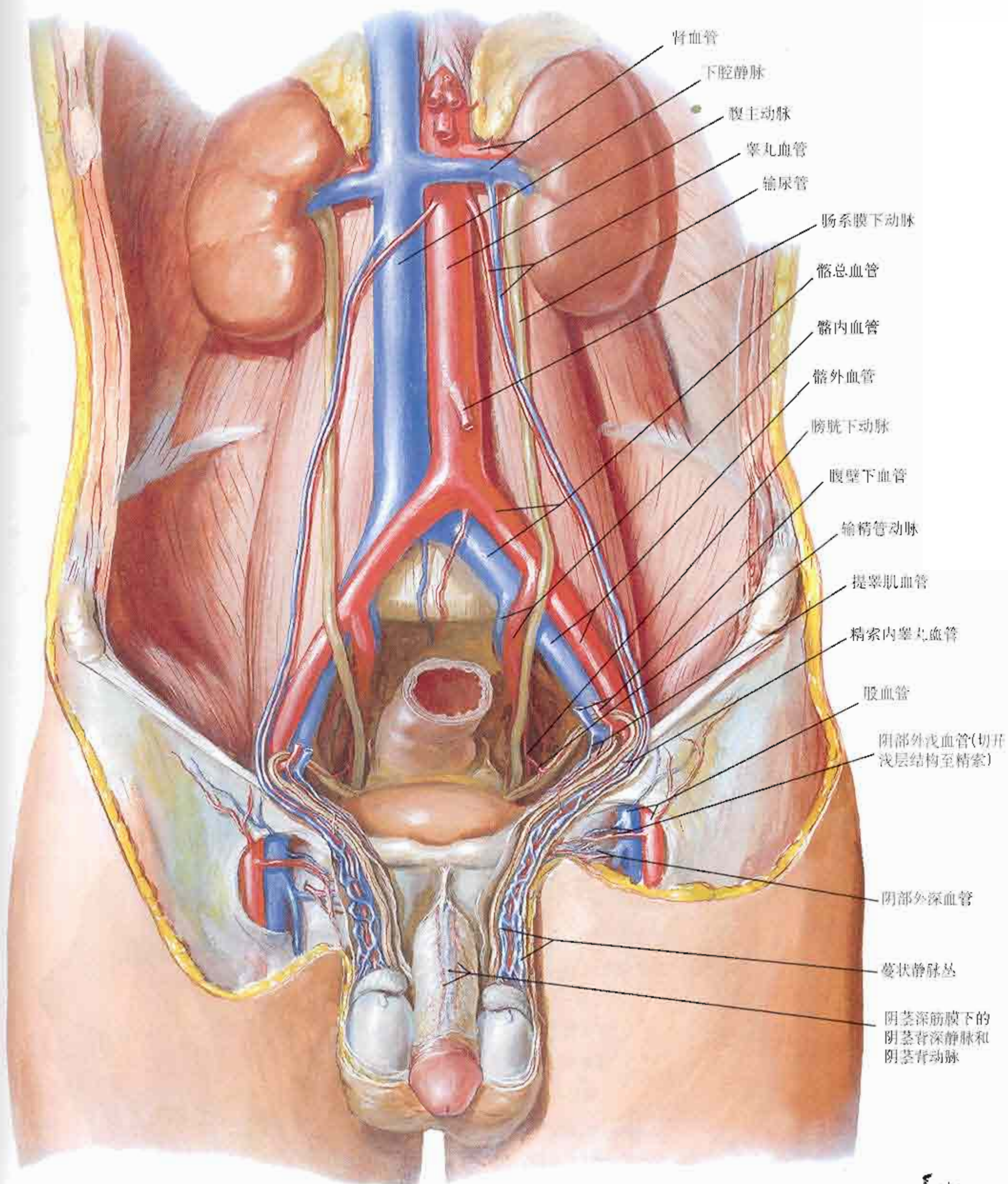


图380

盆和会阴

前面观



F. Netter M.D.
© IGM
1997

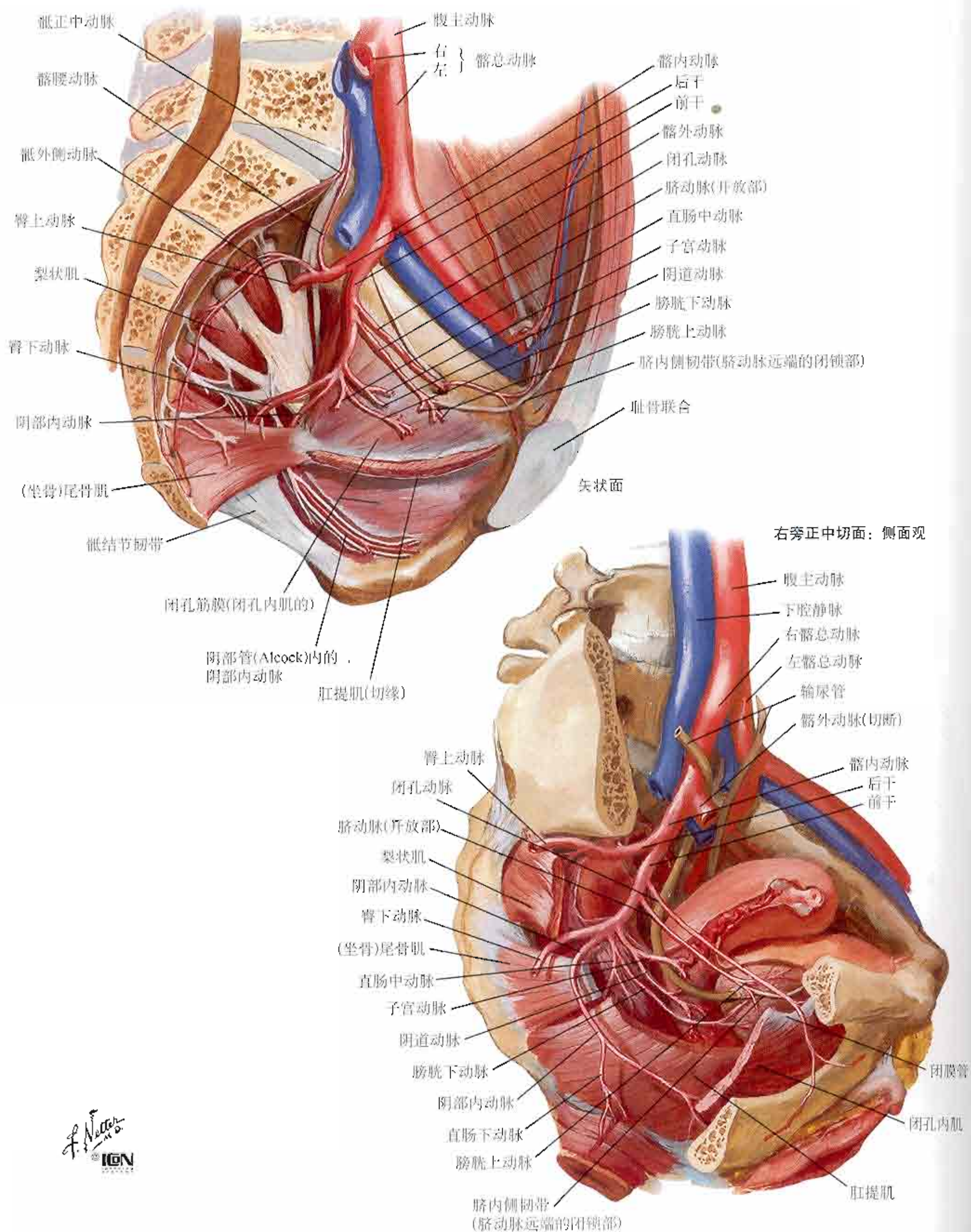
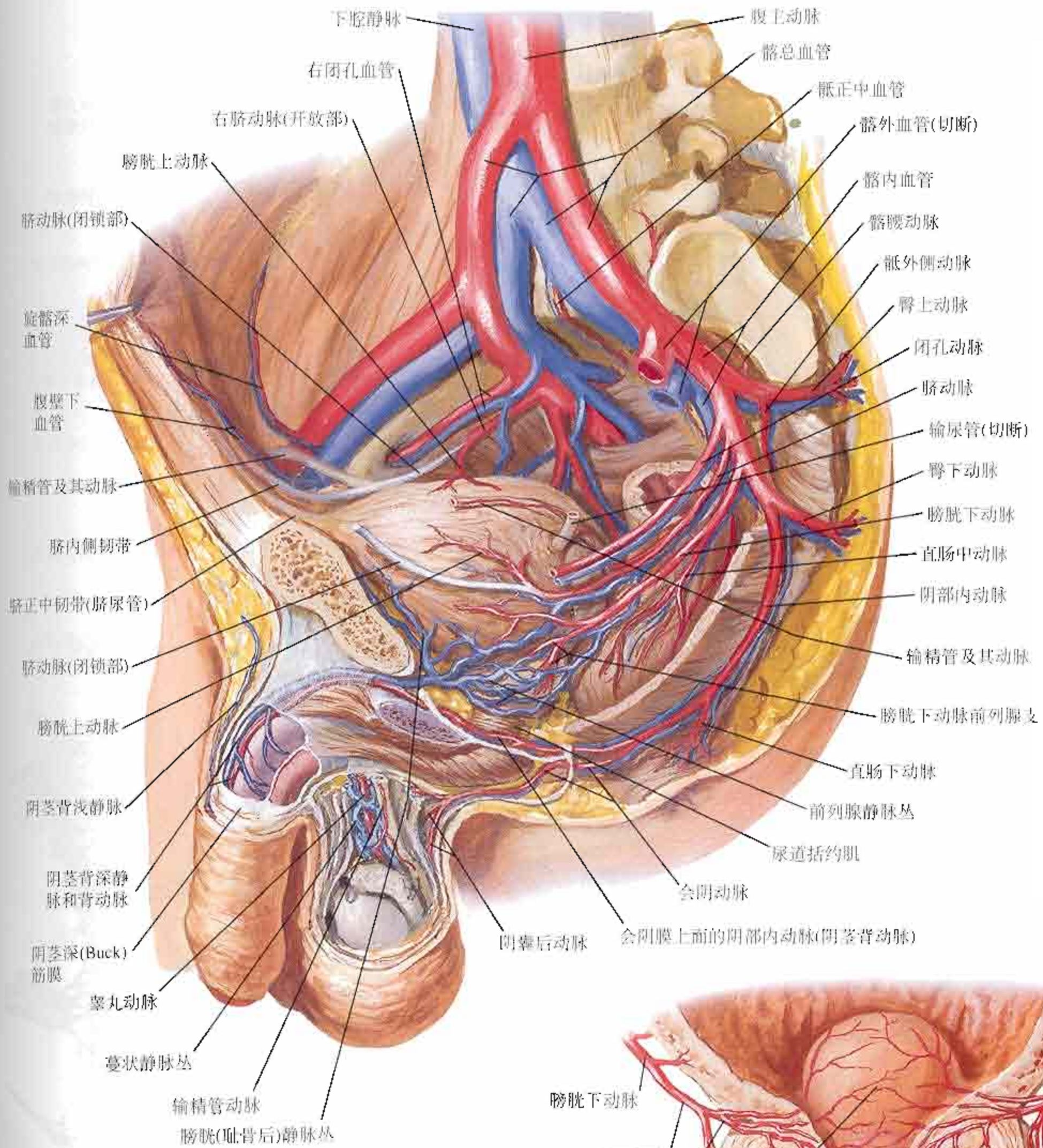
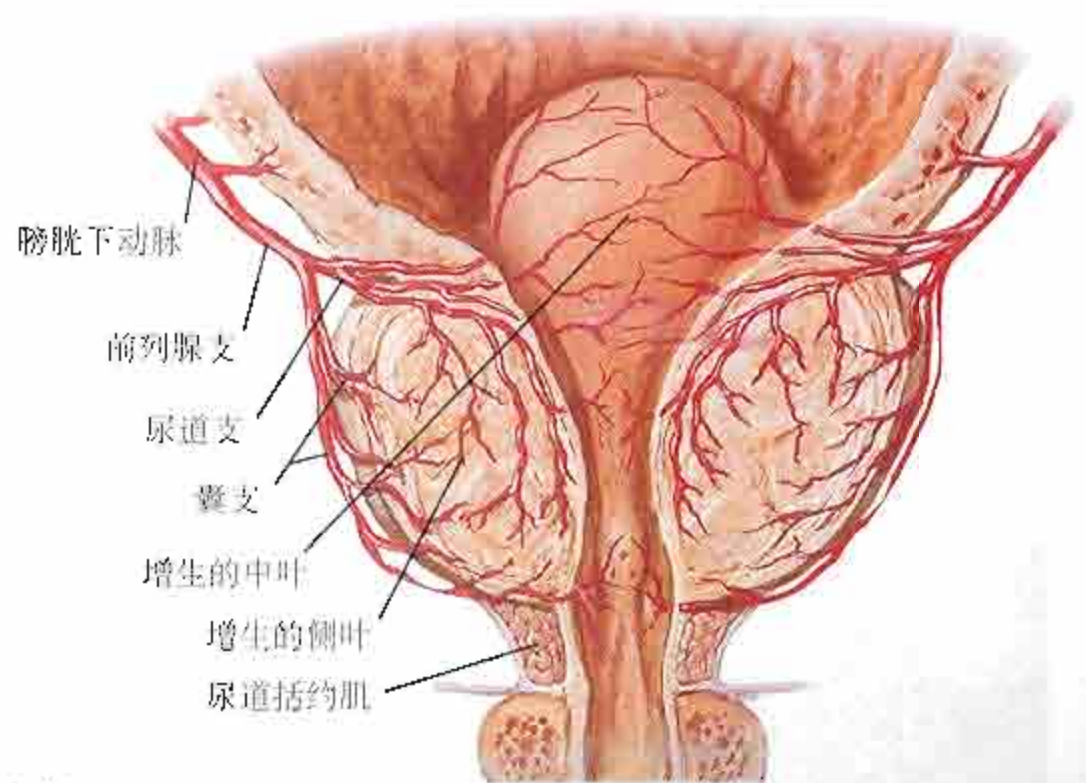


图382

左旁正中切面：侧面观



F. Netter M.D.
C. Machado M.D.
© IGM



前列腺动脉供应
(额状面：良性前列腺增生的前面观)

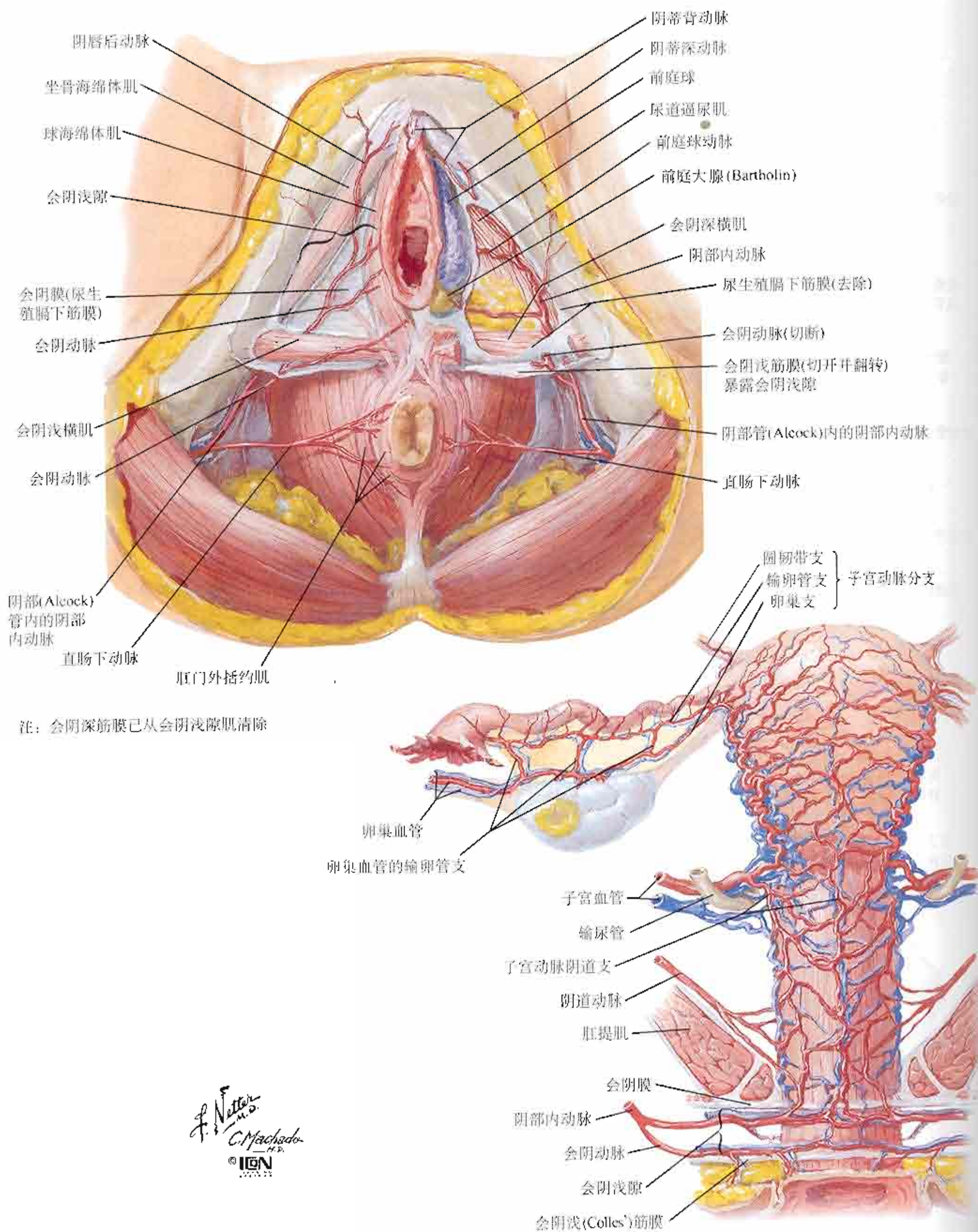
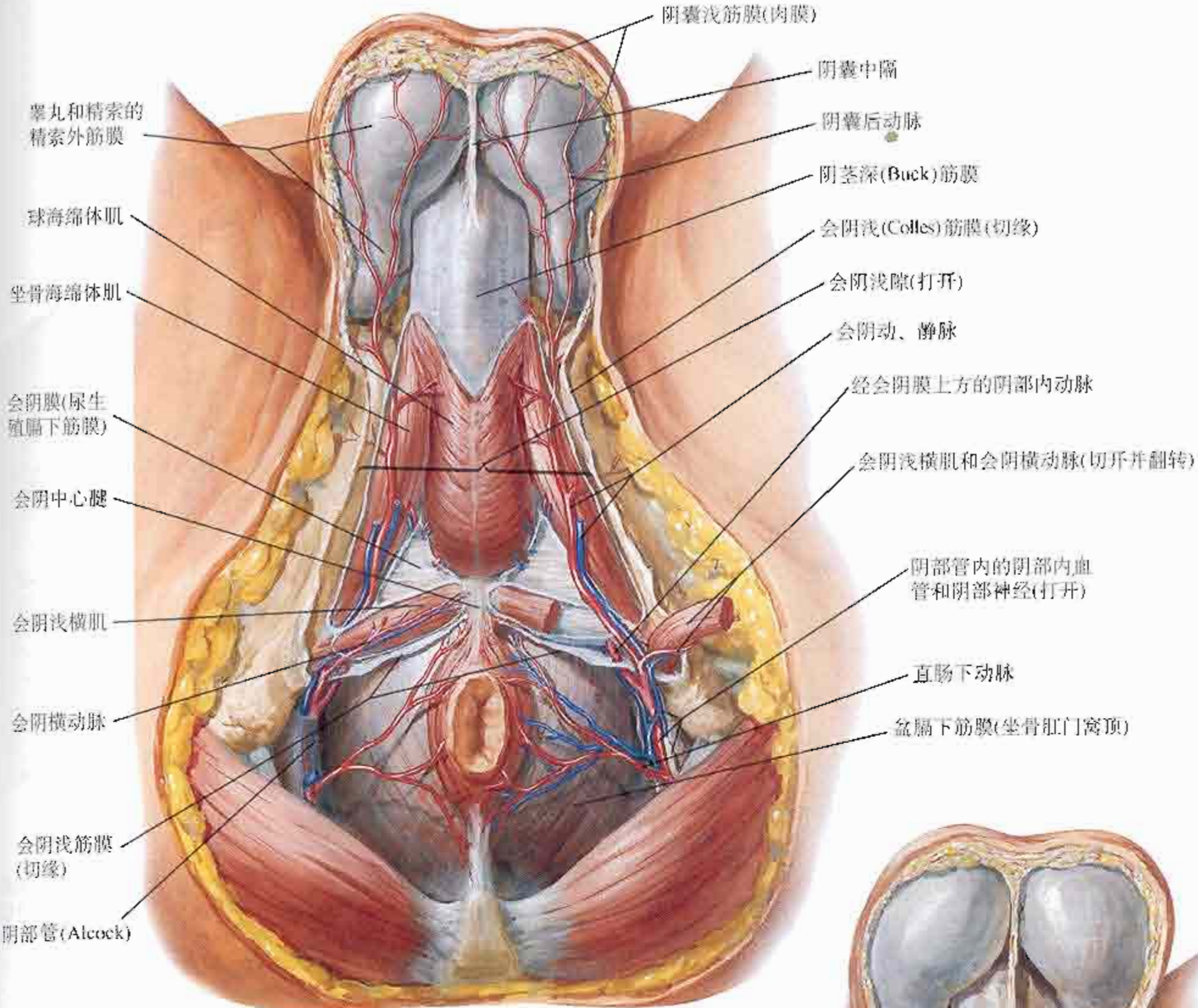
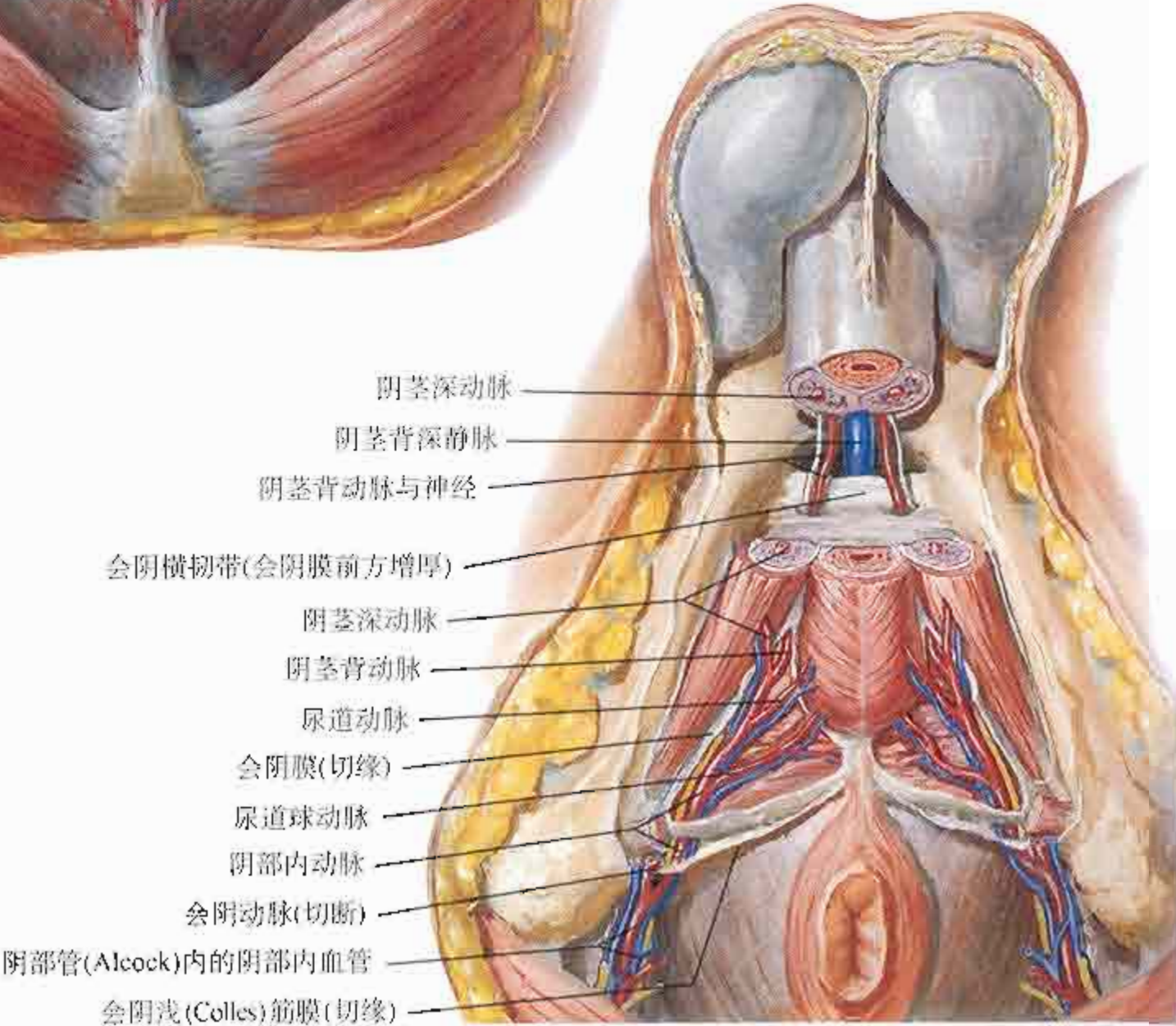


图384



注：会阴深筋膜已从会阴浅隙肌清除



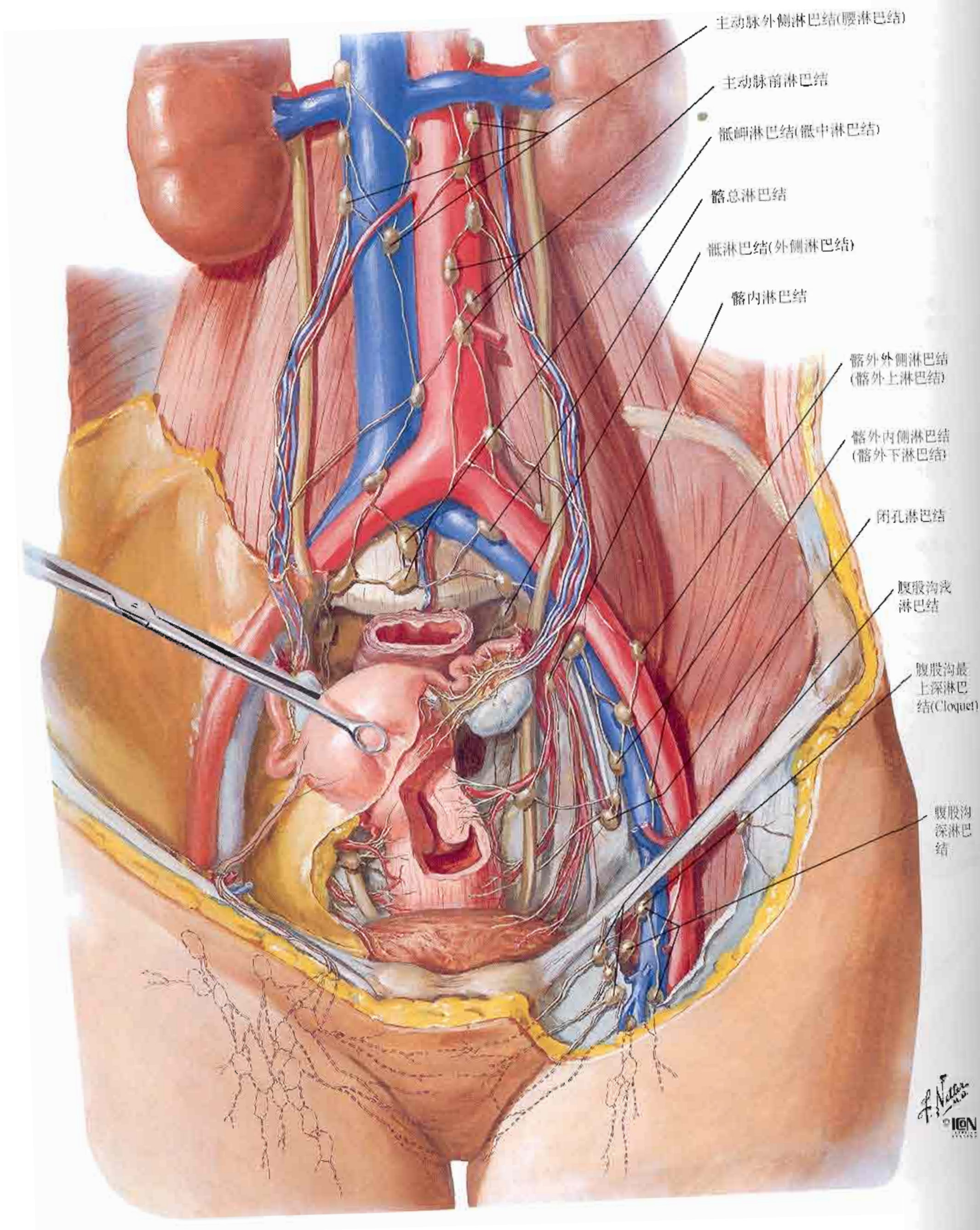
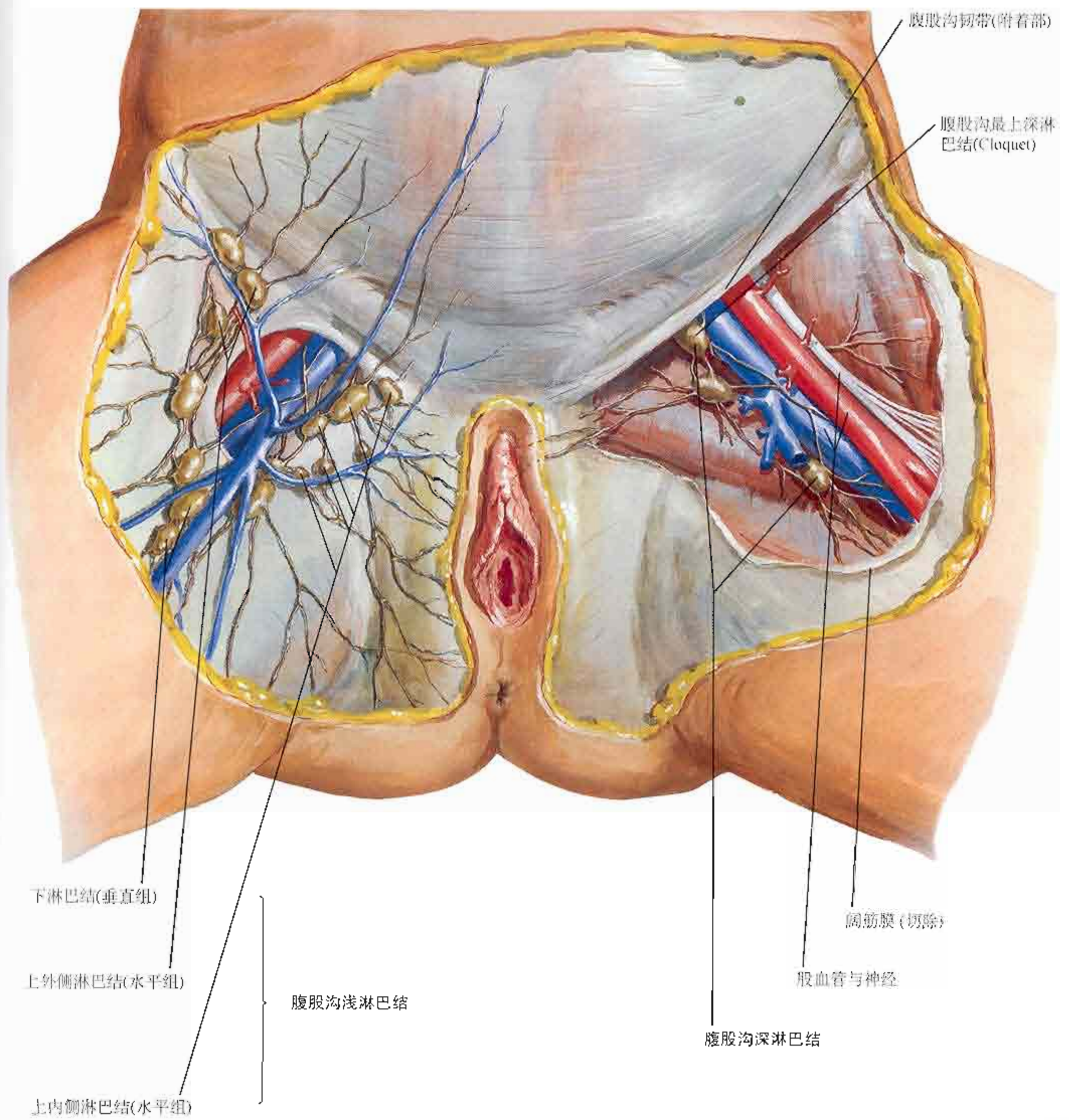
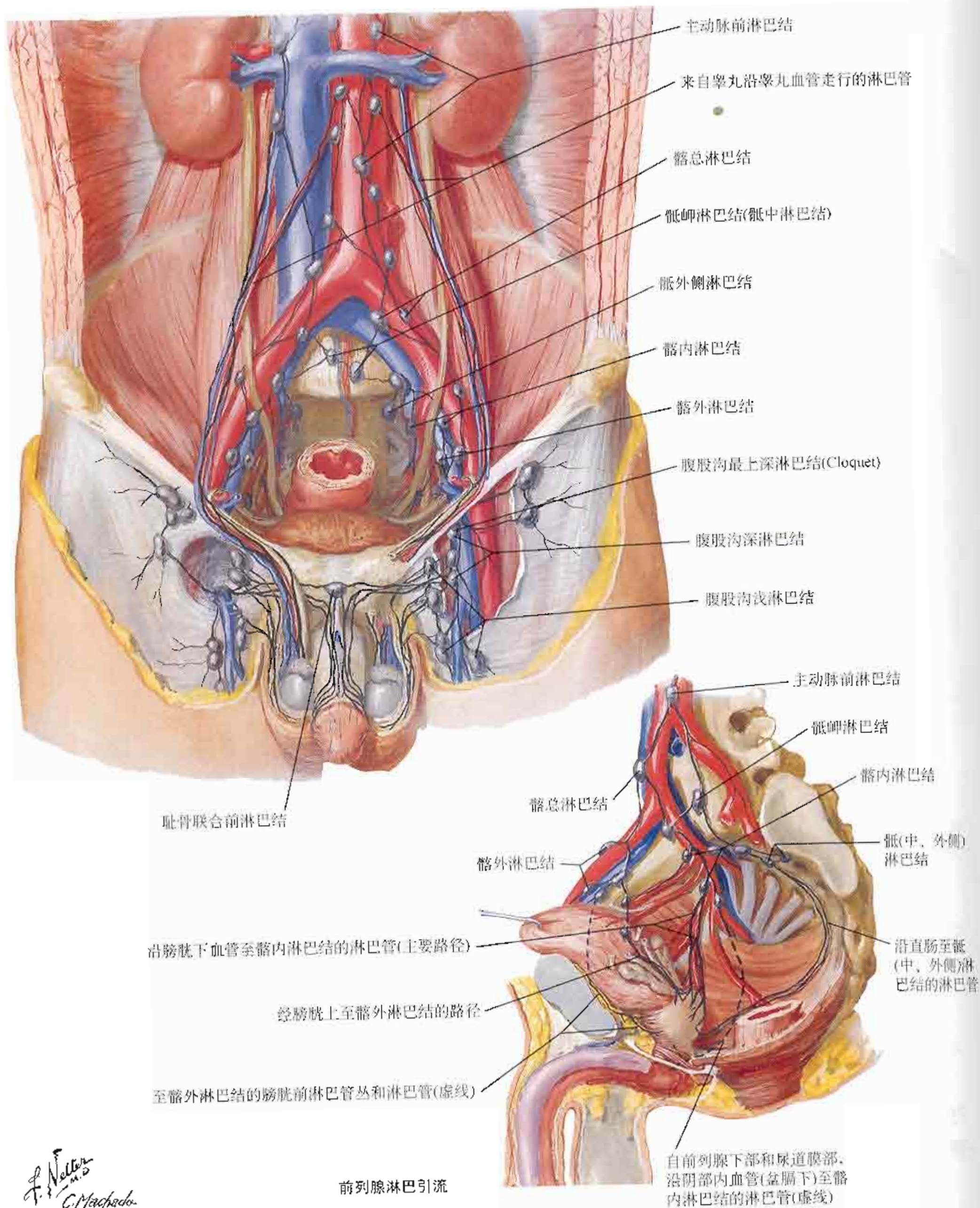


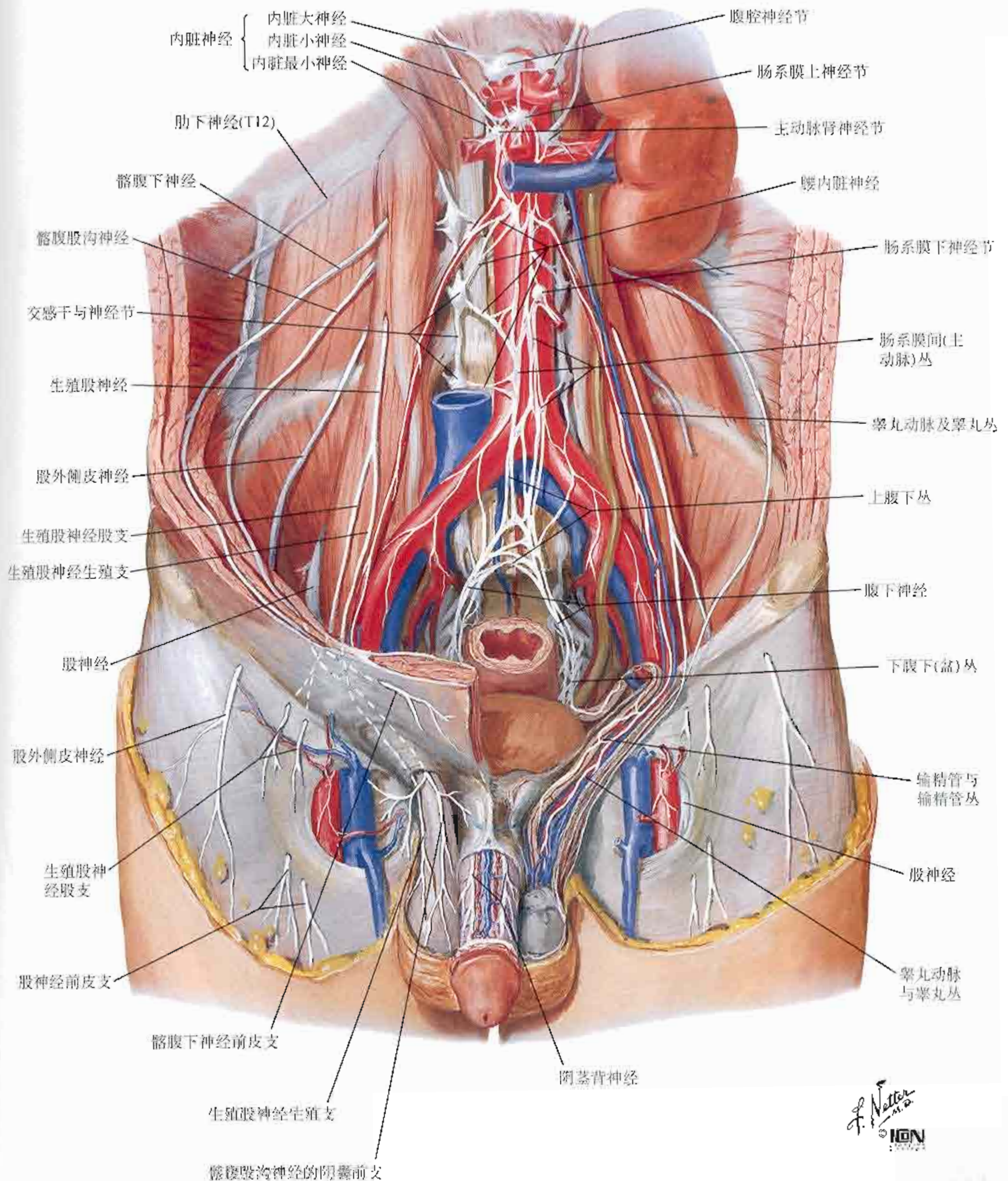
图386





F. Netter M.D.
C. Machado M.D.
© ION

图388



F. Netter M.D.
ION

盆腔脏器的神经：男性

参见图 159、308

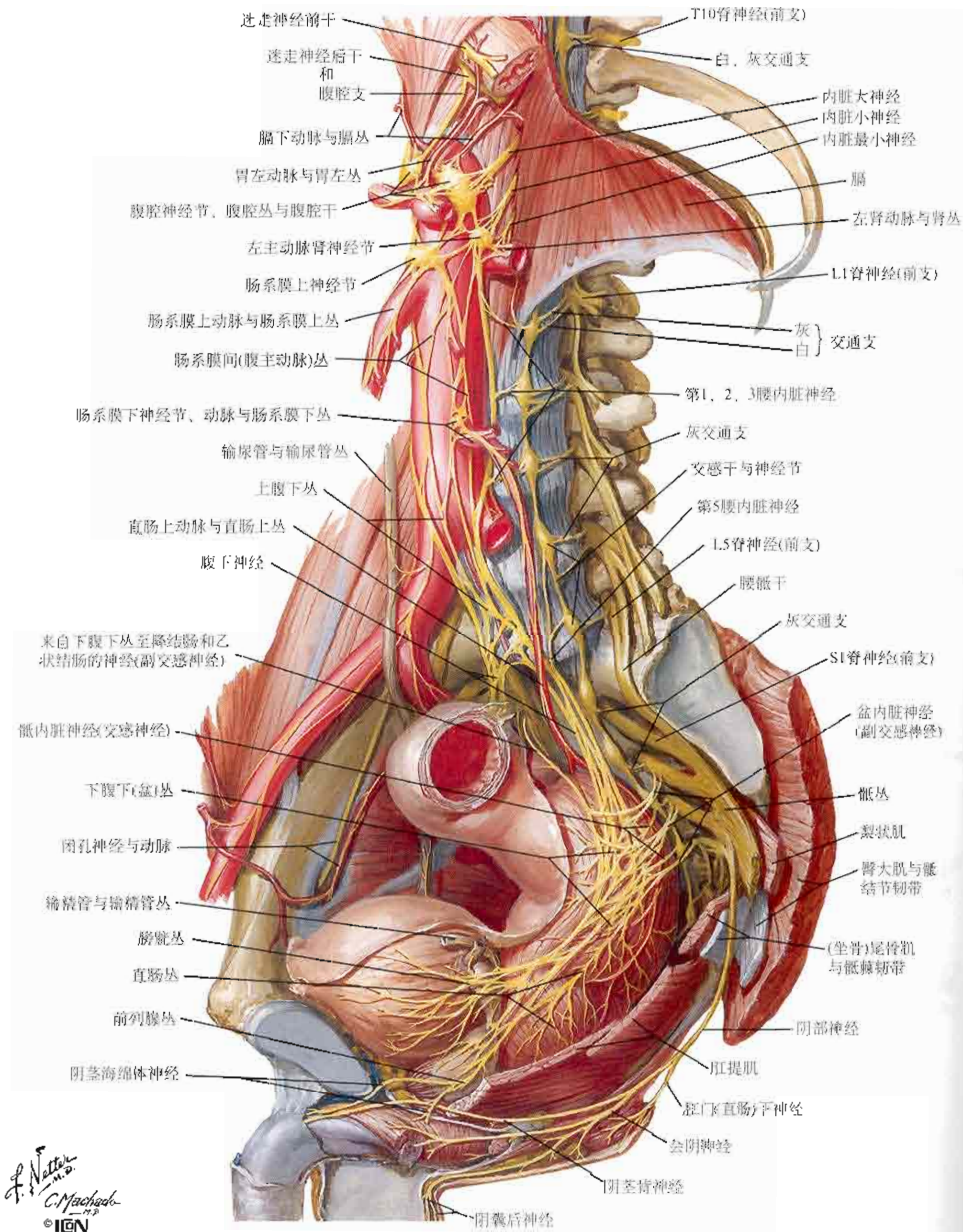
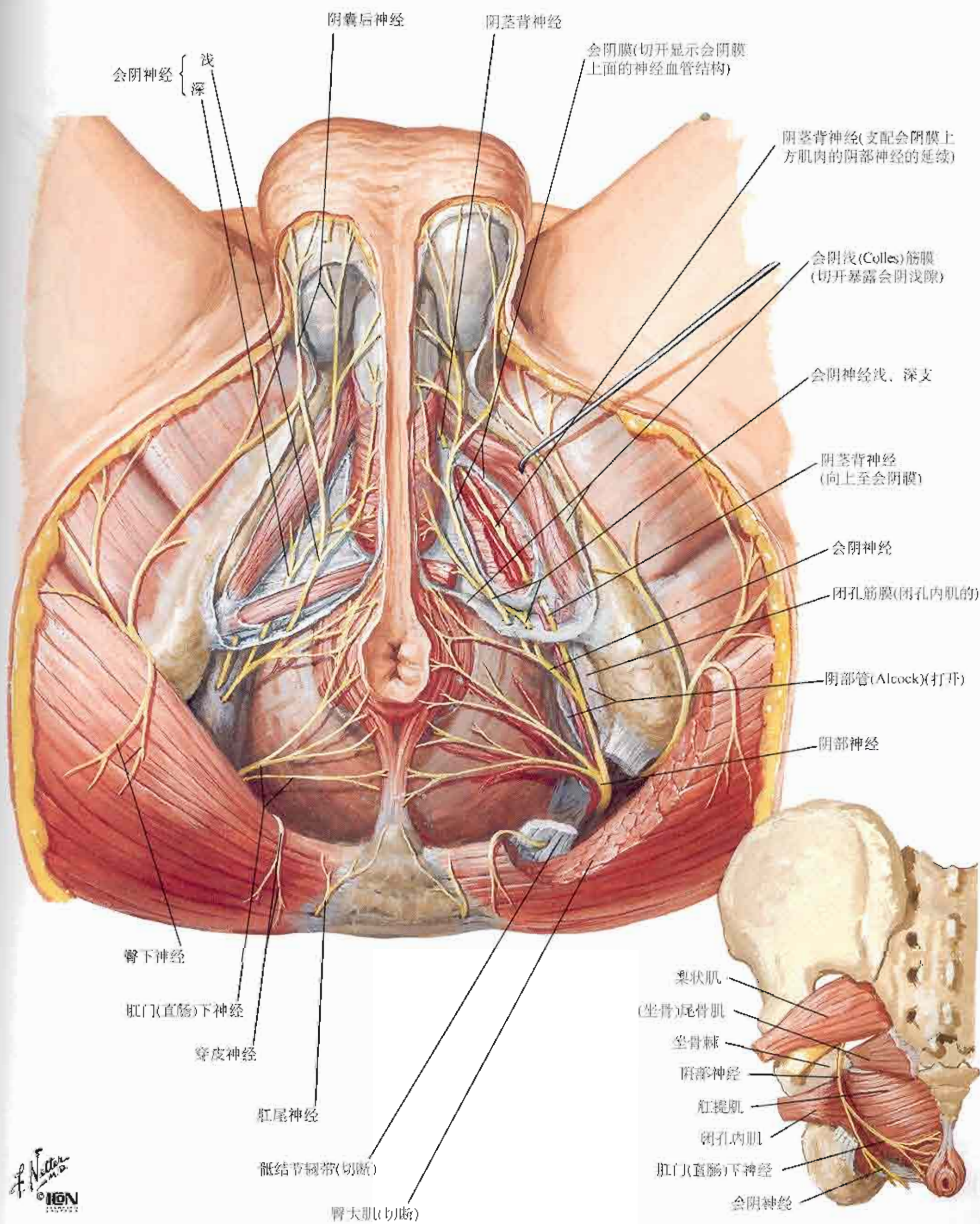


图390

盆和会阴



盆腔脏器的神经：女性

参见图 159、308

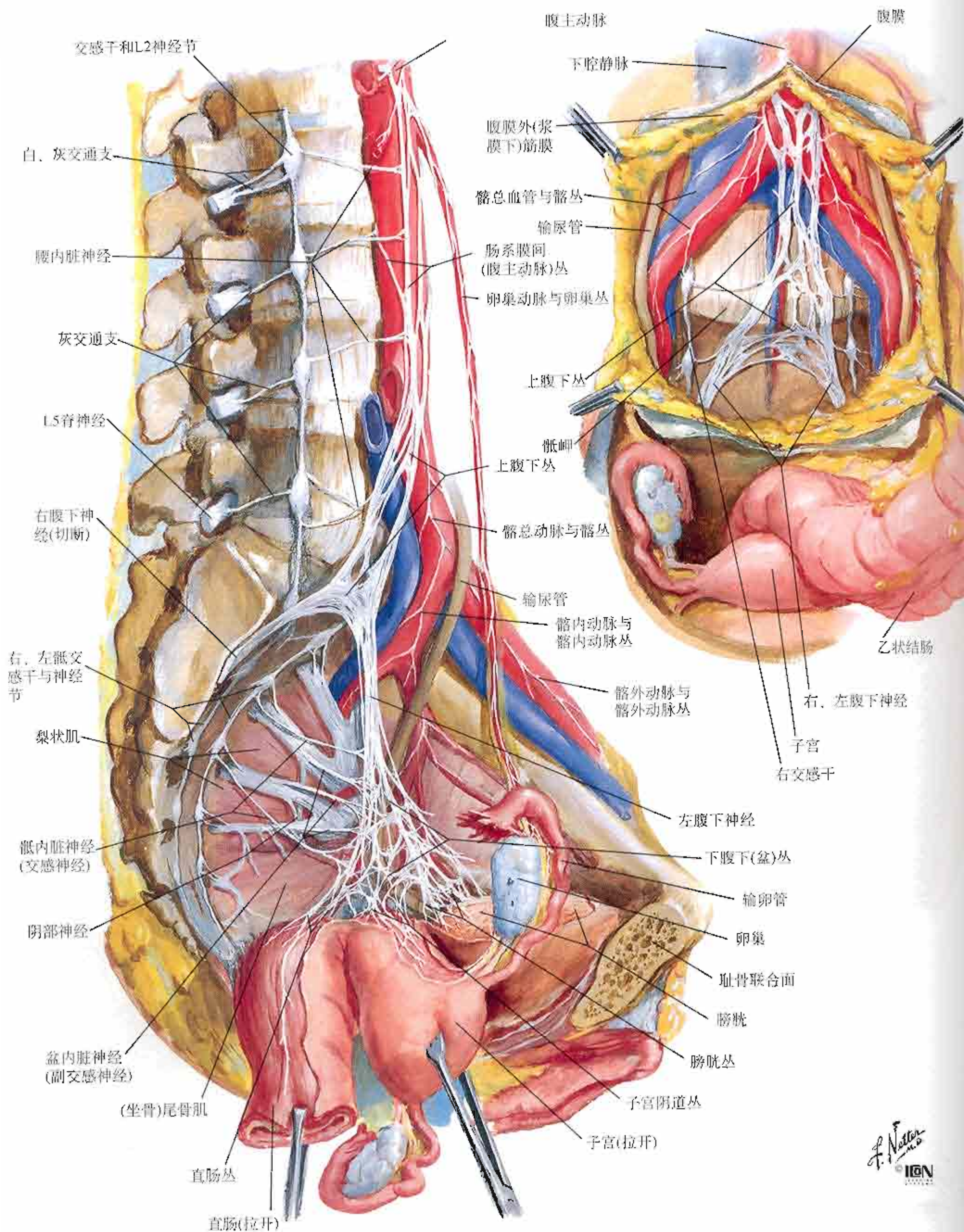
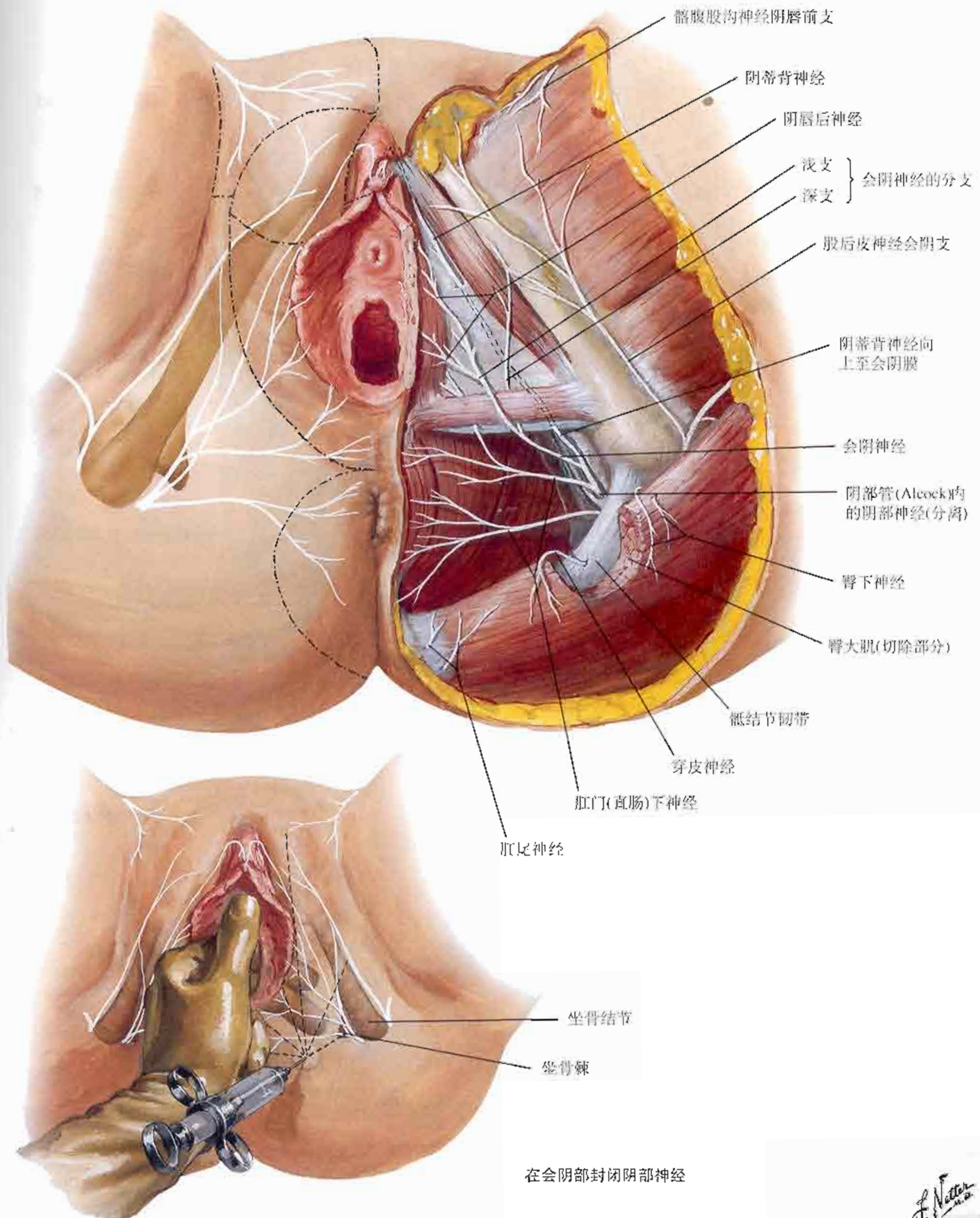


图392

盆和会阴



F. Netter M.D.
© 2004

图393

分娩的神经通路

参见图 159

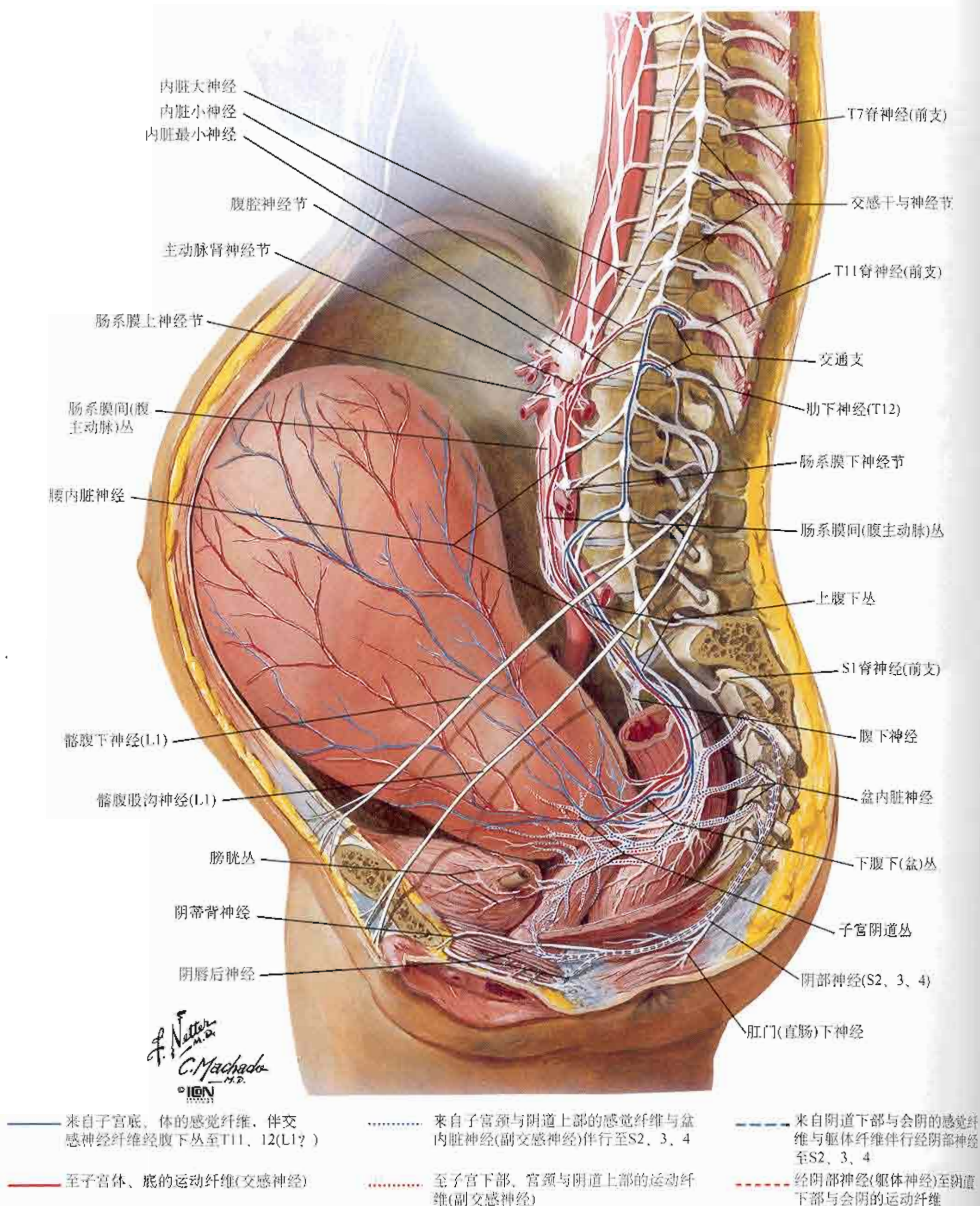
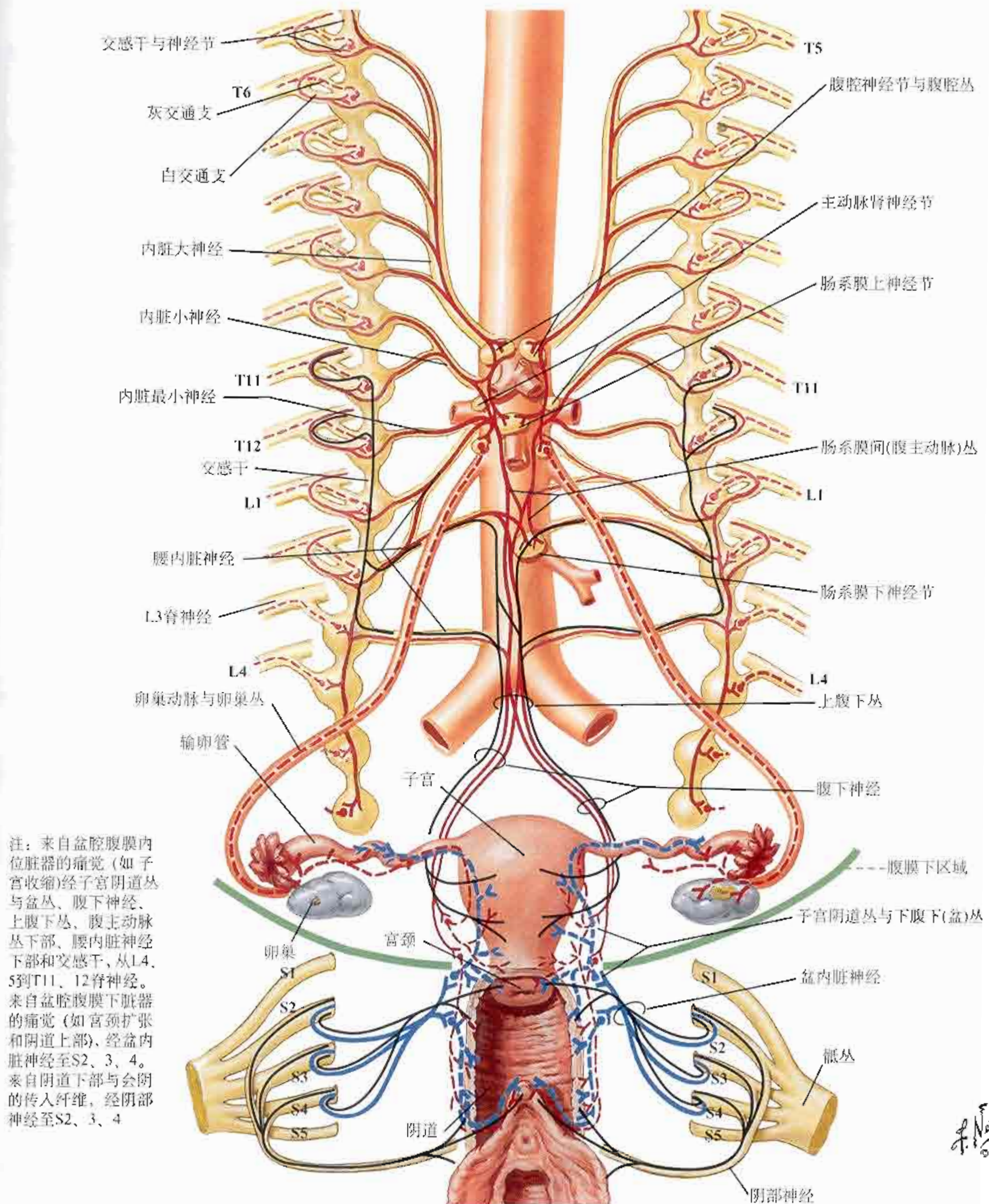


图394

盆和会阴



交感纤维 { 突触前纤维 ————
突触后纤维 - - - - -

副交感纤维 { 突触前纤维 ————
突触后纤维 - - - - -

传入纤维 ————

男性生殖器的神经支配：示意图

参见图 160

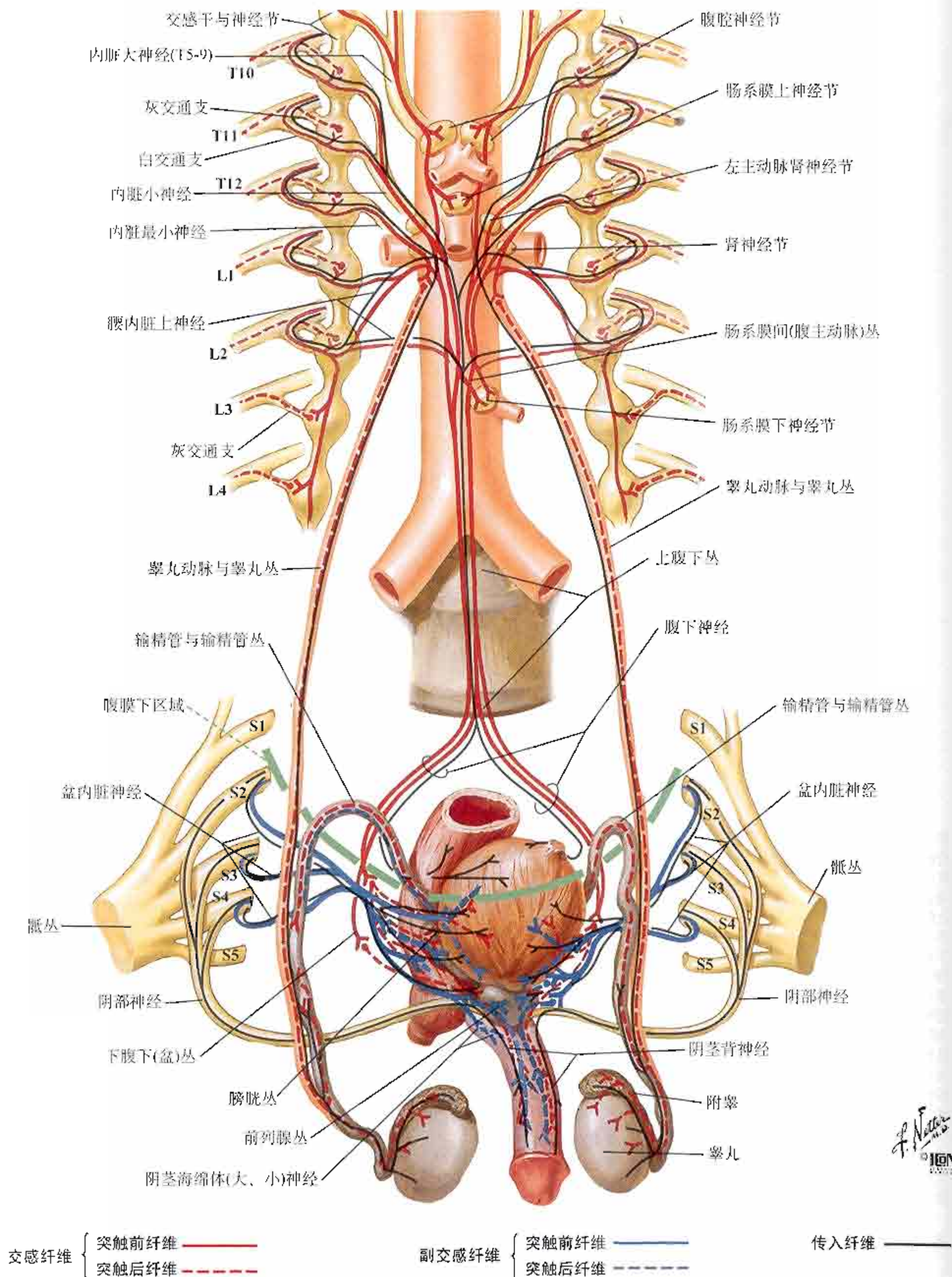


图396

盆和会阴

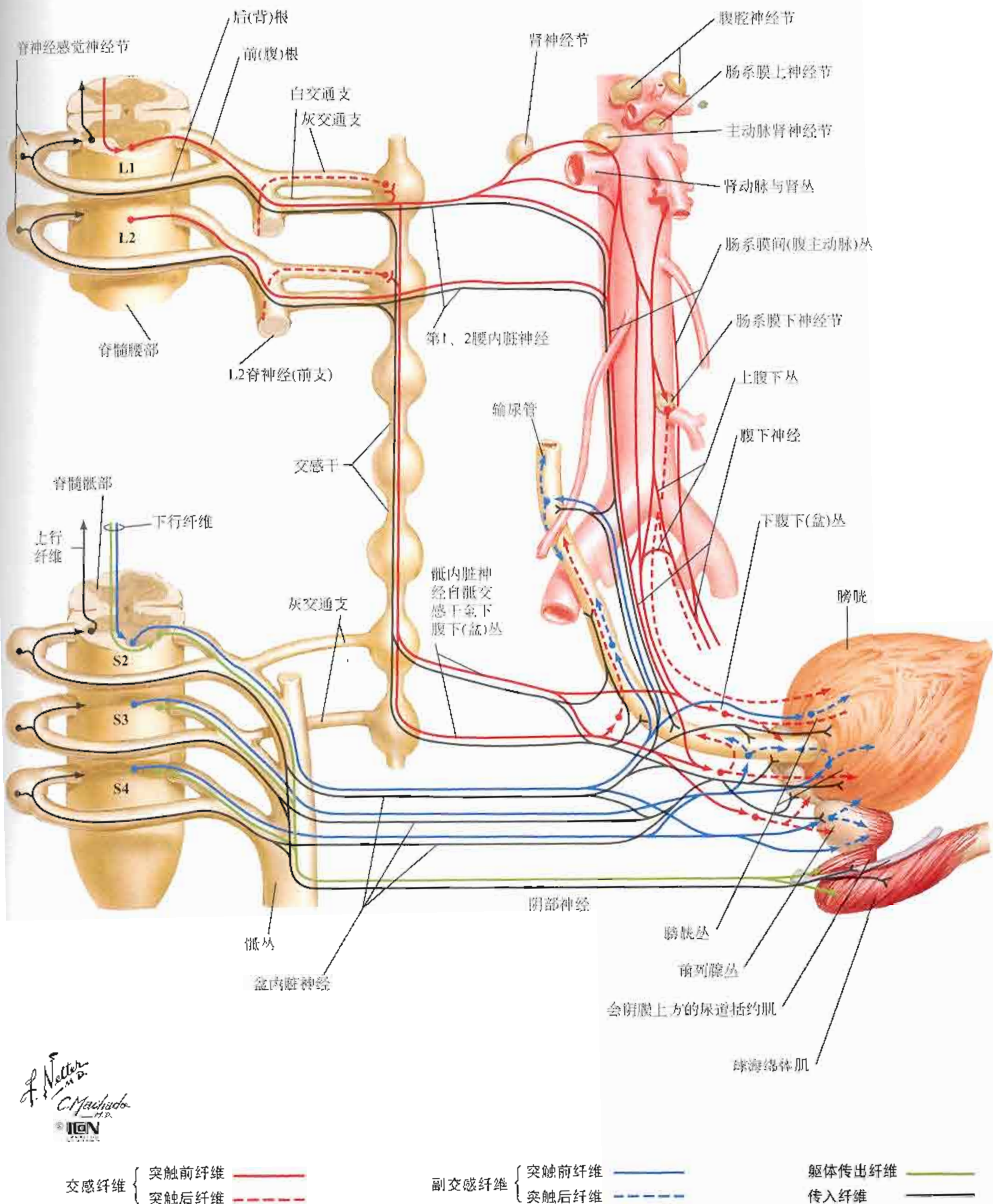


图397

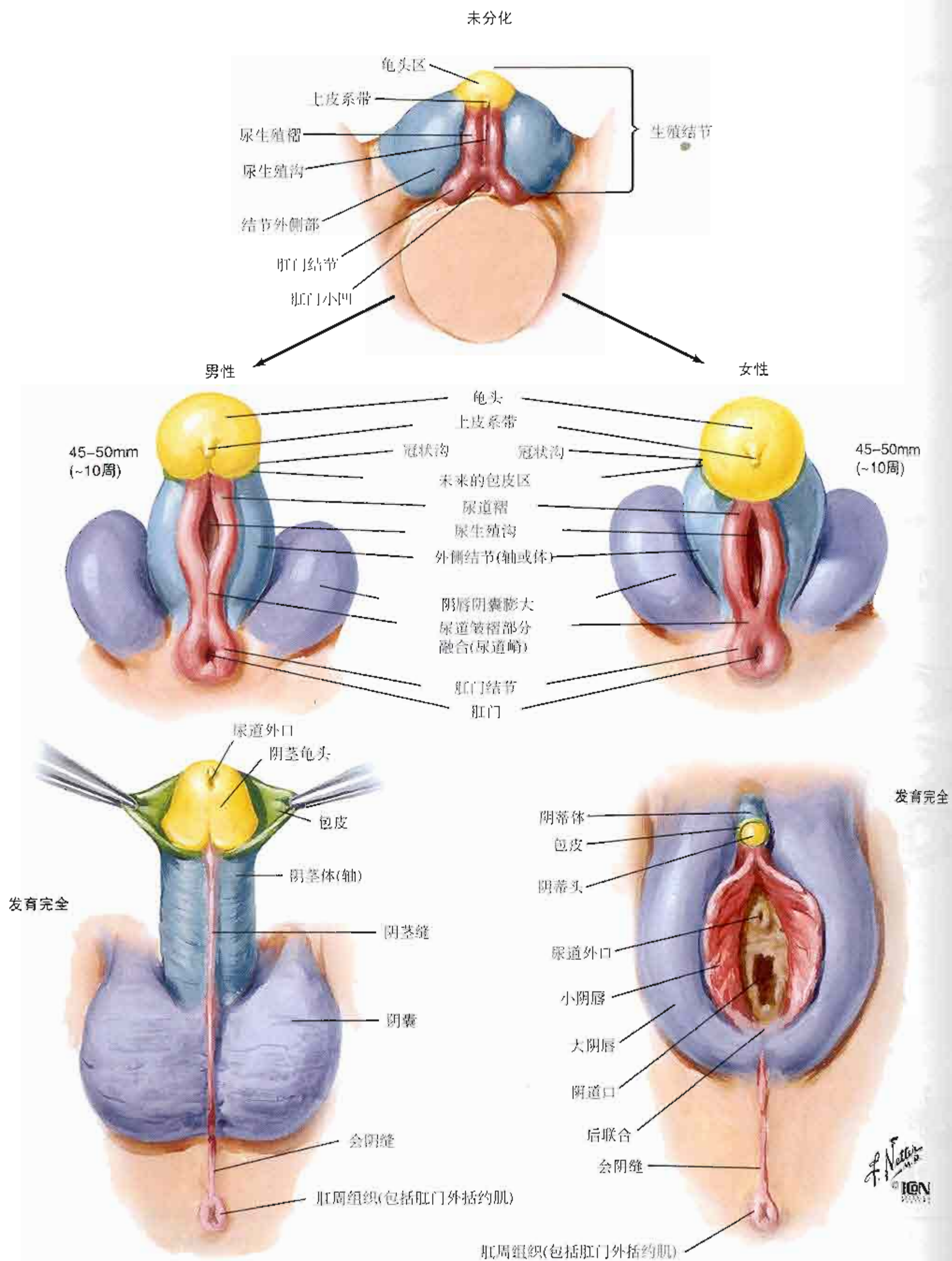
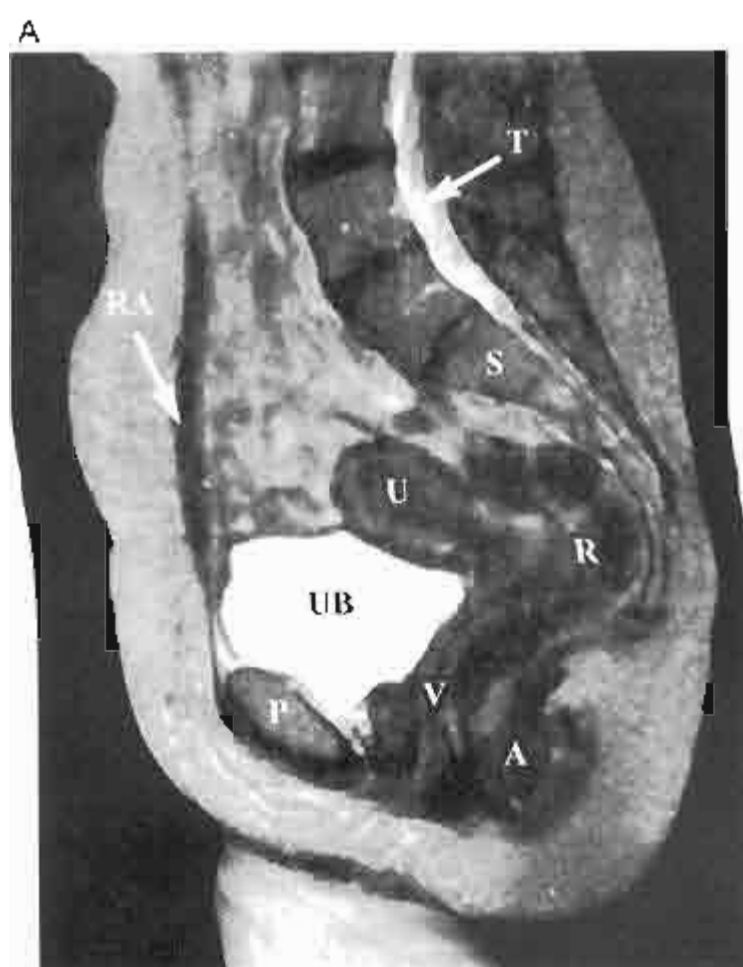

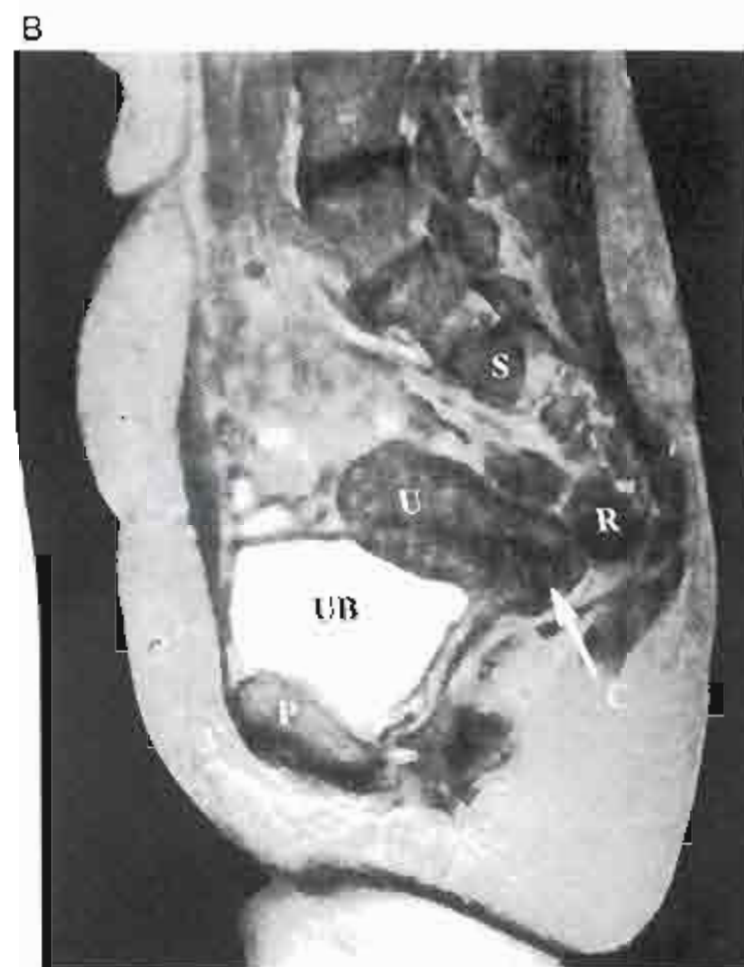
图398

盆腔扫描：矢状位MRI 影像

女性骨盆 正中(A)与旁正中(B)矢状位MRI 影像

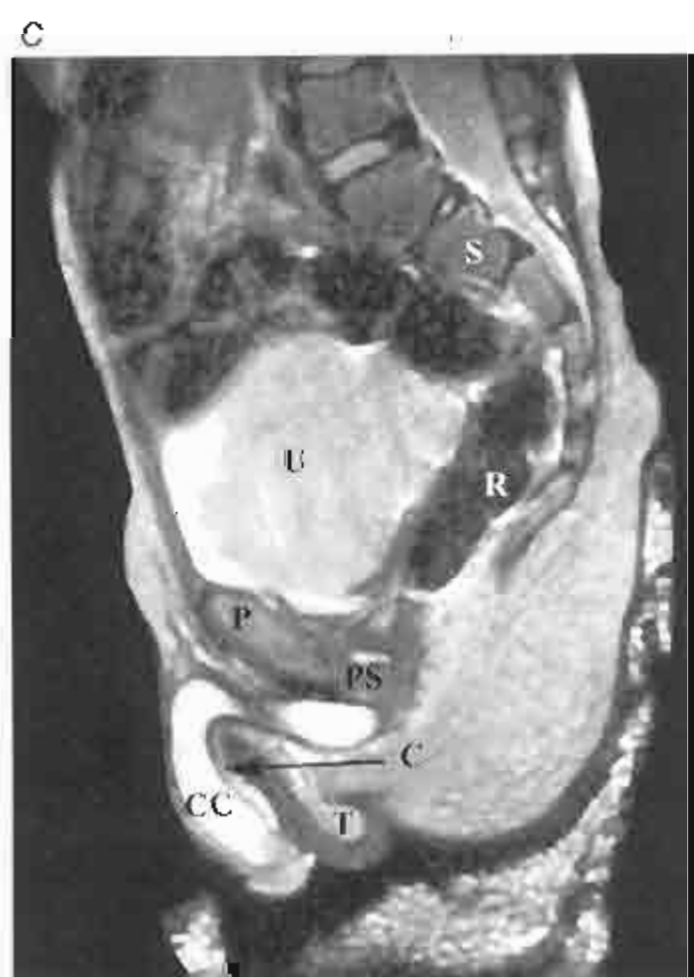

A 肛管
C 宫颈外口
P 耻骨联合
R 直肠
RA 腹直肌

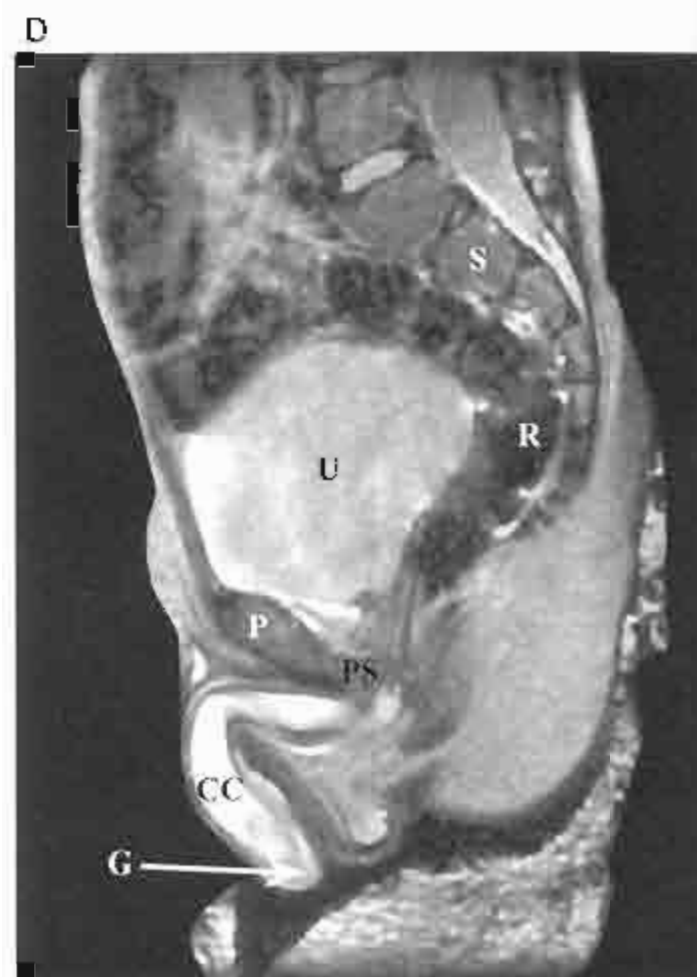


S 骶骨
T 脊膜囊
U 子宫
UB 膀胱
V 阴道

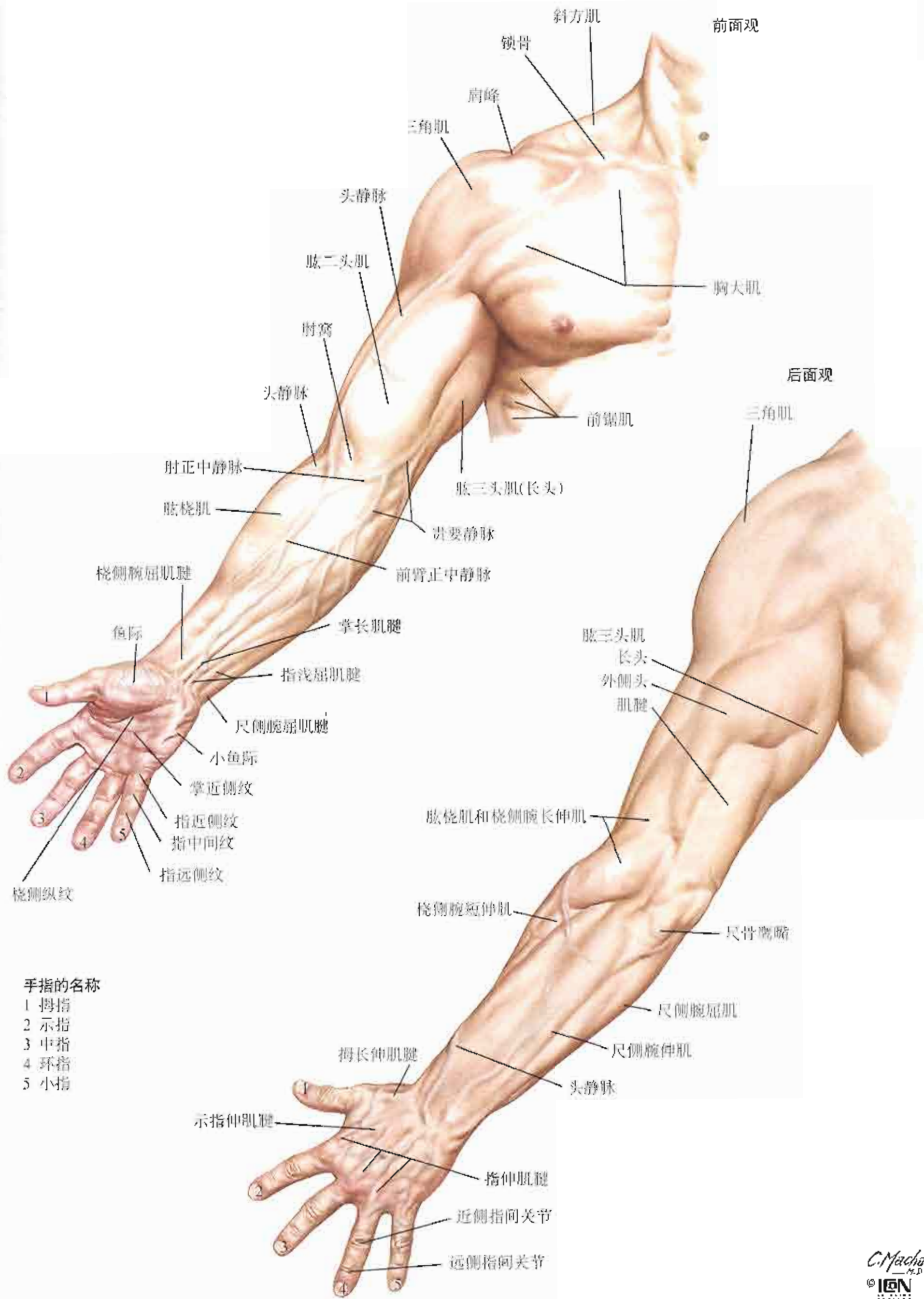
男性骨盆 正中(C)旁正中(D)矢状位MRI 影像



C 尿道海绵体
CC 阴茎海绵体
G 阴茎龟头
P 耻骨联合
PS 前列腺



R 直肠
S 骶骨
T 睾丸
U 膀胱



C. Machado
© I&N

右侧锁骨

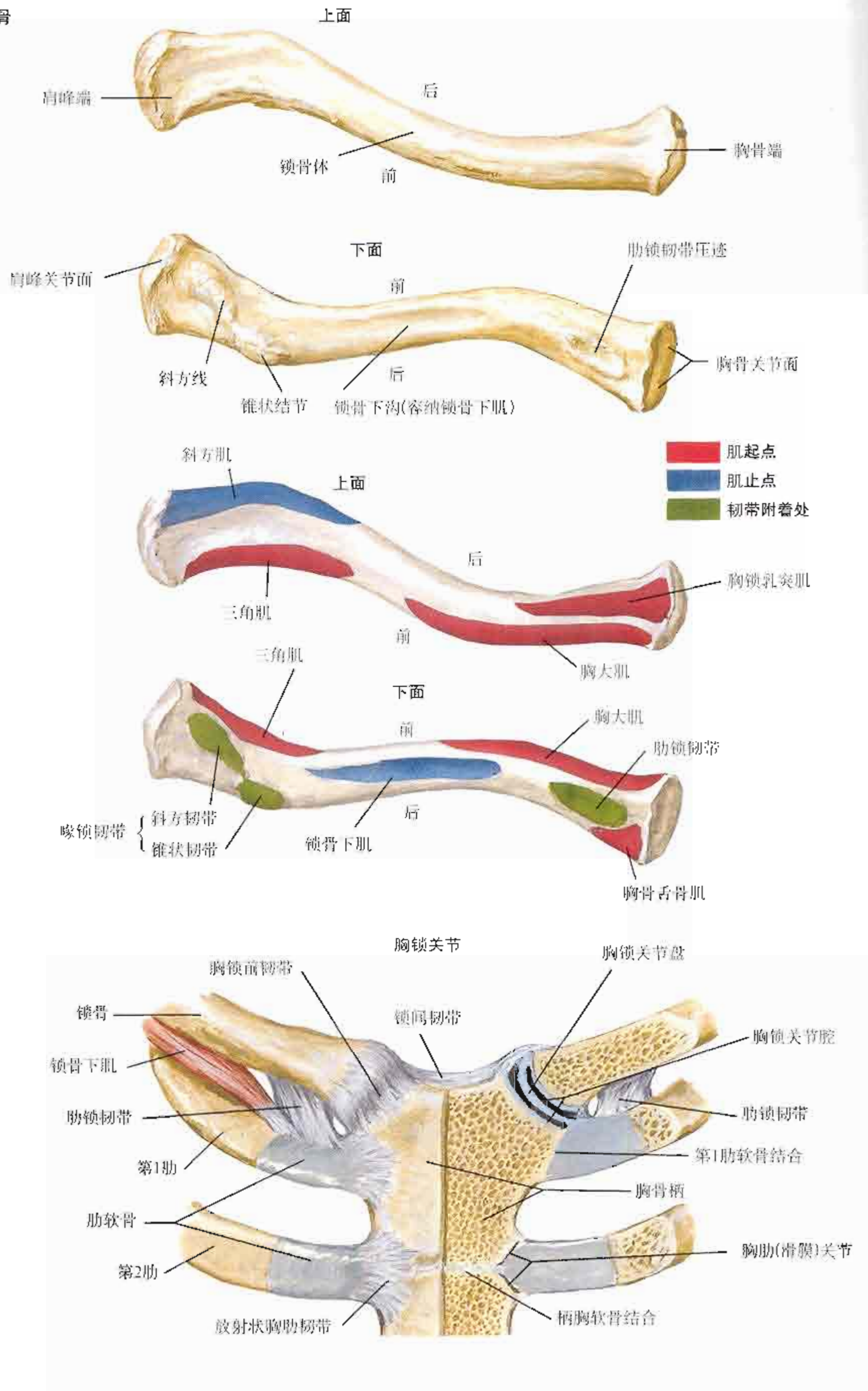
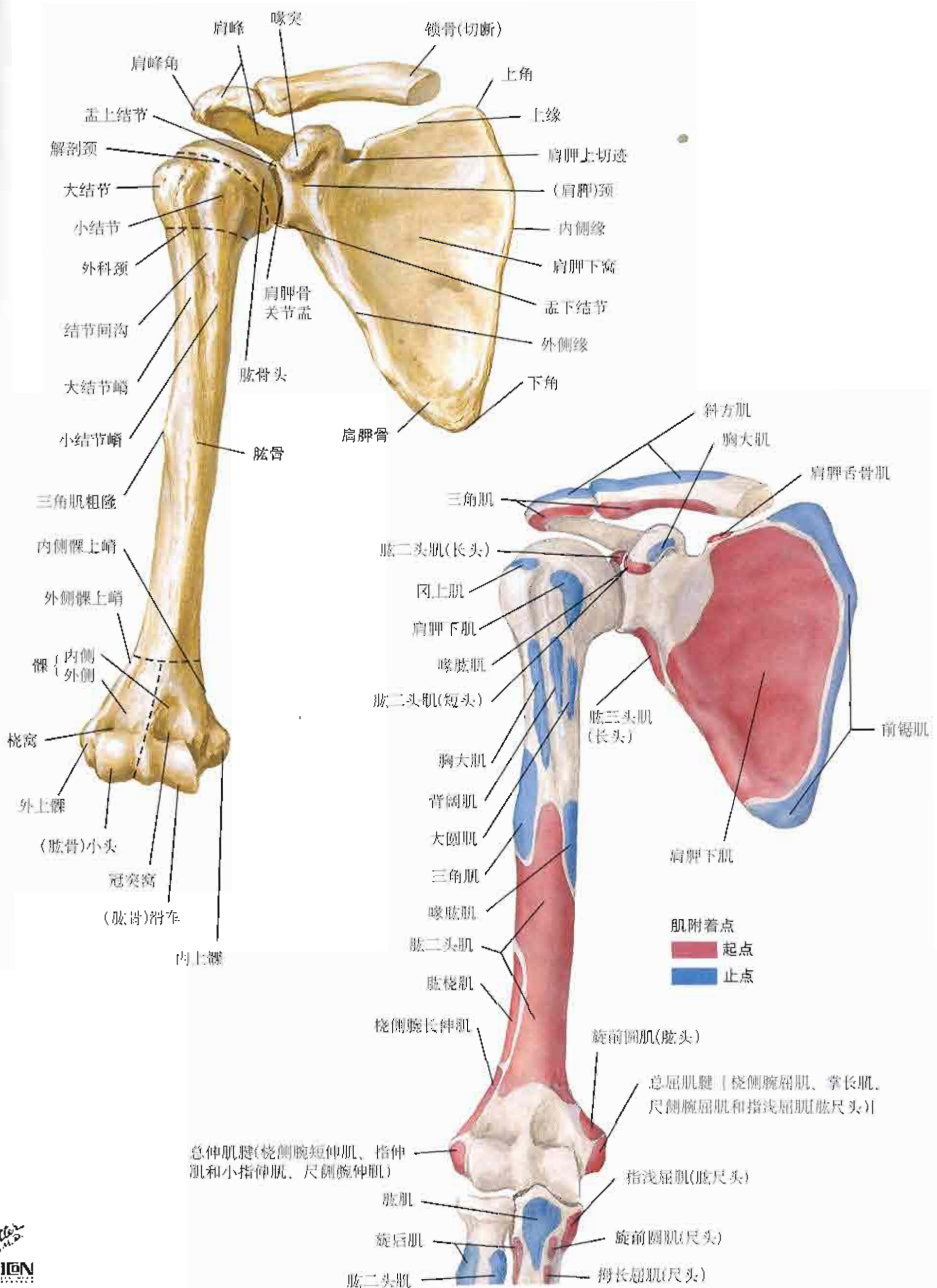


图402

参见图178



肱骨和肩胛骨：后面观

参见图178

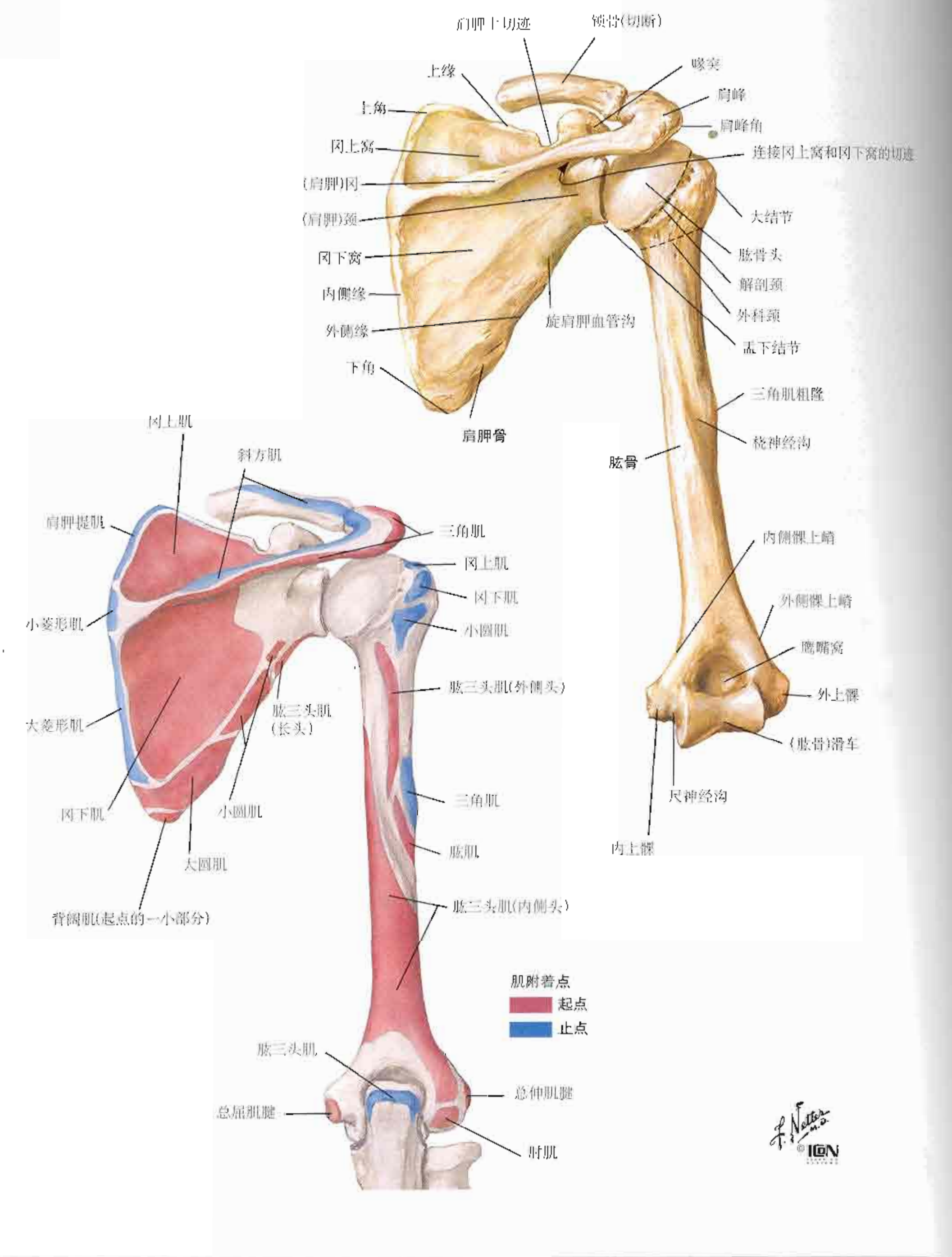
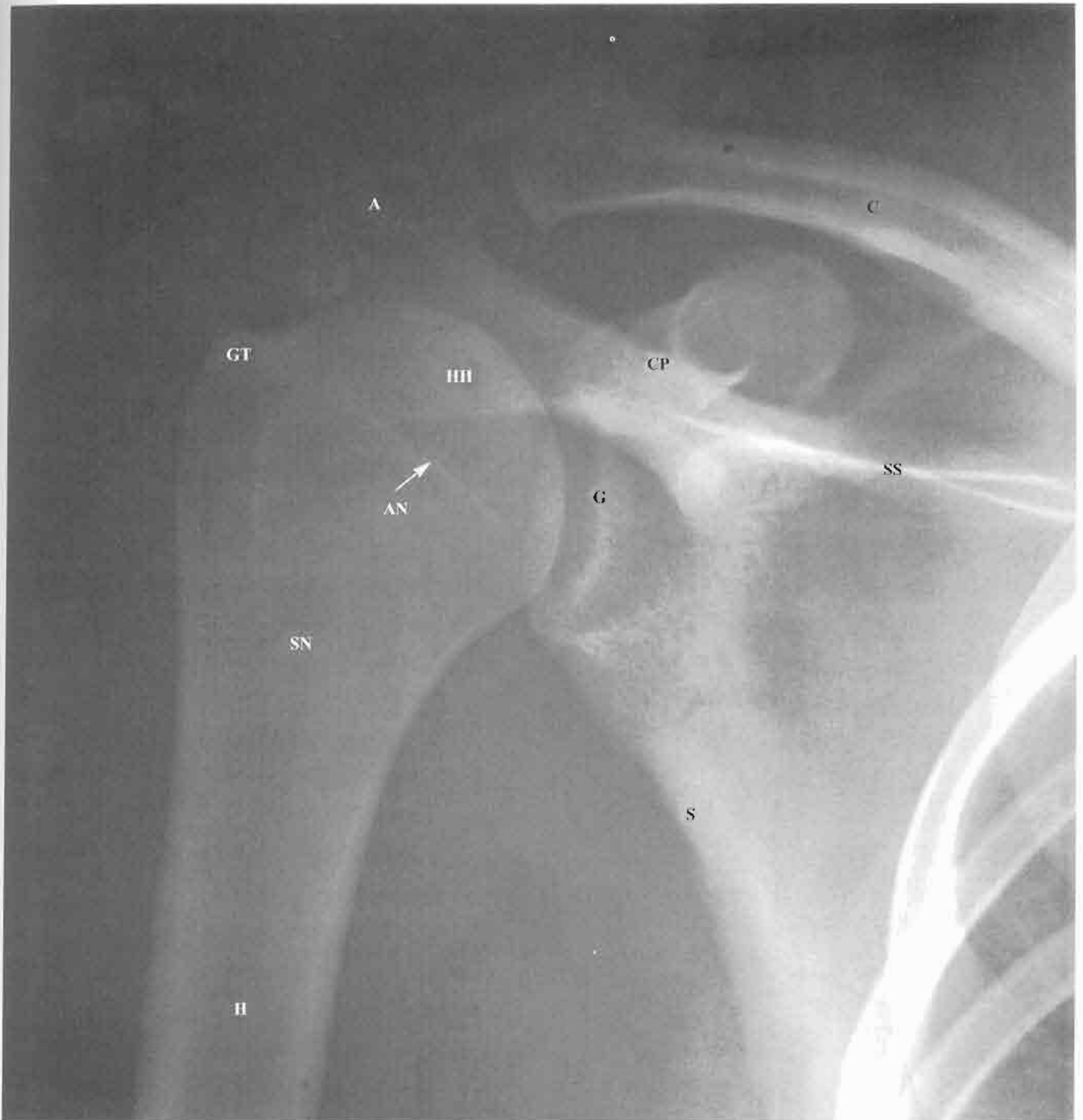

图404

上肢



A	肩峰
AN	肱骨解剖颈
C	锁骨
CP	喙突
G	肩胛骨关节盂
GT	大结节
H	腋骨
HH	肱骨头
S	肩胛骨(外侧缘)
SN	肱骨外科颈
SS	肩胛冈

肩(盂肱)关节

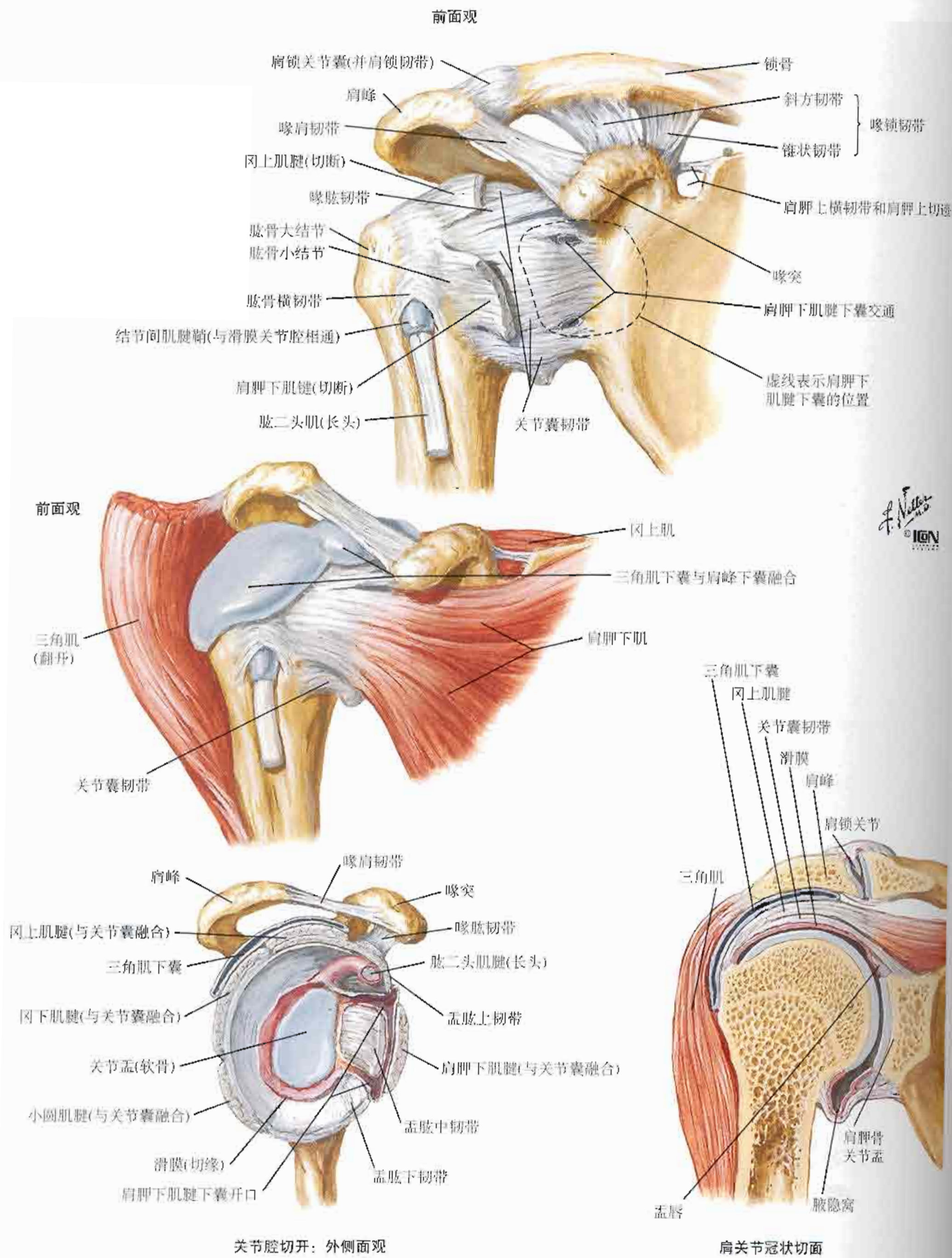



图406

上肢




运动科学网站



运动科学网站



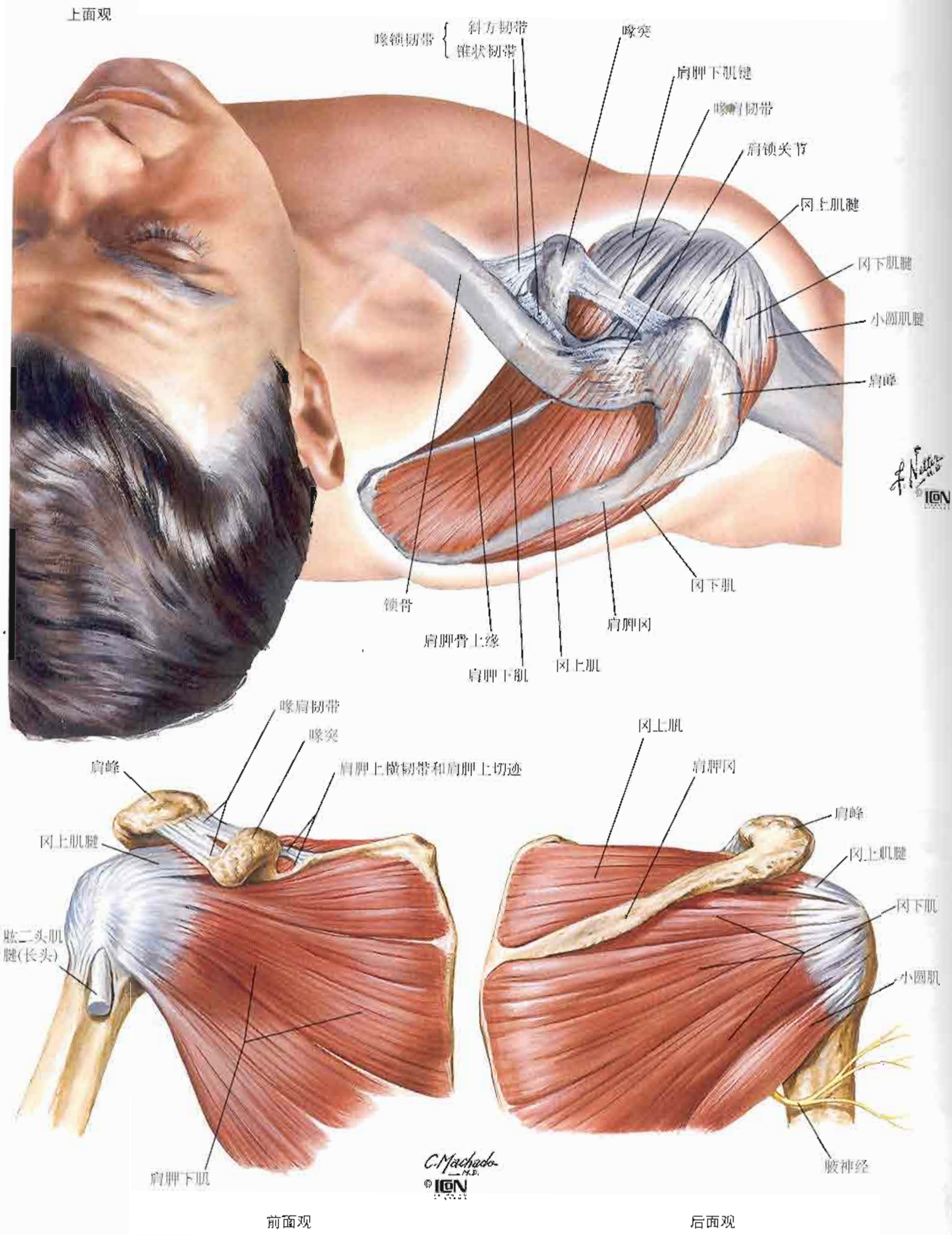
运动科学网站

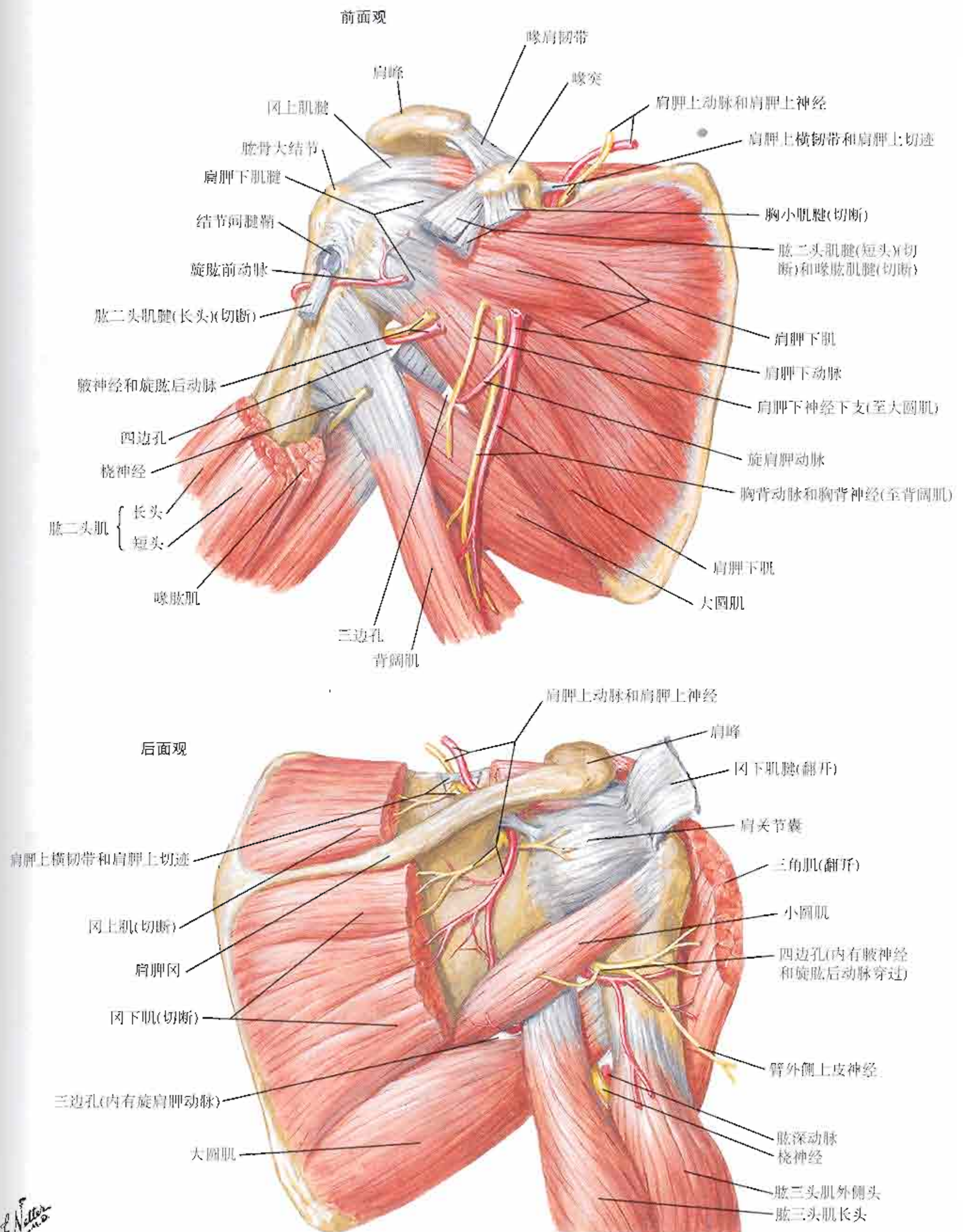


运动科学网站



运动科学网站





参见图29、417

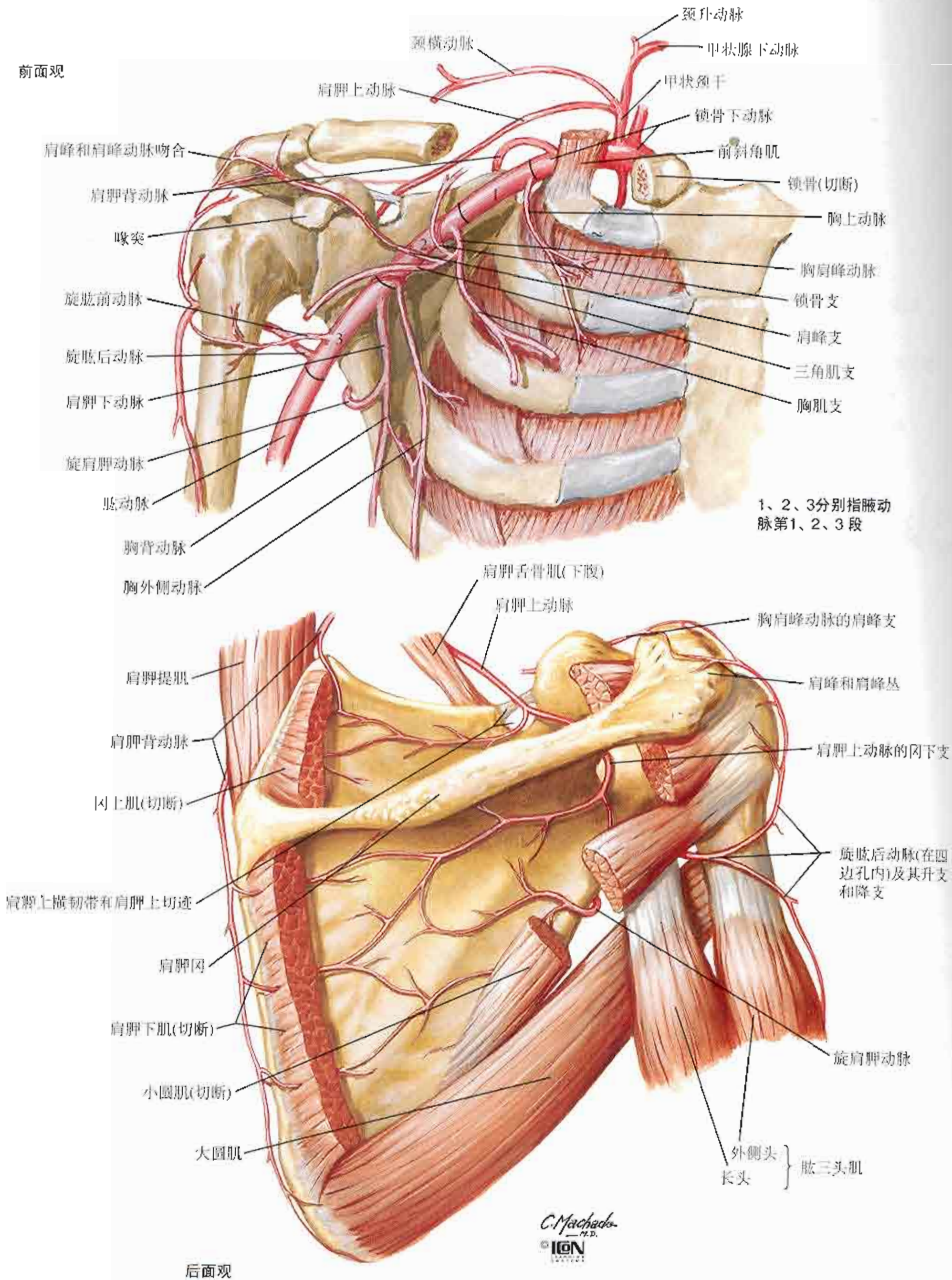
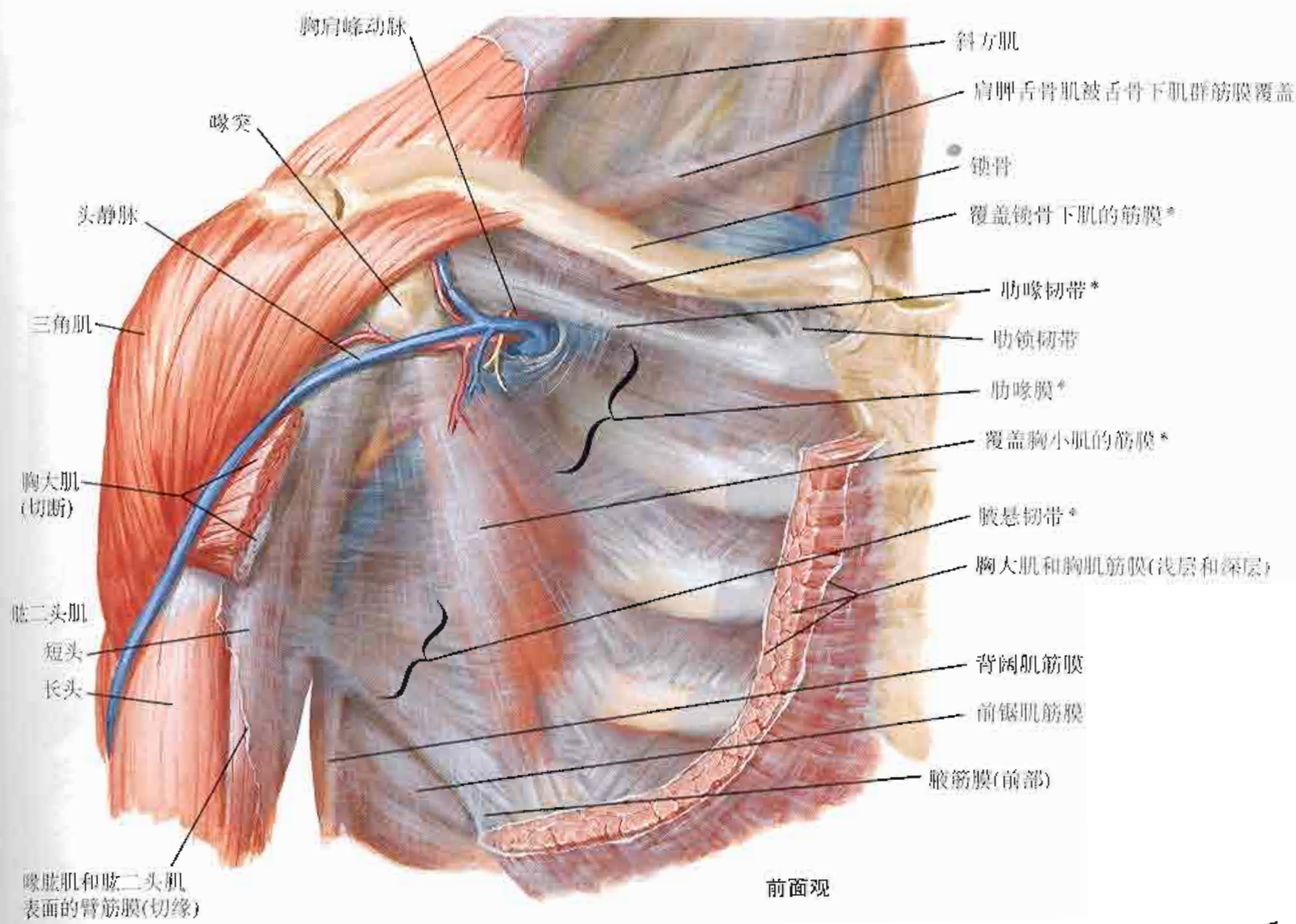


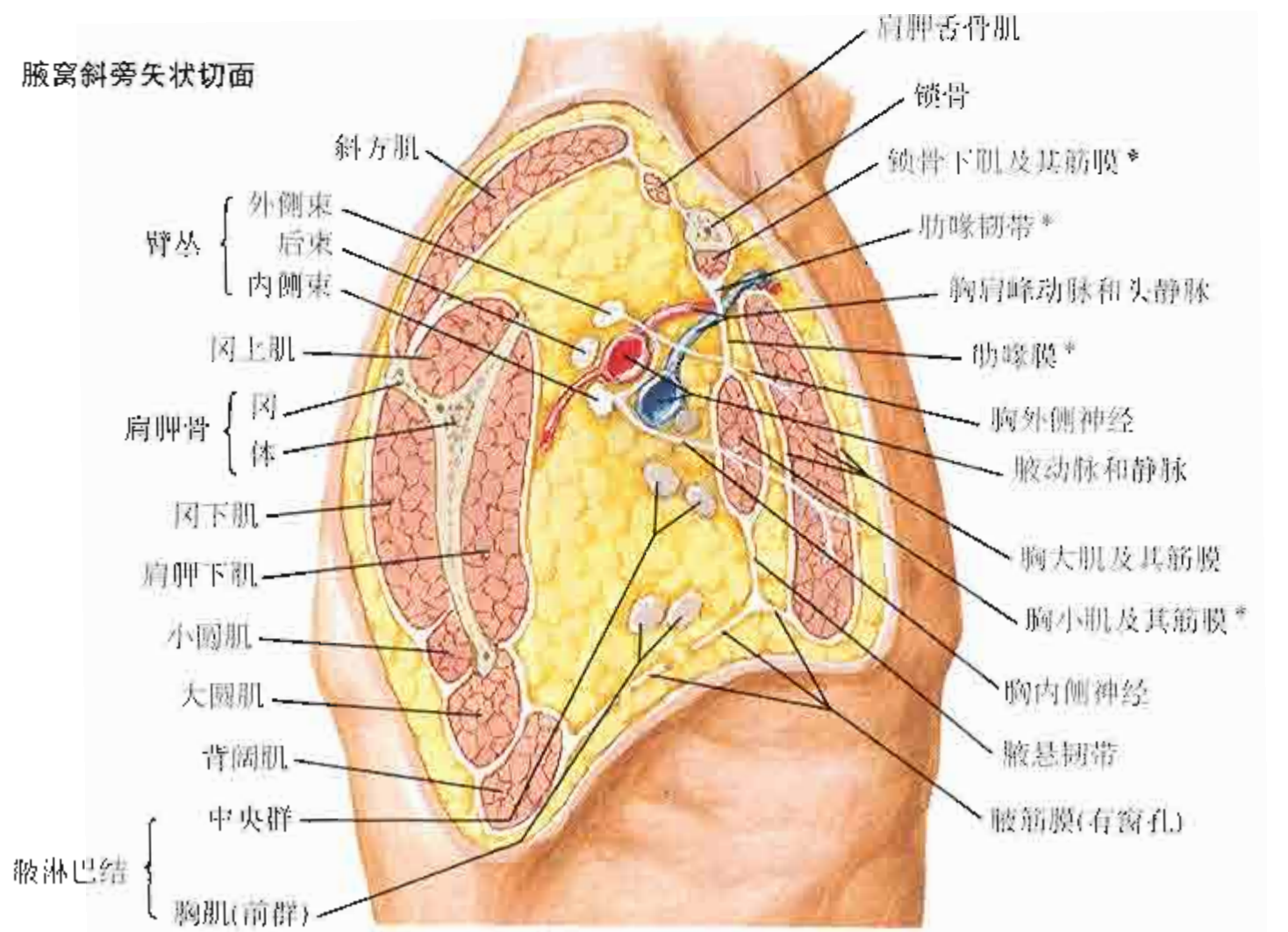
图410

参见图182



F. Netter M.D. IGV

腋窝斜旁矢状切面



* 锁胸筋膜的组成部分

腋窝(解剖): 前面观

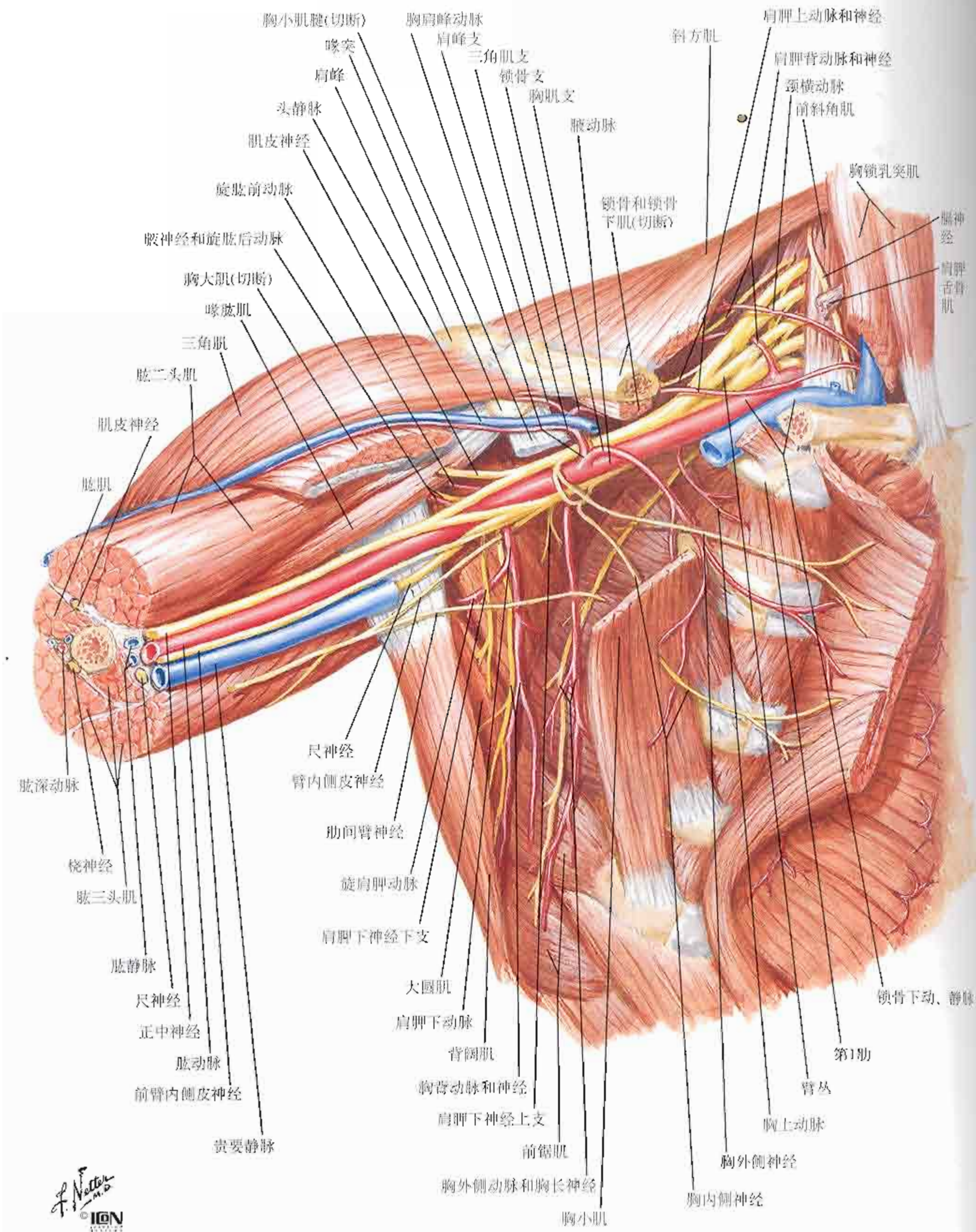
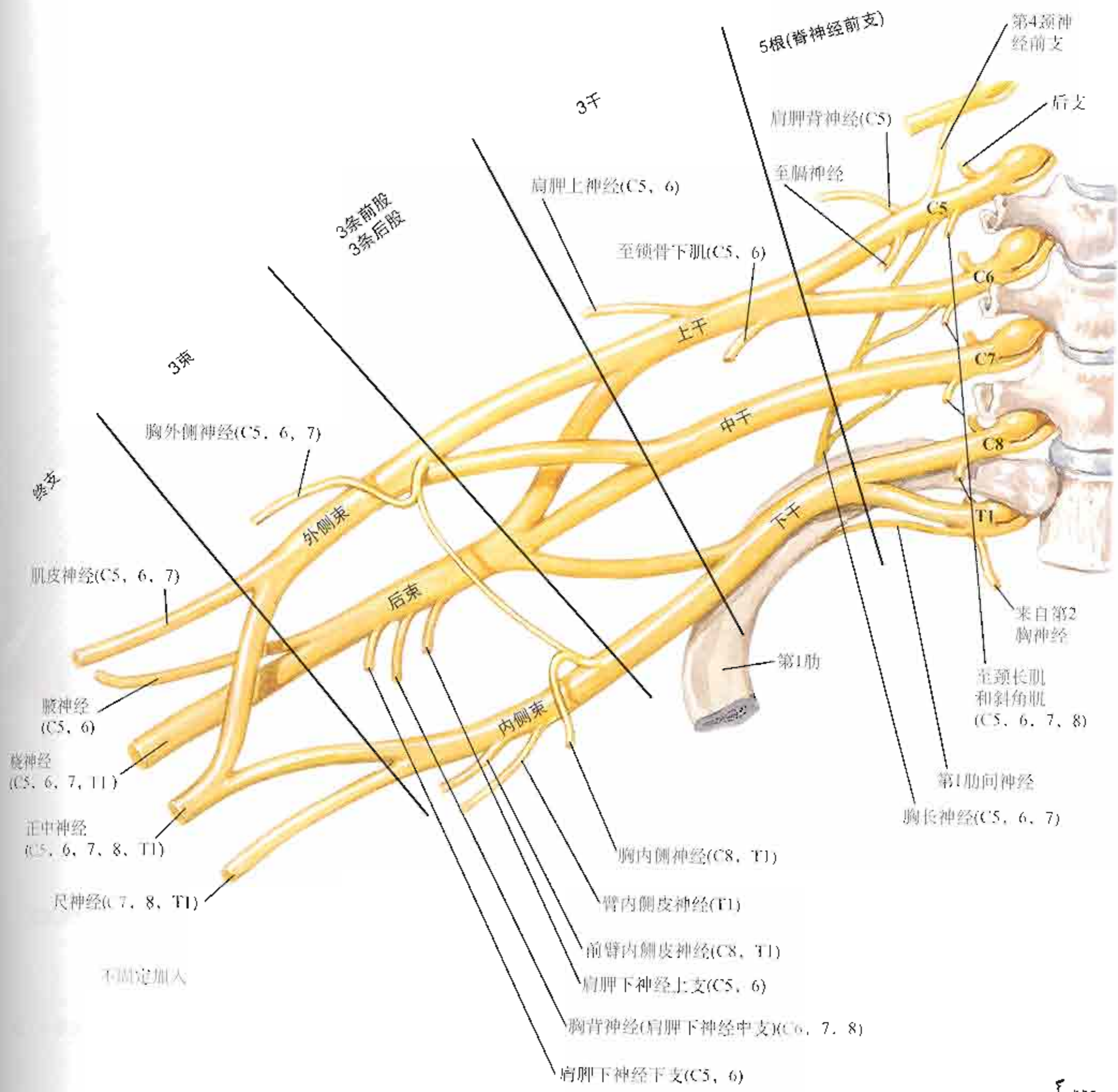


图412

注：示臂丛的常见组成。前置型臂丛第4颈神经前支较大而缺乏第1胸神经前支，后置型臂丛缺乏第5颈神经前支但含有第2胸神经前支



F. Netter M.D.
© IGV

臂肌：前面观

参见图 457

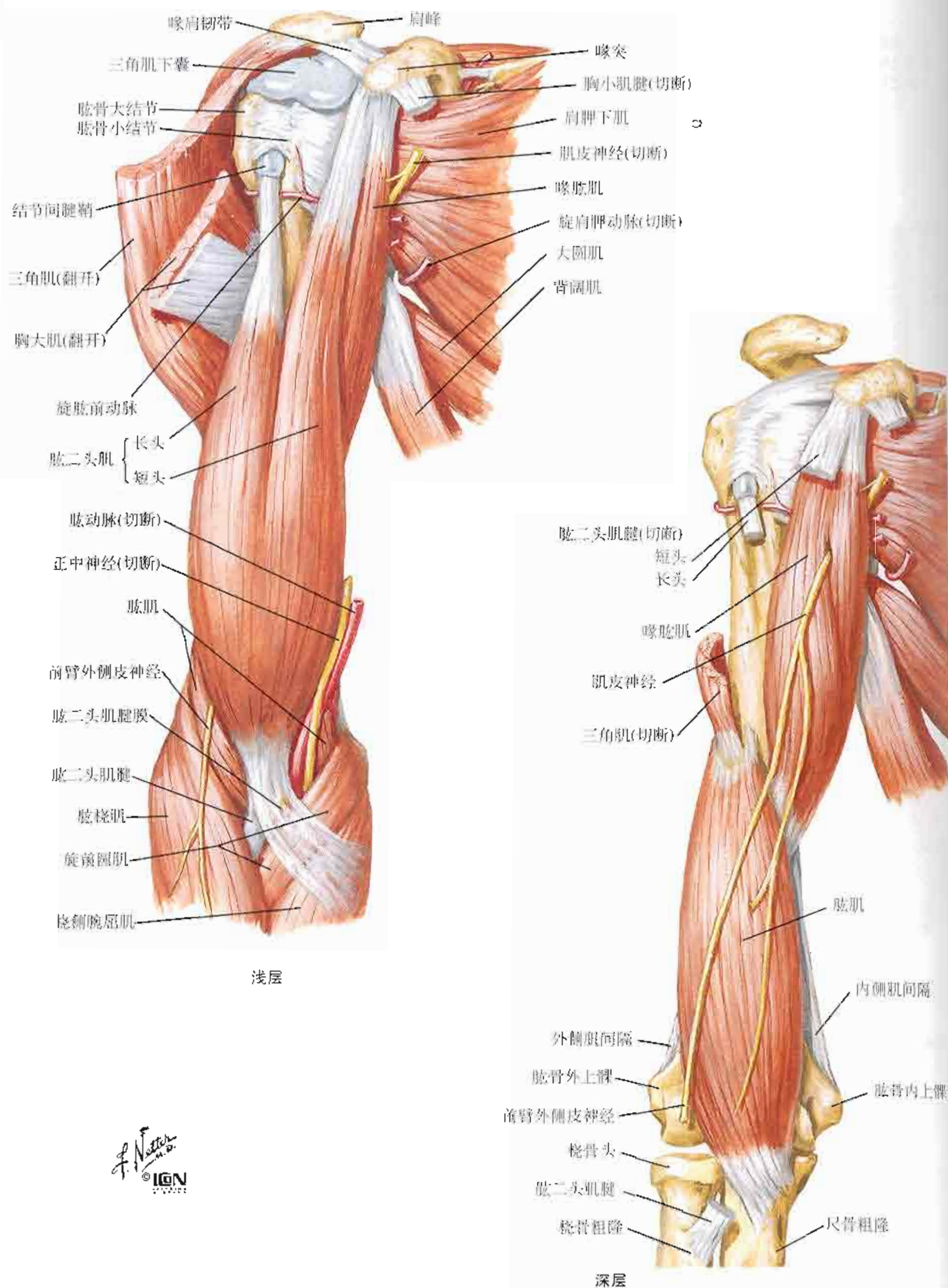


图414

上肢

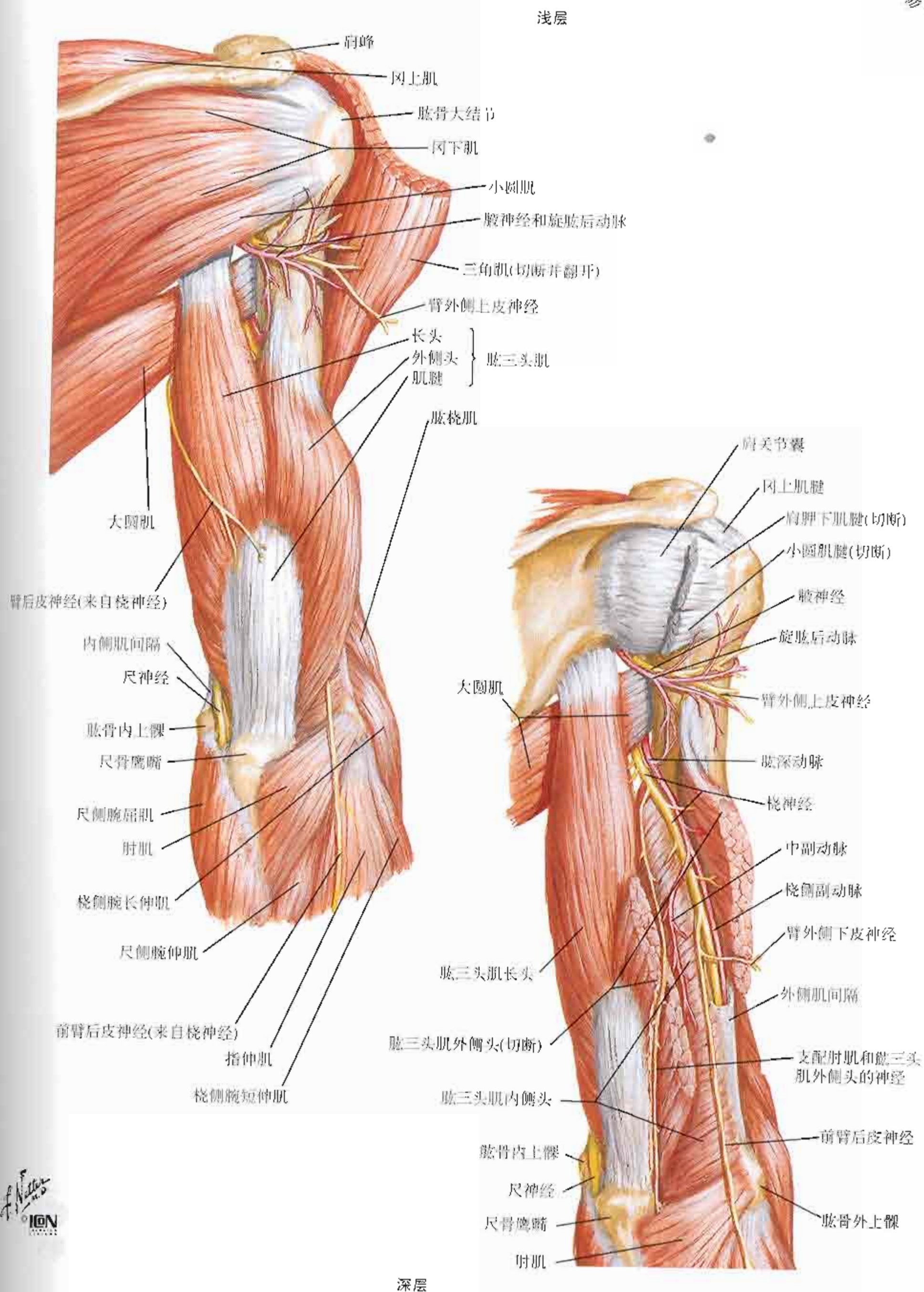


图415

肱动脉(原位)

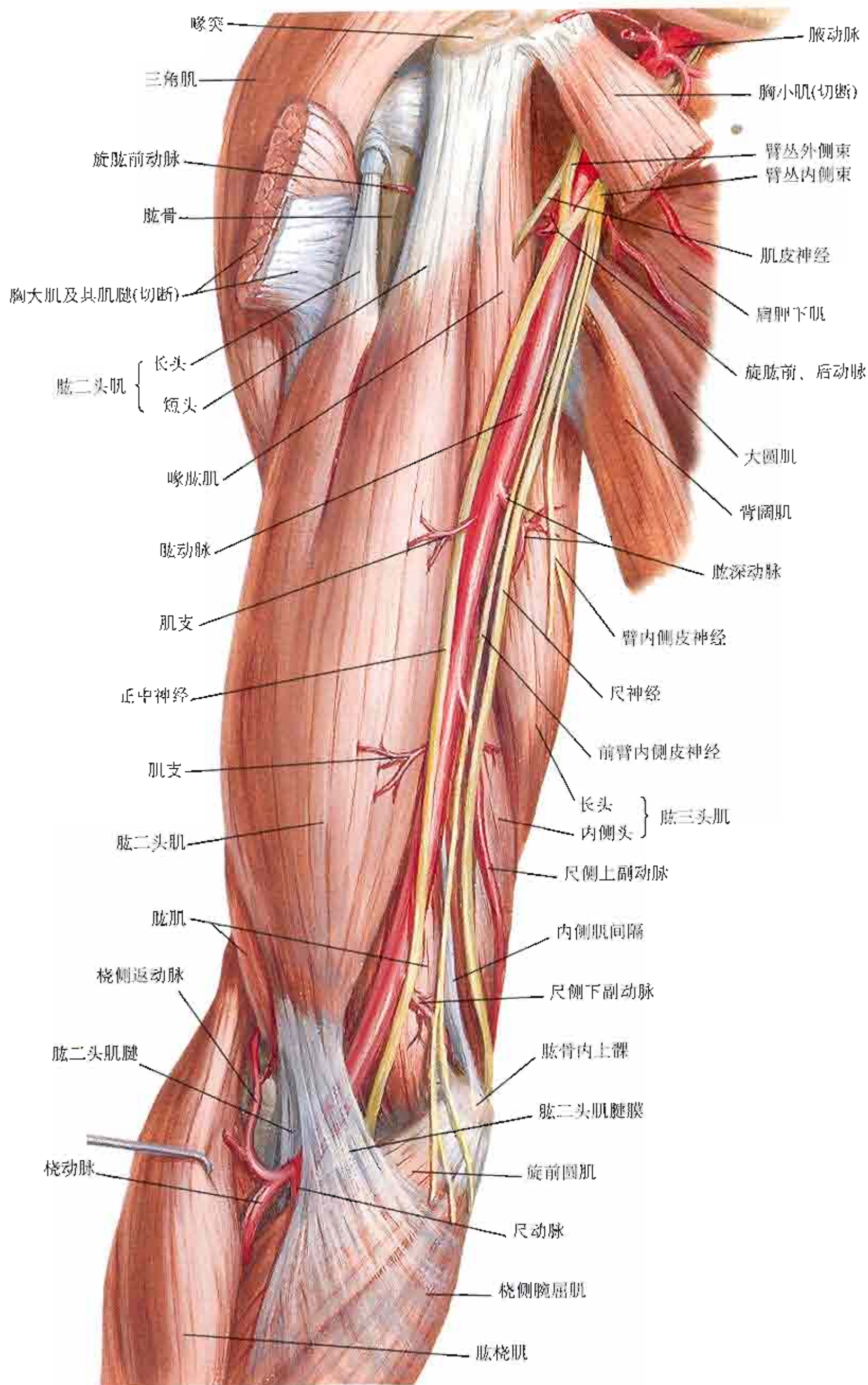
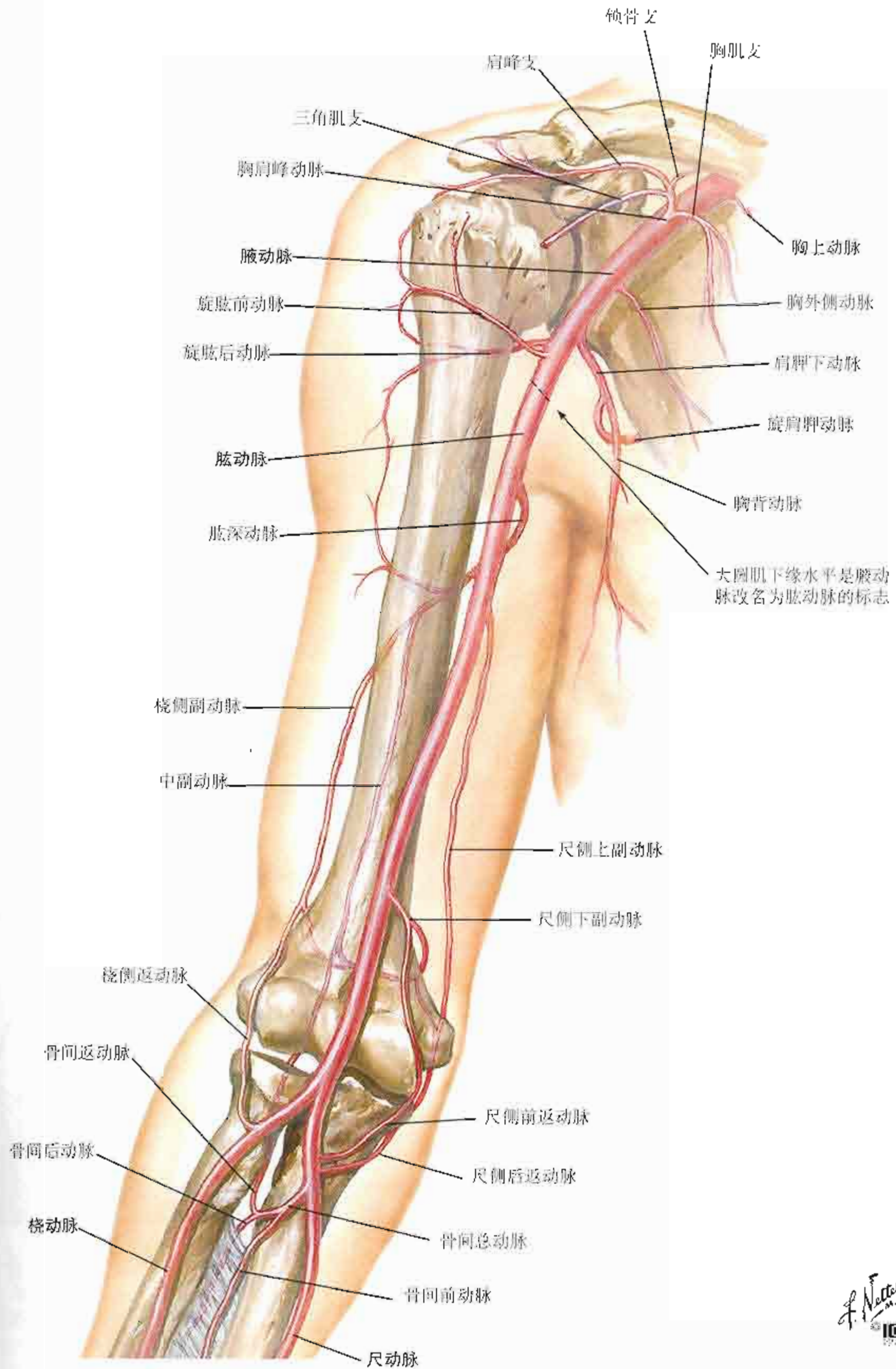


图416



F. Netter M.D.
© IGM

图417

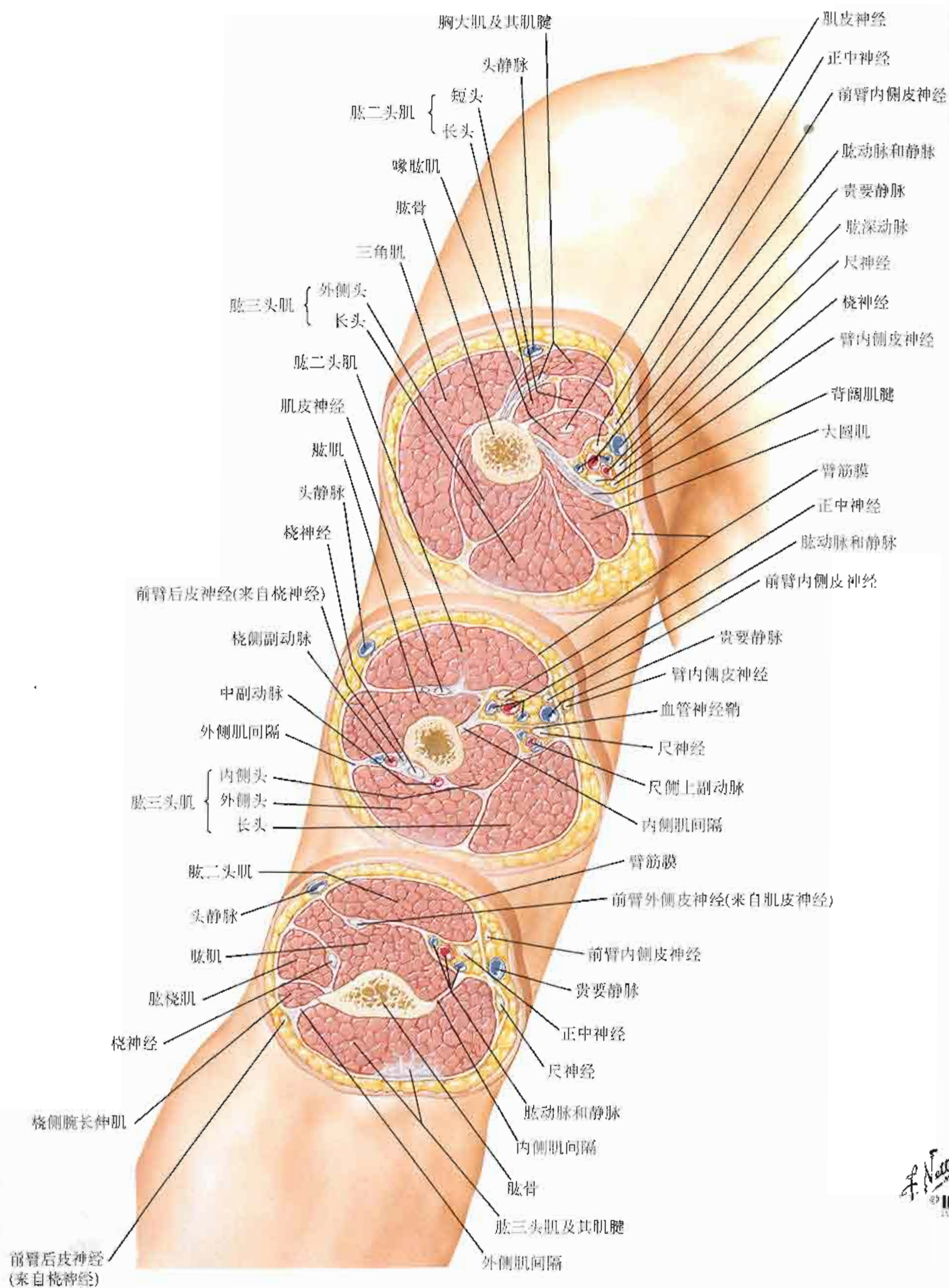
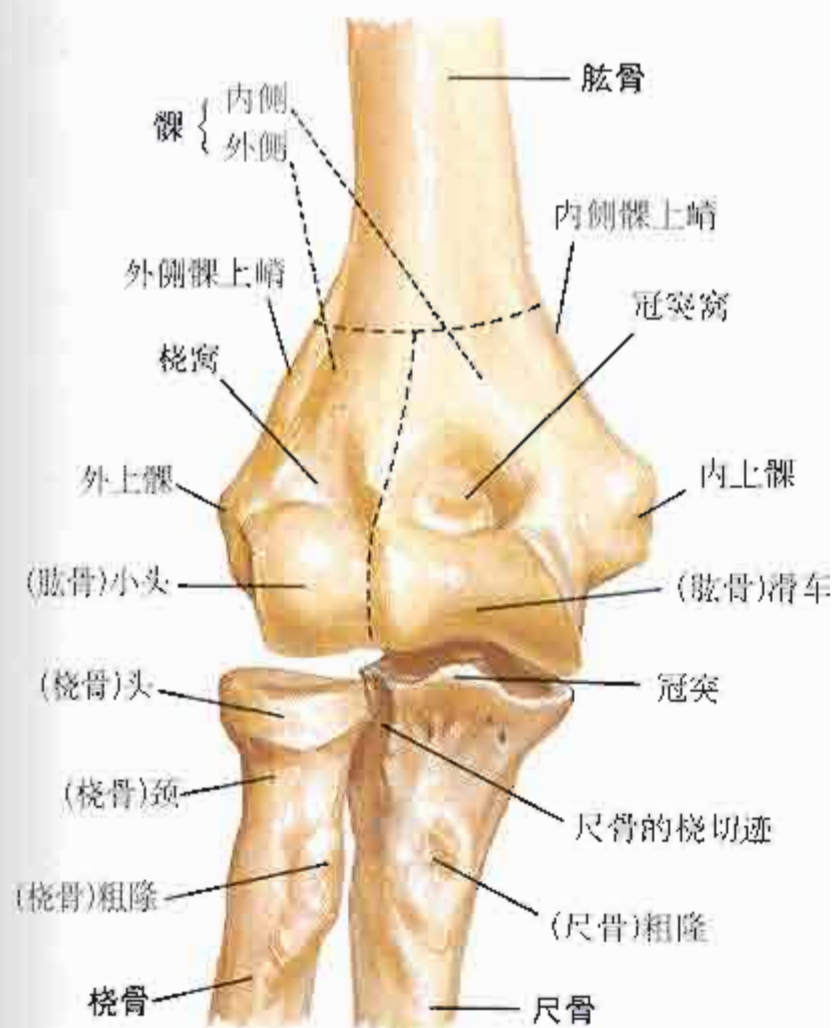
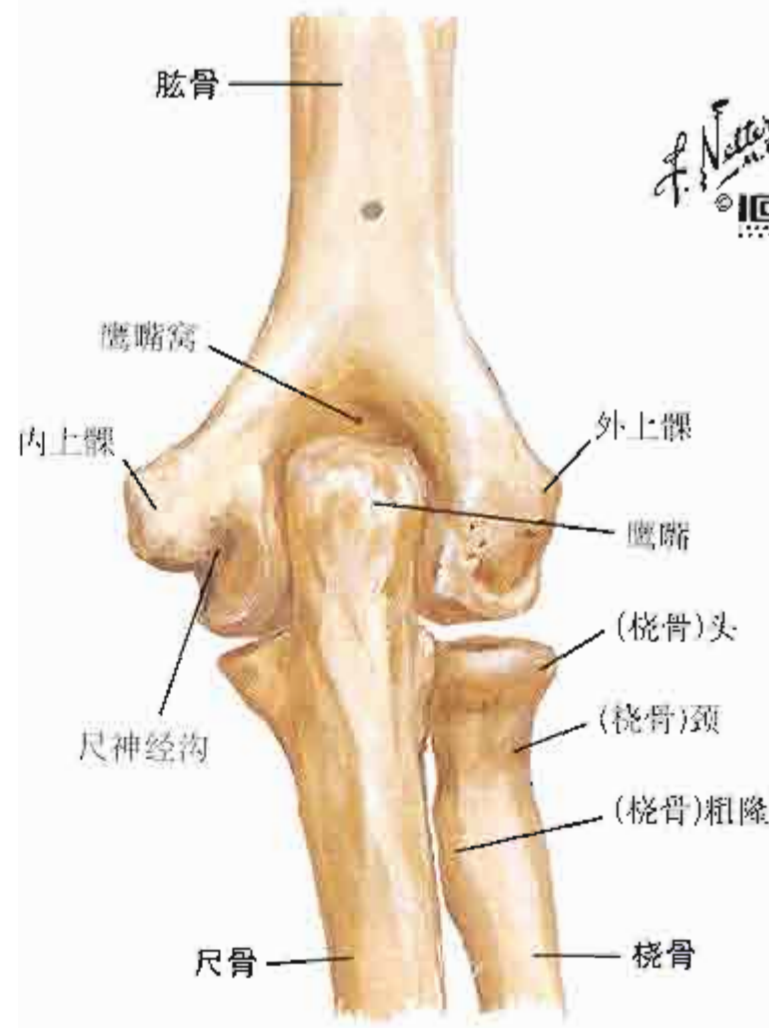


图418

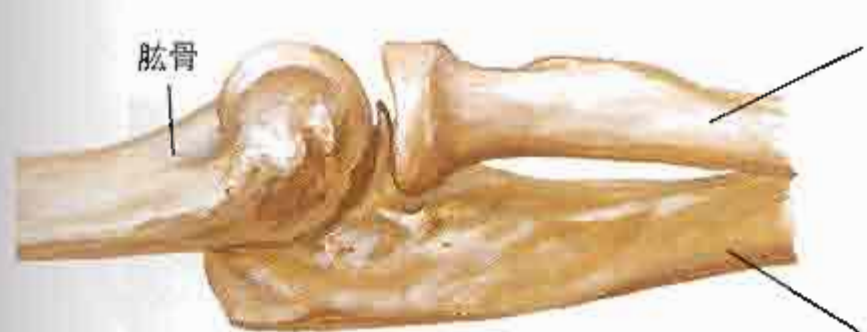右侧肘部



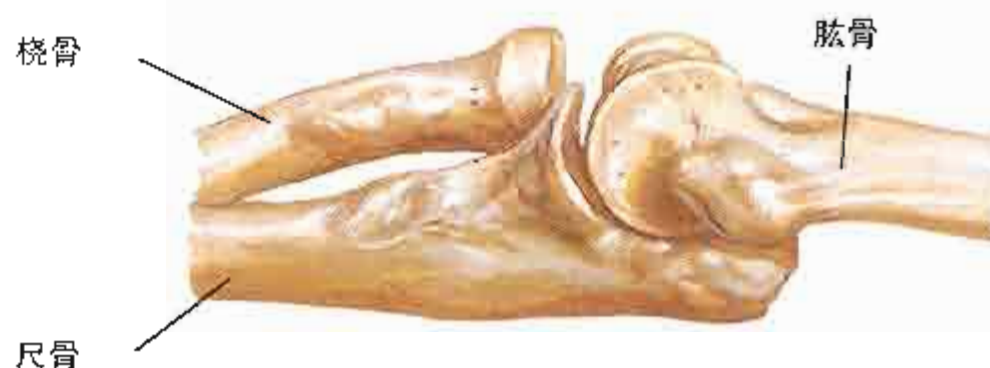伸位：前面观



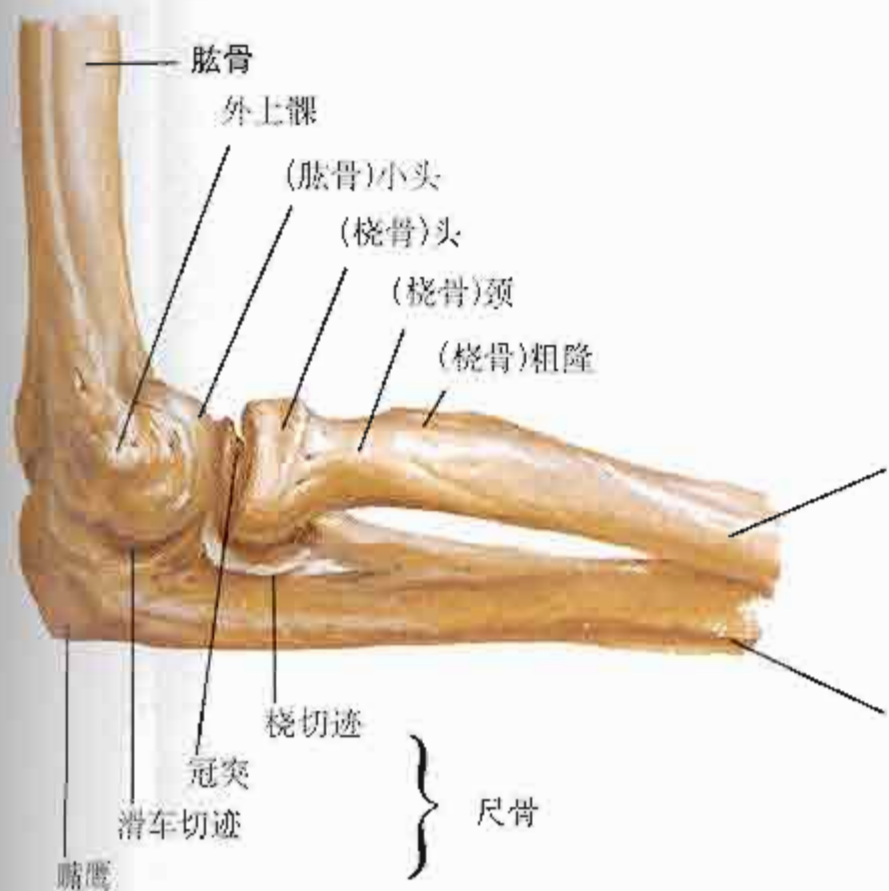
伸位：后面观



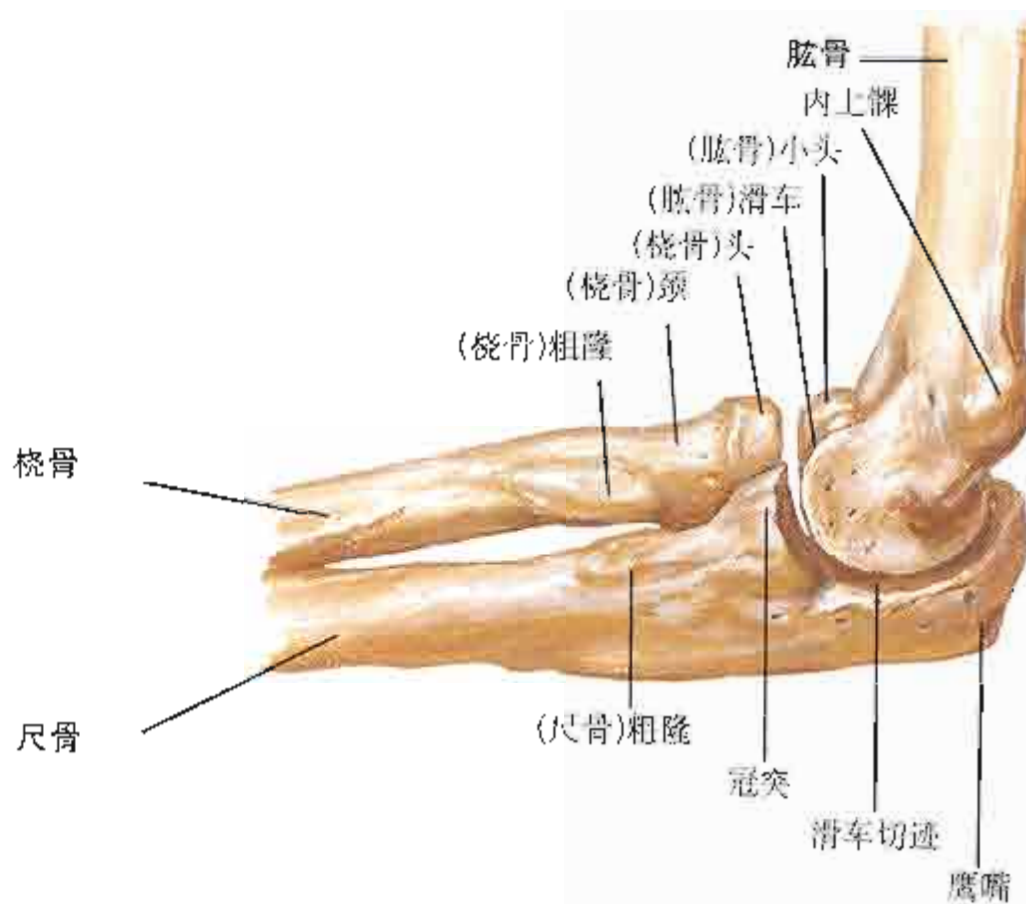
伸位：外侧面观



伸位：内侧面观



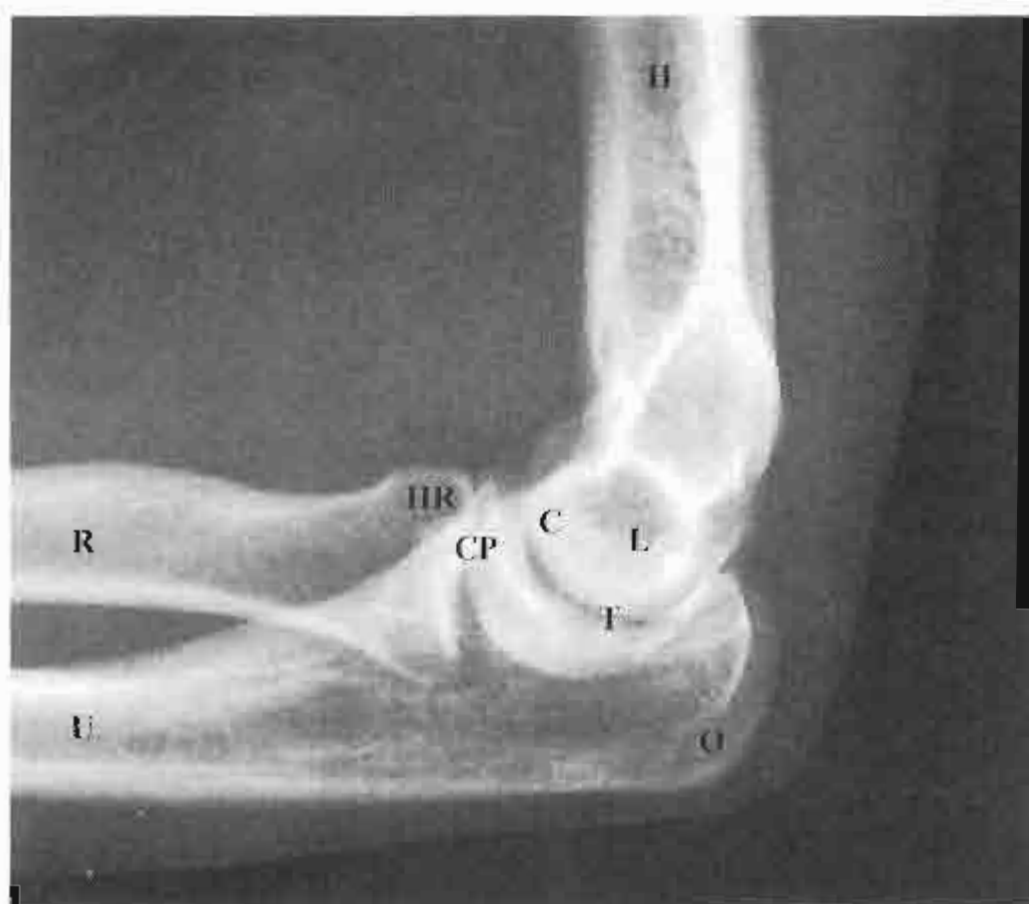
屈90°：外侧面观



屈90°：内侧面观

肘关节：X线平片

参见图419

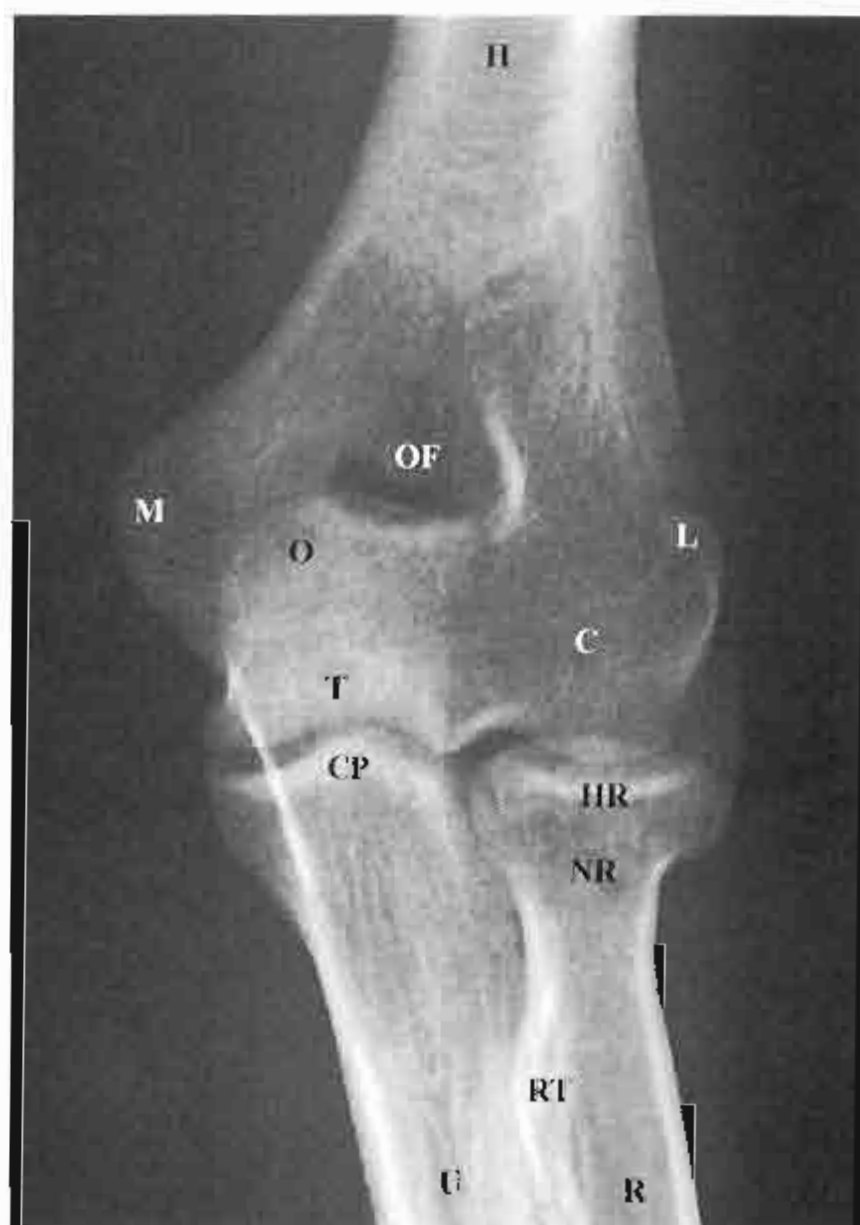

侧位X线平片

C	(肱骨)小头
CP	尺骨冠突
H	肱骨
HR	桡骨头
L	外上髁
O	(尺骨)鹰嘴
R	桡骨
T	滑车切迹
U	尺骨


前后位X线平片

C	(肱骨)小头
CP	尺骨冠突
H	肱骨
HR	桡骨头
L	外上髁
M	内上髁
NR	桡骨颈
O	(尺骨)鹰嘴
OF	鹰嘴窝
R	桡骨
T	肱骨滑车
RT	桡骨粗隆
U	尺骨






运动科学网站



运动科学网站



运动科学网站



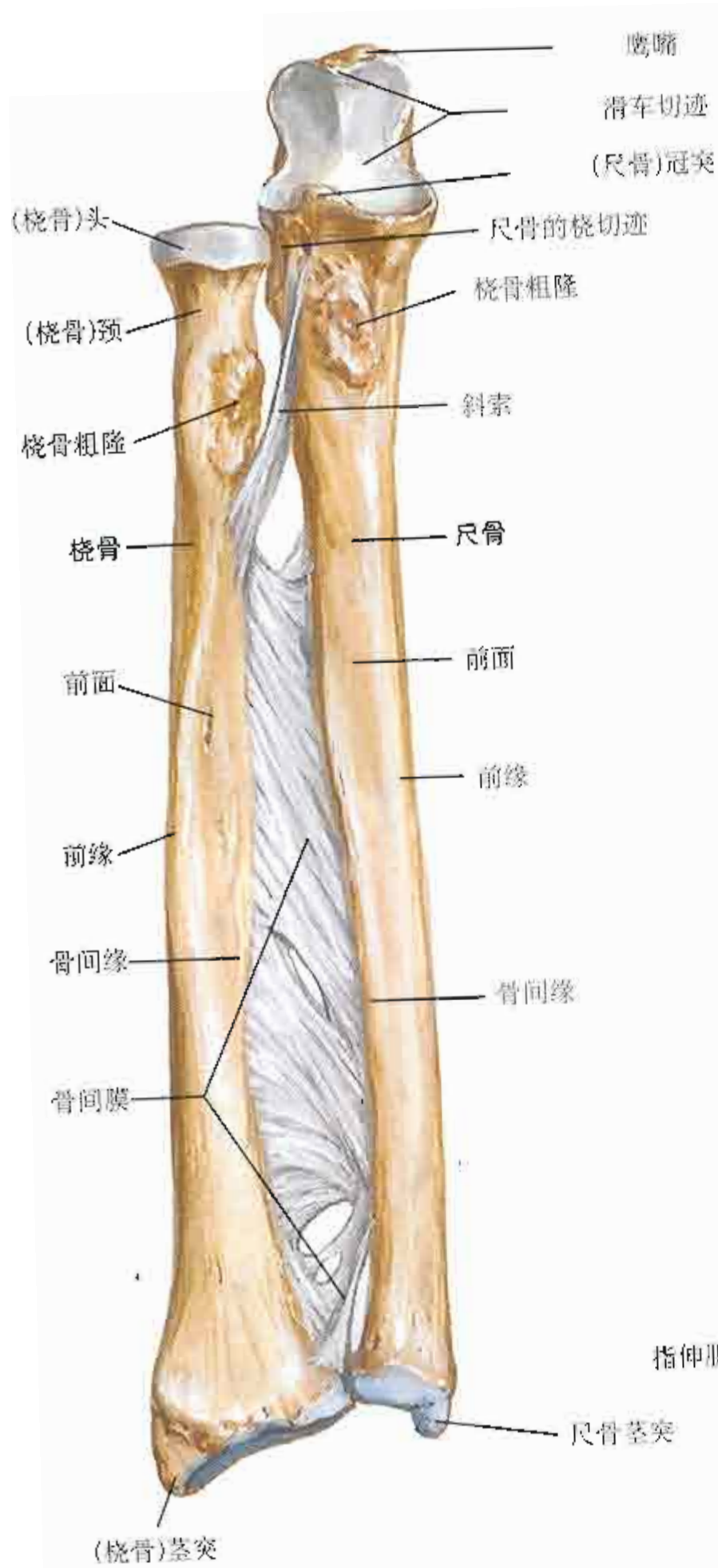
运动科学网站



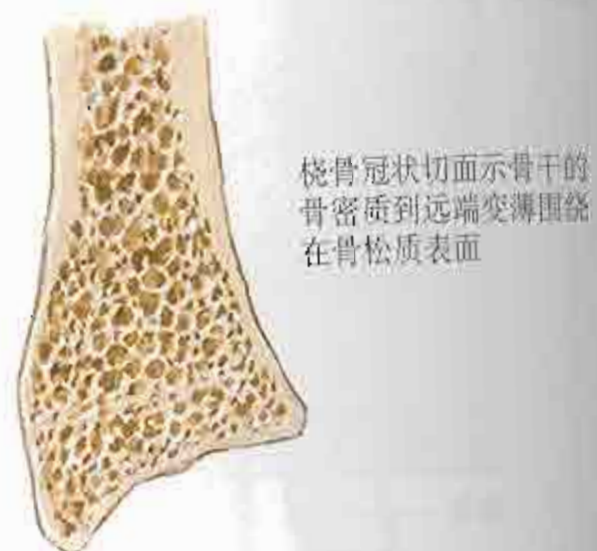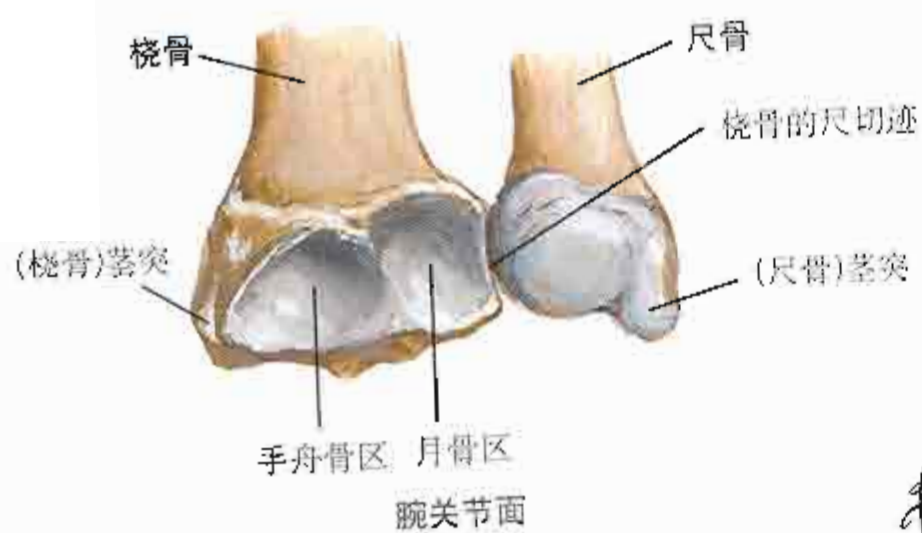
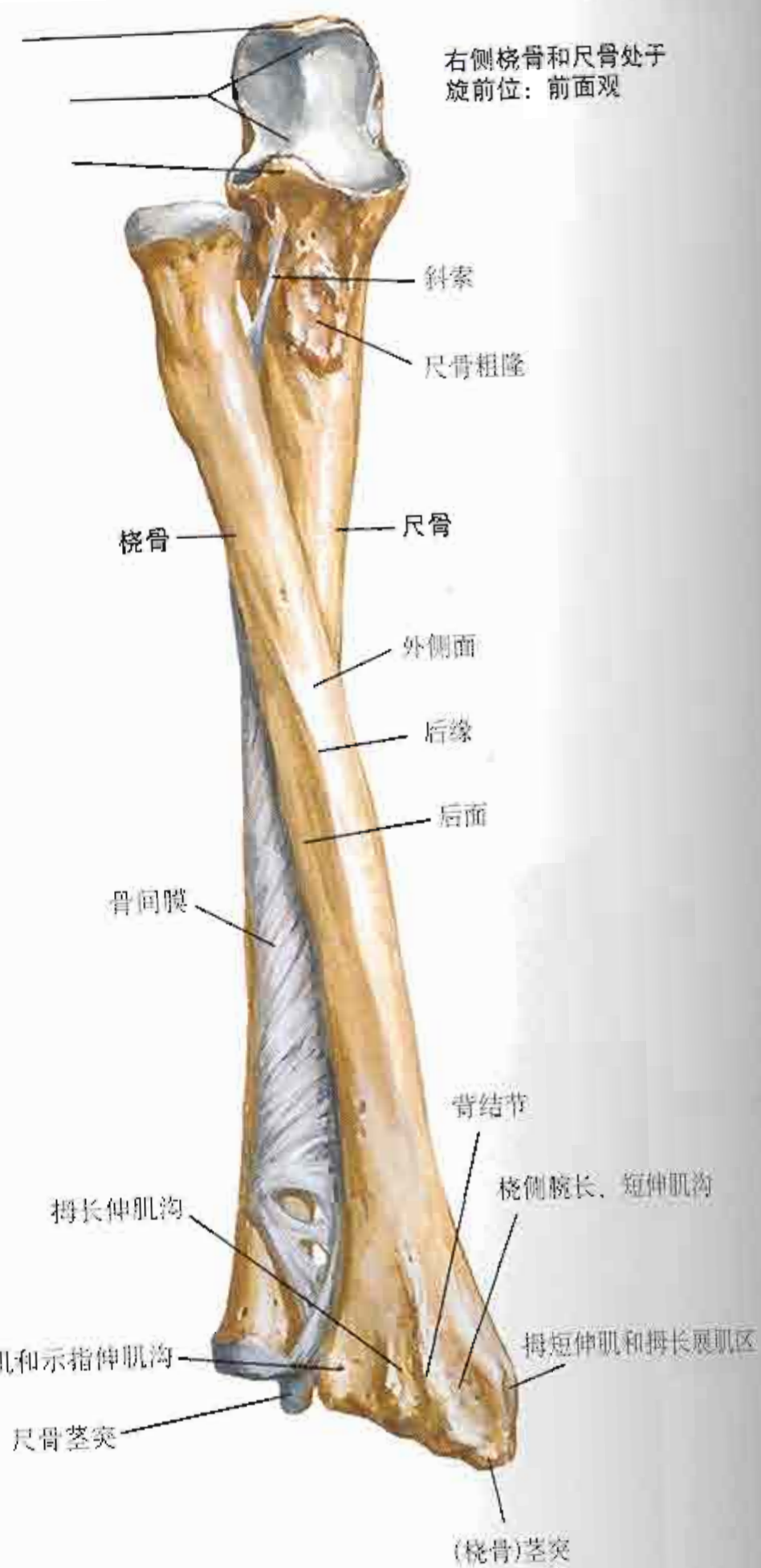
运动科学网站

前臂骨

右侧桡骨和尺骨处于旋后位：前面观



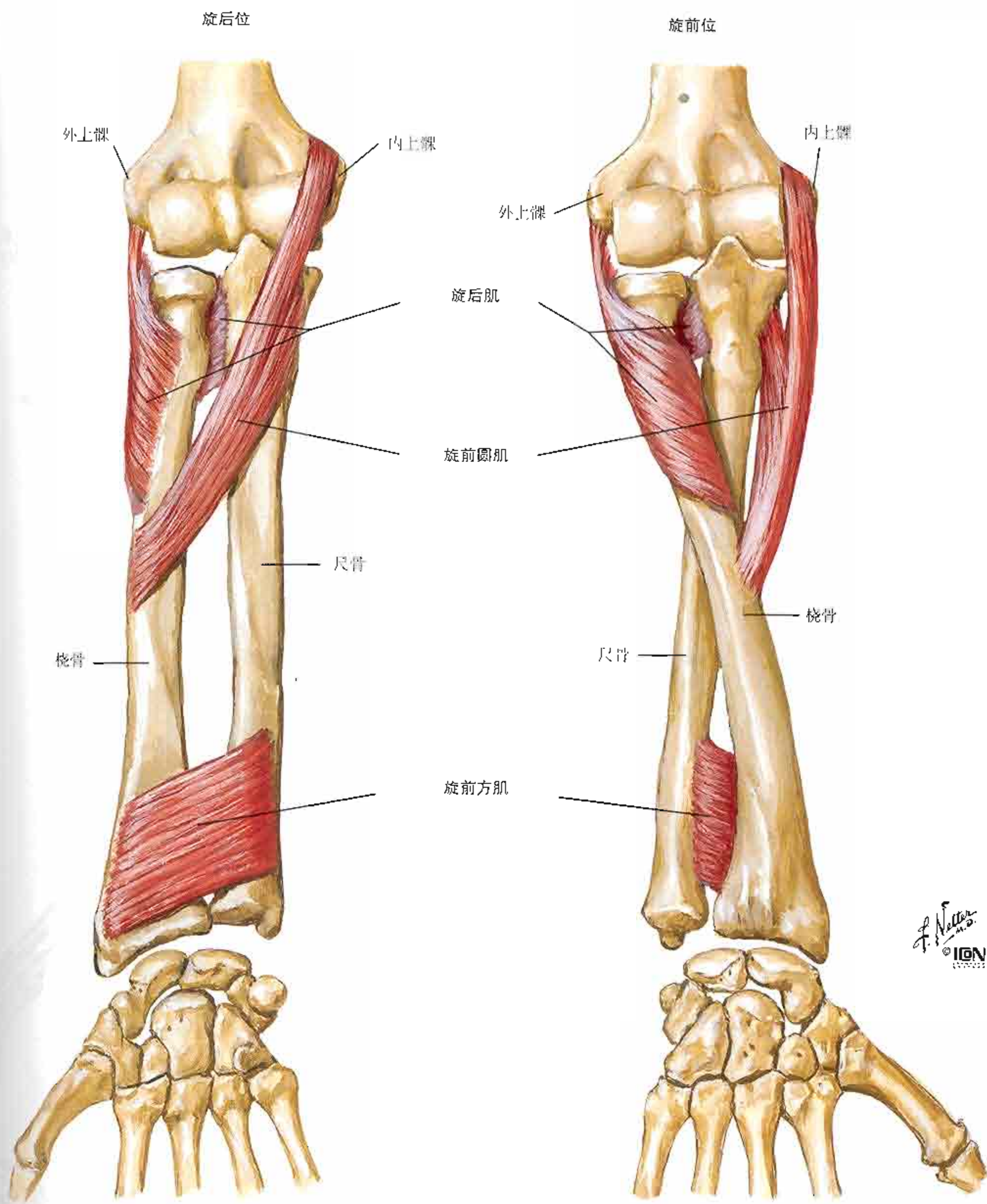
右侧桡骨和尺骨处于旋前位：前面观



上肢

图422

右侧前臂：前面观



F. Netter M.D. ION

前臂肌：伸腕和伸指肌

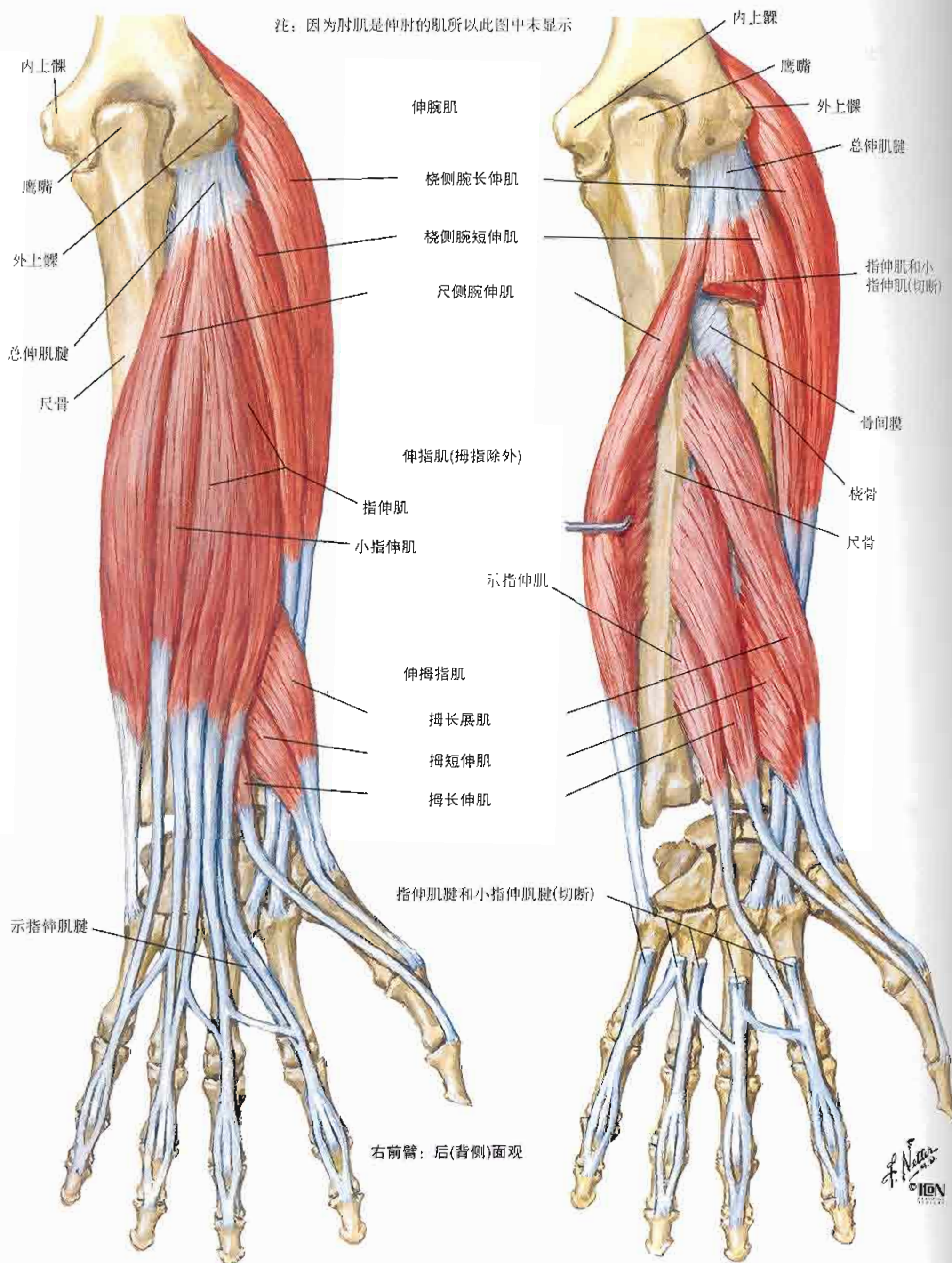
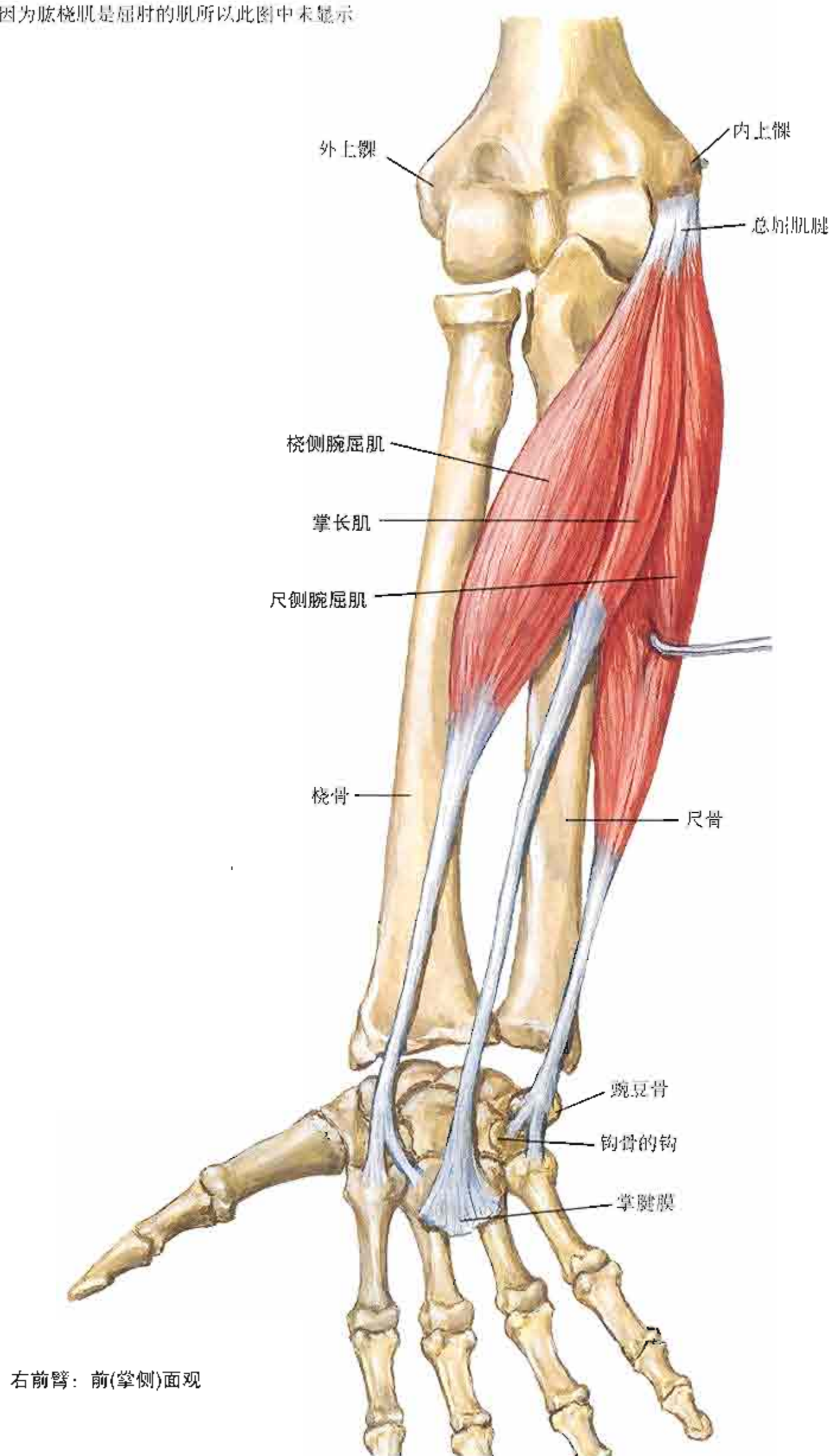


图424

注：因为肱桡肌是屈肘的肌所以此图中未显示



F. Netter M.D.
© IGM

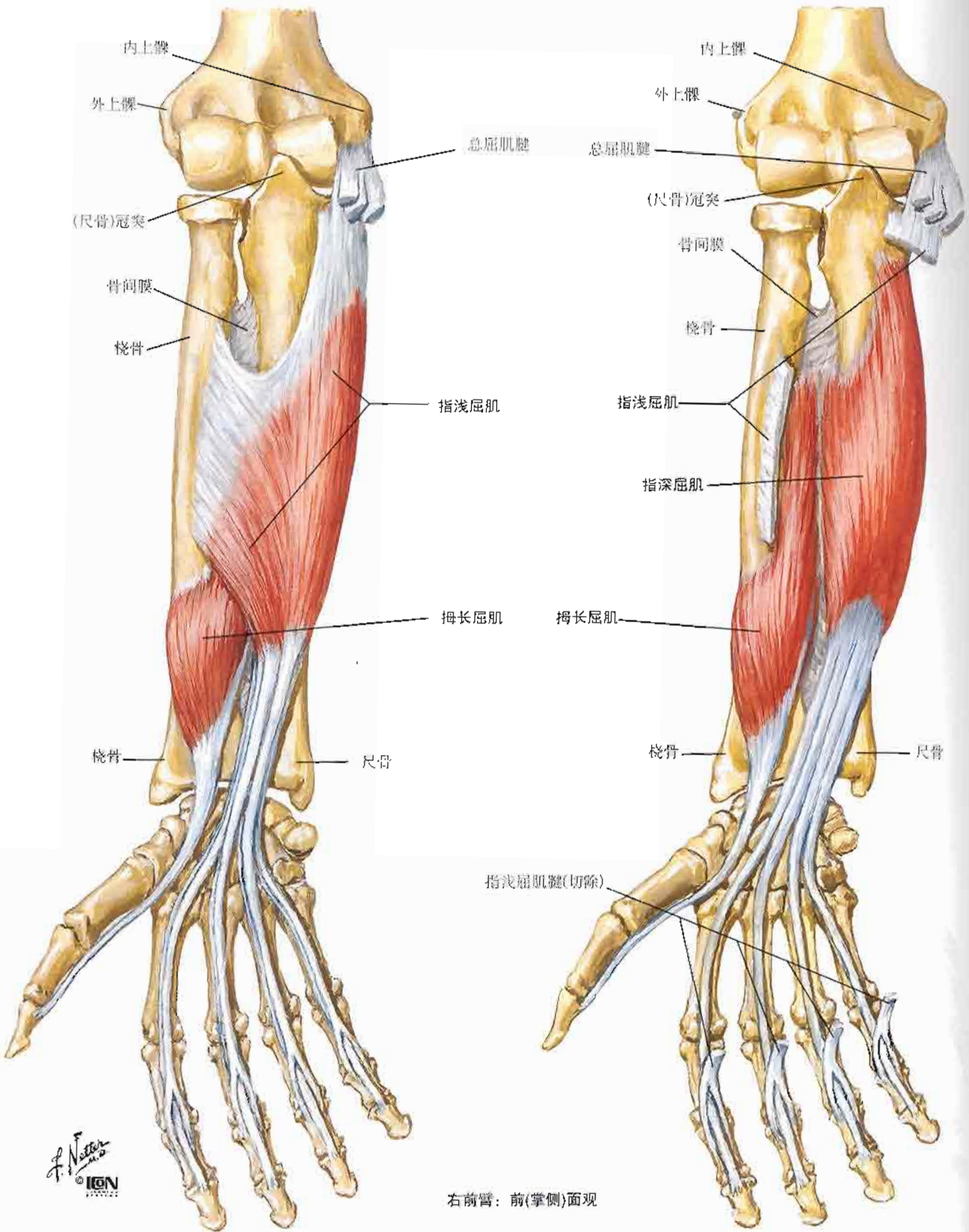
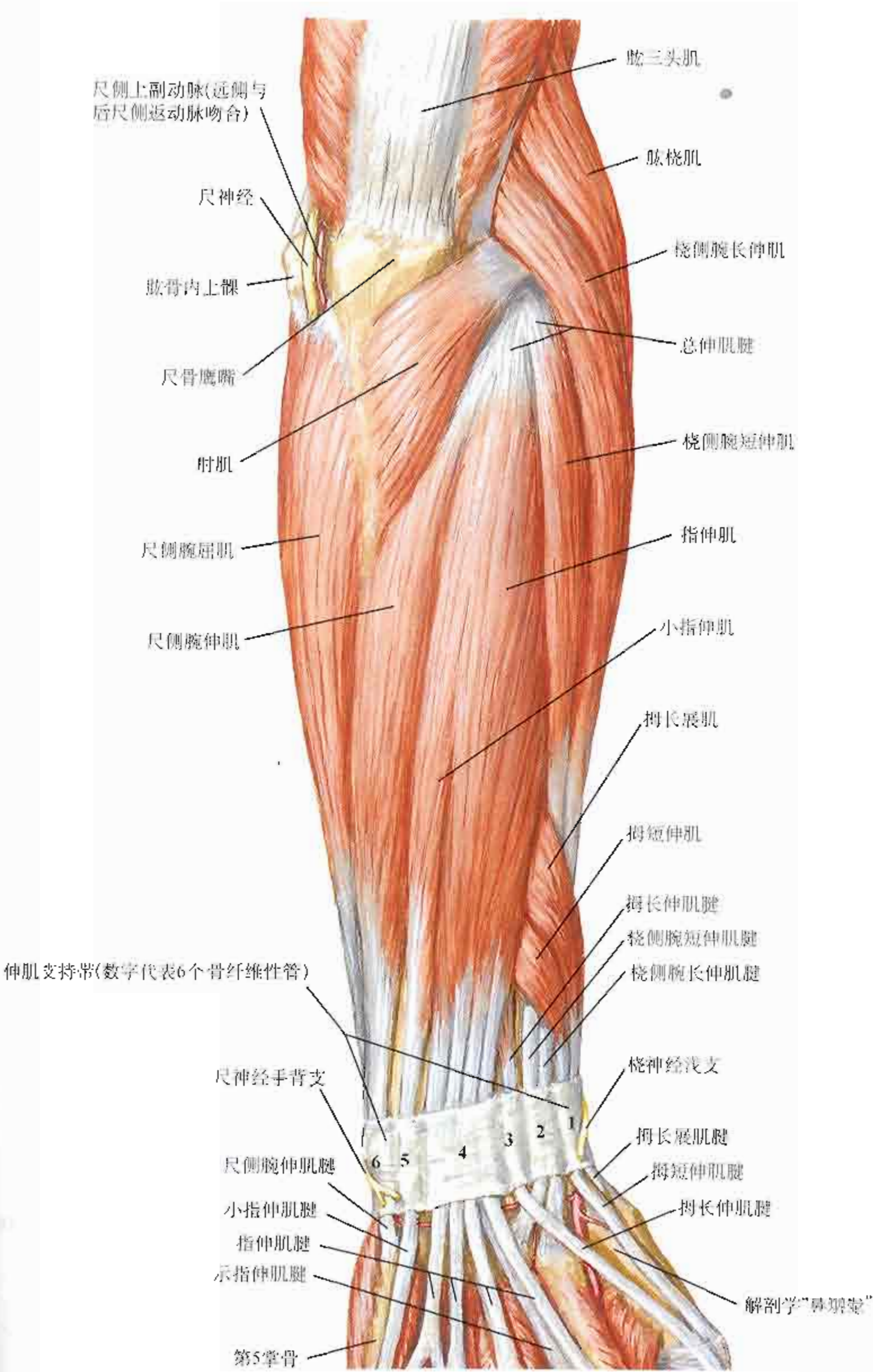


图426

参见图453、461



F. Netter M.D.
© 1997

前臂肌(深层): 后面观

参见图453、461

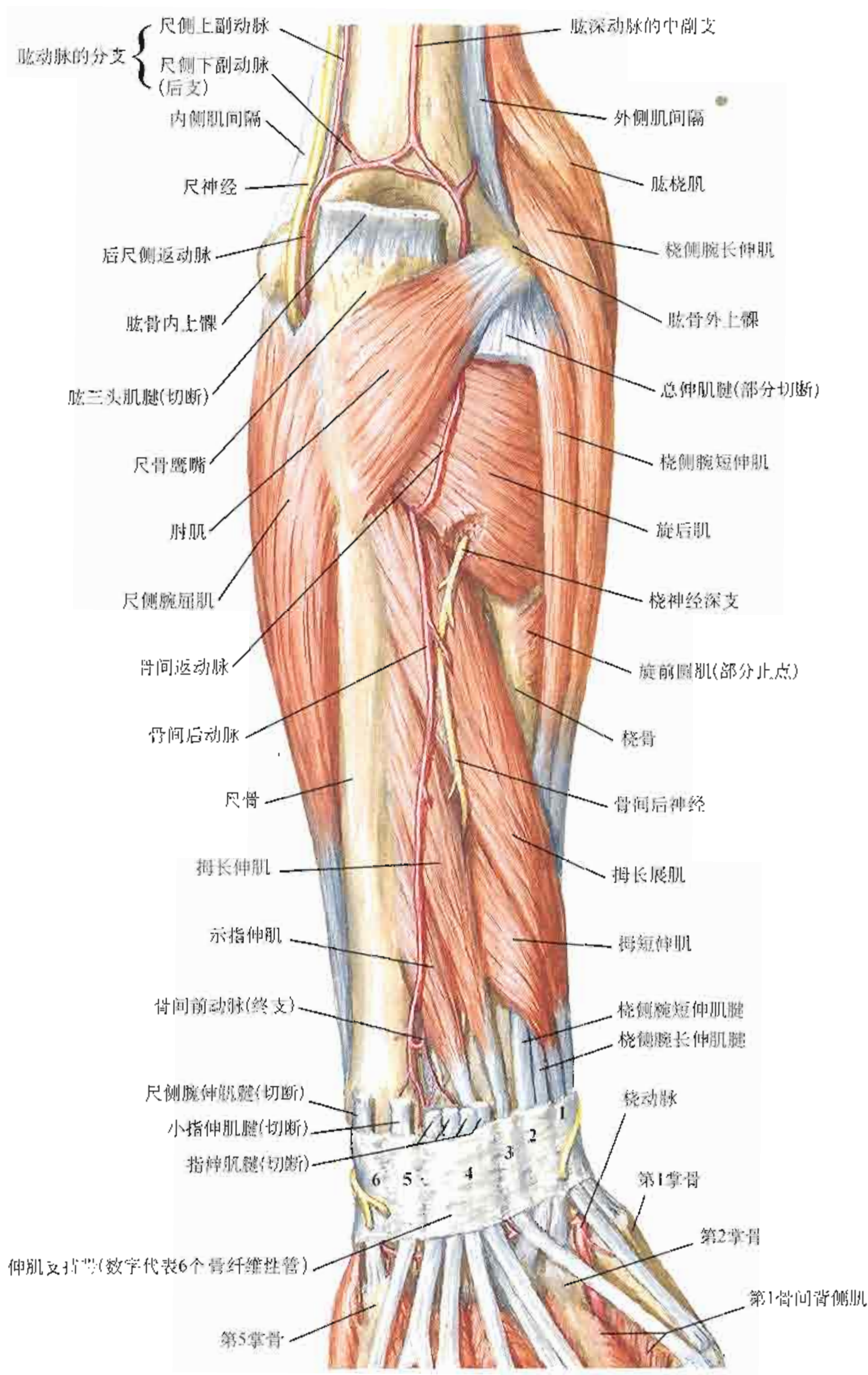
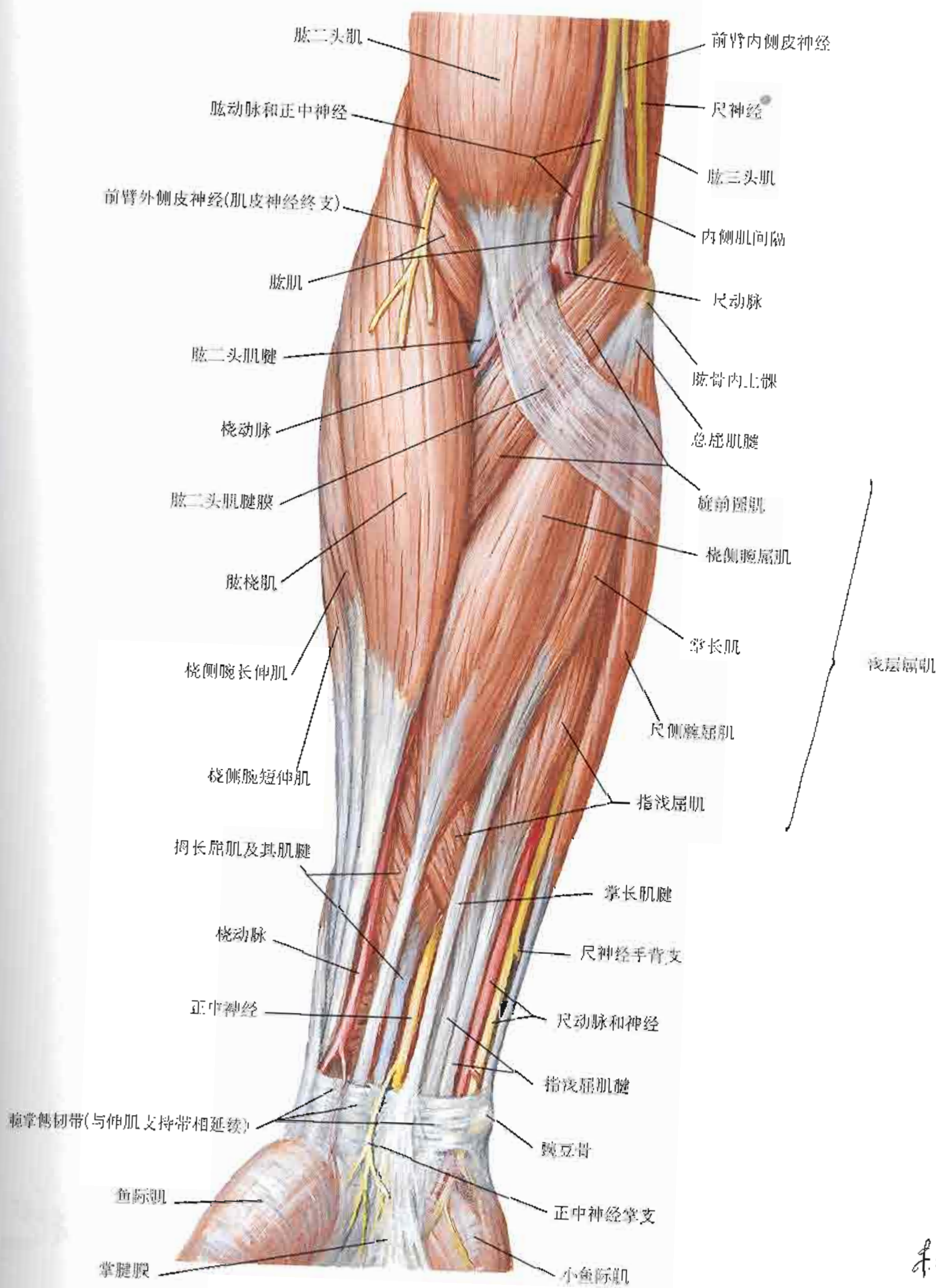


图428

参见图458、459

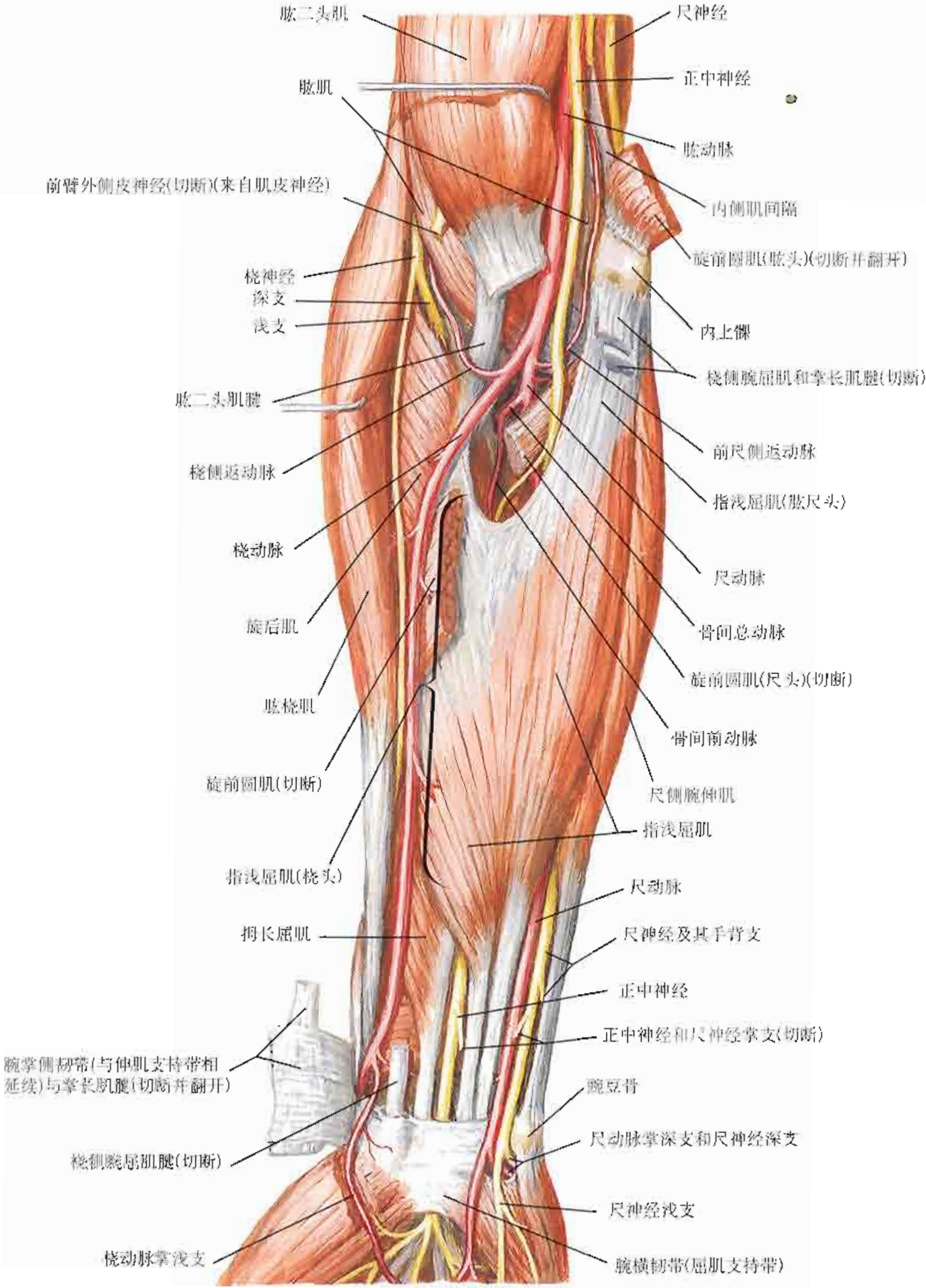


F. Netter M.D.
© IGM

图429

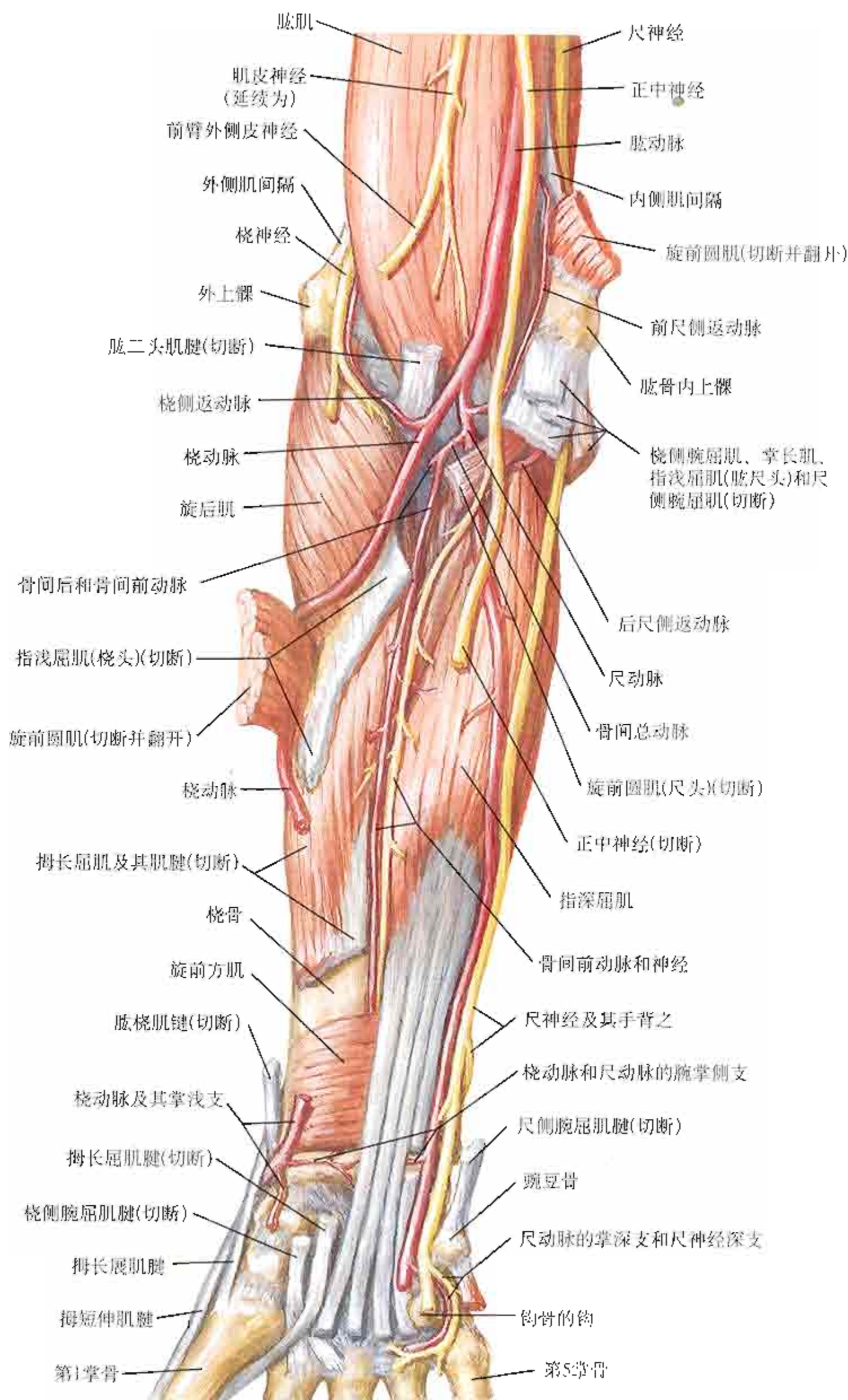
前臂肌(中层): 前面观

参见图458、459



F. Netter M.D.
© 2003

图430



F. Netter M.D.
© ION

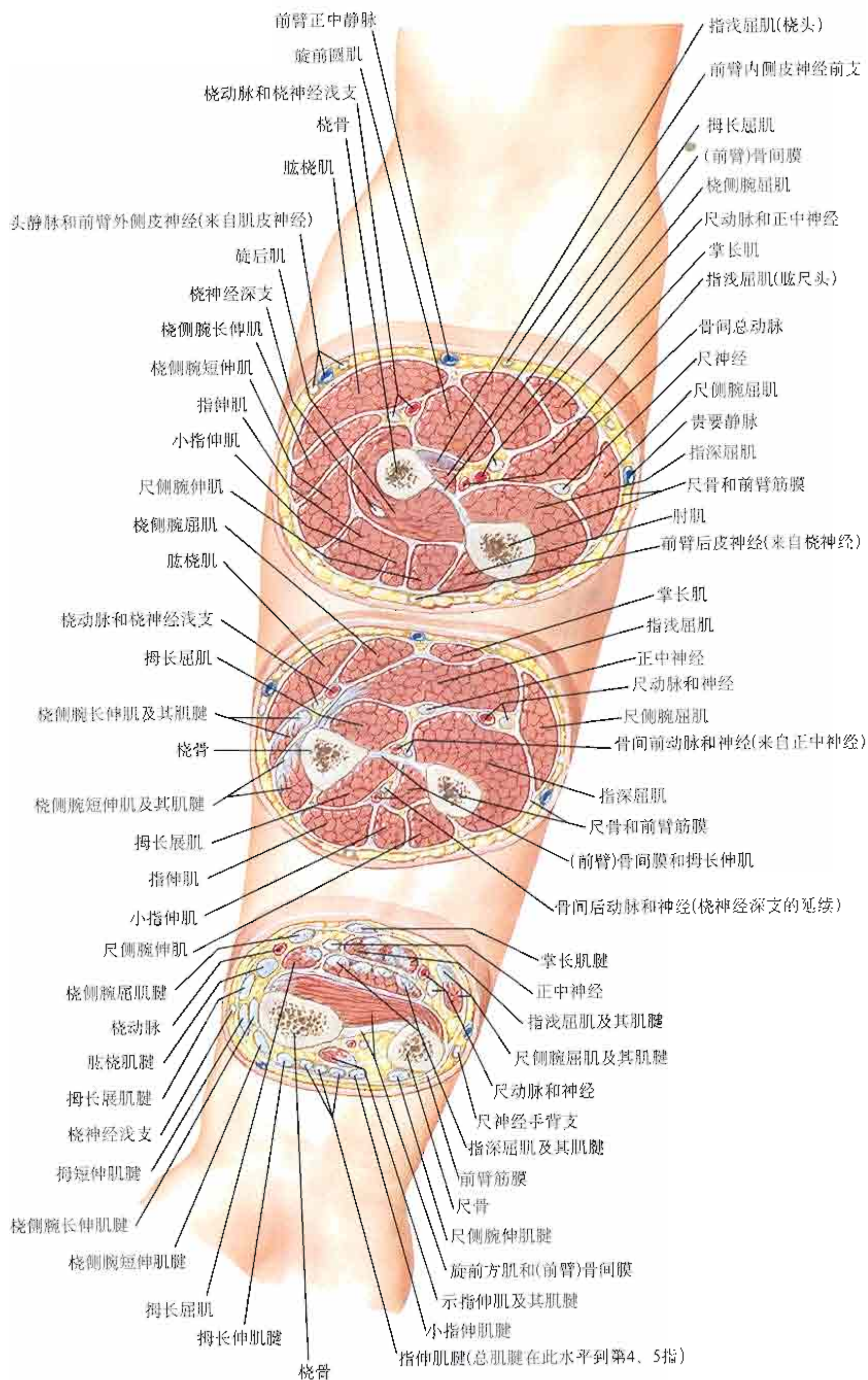
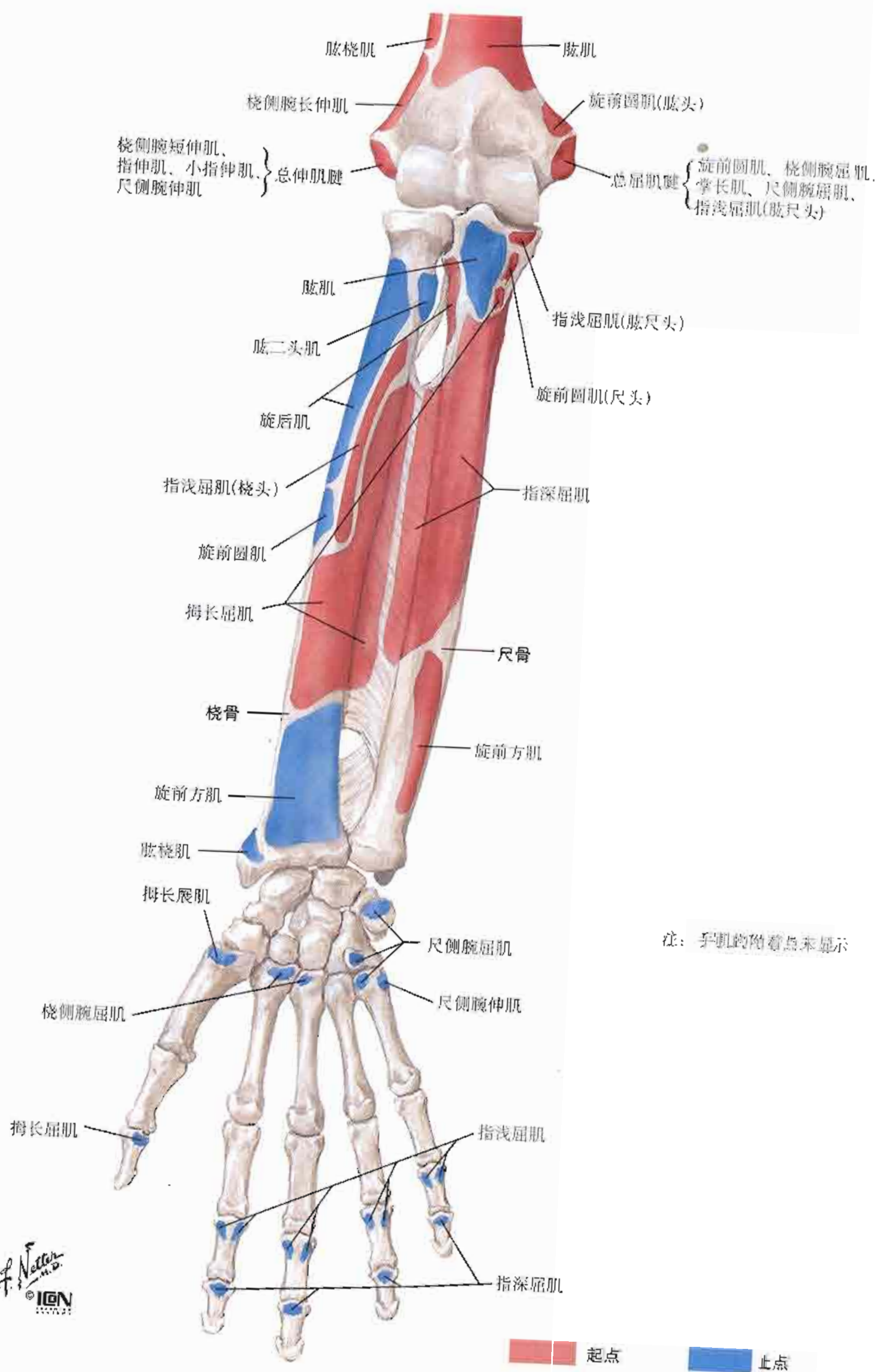


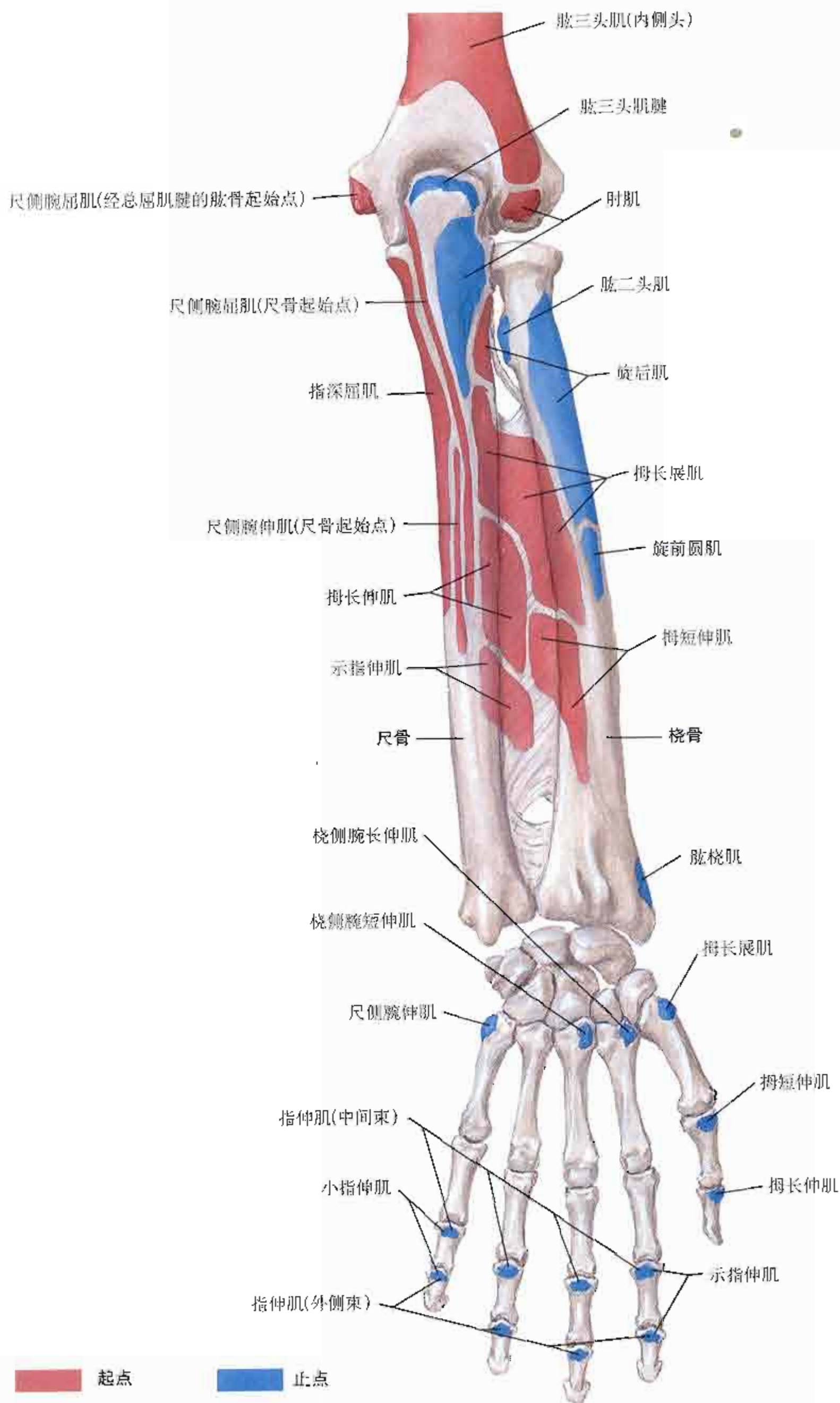
图432



注：手肌的附着点未显示

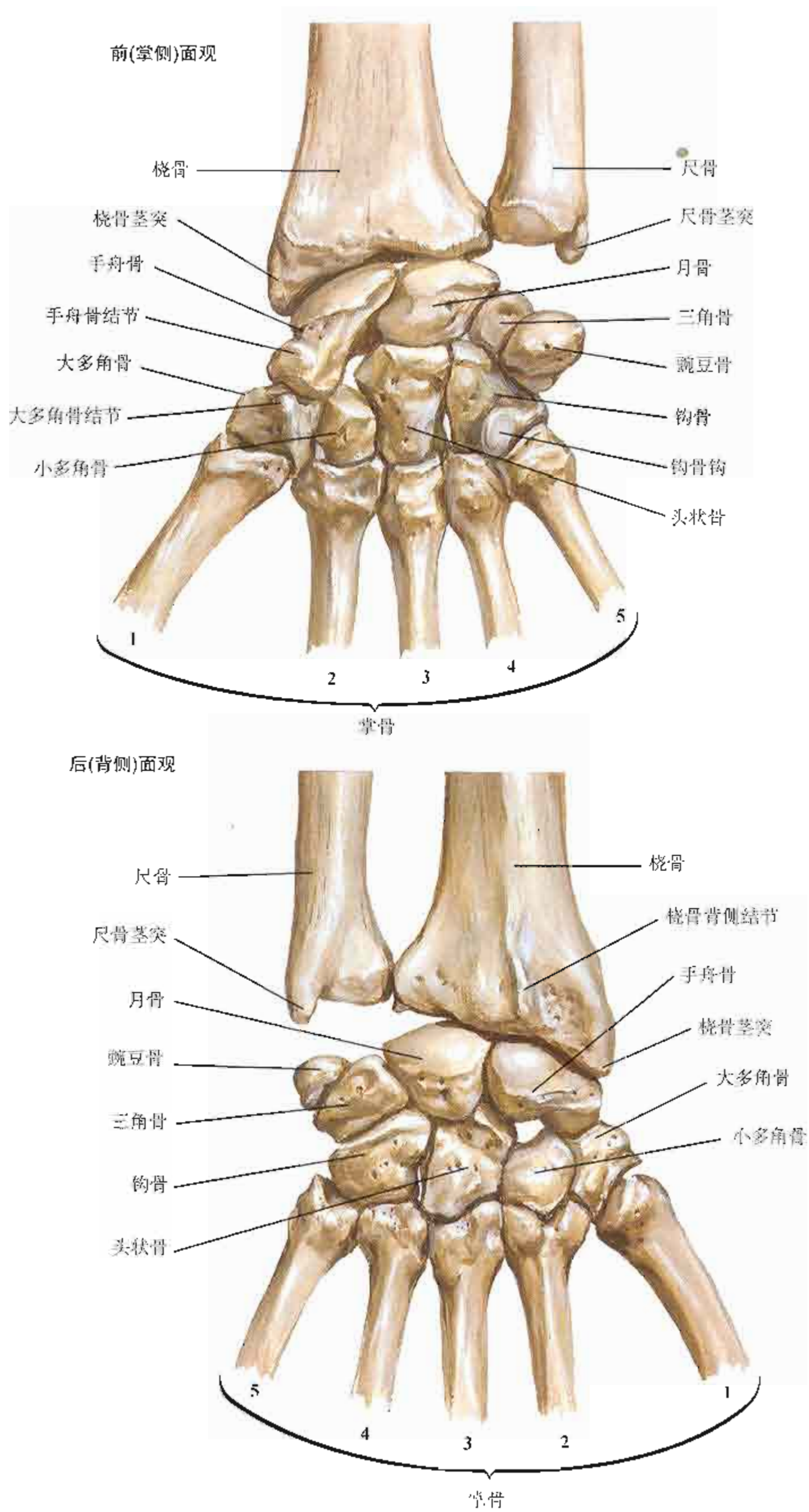
前臂肌附着点：后面观

注：手肌附着点未显示



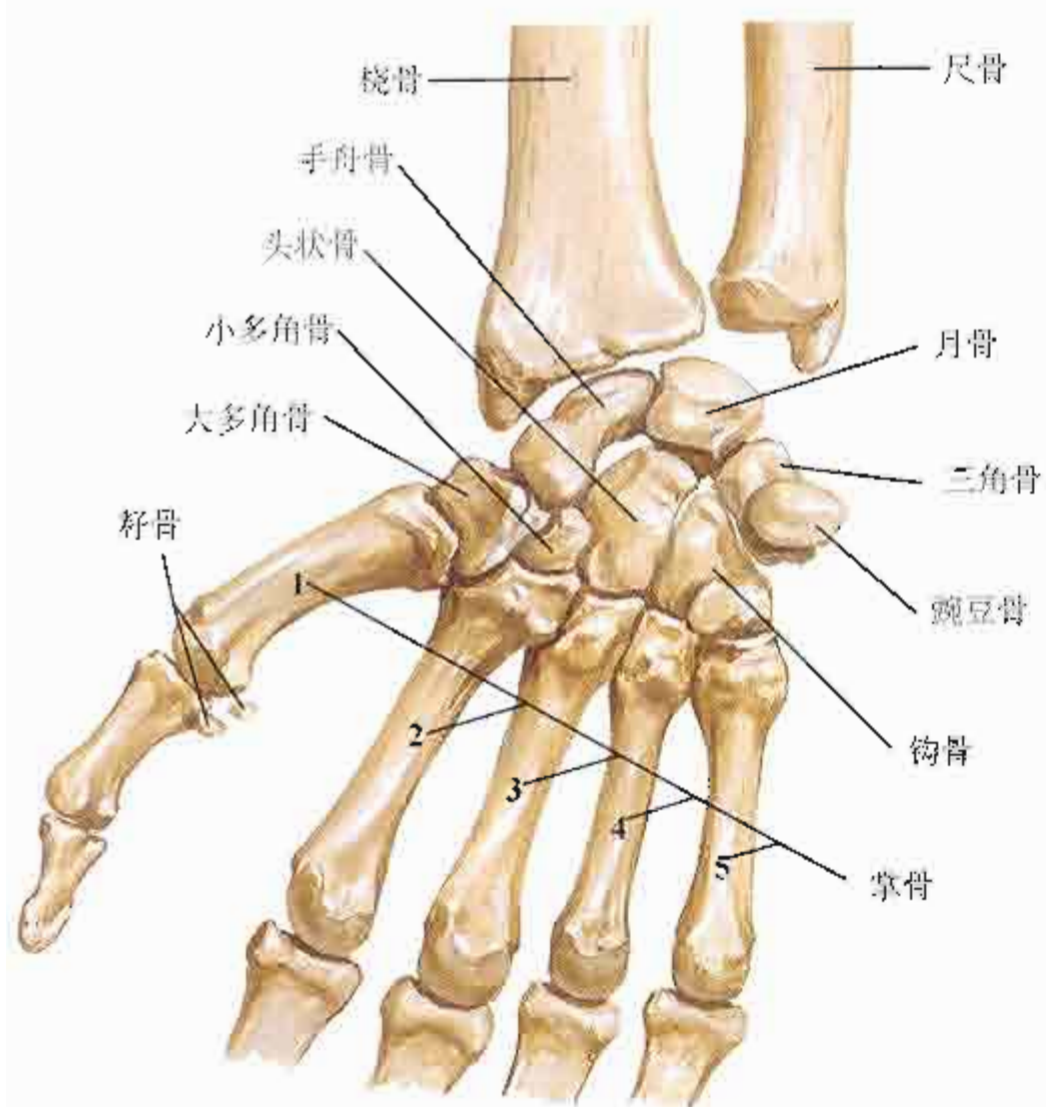
F. Netter M.D. ILLUSTRATIONS

图434

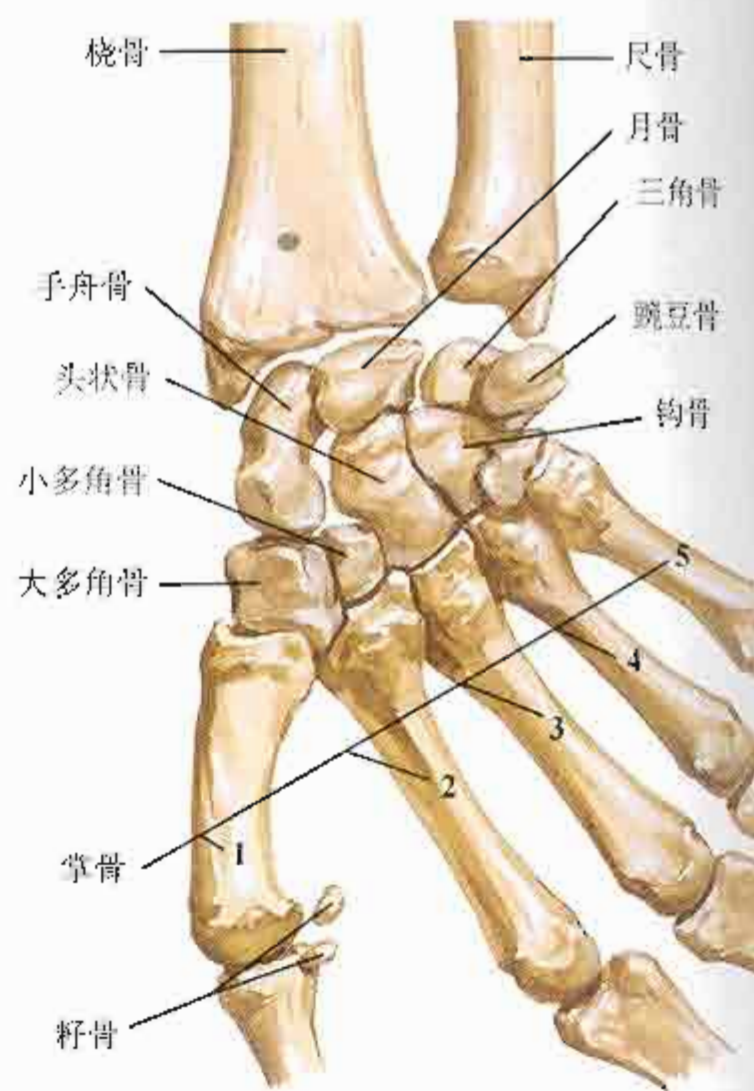

F. Netter M.D.
© IGM
1997

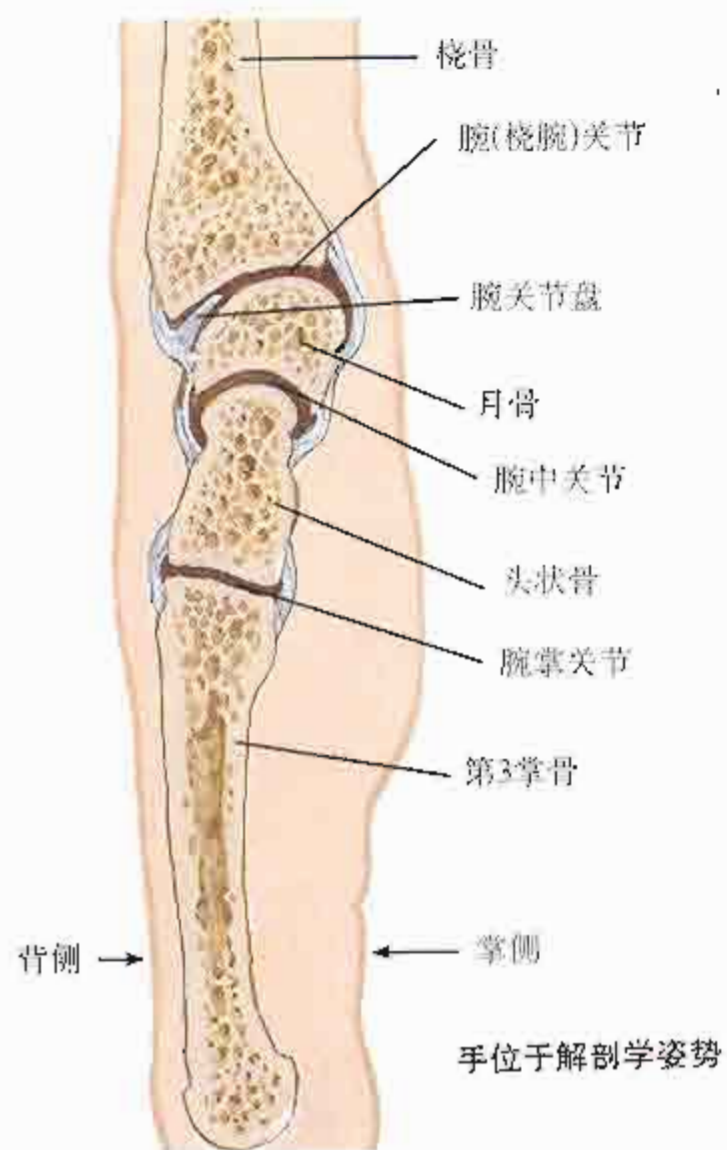
腕关节的运动



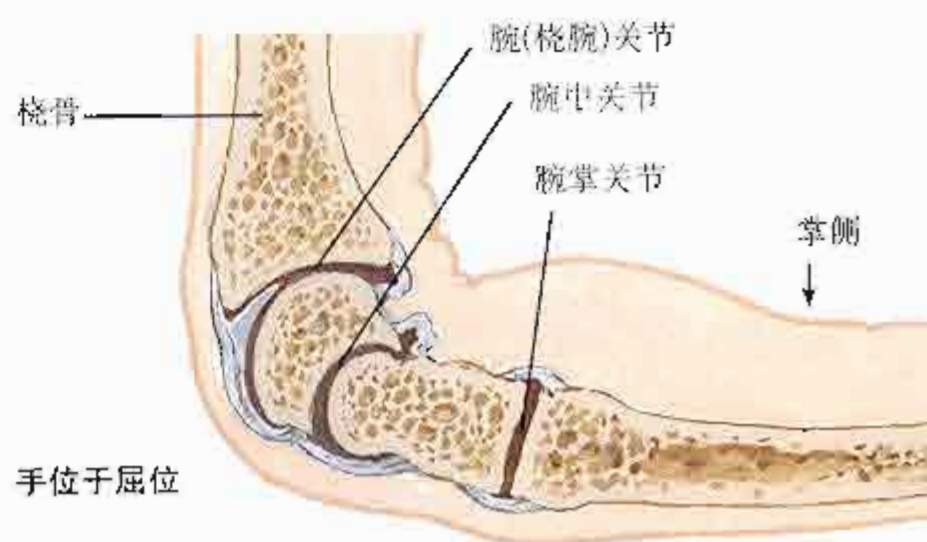
手外展时腕骨的位置：前(掌侧)面观



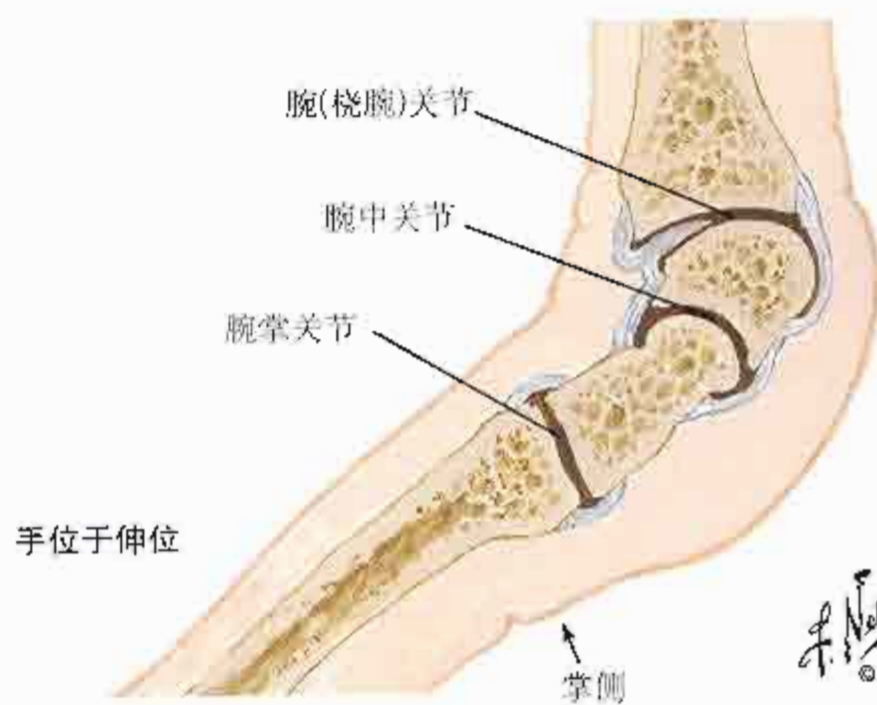
手内收时腕骨的位置：前(掌侧)面观



经腕和中指的矢状断面

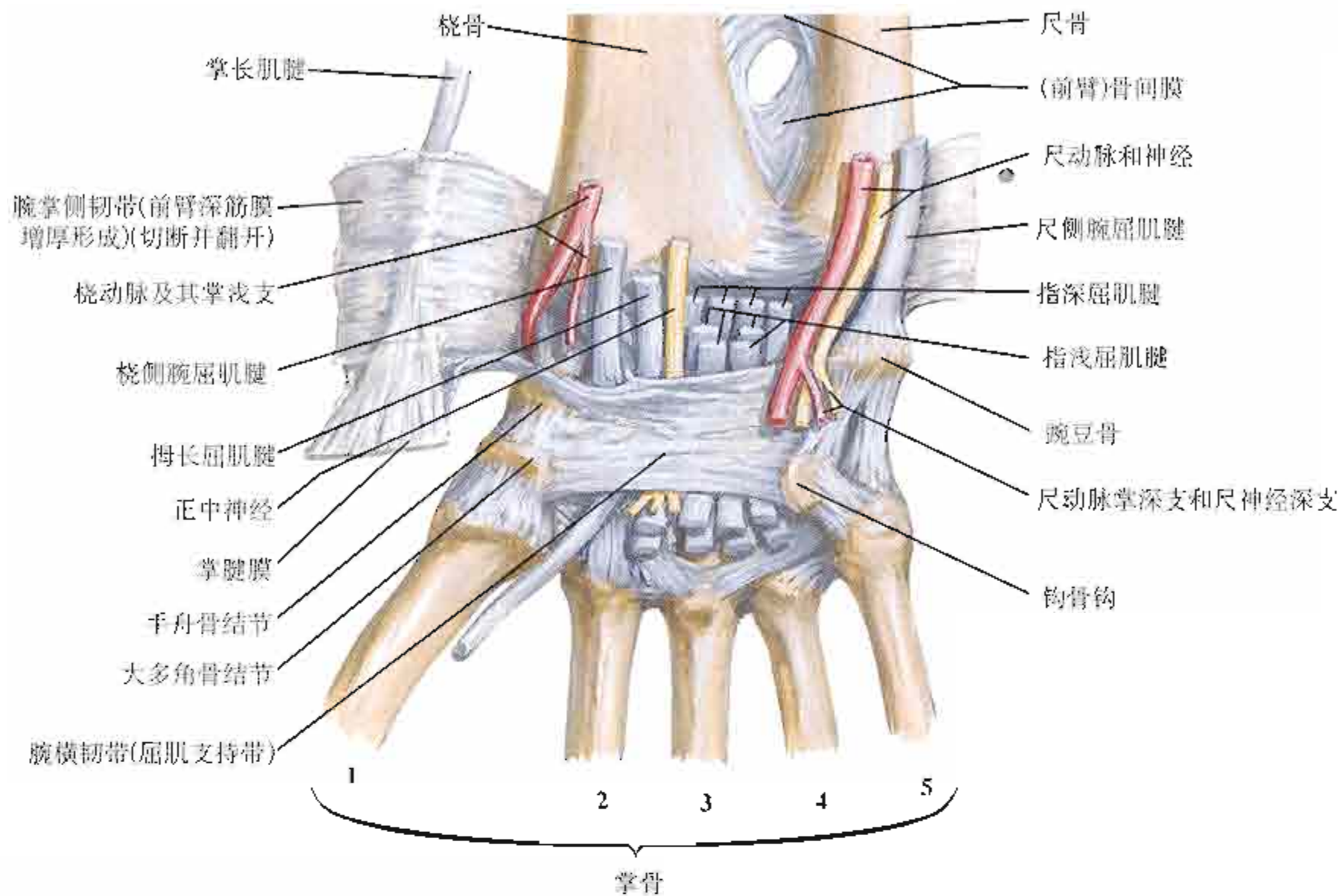


手位于屈位

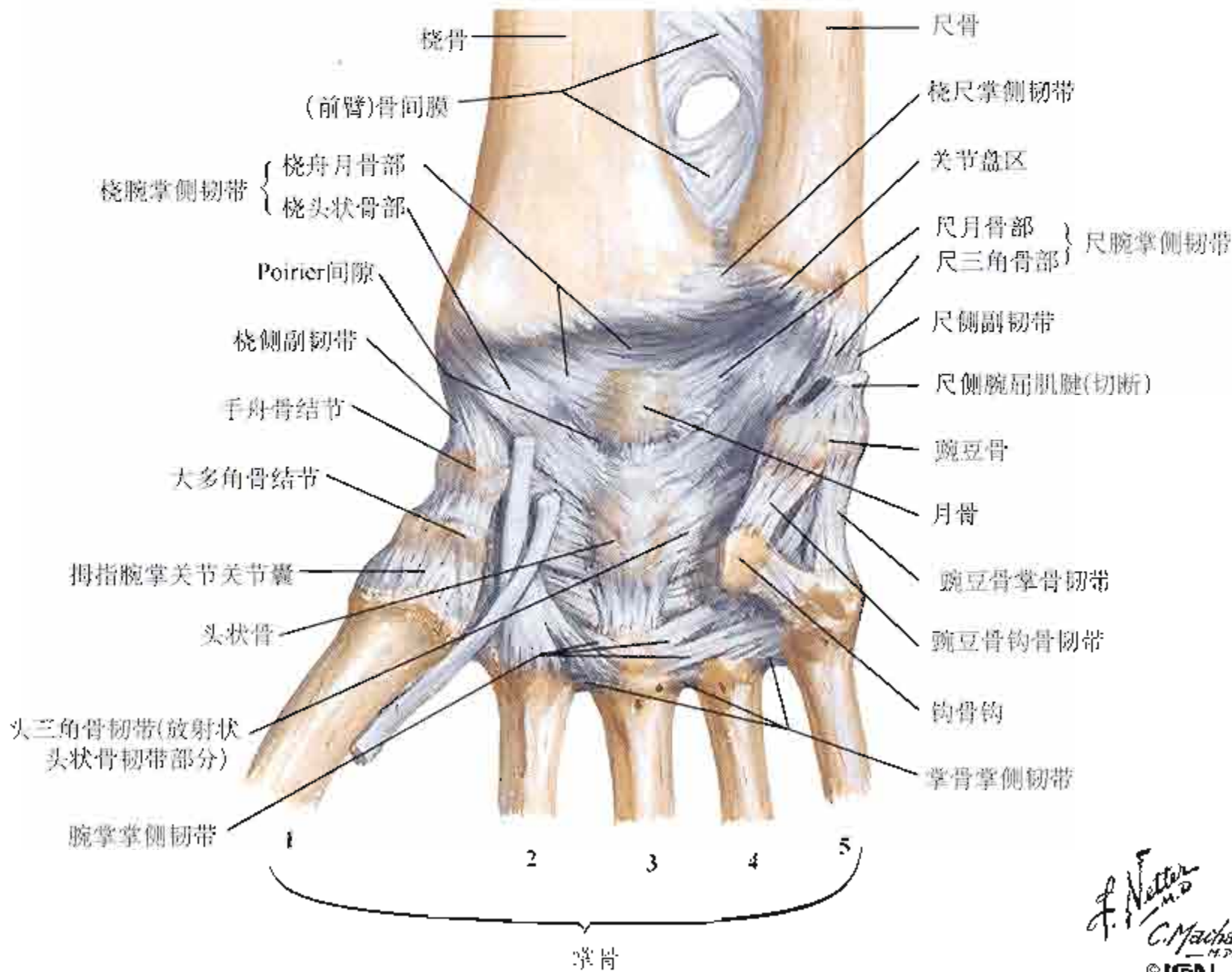


手位于伸位

腕管：掌侧面观



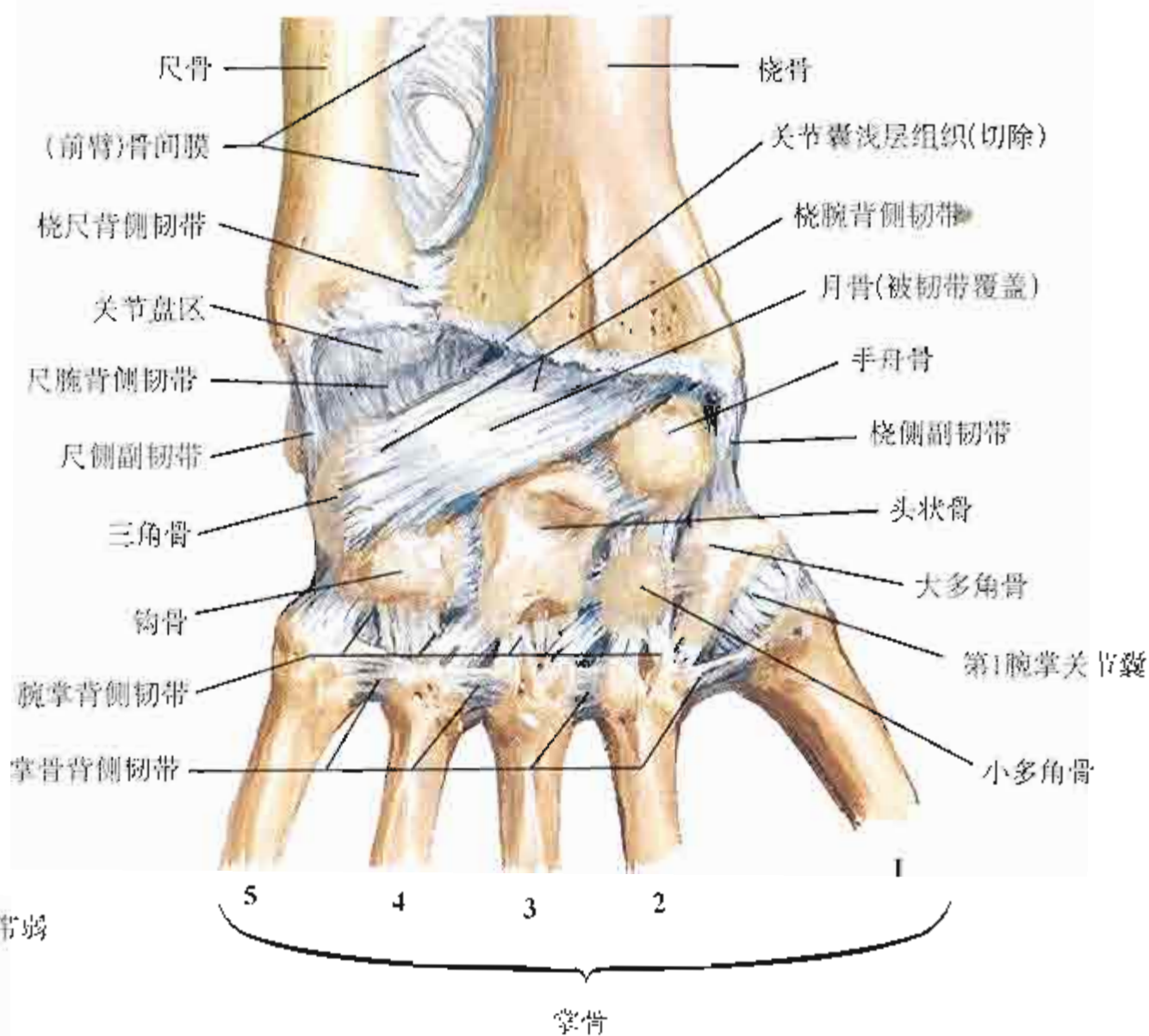
切除屈肌支持带：掌侧面观



F. Netter M.D.
C. Machado M.D.
© IGM

腕部的韧带(续)

后(背侧)面观



注: 背侧韧带比掌侧韧带弱

冠状切面: 背侧面观

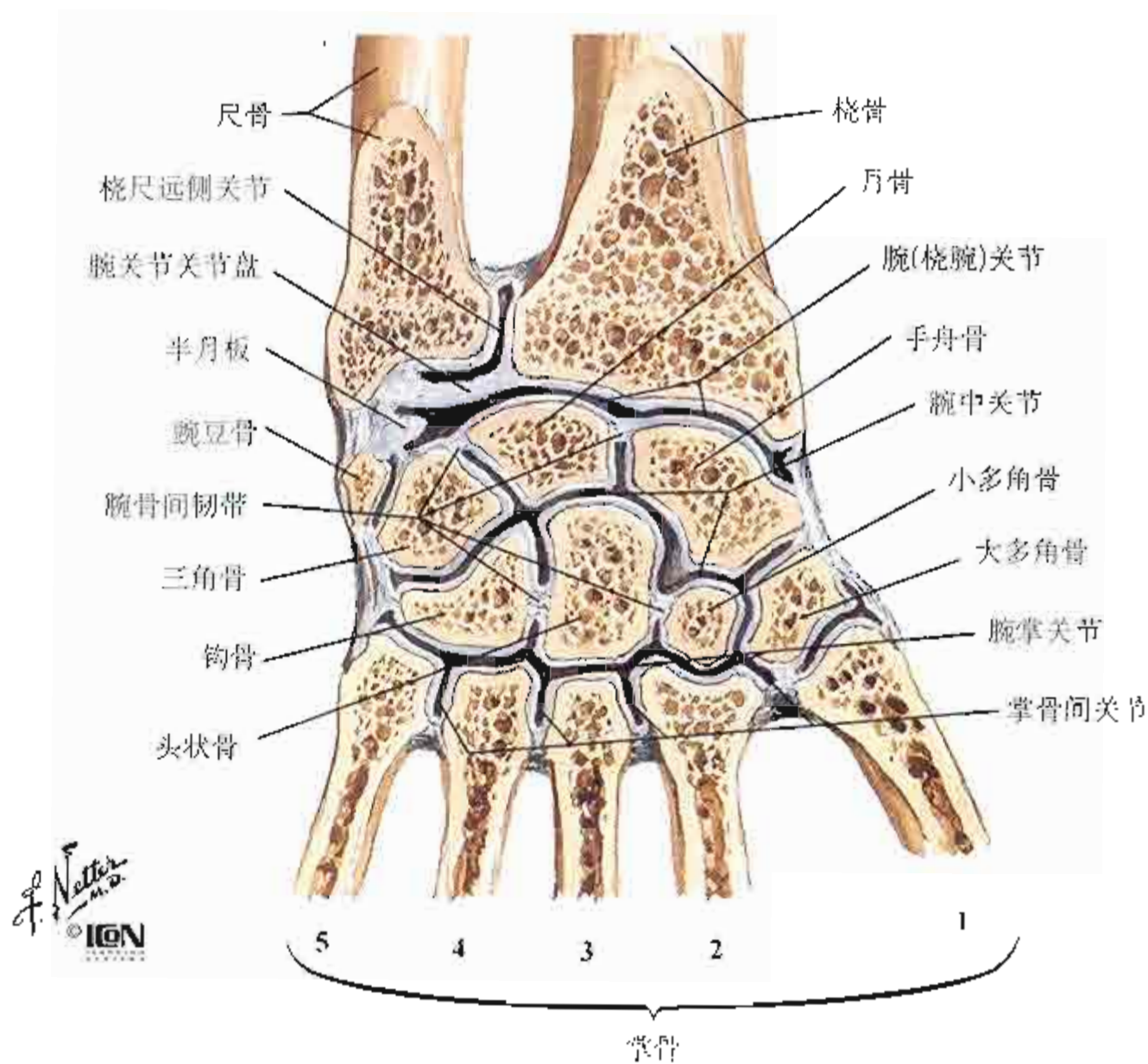
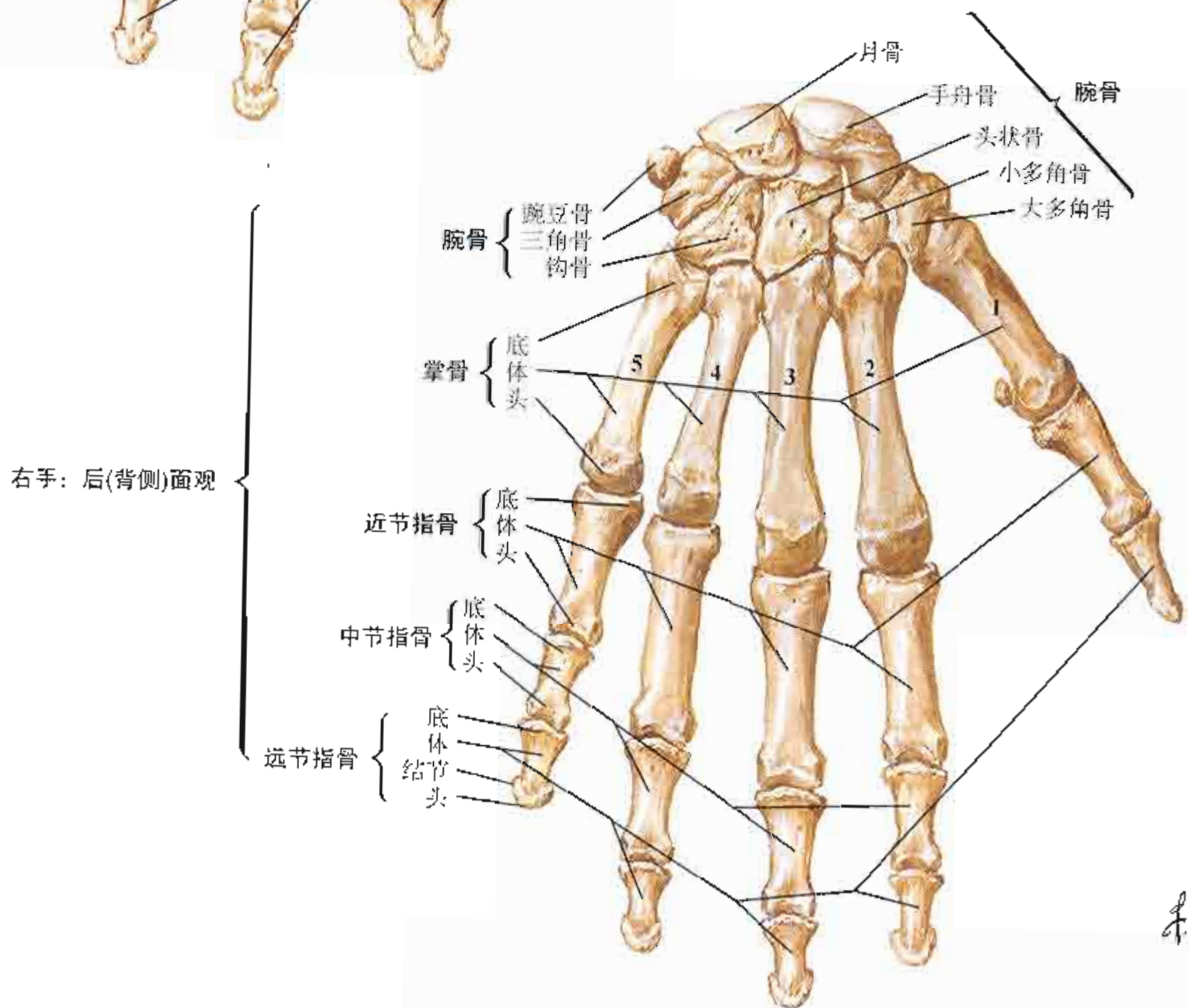
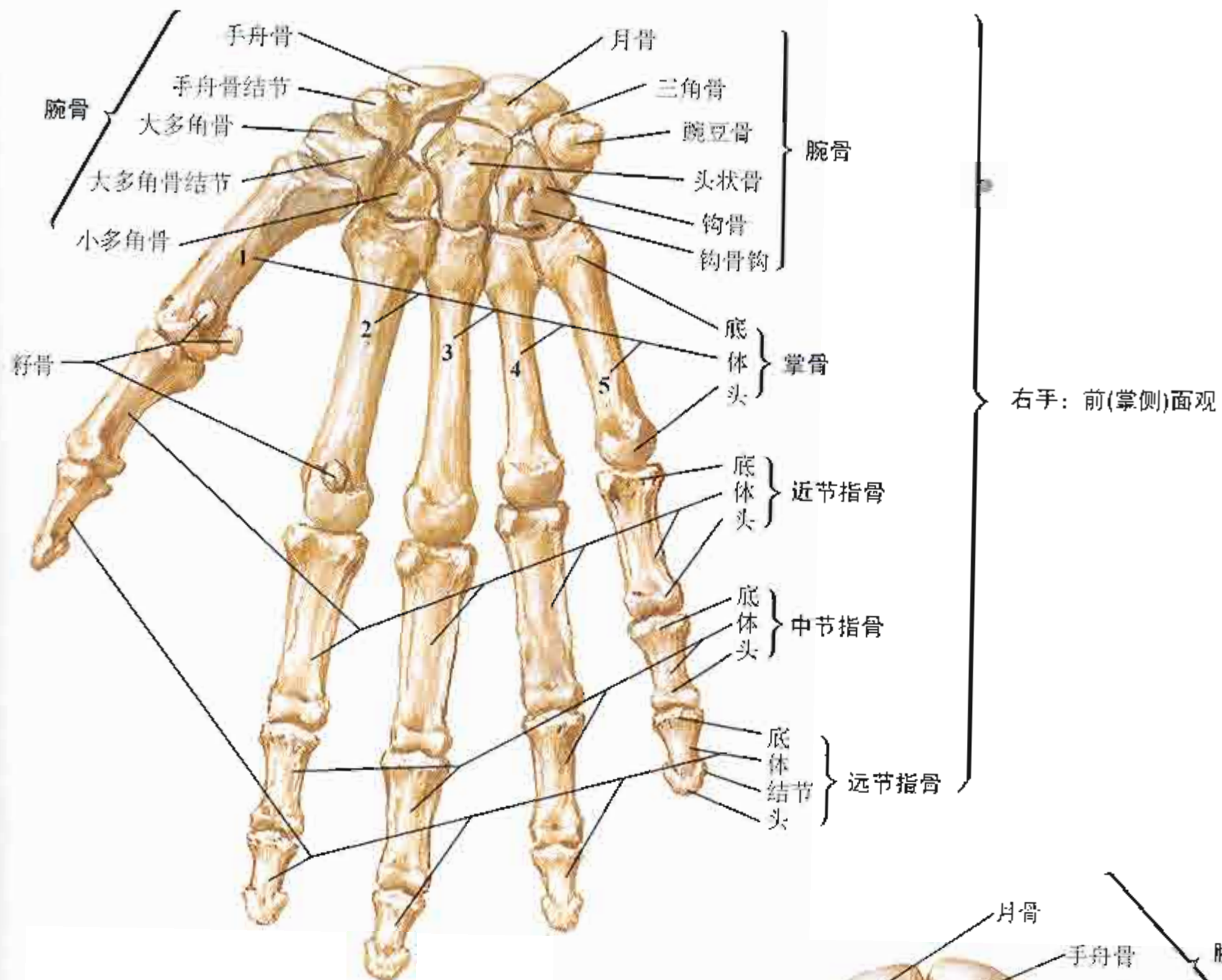


图438

上肢



F. Netter M.D.
© IGV



运动科学网站



运动科学网站



运动科学网站

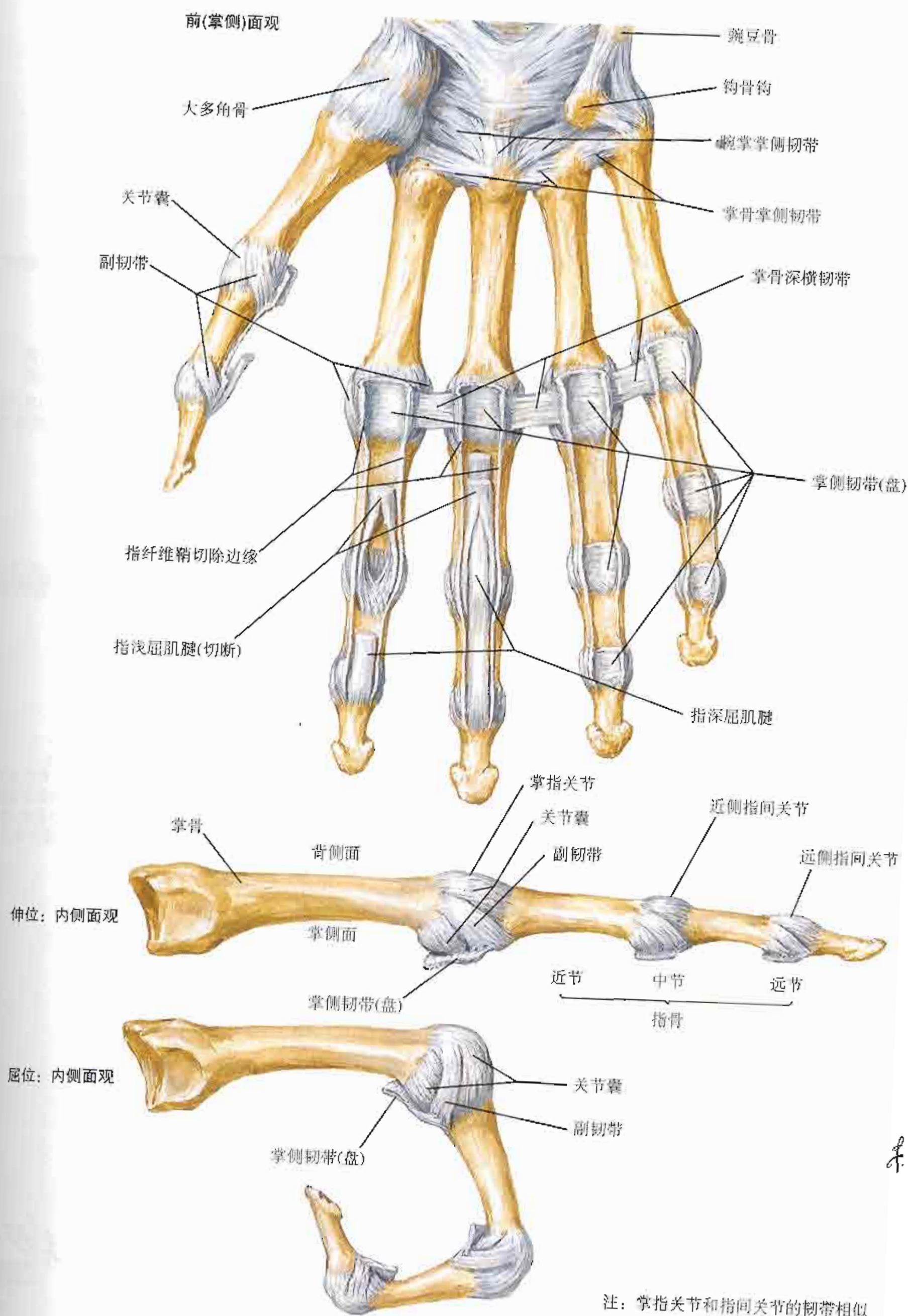


运动科学网站



运动科学网站

www.vo2maxcn.com



F. Netter M.D. IGV



运动科学网站



运动科学网站



运动科学网站

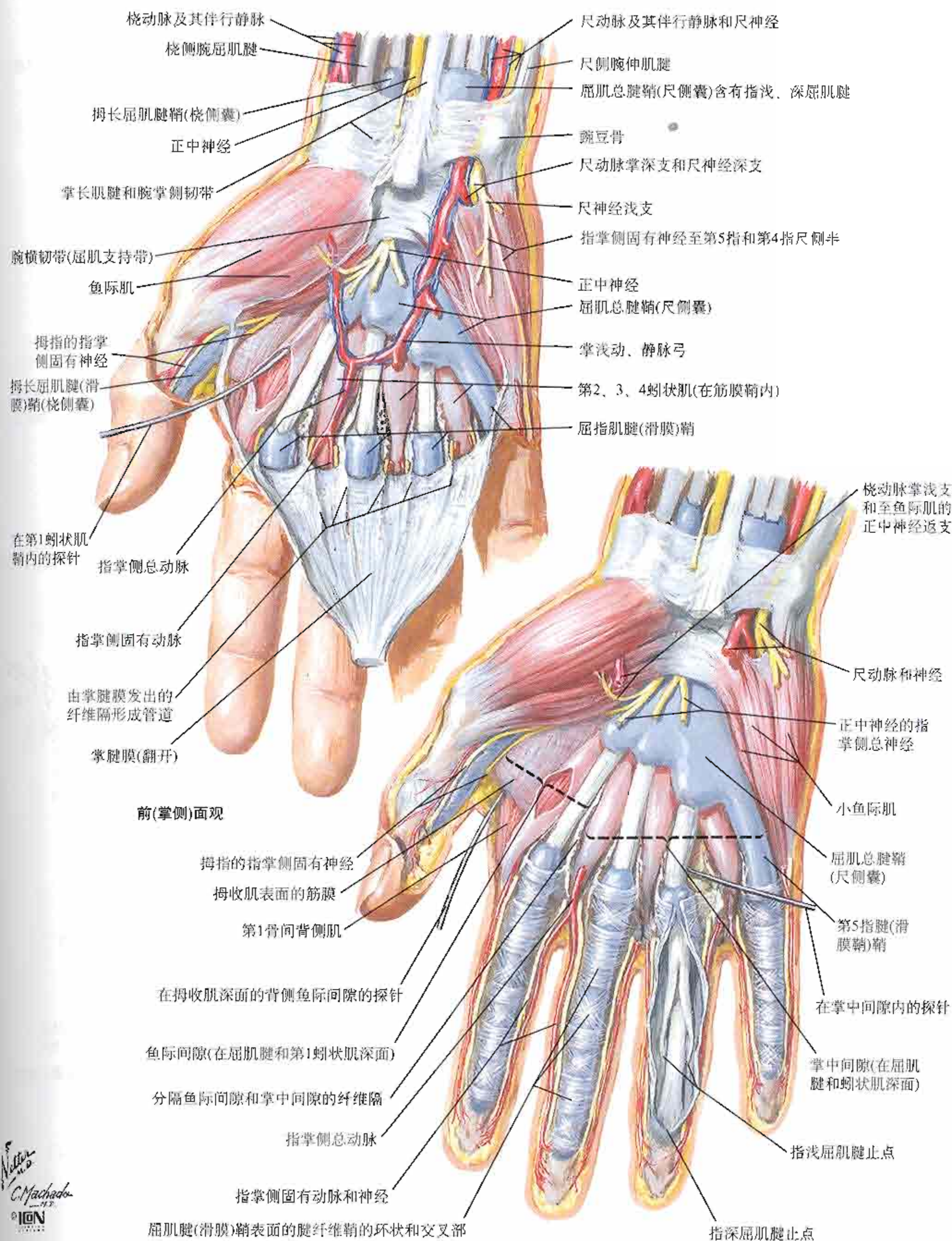


运动科学网站



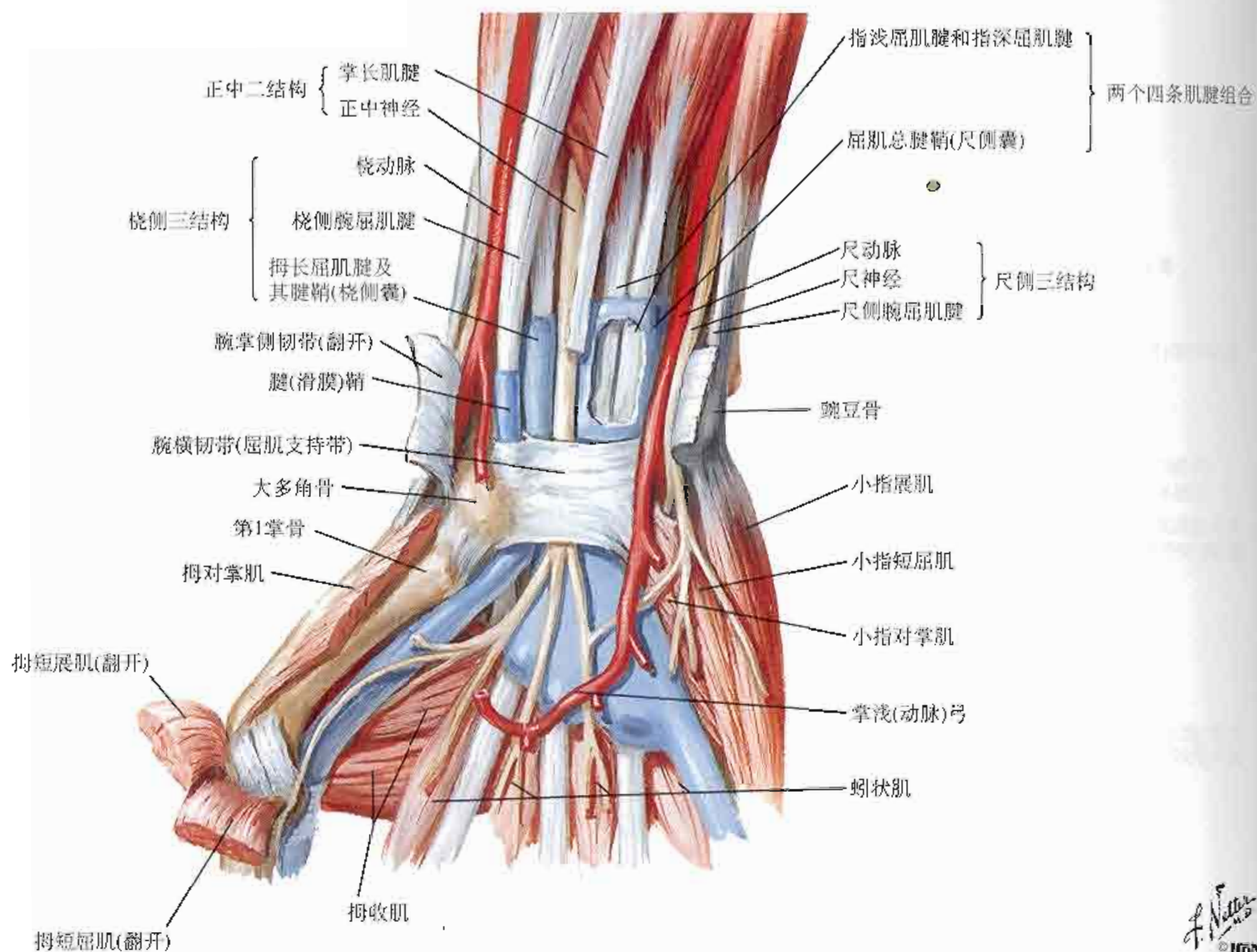
运动科学网站

www.vo2maxcn.com



腕部的屈肌腱、动脉和神经

掌侧面观



腕部横断面显示腕管

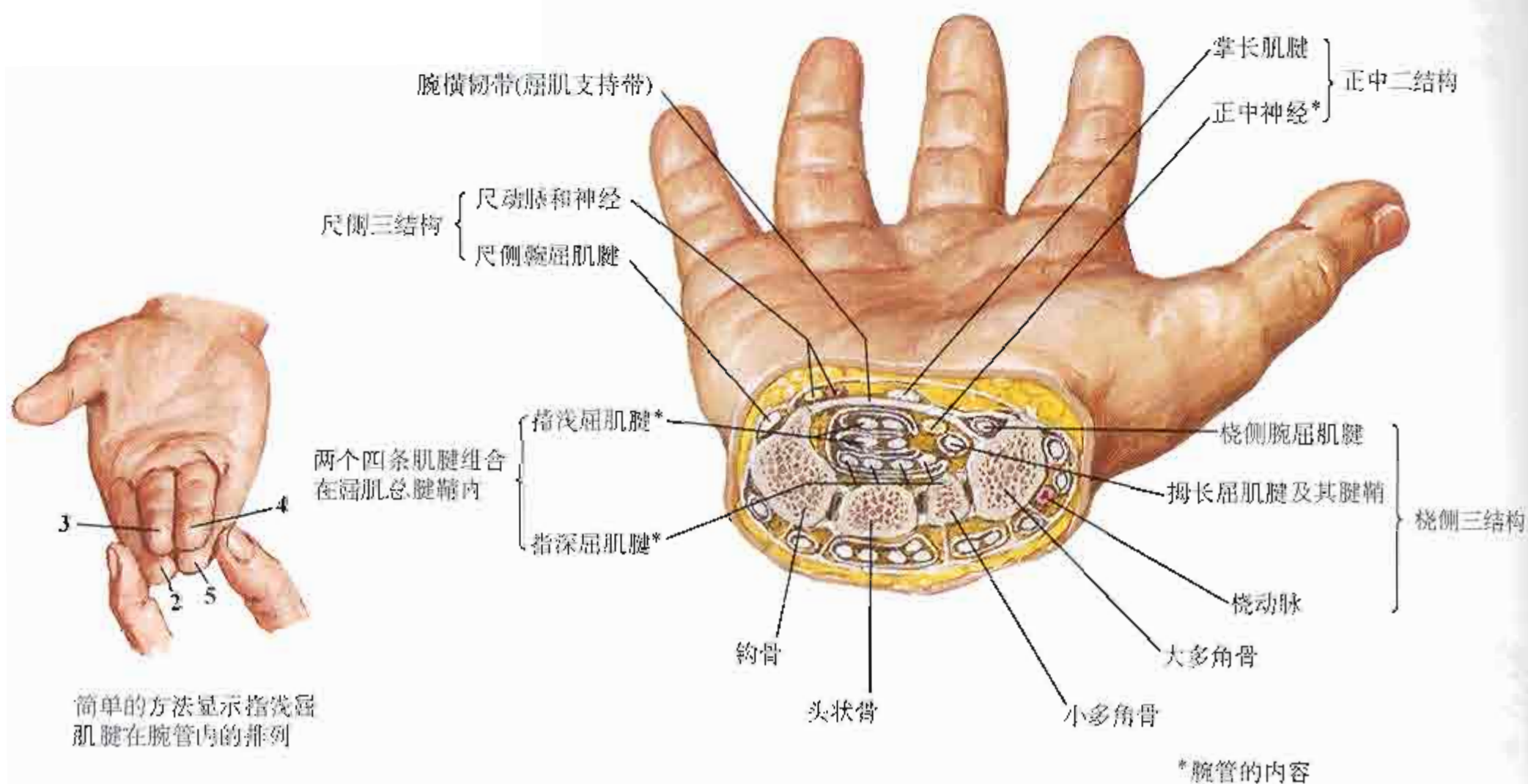
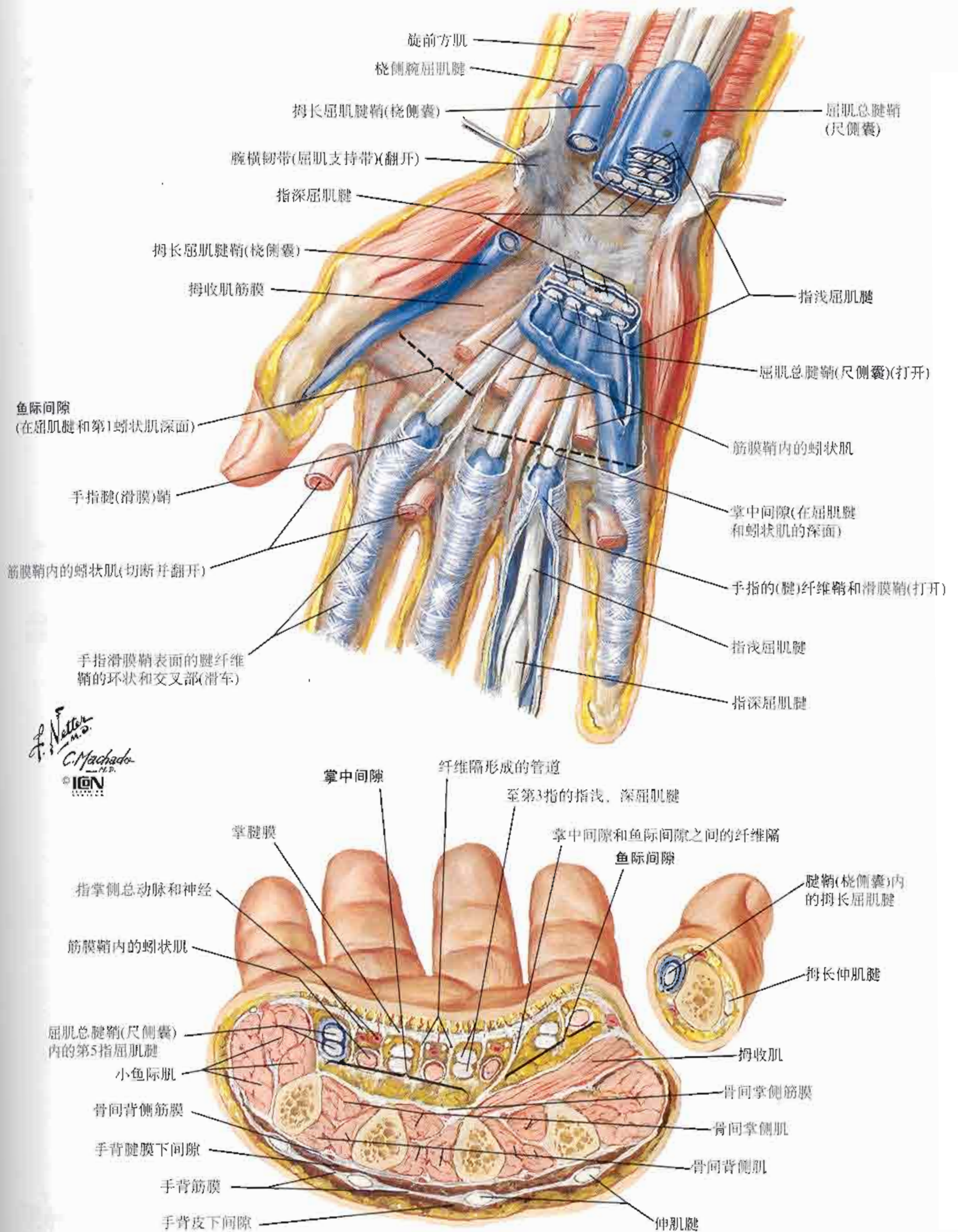


图444

上肢



蚓状肌和滑膜囊、间隙和腱鞘：模式图

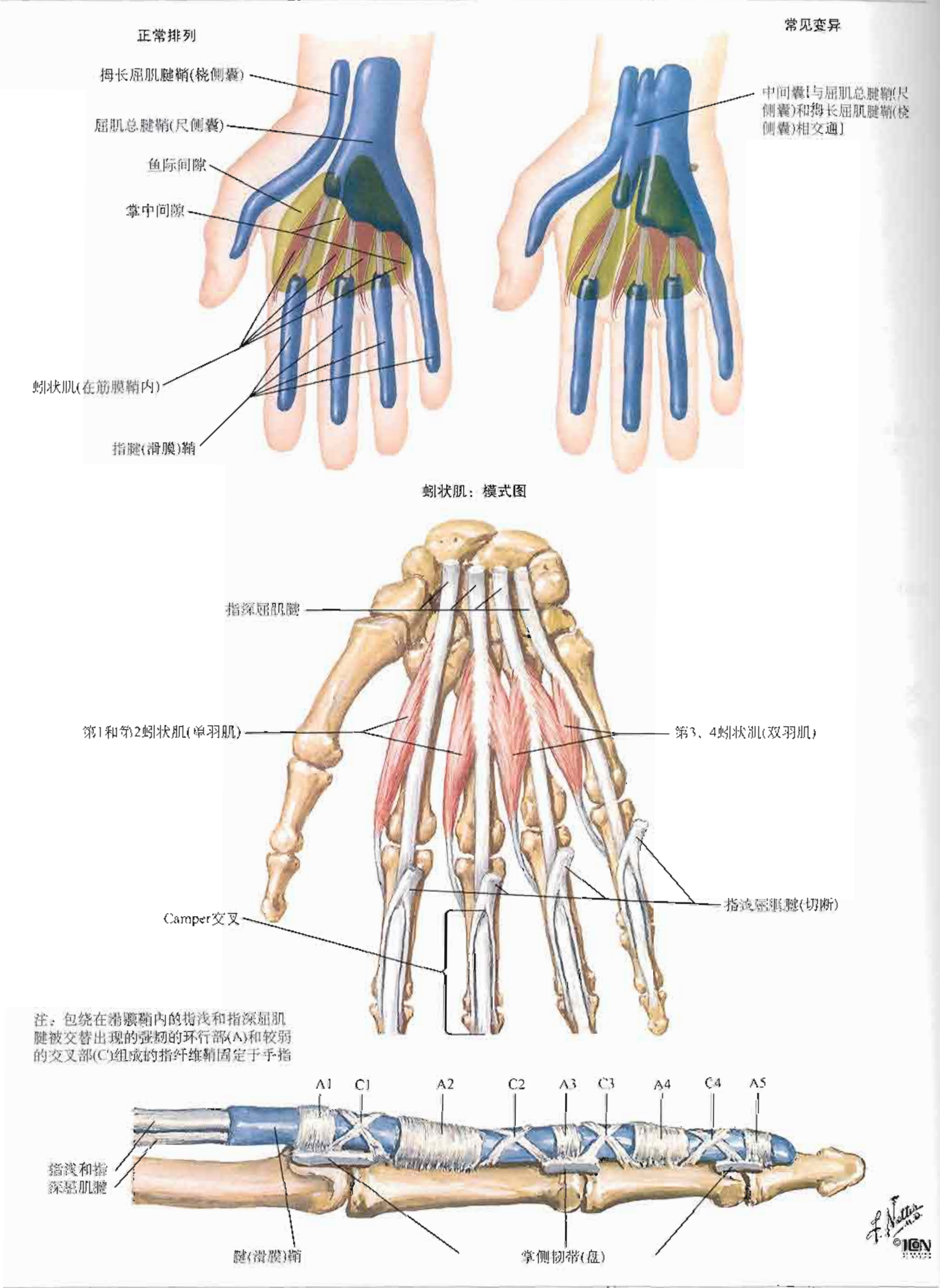
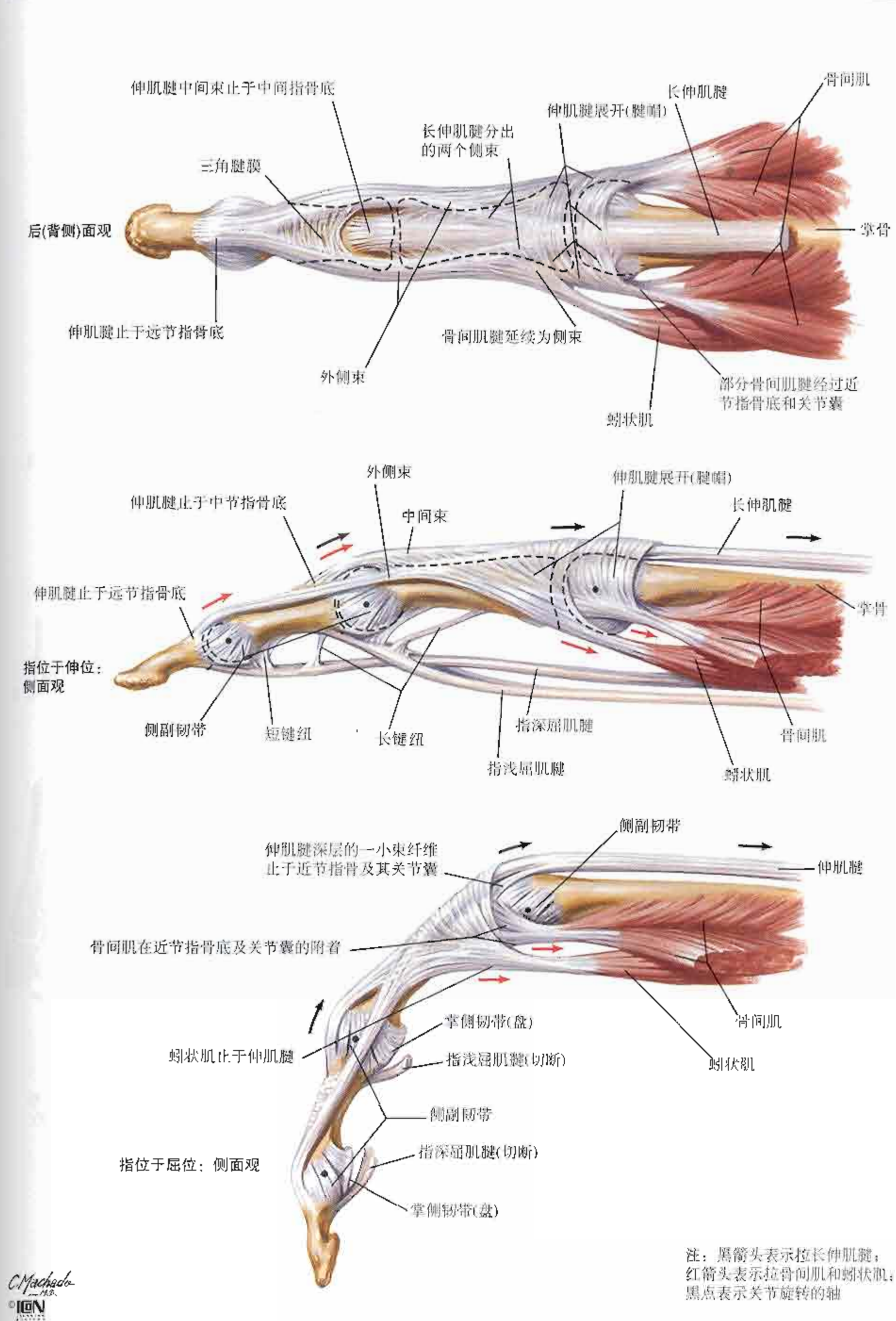


图446



C Machado
1989
ION

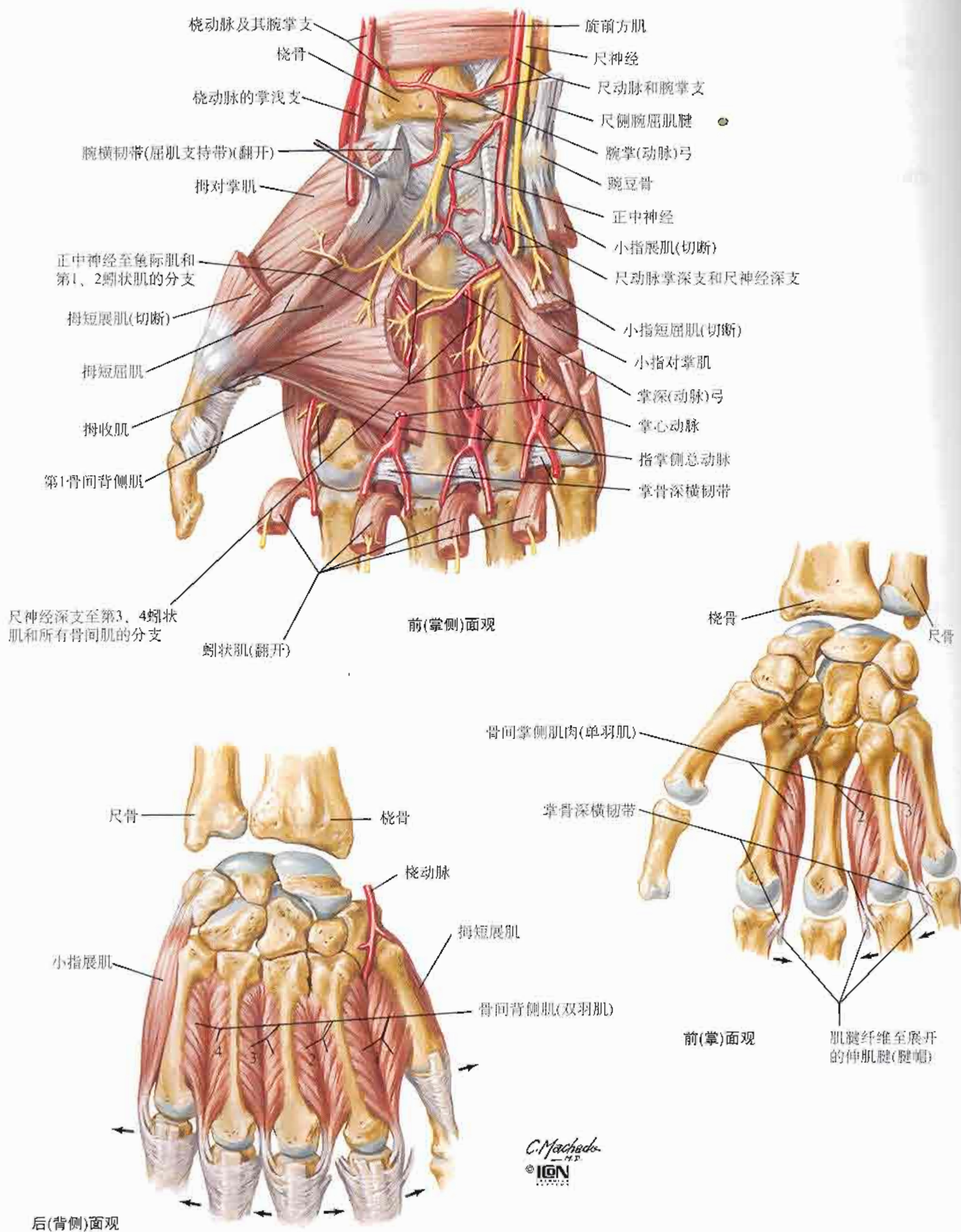
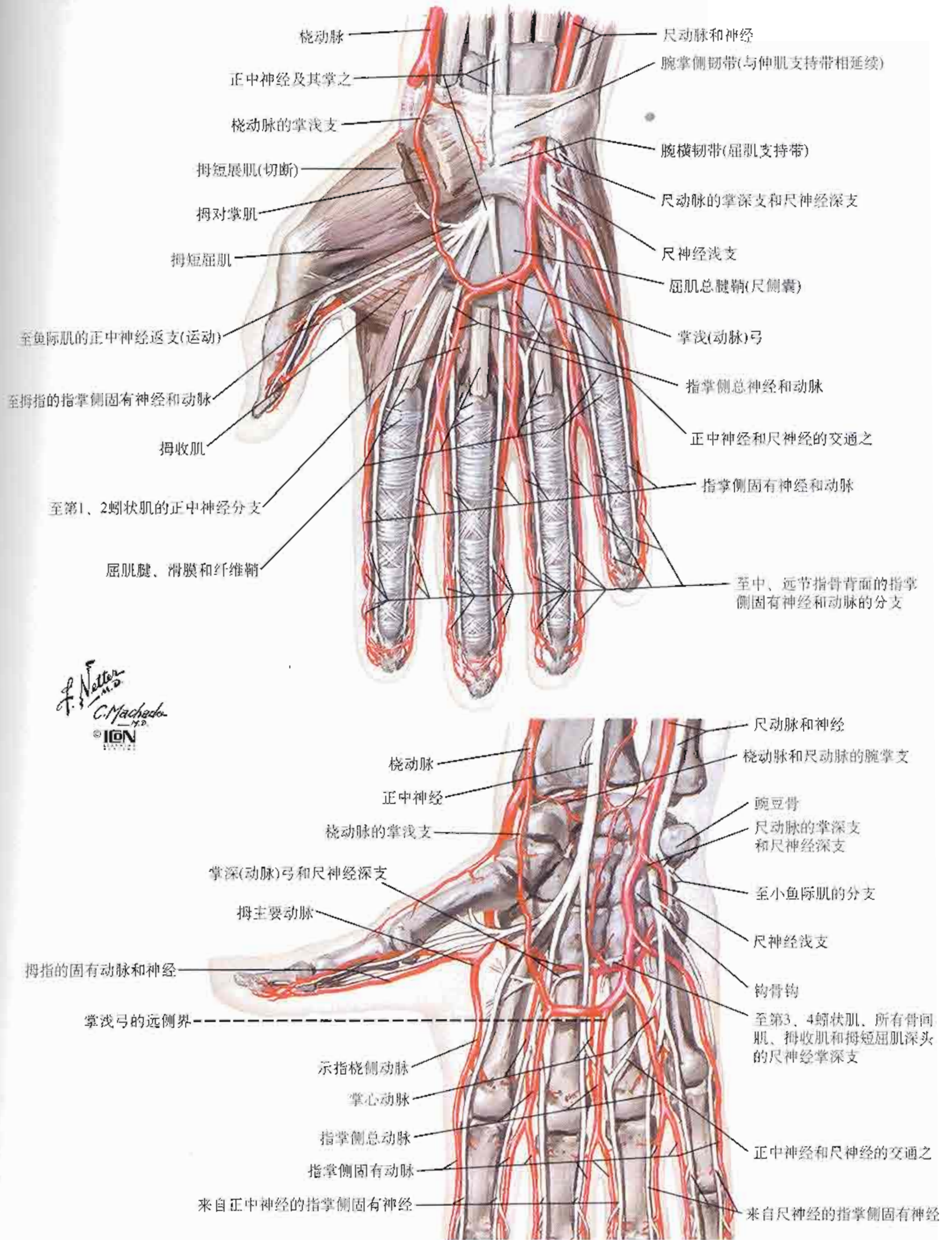
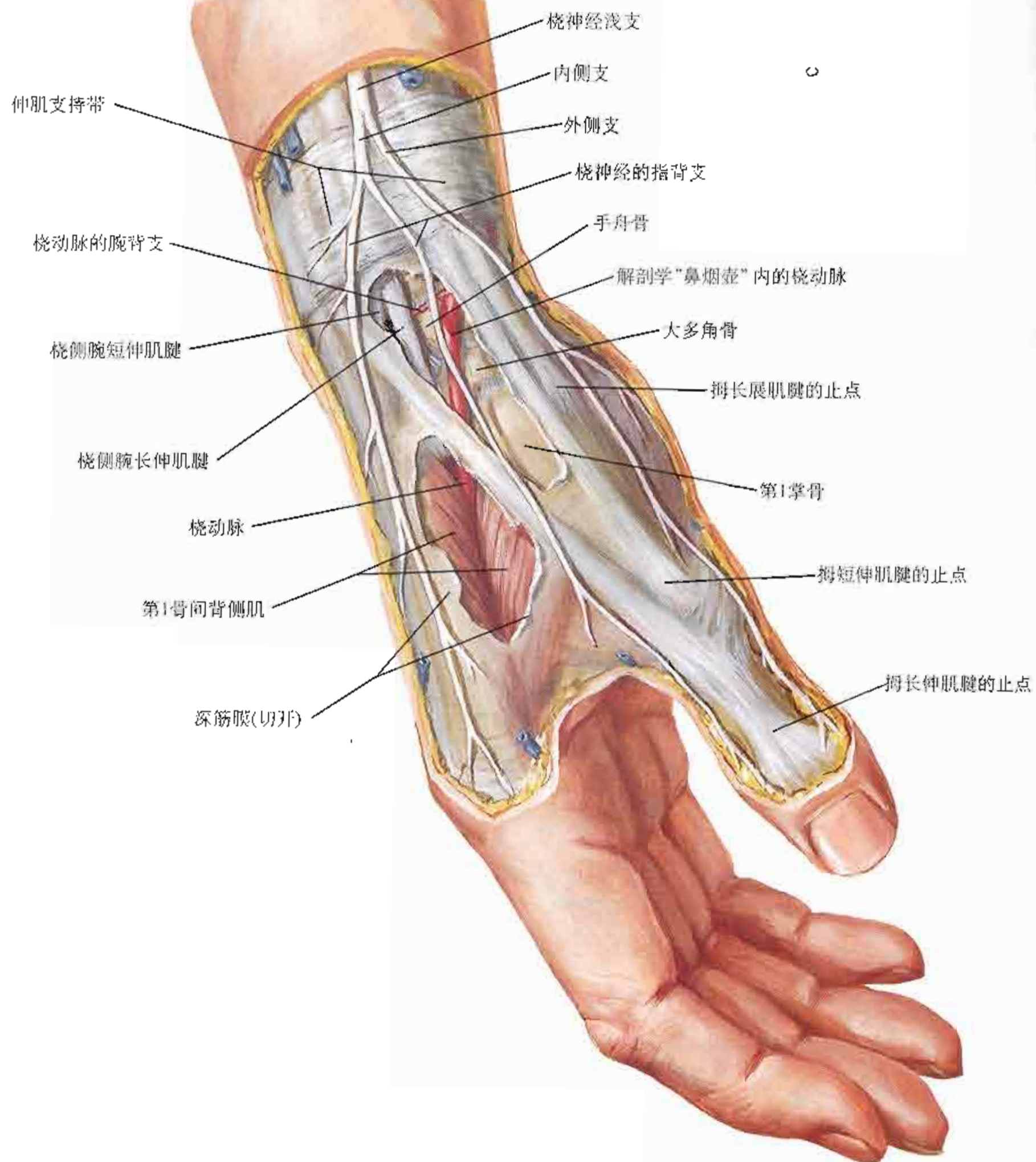


图448



外(桡)侧面观

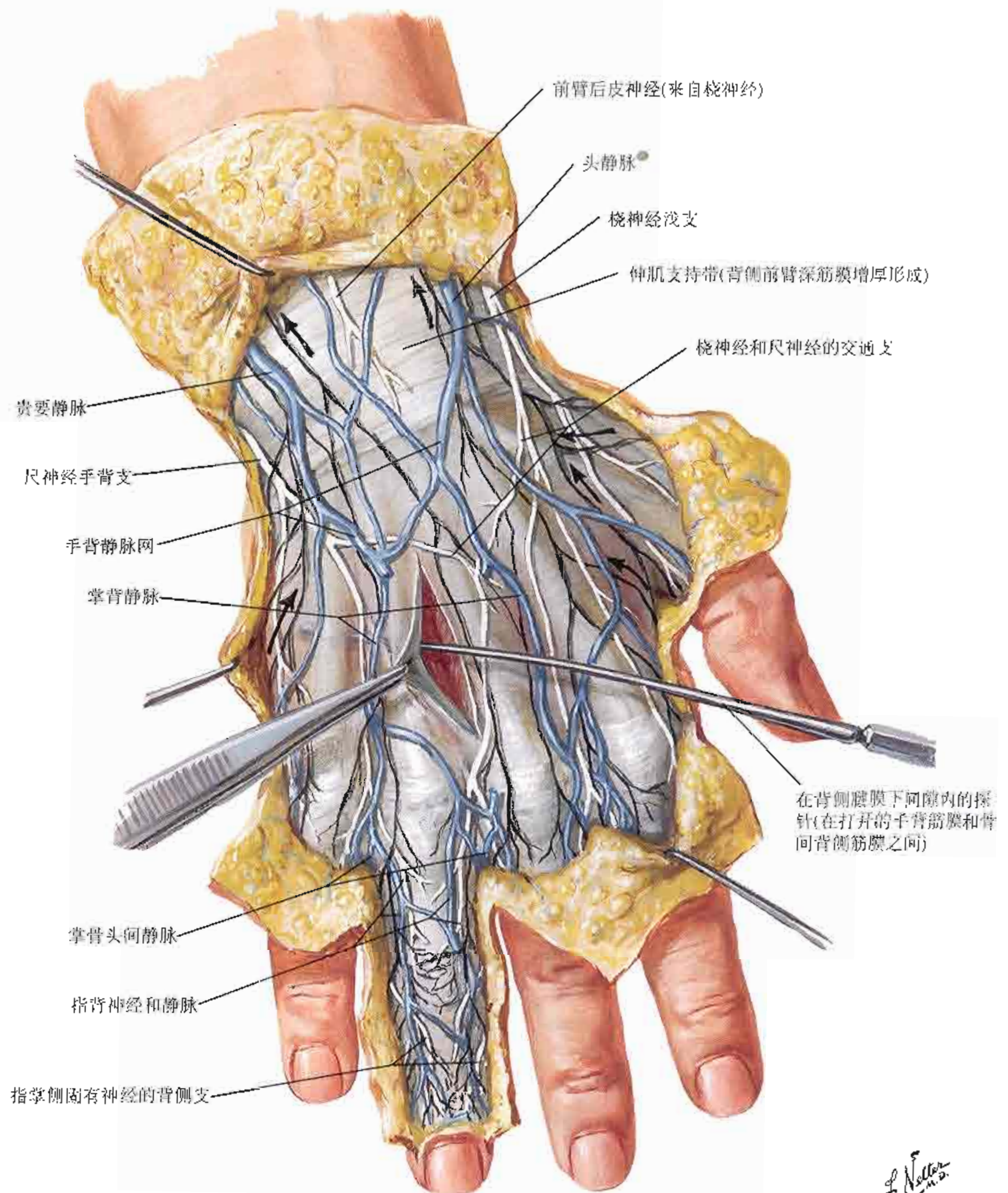


F. Netter M.D.
© 1997

图450

上肢

后(背侧)面观



注：黑色示淋巴管，箭头示淋巴引流方向

F. Netter M.D.
© 1997

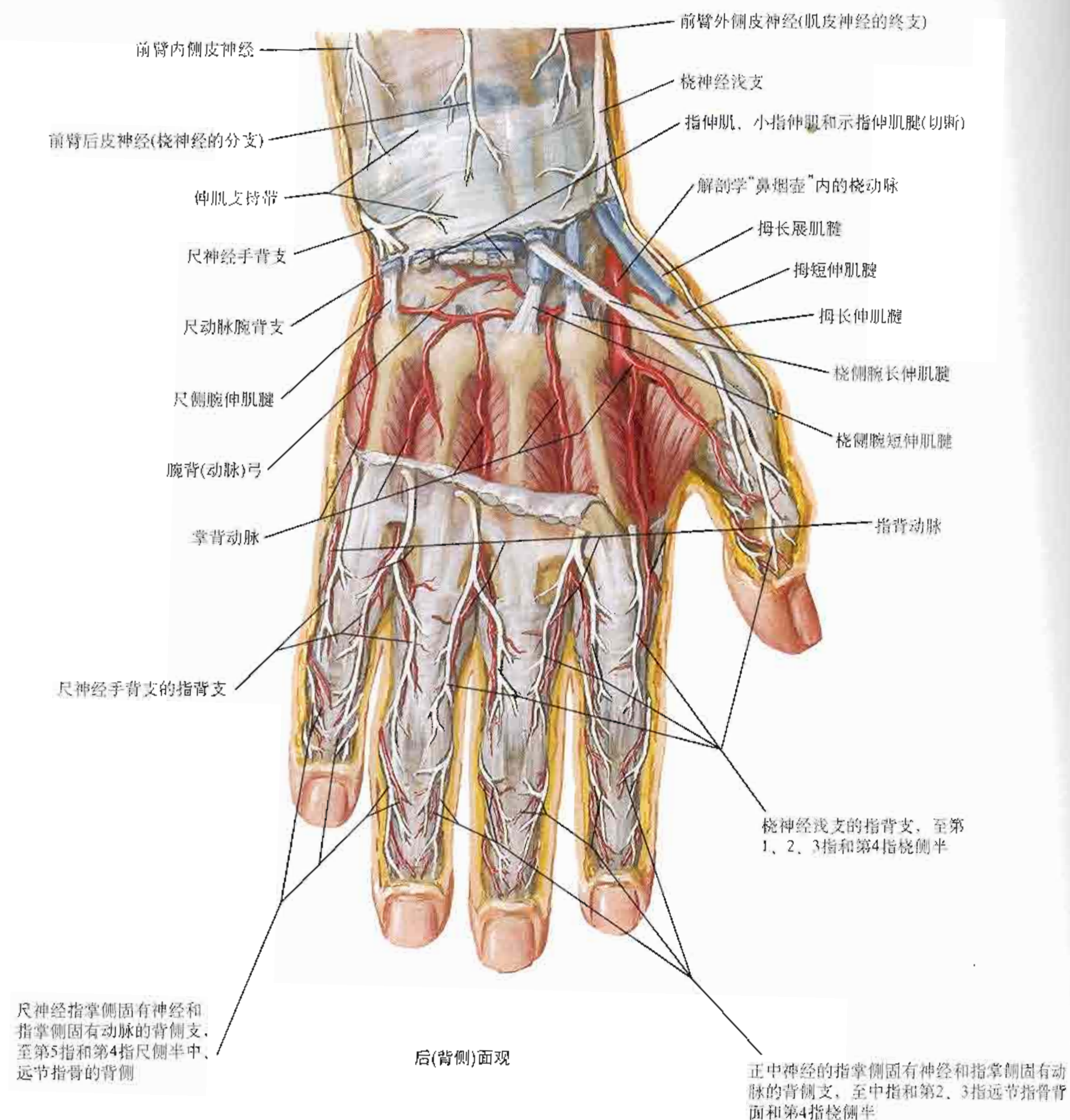
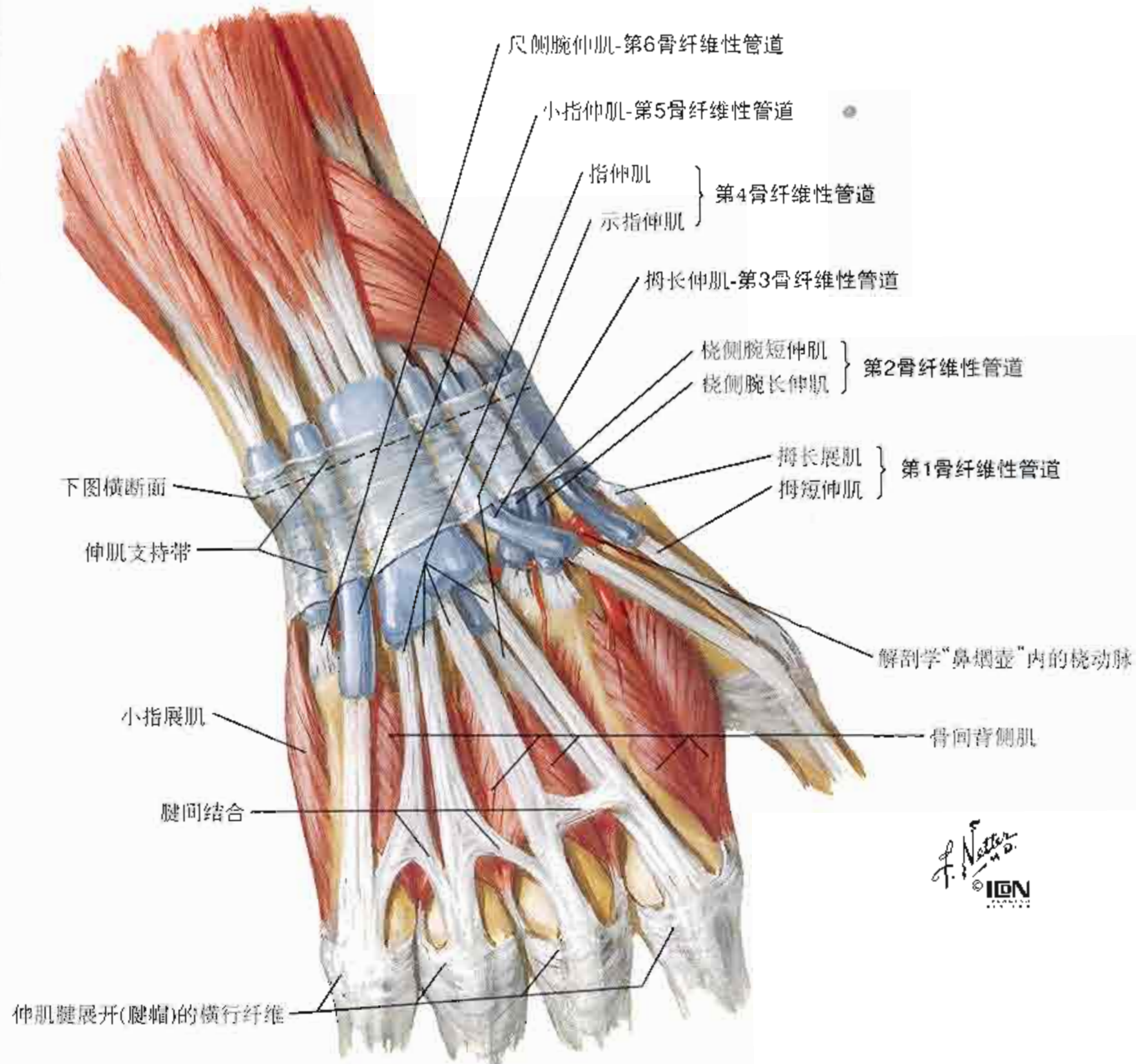


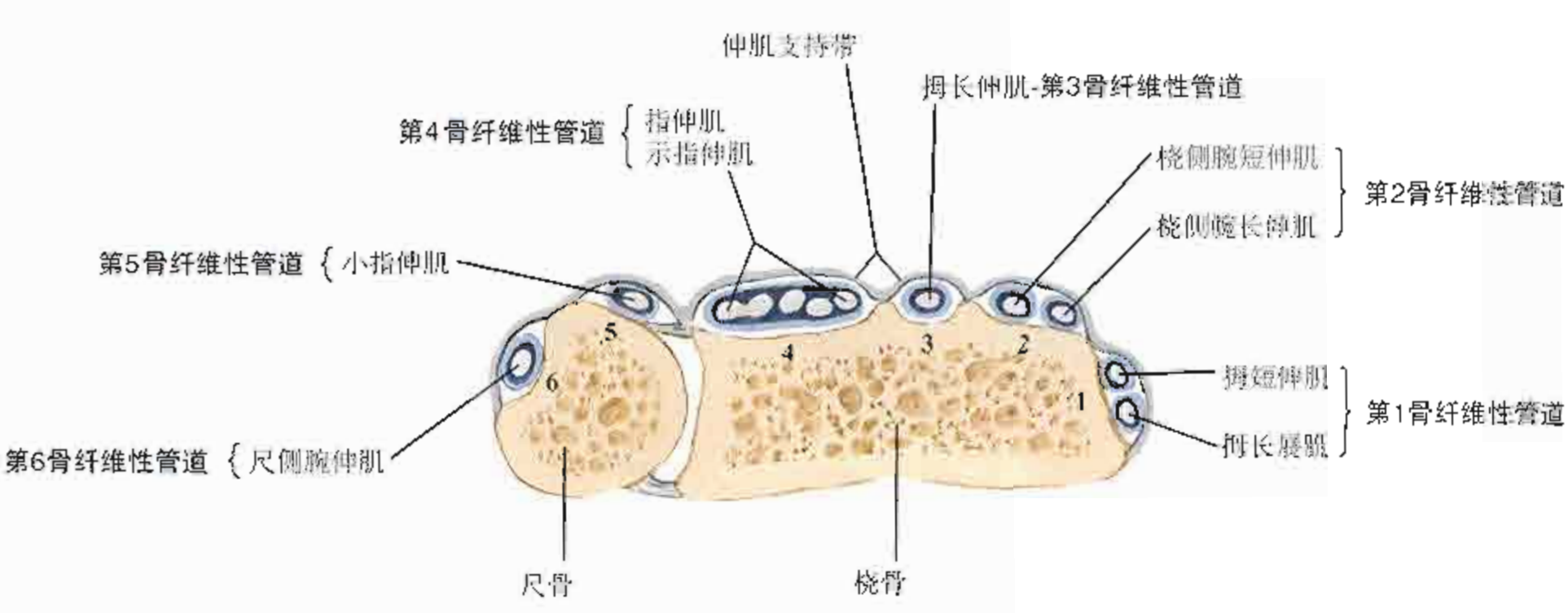
图452

后(背侧)面观



F. Netter M.D. I.D. 100

前臂最远侧横断面



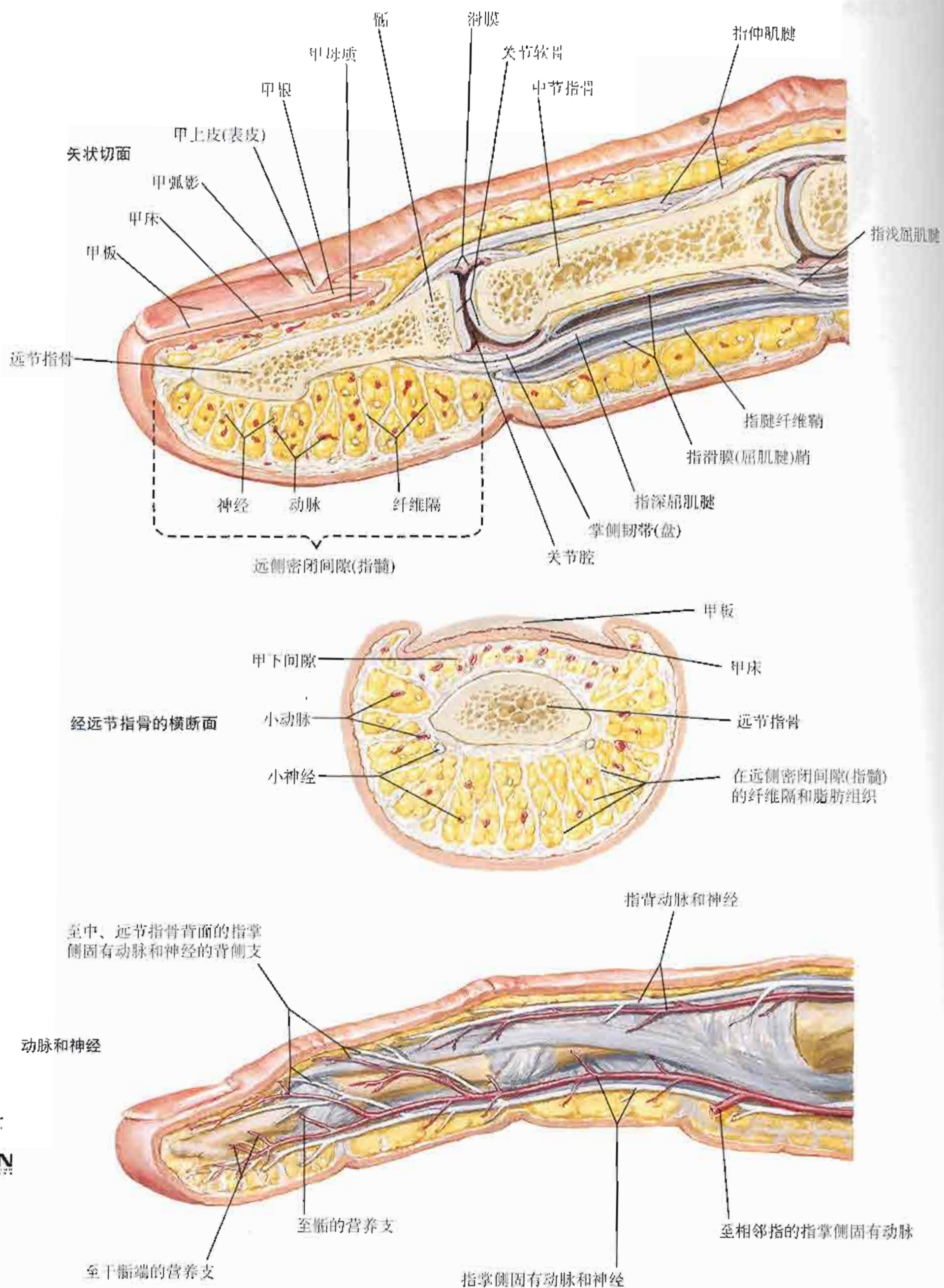



图454




运动科学网站



运动科学网站



运动科学网站

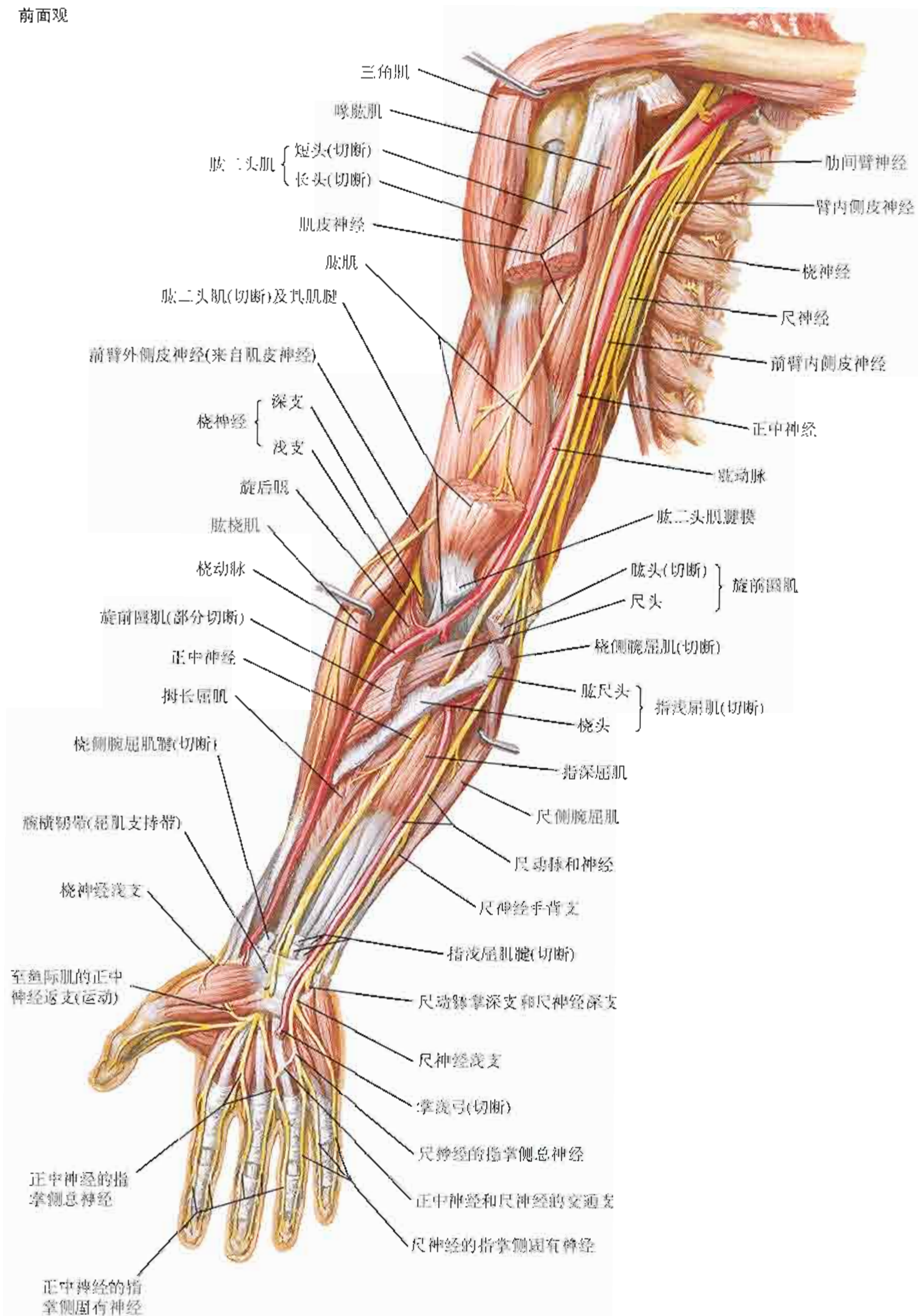


运动科学网站



运动科学网站

前面观



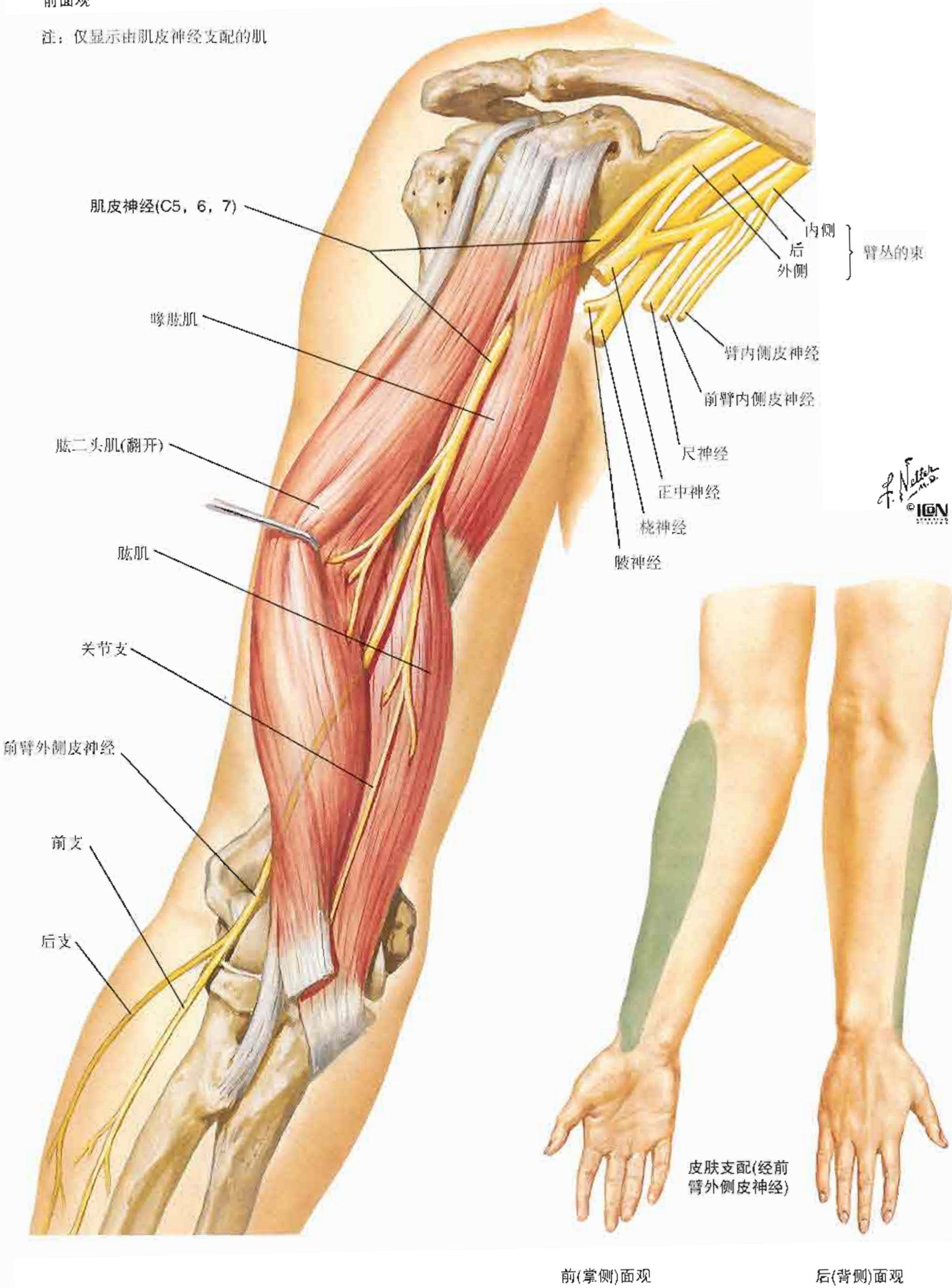
F. Netter M.D. © ION 2004

图456

上肢

前面观

注：仅显示由肌皮神经支配的肌



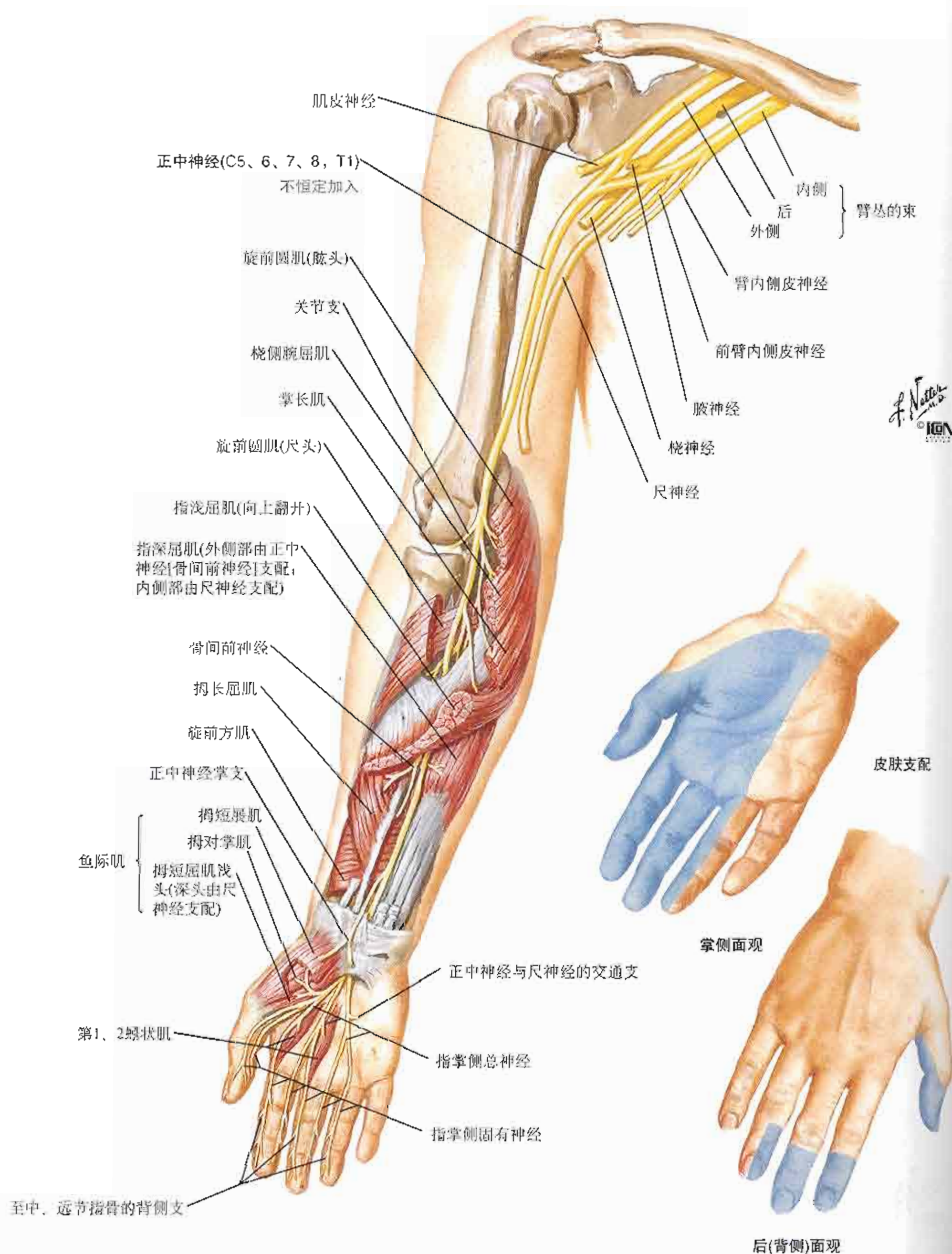


图458

前面观

注：仅显示由尺神经支配的肌

尺神经(C7、8、T1)
(肘以上无分支)
不恒定加入

内上髁

关节支(在内侧髁后方)

指深屈肌(仅内侧半; 外侧半由正中神经的骨间前神经支配)

尺侧腕屈肌(拉向一边)

尺神经手背支

掌支

浅支

深支

掌短肌

小指展肌

小指短屈肌

小指对掌肌

小鱼际肌

指掌侧总神经

正中神经与尺神经的交通支

骨间掌侧和背侧肌

第3、4蚓状肌(向下翻开)

指掌侧固有神经(指背神经来源于背侧支)

至中节和远节指背的背侧支

皮肤支配

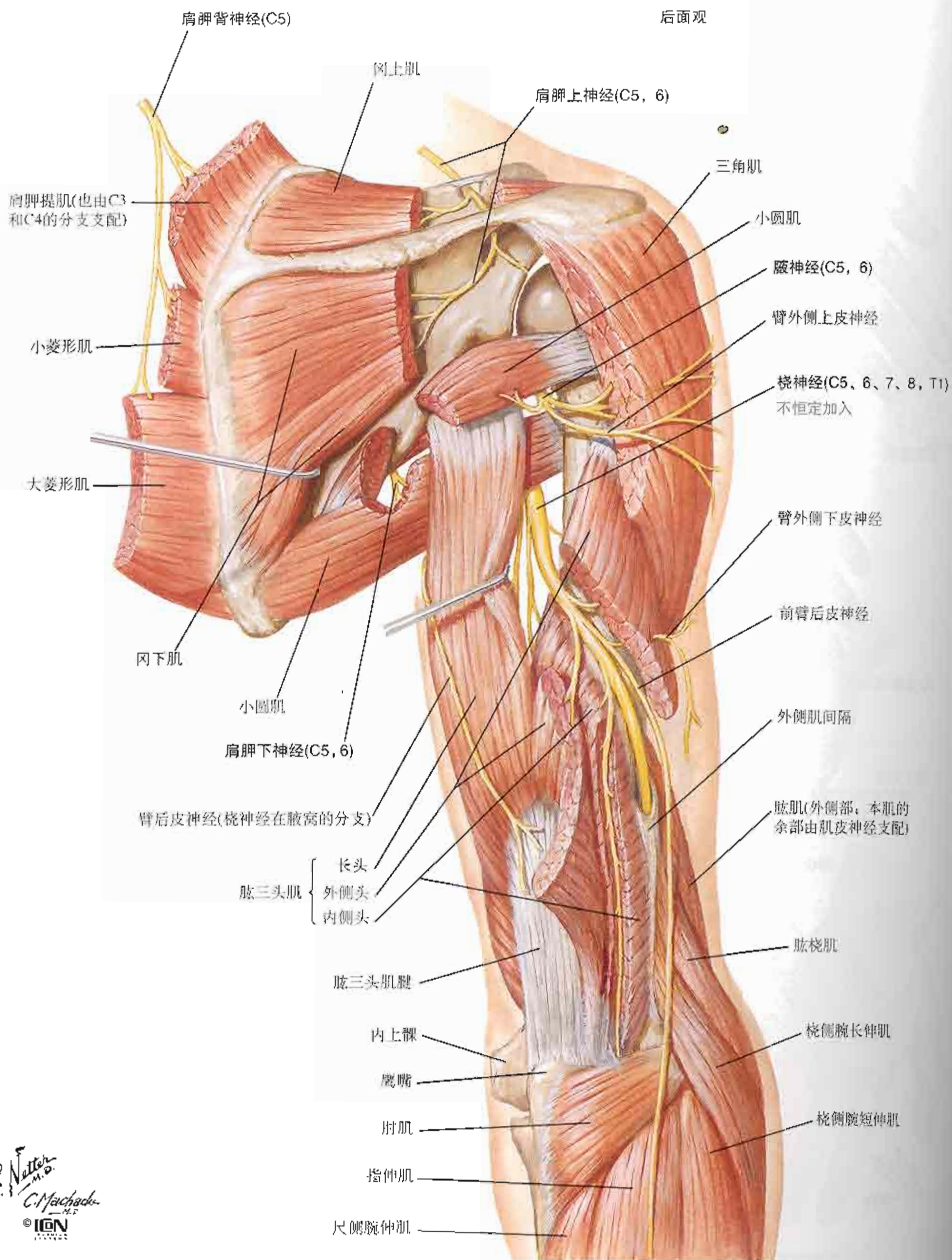
掌侧面观

后(背侧)面观

拇短屈肌(仅深头; 浅头及其它鱼际肌由正中神经支配)

拇收肌

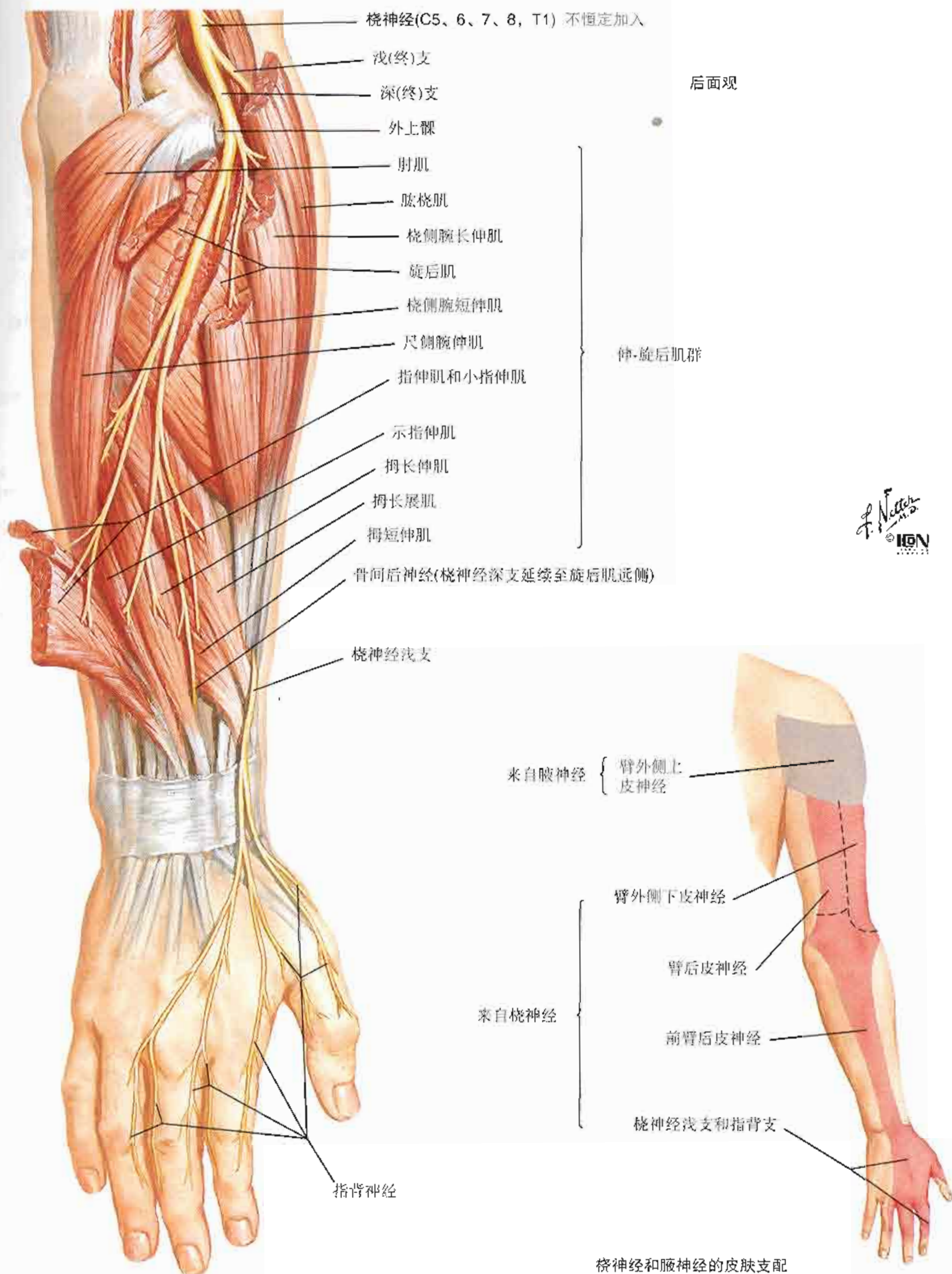




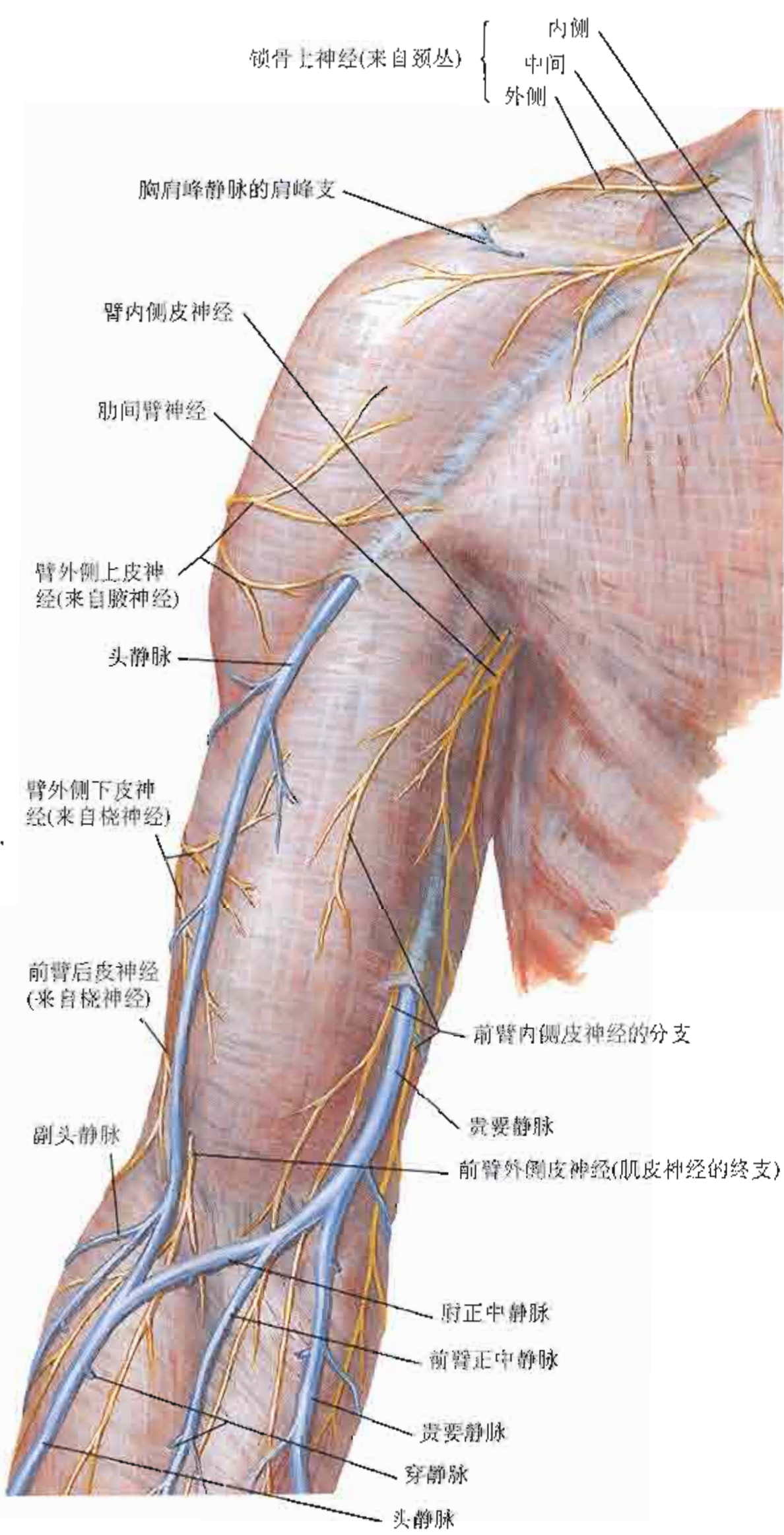
F. Netter M.D.
C. Machado M.D.
© ION

图460

上肢



前面观



后面观

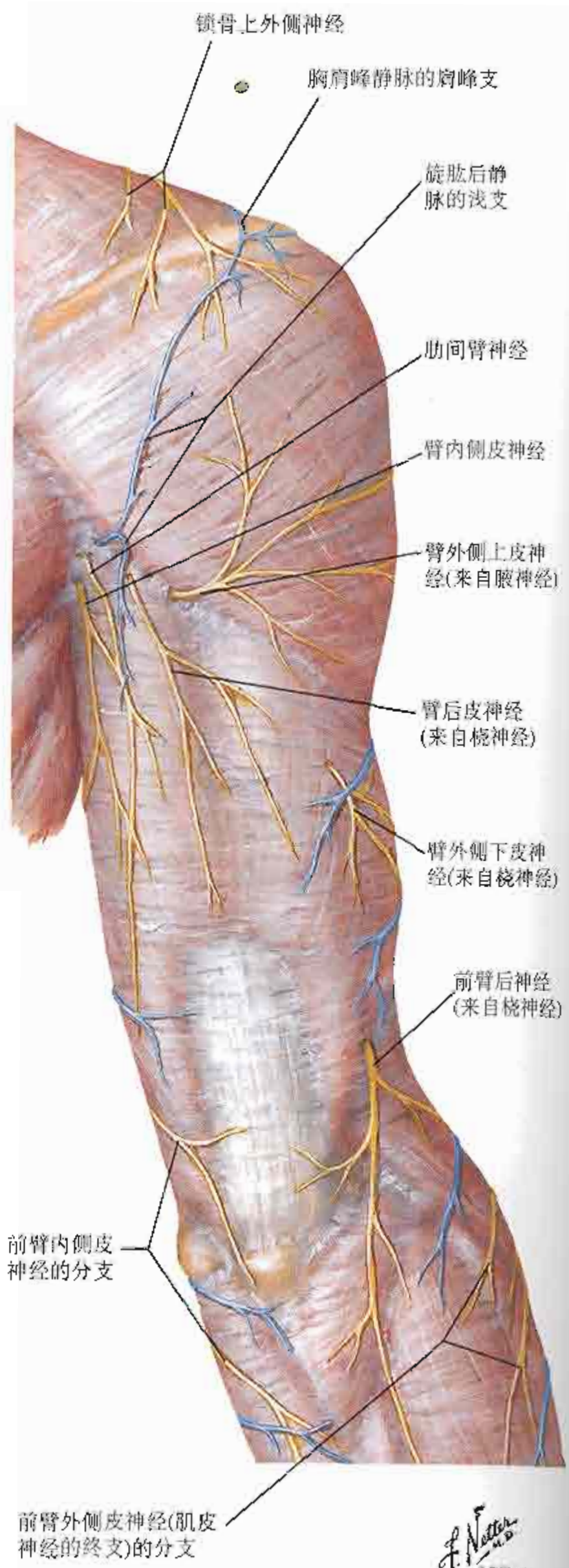
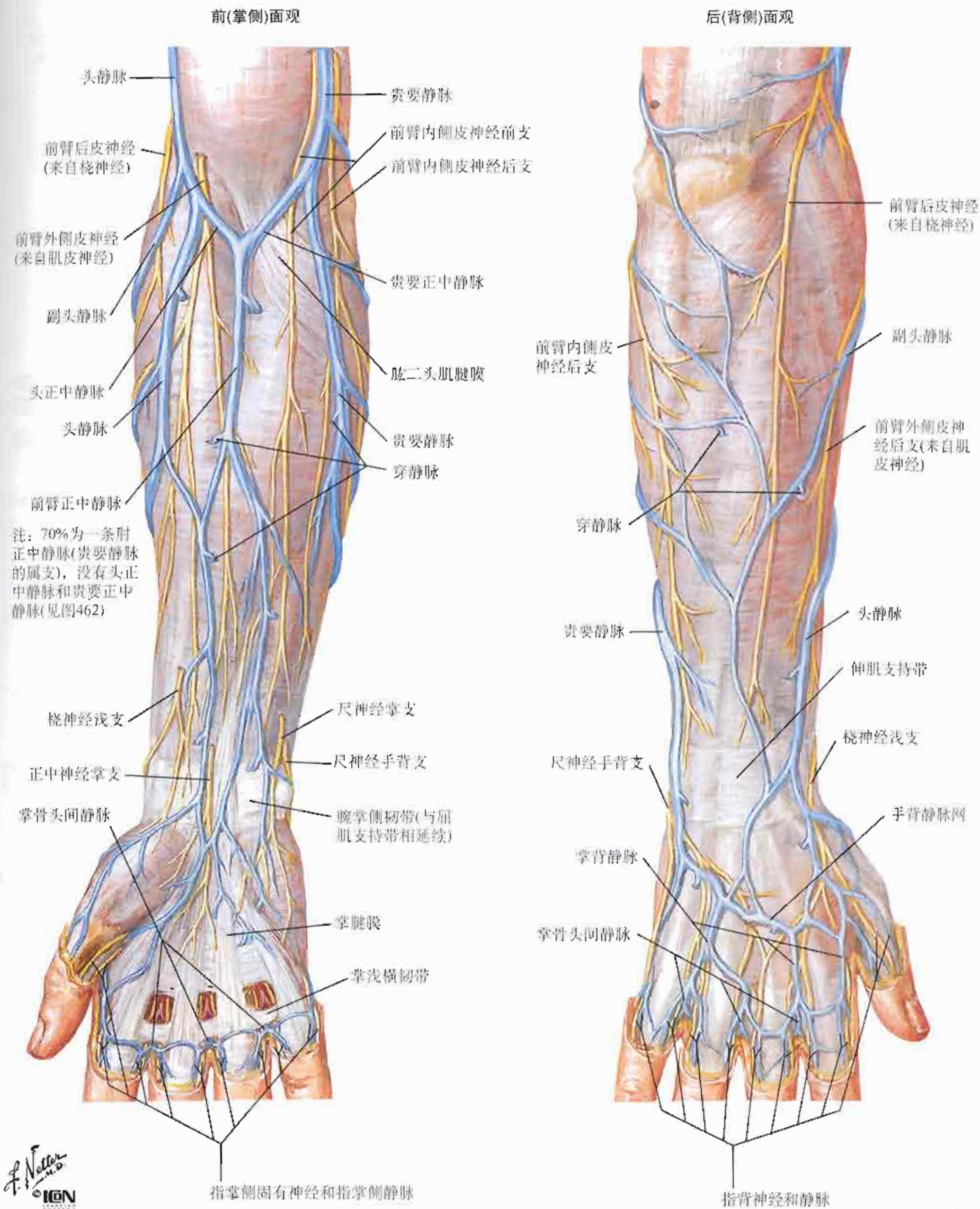


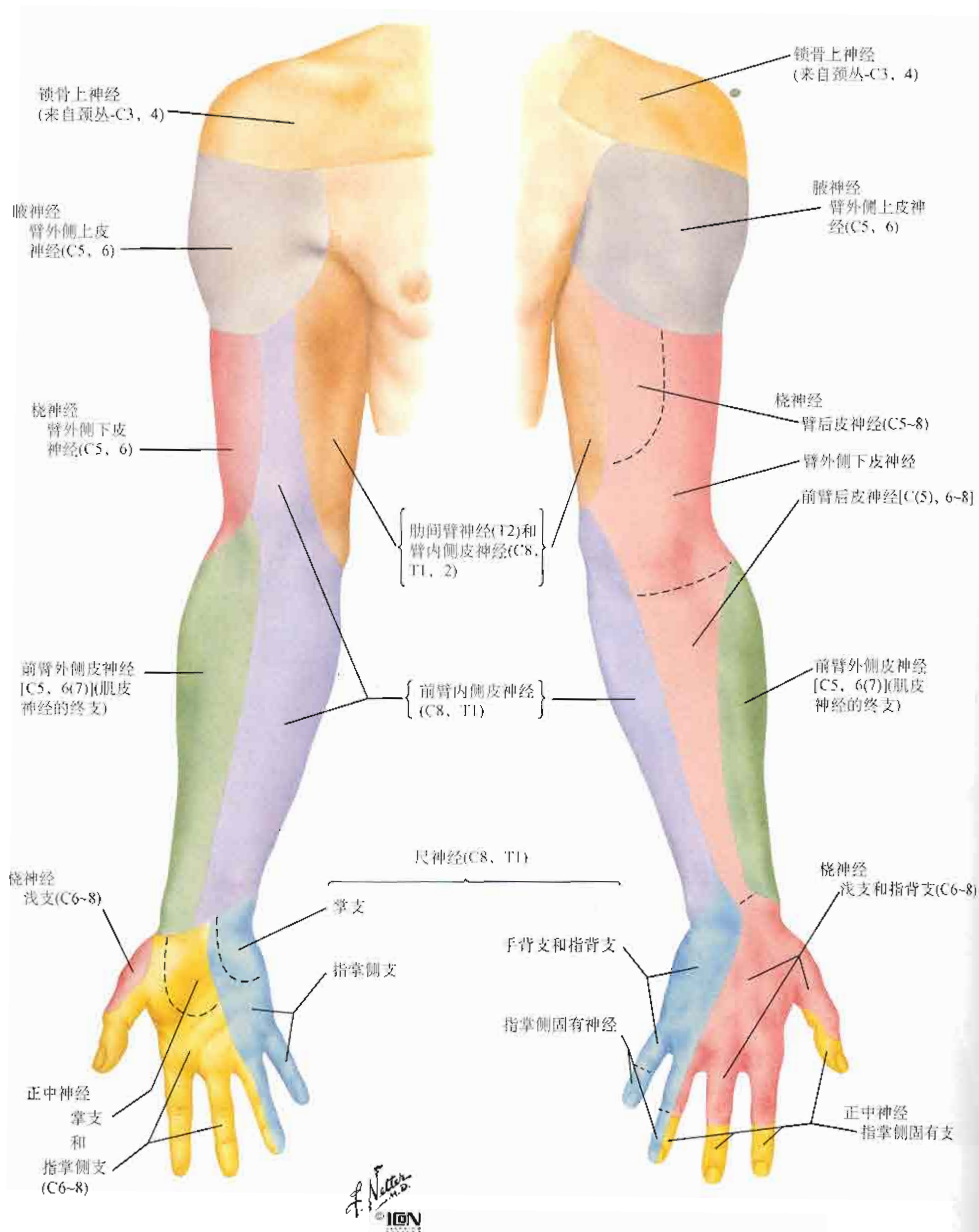
图462



上肢的皮神经支配

前(掌侧)面观


后(背侧)面观



注：尺神经和桡神经支配手背的区域有变异，通常是以第3指为界而不是如图所示的第4指




运动科学网站



运动科学网站



运动科学网站



运动科学网站



运动科学网站

参见图177、451

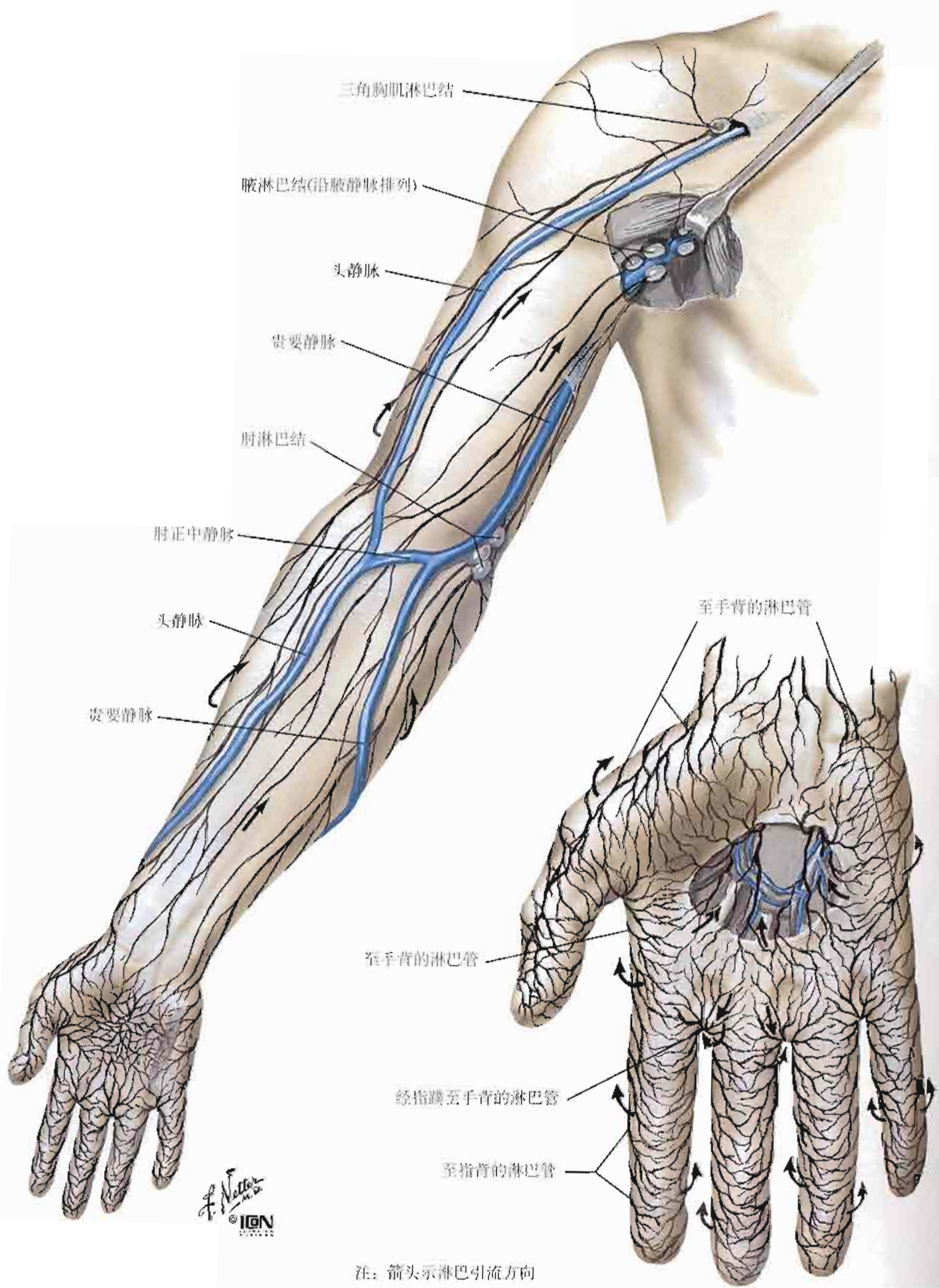
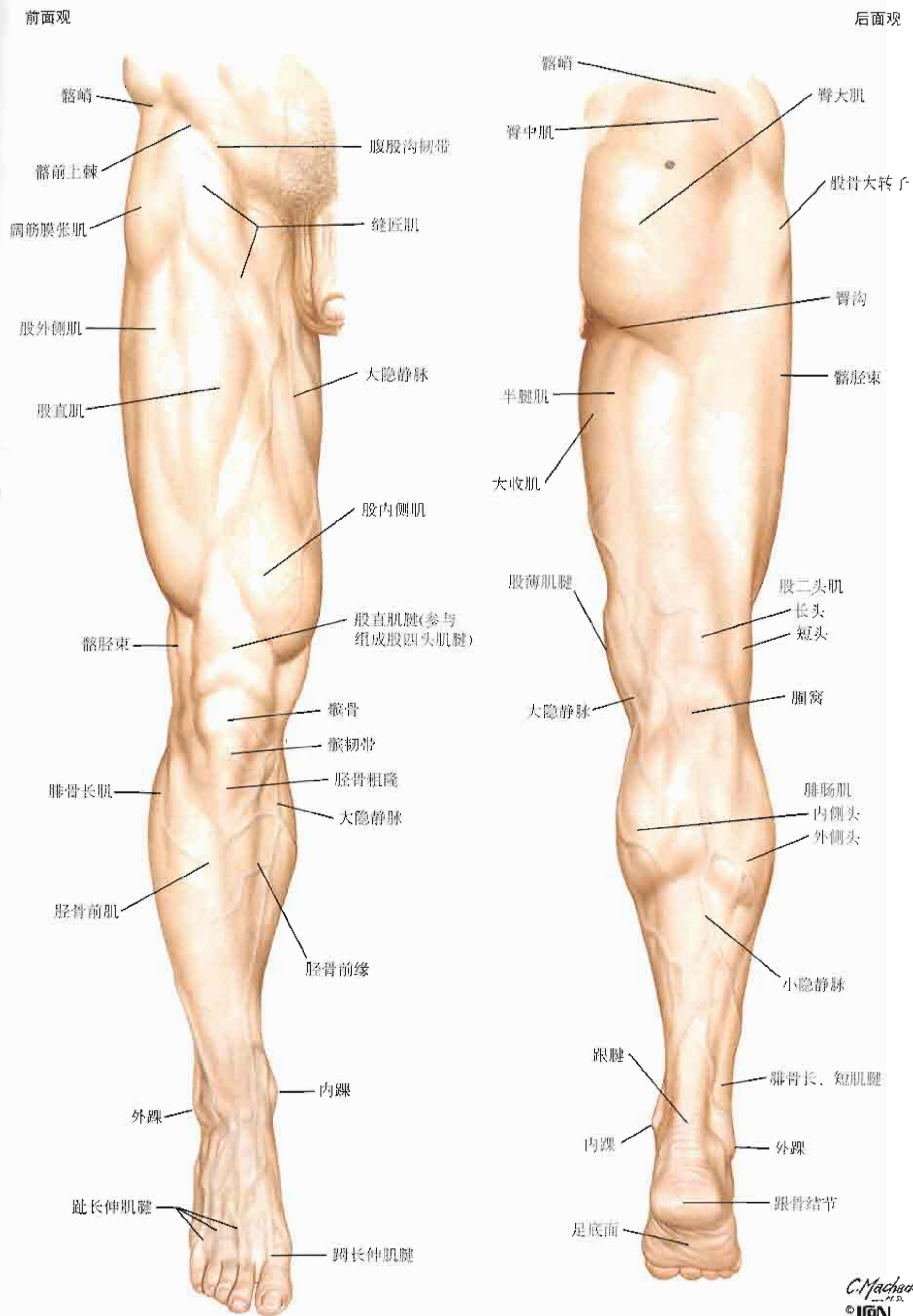


图466



C. Machado
© ION

参见图240、340、341

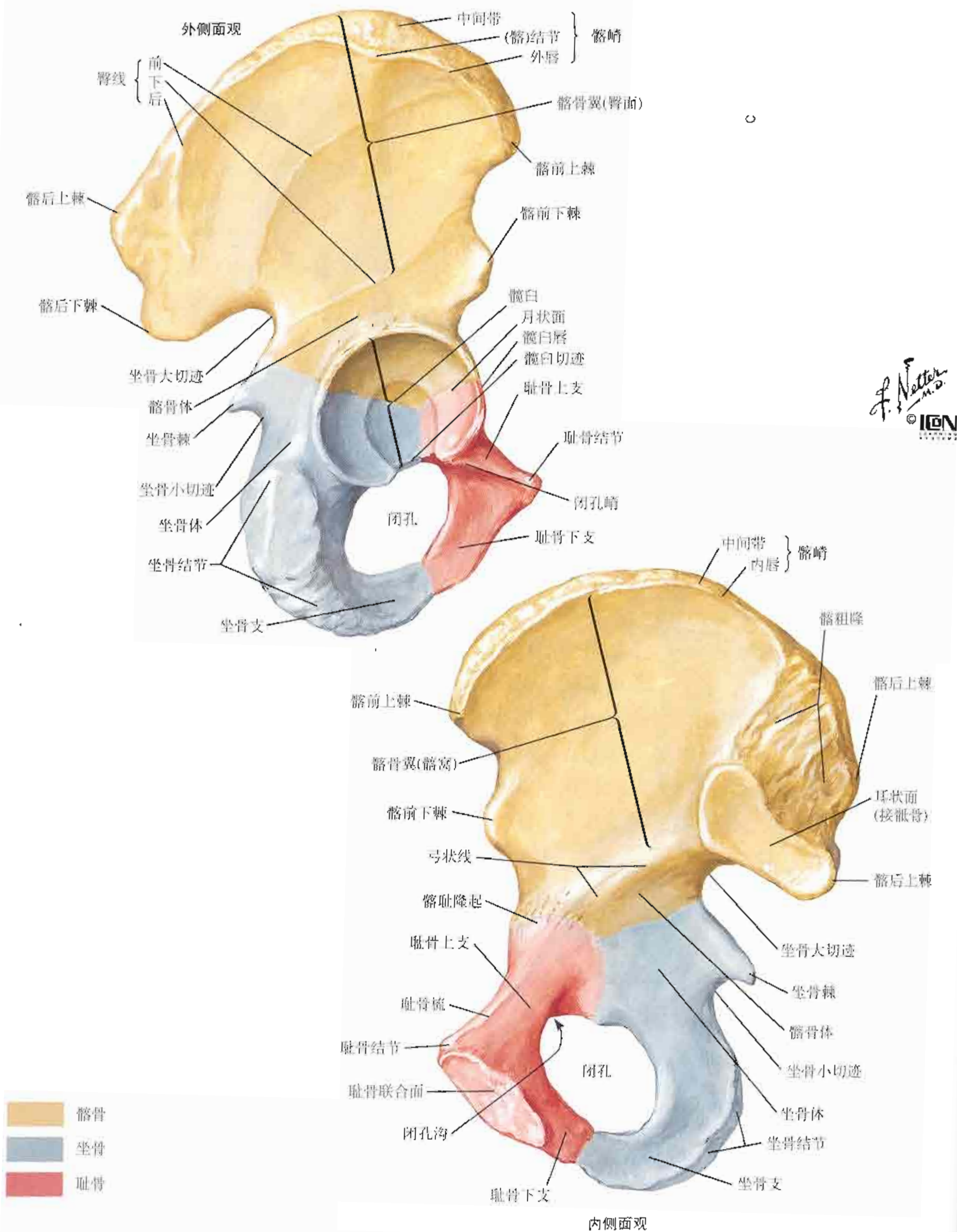
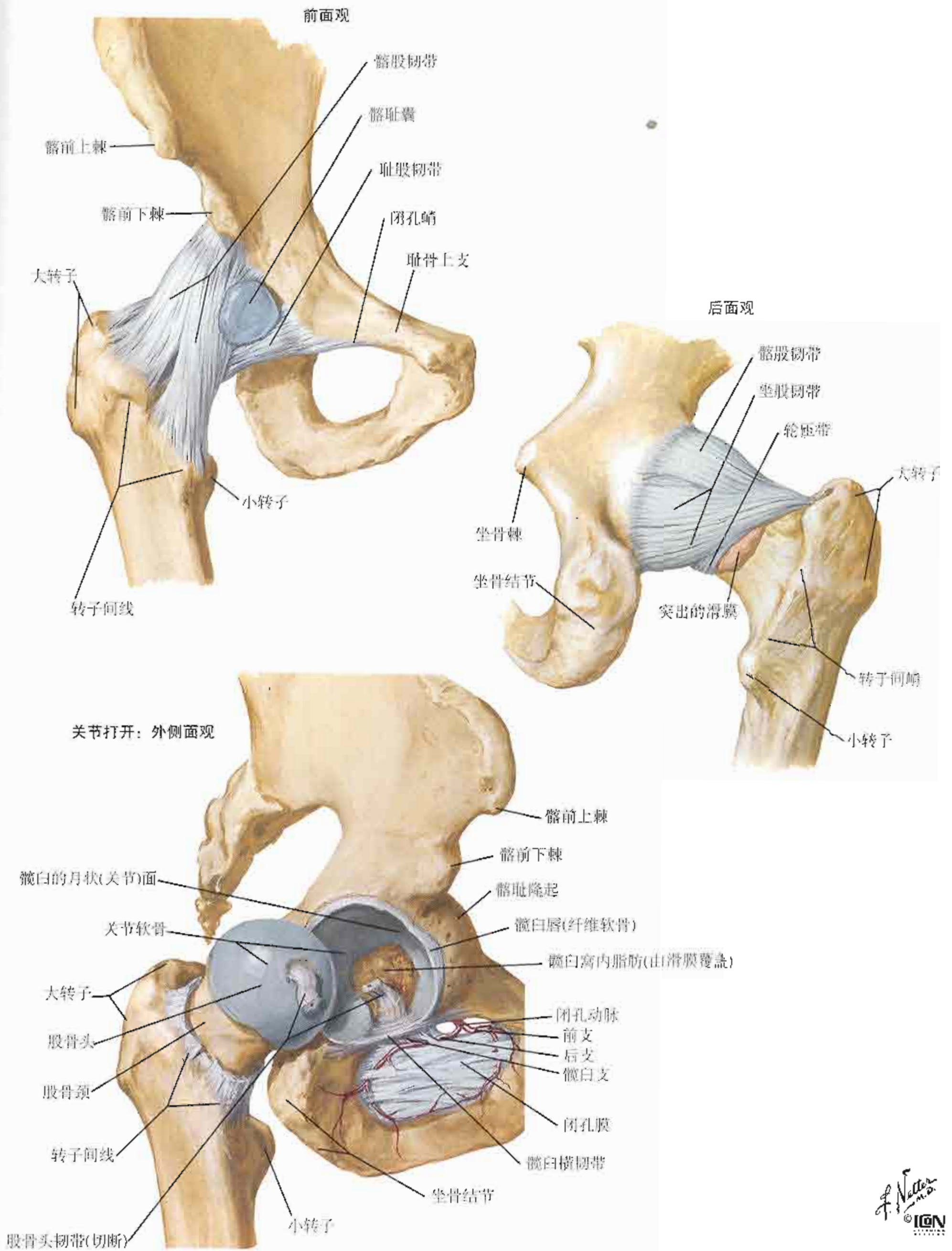
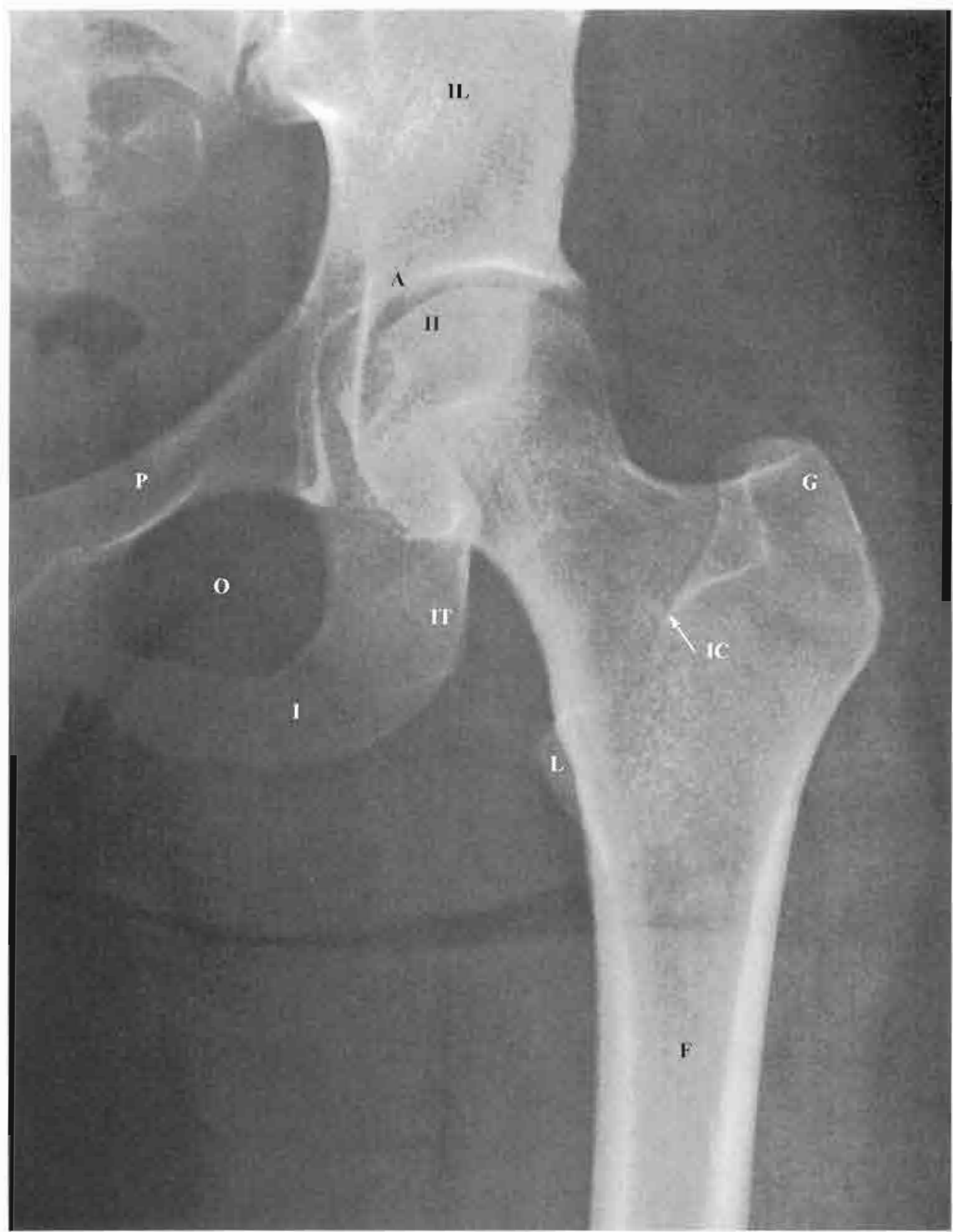


图468 下肢



F. Netter
M.D.
© IGV

参见图469、471




- | | |
|----|--------|
| A | 髋臼 |
| F | 股骨 |
| G | 大转子 |
| H | 股骨头 |
| I | 坐骨 |
| IC | 转子间嵴 |
| IL | 髂骨 |
| IT | 坐骨结节 |
| L | 小转子 |
| O | 闭孔 |
| P | 耻骨(主支) |

图470




运动科学网站



运动科学网站



运动科学网站



运动科学网站



运动科学网站

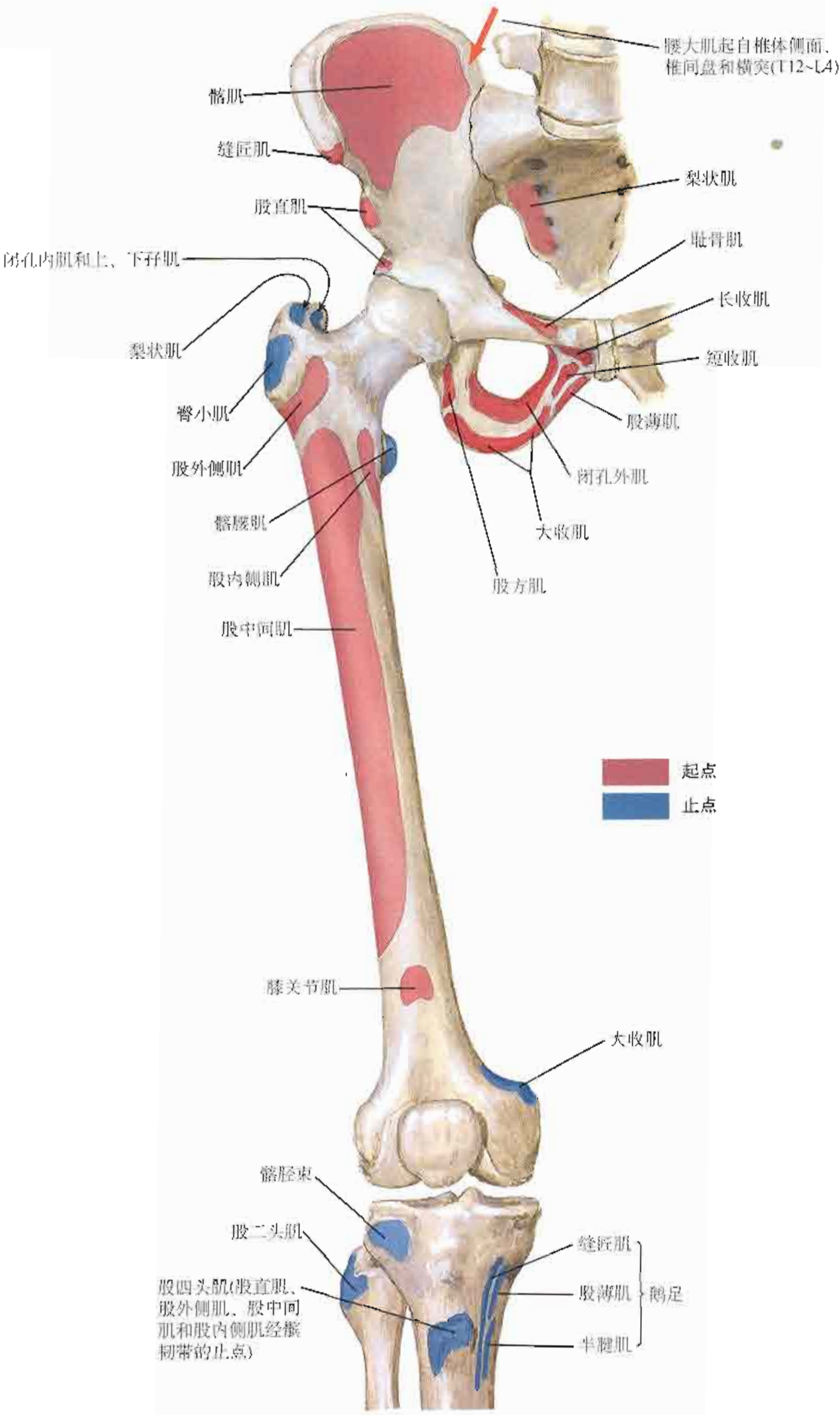
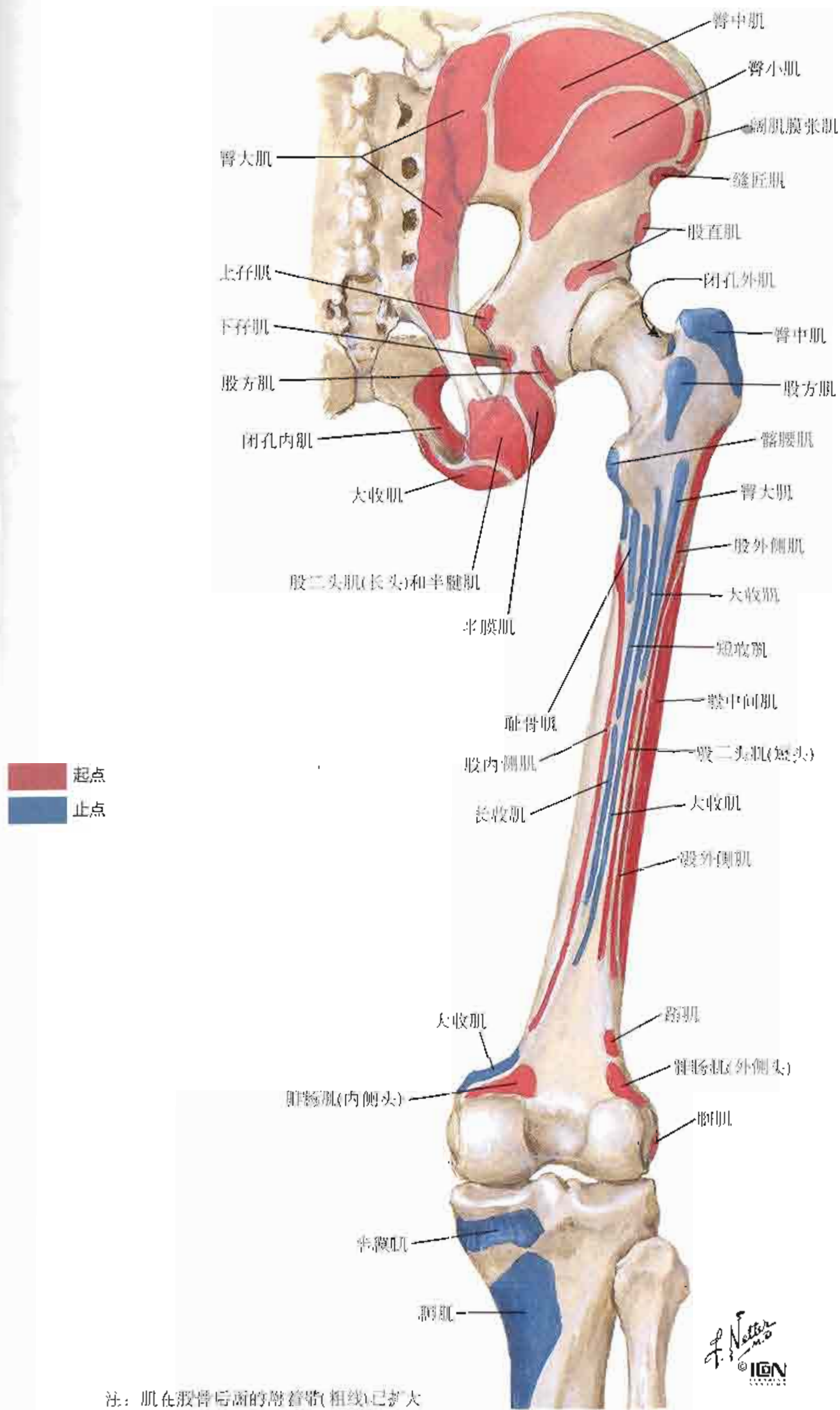
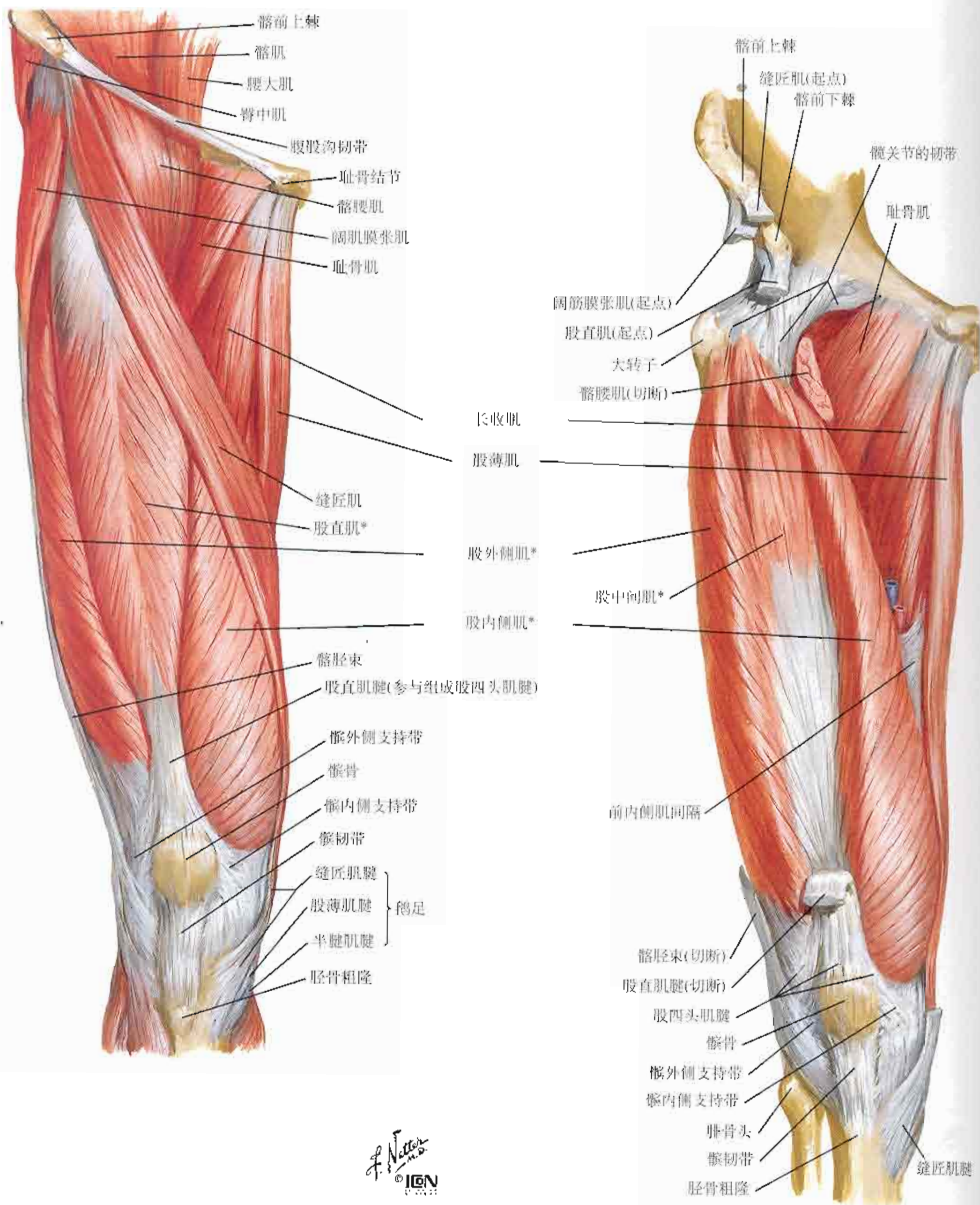


图472



大腿肌：前面观

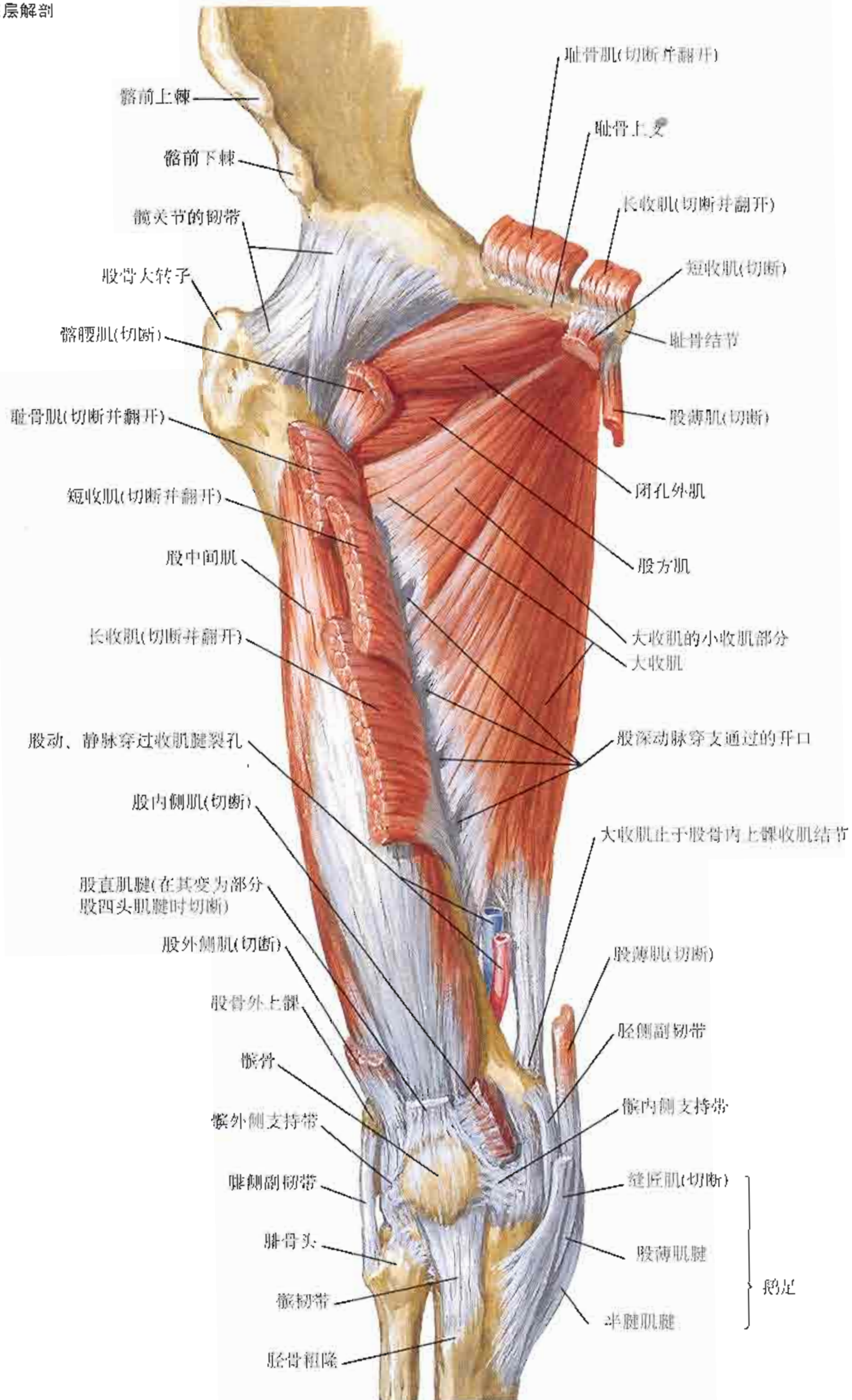


*股四头肌

图474

下肢

深层解剖



F. Netter M.D.
© IGM

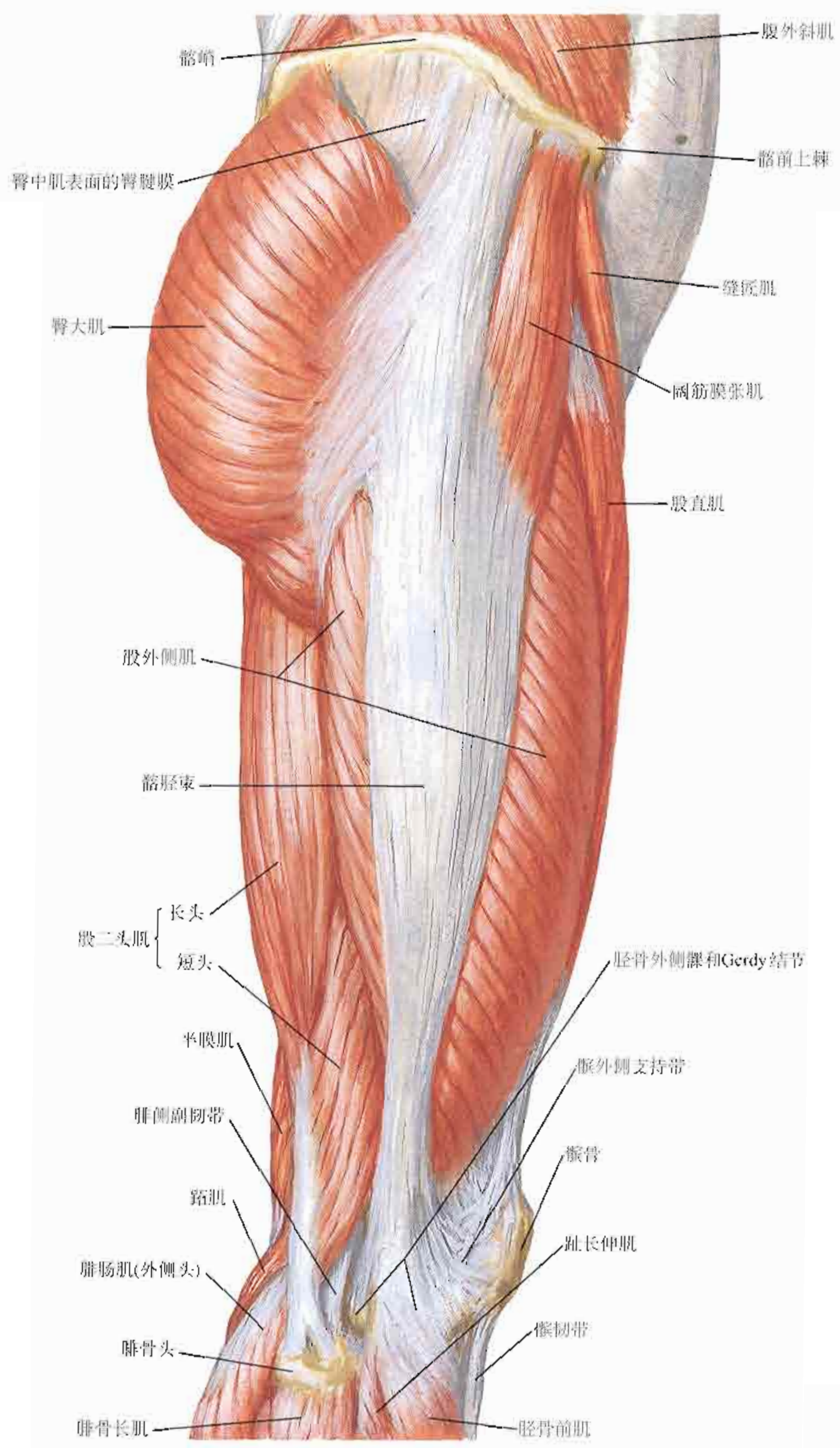
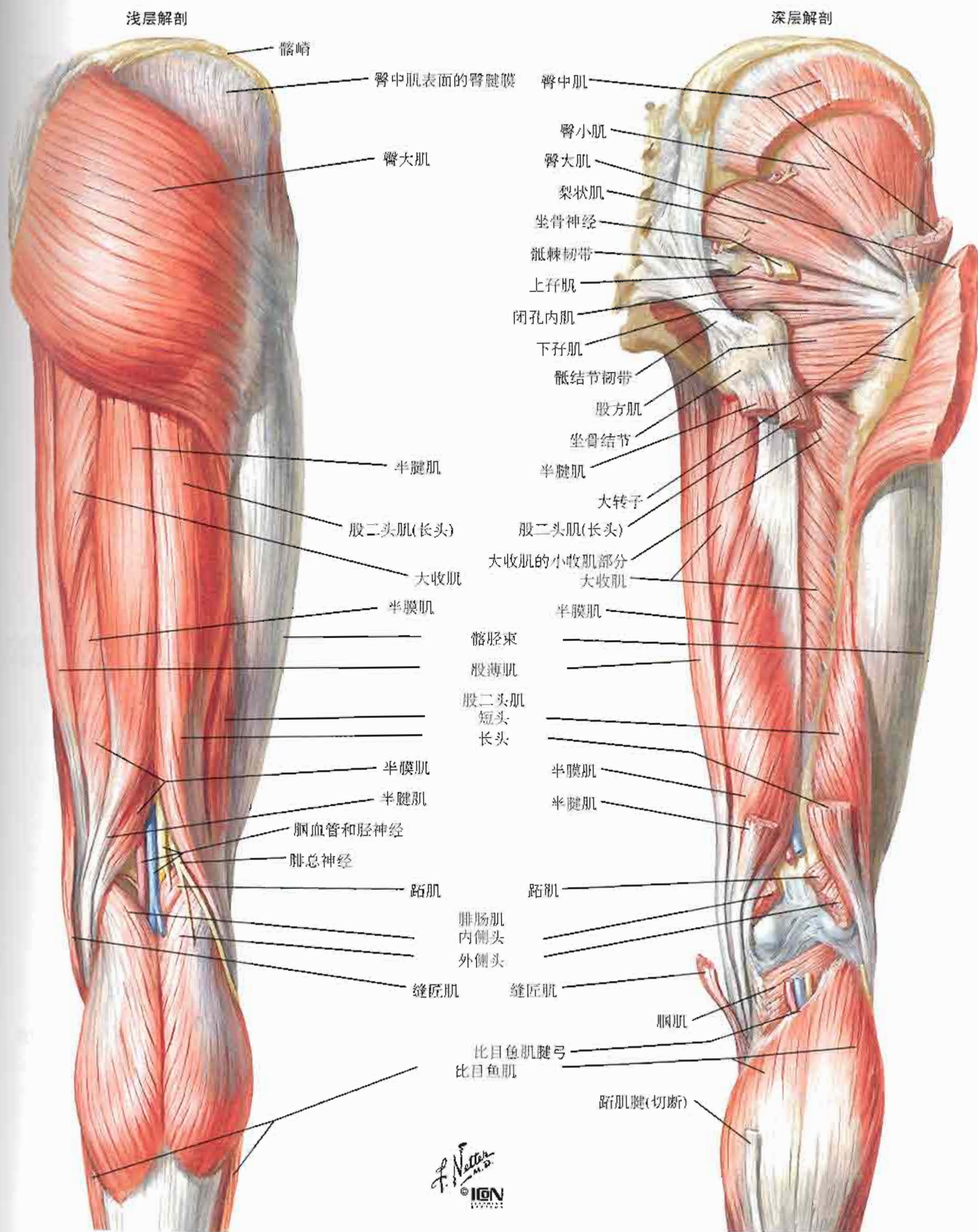


图476

梨状肌和闭孔内肌参见图343、344，闭孔外肌见图483



腰大肌和髂肌

参见图255

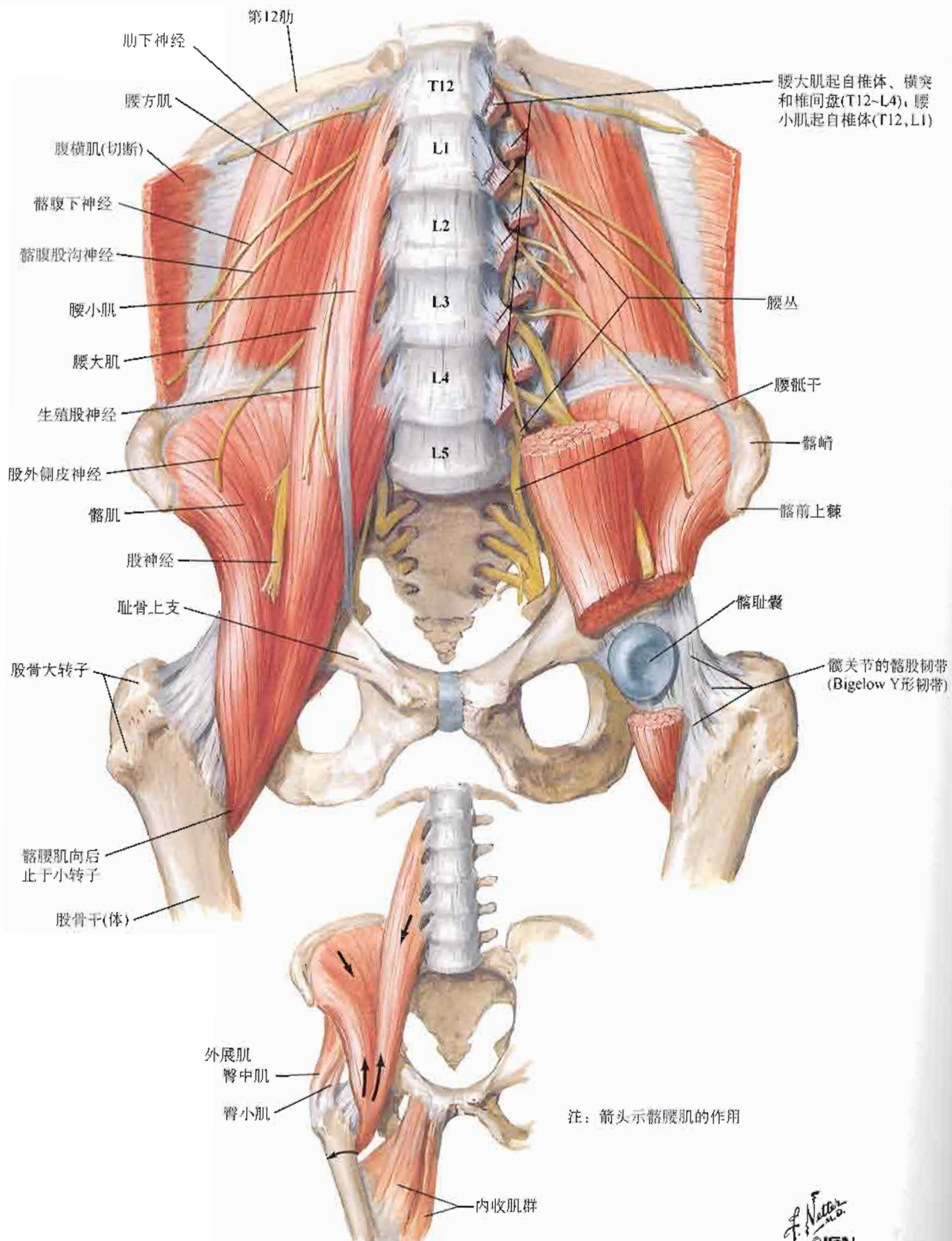
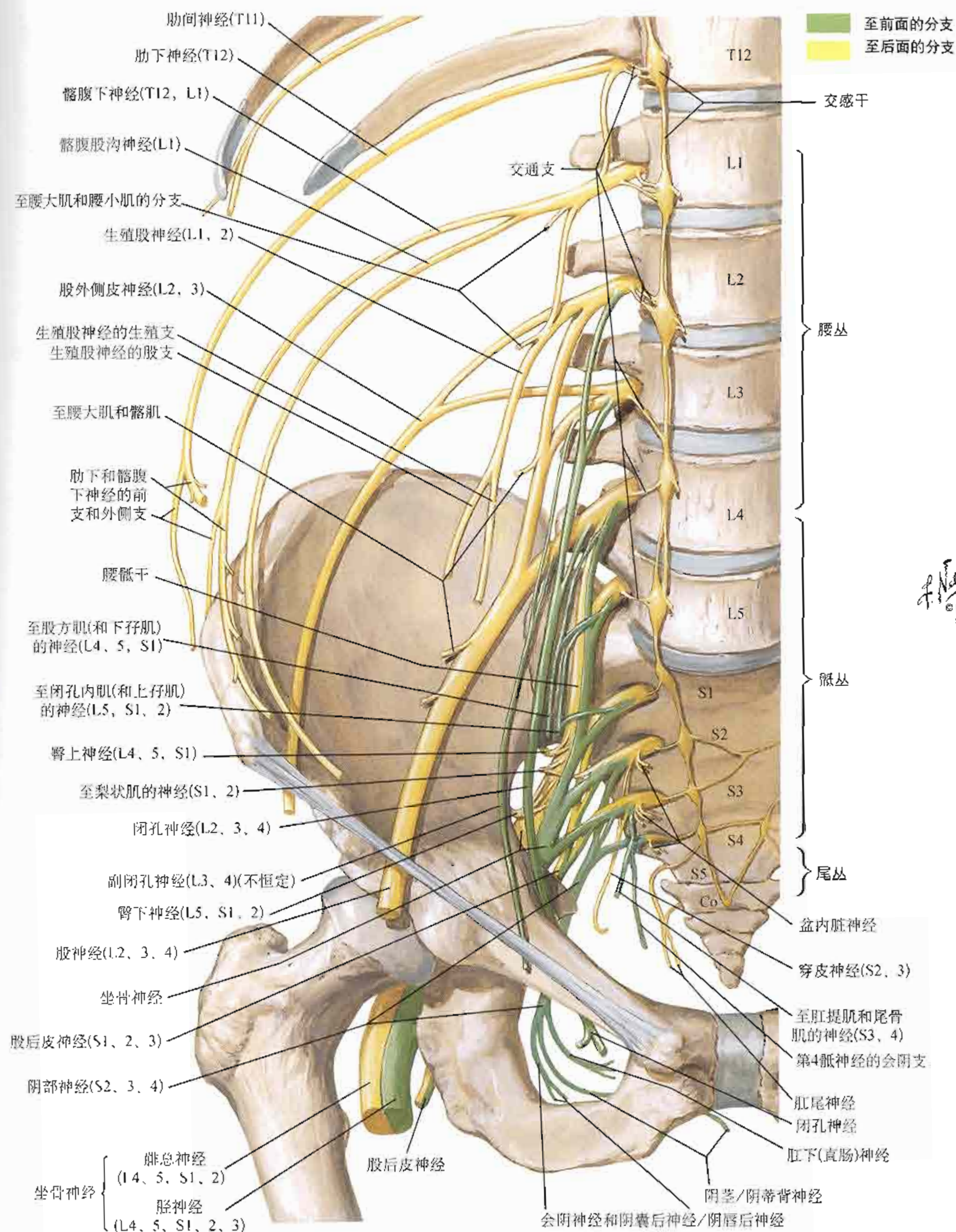


图478

下肢



示意图

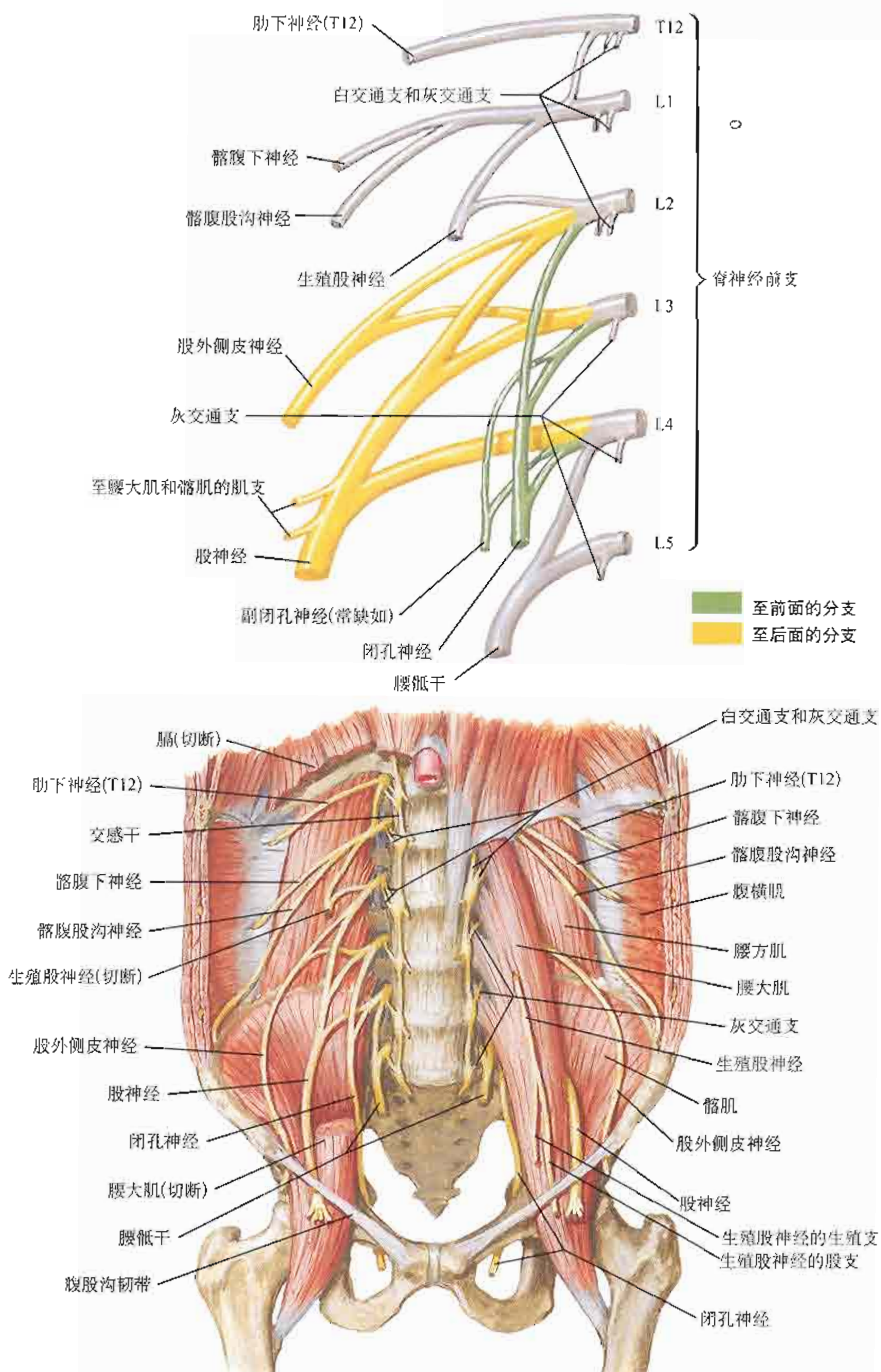
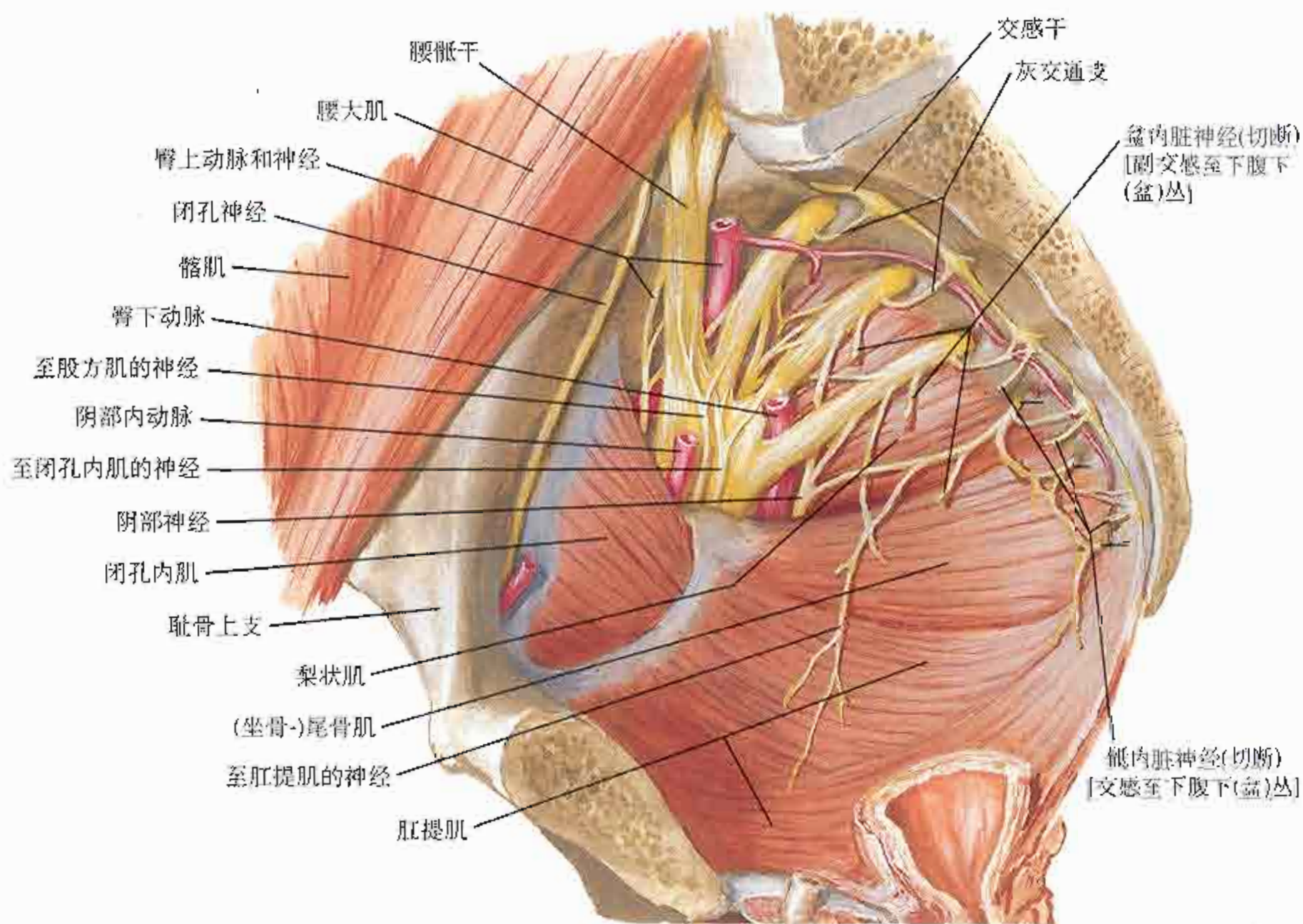
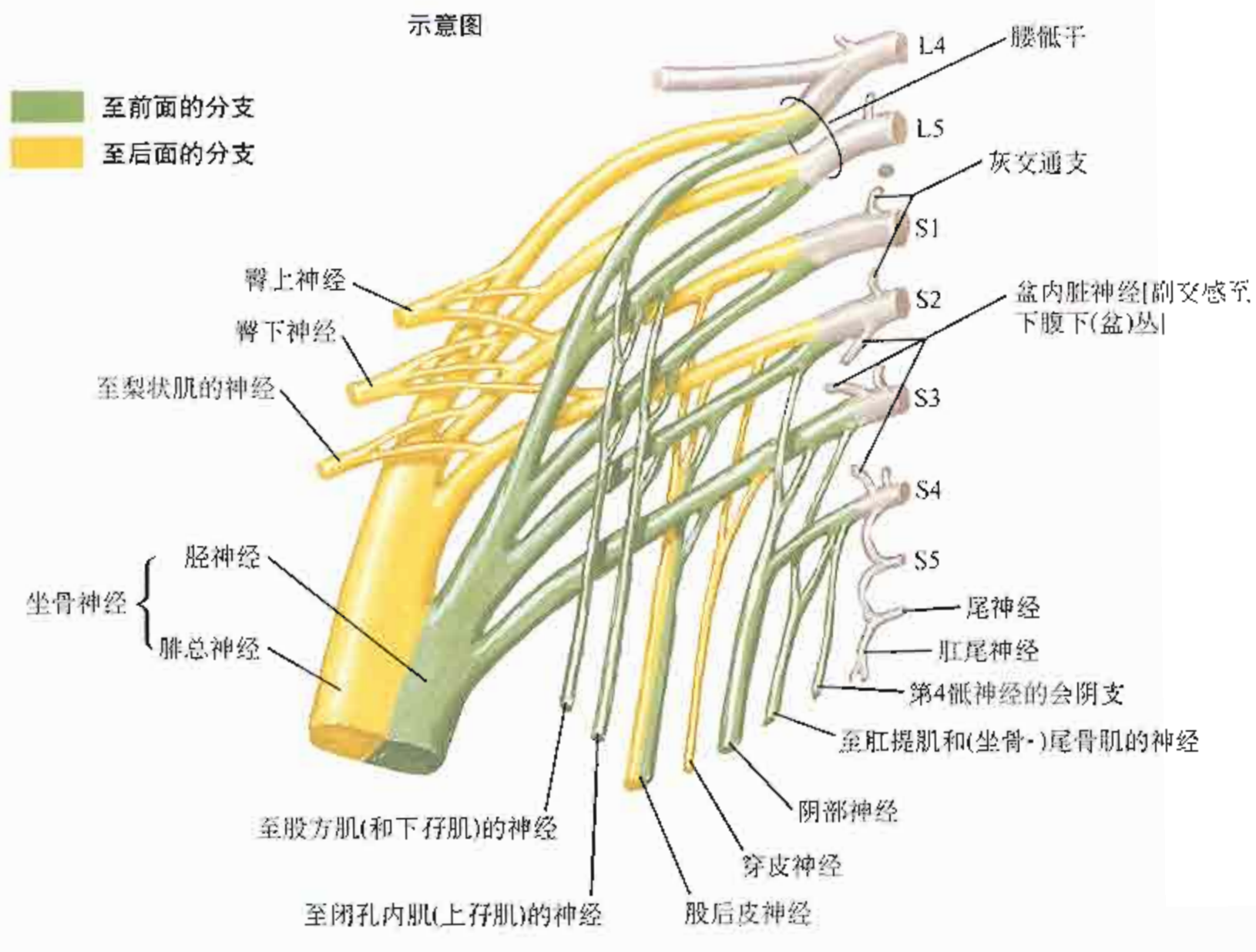


图480



本图位置：骨盆左侧半内侧并稍偏前面观

大腿的动脉和神经：前面观

参见图520

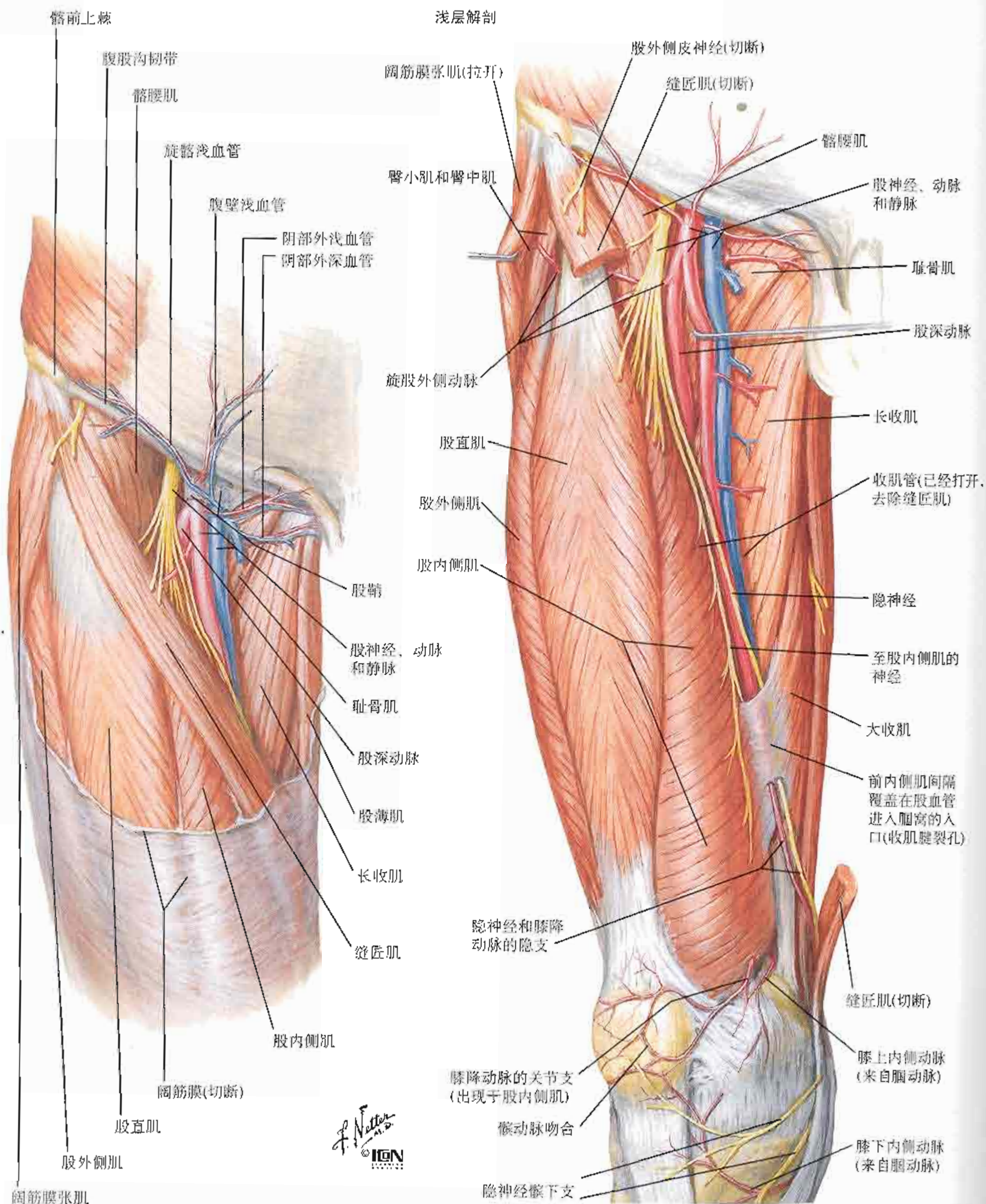
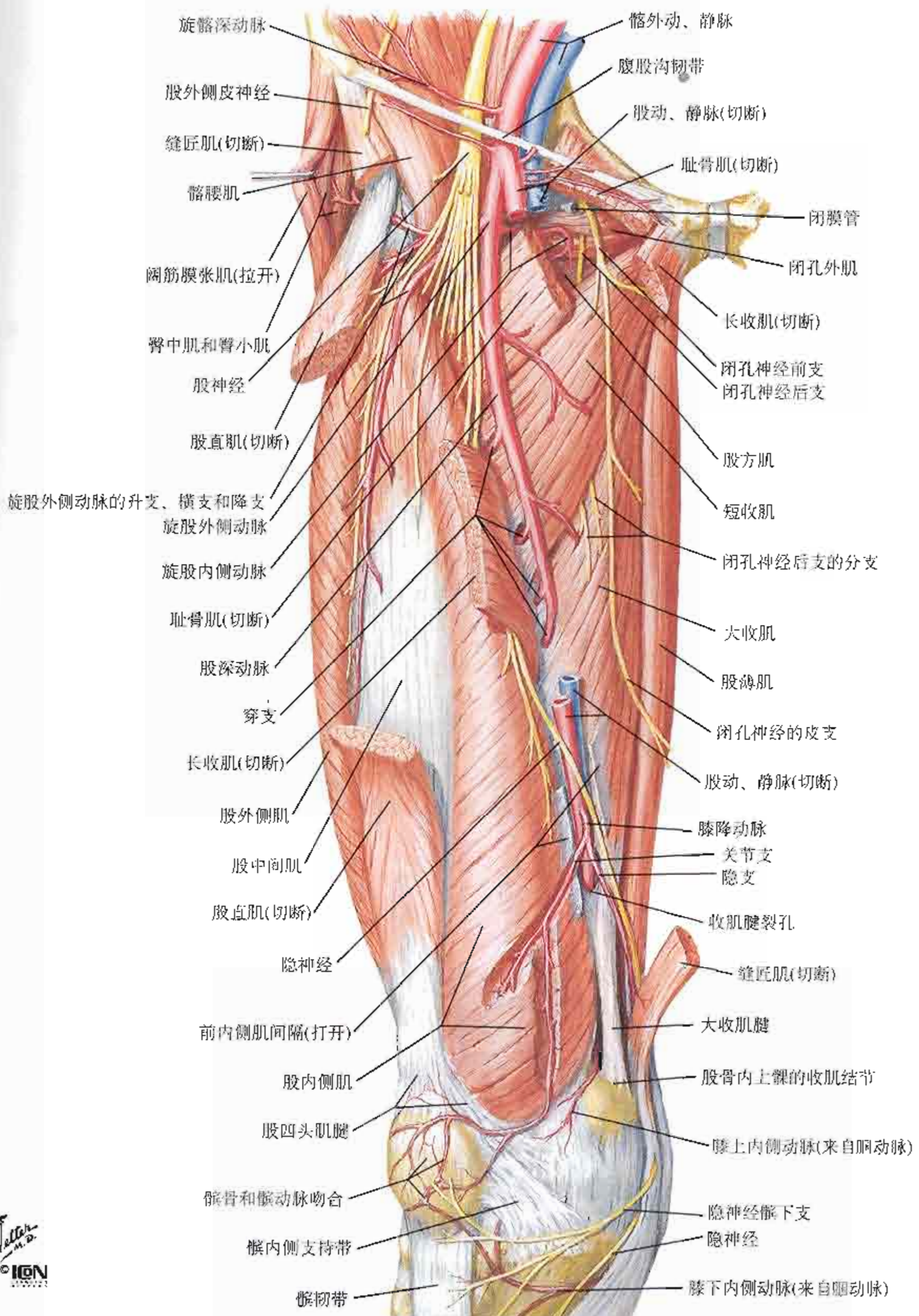


图482

下肢

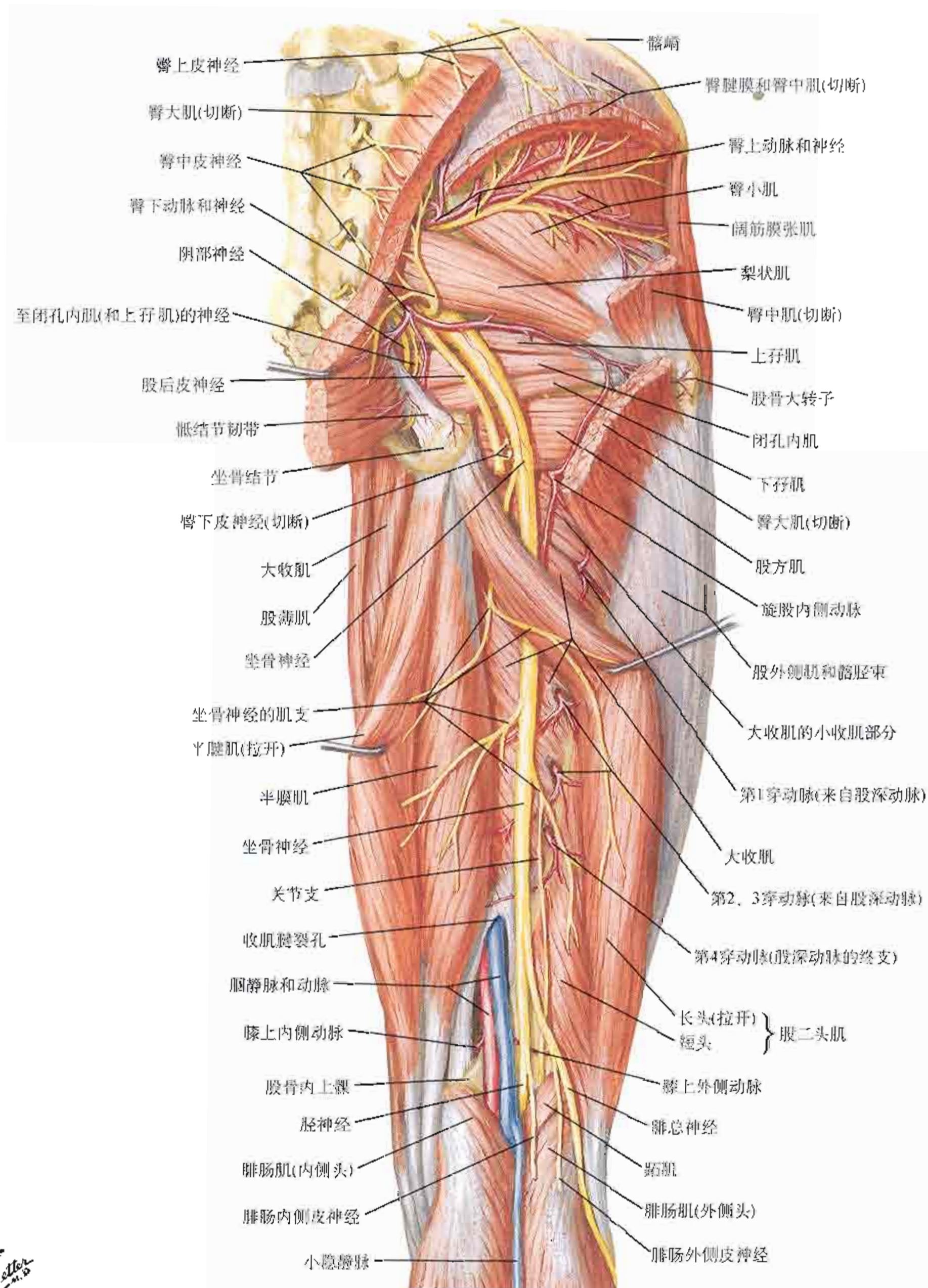
深层解剖



大腿的动脉和神经：后面观

参见图522

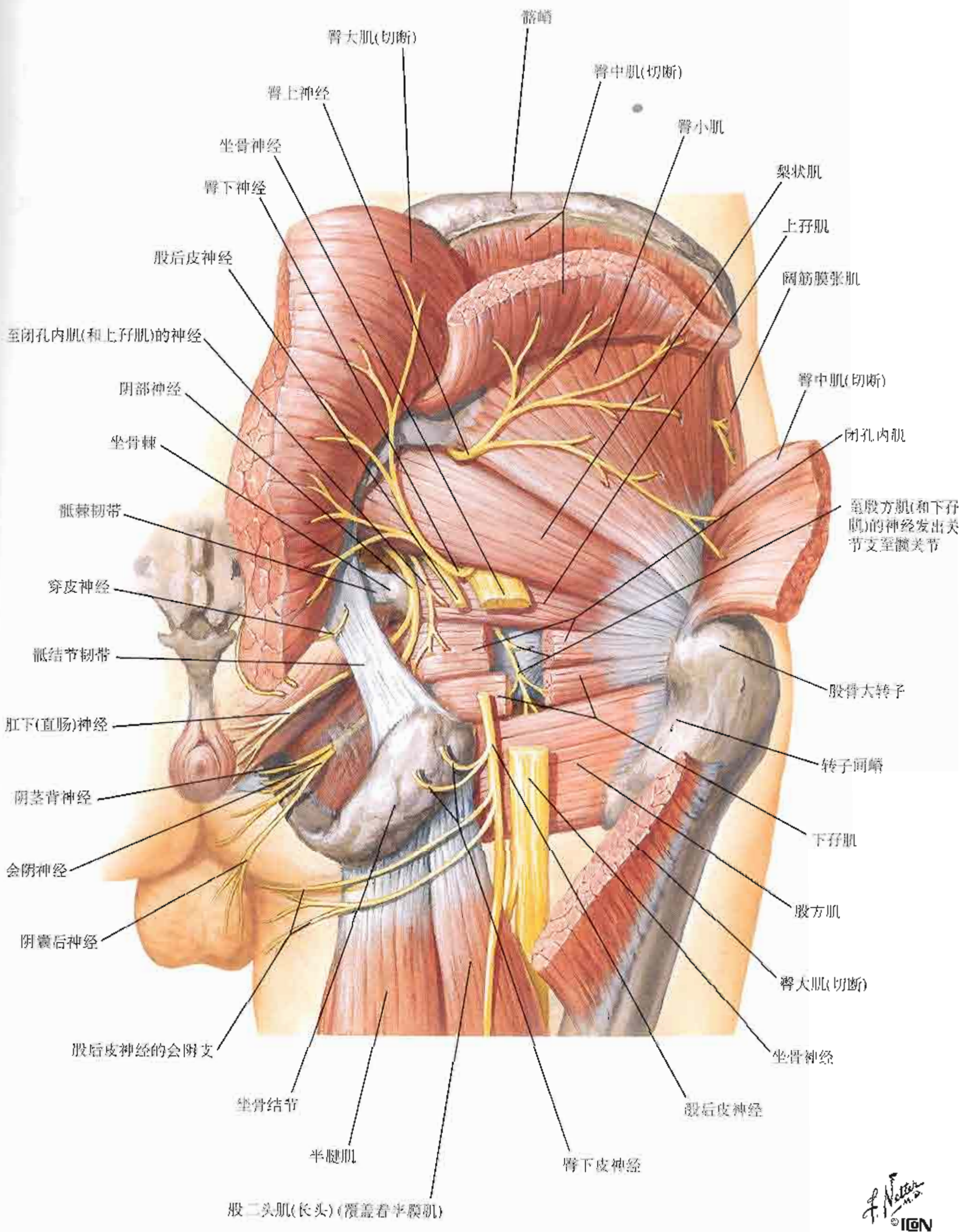
深层解剖



F. Netter M.D.
© IGV

图484

下肢



F. Netter M.D.
© ION

股骨头和股骨颈的动脉

参见图494

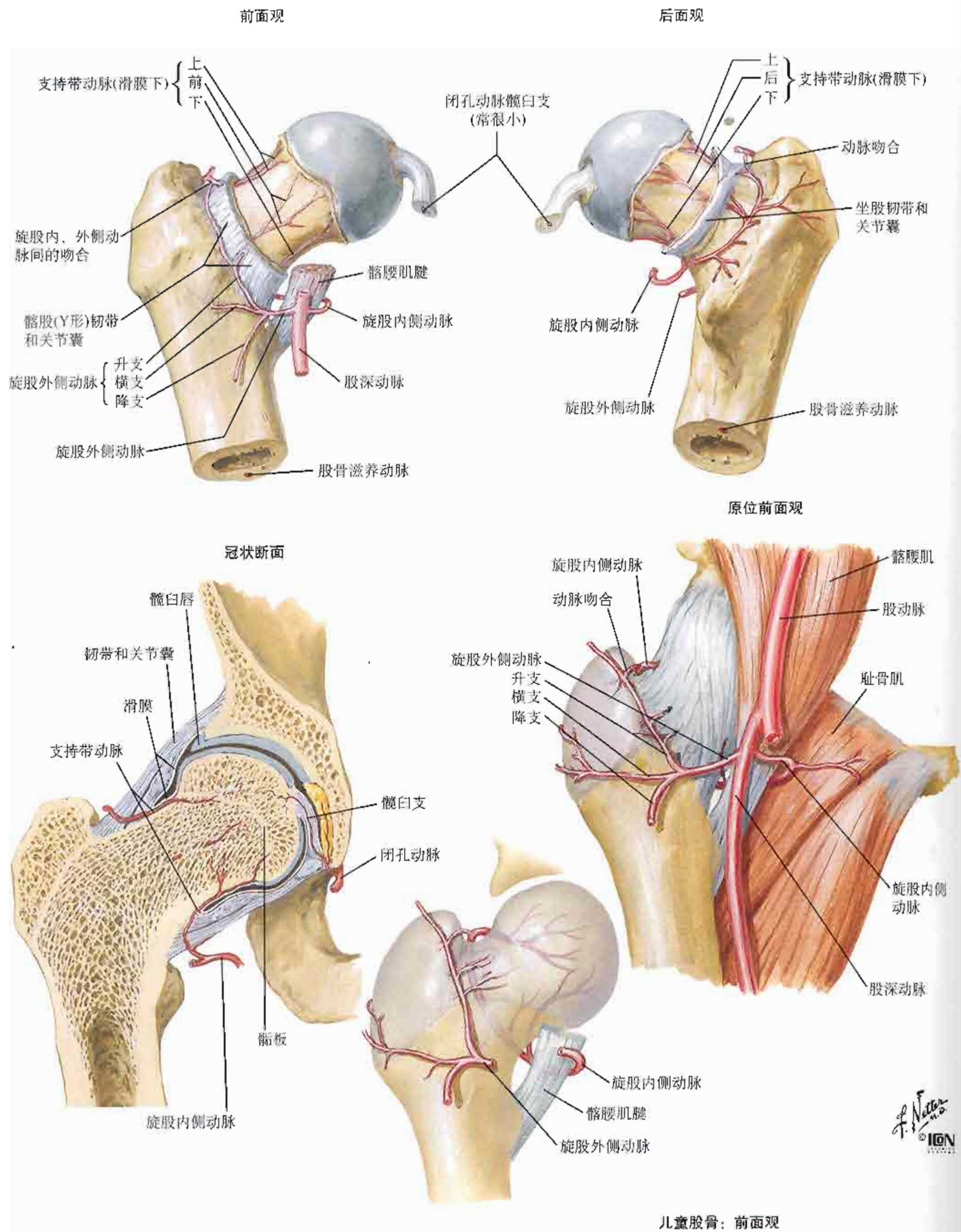
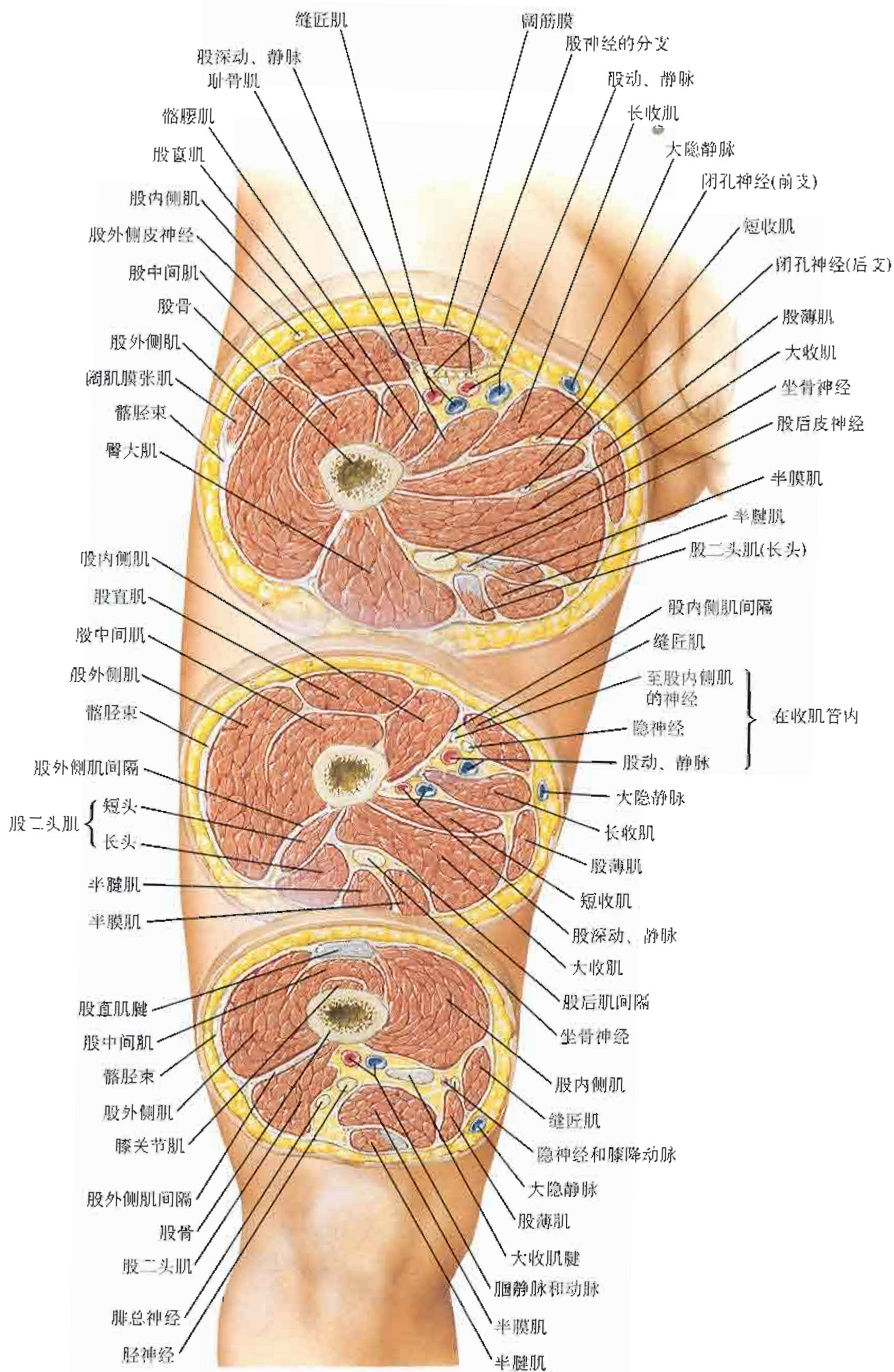


图486

下肢



F. Netter M.D.
© 2004

膝：外侧面和内侧面观

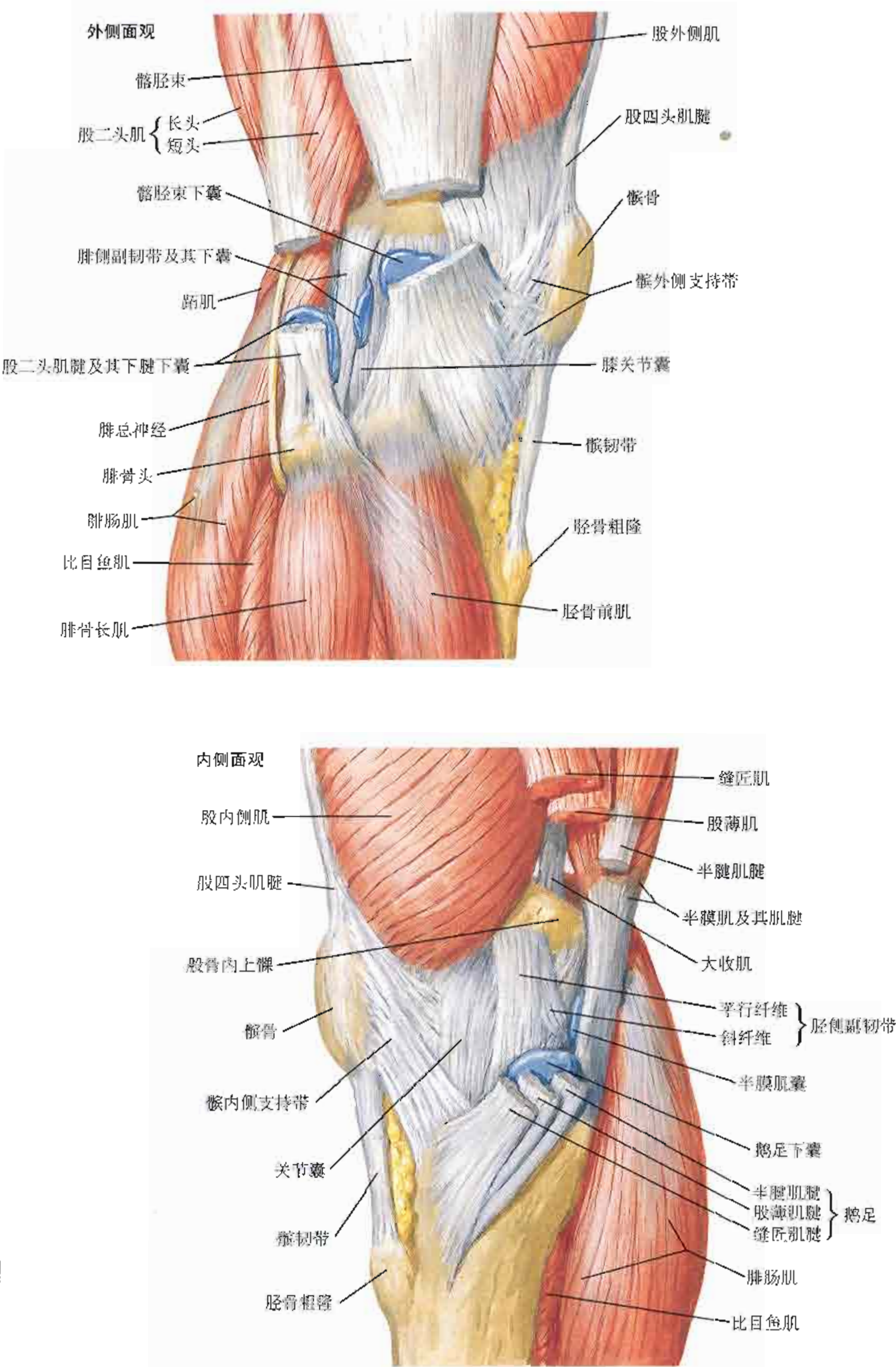
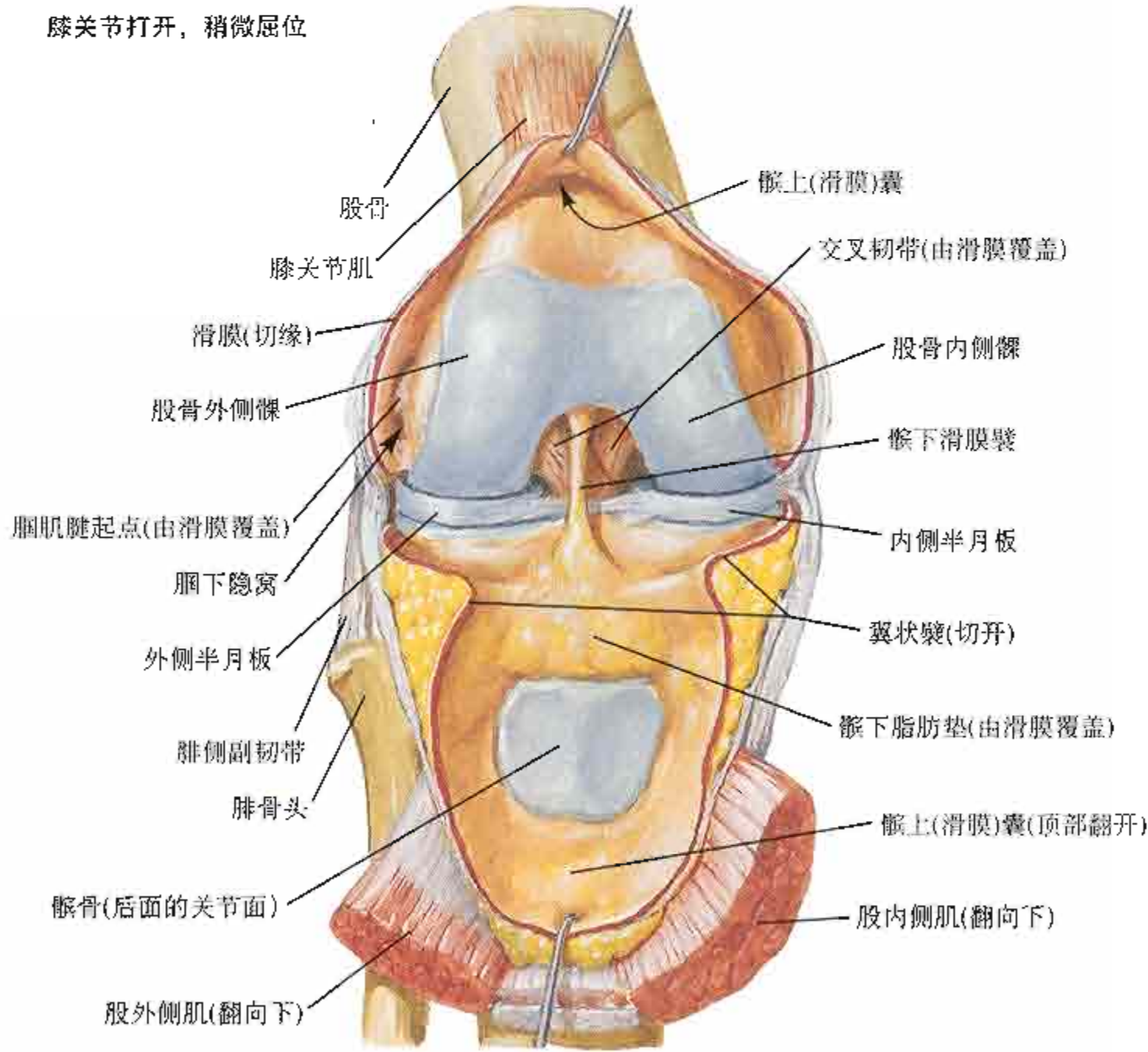
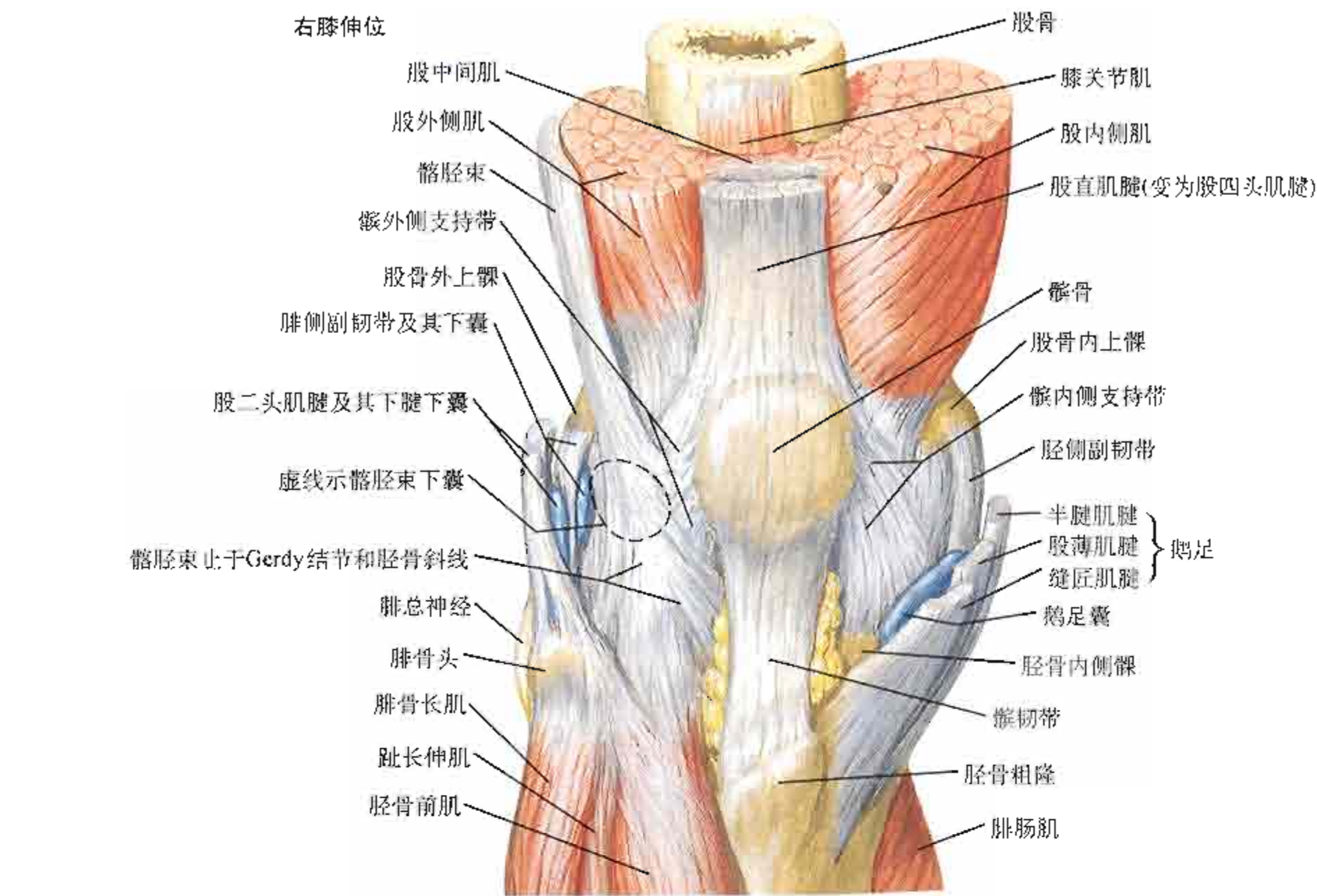
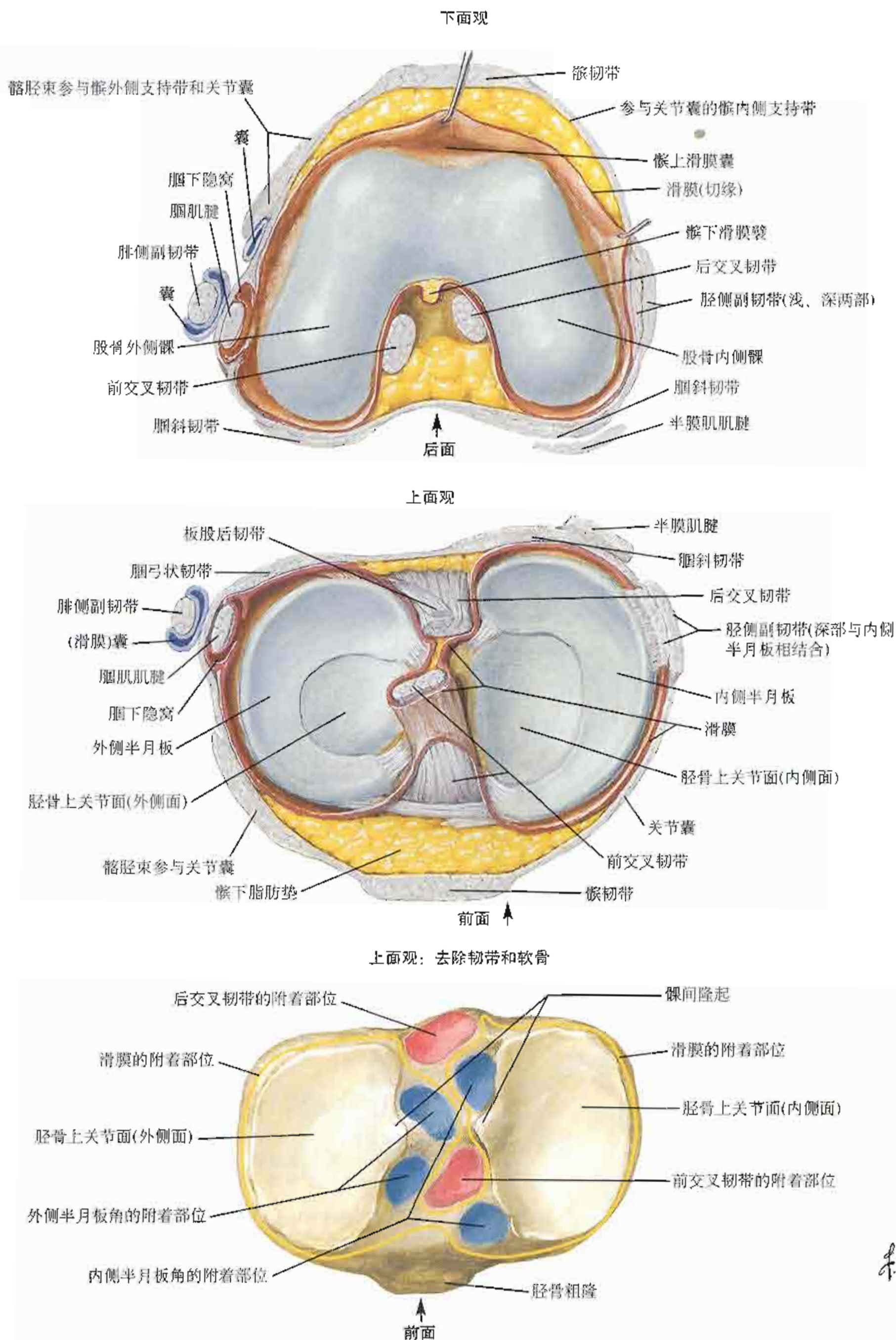
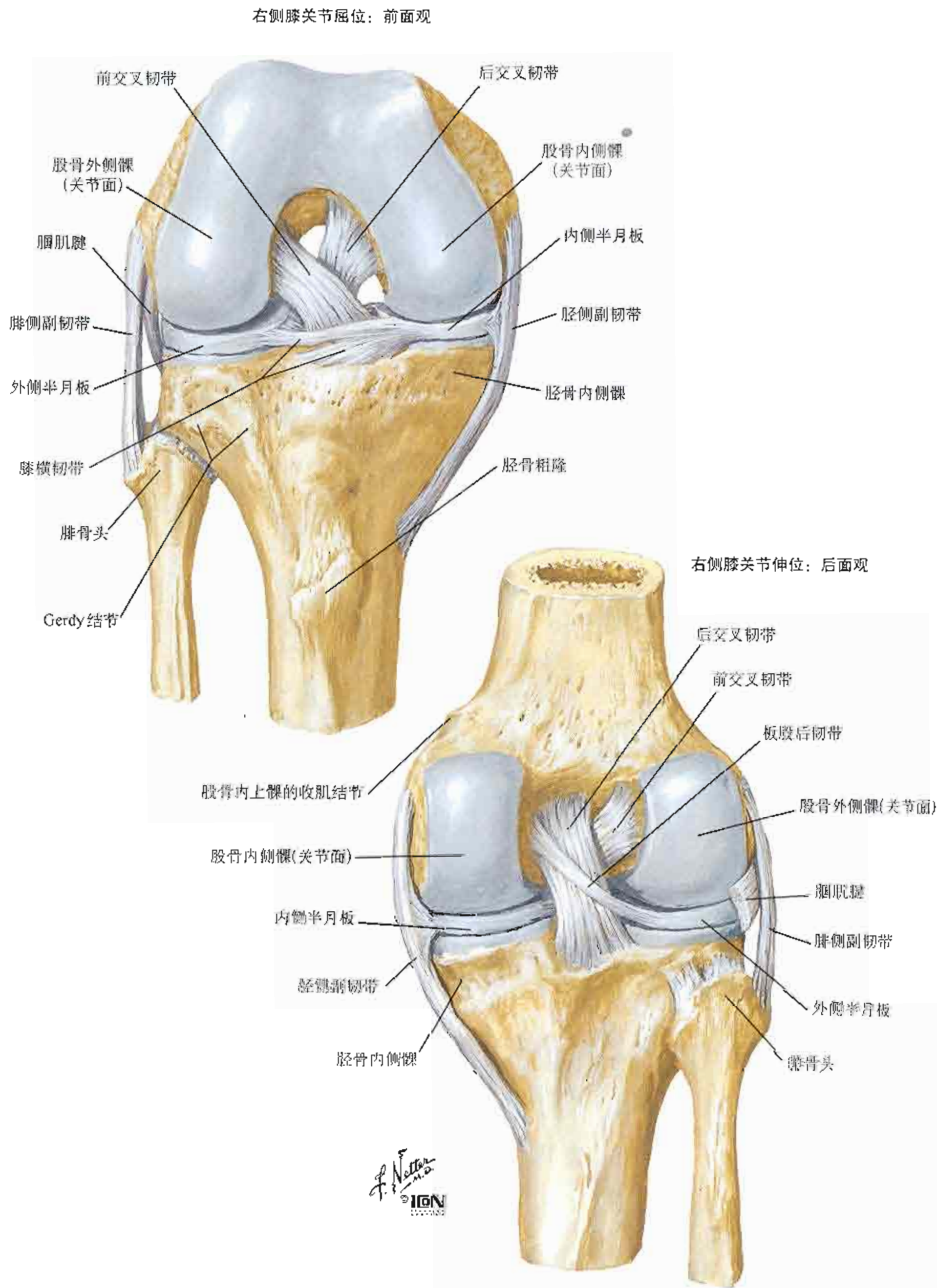


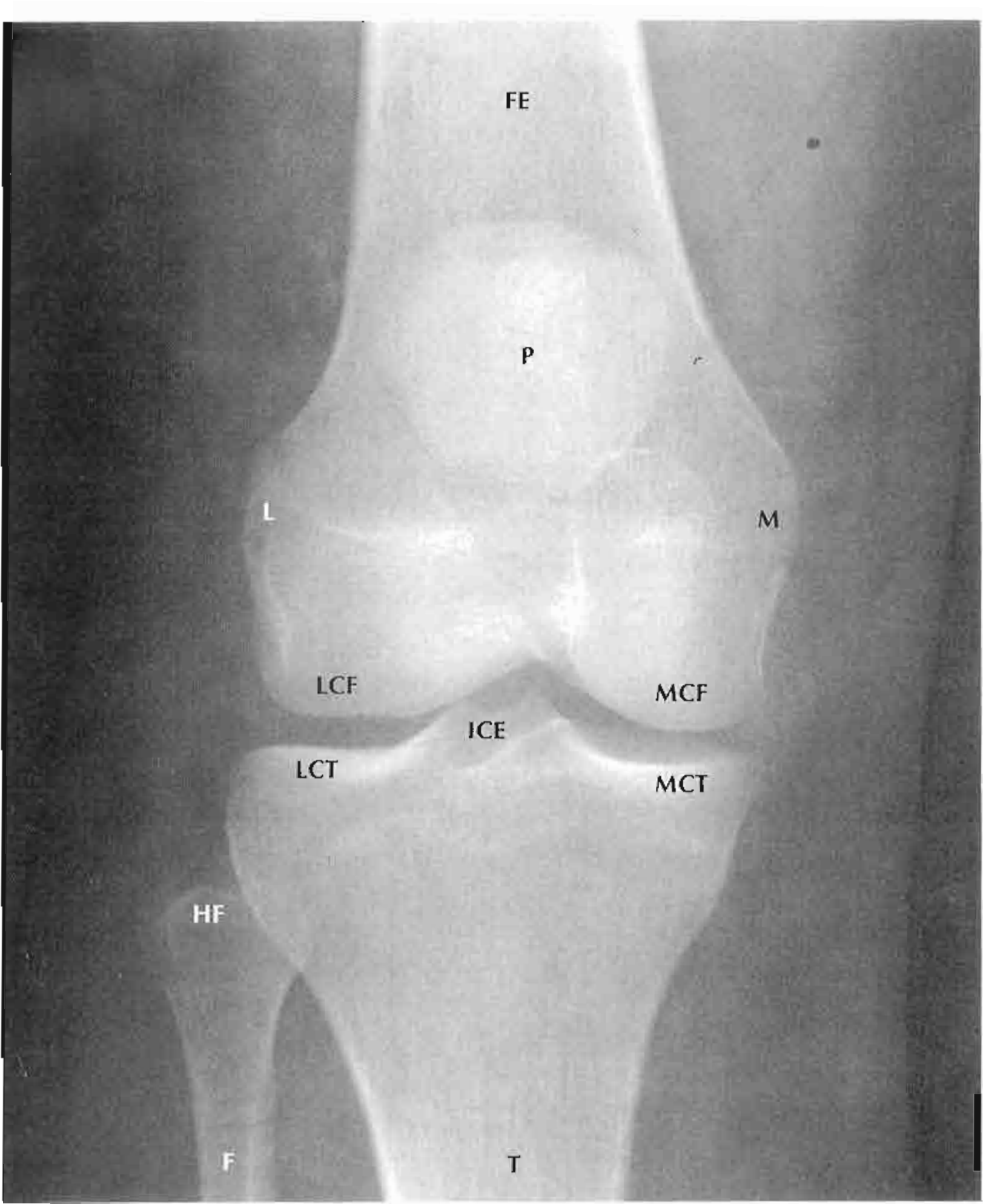
图488



F. Netter M.D.
© IGM
LONDON

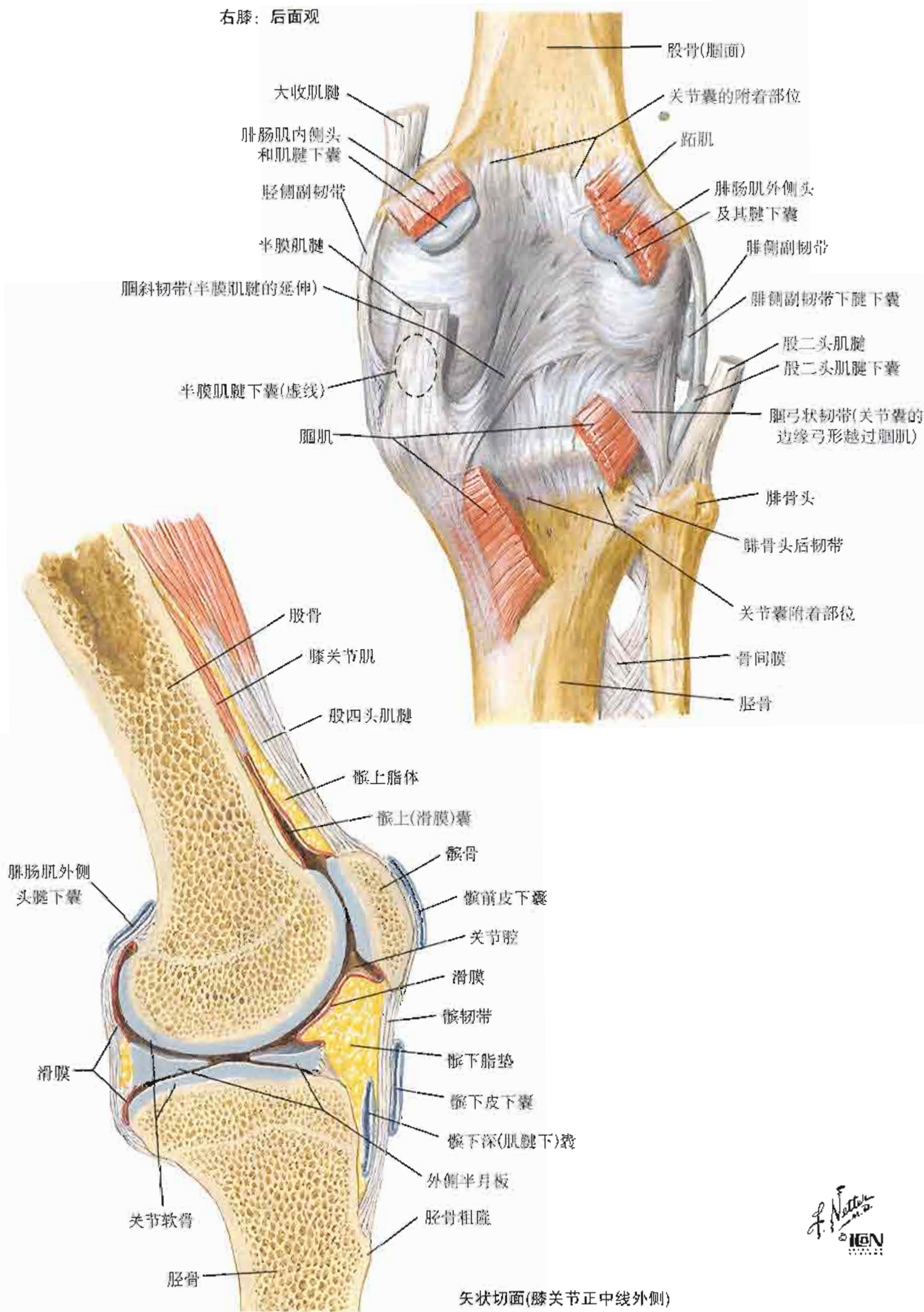






- F 腓骨
- FE 股骨
- HF 髌骨头
- ICE 髌间隆起
- L 外上髌
- LCF 股骨外侧髌
- LCT 胫骨外侧髌
- M 内上髌
- MCF 股骨内侧髌
- MCT 胫骨内侧髌
- P 髌骨
- T 胫骨

图492



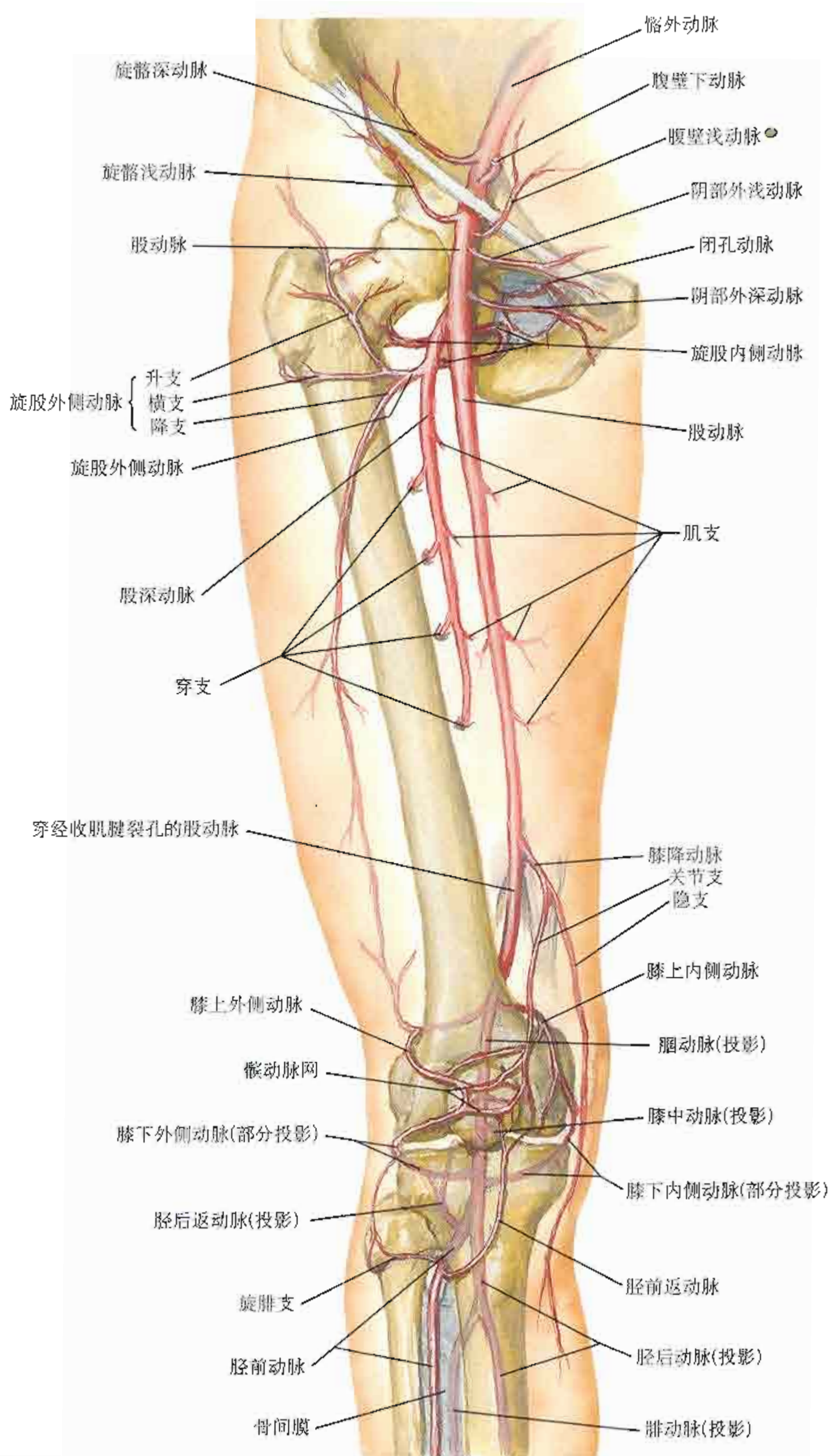
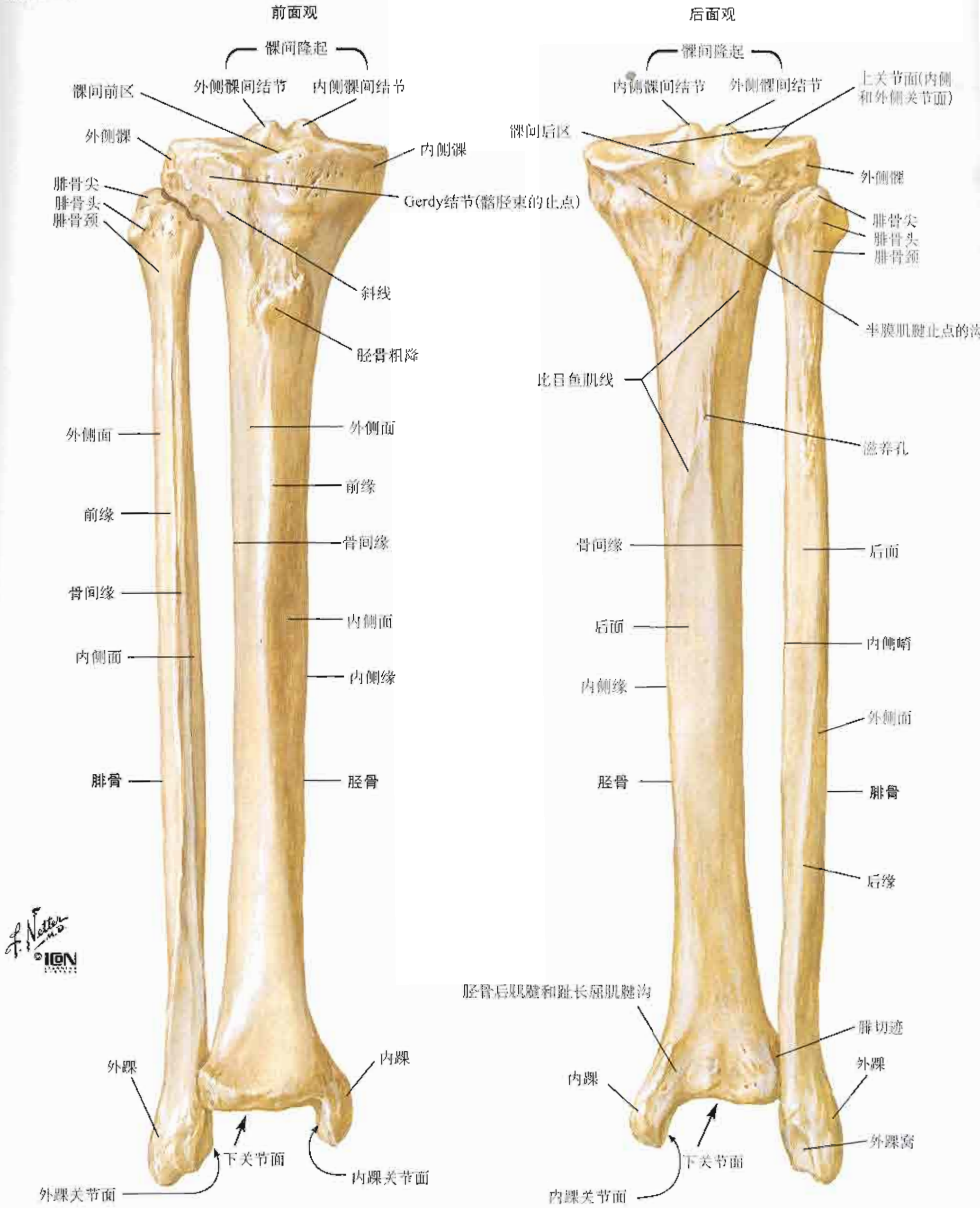


图494

右侧小腿骨



小腿

图495

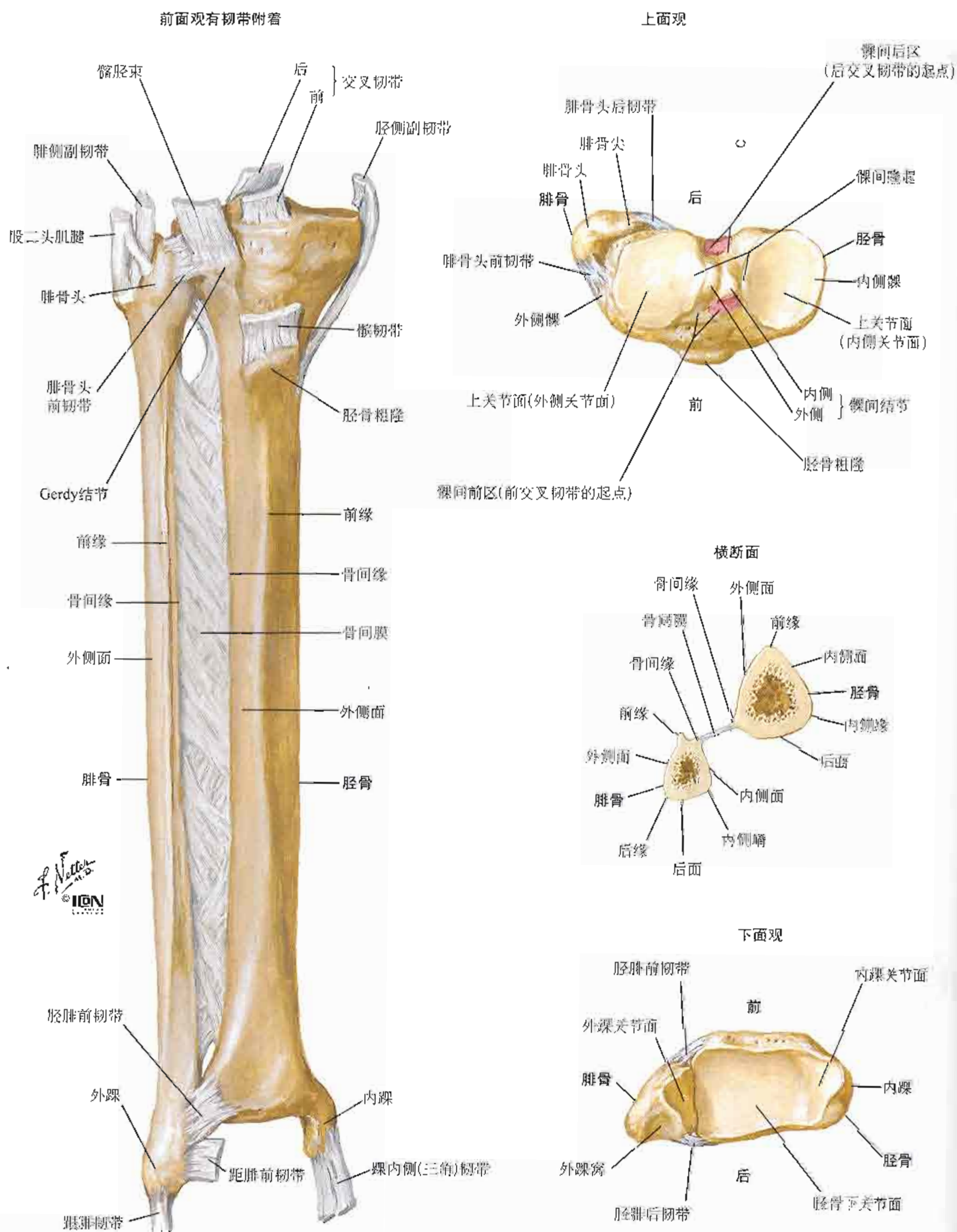



图496




运动科学网站



运动科学网站



运动科学网站



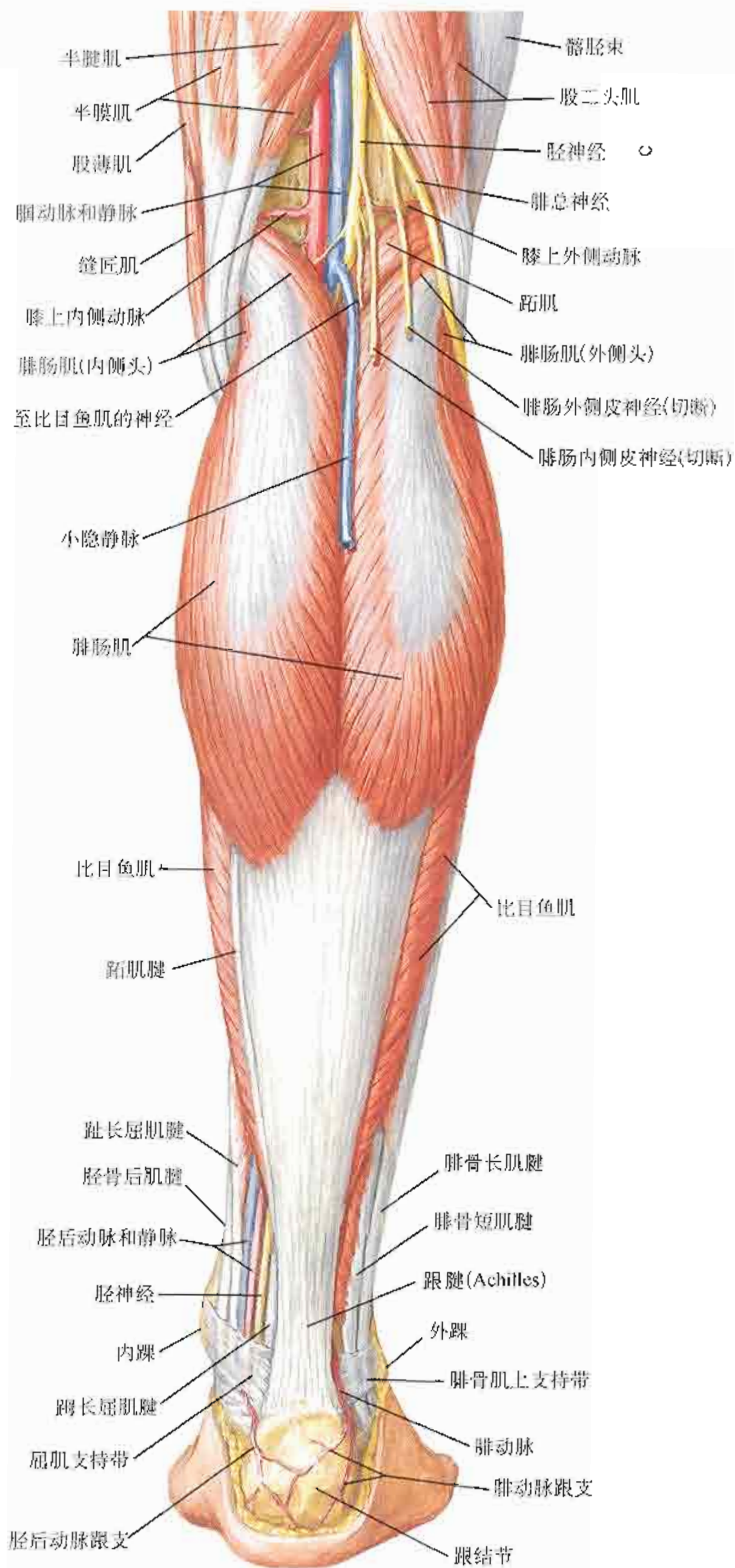
运动科学网站



运动科学网站

小腿肌 (浅层解剖)：后面观

参见图522



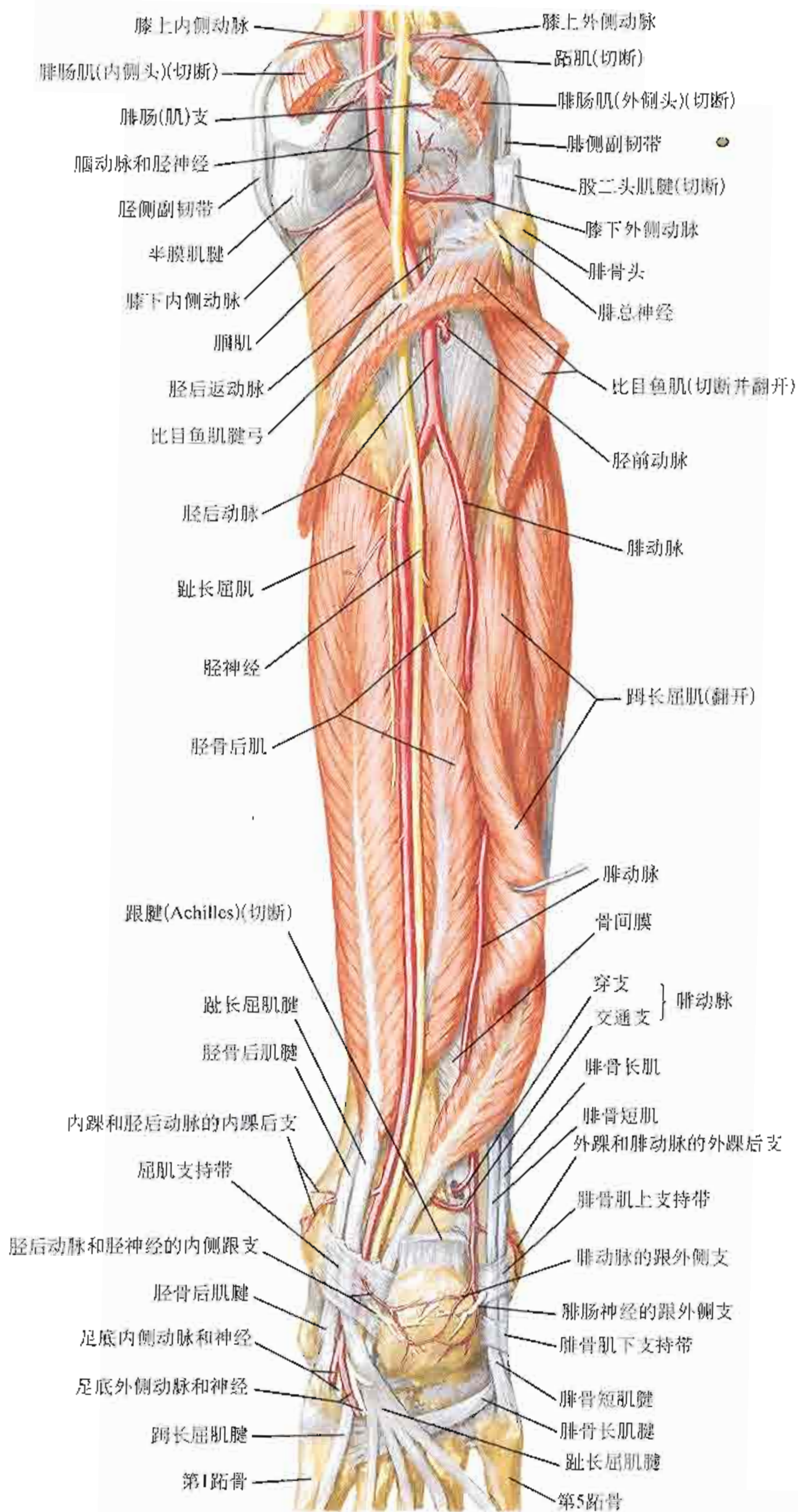
F. Netter M.D.
H&N

图498

下肢

小腿肌 (深层解剖)：后面观

参见图523



F. Netter M.D.
© IGM

图500

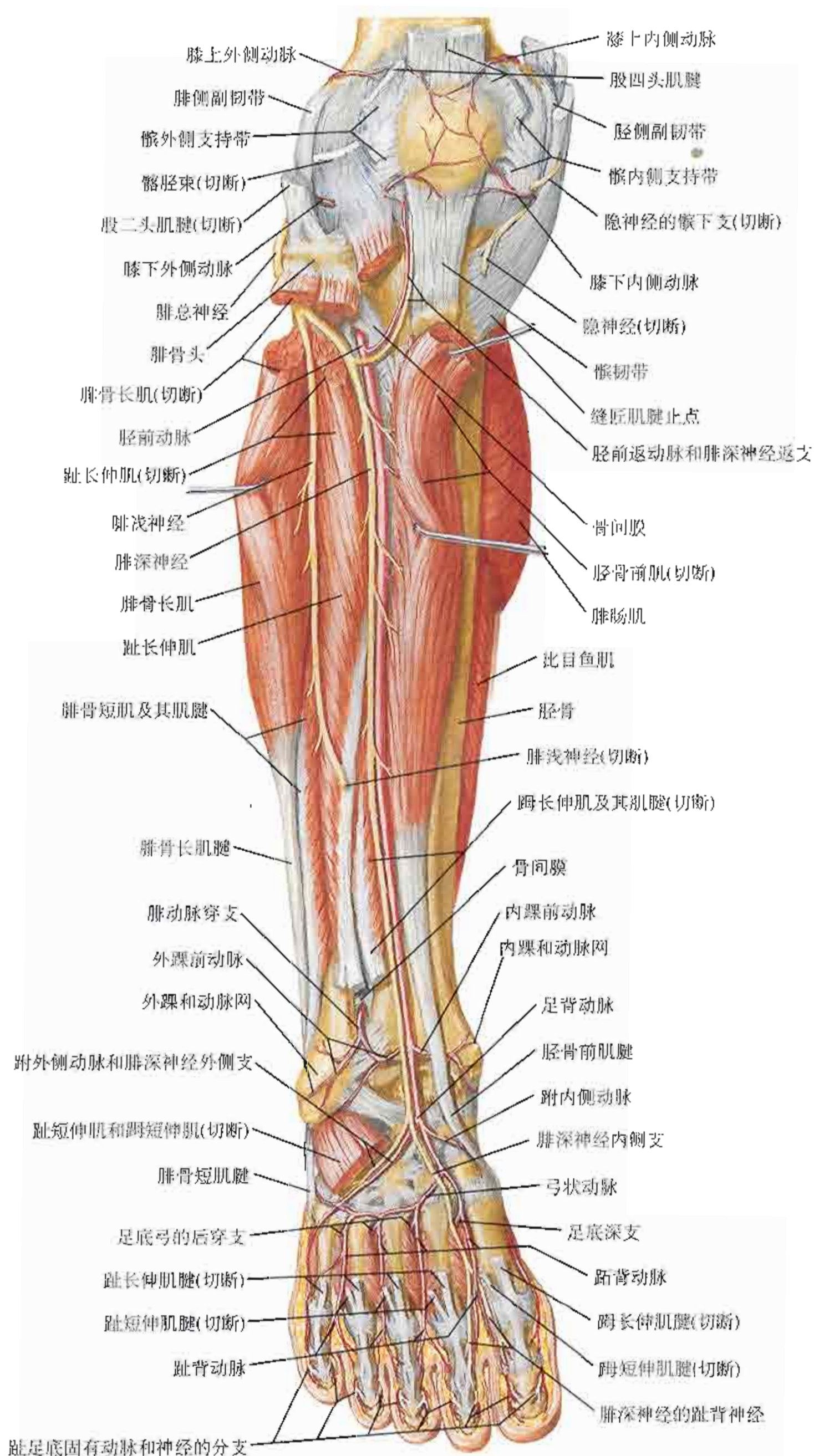
下肢

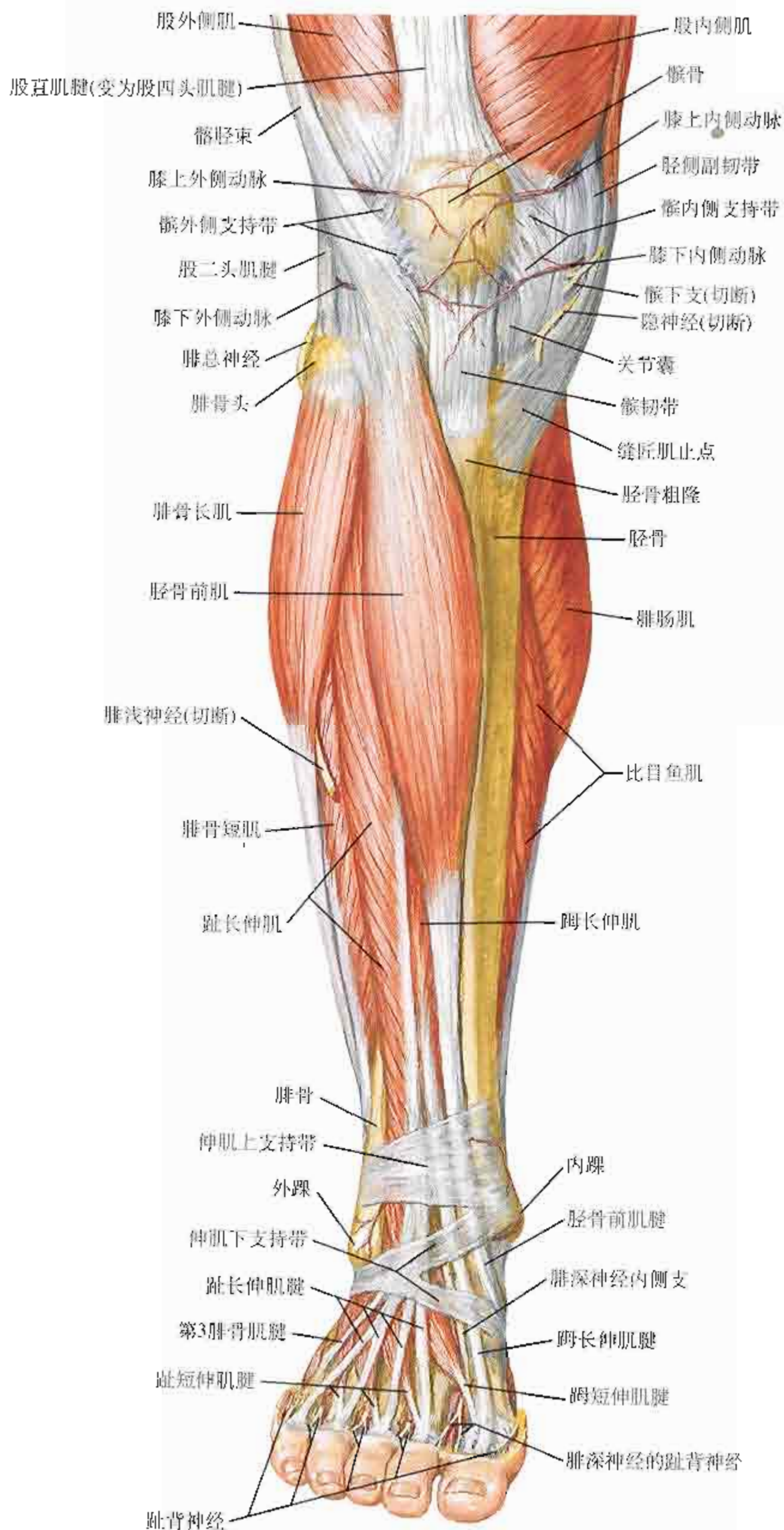

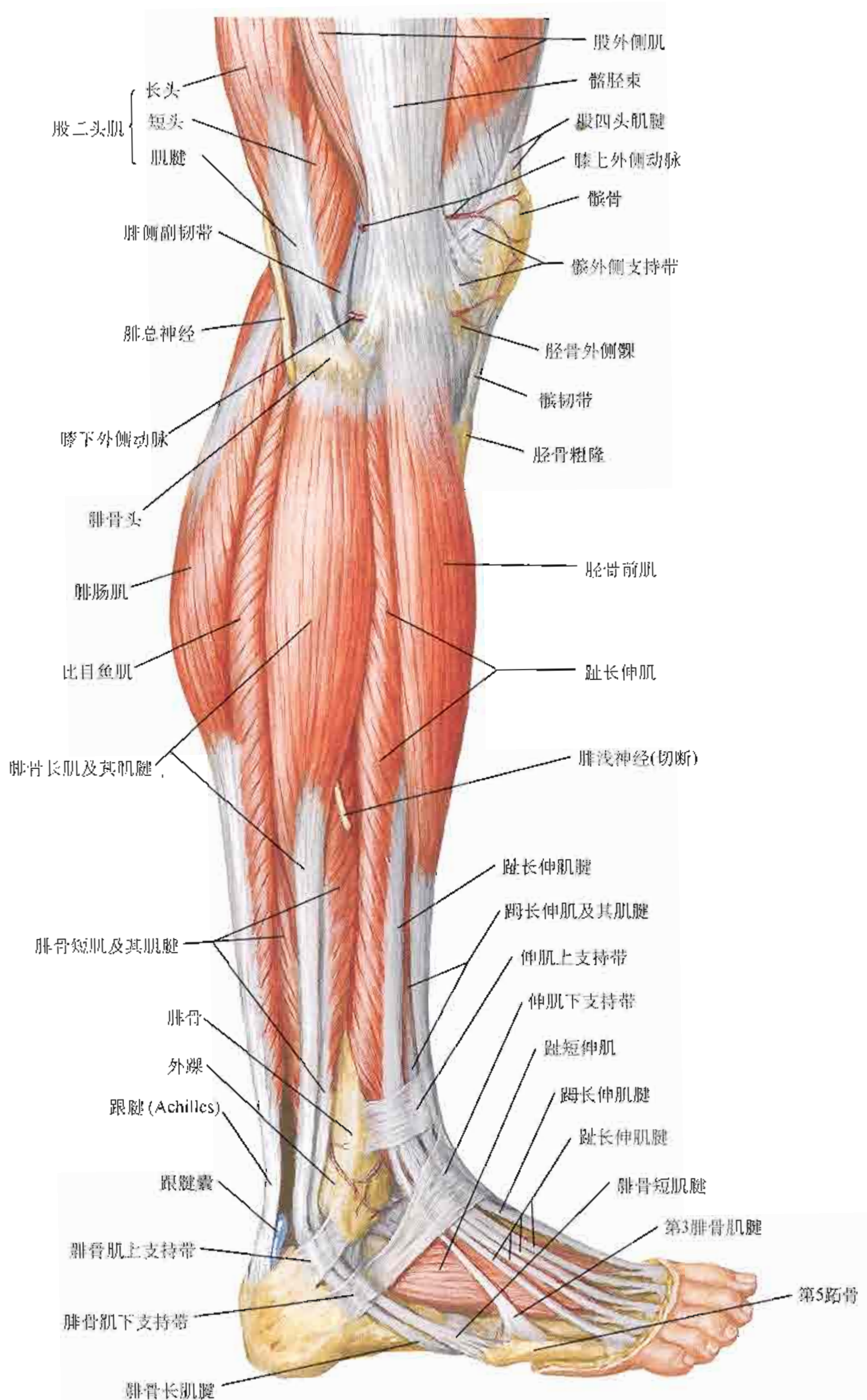
FIG 501

小腿肌(深层解剖): 前面观

参见图 524



参见图 524



F. Netter M.D.
ION

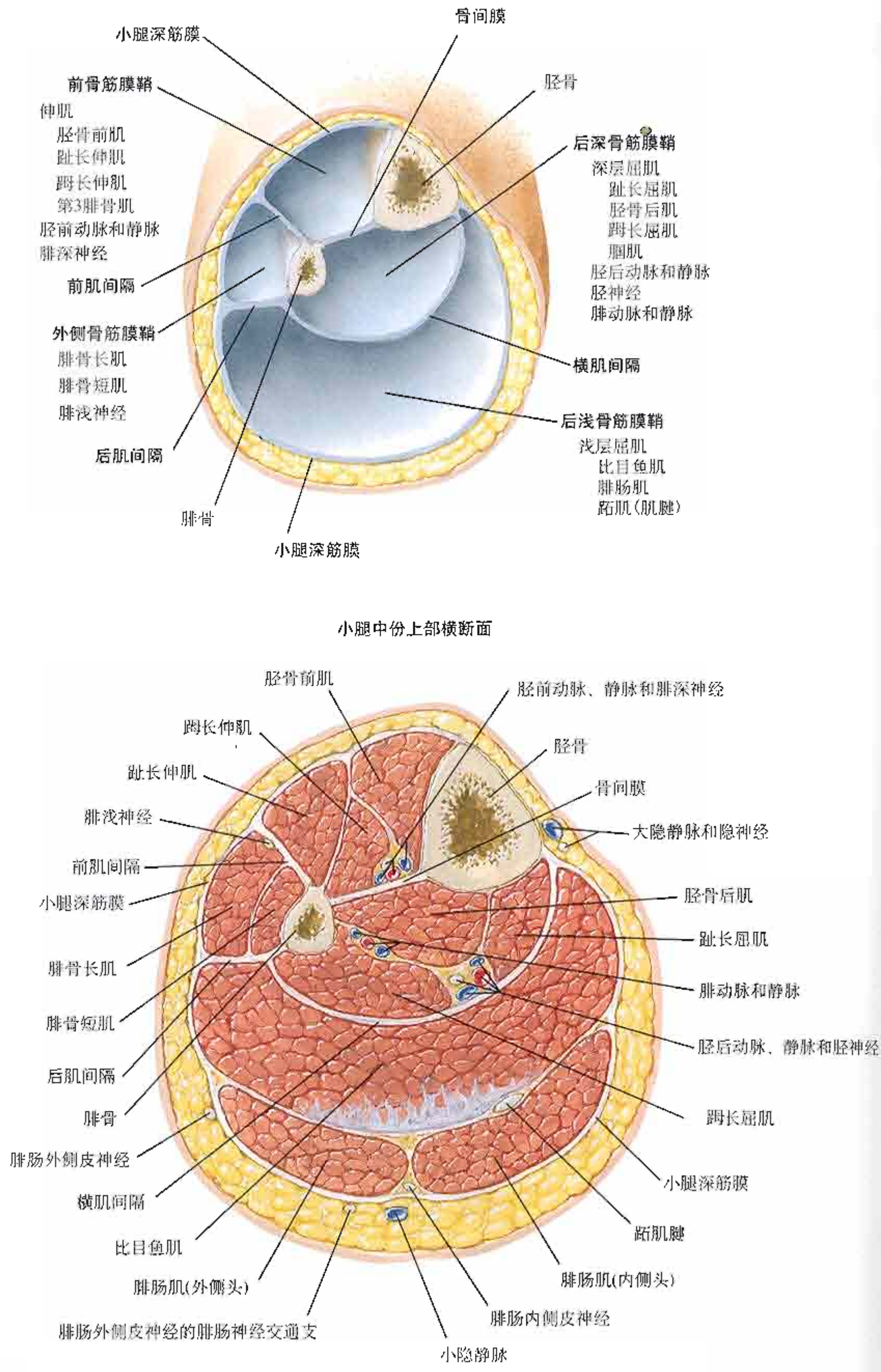
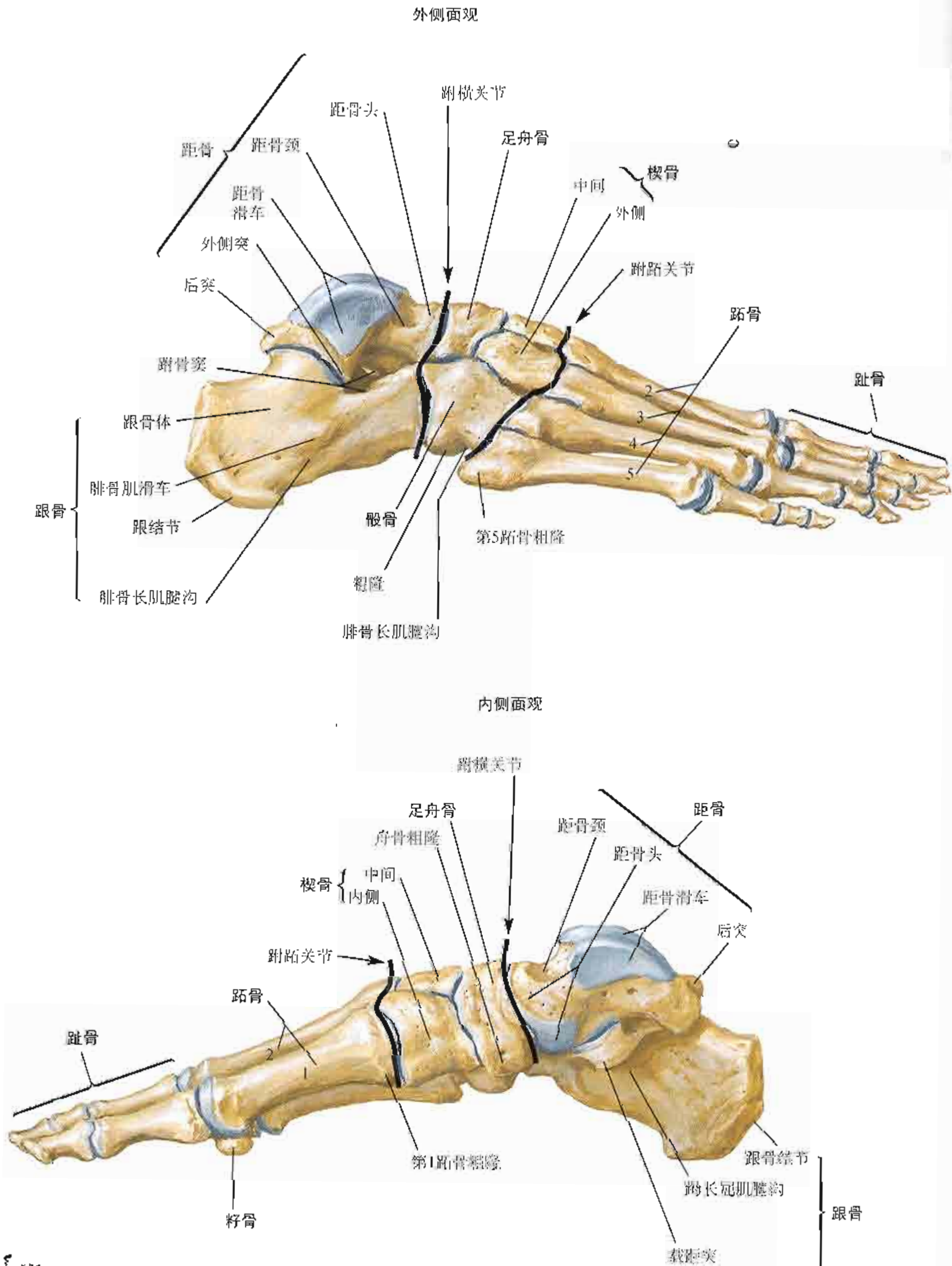
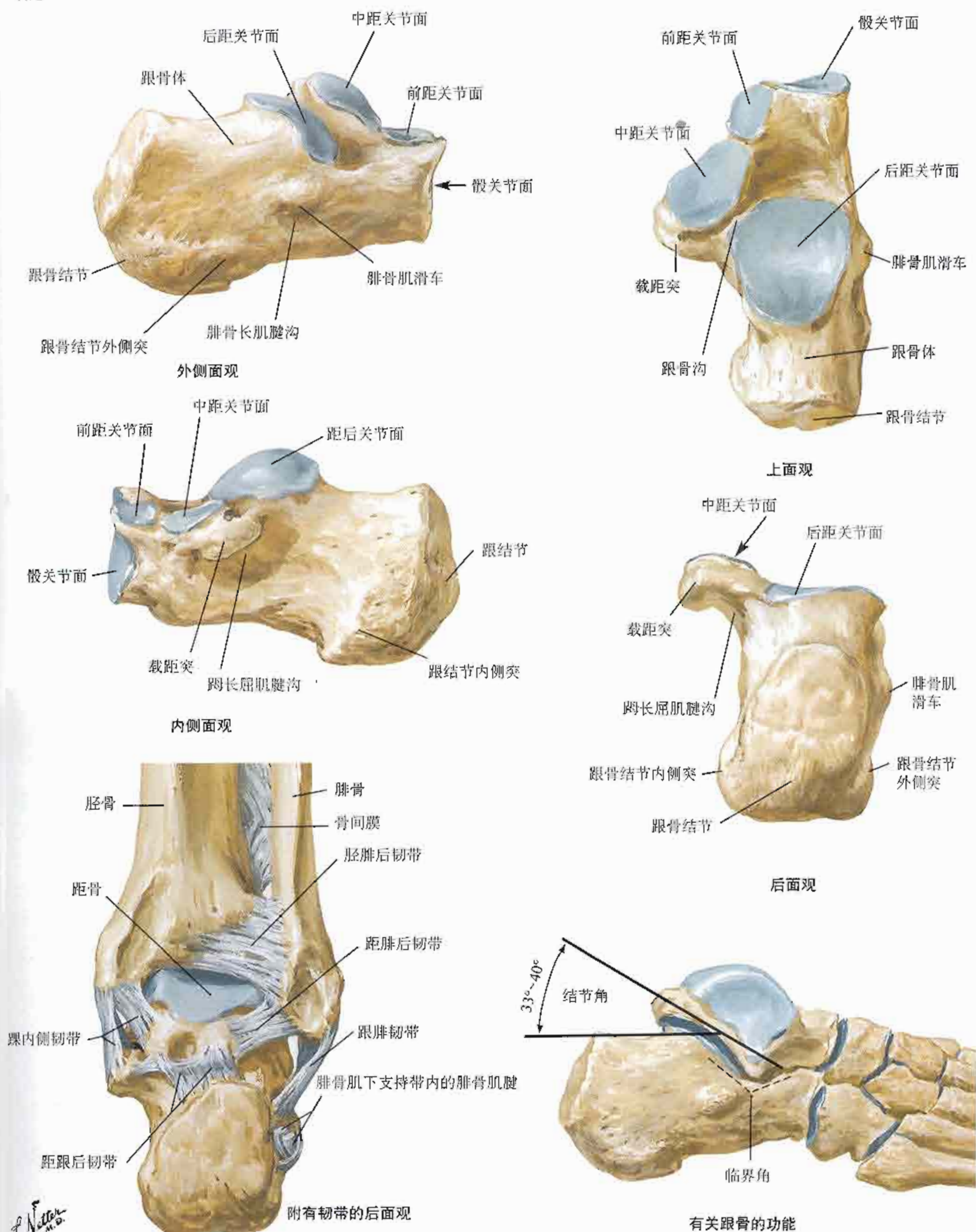
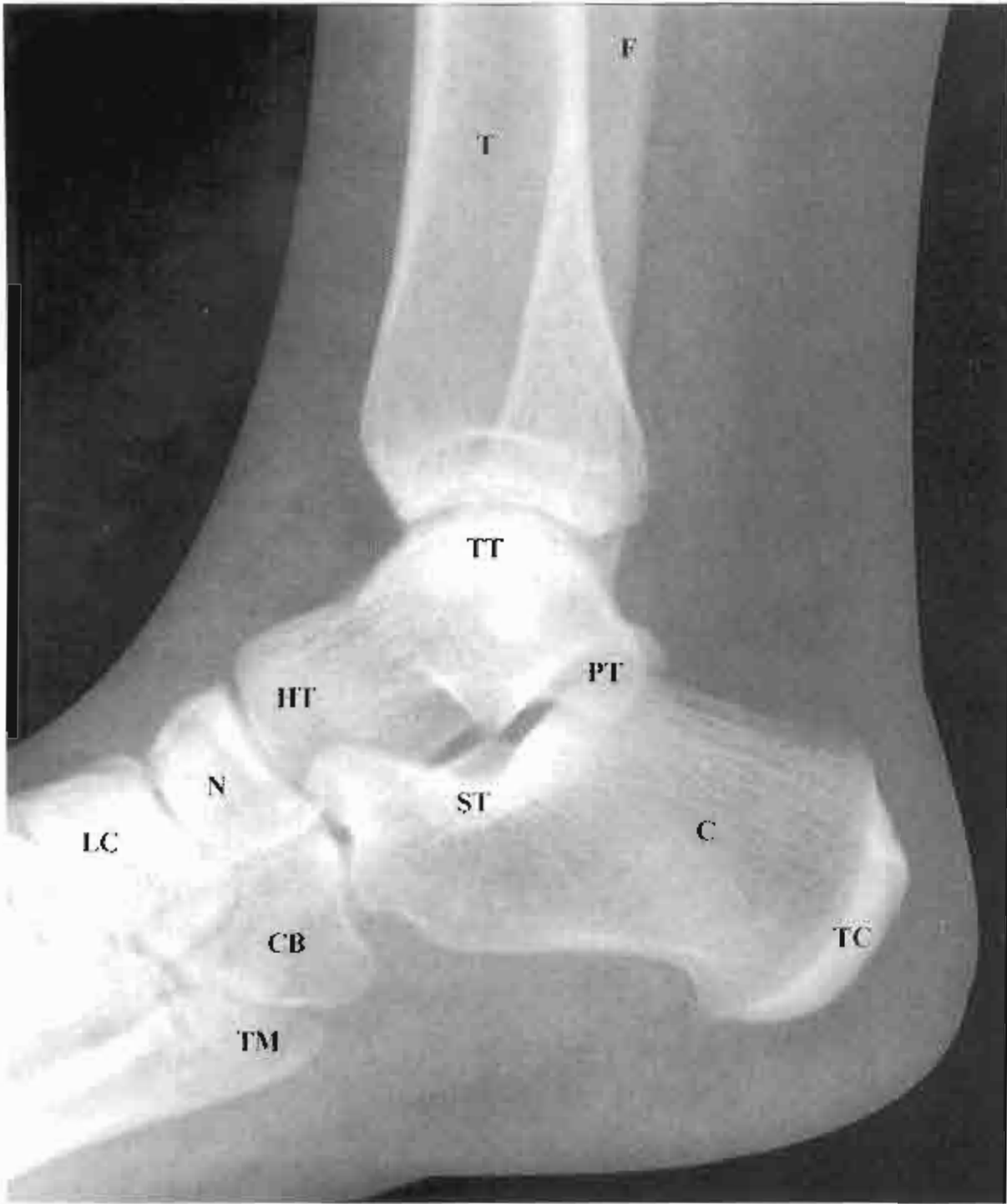


图504



右足





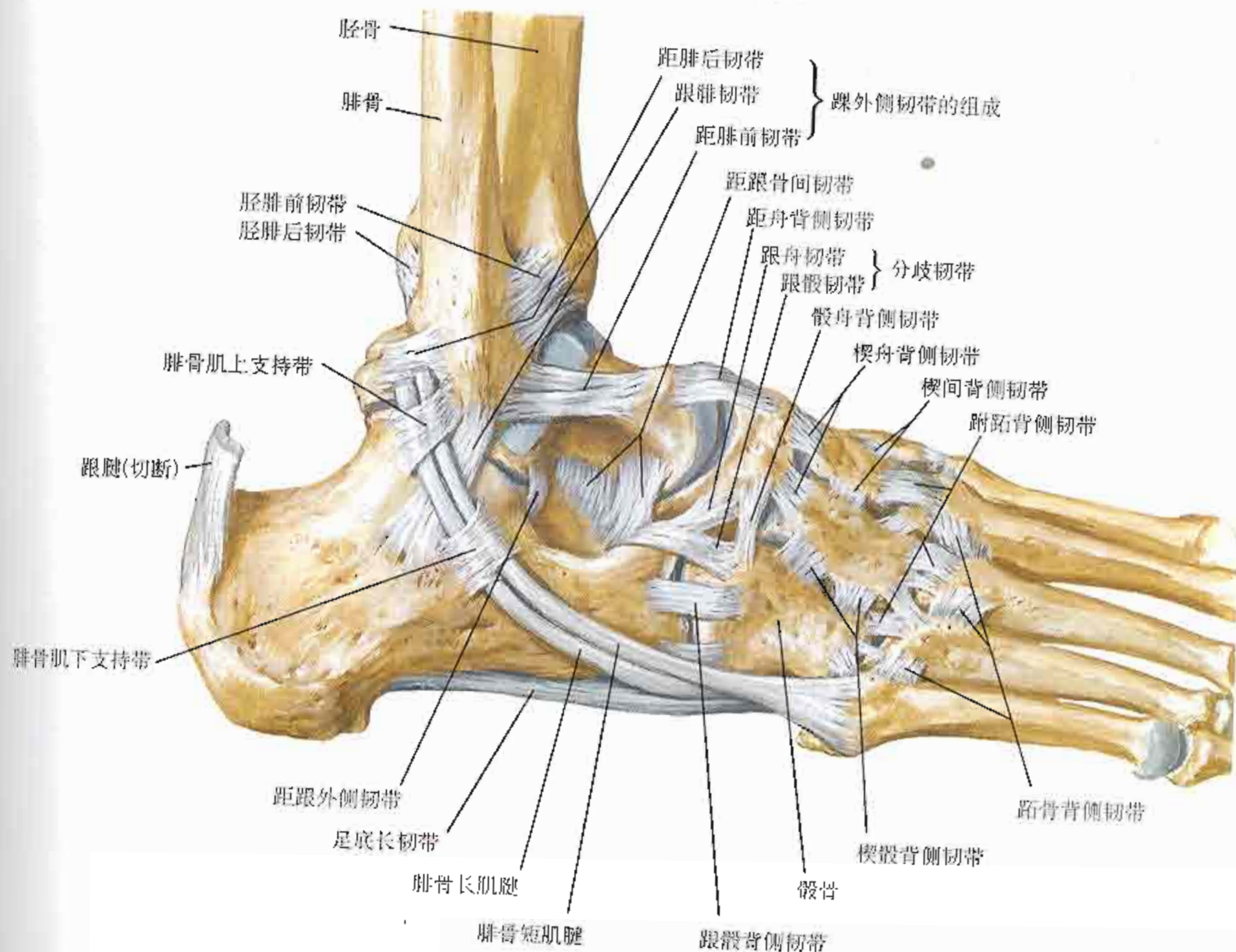
- 外侧面观
- C 跟骨
 - CB 骰骨
 - F 腓骨
 - HT 距骨头
 - LC 外侧楔骨
 - N 足舟骨
 - PT 距骨后突
 - ST 跟骨的载距突
 - T 胫骨
 - TC 跟骨结节
 - TM 第5跖骨粗隆
 - TT 距骨滑车

- 前面观
- F 腓骨
 - LM 外踝
 - MM 内踝
 - T 胫骨
 - TA 距骨

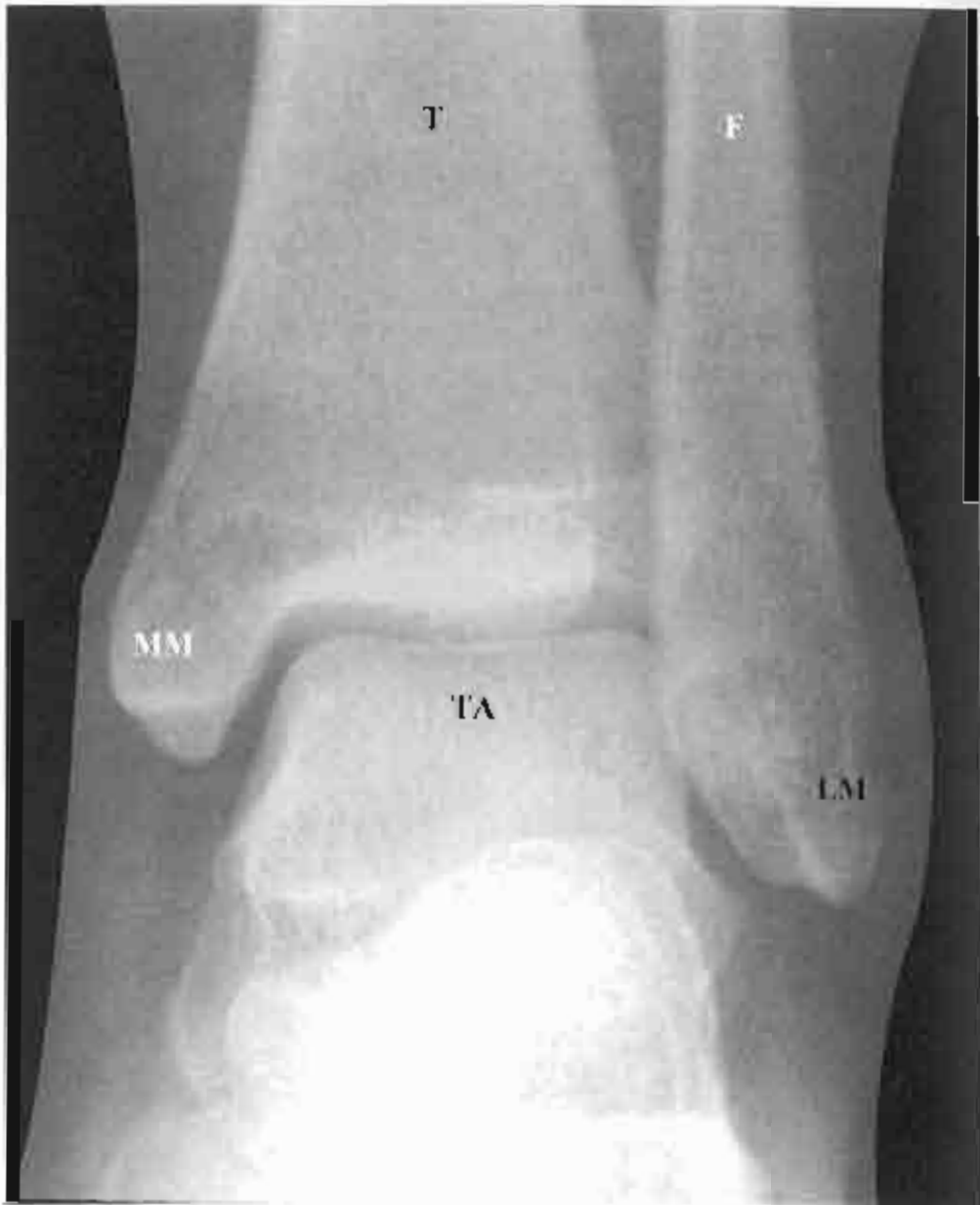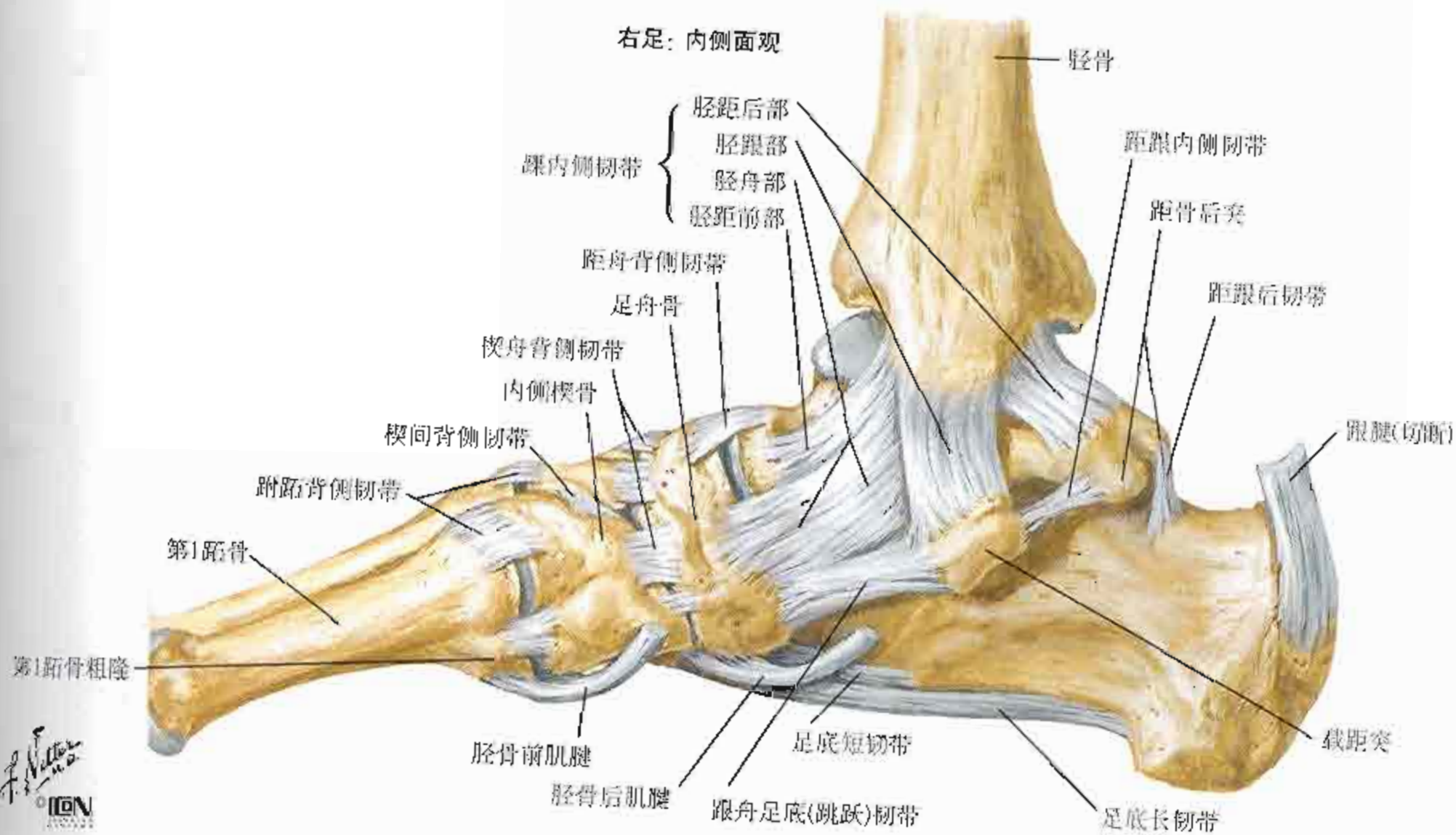


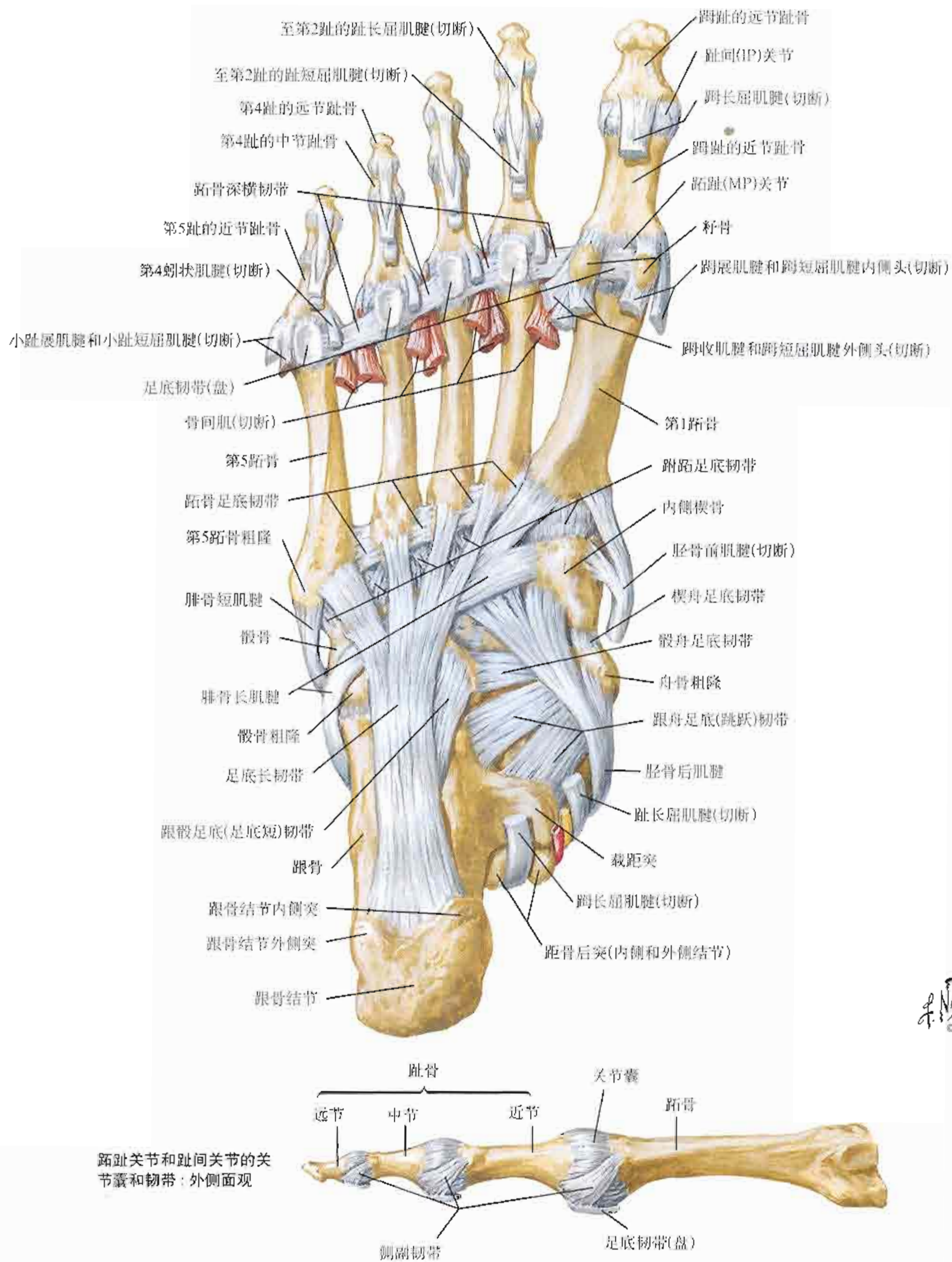
图508

右足：外侧面观

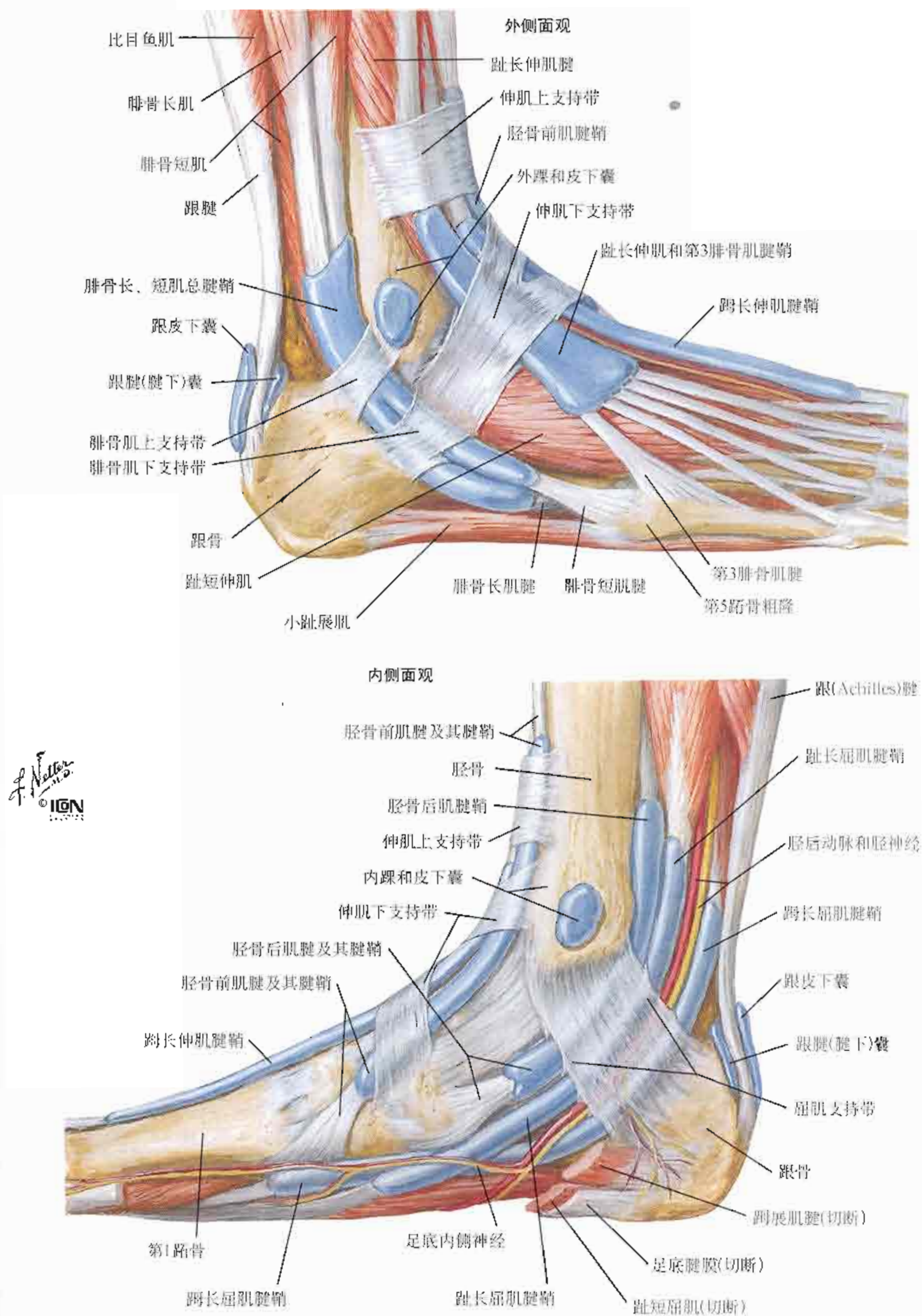


右足：内侧面观





F. Netter M.D.
© IGM



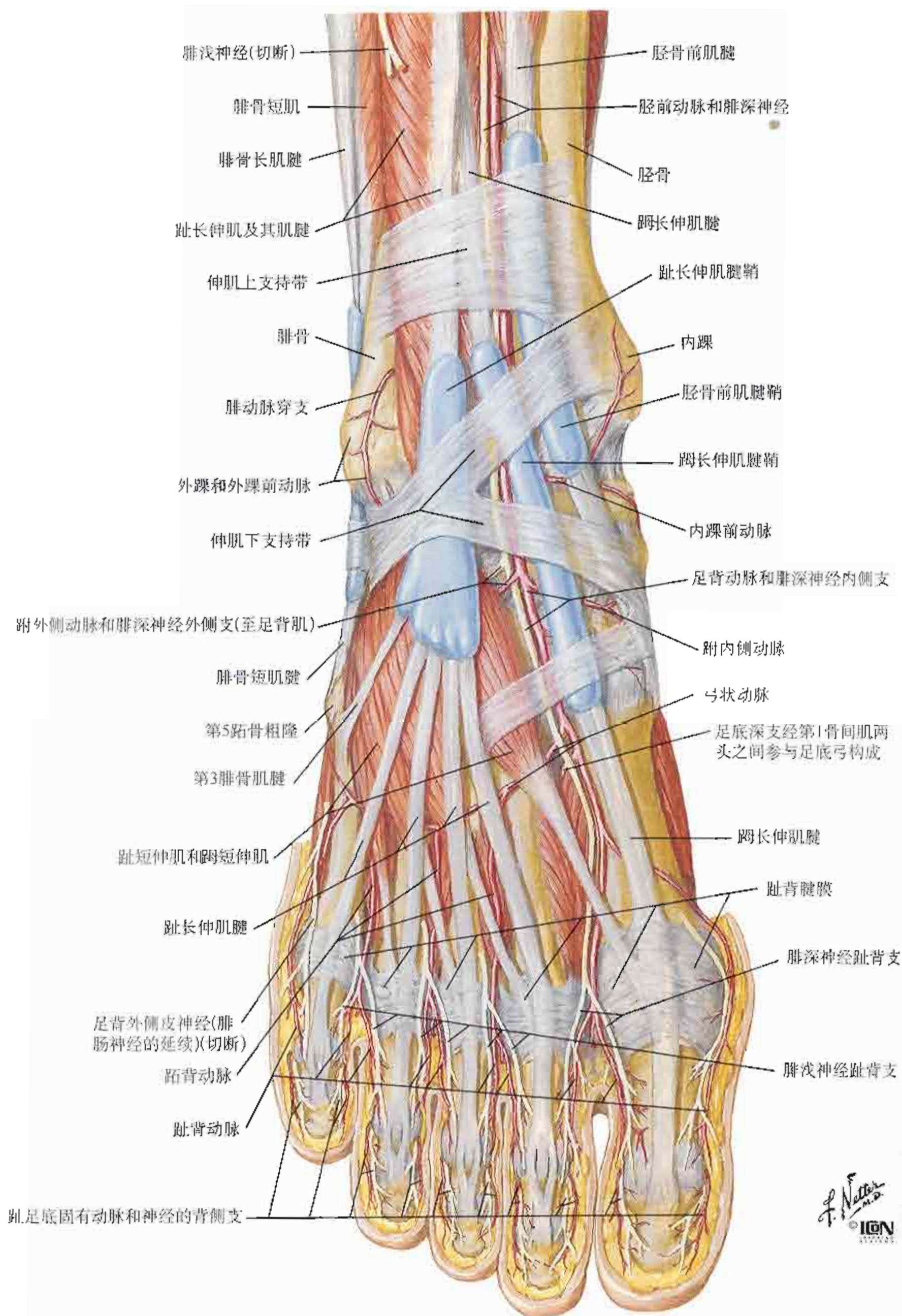
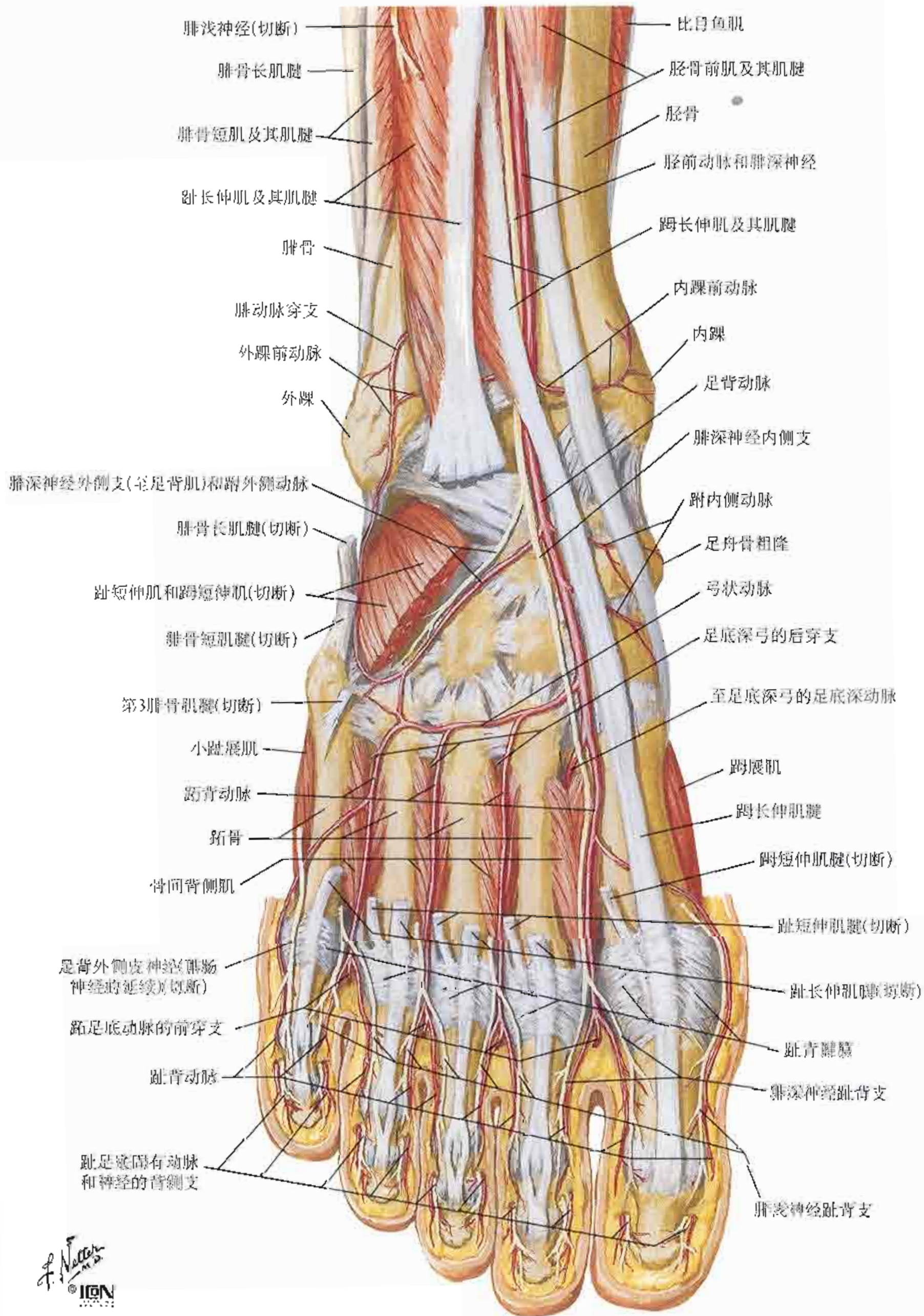
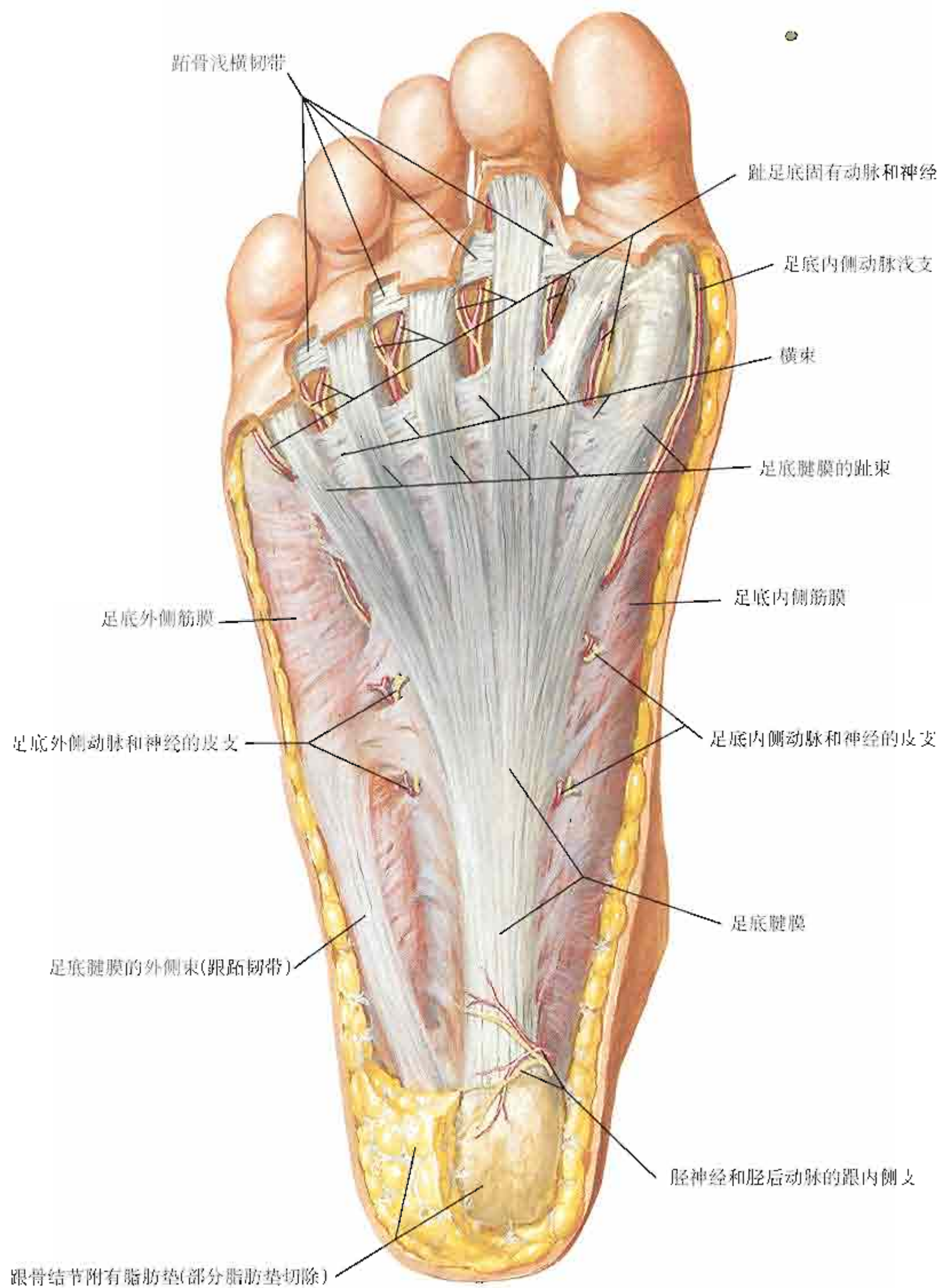
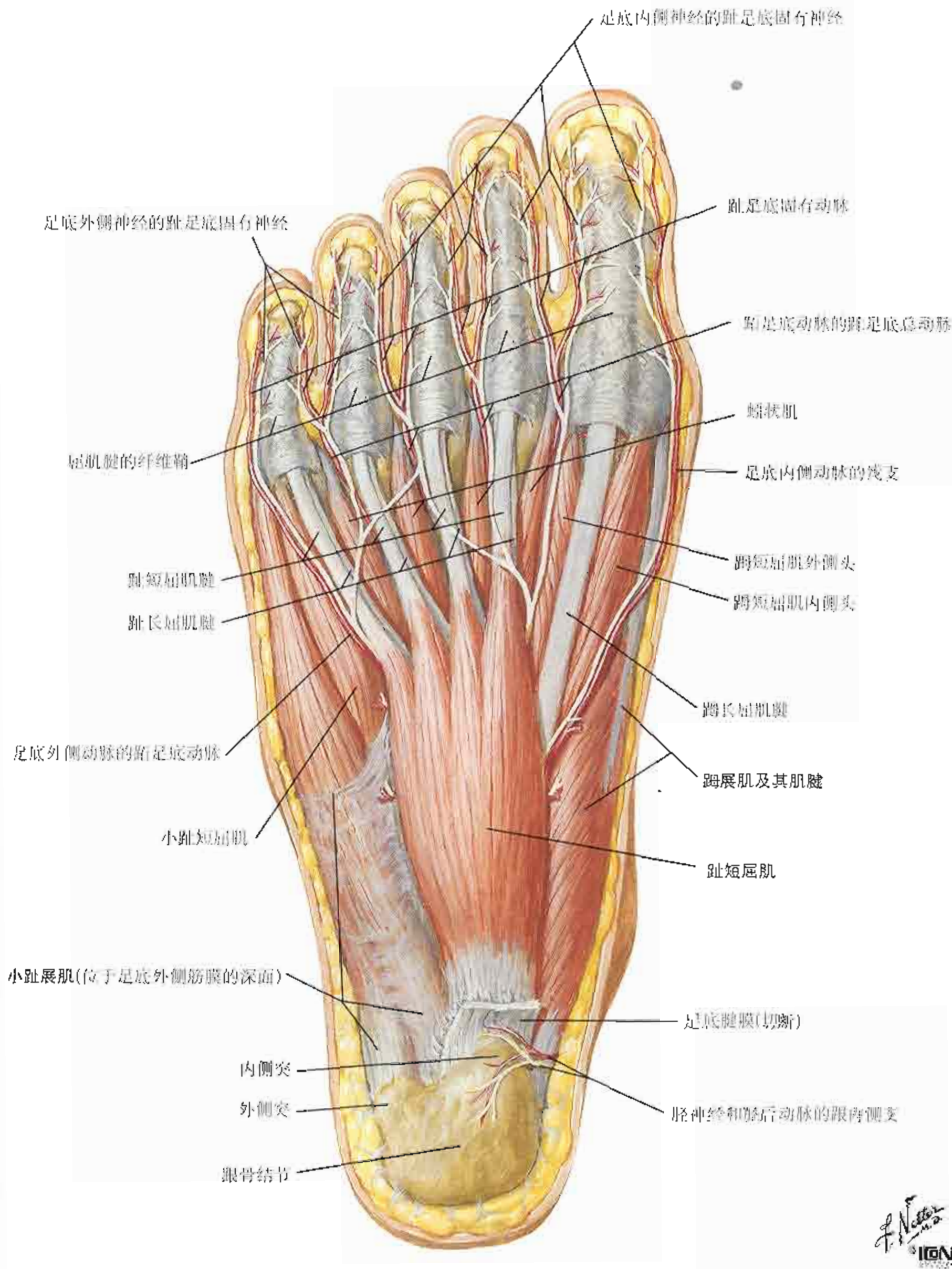


图512

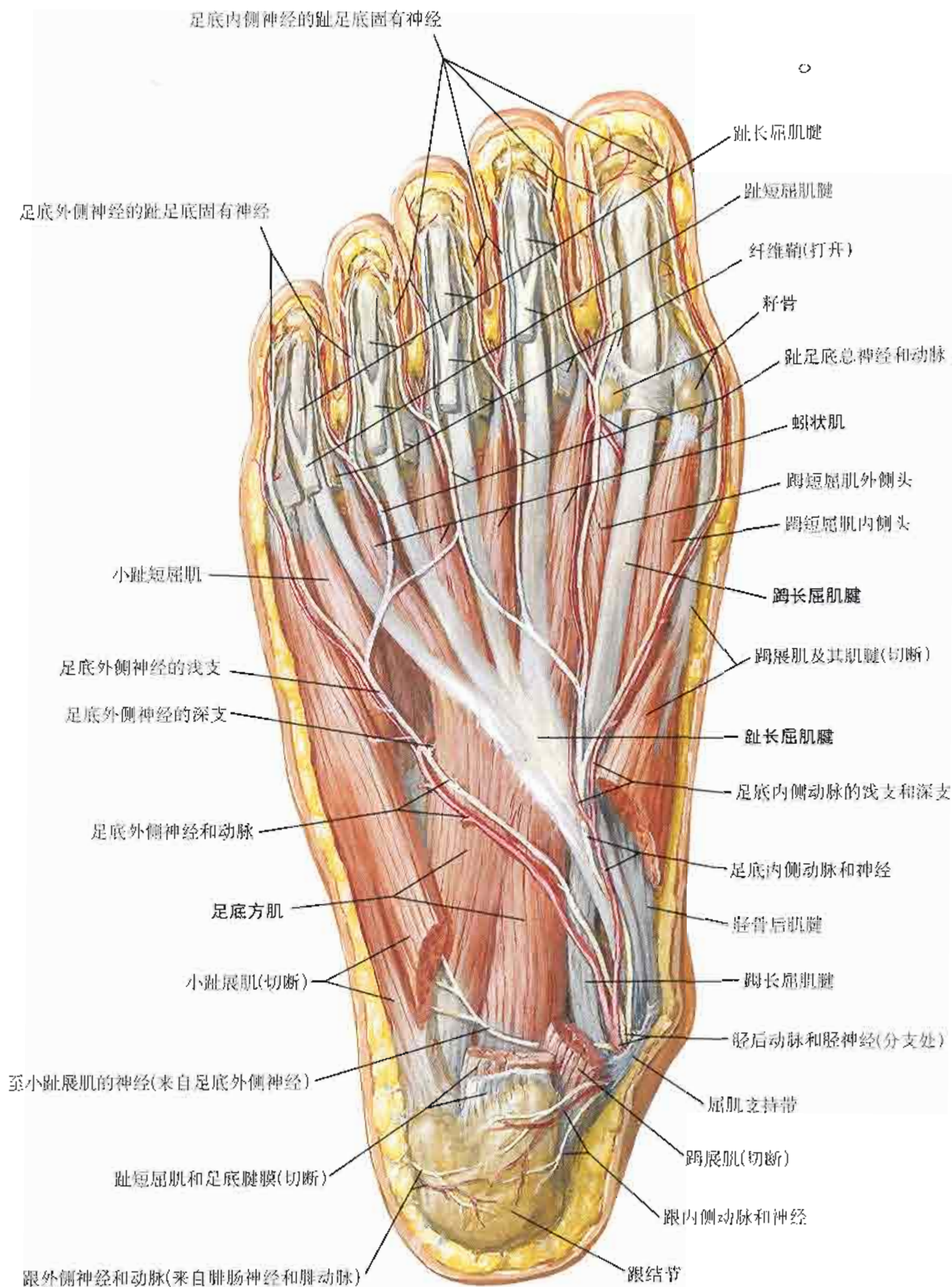




F. Netter M.D.
© 1997

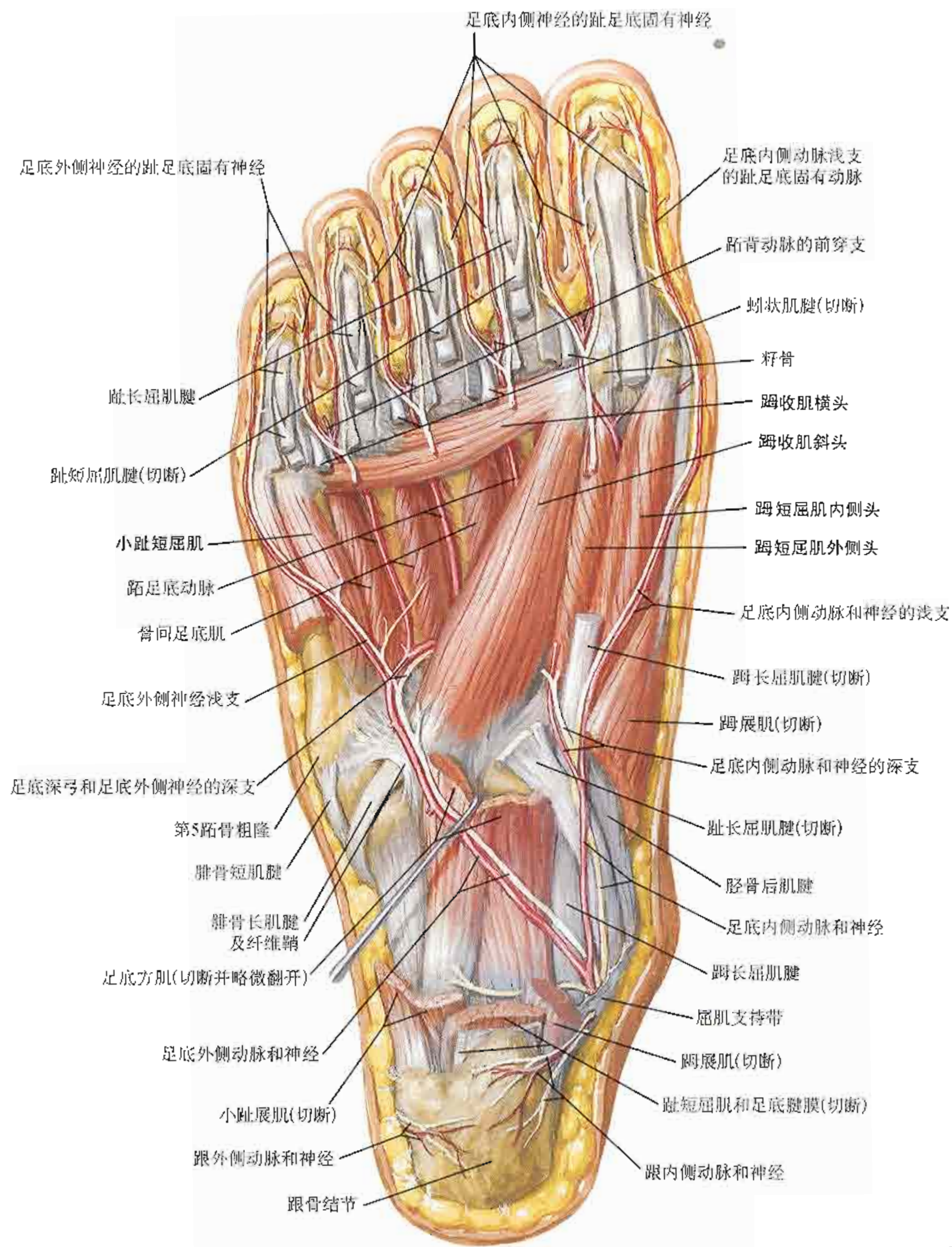


F. Netter
M.D.
ICON



F. Netter M.D. ILLUSTRATIONS

图516



F. Netter M.D.
© ION
ILLUSTRATIONS

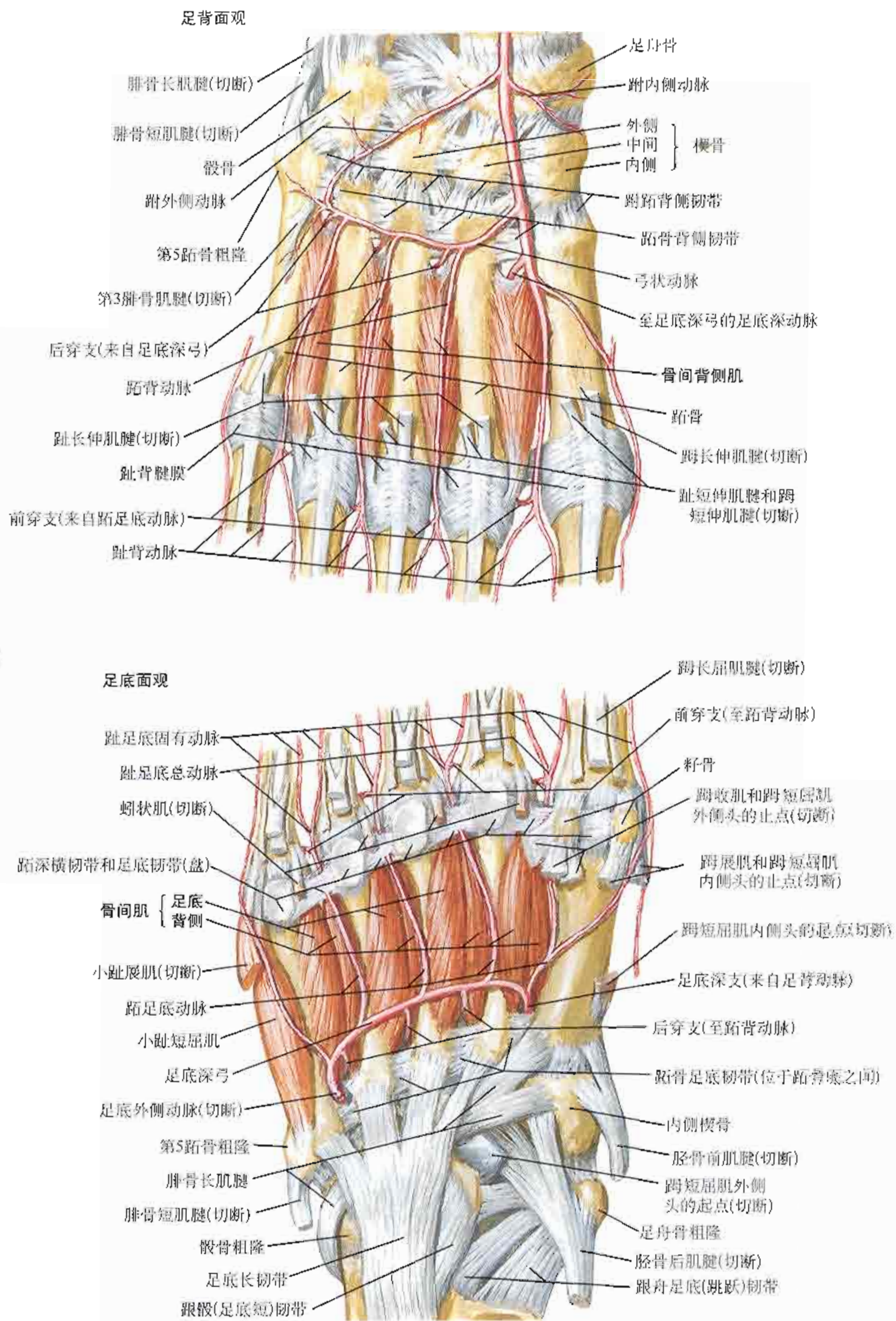
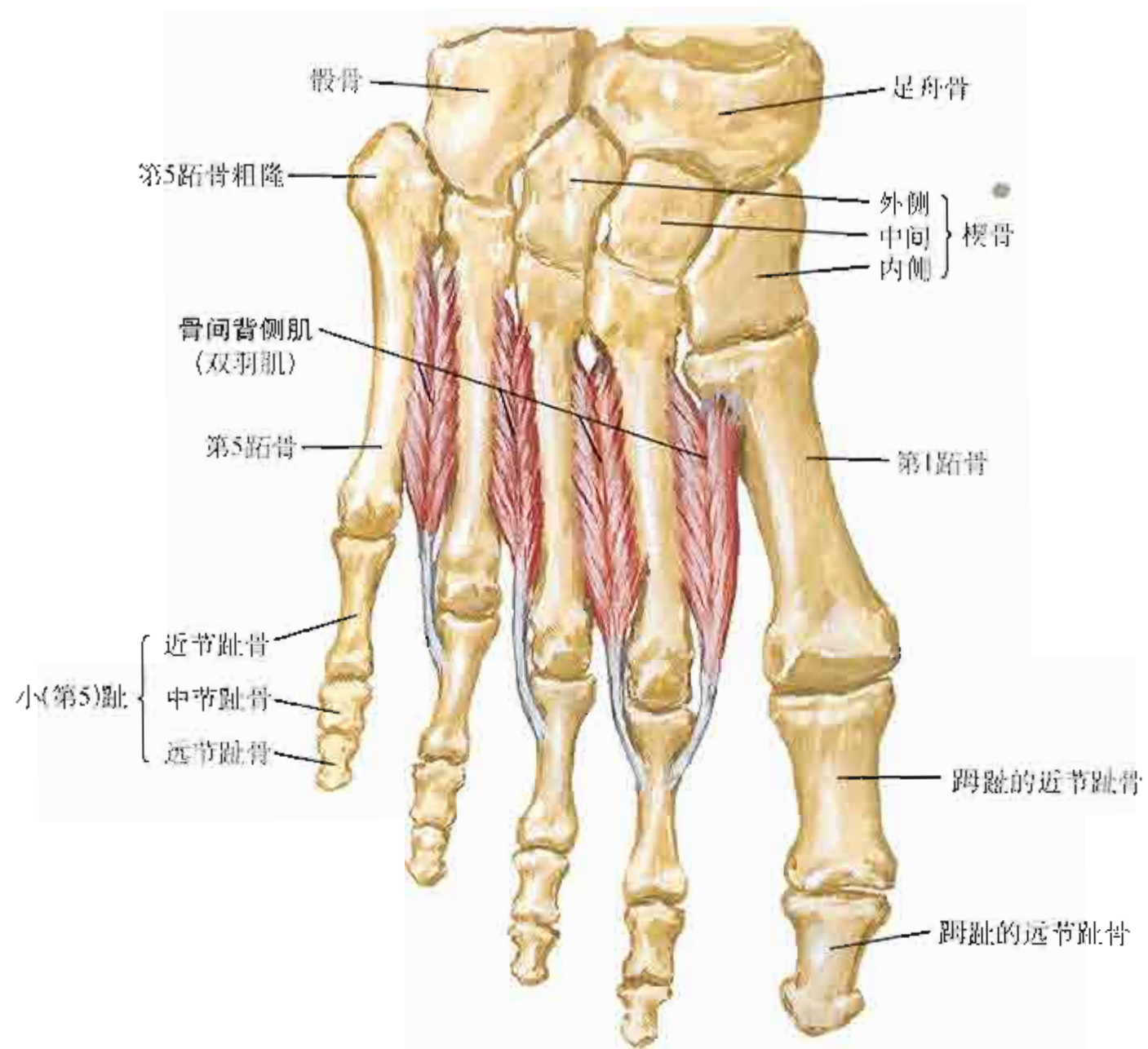
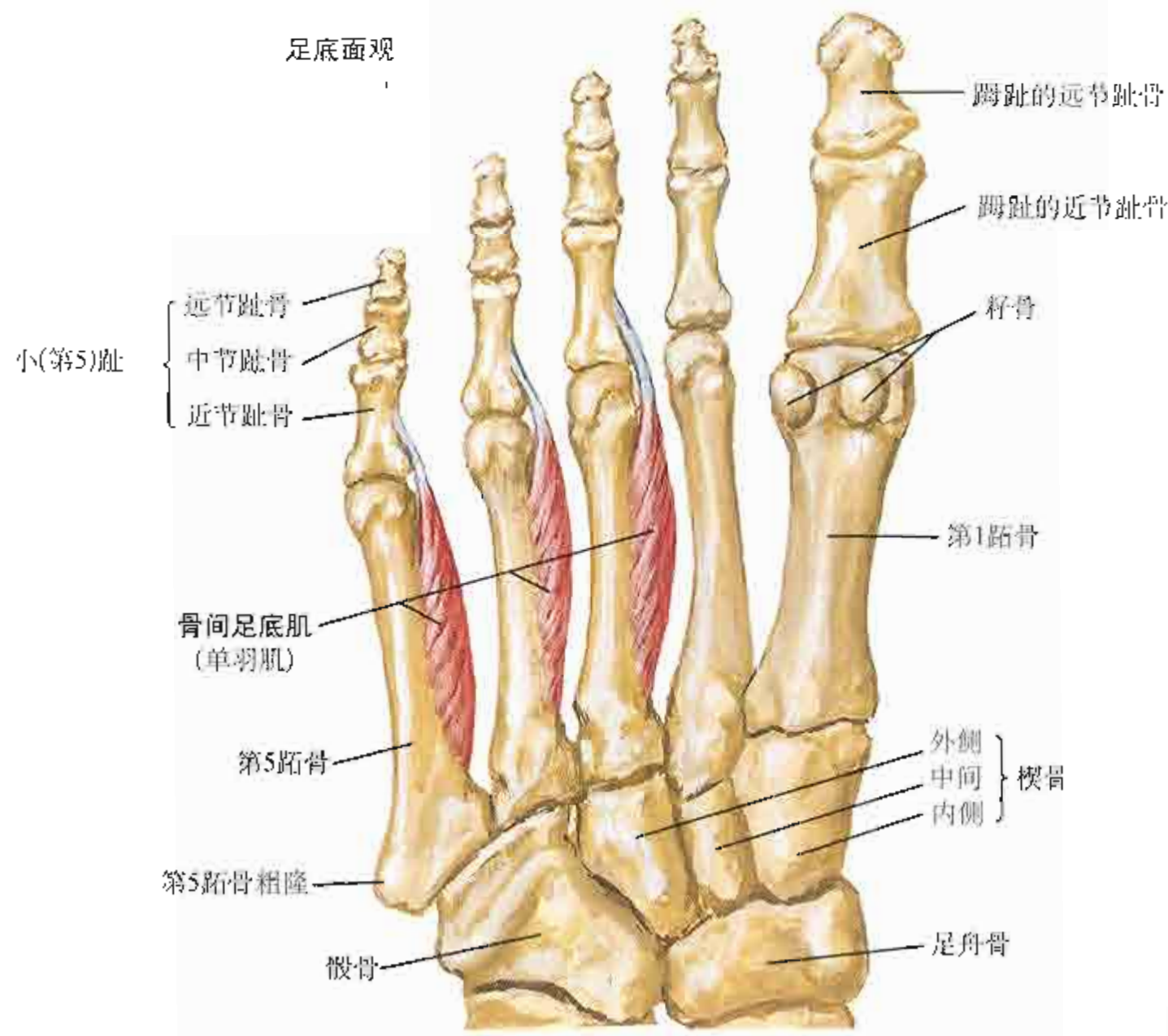


图518

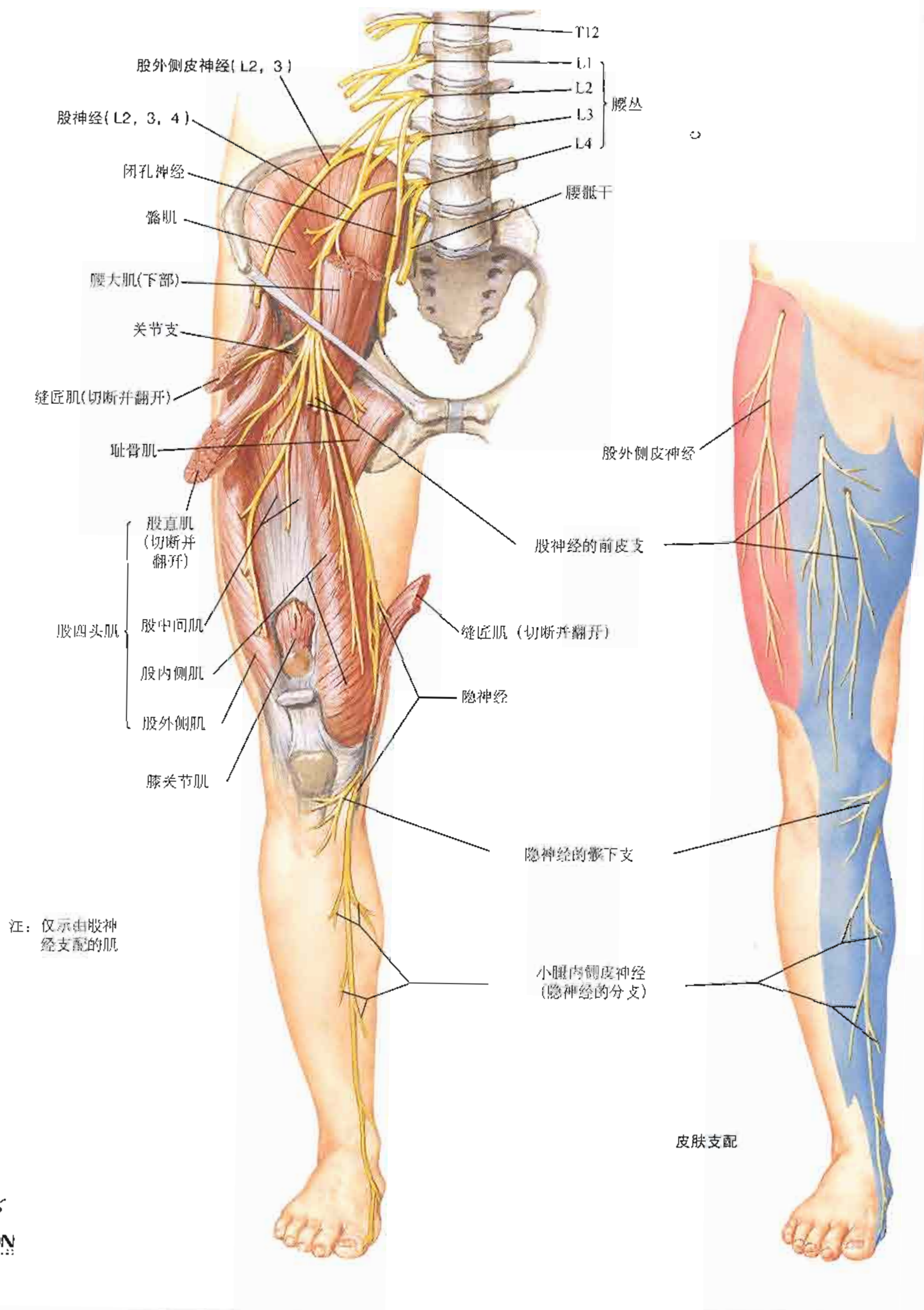
足背面观

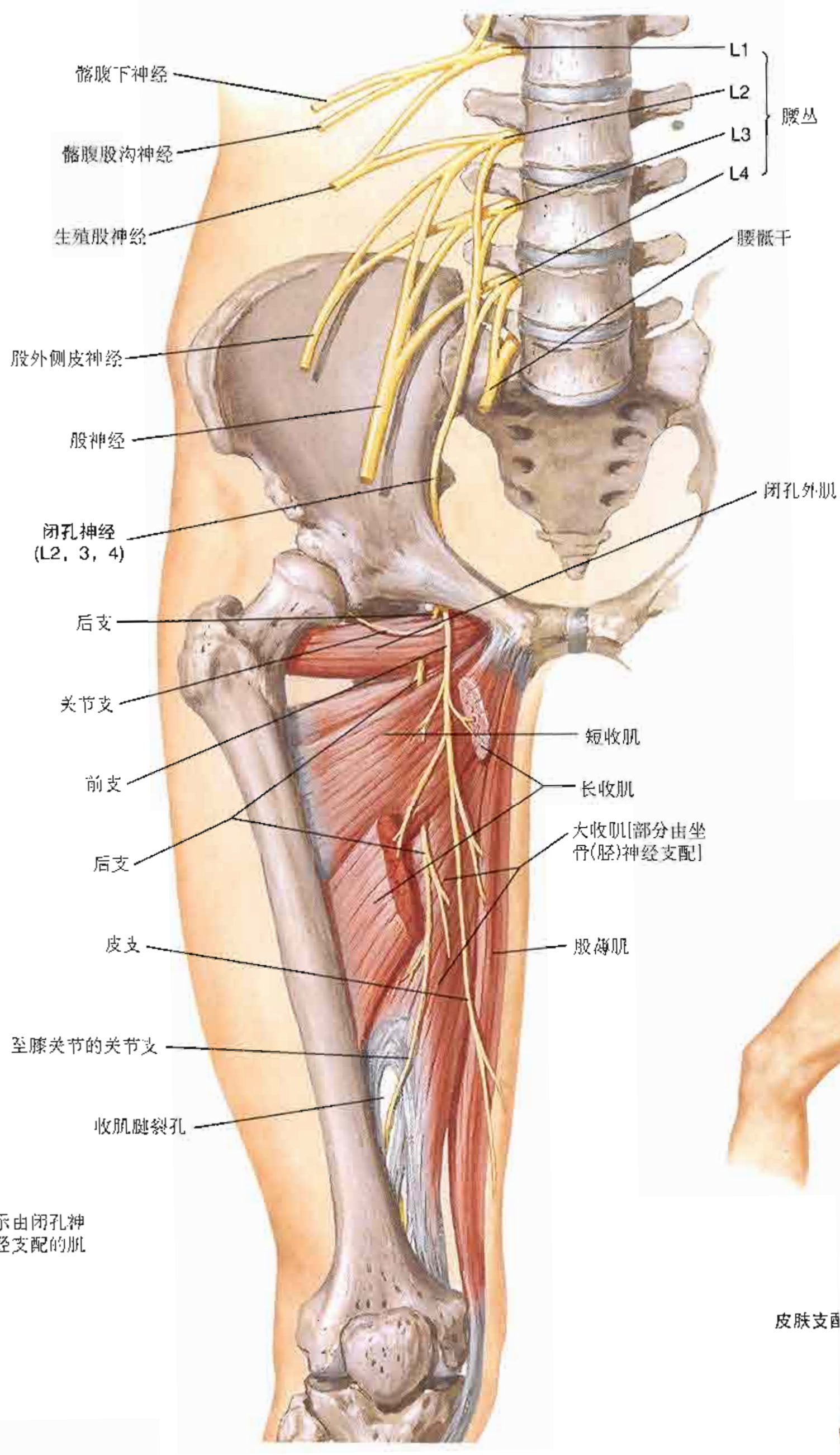


足底面观



F. Netter M.D. ION





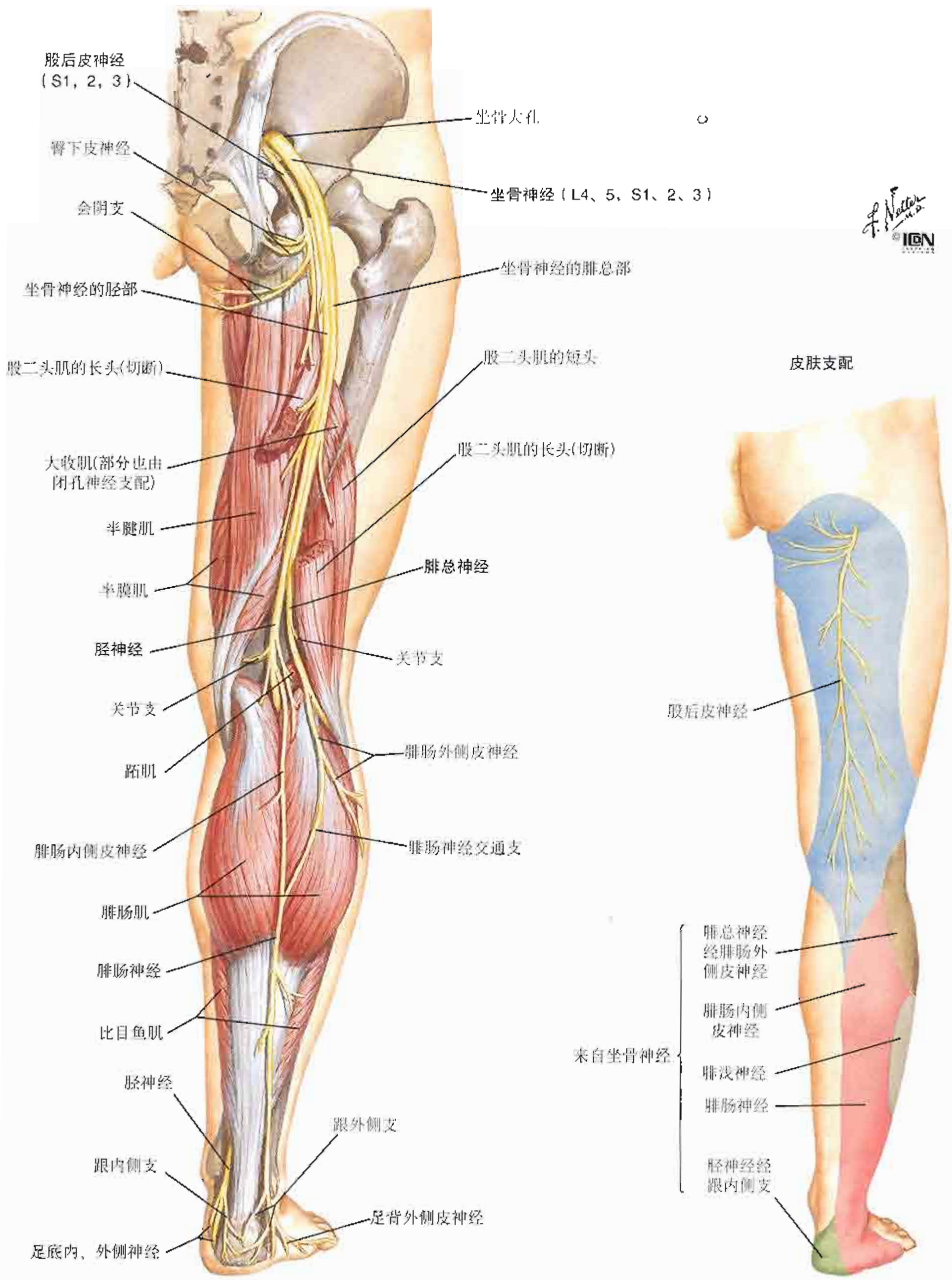
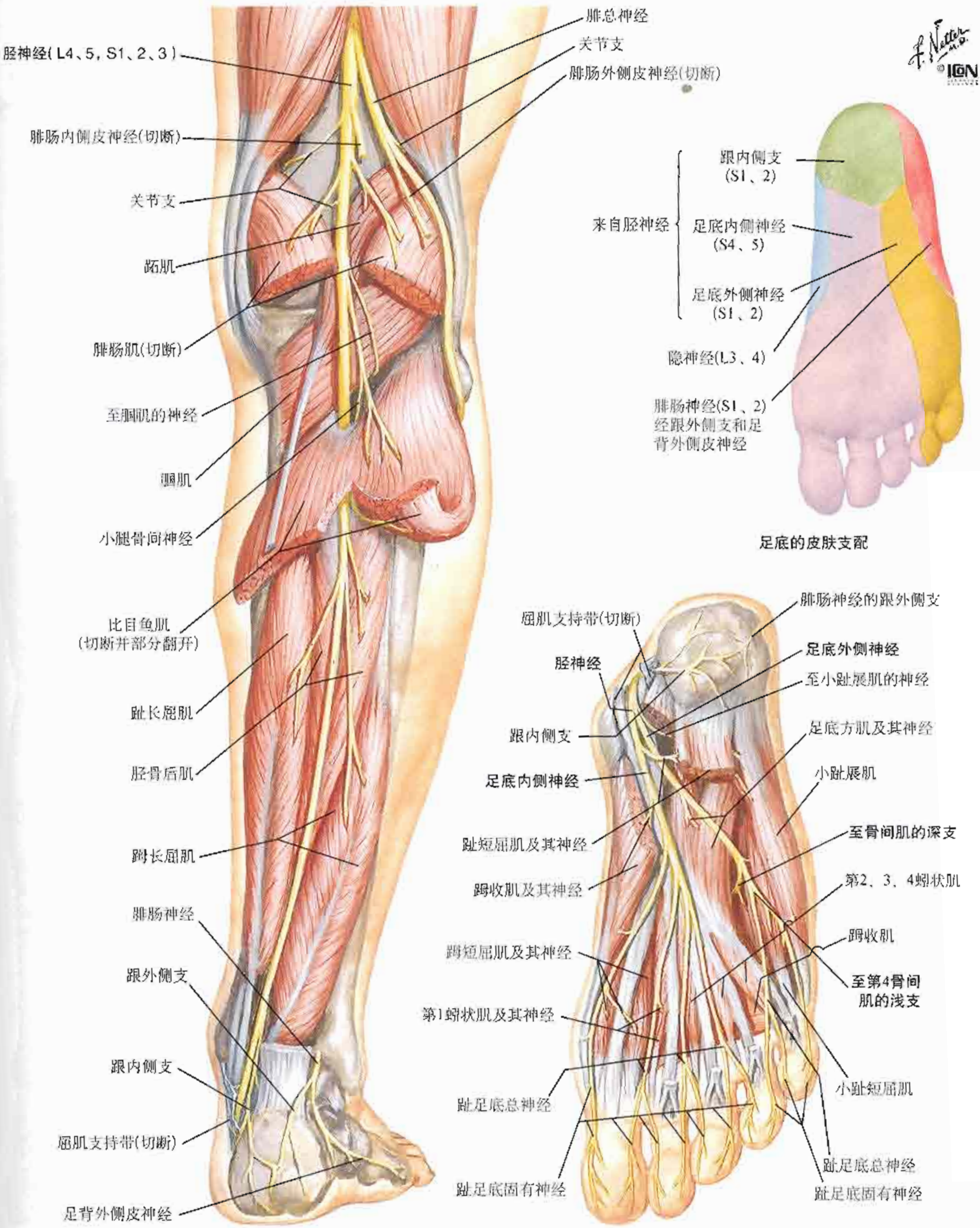


图522



注：关节支未显示

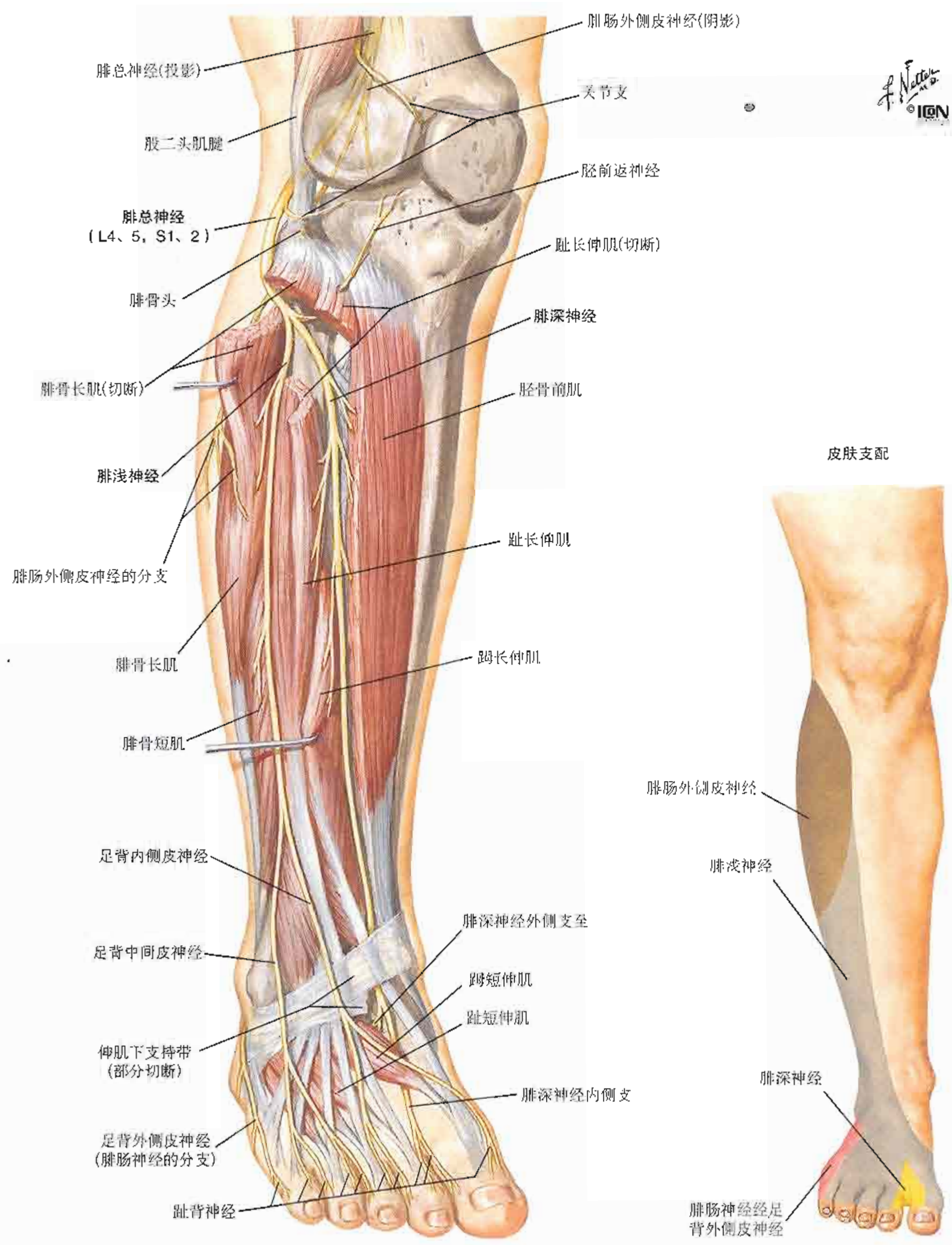


图524




运动科学网站



运动科学网站



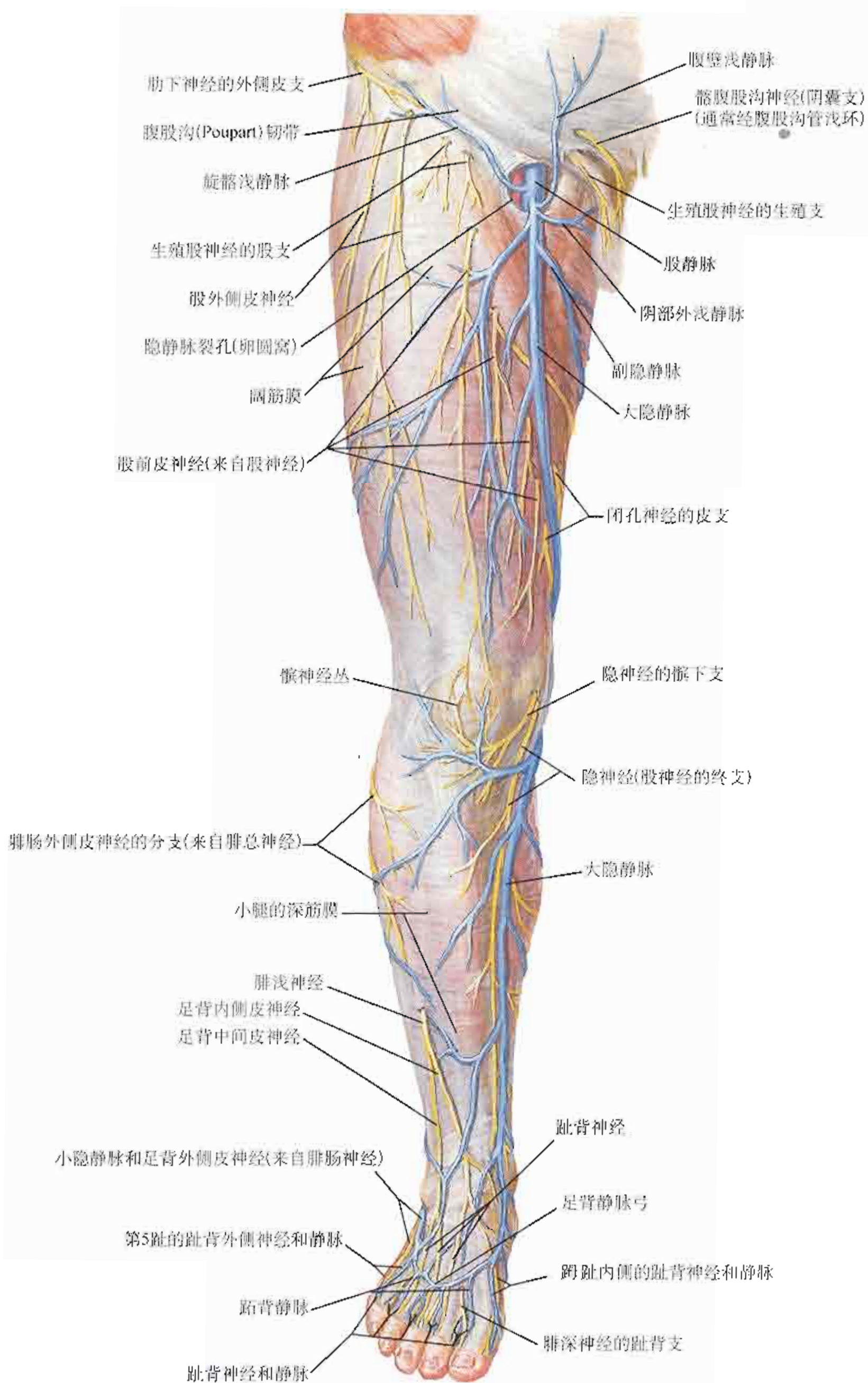
运动科学网站



运动科学网站

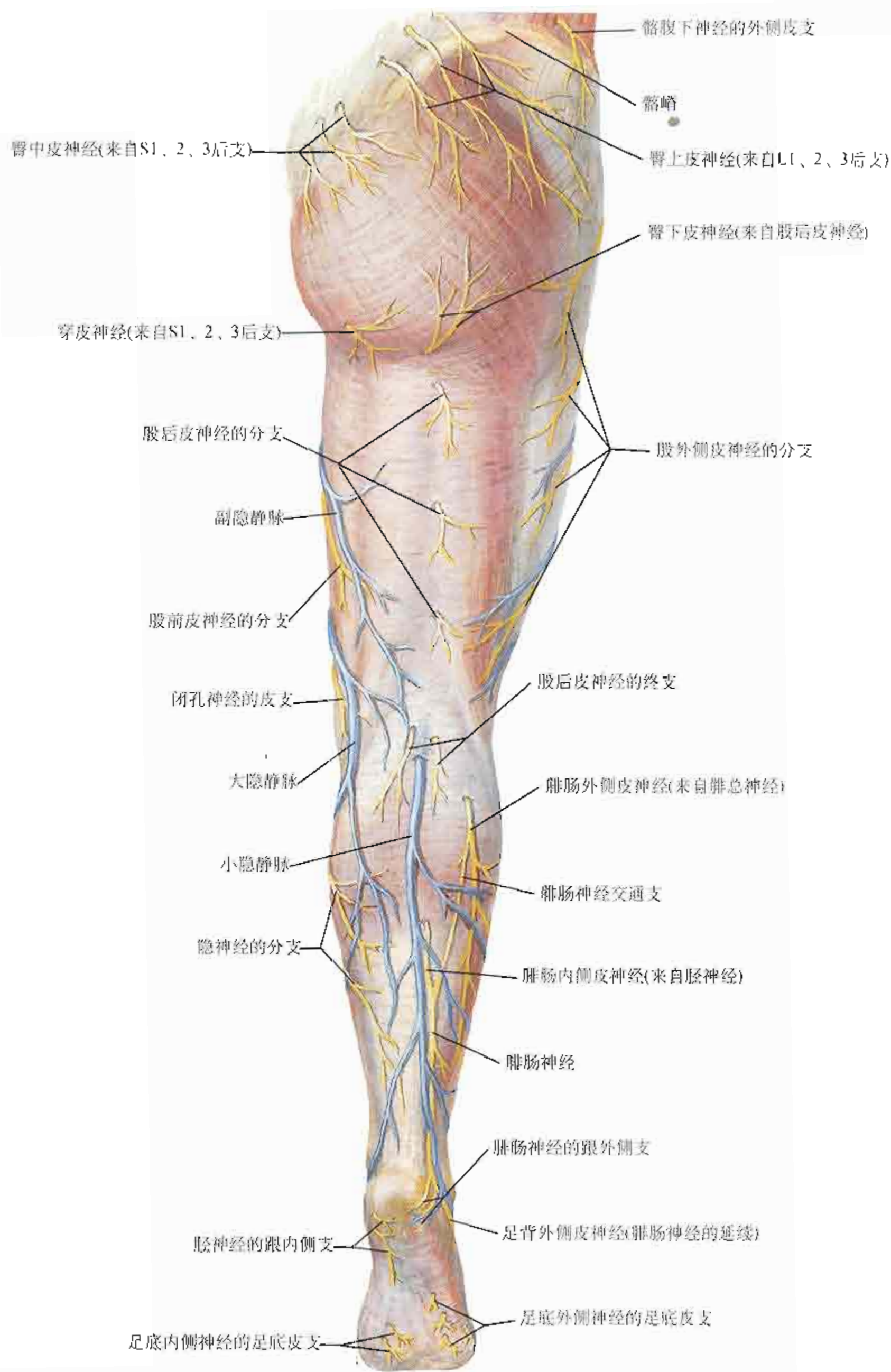


运动科学网站
www.vo2maxcn.com



F. Netter M.D.
© ION

图526



F. Netter M.D.
ION

下肢的淋巴管和淋巴结

参见图387、388

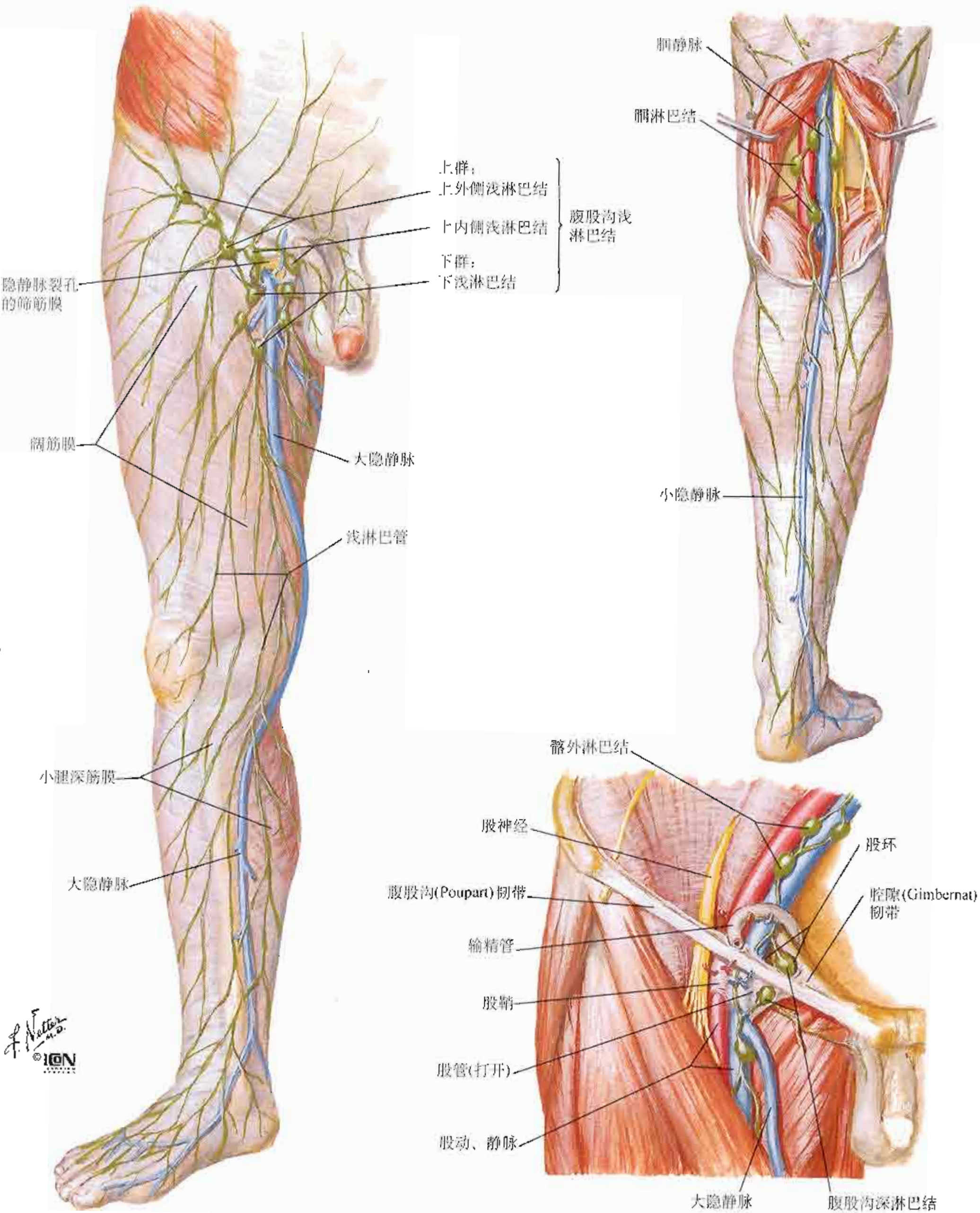
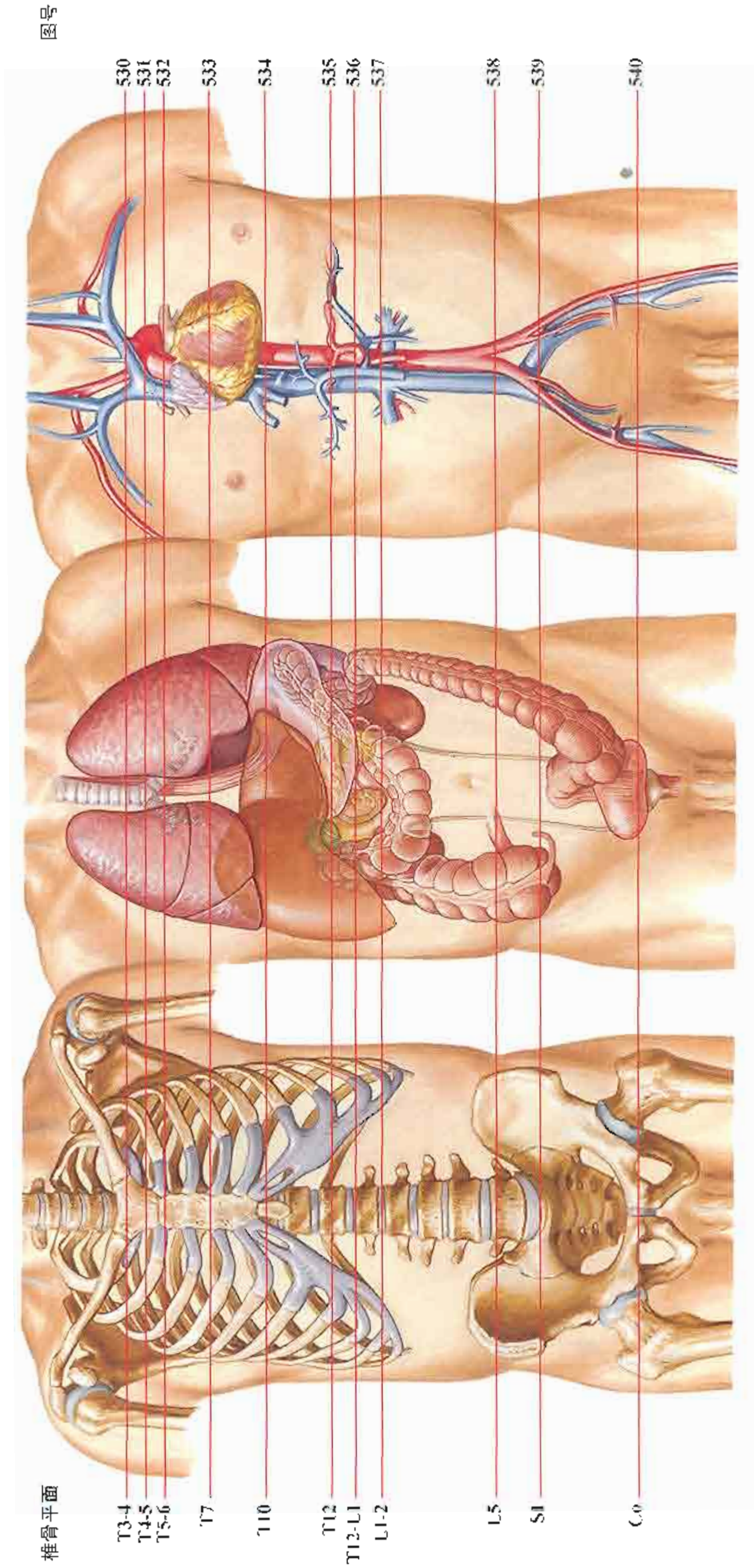


图528

下肢



C. Machado
Ph.D.
© ION
LAVAZZANI

断面总体观

图529

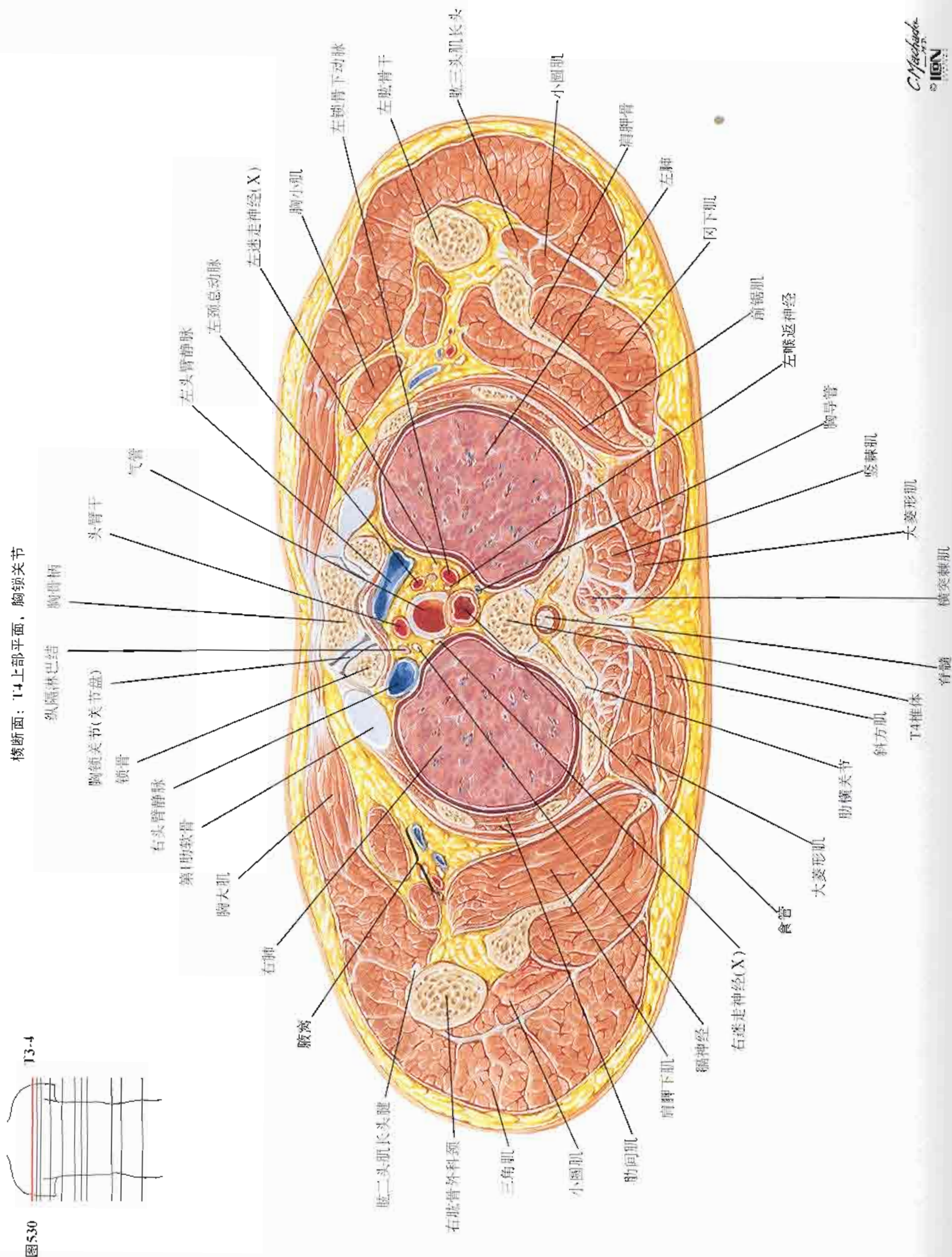
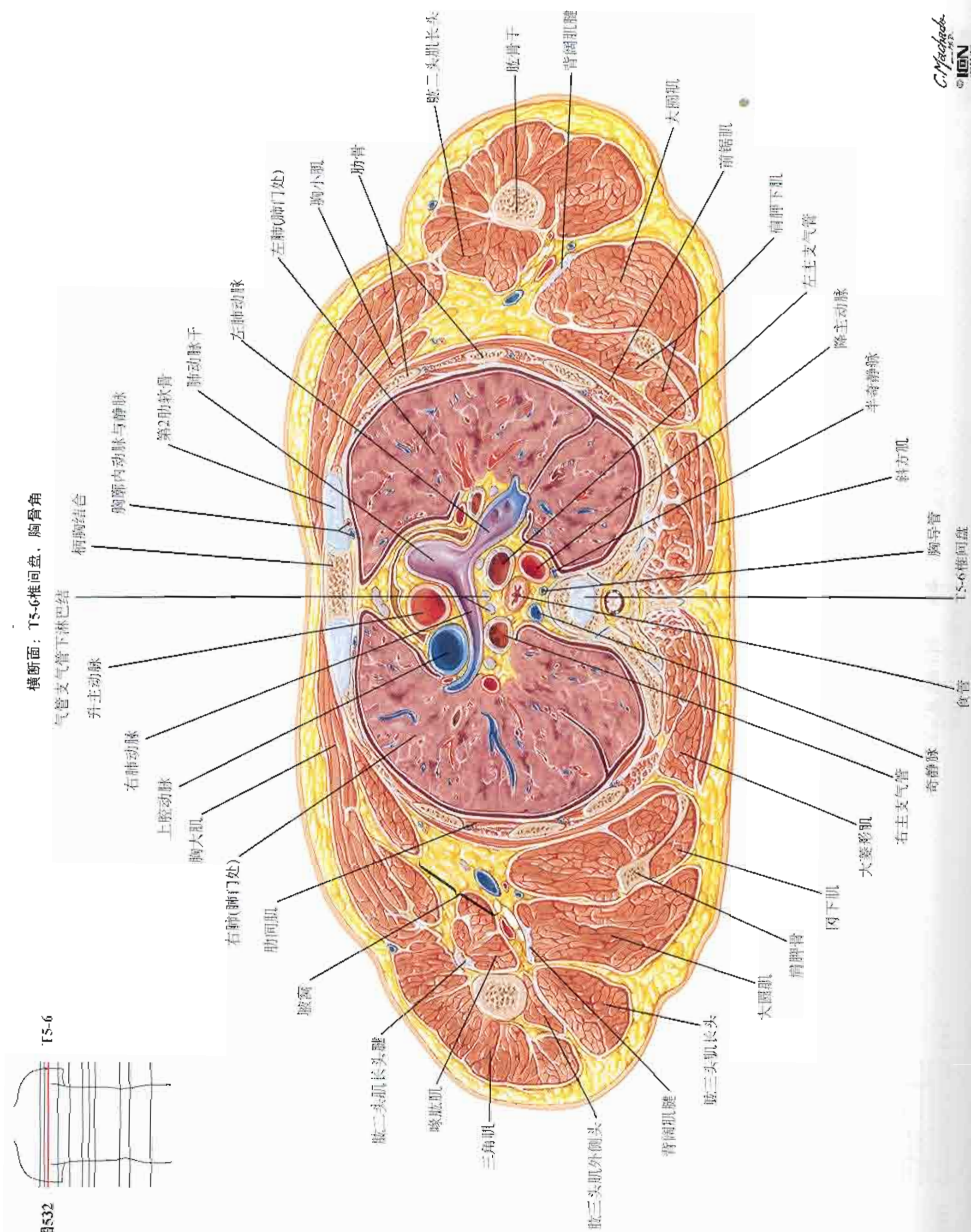


图530



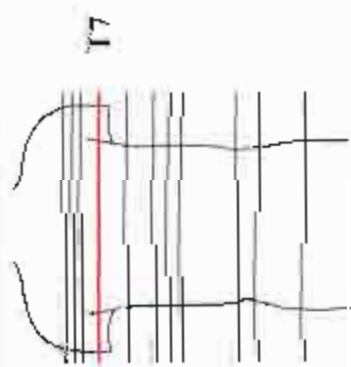
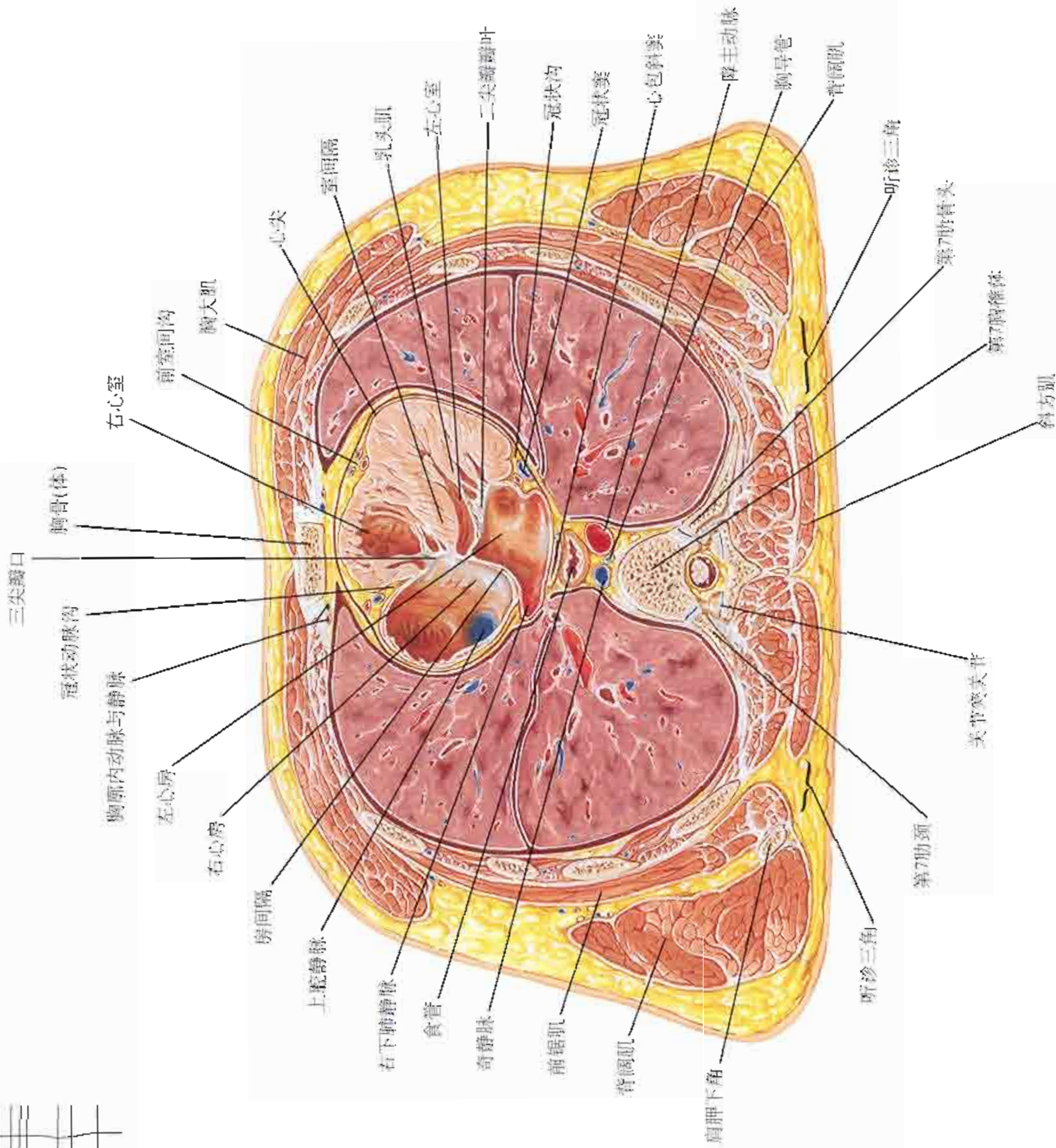
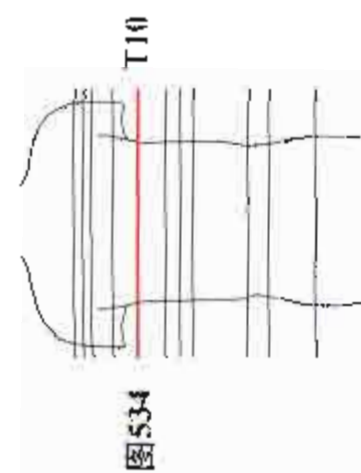


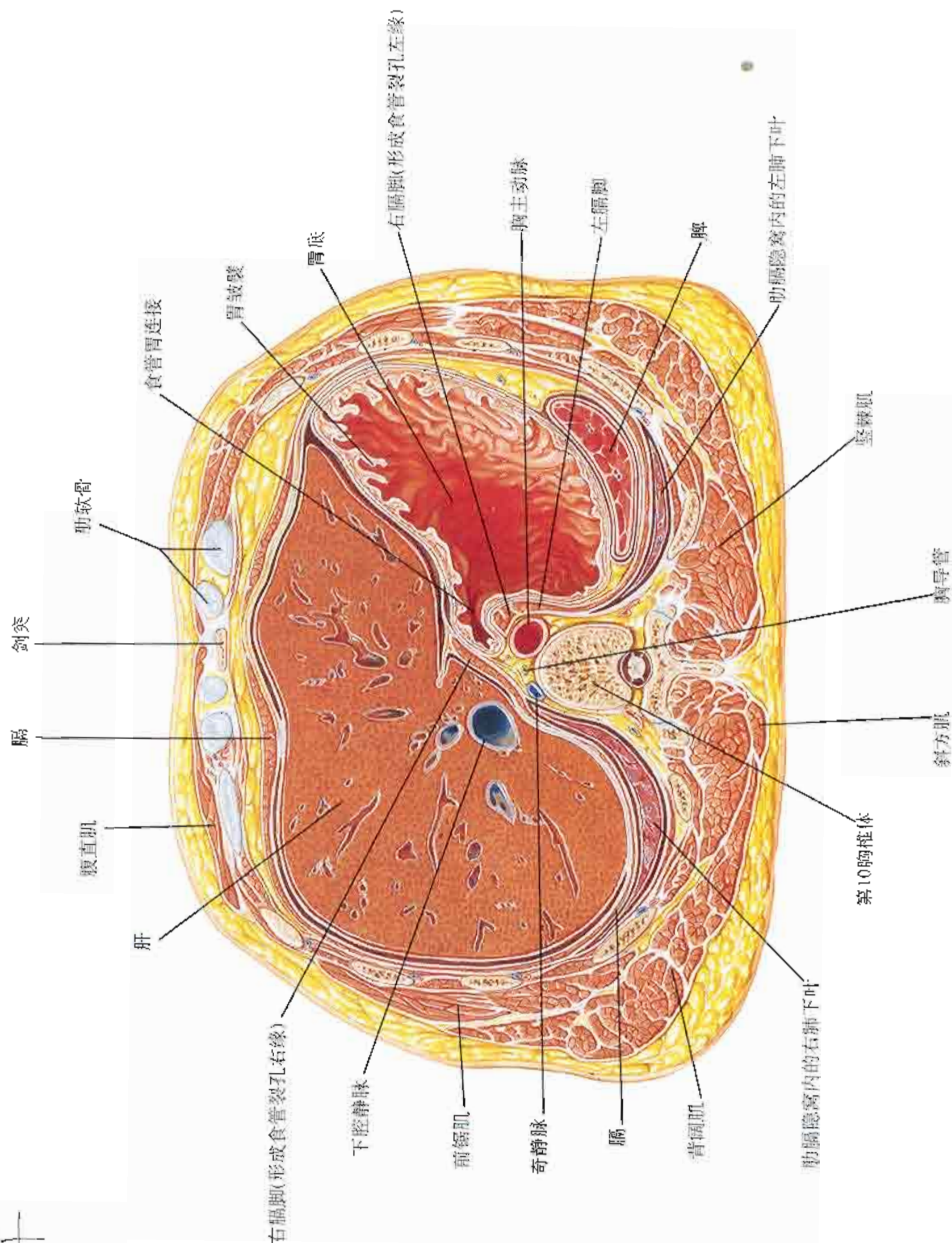
图 533

横断面：T7平面，第3肋间隙

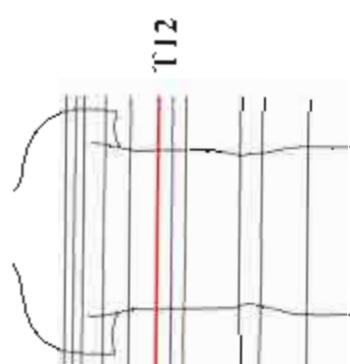
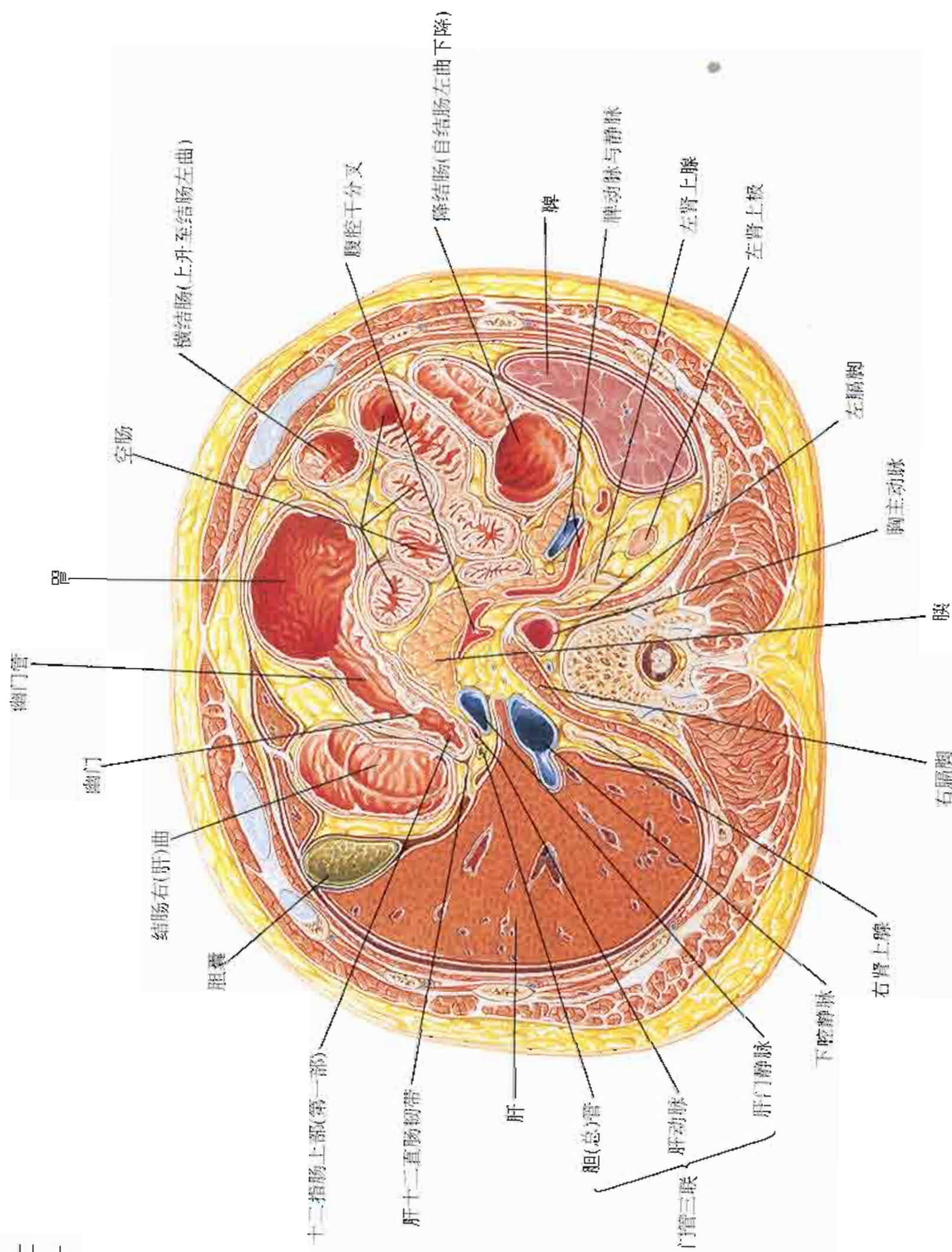




横断面：T10平面，食管胃连接



横断面：T12平面，剑突下



T12

图535

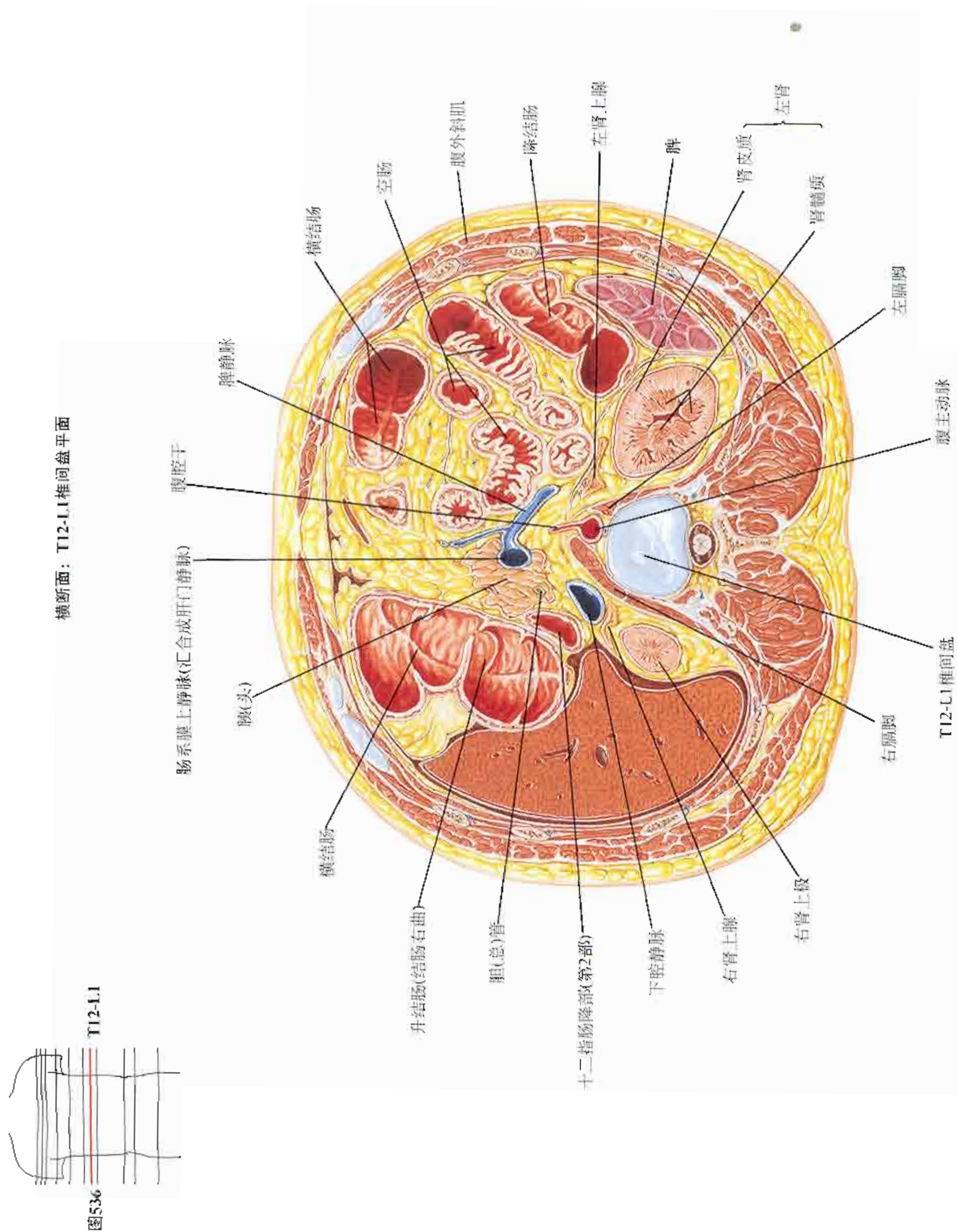
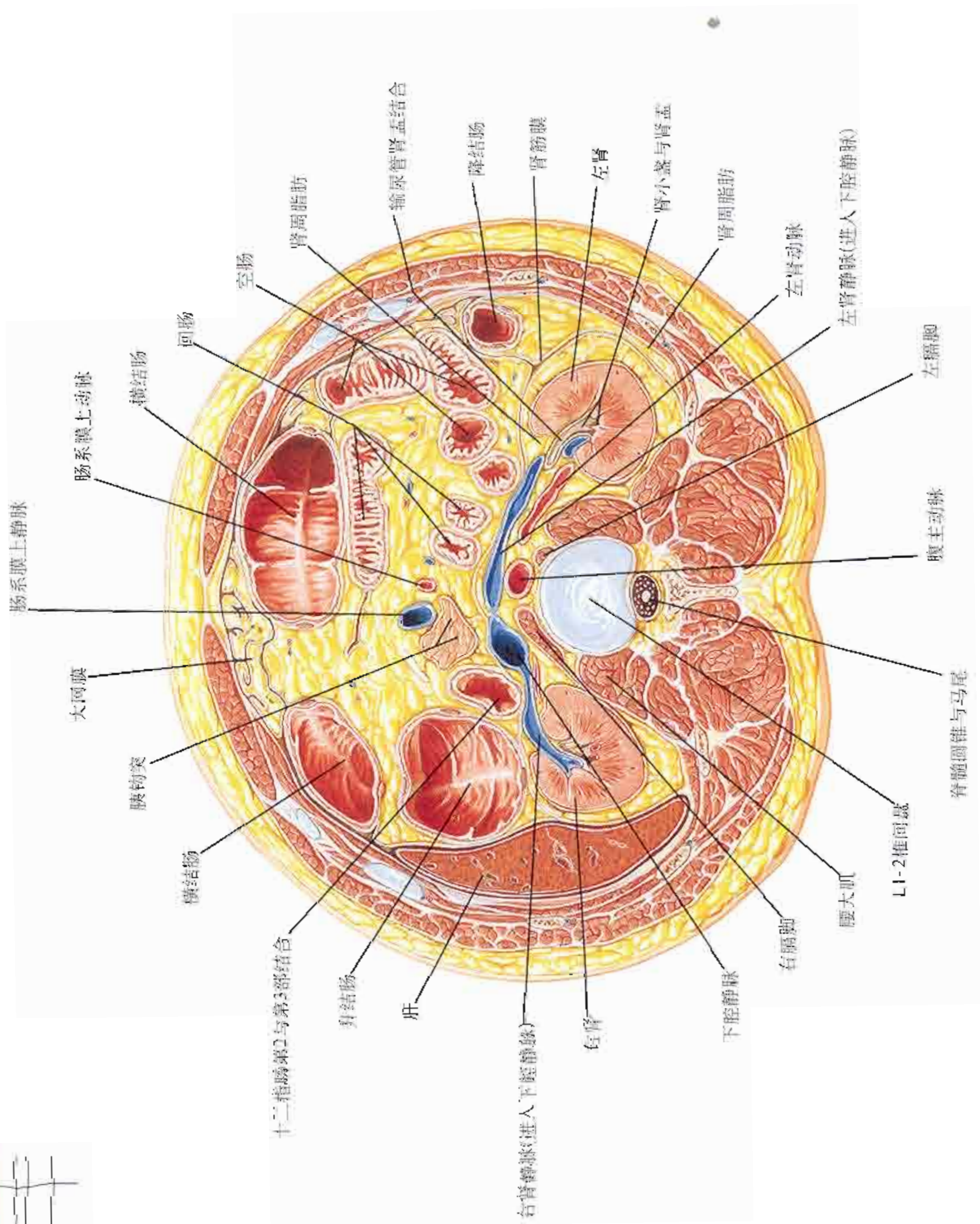
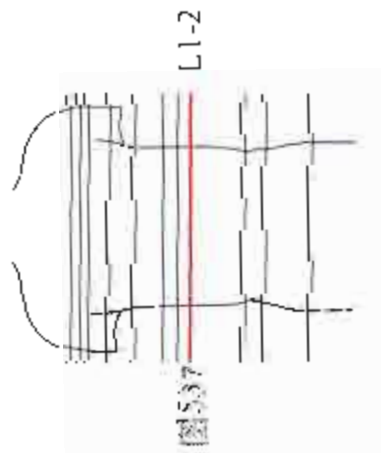


图536

横断面：L1-2椎间盘平面



横断面：L5平面，经结节平面

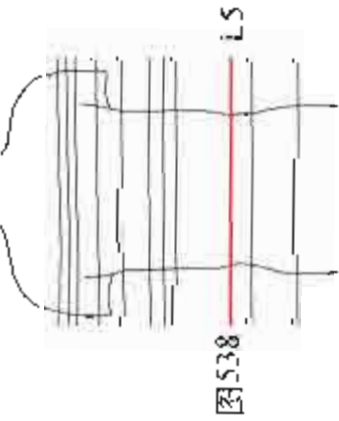
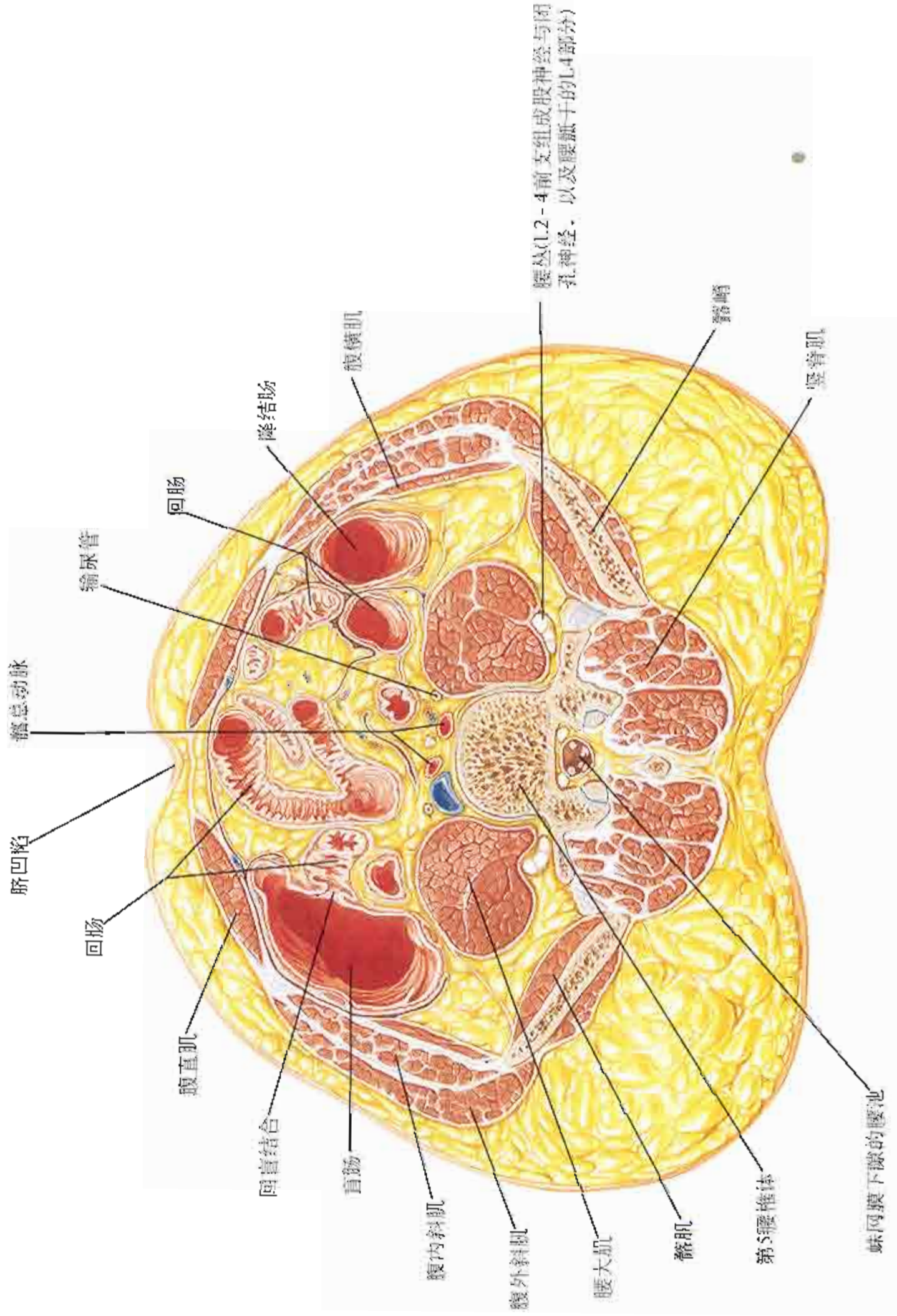


图538





横断面：S1平面，骶前上棘

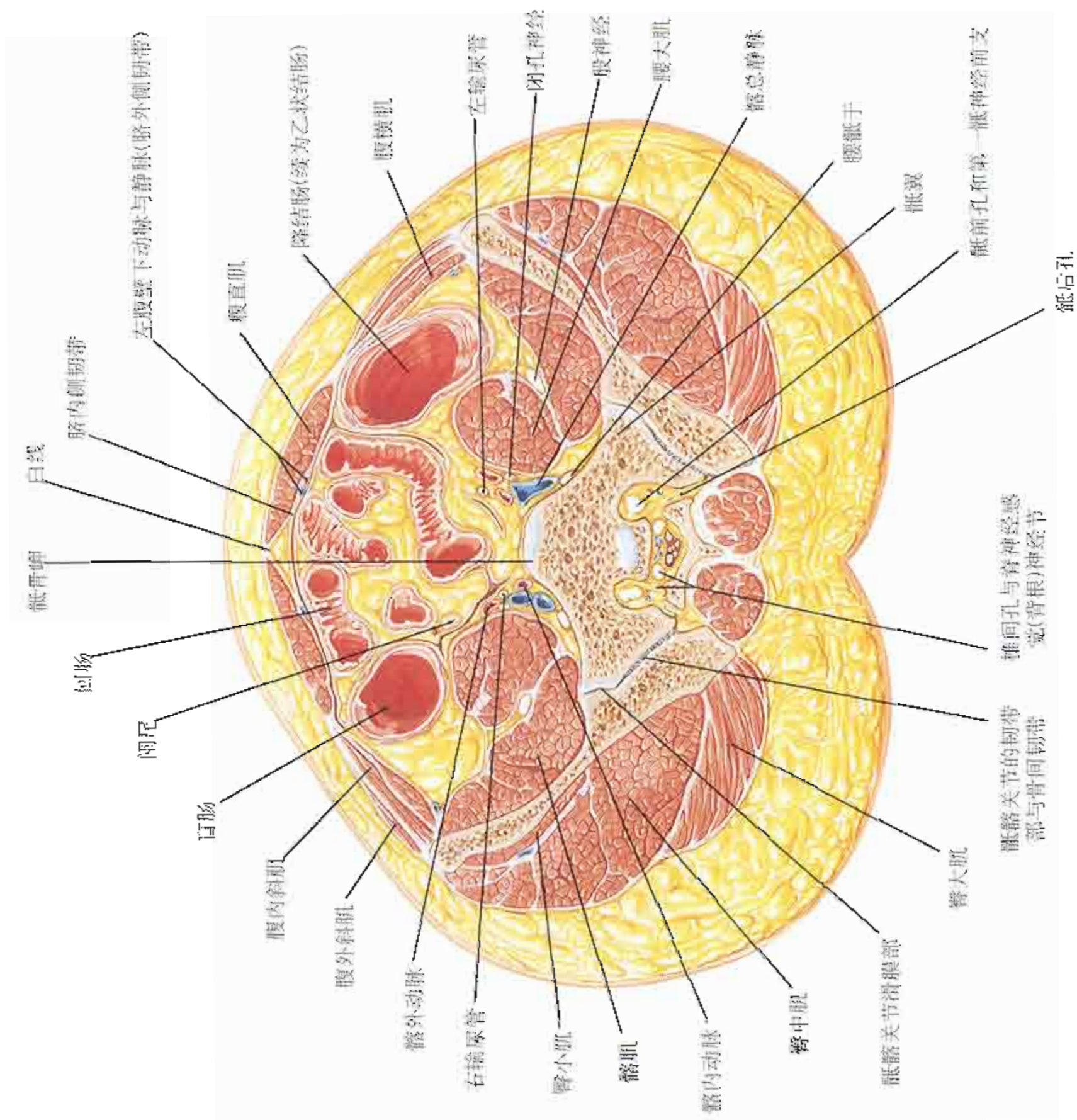


图539

横断面：耻骨嵴、股骨头、尾骨

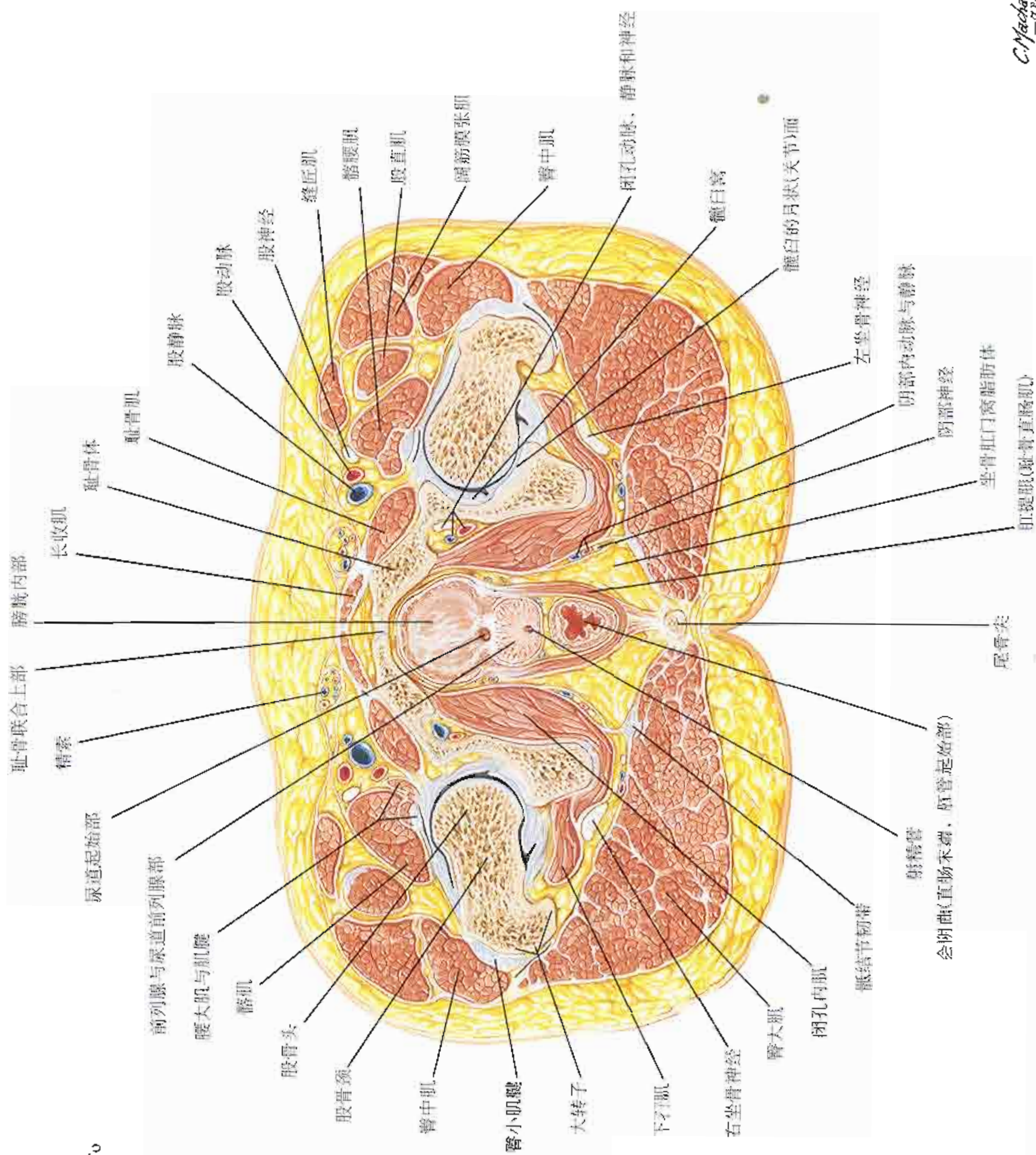
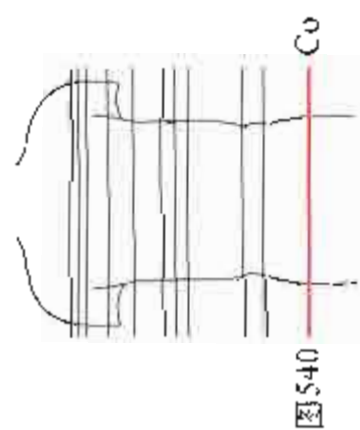

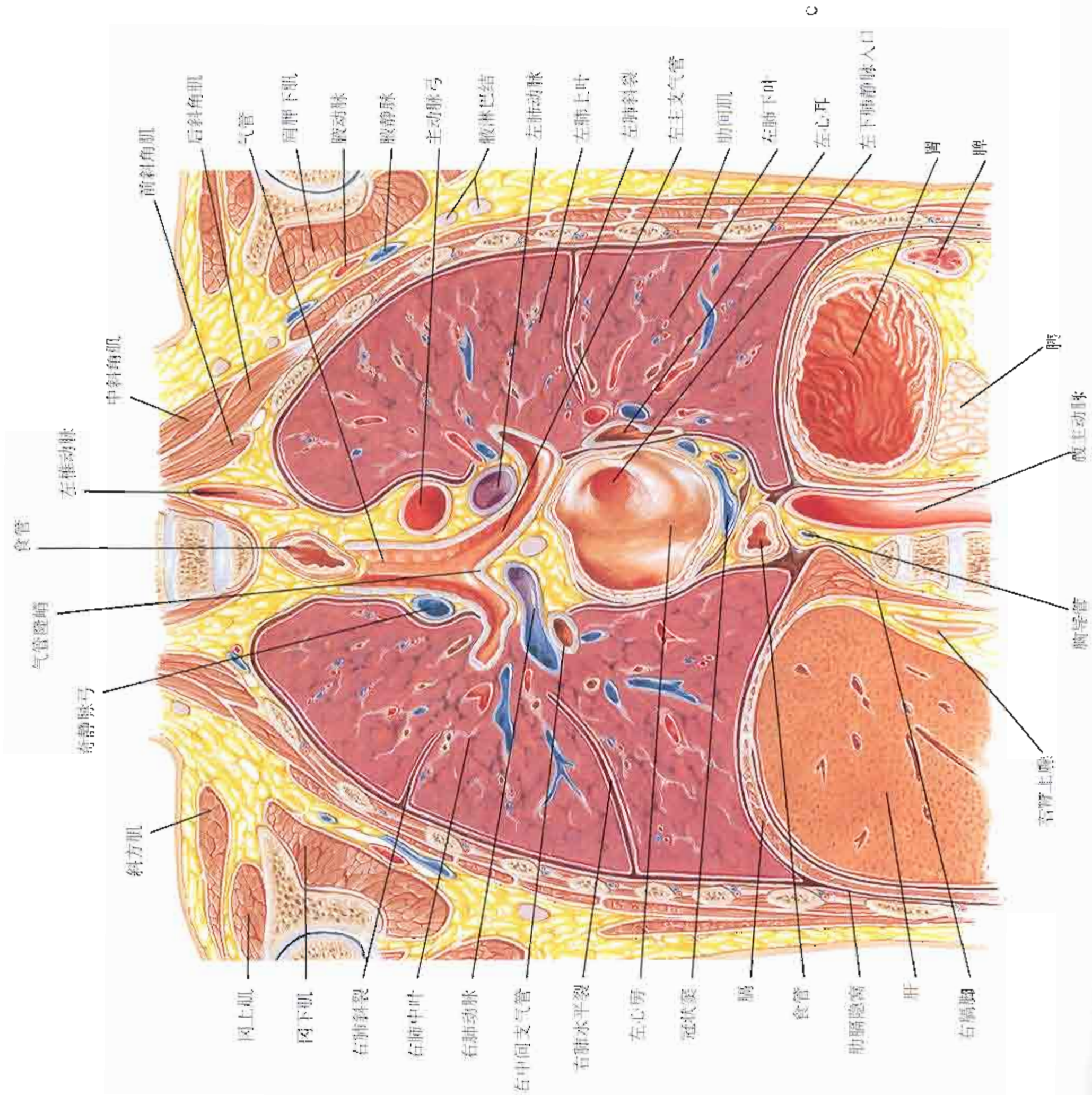

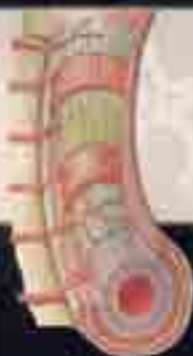
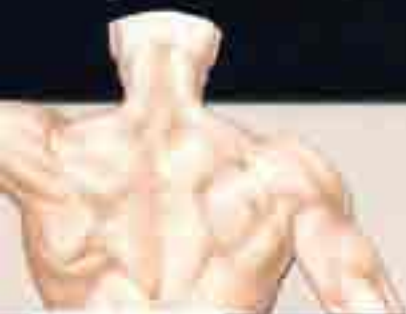图540



冠状断面：膈中线



C. Machado
M.D.
© ION



ISBN 7-117-09578-4



9 787117 095788 >

定价: 212.00 元

主编: 陈 斌
 责任编辑: 王 娟
 封面设计: 郭 勇
 版式设计: 韩红梅
 责任校对: 李 华